

Conclusions: Since arteritis is not a feature of SMA, elastase overactivity is a possible etiology that warrants further study. This final common pathway may explain the development of SMA in a number of apparently disparate conditions including autoimmune disease, alpha-1-antitrypsin deficiency and pregnancy.

258 The Value of C4d Detection in the Diagnosis of Humoral Cardiac Allograft Rejection

AM Safley, S Fedson, P Pytel, S Meehan, A Hussain. University of Chicago, Chicago, IL.

Background: Detection of C4d in endomyocardial biopsies (EMBs) has previously been correlated with the presence of detectable alloantibodies, early and late allograft complications, and cardiac graft loss. However, the clinical value of this marker for diagnosing cardiac humoral rejection has not been well-established.

Design: We evaluated C4d immunohistochemistry (IHC) in 64 archival paraffin-embedded EMBs from 26 cardiac transplant patients. Biopsies were graded as negative or positive for C4d capillary and interstitial staining. Positive biopsies were further graded as focal, diffuse, weak, or strong staining. Allograft survival and clinical status was obtained by chart review.

Results: Strong diffuse (5) and focal (10) capillary C4d staining was observed in 14 biopsies from 7 patients. C4d staining for all other patients showed either negative or focal weak vascular and interstitial reactivity. Among 4 patients with biopsies showing strong positivity, surveillance biopsies at additional time points, post-transplant, 2 months, and later, mean 7.2 months, showed persistent, strongly positive C4d staining. However, clinical cardiac function for these patients remained stable. In contrast, detection of strong C4d positivity for 2 patients appeared to be isolated to episodes of clinical rejection. Overall, negative and weak focal capillary and interstitial C4d staining was observed with similar frequency in normal surveillance biopsies and biopsies performed during episodes of clinical rejection.

Conclusions: Weak capillary and interstitial C4d staining in this study appears to be a nonspecific finding with little or no predictive value or correlation with humoral rejection. Moreover, our results suggest that the clinical correlation between strong C4d IHC positivity in EMBs and acute humoral rejection is unclear. The value of C4d in the diagnosis of humoral rejection remains unclear at this time.

259 Sustained Progression and Loss of Gender-Related Difference of the Atherosclerosis in the Very Old: A Pathological Study of 1,074 Consecutive Autopsy Cases

M Sawabe, T Arai, A Hamamatsu, K Chida, N Tanaka. Tokyo Metropolitan Geriatric Medical Center, Tokyo, Japan; Tokyo University, Tokyo, Japan.

Background: Recent epidemiological surveys show high cardiovascular mortality in females over 85 years, but it is unknown whether the atherosclerosis continues to worsen, or the gender-related difference exists in the very old. To address these issues, we have performed a pathological study of elderly autopsy cases.

Design: The subjects were 1,074 consecutive autopsy cases of in-hospital death. No medicolegal cases were included. The male to female ratio was 1.1:1 and the average age was 80 years. The autopsy rate was 40% and the brain was available in 85% of the cases. Macroscopic evaluation was performed on the atherosclerotic degrees of 10 large arteries including intracranial arteries, common carotid artery, aorta, coronary artery, superior mesenteric artery, and femoral artery.

Results: The severity of atherosclerosis differed greatly among arteries. The age-related increase of atherosclerotic degrees was evident, even after 80 years of age. The atherosclerosis was severer in males than in females in the 60's, but this male predominance decreased with ageing and finally disappeared in the 90's. The changing rate of age-related increase was especially high in the femoral arteries. The correlations of the atherosclerotic degrees among the arteries were generally good with simple correlation coefficients more than 0.4, except for splenic, superior mesenteric and intracranial arteries. The multiple regression analysis of the severity of systemic atherosclerosis showed significant contributions of traditional risk factors such as age (standardized regression coefficient = 0.459, $P < 0.0001$), smoking history (0.278, $P < 0.0001$), hypertension (0.210, $P < 0.0001$), and diabetes mellitus (0.089, $P < 0.005$). Parkinson's disease, chronic hepatitis/cirrhosis and some malignancy (lung cancer, gastric cancer and hematopoietic malignancy) lowered the risk of atherosclerosis. The multiple regression analysis showed the adopted risk factors accounted for 37.7% of the total variation in the systemic atherosclerosis.

Conclusions: The atherosclerosis continued to proceed in the very old. The gender-related difference of atherosclerosis was lost in the 90's. These data accounts for the high cardiovascular mortality in the female very old.

260 Proteomic Profiling of Human Vascular Intimal Proteoglycans

JR Stone, P Talusan, T Kattapuram. Massachusetts General Hospital, Harvard Medical School, Boston, MA.

Background: The proteoglycans are important components of the extracellular matrix and play key roles in vascular diseases. The proteoglycans are upregulated in thickened vascular intima, and are believed to contribute to atherosclerosis by binding and retaining lipoproteins in the vessel wall, and by promoting cell growth. Our current understanding of the complete extracellular proteoglycan composition of human intima is limited, as is our understanding of how this intimal proteoglycan composition varies between arteries with different susceptibilities to the development of atherosclerosis.

Design: Atherosclerosis-prone internal carotid arteries, at the level of the carotid bifurcation, and atherosclerosis-resistant internal thoracic arteries, at the level of the bifurcation of the intercostal arteries below the second rib, were obtained from autopsies. The vessels were first examined histologically; those displaying intimal hyperplasia, but not atheroma formation, were utilized for the proteomic analysis.

The thickened intima was dissected from the vessels, and the proteoglycans extracted and isolated using micro-scale anion exchange chromatography. The proteoglycan core proteins present were then identified using liquid chromatography tandem mass spectrometry.

Results: The extracellular proteoglycan profile of human vascular intima was readily obtained with this technique. This profile was found to be substantially more complex than previously realized with up to ten distinct proteoglycan core proteins present. Importantly, there was a significant difference in the intimal proteoglycan profile of the atherosclerosis-prone internal carotid artery compared with that of the atherosclerosis-resistant internal thoracic artery.

Conclusions: Proteomic techniques can be utilized to profile vascular intimal proteoglycan core proteins. There are significant variations in the intimal proteoglycan composition between different anatomical sites, and these variations may be responsible for the marked differences in susceptibility to atherosclerosis at these sites. Intimal proteoglycan profiling may be a useful approach for the subclassification of vascular diseases.

Cytopathology

261 Spermatogenesis Status in Azoospermic Patients, Correlation of Fine Needle Aspiration Results with Testicular Size and Hormonal Status

HA Abu-Farsakh. King Hussein Cancer Center & First Medical Lab, Amman, Jordan.

Background: The new advances in infertility by injecting sperms into ova, made finding rare sperms in the testis by fine needle aspiration (FNA) is of paramount importance. Azoospermic patients have variable degree of sperm production in the testis (varies from none to abundant).

Design: 720 azoospermic patients studied from the period (1/2000-12/2003). 10 fine needle aspirations from the testis (5 from the right and 5 from the left) were performed on each patient under local anesthesia. Spermatogenesis status reported as normal spermatogenesis (NS), hypospermatogenesis (HS), spermatogenesis arrest at spermatid stage (SATS), spermatogenesis arrest at spermatocyte stage (SACS), or sertoli cell only (SCO). Testicular size recorded as follow : normal testicular size, intermediate size: $\frac{3}{4}$ -1/2 of the normal size and small size: less than $\frac{1}{2}$ of the normal size. FSH hormone records available in 292 patients.

Results: sperms seen in 41% of all cases, regardless of their testicular size. Testicular size in azoospermic patients was noted to be as follows: 37% normal size, 32% intermediate size, 31% small size. Sperms seen at almost the same rate in normal testis compared with smaller type testis 39% vs. 37%. Patients with normal testicular size and normal hormones (total of 145 cases) may have the following spermatogenesis status: NS 17%, HS 32%, SATS 6%, SACS 26%, SCO 19%. Obstructive azoospermia was seen only in only 6% of all azoospermic patients, 15% of all patient containing sperms, and 17% of patient with normal testicular size. Of all patient with normal hormones, 49% have sperms, while sperms are much less seen in patient with abnormal hormones (in only 30%). Patient with less than normal testicular size and with abnormal hormones have 32% chance of having sperms. The number of sites sperms seen is much higher in normal size testis than in smaller testis, as sperms seen in 5-10 sites in normal size testis (27%), compared with 13% of smaller size testis.

Conclusions: Azoospermic patient have all the different cytopathological patterns in the testis (NS, HS, SATS, SACS, and SCO). Testicular size and abnormal hormones alone are not good predictors of finding sperms in the testis. Testis is a heterogeneous organ in sperm production. The more sites we sample the testis, the better chance of having sperms. FNA is an excellent procedure for multiple testicular samples with very high sensitivity in detecting spermatogenesis status in azoospermic patients.

262 Spectral and Spatial Analysis of Thyroid Fine Needle Aspiration Specimens Using the Hybrid Genetic Algorithm "GENIE"

C Angeletti, NR Harvey, V Bossuyt, RM Levenson, DL Rimm. Yale University School of Medicine, New Haven, CT; Los Alamos National Laboratory, Los Alamos, NM; CRI, Inc, Woburn, MA.

Background: Fine needle aspiration (FNA) of the thyroid is widely accepted as the most cost-effective diagnostic test. However, ambiguous diagnostic terms, such as suspicious or indeterminate, are a major limitation of this technique. GENetic Imaginary Exploitation (GENIE) is a recently developed artificial intelligence system that generates mathematical algorithms for the classification of images using spatial and spectral (color) analysis.

Design: Multispectral images from Papanicolaou stained cytology ThinPrep® slides from ten thyroid FNA specimens with surgical follow up were used as training data to distinguish benign follicular cells from papillary carcinoma. The images were imported into the GENIE platform through a Java tool graphical interface. The algorithms generated were tested on a separate validation set containing 46 FNA specimens (one high power image per slide).

Results: Through the use of selected training features, GENIE generated various algorithms that detect papillary carcinoma with sensitivities and specificities of up to 92 and 86 %, respectively. Because these algorithms are generally feature-specific, we designed a new experiment to test if they could be integrated by means of a second higher order algorithm in an analogous way to abstractive thinking. We performed four independent training sessions using the exact same training set, which generated four different algorithms, suggesting that each time GENIE randomly concentrated on particular classificatory features. The areas under ROC curve for each algorithm ranged between 0.771 and 0.828. Using the same platform, the result images of each algorithm in the training set were re-imported to generate a new second order algorithm capable of analyzing the information from the other four (first order) algorithms. On the validation

set, the second order algorithm performed with a highest combined sensitivity and specificity of 87.5 and 73 % respectively, and an area under the ROC curve of 0.862.

Conclusions: GENIE-based analysis of spectral and spatial information can distinguish benign cells from papillary carcinoma, with sensitivity and specificity comparable to cytopathology. Combination of unique algorithms, integrated through a higher order analysis improves the accuracy suggesting a series of algorithms may be attainable that will serve as a valuable ancillary test to classify equivocal thyroid FNAs.

263 Are Infections Other Than HPV Responsible for ASC-US?

DL Aslan, S Setty, GM Oprea, DM McKeon, RC McGlennen, SE Pambuccian. University of Minnesota, Minneapolis, MN.

Background: ASC-US is defined by nuclear changes (enlargement, irregularity and hyperchromasia) that are short of diagnostic for a squamous intraepithelial lesion. These changes are frequently caused by HPV infection; however the majority of cases of ASC-US are not caused by HPV infection. We have studied the role of other infections in causing cellular changes interpreted as ASC-US.

Design: 60 consecutive cases that had an ASC-US diagnosis made according to the 2001 Bethesda system on liquid based Pap tests (LBPT) (Surepath) from 12/01/01 to 12/15/01 were retrieved. The slides were reviewed and re-screened for morphologic evidence of microorganisms or viral cytopathic effect (cocci/bacilli (CB), Candida (CA), Trichomonas vaginalis (TV), herpes simplex virus (HSV), human papillomavirus (HPV)). DNA was extracted from the residual sample and four separate PCR reactions with primers specific for Chlamydia trachomatis (CT), HSV, HPV (MY9/MY11), and TV were performed on all samples. 46 random consecutive Pap tests were used as controls.

Results: Mean age of patients was 35 (range 13-80). 11.7% ASC-US cases, and 21.7% of controls contained morphologic evidence of infections. PCR additionally found 33.3% HPV and 3.4% other infections in the study group and 8.7% HPV and 2.2% other infections in the control group.

Results

	CB	Candida	T. vaginalis	HSV	HPV	C. trachomatis	Total
ASC Pap tests (n=60)							
-Morphology	3 (5.0%)	4 (6.7%)	0	0	0	0	11.7%
-PCR	ND	ND	1 (1.7%)	0	20 (33.3%)	1 (1.7%)	36.7%
Total	(5.0%)	(6.7%)	(1.7%)	0	(33.3%)	(1.7%)	48.4%
Controls (n=46)							
-Morphology	6 (13.0%)	3 (6.5%)	0	0	1 (2.2%)	0	21.7%
-PCR	ND	ND	0	0	5 (10.9%)	1 (2.2%)	13.1%
Total	(13.0%)	(6.5%)	0	0	(10.9%)	(2.2%)	32.6%

ND, not done

Conclusions: Microorganisms other than HPV are only accountable for a minority of cases of ASC-US not caused by HPV. The cause of the cellular changes interpreted as ASC-US in the other cases is unknown and may be resulting from hormonal changes, chemical, trauma, and atrophy. Molecular testing for Gardnerella, Mobiluncus and other agents of bacterial vaginosis and Candida as well as potentially other agents may increase the percentage of ASC-US that is attributable to infection.

264 Are "Inflammatory" Pap Tests Caused by Infection?

DL Aslan, DM McKeon, S Setty, GM Oprea, HE Gulbahce, RC McGlennen, SE Pambuccian. University of Minnesota, Minneapolis, MN.

Background: Inflammation (increased numbers of neutrophils) is frequently present in Pap tests (PT) and was responsible for "obscuring" of the epithelial cells and loss of sensitivity of the conventional Pap smear. Liquid-based Pap tests (LBPT) have largely eliminated the problem and allow detection of organisms that may be responsible for inflammation by performing molecular tests on the residual sample.

Design: "Inflammatory Pap tests" (IPT) were defined by the presence of over 20 PMNs/HPF (40x). 102 consecutive IPT were selected through review of 659 consecutive LBPT (Surepath). Mean age of patients was 33 (range 16-69). The slides were reviewed and rescreened for morphologic evidence of microorganisms or viral cytopathic effect (cocci/bacilli (CB), Candida species (CA), Trichomonas vaginalis (TV), herpes simplex virus (HSV), and human papillomavirus (HPV)). DNA was extracted from the residual sample and four separate PCR reactions with primers specific for Chlamydia trachomatis (CT), HSV, HPV (MY09/11 consensus primers), and TV were performed on all samples. A group of 46 consecutive PT without inflammation served as a control group.

Results: 21.3% vs. 21.7% of inflammatory Pap tests and controls contained infections (Table). PCR found 4.8% and 8.7% additional infections in cases and controls.

	cocci/bacilli	Candida	T. vaginalis	HSV	HPV	CT	Total
IPT (n=102)							
Morphology	8 (7.8%)	6 (13.0%)	1 (0.9%)	0	6 (5.9%)*	0	21.3%
PCR	ND	ND	2 (1.9%)	0	9 (8.8%)	1 (0.9%)	11.6%
Total	8 (7.8%)	6 (13.0%)	2 (1.9%)	0	9 (8.8%)	1 (0.9%)	25.1%
Controls (n=46)							
Morphology	6 (13.0%)	3 (6.5%)	0	0	1 (2.2%)*	0	21.7%
PCR	ND	ND	0	0	5 (10.9%)	1 (2.2%)	13.1%
Total	6 (13.0%)	3 (6.5%)	0	0	5 (10.9%)	1 (2.2%)	32.6%

*At least low grade dysplasia. ND - not done.

There were more Candida and Trichomonas infections and fewer cases with cocci/bacillary flora in the IPTs as compared to the controls. Importantly, there was no significant difference in HPV rates between the two groups.

Conclusions: Most of the inflammation seen in PT is most likely non-infectious in etiology and other factors such as chemical factors, trauma, and atrophy may be responsible for its presence. Molecular testing for Gardnerella, Mobiluncus and other agents of bacterial vaginosis, Candida and possibly other agents may increase the percentage of IPTs that are attributable to infection.

HPV infection was not more common in IPTs; moreover the presence of inflammation did not decrease the rate of detection of HPV-related morphologic changes in LBPTs.

265 Women with Squamous Cell Carcinoma but Mildly Abnormal Cytology: Review of the ALTS Trial Cases

KA Atkins, J Jeronimo, M Stoler, for the ALTS Trial. University of Virginia, Charlottesville, VA; National Cancer Institute, Bethesda, MD.

Background: Pap tests with an interpretation of atypical squamous cells of uncertain significance (ASCUS) or low grade squamous intraepithelial neoplasia (LSIL) occasionally come from women with underlying invasive squamous cell carcinoma (SCC). The ASCUS LSIL Triage Study (ALTS) was a 2 year trial that evaluated 5,060 women with ASCUS (3,488) and LSIL (1,572). This study describes the characteristics of the cancers identified in the course of the trial.

Design: The ALTS database was queried for all women with SCC. Their cytologic and surgical pathology material was reviewed and correlated with clinical course (time to diagnosis), HPV status, cervicography, and Pap test interpretations by the clinical center pathologist (CCP) and QC pathologist (QCP). Since most patients were diagnosed with carcinoma in less than a year, it is assumed that the women had carcinoma at the time of entrance into the study (i.e. cancer did not develop under observation). The database allowed focused review of patients with prevalent cancer to examine the relationship between their initial cytologic interpretation and outcome.

Results: 7 women had squamous cell carcinoma. Five referral Pap smears were interpreted as LSIL and 2 as ASCUS by the CCP; 3 were reinterpreted as HSIL by the QCP. Four of the entrance Pap tests (performed after the referral Pap smear) were interpreted as HSIL by the CCP and QCP. Although 3 women were randomized to conservative management and 1 to HPV triage, 6/7 patients had immediate colposcopy due to their initial randomization or the HSIL interpretation on entrance Pap test. All had high risk HPV by the Hybrid Capture 2 method and PGMY09/11 L1 consensus primer PCR. HPV remained positive until the lesions were entirely excised. One cervigram showed a visible lesion. Three patients had microinvasive carcinoma and four had at least stage IB invasive carcinoma.

Conclusions: * SCC accounted for 1/1,000 women with an ASCUS or LSIL interpretation, comprising 0.3% of women with high risk HPV.

* Sampling, interpretation, and lack of cervicographic evidence account for the missed cases.

* As shown in previous analysis of the ALTS data, oncogenic HPV type is an effective means of triaging women with mildly atypical cytology. All of these women would have been identified with an HPV triage after an ASCUS or LSIL cytology interpretation.

* Repeating the Pap test was effective in clarifying the initial interpretation.

266 Use of Mesothelin in Diagnosing Pancreatic Ductal Carcinoma on FNA Specimens

S Bean, I Elhoum, M Eloubeide, N Jhala, D Jhala, D Crowe, S Gallaspy, D Horton, B Green, DC Chheng. University of Alabama, Birmingham, AL.

Background: Cytologic diagnosis of fine needle aspiration (FNA) of pancreatic ductal carcinoma can be difficult due to morphologic overlap with reactive processes. Mesothelin is a 40kDa glycoprotein attached to the cell surface by phosphatidylinositol. Overexpression of mesothelin has been reported in the majority of the pancreatic ductal carcinoma but not non-neoplastic ductal epithelium. This objective of the study is to evaluate the use of mesothelin as a marker for pancreatic ductal adenocarcinoma on FNA specimens.

Design: Thirty-nine cell blocks of pancreatic FNA from 39 patients (21 females and 18 males with a median age of 64 years) were retrieved and immunostained with anti-mesothelin antibody (clone: 5B2; dilution 1:60; Novocastra Lab Ltd., New Castle upon Tyne, UK). A heat-induced epitope retrieval technique was employed. Immunostaining was performed on an automated stainer. Seven FNAs were from patients with reactive/inflammatory conditions. The remaining 32 FNAs included 28 pancreatic ductal carcinoma, 1 intracystic papillary mucinous carcinoma (IPMT), 1 neuroendocrine cell neoplasm, 1 lymphoma, and 1 sarcoma. The presence of immunoreactivity in more than 10% of the tumor cells, irrespective of level of intensity, was considered positive for mesothelin expression. Follow-up included correlation with pathology materials obtained at surgery and/or review of medical records.

Results: Twenty-six of 28 (93%) pancreatic ductal carcinomas and the IPMT demonstrated positive staining with mesothelin, ranging to focal to diffuse. Positive staining epithelial cells showed intense cytoplasmic staining especially at the apical (luminal) aspects with variable membranous staining. One of the 7 (14%) benign aspirates was positive for mesothelin. None of the non-ductal neoplasms demonstrated mesothelin expression. The difference in mesothelin expression between pancreatic ductal carcinoma and other lesions was statistically significant (p<0.0001, Fisher exact test). The sensitivity and specificity of mesothelin as a marker for pancreatic ductal carcinoma were 97% and 90%, respectively, with a likelihood ratio of 25:1.

Conclusions: Mesothelin is overexpressed in pancreatic ductal carcinoma with an intense apical cytoplasmic and variable membranous staining pattern. Our results suggest that the phenotypic expression of mesothelin can be used as a diagnostic marker of pancreatic ductal adenocarcinoma.

267 Is LSIL, Cannot Exclude HSIL (LGHSIL) a Valid Pap Test Interpretation?

CN Booth, R Massarani-Wajai, A Salhadar, J Weirick, EM Wojcik. Loyola University Chicago Stritch School of Medicine, Maywood, IL.

Background: The Bethesda System 2001 modified the terminology of atypical squamous cells (ASC) to include the category of ASC, cannot exclude HSIL. This interpretation is rendered if there are sparse single cells or small fragments of cells that approximate the size of metaplastic cells with nuclear to cytoplasmic ratios (N/C) similar to that of HSIL. The purpose of this study is to determine the follow-up (F/U) of patients who have similar atypical cells present in a background of unequivocal LSIL, but in which the interpretation is not HSIL.

Design: All Pap tests with LGHSIL were retrieved from the computer database for a one-year period. The F/U was compared to patients with LSIL and HSIL. The following data was recorded: age, patient history, sign-out cytotechnologist (CT), sign-out cytopathologist, CT initial interpretation, time to first F/U, time to diagnostic F/U, F/U procedure and F/U diagnosis. For each case, the most severe history and F/U were recorded. The F/U from each interpretation category was then compared.

Results: A total of 31/21,082 (.15%) LGHSIL interpretations were made by four cytopathologists. Of 20 patients with F/U, 13 (65%) had a cervical biopsy and/or endocervical curettage, one (5%) had a cone biopsy and 6 (30%) had Pap tests as diagnostic F/U. This group was compared to 51 LSIL and 42 HSIL patients with F/U. The mean age for LSIL, LGHSIL and HSIL were 29, 31 and 32 years. The average number of months to first F/U were 1.9, 2.9 and 1.6 months, respectively. The F/U results are detailed in Table 1.

Conclusions: In the 2001 Consensus Guidelines for the management of women with cervical cytologic abnormalities, the recommendations for patients with LSIL were repeat cytologic testing or colposcopy, whereas the recommendations for patients with HSIL were colposcopy with endocervical assessment (Wright, et al. JAMA, 2002;287:2120-9). This study shows that patients with LGHSIL had benign, LSIL (CIN 1) and HSIL (CIN 2-3/CIS) F/U at rates in between that of F/U for LSIL and HSIL patients. These results suggest that patients with LGHSIL may need more aggressive F/U (colposcopy with endocervical assessment) than patients with LSIL alone.

Table 1. Patient Follow-up of LSIL, LGHSIL and HSIL

Follow-up	Interpretation	
	LSIL # (%)	HSIL # (%)
Benign	14 (27)	4 (9)
ASC	1 (2)	0 (0)
LSIL (CIN 1)	30 (59)	7 (17)
LGHSIL	1 (2)	2 (5)
HSIL (CIN 2-3)+	5 (10)	29 (69)
Total	51 (100)	42 (100)

268 Diagnostic Value of CDX-2 and MUC-2 in Determining the Origin of Metastatic Adenocarcinoma in Fine Needle Aspiration Biopsies of the Liver

E Bracamonte, G Iezza, R Baehner. University of California, San Francisco, San Francisco, CA.

Background: CDX-2 is an intestinal transcription factor that is involved in the regulation of proliferation and differentiation of intestinal epithelial cells. Previous studies have shown that CDX-2 can be specifically expressed in intestinal epithelial and endocrine neoplasms. In human intestinal malignancy, many noninvasive tumors show alterations in the expression of mucins defined by the MUC-2 gene and MUC-2 positivity has been associated with a favorable clinical outcome. The value of CDX-2 and MUC-2 in identifying primary sites of metastatic adenocarcinoma in fine needle aspirations of liver metastases has not been studied.

Design: Twenty-two FNA cases of metastatic carcinoma to the liver from various sites were retrieved from the department of pathology's archives from 2001-2004. In all cases the location of the primary tumor was confirmed with immunocytochemical studies of cytokeratins 7 and 20 and/or by clinical history. The FNA formalin fixed paraffin embedded cell blocks were recut and the immunostaining for CDX-2 and MUC-2 was performed on a DAKO Autostainer Universal Staining System with appropriate positive and negative controls.

Results:

Antibodies	CDX-2	MUC-2
Primary sites (cases):		
Colorectal/colon	100% (10/10)	10% (1/10)
Stomach	100% (1/1)	0% (0/1)
Ovarian	0% (0/2)	0% (0/2)
Breast	0% (0/1)	0% (0/1)
Gallbladder/cholangiocarcinoma	0% (0/3)	0% (0/3)
Pancreatic	0% (0/2)	0% (0/2)
Unknown	0% (0/3)	0% (0/3)

Conclusions: CDX-2 is a sensitive and specific marker for identifying metastatic gastrointestinal adenocarcinoma to the liver. When metastatic carcinoma is identified by FNA cytology, an immunocytochemical panel that includes CDX-2 is useful in determining the origin of the metastasis. MUC-2 was not identified in the majority of the metastatic adenocarcinomas and does not warrant inclusion in a diagnostic immunocytochemical panel.

269 Ki-67 and p53 Antigen Detection in Aspiration Biopsies of Non-Small Cell Carcinoma of the Lung (NSCLC)

N Cai, A Kramer, D Yankelevitz, C Henschke, M Vazquez. New York Presbyterian Hospital-Weill Cornell Medical Center, New York, NY.

Background: Immunohistochemistry of Ki-67 and p53 may provide significant prognostic information for patients with NSCLC. We wanted to evaluate the ability to determine the expression of these antibodies pre-operatively on cell block and ThinPrep material of aspiration biopsies of NSCLC.

Design: We identified 48 cases of NSCLC that had prospective analysis of Ki-67 and p53 on FNA cell blocks (n=28) or ThinPrep (n=20) and underwent surgical resection at our institution. Of these, we classified lung adenocarcinomas into four groups: adenocarcinoma (ADC), adenocarcinoma with an extensive bronchioloalveolar growth pattern (ADC-BAC), bronchioloalveolar carcinoma (BAC) and mucinous BAC. Cases with readily visible nuclear staining of 5% of tumor cells were considered positive.

Results: The tumor type of the 48 NSCLC in 48 patients (age: 51 to 82 years; mean: 66) was: ADC in 13 (27%), ADC-BAC in 12 (25%), BAC in 12 (25%), mucinous BAC in 1 (2%), large cell carcinoma in 2 (4%), metastatic adenocarcinoma in 2 (4%), and squamous cell carcinoma in 6 (13%). Of the ADC cases, Ki-67 values ranged from 10 to 100% (mean: 40.8%), seven (54%) had a high proliferation index [HPI] (>50%), and six (46%) were p53+ (mean 21.4%). Of the ADC-BAC, Ki-67 values ranged from 5 to 20% (mean: 15%) and none had a HPI, and four (31%) were p53+ (mean 3.8%). Of the BAC, Ki-67 values ranged from 5 to 25% (mean: 13%), none (0%) had a HPI, and none (0%) were p53+. Of the squamous cell carcinomas, Ki-67 values ranged from 10 to 90% (mean: 54.2%), four (67%) of the cases had a HPI, and three (50%) were p53+ (mean 28.3%). The one case of mucinous BAC had a Ki-67 value of 10% and p53 of 50%. Of two cases of metastatic adenocarcinomas, Ki67 values were 15% and 90% and p53 was 50% and 70%. Of two cases of large cell carcinoma, Ki67 values ranged from 5 to 25% (mean: 15%) and p53 from 75% to 90% (mean: 83%). The Ki-67 labeling index increased significantly from pure BAC, to ADC-BAC, to adenocarcinoma (X²=69.71, p<0.001).

Conclusions: The Ki-67 and p53 labeling increased from pure BAC to invasive cancer. Ki-67 and p53 expressions were significantly higher in adenocarcinoma, squamous cell carcinoma, large cell carcinoma, and metastatic adenocarcinoma than in BAC. These results strongly indicate that Ki-67 and p53 abnormalities are associated with invasive growth of tumor cells.

270 Differences in High Risk Human Papilloma Virus Testing Results in Pregnant and Non-Pregnant Women with Atypical Squamous Cells of Undetermined Significance

ES Campenot, JF Shikle, MY Lin. Naval Medical Center San Diego, San Diego, CA.

Background: Numerous Pap smears are performed on pregnant or post-partum women. The associated hormonal changes effect the cervix causing cytologic changes that can lead to classification of Pap smears as Atypical Squamous Cells of Undetermined Significance (ASCUS). When using Thinprep® liquid based cytology, Hybrid Capture®II HPV testing for high risk human papilloma virus DNA (HRHPV) is performed on cases classified as ASCUS. Because pregnancy may be a state of immunomodulation, the rate of HRHPV positivity may be different in these patients. This study was designed to see if there was a difference in the fraction of HRHPV positive cases in pregnant versus non-pregnant women with a diagnosis of ASCUS.

Design: Pap smear reports classified as ASCUS with HRHPV testing results from the year 2003 were reviewed. Pregnancy or post-partum status (PG/PP), age, and HRHPV (positive or negative) results were tabulated. Data from non-pregnant (NP) women over 45 years of age and the cases where HRHPV results were indeterminate were excluded. Calculations were made to determine if there was a difference in the HRHPV results in PG/PP versus NP groups.

Results: 570 Pap smears classified as ASCUS with HRHPV testing results were analyzed. HRHPV was positive in 37.5 % of women with ASCUS. 95 women were pregnant or post-partum (16.7 %), and of these women 50.5 % (48 of 95) were positive for HRHPV. Of the non-pregnant women with ASCUS under 45 years old, 34.9 % (166/475) were HRHPV positive. Chi-square analysis demonstrated a statistically significant difference in the rate of HRHPV positivity between PG/PP and NP groups (p= 0.004).

Conclusions: The rate of HRHPV positivity was greater (50.5 % versus 34.9 %) in pregnant and post-partum women with ASCUS when compared to non-pregnant women under 45 years of age with ASCUS, and this difference was statistically significant in our study. The clinical significance of this finding is currently unknown, but a future study of colposcopic and biopsy findings is planned to see if pregnant women with ASCUS and a positive HRHPV test might be able to be managed differently.

DISCLAIMER: "The views expressed are those of the author and do not reflect the official policy or position of the department of the Navy, Department of Defense, or the United States Government."

HRHPV RESULTS IN WOMEN UNDER 45 YEARS

Pregnant/ PP	HRHPV POS	HRHPV NEG
YES	50.5 %	49.5 %
NO	34.9 %	65.1 %

271 Fine-Needle Aspiration Cytology of Schwannoma and Its Distinction from Other Spindle Cell Lesions

AA Chen, GT McKee, V Deshpande. Massachusetts General Hospital, Boston, MA.

Background: There is a growing awareness that FNAC, when viewed in conjunction with clinical and radiological data has a role in the primary diagnosis of soft tissue neoplasms. Although the cytological features of schwannoma are well-recognized, a number of other spindle cell lesions mimic schwannomas. Our aim was to retrospectively analyze schwannomas and its mimics in an attempt to develop criteria that would help distinguish them on FNAC.

Design: 41 FNAC specimens with a cytological interpretation of spindle cell neoplasm and histological follow-up were retrieved from the MGH pathology files. Twenty one schwannoma were compared to its potential mimics including gastrointestinal stromal tumor (GIST) (7), low-grade leiomyosarcoma (3), fibromatosis (2), solitary fibrous tumor (2), dermatofibrosarcoma protuberans (1), extraskelatal myxoid chondrosarcoma (1), nodular fasciitis (1), organizing hematoma (1), myoepithelioma (1), and low-grade fibromyxoid sarcoma (1). Cytomorphological features semiquantitatively graded included cellularity, background bare nuclei and spindle cells with intact cytoplasm,

fascicular pattern, fish-hook nuclei, nuclear inclusions, diffuse nuclear atypia and hyperchromasia. Dramatic nuclear pleomorphism was defined as greater than a two-fold variation in the size of nuclei within cell aggregates.

Results: The cytomorphological features of schwannomas included moderate to highly cellularity, with cells arranged in cohesive tissue fragments with fibrillary to fibrous stroma. Fish hook-like nuclei were seen in 9 schwannomas (42.8%) and 5 non-schwannoma cases (20%) ($p=NS$). Nuclear inclusions were found in 11 schwannomas (55%) and one GIST (5%) ($p=0.003$). Dramatic nuclear pleomorphism was identified in the majority of schwannoma cases (16,76.1%) and in 4 non-schwannoma cases (20%) ($p=0.003$). Spindle cells with cytoplasm were noted in 4 (20%) schwannomas and 17 (80.9%) non-schwannoma cases ($P=0.001$). Varocay bodies were seen exclusively with schwannomas (3 cases). The other cytomorphological features did not show statistically significant differences between the two groups.

Conclusions: This study confirms the previous observations that spindle cell tissue fragments with fibrillary stroma, fishhook nuclei and nuclear inclusions are the cytomorphological features of schwannomas on FNAC. However some of these features are shared with other spindle cell mesenchymal lesions. The presence of dramatic nuclear pleomorphism and absence of single spindled cells with intact cytoplasm could help exclude potential schwannoma mimics.

272 Ultrasound-Guided Fine Needle Aspiration Biopsy of Thyroid Lesions: A 5-Year Experience

L Chen, AM Maslan, WA Reeves, RM DeMay. University of Chicago, Chicago, IL.

Background: US-FNAB of the thyroid lesions has gained wide acceptance for detecting occult thyroid carcinoma in nonpalpable thyroid nodules. This technique, however, is not without difficulty and US-FNAB of thyroid is generally less reliable for diagnosis than standard FNAB of palpable nodules. Our group studied the sensitivity, specificity, positive (PPV) and negative predictive value (NPV) of this technique. In addition to reviewing the causes of false negative results, we are interested in studying the true positive cases to see if the indications for US-FNAB were justified.

Design: A computer search of all cases of US-FNAB thyroid lesions at our institution from 1999 to 2003 was done. A total of 216 nodules were biopsied in 201 patients which include 39 non-diagnostic cases (18%), 139 benign lesions (64%; 124 colloid nodules; 14 Hashimoto thyroiditis; 1 granulomatous thyroiditis), 26 cellular nodules (12%), 3 Hurthle cell nodules (1%), 7 papillary carcinomas (3%), one medullary carcinoma and one metastatic carcinoma. Rapid cytology review was performed on all the cases. Forty-eight of the 216 (22%) study cases had subsequent surgery and histology. Cyto-histological correlation was done on cases with surgical follow-up. Patient's charts were reviewed in true positive cases.

Results: Of the 48 cases with surgical follow-up; 36 cases of benign lesions were confirmed as benign by histology, 4 of 5 cases of "cellular nodule" were histologically "follicular adenoma", one case of "Hurthle cell nodule" was histologically a "Hurthle cell adenoma", and 6 cases of "papillary carcinoma" were confirmed by histology. The remaining patient with "cellular nodule" was found to have "papillary carcinoma" (false negative result). The cause of the false negative was sampling error. After reviewing the patients' charts in the 6 true positive cases, we found that 2 cases were actually palpable lesions not requiring ultrasound to locate and the remaining 4 were patients with known papillary carcinoma who had recurrent disease in the neck. Thus, these 4 cases are actually "neck," rather than "thyroid" FNABs.

Conclusions: The sensitivity of US-FNAB for papillary carcinoma at our institution is 85% with a specificity of 100% (including sampling error). The PPV and NPV are 100% and 85%, respectively. However, no cases of nonpalpable primary carcinoma were identified and confirmed by biopsy. Given the high prevalence of nonpalpable thyroid nodules and the minimal mortality of occult carcinoma, systematic effort to examine every thyroid nodule by US-FNAB is probably not justified.

273 Cytologic Diagnostic Strategy for Lymphomas and Other Intraocular Entities in Vitrectomy Specimens

P Chevez-Barrios, K Rishi. The Methodist Hospital, Houston, TX; Baylor College of Medicine, Houston, TX.

Background: To investigate the role and value of various techniques used to diagnose lymphomas, non-granulomatous and granulomatous chronic vitritis, endophthalmitis, and other entities in vitreous specimens with emphasis in small amounts of specimen available.

Design: We reviewed 160 consecutive vitrectomy specimens including vitrectomy taps and washings retrospectively from 1998 to 2004. We compared the yield of liquid-based cytology, cytospin, cell block, immunohistochemistry, flow cytometry and gene rearrangement by PCR in the diagnosis of lymphomas, non-granulomatous and granulomatous chronic vitritis, endophthalmitis, and other entities.

Results: 18 cases (11.25%) were reported as lymphomas (16 cases of B-cell type and 2 cases of T-cell type). Of the remaining vitrectomy specimens, 40 (25%) were non-granulomatous chronic vitritis, 53 (33.125%) were granulomatous vitritis, 13 (8.125%) were endophthalmitis, and 36 (22.5%) were other entities including hemorrhage, asteroid hyalosis, malignant melanoma, etc. There was an adequate sample for diagnoses in 97% of the vitrectomy specimens. Lymphomas were diagnosed using a combination of liquid-based cytology and flow cytometry in 15 cases, gene rearrangement by PCR in 1 case, and cell block and immunohistochemistry in 2 cases. Liquid-based cytology was sufficient for triaging and diagnosing in 79% of the vitrectomy specimens in the remaining non-lymphoma cases.

Conclusions: This strategic approach to vitrectomy specimens demonstrates the high diagnostic yield of liquid-based cytology using even less than 1 ml of undiluted vitreous. It allows for adequate triaging of the specimen when ancillary studies are required, especially when small amount of specimen is available. Flow cytometry proved to be a valuable adjunct in diagnosing intraocular lymphomas versus non-granulomatous vitritis.

274 Rapid Stamp Cytologic Interpretation of Nasopharyngeal Biopsy: Usefulness and Pitfalls

A-Y Chuang, M-L Wu, M-H Tsou. Koo Foundation Sun Yat-Sen Cancer Center, Taipei, Taiwan.

Background: Rapid stamp cytologic interpretation of nasopharyngeal biopsy is frequently requested by head and neck surgeons to evaluate specimen adequacy and also to expedite clinical management. The objective of this study was to analyze the test sensitivity and specificity. We also focused on the cytologic patterns of false negative cases. The results may be helpful to improve the interpretation accuracy of fine needle aspiration on metastatic lesions of nasopharyngeal origin.

Design: Nasopharyngeal stamp cytology slides and biopsy H&E sections were collected and reviewed from 1997 to 2004. All cytology slides were stained by a Romanovsky-type stain (Riu's stain), some of them also had paired Papanicolaou-stained slides. Suspicious cytology results were regarded as negative.

Results: There were 174 nasopharyngeal stamps performed. The cytologic diagnosis was categorized into four groups: benign, 54; suspicious, 11; malignant, 104; and inadequate specimen, 5. There were 24 false-negative and 2 false-positive diagnoses. Our results showed a sensitivity of 80.6% and a specificity of 95.3% for the detection of malignancy. One false negative case was a lymphoblastic lymphoma. The other false negative cases were biopsy proven to be nasopharyngeal carcinomas. The main cytologic patterns of these nasopharyngeal carcinoma smears included scattered single cells (11 cases), clustered nuclei (6 cases), and venule-like tissue fragments (3 cases).

Conclusions: Rapid nasopharyngeal biopsy stamp cytology works well in our hospital with acceptable sensitivity and specificity. Familiar with the several common false negative cytology patterns will be useful to those who lack pertinent experience in this field. Examine any large single cells or crushed cell clusters under higher magnification with scrutiny can prevent most of the false negative interpretation. We also believe experience from the present study can apply to the interpretation of a fine needle aspiration cytology on a metastatic nasopharyngeal carcinoma from any location.

275 Cytologic-Histologic Correlation of Screening and Diagnostic Pap Tests

DJ Chute, J Covell, SE Pambuccian, EB Stelow. University of Virginia, Charlottesville, VA; University of Minnesota, Minneapolis, MN.

Background: Most studies that regard the function of the Pap test (PT), investigate its function as a screening test for cervical squamous cell carcinoma or high-grade squamous intraepithelial lesion (HSIL). Although the PT is most commonly used as a screening test, it can be used as a "diagnostic test," usually in patients with known or suspected lesions. We have recently shown that the yield of atypical interpretations in diagnostic Pap tests (DPTs) is nearly 5 times greater than the yield for screening Pap tests (SPTs). As the populations in which these two tests are used vary with respect to disease prevalence, we speculated that the PT may function differently in each population.

Design: Cytologic-histologic correlation results for PTs accessioned between 4/1/03 and 7/31/03 were reviewed. PTs were considered SPTs or DPTs depending on the billing codes used by referring physicians. Original PT interpretations and tissue biopsy results were recorded. Results were compared for SPTs and DPTs.

Results: We found 641 PTs (257 SPTs and 384 DPTs) that had follow-up biopsy (FUB). Of SPTs interpreted as no intraepithelial lesion or malignancy (NILM) ($n=120$), 14 (11.7%) showed SIL or worse and 4 (3.3%) showed HSIL or worse on FUB. Of SPTs interpreted as atypical squamous cells (ASC) ($n=73$), 32 (43.8%) showed SIL or worse and 8 (11.0%) showed HSIL or worse on FUB. Of SPTs interpreted as low-grade squamous intraepithelial lesion (LSIL) ($n=51$), 27 (52.9%) showed SIL or worse and 8 (15.7%) showed HSIL or worse on FUB. Of SPTs interpreted as HSIL ($n=12$), 9 (75.0%) showed SIL or worse and 9 (75.0%) showed HSIL or worse on FUB. Of DPTs interpreted as NILM ($n=117$), 28 (23.9%) showed SIL or worse and 3 (2.6%) showed HSIL or worse on FUB. Of DPTs interpreted as ASC ($n=84$), 33 (39.3%) showed SIL or worse and 12 (14.3%) showed HSIL or worse on FUB. Of DPTs interpreted as LSIL ($n=116$), 76 (65.5%) showed SIL or worse and 15 (12.9%) showed HSIL or worse on FUB. Of DPTs interpreted as HSIL ($n=64$), 53 (82.8%) showed SIL or worse and 46 (71.9%) showed HSIL or worse on FUB. DPTs interpreted as NILM were more likely than SPTs to show SIL on FUB ($p=0.01$), otherwise there were no significant differences on FUB.

Conclusions: Despite the difference in disease prevalence between women having SPTs and DPTs, the PT seems to function relatively the same in both scenarios. This may in part be due to the fact that samples submitted for SPT also undergo HPV testing when ASC interpretations are rendered.

276 Utility of GLUT 1 Immunostaining in Transbronchial Needle Aspiration Biopsies

LE De Las Casas, RH Bardales, P White, LJ Cloar, P Mukunyadzi, M Thomas, RN Miranda. University of Arkansas for Medical Sciences, Little Rock, AR; University of Minnesota, Minneapolis, MN; Truman Medical Center, Kansas City, MO.

Background: Transbronchial needle aspiration biopsy (TBNAB) is a reliable, and minimally invasive bronchoscopic procedure for diagnosing and staging lung cancer, obviating the need for mediastinoscopy or thoracotomy for some patients. However,

limited amount of representative material from the tumor is a common cause of non-definitive diagnosis.

Glut1, a facilitative cell surface glucose transport protein, which in most normal tissue is restricted to erythrocytes, and perineurium of peripheral nerves, is aberrantly expressed in many cancers. We evaluated the expression of Glut1 by immunohistochemistry on TBNAB material to determine its utility in increasing the accuracy in the diagnosis of carcinomas.

Design: A 5-year retrospective review of all TBNABs with cell block material, radiologic studies, and histologic confirmation was performed at our institution. Cell block material from 22 non-small cell carcinomas (NSCC), including 12 squamous cell carcinomas (SCC), 4 adenocarcinomas (AdC), 1 large cell carcinoma (LCC), and 5 poorly differentiated non-small cell carcinomas (PDNSCC); 12 small cell carcinomas (SmC), 2 non-Hodgkin lymphomas, B cell type, and 10 benign lesions (6 granulomatous processes, 2 pneumonias, 1 abscess, and 1 bronchogenic cyst) were obtained and immunostained with anti-Glut1 (Dako). Glut1 expression was considered positive when at least 5% of lesional cells exhibited distinct cell membrane reactivity.

Results: Immunoreactivity for Glut1 was observed in 19 of 22 NSCCs; 12 of 12 SCC, 4 of 4 AdC, 1 of 1 LCC, and 2 of 5 PDNSCCs. SmC displayed Glut1 positivity in 8 of 12 cases. The two lymphomas and ten benign specimens were all Glut1 negative. The use of Glut1 immunoreactivity in cell block material improved the overall sensitivity (from 76% to 82%) and negative predictive value (from 60% to 67%) of TBNABs for diagnosing carcinomas. The specificity and positive predictive value remained unchanged at 100%. Glut1 staining identified 8 of 34 (23%) carcinomas on cell block material that were previously non-diagnostic TBNAB.

Conclusions: Glut1 immunostaining in cell block material from TBNABs can improve the diagnostic yield in cases of NSCC and SmC.

277 Clinical Significance of a Positive Urovysion FISH Study in Patients with Negative Concurrent Urine Cytology

MN de Peralta-Venturina. William Beaumont Hospital, Royal Oak, MI.

Background: Recent studies have shown that multitarget fluorescence in situ hybridization (FISH) probe set Urovysion (Vysis, Downers Grove, Illinois) containing probes to chromosome 3,7 and 17, and to the 9p21 band is more sensitive compared to urine cytology in detecting urothelial carcinoma. It is not clear what a positive FISH study mean in patients with history of bladder cancer with negative concurrent urine cytology.

Design: Urovysion was performed in 94 consecutive urine samples from 81 patients over a 10-month period (June 2003-March 2004) in our institution. Twelve (12.7%) samples had too few cells to analyze or were suboptimal for analysis due to technical reasons. Of the remaining 82 samples, there were 52 (63.4%) with concurrent urine cytology. This subgroup forms the basis of this study. Results of Urovysion assay was correlated with concurrent urine cytology and clinical follow-up, including subsequent biopsies.

Results: There were 16 positive FISH assays (30.8%); 7 of these had negative, 1 atypical (therapy-related atypia), 6 suspicious and 2 positive concurrent urine cytologies. Six of the 7 FISH positive urine cytology negative patients had history of resection of low grade (Grade 1 or 2) Ta or T1 bladder cancer and intravesical chemotherapy. Follow-up was available in 6 of these patients: 1 patient had subsequent positive bladder biopsy (3 months later); 2 with negative follow-up urine cytologies (4-7 mos. later) but without biopsy or cystoscopic studies; and 3 with negative follow-up biopsies and extensive cystoscopy and upper tract studies, i.e. cystourethroscopy, bilateral retrograde pyelogram, ureteroscopy and nephroscopy. One of these 3 patients had positive FISH study on a right ureteral washing specimen and subsequent positive bladder biopsy but no lesion was identified in the ureters. Another patient had positive repeat FISH study but extensive work-up failed to show disease recurrence 8 months after the initial positive FISH.

Conclusions: In our experience, only 50% of urine samples that were FISH positive showed abnormal concurrent urine cytology. In some patients with known bladder cancer, it is not clear what an isolated positive FISH study mean in a urine sample. Nevertheless, continued and exhaustive clinical work-up may be necessary to establish definitive disease recurrence.

278 Ultrasound-Guided Fine Needle Aspiration of Parathyroid Lesions

HH Dimashkieh, S Krishnamurthy. MD Anderson Cancer Center, Houston, TX.

Background: The parathyroid gland (PG) and PG tumors comprise a small proportion of nonpalpable neck masses that are investigated by ultrasound guided (US) fine needle aspiration biopsy (FNAB). There are very few studies that have reported the utility of FNAB in establishing a preoperative diagnosis for these lesions. We studied our cases of FNAB of PG and PG tumors to establish the cytomorphology, possible pitfalls, and the role of ancillary immunocytochemistry (ICC) in these lesions.

Design: All cases of FNAB of PG and PG tumors in the last 10 years were reviewed in detail and correlated with the histopathologic findings of the surgical excision when available. Cytologic parameters studied included cellularity (1+, 2+, and 3+ based on the presence of <50, 50-500, and >500 cells), cellular distribution (single cells, small loose and cohesive clusters, three dimensional clusters, follicles), nuclear features (shape, nuclear chromatin, mitosis) and background material (colloid/pseudocolloid).

Results: Eighteen retrospective cases of FNAB of PG and PG tumors (12 neck, 2 thyroid, 2 thyroid bed, 1 liver and 1 mediastinum) were studied. The cellularity was 1+, 2+, and 3+ in 4, 2, and 12 cases, respectively. The smears showed cells distributed predominantly as small loose clusters with many single cells scattered in the background. Few cases showed 3-dimensional clusters (n=2), follicles (n=3) and colloid/pseudocolloid (n=2) were present. The individual cells had small round nuclei, finely stippled chromatin, minimal nuclear pleomorphism, and scant amount of delicate cytoplasm. There was no significant variability in the cytomorphologic features of the smears in the cases subsequently diagnosed as normal (n=1), adenoma (n=9) and

carcinoma (n=4). ICC for parathyroid hormone (PTH) was performed on 12 cases (5 smears, 7 cell blocks) and showed distinct cytoplasmic positivity.

Conclusions: 1- Ultrasound-guided FNAB is a useful test in confirming the diagnosis of clinically suspected PG lesions as well as in establishing the presence of PG in unsuspected locations (thyroid bed, mediastinum, and intrathyroid).

2- The different PG lesions (normal, hyperplasia, adenoma, carcinoma) cannot be distinguished solely on cytology.

3- Although there is some overlap of the cytomorphologic features of PG with thyroid gland, the presence of finely stippled nuclear chromatin and absence of colloid are useful distinguishing features.

4- ICC for PTH can be used for the determination of the parathyroid nature of the lesion.

279 Cytologic Features of Urothelial Carcinoma in Instrumented Urines with Cellular Fragments

MM El-Fakharany, PF Mazzara. St John Hospital, Detroit, MI.

Background: The presence of cell clusters in smears of instrumented urine frequently presents a challenge for the cytopathologist as to whether these clusters are indicators of urothelial neoplasms versus being mere instrumentation artifact. We present our own experience along the past several years to highlight the architectural and cytomorphological differences that might help the cytopathologist markedly reduce the number of equivocal cases.

Design: We examined 73 cytology smears of instrumented urine containing urothelial cell clusters dated between 1998 and 2004. All of these patients had at least one follow-up biopsy. Smears were reviewed blindly without knowledge of the follow-up diagnosis. The morphological features reviewed included the presence of a thin rim of cytoplasm (collar) around cell fragments, regularity of fragment border, fragment size, percentage of fragments in relation to total cellularity, nuclear size, nuclear chromatin, and the presence or absence of nucleoli or background inflammation. Results were then analyzed and correlated with the follow-up diagnosis to determine which parameters were most helpful in distinguishing benign cell clusters from urothelial carcinoma.

Results: Of the 73 smears, 39 had a benign diagnosis on follow-up biopsy and 34 were found to have urothelial carcinoma on biopsy. A cytoplasmic collar was present in 29 (74%) smears with a benign follow-up biopsy and 5 (15%) smears with urothelial carcinoma on biopsy (p<0.0001). Regular and rounded fragment borders were identified in 31 (80%) smears with a benign biopsy and 8 (24%) with urothelial carcinoma (p<0.0001). Fine nuclear chromatin was detected in 25 (64%) smears with a benign follow-up and in 6 (18%) with urothelial carcinoma (p<0.0001). Nuclear size averaged 12 microns in the smears with benign pathology and 16 microns in those with urothelial carcinoma. All seven cases with a nuclear size of 20 microns or more had urothelial carcinoma on follow-up biopsy. No statistically significant differences were identified for the presence of background inflammation or nucleoli with regard to benign or malignant follow-up biopsy. Of the 17 smears that had a cytoplasmic collar, regular fragment borders and fine nuclear chromatin, only one (6%) was found to have urothelial carcinoma on follow-up biopsy. Of the 20 smears in which these three features were absent, all twenty contained urothelial carcinoma on biopsy.

Conclusions: Certain architectural and nuclear features can be used to help differentiate urothelial neoplasms from instrumentation artifact in urine cytology smears.

280 Comparison of ThinPrep and Cytospin Preparations in the Evaluation of Nongynecologic Specimens

TM Elsheikh, JL Kirkpatrick, HH Wu. Ball Memorial Hospital, Muncie, IN.

Background: Although numerous studies have examined ThinPrep (TP) and conventional preparation methods in evaluating gynecologic specimens, there exists limited literature comparing TP to conventional cytopspins (CS) in nongynecologic specimens.

Design: Evaluate the differences between TP and CS in a variety of parameters including cellularity, diagnostic yield, specimen preparation, screening time, cytologist preference and impact on final diagnosis. Eighty eight cases were simultaneously prepared yielding 1 TP slide and 2-4 cytopspins from each specimen. The cases included 38 urine, 13 respiratory and 37 body cavity fluids.

Results: TP and CS showed similar cellular yield in 61 cases (69.3%), but superior cellularity was demonstrated in 18 CS (20%) and 9 TP (10%). Cytologists preferred TP in 63 cases (71.6%) and CS in 6 cases (6.8%); while indicated no preference in 19 cases (21.6%). Out of 14 abnormal cytologies, a more definitive diagnosis of malignancy was rendered by TP in 6 suspicious cases (42.9%) and by CS in 2 suspicious cases (14.3%). There was a pathologists preference for TP in 9 (64.3%) and for CS in 3 (21.4%), out of the 14 abnormal cases. TP demonstrated better nuclear chromatin morphology, more uniform distribution of cells, less variability in cell yield, and less cellular overlapping and background debris. CS showed larger sized clusters with better preservation of their architecture, and more variability in cellular yield. Cluster formation was preserved in TP, but tended to be smaller in size and showed significant shrinkage of cell size.

Conclusions: TP was preferred over CS in the majority of cases by both cytotechnologists and pathologists. Cellularity, screening time and specimen preparation were comparable, although the latter was easier to standardize in TP. In suspicious cases, TP was found to be 3 times more helpful than CS in rendering a definitive diagnosis of malignancy. TP, however, is associated with certain artifacts that cytologists must become familiar with when examining such preparations. In summary, TP is superior to CS for evaluation of nongynecologic specimens. In suspicious cases, however, the application of both methods can maximize the diagnostic yield.

281 Significance and Possible Causes of False Negative Results of Reflex HPV-DNA Test

I Eltoun, D Chhieng, D Kosatka, J Roberson, G Jin, T Broker. University of Alabama at Birmingham, Birmingham, AL.

Background: Several recent clinical trials have shown that the triage of women to colposcopy through HPV-DNA testing of ASCUS, compared to triage based on cytology, has improved the sensitivity of detection of high grade cervical lesions while reducing the referral rate to colposcopy. It is conceivable to ask if this high performance is sustained under varied conditions of routine use, particularly given the potential litigation and health risks associated with false negative results. In this report, we assessed the significance and possible reasons for false negative reflex HPV-DNA test under routine laboratory use

Design: We reviewed all liquid-based Pap tests submitted for Digene Reflex HPV testing during the period of Jan. 2002 to Jan. 2004. ASCUS-HPV-DNA negative cases were reviewed to see if any had cervical tissue obtained for any reason (biopsy, endocervical curetting or hysterectomy) within a year following HPV testing. Tissue was evaluated for grade and extends of intraepithelial neoplasia. ThinPrep slides were reviewed and the number and the percentage of abnormal cells were estimated. Errors were classified as screening, sampling or interpretation errors.

Results: During the study period, 25,164 ThinPrep tests were performed resulting in 2672 (11%) ASC-US and 1371(5%) LSIL+ diagnoses. 2309 ASC-US (86%) cases were tested for HPV; 789 (34%) were positive and 1520 (66%) were negative. Of 316 cases positive for HPV and biopsied, 36 (11%) were CIN2-3 positive. Of 82 HPV-DNA negative cases who had tissue available for review, 63 (77%) cases were normal, 13 (16%) had CIN1 and 6 (7%) had CIN2-3. Because colposcopy was not performed in the majority of HPV negative cases, the CIN2-3 false negative fraction was at least 6/42 (14%). Except in one case, the linear extension of these CIN2-3 lesion measured less than 4.0 mm with no endocervical involvement and on cytologic review, the number of abnormal cells ranged 8-39 cells per slide. Because of the small size of these lesions, the error was most likely due to sampling.

Conclusions: False negative Reflex-HPV DNA test under routine laboratory use is higher than reported in clinical trials. The majority of missed CIN2-3 are small and shed few abnormal cells. To rule out infection with viral type not included in Digene cocktail, we are currently performing viral genotyping in these cases.

282 Endoscopic Ultrasound-Guided Fine Needle Aspiration Cytology Diagnosis of Intraductal Papillary Mucinous Tumor of the Pancreas Is Highly Predictive of Pancreatic Neoplasia

RE Emerson, HM Cramer. Indiana University School of Medicine, Indianapolis, IN.

Background: Intraductal papillary mucinous tumors (IPMT) have been considered difficult to diagnose by fine needle aspiration (FNA) cytology. We review our experience with a series of cases diagnosed by endoscopic ultrasound (EUS)-guided FNA.

Design: We performed a computerized search of our cytology and surgical pathology files for cases diagnosed as IPMT or consistent with IPMT for an 8.6 year period. Of the cytology cases, only specimens obtained by EUS guided FNA were included. Cases in which adenocarcinoma was considered in the differential diagnosis were excluded from the study. Histologic follow-up of the FNA IPMT cases was obtained. Among those cases diagnosed as IPMT by histology, a search was made for preceding EUS-guided FNA specimens.

Results: Fifty cases were diagnosed by EUS FNA as IPMT or consistent with IPMT. Of these patients, 18 (36%) underwent surgical excision of part of the pancreas. Pancreatic neoplasia was demonstrated in 17 of these cases (94%). The histologic diagnoses were IPMT (15 cases), pancreatic intraductal neoplasia (1 case), invasive mucin-producing adenocarcinoma (1 case), and chronic pancreatitis with an abscess and pseudocyst (1 case). Forty-seven cases of IPMT without coexisting adenocarcinoma were diagnosed by histology following excision of part of the pancreas during this time period. Of these, 25 (53%) had a preceding EUS FNA. The diagnosis made by EUS FNA in these 25 cases was negative or nondiagnostic (7 cases), benign cyst (1 case), chronic pancreatitis (2 cases), atypical ductal cells (3 cases), adenocarcinoma (1 case), consistent with mucinous cystic neoplasm (4 cases), and IPMT or consistent with IPMT (7 cases). A diagnosis of probable or definite neoplasia was, therefore, made in 60% of cases of histologically-proven IPMT by the preceding EUS FNA.

Conclusions: A FNA diagnosis of IPMT or consistent with IPMT is highly predictive of pancreatic neoplasia which is most commonly IPMT. In contrast, among histologically-proven IPMT cases, sensitivity is only moderate.

283 High-Risk HPV Testing by PCR of Cervical Cytology Samples Classified According to Bethesda 2001 Guidelines May Benefit Both ASC-US and LSIL Patient Management

MF Evans, CS-C Adamson, JL Papillo, TL St. John, G Leiman, K Cooper. University of Vermont, Burlington, VT.

Background: Management of women with ASCUS or LSIL is problematic as 15-30% of these patients may harbor high-grade cervical intraepithelial neoplasia (CIN-2/3). The Hybrid Capture II (HC2) assay tests for 13 high-risk (HR) HPV types and has been shown to benefit the management of ASCUS by allowing exclusion from referral for colposcopy HR HPV negative women. Approximately 50% of ASCUS patients test HR HPV negative and are also negative for CIN-3. However HC2 testing does not benefit LSIL management because 83% of patients have tested positive for HR HPV by this assay. The present study has examined by PCR the distribution of individual HPV types among ThinPrep samples diagnosed according to the 2001 Bethesda Guidelines.

Design: DNA purified from cell samples from 300 women with no intraepithelial lesion or malignancy (NIL), 200 with ASC-US, 200 with LSIL, 200 with ASC-H, and

200 with HSIL, has been tested for HPV by General Primer 5+/6+ PCR followed by dot blot hybridization of PCR products with HPV type specific oligonucleotide probes. HPV assays were conducted blinded to cytology diagnoses.

Results: HPV was detected in 27% NIL, 89.5% ASC-US, 97.5% LSIL, 93% ASC-H, and 96.5% HSIL samples. One or more of the 13 HR types was detected in 53% ASC-US, 55.5% LSIL, 80% ASC-H and 87.5% HSIL samples (p<0.001). Low-risk types were identified in 17.5% ASC-US, 23% LSIL, 4.5% ASC-H and 4.5% HSIL samples (p<0.001). HPV-16 was the most common type and was detected in 15.5% ASC-US, 15.5% LSIL, 48.5% ASC-H and 49% HSIL (p<0.001). Follow-up biopsy data were obtained for 306 patients. A benign diagnosis was recorded for 46/62 (74%) ASC-US [28/46 HR positive], 27/62 (44%) LSIL [15/27 HR positive], 37/77 (48%) ASC-H and 20/105 (19%) HSIL patients. CIN-2/3 was identified for 7 (11%) ASC-US [7/7 HR positive], 10 (16%) LSIL [5/10 HR positive], 36 (47%) ASC-H, and 77 (73%) HSIL patients.

Conclusions: HR HPV type distinguishes ASC-US and LSIL from ASC-H and HSIL. This is paralleled by the higher prevalence of CIN-2/3 in ASC-H and HSIL patients. The data suggest HR HPV typing by PCR of samples classified according to 2001 Bethesda Guidelines could benefit both ASC-US and LSIL management, as 47-44.5% of patients were HR HPV negative. However, the high percentages of HR HPV positive ASC-US/LSIL patients for who benign changes were detected limits test specificity, and further studies are required to determine the sensitivity of HR HPV for CIN-2/3 in these patients.

284 Routine Vaginal Pap Test Is Not Useful in Low-Risk Women Status-Post Hysterectomy for Benign Disease

H Farghaly, V Padmanabhan, D Bourgeois, C Shwede, RS Hoda. Medical University of South Carolina, Charleston, SC.

Background: United States Preventive Services Task Force has recommended that routine yearly Pap (vaginal) test screening is unnecessary for women who are status-post (S/P) total hysterectomy (T-Hyst) for benign disease (*Guide to Clinical Preventive Services*. 2nd ed. Baltimore, MD: Williams & Wilkins, 1996:105-118). We sought to evaluate the usefulness of Pap tests in such women at our Institution.

Design: Computerized data of patients (pts) with vaginal Pap tests performed within 3-years of a T-Hyst for benign disease, over a 6-year-period (Jan '97-Dec '02), was retrospectively evaluated. Cytologic findings on the Pap tests were reviewed for epithelial abnormalities (Ep Abnl) and non-neoplastic (N-Neopl) findings based on three age groups (gps), 18-44 yrs, 45-64 yrs and ≥65 yrs (*Sirovich et al, 2004;291:2990-2993*).

Results: Of 1860 T-Hyst performed during the study period, 1303 (70%) were for benign disease. Of these, 748 were 18-44 yrs; 504 were 45-64 yrs and 51 were ≥65 yrs. Five hundred and eighty-one of 1303 (44.5%) pts had one or more vaginal Pap tests within three yrs of T-Hyst. Of the 581 women, 288 (38.5%) were 18-44 yrs; 272 (54%) were 45-64 yrs and 21 (41%) were ≥65 yrs. Overall, only 28/581 (5%) of the Pap tests showed an Ep Abnl, 252/581 (43%) showed N-Neopl findings and the remaining 301/581 (52%) were unremarkable. The Ep Abnl included atypical squamous cells of undetermined significance, 19 (3%), and low-grade vaginal intraepithelial lesion (LG-VAIN), 9 (2%). The N-Neopl findings included organisms, 237 (bacterial vaginosis, 104; trichomoniasis, 31 and fungal organisms consistent with candida spp., 102); atrophy, 14 and vaginal endometriosis, 1. Based on the individual age-gps, Pap tests in 288 of 18-44 yrs showed Ep Abnl in 7 (2.4%) and N-Neopl findings in 138 (48%); 272 of 45-64 yrs showed Ep Abnl in 21(8%) and N-Neopl findings in 107 (39%) and 21 of ≥65 yrs showed Ep Abnl in 0 (0%) and N-Neopl findings in 7 (14%).

Conclusions: Continued vaginal Pap test screening of low-risk women S/P total hysterectomy for benign disease does not appear to be useful, particularly in those ≥65 yrs. Overall, only 2% of women had a LG-VAIN, while 41% had N-Neopl findings, mostly organisms. A better use of available resources would be to target high-risk women not otherwise being screened for squamous intraepithelial lesions.

285 Histopathological and Cytopathological Diagnoses Discrepancies in Head and Neck Region: Pitfalls, Causes and Preventive Strategies

L Fathallah, OE Tulunay, M Al-Abbadi, J Feng, JR Jacobs, M Husain. Wayne State University, Detroit Medical Center, Detroit, MI.

Background: Otolaryngologists commonly request FNA as a primary investigation of a palpable head and neck lesions. Correlation of FNA diagnosis with the surgical resection diagnosis is an essential part of any quality control or assurance program in all cytology laboratories. The existence of discrepancies between them is well known but causes are not well studied.

Design: Six hundred and ten cases of FNAB specimens from head and neck excluding thyroid were retrieved by computerized database search at the DMC from July 1999 to July 2004. Examination of the Pathology reports and patient charts for a corresponding surgical resection performed within 3 months in the same location and with a discrepant diagnosis revealed 20 cases (3.3%). Sites sampled included parotid or submandibular (n=5), lymph nodes (n=8), and paratracheal/paraesophageal neck masses (n=7). No pathologist was available for immediate adequacy evaluation and triage in those cases. Cytology and histology slides were examined and errors were categorized as sampling, lack of triage, and interpretative.

Results: Causes of false-negative FNAB diagnoses (n=18) included sampling error (n=3), inadequate for interpretation due to insufficient material (n=5), lack of triage/for ancillary studies (n=4) (such as sampling for flowcytometry if lymphoma is suspected), and interpretation errors (n=6). Most of the interpretation errors were minor due to bland cytomorphology (n=4) or sampling from a region with tumor differentiation (n=2). There were 2 false positive FNAs. Both were called mucocystic carcinoma in the parotid gland while the corresponding surgical resections showed chronic sialoadenitis (1) and lymphoepithelial cyst of parotid (1).

Conclusions: FNAB is an effective tool for diagnosis and triage of patients with head and neck lesions. Adequate sampling with sufficient cellularity and triage for ancillary studies are critical to avoid false-negative diagnoses. In 16/18 false negative cases the discrepancy would be potentially minimized if onsite specimen adequacy evaluation by pathologist was available. Chronic sialoadenitis and lymphoepithelial cyst of parotid with the presence of multiple macrophages and epithelial atypia were potential pitfalls for mucoepidermoid carcinoma. For optimal triage of FNAB samples, an onsite evaluation performed by a pathologist is highly recommended.

286 Two-Year Follow up of Women with High Risk HPV DNA Positive ASCUS Interpretation in a Community Practice Setting

J Feng, M Husain. Wayne State University, Detroit Medical Center, Detroit, MI.
Background: Cervical cytology interpretation of ASCUS is a heterogeneous category which includes self-limited productive HPV infections, few CIN 2-3 and rare squamous cell carcinoma. ALTS demonstrated that 26.7% of HPV positive ASCUS women had biopsy confirmed CIN2-3 at enrollment or lesion was detected during two-year follow up. In the community practice setting, follow up of women with HPV positive ASCUS interpretation using 2001 Bethesda system is not well established. The purpose of our study is to benchmark the risk of HGSIL/CIN2-3 in our patient population.

Design: Eight hundred forty six patients with Thin-Prep cervical cytology of ASCUS interpretation in whom high risk HPV DNA was detected by reflex testing (Hybrid capture2) were identified from January to December 2002. The ASC-US and HPV data base was queried. The patient population included hospital clinics and private office practice in the metropolitan Detroit area. Ages ranged from 12 to 81 years old with median of 25.0. Patients without any follow up are not included. Any HGSIL/CIN2-3 cytology or biopsy diagnosis was defined as the end point of follow up. For the remaining women, the results of last follow up were recorded. The results are categorized into three groups: negative, LGSIL/CIN1 (including ASCUS or high-risk HPV DNA positivity) and HGSIL/CIN2-3. Any followup cytology interpretation of HGSIL with discordant histology was reviewed by two cytopathologists to achieve consensus interpretation.

Results: Of 846, only 514 patients had follow up by cytology, biopsy or both. 64.3 % of patients had 18 to 24 months of follow up and the remaining patients had 15 months. 291 patients (56.6%) became negative in median interval of 8.5 months (ranging 0 to 28 months). 174 patients (33.9%) had persistent LGSIL/CIN 1 with median interval of 8.5 months (0 to 20 months). 37 patients (7.2%) had CIN 2 diagnosis with median age of 22.0 and median interval of 4.5 months (0-19 months) and 12 patients (2.3%) diagnosed CIN 3 with median age of 31.0 years old and median interval of 6.5 months (0-15 months). 41% of these HGSIL/CIN2-3 were diagnosed within 3 months of index ASCUS Pap, while 59% of those were detected during 3 to 19 months of follow up.

Conclusions: Our study benchmarks that 1 in 10 women with HPV positive ASCUS cervical cytology will have high grade SIL or CIN2-3 detected at initial presentation or develop CIN2/3 within two-year follow-up period. Conversely, more than half ASC-US HPV DNA positive women clear virus and revert to normal cytology.

287 HER2 Immunostaining in Cytologic Samples of Metastatic Breast Cancer: Does Antibody Clone and Pretreatment Method Effect Results?

PA Fetsch, A Abati. National Cancer Institute/National Institutes of Health, Bethesda, MD.

Background: There is no consensus regarding the use of heat induced epitope retrieval (HIER) for immunohistochemistry. Utilization is arbitrary and results rather than specificity driven. Standardization and use of HIER is particularly important with immunohistochemical (IHC) markers which direct the course of cancer treatment, such as Herceptin therapy. Many laboratories are performing IHC analysis using various antibodies (Abs) and methodologies for HER2/neu. We attempted to determine the effects of Ab clone and pretreatment methods on interpretation in cytologic samples.

Design: Formalin-fixed, paraffin-embedded cell block sections from 54 cases of metastatic breast cancer (24 FNA's, 30 effusions) were analyzed for HER2 expression. For each sample, the following antibodies were tested:

1. HER2/neu clone CB11 (BioGenex, no pretreatment as per manufacturer)
2. HER2/neu clone CB11 (BioGenex, HIER)
3. HER2/neu clone TAB250 (Zymed, ficin pretreatment as per manufacturer)
4. HER2/neu clone TAB250 (Zymed, HIER)
5. HER2/neu polyclonal (DAKO, HIER as per manufacturer)

To standardize interpretation and thus rule out interobserver variability, all slides were reviewed in a blinded fashion by one pathologist using the FDA-approved scoring system for the HercepTest.

Results: In total, 15/54 (28%) cases were 2-3+ HER2 (+). 9/54 (17%) cases using CB-11 showed a significant increase in immunoreactivity using HIER (ie. from 0/1+ to 2-3+), whereas only 1 showed a decrease. In 29/54, the cytoplasmic background was significantly higher after HIER, whereas only 2/54 cases of non pretreated samples showed significant cytoplasmic background. HIER pretreatment did not increase HER2 staining in any TAB-250 sample, rather 4/54 (7%) of cases showed a significant decrease with HIER. When comparing CB-11 and TAB250 to the DAKO Ab, there were 4 cases in which DAKO was (+) CB 11 (-) and 2 where DAKO was (-) and CB-11(+). In 6 cases the DAKO Ab was (+) but TAB250 (-); there were none in which the DAKO antibody was (-) and the TAB250(+)

Conclusions: The DAKO Ab yielded the most HER2 (+) samples. With CB-11, HIER led to a significant increase in scoring in 17% cases. The increase in cytoplasmic background staining associated with HIER could potentially lead to false positive interpretation in negative cases. HIER had little impact on TAB250 staining.

288 Fine Needle Aspiration of the Orbit and Ocular Adnexa. A Retrospective Study of 59 Cases

RR Fonseca, J Cabral, E Mendonça. Instituto Português Oncologia Francisco Gentil CROL SA, Lisboa, Portugal.

Background: Primary and metastatic tumour diseases are rare in the orbit and ocular adnexa. Fine needle aspiration cytology (FNA) is a simple procedure and provides a valuable preoperative assessment with high diagnostic accuracy. This study addresses our experience in the diagnosis of such lesions.

Design: A total of 59 FNAs were performed on lesions of the orbit and ocular region, between 1999 and 2004 (orbit n= 45; ocular adnexa n= 14). Cytology, histopathology and medical records were reviewed. Cytological diagnoses were correlated with histopathology and clinical follow-up in order to evaluate the utility of FNA in the management of these patients. FNA was done in 20 cases for primary diagnosis, and on follow-up of known diseases for the remaining 39.

Results: Patients ranged in age from 1 to 86 years old (mean age: 51.1 yrs). The male/female ratio was nearly equal (30/29). Among the 59 FNAs, 37 (63%) were diagnosed as malignant and 9 (15%) as non neoplastic lesions. In 13 cases (22%) the sample was considered inadequate for diagnosis. Malignant diagnoses included the following entities: skin adnexal tumour, squamous cell carcinoma, metastatic carcinoma, malignant melanoma, sarcoma and lymphoma. There were no false positive results. There were 2 false negative results (3.4%). No complications were reported.

Conclusions: FNA is a reliable, safe and minimally invasive diagnostic technique that can be routinely used in outpatient clinics for a rapid diagnosis allowing to distinguish between inflammatory, benign and malignant lesions and the subtypes of malignant tumours of the orbit and ocular adnexa.

289 Molecular Pathology Evaluation of Indeterminate Common Bile Duct Brushing Cytology Specimens

OE Gologan, S Finkelstein, YL Liu, O Lapkus, PA Swalsky, M Wilson, JF Silverman. Allegheny General Hospital, Pittsburgh, PA; RedPath Integrated Pathology, Pittsburgh, PA.

Background: Common bile duct (CBD) brushing cytology is an important method for diagnosing biliary malignancies. However, its low sensitivity (approximately 50%) indicates a need for additional diagnostic techniques in cases with equivocal conventional cytomorphology. An integrated cytomorphologic/molecular approach may increase the diagnostic yield of CBD brushing cytology of indeterminate cases. We analyzed the molecular alterations in cytologically atypical, suspicious and malignant lesions using microdissection and broad panel mutational genotyping.

Design: Twenty-one (21) CBD brushing cytology specimens were retrieved from a tertiary medical center cytology archives. Xylene resistant markings were placed on the slide underside and the coverslips were removed. Clusters of atypical, suspicious and malignant Papanicolaou stained cells were manually microdissected and DNA was extracted. Mutations (allelic imbalance [LOH]) were quantitatively determined for a broad panel of 15 markers (1p, 3p, 5q, 9p, 10q, 17p, 17q, 21q, 22q) as well as point mutation in k-ras-2 using PCR/capillary electrophoresis. The presence, cumulative amount (fractional mutation index [FMI]) and time course of mutational damage was correlated with the cytologic diagnosis (Chi square).

Results: Ten (10) of 17 atypical cases (59%) showed low-grade mutation levels (FMI=0.18). Seven (7) atypical cases (41%) showed no mutation for the markers studied. The first acquired mutations were equally distributed across all molecular markers. The suspicious cases demonstrated a rate of mutation similar to the atypical group with mutational changes (FMI=0.16). The one malignant case showed a significantly higher mutation rate (FMI=0.3). One (1) atypical (6%) and 1 suspicious case (33%) manifested k-ras-2 mutations.

Conclusions: The presence of mutational events in CBD brushing cytology specimens suggests early neoplastic changes in some indeterminate cases (atypical/suspicious). Progressive accumulation of mutations correlate with increasing cytomorphologic atypia and provides a stronger support for a diagnosis of cholangiocarcinoma. Incorporating mutational analysis into cytologic evaluation may allow early detection of malignancy and reduction in indeterminate diagnoses and select patients at greater risk for neoplastic progression; thereby requiring closer monitoring and follow-up. K-ras-2 point mutations may signal a pancreatic carcinoma.

290 Impact of Bethesda 2001 on the Unsatisfactory ThinPrep Specimen: Clinical Implications and Contributing Conditions

KB Green, CK Arnott, PL Schubert, KA Ely. Vanderbilt University, Nashville, TN.

Background: The 2001 Bethesda System for cervicovaginal cytology reporting modified the guidelines for specimen adequacy by eliminating the "Satisfactory but limited by" designation. It also proposed criteria for estimating squamous component on liquid-based techniques using cell counts. This update prompted us to evaluate the impact of such a revision on our laboratory adequacy rates. Conditions contributing to the unsatisfactory specimen, as well as, clinical follow-up diagnoses were analyzed.

Design: The computerized database from Vanderbilt University Medical Center Cytopathology Laboratory was searched over the nineteen months following introduction of the Bethesda System 2001 for all cervical liquid-based preparations (ThinPrep) rendered unsatisfactory for interpretation. Vaginal samples were not included in the study population. The rate of unsatisfactory reports collected during this period was compared to that of the preceding nineteen months. Data regarding patient age, date of last menstrual period, reason for the inadequate smear, time to follow-up and clinicopathologic follow-up results were also obtained.

Results: During the interval prior to the implementation of Bethesda 2001, a total of 26,001 liquid-based cytologies were reviewed, of which 238 (0.92%) were considered unsatisfactory for interpretation. 27,344 cervical ThinPrep smears were collected in the following nineteen months; 401(1.5%) were unsatisfactory specimens (326 due to scant squamous cellularity, 38 due to obscuring factors, 36 due to scant squamous

cellularity and obscuring factors, and 1 unspecified). The latter group consisted of 24 post-partum and 33 pregnant women, and 101 patients whose last menstrual period was within 7 days of the Pap smear. 283 (70.6%) of the patients received follow-up, with an average time to follow-up of 3.8 months. Follow-up diagnoses included 244 (86.2%) negative for intraepithelial lesion, 19 (6.7%) atypical squamous cells, 3 (1.1%) atypical squamous cells, high grade cannot exclude high-grade squamous intraepithelial lesion, 15(5.3%) low grade squamous intraepithelial lesion and 2 (0.7%) high grade squamous intraepithelial lesion.

Conclusions: The adoption of Bethesda 2001 resulted in an increase in the unsatisfactory rate (1.5% versus 0.92%) in our laboratory. 39.4% of inadequate samples were derived from patients who were post-partum, pregnant or within one week of their last menstrual period. The majority of women who received follow-up did not develop a significant cervical abnormality.

291 Predictive Value of p16^{INK4A} in Detection of CIN 2/3 from Women with LSIL Pap Results, a Biopsy Comparison Study

M Guo, L Hu, J Zhou, Z He, L Martin, M Baliga. The University of Texas, MD Anderson Cancer Center, Houston, TX; The University of Mississippi Medical Center, Jackson, MS.

Background: p16^{INK4A} over-expression has been reported to be closely associated with high-risk HPV infection and high-grade cervical intraepithelial lesion (CIN 2/3). To evaluate p16^{INK4A} as a potential triage marker in women with LSIL Pap result, we compared p16^{INK4A} immunocytochemistry staining in SurePath cytology specimen with the results of corresponding follow up cervical biopsy.

Design: A total of 116 women aged 17 to 45 years with LSIL Pap results and follow-up biopsies were selected from the cervical cancer-screening program, Mississippi State Department of Health, in 2003. p16^{INK4A} immunocytochemistry assay was performed on duplicated SurePath specimen. p16^{INK4A} positive cells were sub-classified as LSIL, HSIL/ASC-H, squamous metaplastic, endocervical or endometrial cells, and compared with the diagnoses of corresponding follow up cervical biopsy.

Results: Of 116 cases of LSIL, 64 cases (55.2%) showed p16^{INK4A} positive dysplastic cells, either LSIL or with HSIL/ASC-H cells. Thirteen out of 14 biopsy confirmed CIN 2/3 cases were found in p16^{INK4A} positive cytology specimen, predominantly in the specimen containing HSIL or ASC-H cells (11/13) (Table). The positive predictive value (PPV) for detecting CIN 2/3 by p16^{INK4A} immunostain is 20.3%. p16^{INK4A} positive squamous metaplastic cells (47 cases), endocervical (26 cases) and endometrial cells (3 cases) were observed. Most of these cells were found co-existing with p16^{INK4A} positive dysplastic cells. Three cytology specimen contained p16^{INK4A} positive small metaplastic cells without p16^{INK4A} positive dysplastic cells. Of these 3 cases, one case showed CIN2 on biopsy.

Conclusions: p16^{INK4A} immunocytochemistry assay in SurePath cytology specimen shows a high predictive value for detecting CIN 2/3 among women with LSIL Pap results. Except for small metaplastic cells, false positive staining of p16^{INK4A} in non-dysplastic cells shows little or no effects on the predictive value of p16^{INK4A} for detecting CIN 2/3.

Table: Comparison of p16^{INK4A} Immunocytochemistry staining in SurePath specimen with corresponding follow-up cervical biopsy (LSIL, n=116)

p16 ^{INK4A}	Cervical Biopsy			
	Cervicitis	CIN1	CIN2/3	Total (%)
HSIL/ASC-H +	2	12	11	25 (21.6)
LSIL +	11	26	2	39 (33.6)
LSIL -	12	39	1	52 (44.8)
Total (%)	25 (21.6)	77 (66.4)	14 (12.0)	116 (100)

292 Histopathologic Extent of Cervical Intraepithelial Neoplasia 3 Lesions Correlates with the Number of Abnormal Cells in the Preceding HGSIL ThinPrep Cytology

S H. Khayyata, C Christensen, D Kmak, M Husain. Wayne State University, Detroit, MI.

Background: Cervical intraepithelial neoplasia 3 (CIN3) is considered the true precursor of squamous carcinoma and a surrogate end point for cervical screening programs. Several studies have suggested that the size of CIN 3 lesions in LEEP specimens is significantly larger in cases associated with invasion than those with no invasion. The purpose of this study is to correlate the size of the CIN 3 lesions in LEEP specimens with the number of HGSIL cells in the preceding ThinPrep.

HGSIL: High Grade Squamous Intraepithelial Lesion

Design: We reviewed 42 consecutive LEEP specimens between May 2003 and June 2004 with a diagnosis of CIN 3 from the LEEP data file, and identified the most recent Papsmear (we limited our study to the CIN 3 ThinPrep). The age group of the patients had a mean of 33.6, a median of 34.5, and range from 18-57 years. Abnormal cells in the ThinPrep were quantitated by dividing the slide into four quadrants, and counting the abnormal cells in each quadrant. We categorize the CIN 3 LEEP specimens into 3 groups: Extensive lesions involving 3 or 4 quadrants, Moderate lesions involving 2 quadrants, and Focal lesions involving a single quadrant.

Results: The resultant number of abnormal cells on all ThinPreps had a mean of 165, median of 140, and ranged from 10-500. The number of abnormal cells in ThinPrep showed strong correlation with the size of the CIN 3 lesions in LEEP specimens (Pearson correlation P=0.0001). Single quadrant CIN 3 LEEP lesions were more likely to have less than 100 abnormal cells in the corresponding ThinPrep, while the extensive lesions tended to correlate with more than 200 abnormal cells. Please see the attached Table (1).

Conclusions: The size of CIN 3 lesions in the LEEP specimens correlates well with the number of abnormal cells in HGSIL cytology specimens in our patient population. No correlation was found between the age of the patients and the size of the CIN 3 lesions. We are extending this study to include all preceding abnormal cytology

interpretation in our LEEP data file, and also investigate the quality assurance value of correlating abnormal cytology with the size of CIN 3 lesions in LEEP specimens.

Table (1)

Quadrants/number of abnormal cells	<100	100-200	>200	Total
3 & 4 Quadrants	5	4	14	23
2 Quadrants	2	7	0	9
1 Quadrants	6	4	0	10
	13	15	14	42

293 Fine Needle Aspiration of Lung Lesions: A Clinicopathological and Cytopathological Review of 150 Cases in a Community-Based Hospital with Emphasis on the Relation between the Number of Passes and the Incidence of Pneumothorax

RA Halloush, FA Khasawneh, H Saleh, T Piskorawski, M Alabbadi. Wayne State University/Detroit Medical Center, Detroit, MI.

Background: Image-guided transthoracic Fine Needle Aspiration (FNA) to diagnose lung lesions is currently a recognized initial diagnostic procedure. It has proven its sensitivity and specificity and is considered to be safe and cost effective. The aim of this study was to review the lung FNA's that were done in our hospital, a Community-Based Hospital with 600+ beds, between January 1998 and April 2004. Accuracy, Sample adequacy, and the relation between the number of passes and sample adequacy and the occurrence of pneumothorax are presented.

Design: One hundred fifty cases of lung FNA from the department of pathology files were identified and the available specimens and patient charts were reviewed. The interobserver agreement was calculated. The relation between the number of passes and the adequacy of the sample obtained and the subsequent development of pneumothorax was tested using Fisher Exact Test.

Results: The material of 132 patients (88%) out of 150 were retrieved and reviewed. There were 85 cases of Non-Small Cell Lung Cancer (64%), 9 cases of Small Cell Lung Cancer (7%), 7 cases of metastatic cancer (5%) and 38 cases were read negative for cancer (24%). The Non-Small Cell Lung Cancer Cases included; 38 cases of Adenocarcinoma (45%), 22 cases of Squamous Cell Carcinoma (26%), 7 cases of Large Cell undifferentiated Carcinoma (8%), and 17 cases not sub-typed (21%). The interobserver agreement κ was 0.972, (95% CI 0.94 – 1.00). The charts of 138 patients (92%) were reviewed for post-procedure X-ray confirmed pneumothorax. Sixteen patients (11.6%) developed pneumothorax and only 3 patients (2%) required a chest tube for treatment. The number of passes was identified in 118 patients (79%). Seven out of 53 patients who had 3 passes or more developed pneumothorax while 9 out of 65 patients who had less than 3 passes developed pneumothorax, (P = 1.00). Nine out of 52 patients who had 3 passes or more had inadequate samples while 10 out of 66 patients who had less than 3 passes had inadequate samples, (P = 0.80).

Conclusions: FNA to diagnose peripheral lung lesions is a safe procedure with a low incidence of pneumothorax. Its findings are reproducible with high interobserver agreement. High number of passes was neither associated with increased incidence of pneumothorax nor it correlated with obtaining adequate sample.

294 Differential Expression of Neuroendocrine Markers in Liver Metastases of Cancers of Unknown Primary

DE Hansel, A Maitra, MG House, CJ Yeo, SZ Ali. The Johns Hopkins Hospital, Baltimore, MD.

Background: Metastatic disease involving the liver is common in many advanced tumors, including carcinomas and neuroendocrine neoplasms. Unfortunately, many poorly differentiated carcinomas demonstrate loss of specific, organ-dependent immunolabeling characteristics and develop features reminiscent of neuroendocrine neoplasms. Cytomorphology on fine-needle aspiration (FNA) of these metastases often fails to reveal the primary site of tumor origin, which poses difficulties in patient management and prognosis.

Design: Fifty-two FNAs of liver metastases containing the terms "neuroendocrine", "islet cell", or "carcinoid" in their diagnoses were examined. Patient follow-up was subsequently obtained to determine identification of primary tumor origin.

Results: In total, 52 lesions were examined and were diagnosed as neuroendocrine carcinomas or carcinomas with focal neuroendocrine differentiation. The primary site of tumor origin was confirmed by imaging, surgery, or autopsy in 39 patients. Site of tumor origin included the pancreas (14), lung (9), intestine (6), prostate (3), and other sites (7). Examination of chromogranin-A (CHG) and synaptophysin (SYN) immunolabeling of FNA cell blocks revealed differential expression of these markers between gastrointestinal and non-gastrointestinal primary sites. Robust, diffuse labeling for both CHG and SYN was identified in metastases arising from 90% of pancreatic (islet cell) or 100% of intestinal primary tumors. In contrast, only 37% of metastases arising from lung neuroendocrine primary tumors demonstrated both CHG and SYN immunoreactivity. Two of three metastatic prostate cancers demonstrated both CHG and SYN labeling, but were additionally positive for PSA and PSAP. Metastases arising from other sites often demonstrated immunolabeling patterns indicative of the primary site of origin.

Conclusions: FNA analysis of liver metastases is frequently undertaken prior to the identification of primary site of tumor origin. Differential expression of CHG and SYN in lesions demonstrating neuroendocrine features may help differentiate primary intestinal versus non-intestinal sites of origin. Additional labeling panels may further aid in the diagnosis of these lesions, such as TTF-1 in cases of lung and PSA/PSAP in prostatic primaries.

295 FNA of the Stomach: A Review of 241 Cases

J Hu, HM Cramer. Indiana University School of Medicine, Indianapolis, IN.

Background: Advances in endoscopy and endoscopic ultrasound have made it possible to perform FNA at a variety of gastrointestinal tract sites. In this study, we report our experience with transgastric FNA (TG-FNA).

Design: A computerized search of our cytology database was performed and all TG-FNAs performed during the 14 year period extending from July 1, 1990 through June 30, 2004 were identified. All cytology reports and correlating surgical pathology (SP) reports and selected microscopic slides were retrospectively reviewed.

Results: Correlating SP was obtained in 117 of 241 TG-FNAs (49 percent). SP follow-up was obtained for 9 of 18 cases diagnosed as carcinoma by FNA and the diagnosis was confirmed in 8 of 9 cases with one case of surgical pathology sampling error (SPSE). Of 10 cases diagnosed as carcinoma on SP, correlating FNA showed only benign (8) or atypical (2) findings. Only 1 of 3 cases diagnosed as suspicious for carcinoma by FNA was confirmed as carcinoma on follow-up SP. SP follow-up was not obtained for 4 cases diagnosed as positive (2) or suspicious (2) for neuroendocrine tumor (3 carcinoid, 1 neuroendocrine carcinoma). SP follow-up was obtained for 5 of 7 FNA cases of non-Hodgkin lymphoma (4 positive, 3 suspicious). The FNA diagnosis was confirmed in 4 of 5 cases; one case diagnosed as suspicious for lymphoma proved to be carcinoma on SP. There were 4 cases of non-Hodgkin lymphoma and 1 case of Hodgkin lymphoma diagnosed by SP which had received negative FNA diagnoses. SP follow-up was not obtained for either FNA case of melanoma and granulocytic sarcoma. There were 48 mesenchymal tumors and lesions (24 gastrointestinal stromal tumors [GIST], 11 leiomyomas (LM), 9 spindle cell tumors or lesions, 3 leiomyosarcomas (LMS) and 1 peripheral nerve sheath tumor diagnosed by TG-FNA. Follow-up SP was obtained for only 14 of the 48 cases. There were 7 SPSE cases. SP confirmation of the FNA diagnosis of GIST was obtained in 2 cases and the SP in 1 case showed LMS. One case diagnosed as LMS on FNA proved to be a GIST. SP follow-up of 3 FNA cases (2 LM, 1 spindle cell neoplasm) disclosed 2 LM and 1 carcinoid tumor. SP follow-up disclosed no malignancies among 67 cases diagnosed as unsatisfactory (8), atypical (9), inflammatory (5) or benign (45) by FNA. SP follow-up was not obtained in 76 FNA cases (3 atypical, 24 unsatisfactory, 49 benign).

Conclusions: Although TG-FNA appears to have lower sensitivity for the diagnosis of carcinoma and lymphomas than FNAs performed at other body sites, a positive diagnosis is highly reliable and can be used to guide patient management.

296 Fine Needle Aspiration (FNA) Cytology of Bone Lesions: A Retrospective Study of 403 Cases

J Hu, HM Cramer. Indiana University School of Medicine, Indianapolis, IN.

Background: Due to its cost-effectiveness, high sensitivity and specificity, FNA is a well accepted modality for the investigation of lesions in many body sites. The purpose of this study is to demonstrate the utility of FNA for the diagnosis of patients with bone lesions.

Design: A computerized search of the cytology database at our institution was performed for the 14 year period beginning July 1, 1990 and ending June 30, 2004 and all cases of FNA of bone lesions were identified. The cytology reports and correlating surgical pathology reports from these patients were retrospectively reviewed. Microscopic slides from selective cases were also re-examined. The sensitivity and specificity of bone FNA were determined.

Results: Over the 14 years, a total of 404 FNA cases of bone lesions were encountered. An FNA diagnosis was rendered in 371 of the 404 cases (92%) with 33 cases (8%) considered unsatisfactory for evaluation. A definitive diagnosis of malignancy was made in 215 of the 371 cases (58%) and 150 cases (40%) were diagnosed as benign. There were 3 cases (1%) diagnosed as suspicious for malignancy and 3 cases (1%) in which atypical cells were identified. The malignancies diagnosed by FNA included 185 metastases (86%) and 30 primary tumors (14%). The 151 cases of metastatic carcinoma accounted for 70 percent of the malignancies. Benign diagnoses included normal bone elements (39), benign bone tumors (19), inflammatory processes (43) and other non-specific findings (49). Correlating histopathologic follow-up was available for 79 of the 215 malignant FNA cases (37%) and for 75 of the 150 benign FNA cases (50%). Malignancy was confirmed on histopathology for 78 of 79 patients (99%) with malignant FNA diagnoses; one patient diagnosed as chondrosarcoma actually had a chondroblastoma. Histopathology follow-up was available for 5 of 6 cases diagnosed either as atypical cells or suspicious for malignancy. Malignancy was confirmed for 3 of these 5 cases and 2 cases proved to be benign. Of the patients with benign FNA diagnoses, 68 (91%) were confirmed as benign following histopathologic evaluation, but there were 7 false negative cases (9%). In this series, the sensitivity of FNA of bone lesions was 92 percent and the specificity was 99 percent.

Conclusions: FNA is a useful diagnostic tool for the evaluation of bone lesions. Metastases accounted for the vast majority of malignancies involving bone diagnosed by FNA. FNA is an excellent method of documenting bone metastases in patients with known malignancies.

297 A Panel of Immunohistochemical Stains Is Useful in the Differential Diagnosis of Primary Round Cell Pancreatic Neoplasms

J Hu, RE Emerson. Indiana University School of Medicine, Indianapolis, IN.

Background: In fine needle aspiration cytology specimens, islet cell tumors, acinar cell carcinomas, and solid-pseudopapillary tumors of the pancreas all commonly present as moderately cohesive round cells with a moderate amount of variably granular cytoplasm. Moderately cohesive round cells can occasionally also be seen in aspirates from pancreatic ductal-type adenocarcinomas. Results with a large number of immunohistochemical stains have been reported for each of these tumors, but the optimal immunohistochemical panel in this situation has not been established.

Design: We performed a computerized search for cases of each of these tumors. Stains were performed on fine needle aspiration cell blocks from histologically-proven tumors and on blocks from surgical pathology specimens. A panel of immunohistochemical stains was performed including antibodies reactive with keratin (AE1/AE3 and CAM5.2), chromogranin, synaptophysin, α -1-antitrypsin (α 1AT), α -1-antichymotrypsin (α 1ACT), CD10, CD56, and vimentin. Staining was scored in each case with a 0 to 3+ scale.

Results: Ductal adenocarcinomas stained with antibodies to keratin, α 1AT, α 1ACT, and, in some cases, with CD10 and CD56. Islet cell tumors stained, in a majority of cases, with all antibodies evaluated except vimentin and were the only tumors staining with chromogranin and synaptophysin. Only 2 acinar cell carcinomas and 2 solid-pseudopapillary tumors were available for evaluation. The acinar cell carcinomas were positive with keratin, α 1AT, α 1ACT, and CD10 in contrast to the solid-pseudopapillary tumors which were negative with keratin, positive with CD56 and, in one case, positive with vimentin. Good correlation was observed between the results of stains performed on cell block sections and surgical specimens.

Conclusions: A panel of immunohistochemical stains is useful in the differential diagnosis of primary round cell neoplasms. The pattern of immunohistochemical findings in cell block specimens is consistent with that observed in surgical specimens.

Results of Immunohistochemical Stains

	Ductal adenocarcinoma	Islet cell tumor	Acinar cell carcinoma	Solid-pseudopapillary tumor
Keratin	11/11	17/17	2/2	0/2
Chromogranin	0/11	17/17	0/2	0/2
Synaptophysin	0/11	17/17	0/2	0/2
α -1-antitrypsin	10/11	10/17	2/2	1/2
α -1-antichymotrypsin	10/11	11/17	2/2	2/2
CD10	4/10	7/17	2/2	2/2
CD56	3/11	14/17	0/2	2/2
Vimentin	0/11	0/17	0/2	1/2

298 Fine Needle Aspiration of Renal Cortical Lesions in Adults

P Iyengar, H Al-Ahmadie, VE Reuter, S Olgac, O Lin. Memorial Sloan-Kettering Cancer Center, New York, NY.

Background: The role of fine needle aspiration (FNA) of renal cortical lesions was minimal in the past because the result of the FNA did not affect clinical management. All solid renal cortical lesions, except metastases, were subject to surgical resection. However, with our greater understanding of the diverse biology of renal tumor types and the advent of neoadjuvant targeted therapies, knowledge of the renal cortical tumor histological subtype is critical for tailoring clinical trials and follow-up strategies. Renal cortical carcinomas (RCC) have distinct histological subtypes with varying degrees of metastatic potential. Conventional RCC has a less favorable outcome when compared with papillary and chromophobe RCC. A diagnosis of oncocytoma might prevent unnecessary surgery in a poor surgical candidate.

Design: Thirty-two consecutive cases of renal cortical lesions were submitted to FNA using a 21G needle. An air-dried smear and a Thinprep® slide were prepared. The slides were Diff-Quick® and Papanicolaou stained, respectively. The cytology specimens were reviewed and classified according to the WHO classification, without knowledge of the clinical history or histologic diagnosis. The results were compared to the histologic diagnosis.

Results: Two of 32 specimens were unsatisfactory due to lack of diagnostic material. The overall accuracy of cytology in the remaining 30 cases was 80%. The correct diagnoses were rendered in 5/5 oncocytomas (100%), 15/15 conventional RCC (100%), 2/4 papillary RCC (50%) and 2/3 chromophobe RCC (66%). Three cases were misdiagnosed as RCC by FNA: one case classified cytologically as conventional RCC was an angiomylipoma; two cases diagnosed cytologically as papillary RCC were in fact a metastatic colonic adenocarcinoma and a papillary urothelial carcinoma of the renal pelvis. The other misdiagnoses by FNA were errors in subtyping the primary renal cortical neoplasms: two cases classified cytologically as conventional RCC were, histologically, a papillary RCC and a chromophobe RCC; and one case diagnosed as oncocytoma in the cytology preparations was a papillary RCC.

Conclusions: Cytomorphology is relatively accurate in subtyping renal cortical lesions in adults. Clinico-radiological correlation is important to avoid misinterpreting secondary involvement of the renal cortex by a neoplasm as RCC. Papillary renal cell carcinomas represent the most difficult subtype of RCC to be correctly identified.

299 Characteristics of Apparently False Negative Digene Hybrid Capture II High Risk HPV DNA Testing

RA Jastania, WR Geddie, WB Chapman, SL Boerner. University Health Network, Toronto, ON, Canada.

Background: High risk Human Papilloma Virus (HPV) DNA as detected by the Digene Hybrid Capture II assay (hc HPV test) is highly correlated with cytologic/histologic evidence of high grade squamous intraepithelial lesion. False negative results may be obtained from cervical samples tested for high risk HPV DNA hc HPV test. This study was initiated to characterize cases in which a negative high risk HPV DNA test was followed by the biopsy confirmation of high grade squamous dysplasia (HSIL or CIN 2 or 3).

Design: Cases were selected from samples from a colposcopy unit collected over 32-month period (November 2001 - June 2004) and tested for high risk HPV DNA by hc HPV test, that were on follow-up diagnosed with at least HSIL (CIN 2 or 3) on histologic biopsies. The histology, concurrent cytology and HPV DNA testing results of cases with HSIL and negative HPV test were reviewed.

Results: 2306 hc HPV tests were performed on 2070 patients. From this, 1382 tests had follow-up biopsies from 1319 patients. Nine samples (from 8 patients) had negative hc HPV test followed by biopsies diagnosed as at least CIN 2 or 3. Patient age ranged from 29 to 58 years (average 44 years). The reason for referral to colposcopy was HSIL in 7

patients and ASC-US in one patient. Eight cytology specimens concurrent with the hc HPV test were available for review, with 6 showing HSIL, one LSIL and one NILM. On review of the surgical specimens, four were CIN 2 or 3; one microinvasive squamous carcinoma; one invasive squamous carcinoma; one patient had a biopsy that on review was reinterpreted as low grade dysplasia; and one patient had squamous dysplasia in a curettage sample that could not be accurately graded. On review of the HPV test results, five specimens had mean relative light units per cutoff value (RLU/CO) <0.3, one had RLU/CO of 0.42 and three specimens had RLU/CO >0.5.

Conclusions: In spite of the high negative predictive value of the hc HPV test, false negative results occur. The false negative results may be due to sample inadequacy, contamination with interfering substances, or of low quantities of HPV DNA. Most of the false negative cases in our study were in patient with concurrent HSIL cytology, suggesting that a negative hc HPV test in this setting may have a lower negative predictive value. The negative predictive value may also be comprised in cases in which the copy number of the HPV DNA is low and the RLU/CO is near the cut-off value for a negative result.

300 Can Apomucin (MUC4) Be Used as a Biomarker To Differentiate Chronic Pancreatitis from Pancreatic Adenocarcinoma on Endosonographically Obtained Fine Needle Aspirates?

NC Jhala, DN Jhala, WE Grizzle, IE Eltoum, M Eloubeidi, J Jones, SK Batra. University of Alabama at Birmingham, Birmingham, AL; University of Nebraska Medical Center and Eppley Cancer Institute, Omaha, NE.

Background: Fine needle aspirates (FNA) from a clinically suspected pancreatic adenocarcinoma frequently pose a challenge for a cytopathologist in differentiating chronic pancreatitis from pancreatic adenocarcinoma. A biomarker that can differentiate pancreatic carcinoma from reactive ductal epithelium in small FNA samples would therefore be of great value. It has been shown that the apomucin MUC4 is not detectable at the RNA level in normal pancreas but is detectable at high levels in invasive pancreatic adenocarcinoma. The present study was undertaken to determine if MUC4 expression can be used to differentiate reactive ductal epithelium from pancreatic adenocarcinoma on fine needle aspirate (FNA) samples from suspected pancreatic carcinoma on endosonographic (EUS) imaging.

Design: Forty five (31 adenocarcinoma, 1 suspicious for carcinoma, 3 atypical favor reactive change, and 10 chronic pancreatitis) paraffin embedded cell blocks from EUS-FNA samples from suspected pancreatic adenocarcinoma in the head of the pancreas were retrieved from the files. All paraffin embedded sections were immunohistochemically stained with mouse monoclonal antibody to MUC4 antigen (dilution: 1:3000, obtained from the University of Nebraska, NE). MUC4 expression was reviewed by two pathologists blinded to the cytology diagnosis. Cytoplasmic expression of MUC4 in atypical cells was categorized as a positive result. All cases had either surgical resection or clinical follow up which served as the gold standard. Fischer's exact test was performed to determine association of MUC4 expression in pancreatic adenocarcinoma

Results: MUC4 was significantly ($p < 0.001$) more commonly expressed in adenocarcinoma (28/31; 90%) than in chronic pancreatitis (0/10; 0%). All cases identified as atypical cells favor reactive change also did not stain for MUC4 expression. One case of suspicious for carcinoma was positive for MUC4 expression which on resection demonstrated only marked chronic pancreatitis. The sensitivity, specificity and efficiency of MUC4 expression as a marker for pancreatic ductal adenocarcinoma was 90%, 91%, and 90%, respectively.

Conclusions: MUC4 expression can be used as biomarker to diagnose pancreatic adenocarcinoma on FNA samples obtained from clinically suspected pancreatic adenocarcinoma.

301 Calretinin (CAL), Estrogen (ER) and Progesterone (PR) Staining in Primary Breast Carcinoma: A Potential Pitfall in the Immunohistochemical (IHC) Evaluation of Body Fluids

XY Jiang, VS Ghali, T Faisal, BM Wenig. Beth Israel Medical Center, New York, NY.

Background: Evaluation of body fluids to identify the origins of malignant cells is often a challenging task. Although CAL is a useful marker to differentiate mesothelial cell lesions (CAL+) from adenocarcinoma (CAL-), its specificity is at times limited. A few studies have shown that breast carcinoma can express CAL. In the presence of a neoplastic effusion, especially in a woman, positive CAL may make the diagnosis more challenging and may result in erroneous diagnoses.

Design: Formalin-fixed, paraffin-embedded tissue sections from 75 invasive breast carcinomas, including 63 cases of duct carcinoma, 10 cases of lobular carcinoma, one case of medullary carcinoma and one case of tubular carcinoma, were immunostained for CAL (Zymed, DC8), ER (Dako, ID5), and PR (Dako, 636). IHC staining was performed using avidin-biotin complex with microwave antigen retrieval method. The percentage and intensity of nuclear and cytoplasmic staining for CAL and the nuclear staining for ER and PR were evaluated. Regarding CAL, cases showing >10% of the tumor cells staining strongly (3+) or >25% of the tumor cells staining moderately (2+) were considered to be positive. Regarding ER and PR, cases showing >10% of the tumor cell staining strongly (3+) were considered positive. Immunoreactivity was also correlated with histologic tumor type and grade.

Results: 19/75 (25%) cases were positive for CAL, including 17 cases of duct carcinoma, one case of medullary carcinoma and one case of lobular carcinoma. 12/17 (71%) of CAL positive duct carcinoma cases were poorly differentiated, 4/17 (24%) were moderately differentiated, and only 1/17 (6%) was well differentiated. Analysis of ER and PR staining in the CAL positive duct carcinoma cases revealed that 9/17 (53%) were both ER and PR negative, 6/17 (35%) were both ER and PR positive, and 4/17 (24%) were ER positive and PR negative.

Conclusions: When evaluating body fluid for the origins of malignant cells, a large panel of antibodies, including ER and PR, should be utilized to differentiate between CAL positive effusion tumors. In addition, considering the significant occurrence of CAL positive, ER negative and PR negative breast carcinoma cases, more expanded panels should be used before excluding origin from a primary breast carcinoma. Thus, limited IHC evaluation of body fluids could potentially result in misdiagnosis and inaccurate differentiation between mesothelial lesions and metastatic carcinoma, including breast carcinoma.

302 A Simplified Classification of Thyroid Fine Needle Aspirations Correlated with Clinical Outcome

MA Jones, DM Dressel, ST Bigos. Maine Medical Center, Portland, ME.

Background: The lack of standard diagnostic reporting terminology and classification for thyroid fine needle aspiration (FNA) has led to unnecessary confusion for clinicians in interpreting reports and appropriately triaging thyroid nodules. We have developed a simple, clinically meaningful, standardized reporting format for thyroid FNAs based on review and follow-up (f/u) of over 400 aspirates.

Design: We retrospectively reviewed 445 FNAs taken at a single institution over a 6 year period (1995-2001) and correlated them with tissue diagnoses and clinical f/u. The cases were then classified into one of only 4 categories: 1) Unsatisfactory (Unsat), 2) Benign (Ben), 3) Atypical/Suspicious (A/S), 4) Positive (Pos). Published criteria were used for classification of smears. FNAs in which a diagnosis of malignancy could not be excluded were placed in the A/S category. Clinical triage for each category was 1) Repeat FNA, 2) Clinical f/u, 3) Surgery, 4) Surgery. Two pathologists categorized all of the FNAs.

Results: Of 445 FNAs, 16% were unsat, 56% benign, 22% A/S, 6% pos. The classification resulted in 28% of patients (pts) being referred for surgical excision. Correlation of the FNAs with the pathology results showed that 26% of A/S pts had carcinoma and 100% of pos pts had carcinoma thus the false pos rate was 0 (100% specificity). Based on clinical and pathology f/u, only 3% of pts had false negative FNAs.

Conclusions: Based on these findings we have adopted the practice of classifying all thyroid FNAs into one of these four categories. We state the classification first in the diagnostic line and follow the classification with a more descriptive diagnosis that outlines the specific cytologic findings in the aspiration and includes more specific diagnoses should they be appropriate (e.g. Hashimoto's disease, benign adenomatous nodule). Descriptive diagnoses alone do not provide clear treatment guidelines for clinicians. Our classification minimizes false negatives, sends approximately one in four pts to surgical excision and yields one in four pts with carcinoma diagnoses. Whatever the descriptive diagnosis, our classification provides clear triage options to clinicians.

303 Atypical Squamous Cells-Cannot Rule out High Grade SIL: Implications for Management in Postmenopausal and Pregnant Women

A Joutovsky, P Levine, P Elgert, J Cangiarella, A Sinsir. New York University, New York, NY.

Background: Although a few investigators correlated age with outcome in women with "atypical squamous cells-cannot rule out high grade SIL (ASC-H)", there are no studies specifically targeting pregnant (PG) and postmenopausal (PM) women. Two prior studies that correlated age with outcome showed conflicting results. Loro et al found a lower incidence of SIL after an ASC-H Pap test in women > 40 years of age in comparison to women < 40. Conversely, Sheils and Wilbur found no difference in the overall incidence of SIL in women younger and older than 40 years of age. We addressed the PG and PM women as separate categories due to the recognized difficulties in accurately distinguishing atrophy and pregnancy related physiologic cytologic changes from SIL. The association of ASC-H with pregnancy has not been previously addressed. In PM women, the incidence of SIL has been shown to decrease greatly, and atrophy-related changes simulating ASC/SIL has been shown to be rarely associated with biopsy proven SIL. Therefore, we postulated that PG and PM women with ASC-H should have a lower incidence of SIL compared to nonpregnant women of reproductive age.

Design: Women with ASC-H Pap tests were identified through the search of departmental computer files. Only women with tissue follow-up (punch biopsy, LEEP or cone) were included in the study. The outcome in PG and PM women was compared with women younger than 40 years of age. Statistical analysis was done using the chi-square test.

Results:

Histologic Findings in Postmenopausal and Pregnant Women with ASC-H Pap Test

	Negative	Condyloma/CIN 1	CIN 2/3	Total Number
Age < 40 years	33%	34%	33%	206
Postmenopausal women	58% (p<0.001)	14% (p<0.001)	28% (p<0.001)	100
Pregnant women	47% (p<1.0)	26% (p<1.0)	26% (p<1.0)	19

P values for postmenopausal and pregnant women are calculated in comparison to women <40 years of age (p<0.05 is statistically significant).

Conclusions: We found significant differences in the incidences of low and high grade SILs in PM women after an ASC-H Pap test compared to women younger than 40 years of age. While the overall incidence of SIL was lower in PM women, high grade SIL was much more common than condyloma/CIN 1. The incidences of low and high grade SILs in PG women were similar to nonpregnant women younger than 40 years of age. Therefore, while diagnostic pitfalls must be recognized in postmenopausal and pregnant women, the significance of ASC-H should not be underestimated.

304 The Role of Combined Urine Cytology and Vysis Urovysion in Predicting Recurrent Urothelial Carcinoma

W Kabbani, S Traif, MT Siddiqui, A Fulmer, D Wanzer, A Sagalowsky, R Ashfaq, University of Texas Southwestern Medical Center, Dallas, TX.

Background: Multitarget color Vysis Urovysion test has been validated in several recent studies to be a very sensitive and specific tool for urothelial carcinoma preceding in many cases the clinicopathologic recurrence. The aim of this study is to address the utilization of Urovysion in combination with urine Cytology for predicting clinical recurrence of urothelial carcinoma.

Design: A total of 256 urine samples for which Urovysion FISH was performed in 2003-2004 were retrieved. All cases with concurrent cytology and follow up biopsy were retrospectively identified. Spearman rank test was used to correlate FISH with Cytology. The sensitivity, specificity, positive and negative predictive values were calculated for FISH, Cytology and a combination of FISH and Cytology considering any concordant abnormal results as positive and concordant negative results as negative.

Results: There were 224 informative FISH samples with 141 concurrent cytology samples and 37 follow up biopsies (mean follow up time of 41 days). The FISH, Cytology, and Biopsy results are shown in Table-1.

FISH showed a positive correlation with concurrent urine cytology (Spearman $r=0.51$, $p=0.0001$).

The sensitivity, specificity, PPV, and NPV are summarized in Table-2.

Conclusions: Vysis Urovysion FISH is a sensitive and specific screening method for detecting early recurrent urothelial carcinoma with a good correlation with urine cytology and its negative and positive predictive values may be significantly improved when combined with concurrent urine cytology suggesting that such combination may be useful for triaging monitored patients for cystoscopy and biopsy.

Table-1: Summary of FISH, Cytology and Biopsy Results

	FISH	Cytology	FU Biopsy
Positive	73 (33%)	10 (7%)	28 (76%)
Negative	140 (62%)	106 (75%)	7 (19%)
Atypical	11 (5%)	25 (18%)	2 (5%)
Total	224	141	37

Table-2: Sensitivity, Specificity, Positive and Negative Predictive Values.

	Sensitivity	Specificity	PPV	NPV
FISH	89%	29%	83%	40%
CYTOLOGY	38%	100%	100%	35%
FISH and Cytology	100%	67%	94%	100%

305 p16^{INK4a} Immunostaining of Liquid Based Cervical Cytology Smears with SurePath®- Comparison of Two Antibodies

P Kotov, L Parameswaran, JA Parisi, M Chivkula, A Cafaro, M Fuentes, VB Shidham, Medical College of Wisconsin, Milwaukee, WI.

Background: The over expression of p16^{INK4a} (p16) in cervical smears is reported in association with HPV related dysplasia. This finding may be used as an objective parameter to improve the accuracy of interpretation in cervical cytology. However, different types of antibodies available have not been compared using liquid based cytology preparations.

Design: 44 (25 HSIL and 19 ASC-H) SurePath™ (TriPath Imaging Inc, Burlington, NC), liquid-based cervical cytology specimens were studied. Two smears were immunostained for p16 with DAKO kit [CINtec™ p16^{INK4a} Histology Kit, Clone E6H4 (DakoCytomation California Inc., Carpinteria, CA), heat retrieval with citrate buffer 0.1M] and CellMarque antibodies [Clone 16PO4 (Cell Marque Corporation, Hot Springs, AZ), dilution 1:100, without antigen retrieval step] respectively. DAKO kit was used according to manufacturers instructions, except that unstained SurePath™ smears were used instead of paraffin sections. CellMarque was standardized in our lab. The immunoreactivity patterns were noted. The results with two types of antibodies were compared and analyzed with Chi-square test.

Results: The results with two antibodies were comparable (table 1) without statistically significant difference (Chi-square test, $p > 0.5$). The intensity of immunostaining was relatively superior with DAKO with relatively less frequent cytoplasmic immunoreactivity than with CellMarque. As additional observation, both methods stained the bacteria in the background.

Conclusions: The two antibodies studied did not show significant difference in the results with high-grade squamous intraepithelial lesion (HSIL) and atypical squamous cells, cannot exclude high-grade squamous intraepithelial lesion (ASC-H) specimens. Immunostaining with different p16 antibodies.

Cytology interpretation (n)	p16 source	p16 immunostaining pattern*	
		Negative results	Positive results
HSIL (25)	CellMarque	1	2
		5	1
	Dako	6	0
		6	3
ASC-H (19)	CellMarque	5	3
		6	1
	Dako	6	1
		6	0

n, total numbers, HSIL, high-grade squamous intraepithelial lesion, ASC-H, atypical squamous cells, cannot exclude high-grade squamous intraepithelial lesion. *Immunostaining patterns- 1- none, 2- cytoplasmic alone, 3- nuclear alone, 4- nuclear with cytoplasmic.

306 Application of p16^{INK4a} Immunostaining for Definitive Interpretation of ASC-H in Liquid Based Cervical Cytology Smears with SurePath®

P Kotov, L Parameswaran, JA Parisi, M Chivkula, A Cafaro, M Fuentes, VB Shidham, Medical College of Wisconsin, Milwaukee, WI.

Background: Atypical squamous cells, cannot exclude high-grade squamous intraepithelial lesion (ASC-H) is a recently introduced category in 2001 Bethesda system. We evaluated the role of p16 immunostaining of SurePath™ (TriPath Imaging Inc, Burlington, NC) smears for definitive interpretation of ASC-H in liquid based cervical cytology smears.

Design: We studied 44 (25 HSIL and 19 ASC-H) liquid-based cervical cytology specimens. The unstained smears were immunostained with DAKO kit [CINtec™ p16^{INK4a} Histology Kit, Clone E6H4 (DakoCytomation California Inc., Carpinteria, CA) according to manufacturer's instructions. However, instead of paraffin sections, unstained SurePath™ smears were used. The immunoreactivity patterns- none (1), cytoplasmic alone (2), nuclear alone (3), and nuclear with cytoplasmic (4) were noted. Only nuclear and nuclear with cytoplasmic immunostaining was considered positive. None or only cytoplasmic immunostaining was considered negative.

Results: Cytoplasmic immunoreactivity alone was rare (table 1). If observed it was present in rare cells. When cytoplasmic immunostaining was associated with nuclear immunoreactivity, the interpretation of nuclear positivity was relatively difficult to interpret. p16 positivity correlated with dysplasia in 76% cases with HSIL cervical cytology. The 6 negative results in HSIL cases may reflect the sampling artifact. 80% (4 out of 5) of the biopsy proven ASC-H cases with dysplasia showed p16 positivity (Table 1).

Conclusions: p16 immunostaining may be used as ancillary test for objective interpretation of ASC-H with definitive interpretation of dysplasia. Nuclear or nuclear with cytoplasmic p16 immunostaining is consistent with positive results.

Results of immunostaining with p16.

Cytology interpretation (n)	Negative results	p16 immunostaining pattern*	
		Positive results	
HSIL (25)	1	2	3
	6	0	3 (Bo- 1, Bn- 1, C3- 6, Ca- 2)
	6 (Bo- 3, C1- 3)		C2- 1)
ASC-H (19)	6 (Bo- 2, Bn- 2, C1- 2)	1 (Bn- 1)	0
			12 (Bo- 6, Bn- 1, C3- 3, Cs- 1)

n= total number of cases, HSIL, high-grade squamous intraepithelial lesion, ASC-H, atypical squamous cells, cannot exclude high-grade squamous intraepithelial lesion. *Immunostaining patterns- 1- none, 2- cytoplasmic alone, 3- nuclear alone, 4- nuclear with cytoplasmic. The biopsy results are shown in parenthesis (Bo- no biopsy, Bn- biopsy negative, C1- CIN- I, C2- CIN- II, C3- CIN- III, Cs- carcinoma in situ, Ca- invasive carcinoma)

307 Utility of Fine-Needle Aspiration Biopsy in Measuring the Gene Transfer Efficacy of Adenoviral p53 (Advexin) Gene Therapy in Patients with Locally Advanced Breast Cancer

S Krishnamurthy, LT Guerra, V Valero, M Cristofanilli, M. D. Anderson Cancer Center, Houston, TX.

Background: Very few studies have reported the utility of fine-needle aspiration biopsy (FNAB) for monitoring sequential alterations in molecular events in tumors following therapeutic interventions. We studied the gene transfer efficacy of intratumoral administration of Advexin, which contains the human wild-type p53 transgene tagged to an adenoviral vector, in locally advanced breast cancer (LABC) by measuring levels of p53 mRNA with real-time RT-PCR of sequential FNAB's samples.

Design: Twelve patients with LABC were treated with intratumoral injections of Advexin 2.5 X 10¹² viral particles on days 1 and 2, of each cycle and conventional chemotherapy with docetaxel and doxorubicin. Single-pass FNAB was performed on day 1 before therapy and on days 3, 4, and 21. Aspirated material was collected in RNA, kept at room temperature for 20 minutes and stored at -20°C. RNA was extracted, and quantitated, and 40 ng of total RNA was used for real-time RT-PCR. The $\delta\delta Ct$ method was used to calculate differences in p53 expression in the samples relative to Stratagene's universal human reference RNA.

Results: The median size of the breast tumors was 8.0 cm (range, 5.0 - 11.0 cm); 7 patients had stage T4 tumors, 4 had T3, and 1 had T2. RNA could be extracted from 30 (63%) of 48 samples. The mean RNA concentration was 562.33 pg/ml (range, 33.56-4897.64 pg/ml). In 6 patients, RNA was available for analysis from all 4 FNABs. In 5 of these 6 patients, there were sequential increases in p53 mRNA levels, with the highest levels on day 21. The mean p53 mRNA level in these 5 patients was 4 on day 1 and on day 21 was 22695. In another patient p53 levels measured on days 2 and 21 demonstrated increases (7392 vs 31,216). Thus, 6(86%) of 7 patients had sequential increases in p53 levels.

Conclusions: 1. The gene transfer efficacy of Advexin therapy was demonstrated in this study by increases in p53 mRNA levels in the LABCs. 2. FNAB is an excellent technique to study sequential changes in molecular events in tumors. 3. Single-pass FNAB can provide sufficient RNA for molecular studies.

308 Parakeratotic Pearls and HCII HPV Results: Correlation in Liquid Based Cervicovaginal Cytology Specimens Interpreted as ASC-US

LA Kubba, JL Tice, H Antonopoulos, BM Oddo, AG Nickolov, EA Hahn, KL Kaul, CD Sturgis, Evanston Northwestern Healthcare, Evanston, IL; Northwestern University Feinberg School of Medicine, Chicago, IL; ENH Center for Outcomes Research and Education, Evanston, IL.

Background: Parakeratotic pearls (PKPs) are sometimes present in cervicovaginal cytology samples (CVCs) interpreted as SIL and may be histologically identified in condylomata and squamous dysplasias. Some authors support adding PKPs to the list of features warranting a diagnosis of ASC-US or even LGSIL. We report data from >800 consecutive samples labeled as ASC-US with reflex HPV testing and report the correlation between a specific cytomorphic finding, parakeratotic pearls (PKPs), and reflex HCII results.

Design: During an 11-month period, September 2002 - July 2003, 856 ThinPrep® CVCs interpreted as ASC-US at Evanston Northwestern Healthcare were reflexively triaged to our in-house molecular laboratory for HCII HPV testing. (Insufficient quantity of material for HCII, or inflammation obscuring >25% of epithelial cells resulted in exclusion of 36 samples, leaving 820 specimens). The slides were rescreened by three senior cytotechnologists (JT, HA, BO), and all possible PKPs were marked. PKPs were defined at 4X objective magnification as cohesive aggregates of at least 6 squamous cells arranged in a tight whorled group. At 40X their features included slight nuclear

membrane irregularity, hyperchromasia, pyknosis, and cytoplasmic orangeophilia. All slides marked as potentially positive for PKPs were viewed by two pathologists (CDS, LAK) for confirmation. High risk (HR) HPV (types 16, 18, 31, 33, 39, 45, 51, 52, 56, 58, 59, and 68) HCII testing results were recorded (blinded) and correlated with the presence of one or more PKPs.

Results: Of 820 women (mean age 37 yrs, range 15 to 86) with a diagnosis of ASC-US, 12% (97/820) had PKPs in their ThinPrep® slides, and 20% (161/820) had positive HCII assays for HR HPV. One percent of all reflexed ASC-US vials (11/820, 1%) had both PKPs and positive HR HPV assays (sensitivity 6.8%, specificity 87.1%).

Table 1

Parakeratotic Pearls	HR HPV present	HR HPV absent	Total
Present	11	86	97
Absent	150	573	723
Total	161	659	820

Conclusions: PKPs in ThinPrep® CVCs interpreted as ASC-US do not independently correlate to a positive reflex test for HR HPV (P<0.0291). Our data suggest that PKPs are most often unrelated to underlying HR HPV infection. Finding PKPs alone in CVCs does not warrant an interpretation of SIL and should be used only in concert with other findings to label a sample as ASC-US.

309 Integrated Molecular Pathology Evaluation of Pancreatic Brush Cytology

O Lapkus, YL Liu, M Leon, PA Swalsky, M Wilson, SD Finkelstein, JF Silverman. Allegheny General Hospital, Pittsburgh, PA; RedPath Integrated Pathology, Pittsburgh, PA.

Background: Cytologic evaluation of pancreatic duct brushing (PDB) cytology can be challenging, especially in determining the significance of atypia lacking unequivocal cytologic features of malignancy. Moreover, there is increasing reliance on cytology for definitive diagnosis with subsequent treatment implications. We evaluated the efficacy of an integrated molecular and cytology approach using microdissection and broad panel mutational genotyping.

Design: 40 PDB cytology specimens were retrieved from the cytology archives. Xylene resistant markings were placed on the slide underside and coverslips removed. Clusters of normal (n=10), atypical (n=20) and malignant (n=10) cells were manually microdissected and DNA extracted. Mutations (allelic imbalance [LOH]) were quantitatively determined for a broad panel of 15 markers (1p,3p,5q,9p,10q,17p,17q,21q,22q) as well as point mutation in K-ras-2 using PCR/capillary electrophoresis. The presence, cumulative amount (fractional mutation index [FMI]) and time course of mutational damage was correlated with cytologic diagnoses (Chi square).

Results: All benign cytology cases displayed a low levels of mutation (FMI 0.14, SD 0.07). Atypical cytology cases manifested a significantly higher rate of mutation accumulation (FMI 0.24, SD 0.15, p<. 05), dominated by K-ras-2 point mutation as the first event. 7/20 (35%) of atypical cases manifested 3 or greater accumulated mutations. Malignant cases correlated with the highest levels of cumulative mutational damage (FMI 0.38, SD 0.08, p<. 01) with no case having fewer than 3 mutations. 90% of malignancies manifested K-ras-2 as the initial acquired mutation.

Conclusions: The diagnosis of malignancy can be improved by quantifying the extent of acquired mutational damage guided by cytomorphology to optimize sample selection for molecular analysis. The benign cells demonstrated a low level of mutation with proportionately increased mutations in the atypical and malignant cases. Approximately 1/3 of the atypical PDB specimens showed a significant rate of mutation accumulation, which could prompt closer follow-up. Neoplasia appears to begin with a wide range of potential mutational targets; however the acquisition of K-ras-2 appears to accelerate over the time course. Early diagnosis, and better discrimination between cytologic atypia and carcinoma can potentially be achieved by incorporating mutational analysis into the cytology evaluation.

310 What Is the Significance of a Negative FISH in Patients with Atypical Urine Cytology?

S Latif, ML Nordberg, D Veillon, S Martin, GA Herrera, EA Turbat-Herrera. Louisiana State University Health Sciences Center, Shreveport, LA.

Background: More than 54,000 cases of urothelial carcinoma are detected annually; 10,000 people die. Cystoscopy and urine cytology are the primary methods for the detection of urothelial carcinoma. However, as poor sensitivity of urine cytology, especially in diagnosing low-grade tumors presents a diagnostic challenge, more sensitive methods are desired for the detection of transitional cell carcinoma (TCC). Fluorescence in situ hybridization (FISH) analyses have been used in detection of these malignancies as increased chromosomal instability and aneuploidy have been found to accompany bladder tumor progression. This prospective study was initiated to determine if chromosomal abnormalities in urine cytology help predict the diagnosis in urinary bladder biopsies.

Design: Forty-eight atypical /positive urine cytology specimens were examined in the routine manner and FISH performed. The patients were from 16 to 81 years of age. Cytospin preparations were made according to standard protocol for cytology and hybridized with a multicolor probe set designed to assess aneuploidies of chromosomes 3, 7, 17, and the p16/9p21 locus (UroVysion, Vysis/Abbott).

Results: Cytology results were reported as positive in all 9 cases of flat type and high grade TCC. Thirty six cases were reported as atypical and 5 as reactive. Twenty-two tissue biopsies were positive for TCC; two cases were diagnosed as adenocarcinoma or nephrogenic metaplasia. Two tissue biopsies were negative for malignancy. Chromosomal studies on urine specimens were abnormal in 13/22 TCC cases (60%). All high grade TCC were abnormal by FISH (5/5). In flat type TCC, FISH analyses were abnormal in (4/5) 80% of cases, but only (4/9) 44 % of intermediate grade and (1/

4) 25% of low grade papillary TCC were abnormal. Forty percent of TCC proven by biopsy were negative by FISH. Surgical biopsies were not performed in most FISH negative atypical cytologies, in patients less than 50 years of age

Conclusions: FISH analyses were abnormal in a significant number of cases that were diagnosed initially as positive/atypical by cytology. Sampling and non-targeted chromosomal abnormalities may explain the negative FISH results in biopsy-proven TCC cases. Currently, we recommend that FISH be used in conjunction with cytostcopy and urine cytology to detect TCC cases more effectively. Normal FISH results can be seen in urine cytologies of biopsy proven low grade TCC. We recommend biopsy on FISH negative cases with more than one atypical urine cytology.

311 Reflex Testing for HPV by Hybrid Capture HCII in Women Less Than 20 Years of Age Strongly Supports the Need for Testing in This Age Group

S Latif, J Matthews-Greer, D Rivette, B Meeks, R Reyes, JA Bocchini, EA Turbat-Herrera. Louisiana State University Health Sciences Center, Shreveport, LA.

Background: Testing for high-risk (HR) HPV on patients with atypical pap smears has become common in private practice settings. It is known that young women (adolescents) are more likely to get HPV infection resulting in dysplasia. However reflex testing in university hospitals is less commonplace due to the expense of the test coupled with institutional budget constraints. In our pediatric population the prevalence of cervical abnormalities (ASC-US and above) is high. Testing is performed in patients of all ages using the Hybrid Capture II (HCII) assay. The purpose of this study is to establish the prevalence of HPV in our university hospital based population of less than 20yrs of age and compare it to other socioeconomic groups.

Design: 873 patients underwent reflex HPV testing from Jan 1-Aug 1,2004, at the LSUHSC. Patients were divided into three groups:13-19 yo, 20-25 yo and >25yo. Liquid-based pap smears were prepared in the routine fashion. The remaining sample was submitted for HCII assay for detection of high-risk HPV using a cut-off of 1.2 to prevent missing true positives. One hundred and forty-three patients <20yrs of age from LSUHSC were compared with 40pts of the same age from our outreach clients (OR). In our 20-24 age group,170 LSUHSC patients were compared with 64 (OR) patients. In our >25 year old, 445 LSUHSC patients were compared with 111 (OR) patients.

Results: Out of 873 HCII assays for high risk HPV, 6 were indeterminate (1%), 540 were positive (62%) and 327 were negative (37%). (See table).

Conclusions: HPV is more prevalent in our pts less than 20yrs of age (13-19) especially the free care (LSUHSC-S) group (86%) as compared to the OR (75%) of the same age group. Our study supports the need for HPV testing and close follow-up to prevent cervical carcinoma in young women less than 20 yrs especially those of lower socioeconomic group where HPV is more prevalent.

RESULTS

Total Patients 873	<20(%)	20-24(%)	>25 (%)
LSUHSC	123/143 (86)	143/170 (84)	198/445 (44)
OR	30/40 (75)	46/64 (72)	40/111 (36)

312 Fluorescence In-Situ Hybridization in Detecting Lung Cancer in Bronchial Brushing Specimens

S Latif, EA Turbat-Herrera, A Sarker, S Martin, M Lowery-Nordberg. Louisiana State University Health Sciences Center, Shreveport, LA; Feist-Weiller Cancer Center, Shreveport, LA.

Background: Lung carcinoma diagnosed at an early stage has a better prognosis. Despite present screening strategies aimed at early cancer detection, bronchial washing/ brushing and sputum cytologies still lack sensitivity for the presence of tumor cells. Morphologic determination of reactive vs. neoplastic cells can be difficult. Genetic instability and overt chromosomal aneuploidy is documented in lung carcinoma. Fluorescence in situ hybridization (FISH) analysis is a powerful tool for detecting chromosome and locus-specific changes in tumor cells. Using FISH, chromosomal abnormalities can be investigated independently of the proliferative capacity of tumor cells in vitro.

Design: This study was designed to determine if FISH analysis is useful for detecting lung carcinoma in bronchial brushing specimens. Using a multicolor probe cocktail (LAVysion, Vysis/Abbott), cytology preparations were evaluated for genetic abnormalities including epidermal growth factor receptor (EGFR) (7p12), c-myc (8q24), chromosome 5 (5p15.2), and chromosome 6. The results of this FISH assay were compared with the cytomorphologic diagnoses. Forty-one bronchial brushing specimens were studied. Thirty-three were reported as atypical, suspicious for carcinoma or positive for carcinoma (considered positive for study purposes). Eight were reported as normal or negative. Biopsies were performed in 36/41 cases. Cytology slides were destained and FISH performed following standard procedure. Cells showing > two signals for any chromosomal locus were considered aneuploid. Cells showing < two signals of each chromosome were interpreted as having a deletion. Both these categories were considered FISH positive.

Results: See table for results.

Conclusions: Cytologic and histologic diagnoses in bronchial brushing specimens are concordant in 60% atypical, 66% suspicious and 88% of positive cases. FISH is useful as an ancillary tool with cytology and histology, especially in cases when the biopsy is difficult to obtain. FISH was supportive of the diagnosis in 10% atypical and 50% of suspicious cases. Investigations of additional chromosomal loci, along with a larger study series, is in progress to answer remaining questions.

Results	FISH 17/33 (51%)	Biopsy 25/36(70%)
cytology#33/41(80%)		
atypical 10	1/10 (10%)	6/10 (60%)
Suspicious 6	3/6 (50%)	4/6 (66%)
Positive 17	13/17 (77%)	15/17(88%)

313 Follicular Thyroid Proliferations without Conclusive Cytology: Telomerase Activity Increases Diagnostic Sensitivity

E Lerma, J Mora, F Alvarez-Nuñez, S Bague, A Carreras, E Esteva, A Clua, X Rius, A Leiva, J Prat. Hospital de la Santa Creu i Sant Pau. Autonomous University of Barcelona., Spain.

Background: Telomerase activity (TA) has been detected in most malignant neoplasms, including thyroid carcinomas. We studied the utility of TA detection as an ancillary tool to thyroid FNA for cases with non-conclusive cytological diagnosis.

Design: Material obtained by FNA from palpable thyroid nodules in one hundred and sixty seven consecutive patients was processed for conventional cytological studies and, simultaneously, for TA study. All negative cases have been followed for more than one year and the suspicious/positive tumors by FNA or TA, have been resected for pathological studies of nodules. Telomerase activity was analyzed by Telomerase PCR ELISA® (Roche Diagnostics).

Results: Cytology: One hundred and twenty cases were negative for malignant cells 21 were suspicious and 6 positive for malignant tumor cells. Other twenty cases were excluded because insufficiency of material for cytological study. **Histopathological confirmation:** was obtained in 23 patients, 17 with suspicious cytology, 5 with positive FNA, and 1 with insufficient material for cytological diagnoses but high clinical suspicion of neoplasia. The histopathological diagnosis were nodular hyperplasia in 5 cases, follicular adenoma in 3, papillary carcinoma in 11, follicular carcinoma in 1, medullary carcinoma in 2 and lymphoma in 1. **Telomerase Activity:** was positive in one follicular adenoma, one medullary carcinoma, one lymphoma and three papillary carcinomas, including the case with insufficient material for cytologic study.

Conclusions: Detection of TA confirmed a neoplasm in 5 of 23 suspicious thyroid nodules. Although less sensitive than FNA, TA specificity for neoplasia was 100%. Thyroid FNA sensitivity can be increased with TA detection when cytology is nonconclusive for malignancy.

314 CDX2 Protein Expression in Pulmonary FNA Specimens: A Useful Adjunct for the Diagnosis of Metastatic Colorectal Adenocarcinoma

P Levine, A Joutovsky, J Cangiarrella, H Yee, A Simsir. New York University School of Medicine, New York, NY.

Background: CDX2 is a homeobox gene which encodes a transcription factor that plays a vital role in the development and differentiation of intestinal epithelial cells. Recent studies showed that CDX2 protein expression by immunohistochemistry has a high predictive value for confirming the diagnosis of colorectal adenocarcinoma (ACA). A comprehensive study that evaluated CDX2 expression in microarrays of 745 carcinomas from many anatomic sites detected strong and extensive immunohistochemical staining in 90% of colonic ACAs whereas only 20 to 30% of ovarian mucinous, gastric and esophageal carcinomas, and less than 1% of other types of carcinomas were immunoreactive for CDX2. CDX2 expression has not been studied in FNA specimens. Immunohistochemical staining patterns may vary in clinical samples obtained by FNA due to the small amount of tissue collected and fixation. The differentiation of primary pulmonary ACA from metastatic colorectal ACA can be extremely challenging on FNA in patients with known history of colorectal primary and a single lung nodule, or in patients who present with multiple lung nodules and no known primary. TTF-1, CK7 and CK20 may not always aid in the differential diagnosis. In this study, we sought to evaluate the clinical utility of CDX2 in lung specimens obtained by FNA.

Design: Cell blocks from 21 primary lung and 20 metastatic colorectal ACAs to the lung were retrieved. The cell block sections were immunostained with a CDX2 monoclonal antibody. Positive staining was defined as nuclear staining in greater than 10% of the tumor cells. Staining intensity was scored from 1+ (weak) to 3+ (strong).

Results: All primary pulmonary ACAs were negative for CDX2. Fifteen of 20 (75%) metastatic colorectal ACAs to the lung were positive for CDX2. The staining was crisp and very easy to interpret. The positivity ranged from 1+ to 3+ (13% 1+, 46% 2+, 40% 3+). In 50% of the cases, the staining was diffuse, in 30% staining was present in 50 to 75% of the cells, and in 20%, 10 to 50% of the cells were positive.

Conclusions: CDX2 is a highly useful immunohistochemical marker for the differentiation of primary pulmonary ACA from colorectal ACA metastatic to the lung in FNA specimens. However, in cytologic specimens, its sensitivity for colorectal ACA is lower than the previously reported rates (90 to 99%) for surgical specimens. We are currently studying a larger number of a variety of tumors metastatic to the lung to better define the sensitivity and specificity for CDX2.

315 Diagnostic Value of OCT4 in Separating Metastatic Seminoma from Other Malignant Neoplasms in Fine Needle Aspiration Cytology and Core Biopsy Specimens

X Lin, YL Liu, JF Silverman. Allegheny General Hospital, Pittsburgh, PA.

Background: OCT4 is a transcription factor that is expressed in the embryonic stem cells and germ cells. Previous studies indicated that OCT4 can be expressed in seminoma and embryonal carcinoma, but not in other types of germ cell tumors. Separation of metastatic seminoma from malignant lymphoma and metastatic melanoma is important and can be challenging in FNA cytology and core biopsy. The diagnostic value of OCT4 in separating metastatic seminoma from malignant lymphoma and melanoma in FNA cytology and core biopsy has not been studied.

Design: 45 FNA and core biopsies including 15 seminomas, 15 large cell lymphomas, and 15 metastatic melanoma were retrieved from the hospital computer system. Immunostaining for OCT4, LCA, S-100 and HMB-45 were performed on an automated immunostainer with appropriate positive and negative controls. The statistical analysis was performed with Chi-Square.

Results:

Table. Immunohistochemical reactivity to OCT4, LCA, S-100 and HMB-45 in seminoma, lymphoma and melanoma

Neoplasms	OCT4	LCA	S-100	HMB-45
Seminoma	100.0% (15/15)*	0.0% (0/15)	0.0% (0/15)	0.0% (0/15)
Lymphoma	0.0% (0/15)	100.0% (15/15)*	0.0% (0/15)	0.0% (0/15)
Melanoma	0.0% (0/15)	0.0% (0/15)	100.0% (15/15)*	80.0% (12/15)*

*; P < 0.01

Conclusions: Our results show that OCT4 is selectively expressed in metastatic seminomas, but not in lymphomas and melanomas. We recommend that OCT4, LCA, S-100 and HMB-45 be included in the immunohistochemical panel for the work up of metastatic tumors when the differential diagnosis includes metastatic seminoma, lymphoma and melanoma in FNA cytology and core biopsies.

316 Role of NMP-22 in Atypical Urine Cytology: Do We Have a Silver Bullet?

I Mansoor, RR Calam, EW Schervish, B Al-Khafaji. St. John Hospital and Medical Center, Detroit, MI.

Background: Inconclusive (Atypical) urine cytology remains a major dilemma in the current clinical practice. This study aims to determine the diagnostic utility of nuclear matrix protein-22 (NMP22) marker in the diagnostic work-up of patients with atypical urine cytology.

Design: Over the period 1/2002 to 4/2004, we identified two hundred and fifty-four inconclusive (INC) urine cytology samples that had undergone NMP-22 marker testing and a follow-up Cystoscopy with surgical biopsy. NMP-22 test was considered positive when the marker signal was higher than 10 U/ml. Cystoscopy with histological diagnosis on surgical biopsy was considered the reference test.

Results: Patients mean age was 72 (SD 9.8) years (ranging from 48 to 92), 75% were male and 25% female. Table-I compares the histopathological diagnosis (positive or negative for neoplasm) versus NMP-22 results. Meanwhile, Table-II lists the specific histopathological entities on surgical biopsy evaluation, and compares to NMP-22 results. NMP-22 showed an overall sensitivity (SN) of 64%, specificity (SP) of 98%, positive predictive value (PPV) 95.3% and negative predictive value (NPV) 82%. When NMP-22 testing was applied to INC cases only 38/254 (15%) were misclassified in regards to the presence or absence of a neoplasm.

Conclusions: Our study demonstrates that NMP-22 testing aided in the clarification of the majority (85%) of INC cases. Urinary NMP-22 is a rapid and effective marker that can be used as a non-invasive adjuvant test with cytology, especially in the inconclusive/atypical cases. NMP-22 offers a rapid instant alternative to repeat cytological evaluation or surgical biopsy to clarify atypical urine cytology in clinical practice. Furthermore, NMP-22 has an excellent overall specificity (98%), PPV (95.3%), plus a high sensitivity for high-grade lesions (77%). NMP-22 showed a comparatively lower sensitivity in low-grade lesions (53%) as 22/47 (41%) of LG-PUCs were misclassified as false negative. However, all these cases were inconclusive on cytology.

Table I

Histological Diagnosis	Negative NMP-22	Positive NMP-22	Total
Negative	155 (TN)	3 (FP)	158
Positive	35 (FN)	61 (TP)	96
Total	190	64	254

TN= true negative, FP=false positive, FN=false negative, TP=true positive

Table II

Histological Diagnosis	NMP Negative	NMP Positive	Total	SN*/SP** of NMP
LG-PUC	22	25	47	53%*
HG non-invasive PUC	7	18	25	72%*
HG invasive PUC	0	10	10	100%*
Flat Carcinoma	6	8	14	58%*
Reactive	50	1	51	98%**
Negative	105	2	107	98%**
Total	190	64	254	-

317 Atypical Urine Cytology: First Try, Second Try, Do We Improve?

I Mansoor, B Al-Khafaji. St. John Hospital and Medical Center, Detroit, MI.

Background: Inconclusive (Atypical) urine cytology remains a major dilemma in the current clinical practice. This study aims to compare the diagnostic utility and accuracy of urine cytology in detecting Urothelial Neoplasm (UNp), performed only once on the first encounter of patient versus repeating urine cytology at a consecutive visit.

Design: One thousand two hundred and eight urine cytology samples were evaluated in this study, during the period 1/2002 to 4/2004. These included 954 initial urine evaluations with 254 follow-up urine evaluations on the inconclusive cases, i.e. with a prior diagnosis of atypical urine cytology. All had a follow-up cystoscopy with surgical biopsy. Cystoscopy with histological diagnosis on surgical biopsy was considered the reference test.

Results: Patients in our study had a mean age of 68 (SD 10.9) years, ranging from 19 to 96. 83% were males and 17% females. Eight hundred and twenty one cases were negative for malignancy on surgical biopsy histological evaluation, while 133 cases revealed an UNp (17 Invasive High-grade (HG) UC, 31 Non-invasive HGUC, 18 Flat carcinoma-in-situ, 63 Low-grade (LG) UC, 4 Papillary Urothelial Neoplasm). Meanwhile, cytological evaluation, which preceded the biopsy of surgically negative cases, concurred in 665 as true negative (TN), was inconclusive/atypical (INC) in 158, and false-positive (FP) in 2 cases. As for cytological evaluation of surgically positive cases it conflicted in 20 false-negative (FN), was inconclusive/atypical in 96, and concurred in 13 true positive (TP). Urine cytology was repeated a second time on all 254 inconclusive cases at a mean interval of 16 days. Among the surgically negative cases only 26 of 158 persisted as INC with the remaining 132 as TN, and 0 FP. Whereas 89 of 96 (93%) INC cytology persisted in surgically positive cases, 6 were TP for UNp, and 1 was FN.

Conclusions: Atypical urine cytology continues as a diagnostic/clinical dilemma, with a 26% inconclusive rate on the first encounter in this study. However, repeat urine cytology dramatically reduces the INC rate to almost half 115/254 (12%). Furthermore, 77% (89/115) of persistent INC urine cytology on a second exam were associated with UNp. In conclusion, persistent atypical urine cytology on two samples showed a 77% association with a Urothelial Neoplasm. A thorough clinical/diagnostic work-up is recommended in all such cases with persistent atypical cells on repeated urine cytology.

318 The Incidence of HPV and Cervical Dysplasia in Rural Nigeria

N Markelova, PF Schnatz, D Holmes, J Harp, K Stevens, K Hodges, W Waszczak, SR Mandavilli. Hartford Hospital, Hartford, CT.

Background: It is commonly accepted that HPV is the precursor to cervical cancer. Effective screening programs have decreased the incidence of cervical cancer in women in developed countries but worldwide cervical cancer is the second most common cause of death. Less information is known about the prevalence of HPV and dysplasia in third world countries. The aim of this study was to find the prevalence of HPV and cervical dysplasia in a rural town of Nigeria.

Design: In March of 2004, a medical mission project was performed in Okene, Kogi State, Nigeria through the Christian Medical Fellowship (www.C-M-F.org). During the course of the mission, the ObGyn team evaluated 231 consecutive patients. ThinPrep™ PAP smears were collected by the standard technique on two hundred patients (age ranging from 19 to 65 years; average age 33 years) who met our criteria of not being pregnant and not having a known history of cervical dysplasia or cervical cancer. One hundred and ninety nine PAP smears were available for cytologic analysis and HPV DNA detection (performed using Digene HPV DNA Hybrid Capture II™ test).

Results: Of the patients seen, 3 (1.3 %) claimed to have had a PAP smear in the past. Fifteen patients (6.5 %) had never seen doctor before and 161 (69.7 %) had seen a doctor four or less times in their life. Of the 199 PAP smears performed, 22.6% had either High Risk (HR) HPV, Low risk (LR) HPV, or both. HR HPV was present in 18.1% of the women. There were 13 (6.5%) abnormal PAP smears, and of those there were 9 (4.5%) cases of ASCUS, 1 (0.5%) AGUS, 2 (1%) LSIL, and 1(0.5%) HSIL. Other findings were Trichomonas vaginalis in 18 cases (9%) and Candida in 27 (13.5%). **Conclusions:** The incidence of HPV and abnormal PAP smears was higher in our population than in the United States as reported by the Centers for Disease Control. The incidence of HPV and abnormal PAP smears, however, was lower in our study population than previous studies conducted in other African cities. Improved access to health care and implementation of cervical cancer screening programs may help decrease the transmission of HPV and subsequent cervical cancer in underprivileged areas.

319 The Significance of Squamous Dysplasia in Urine Specimens from Patients with High Grade Urothelial Carcinoma (HGUC)

S Masoom, CN Booth, A Salhadar, R Massarani-Wafai, EM Wojcik. Loyola University Medical Center, Maywood, IL.

Background: The term urothelial carcinoma (UC) is used for tumors that have recognizable areas of urothelial differentiation. UC also includes tumors that have squamous, or other types of differentiation as major components. The term squamous cell carcinoma is reserved for cases with purely malignant squamous cells. Squamous differentiation occurs mainly in HGUC with invasion. The aim of this study was to determine the frequency of dysplastic squamous cells (DSC) in urine specimens obtained from patients with HGUC.

Design: Ninety-eight urine cytology specimens (49 bladder, 8 ureteral and 7 renal pelvic washings, 25 voided urines, 6 catheterized urines and 3 ureteral brushings) and 93 corresponding surgical specimens (71 biopsies, 5 nephrectomies, 12 cystectomies, 4 ureterectomies, and 1 urethrectomy) diagnosed as HGUC (WHO Grade 2 and 3) were obtained from 68 patients (49 male and 19 female) ranging from age 40 to 89 years (mean= 70 years). The original cytologic diagnoses were: positive or suspicious (56 cases; 57%) and negative or atypical (42 cases; 43%). Cytologic and surgical specimens were reviewed and the following parameters were evaluated: histologic presence of squamous differentiation, and DSC on cytology.

Results: Twenty patients of 68 (29%) had surgical specimens that showed squamous differentiation. Seventeen patients had urine cytology specimens, which showed DSC (25%). In 16 patients (23%), squamous differentiation was seen in both cytologic and surgical specimens. Thirteen of 56 (23%) urine specimens initially diagnosed as positive or suspicious contained DSC. In four cases, only DSC were seen and there was no evidence of malignant urothelial cells.

Conclusions: Squamous differentiation is a relatively common finding in patients with HGUC. In a significant number of cases (25%), DSC are present in urine specimens from patients with urothelial carcinoma and indicate high tumor grade. Rarely, dysplastic squamous cells are the only evidence of a high-grade malignancy. The presence of dysplastic squamous cells should be reported on cytologic urine specimens with appropriate comments explaining the possibility of an underlying malignancy.

320 Comparison of Biopsy and Cytology Samples Taken with the Light Induced Fluorescence Endoscopy (LIFE) Bronchoscopy System

SJ Maygarden, W Funkhouser, G Flake, R Slebos, F Detterbeck, J Taylor, M Rivera. UNC, Chapel Hill, NC; NIEHS, Research Triangle Park, NC; Vanderbilt Medical Center, Nashville, TN.

Background: The LIFE bronchoscopy system is a research tool used to monitor patients at high risk for development of malignancies of bronchial epithelium. LIFE bronchoscopy uses a helium cadmium blue laser to cause bronchial epithelium to autofluoresce. Normal and abnormal tissues fluoresce different colors, which can guide sampling.

Design: The pathology reports of all patients enrolled in the UNC LIFE trial from Nov 1999-May 2004 were reviewed. Numbers of patients and procedures with both biopsy (bx) and cytology (cyt) performed and results of concomitant bx and cyt sampling were compared.

Results: 47 patients were enrolled in the study. 42 of these had both bx and cyt (bronchial wash and/or brush) samples. These 42 patients underwent a total of 81 LIFE bronchoscopy procedures (1-6/patient), 74 of which included cytologic samples. These 74 procedures generated 299 bx for permanent sections(1-9/procedure), 159 bx for molecular analysis with frozen sections (FS) available for morphologic evaluation, and 145 cyt (1-5/procedure). Comparison of bx (permanent and FS results) and cyt results revealed that in 39 procedures (52.7%) both the bx and cyt specimens were benign (normal, inflammation or squamous metaplasia). In 14 procedures (18.9%) bx showed moderate/severe dysplasia, squamous carcinoma in situ or microinvasive carcinoma, and cyt specimens were atypical, suspicious or malignant. Non-correlating procedures included 17 (23%) in which cyt was benign and bx showed mild dysplasia on permanent sections (9) or on FS sections only (8); 3 procedures (4%) in which bx showed moderate dysplasia and cyt was negative, and 1 procedure (1.3%) in which cyto was suspicious for malignancy and bx was negative. This latter patient had subsequent needle bx of a mass which showed squamous cell carcinoma.

Conclusions: Cytologic specimens are a useful adjunct to biopsy in these high risk patients. Cytology was 82% sensitive and 100% specific for the detection of moderate dysplasia and above, and 100% sensitive and specific for severe dysplasia and above. In one case cytology only was positive, and biopsy missed the lesion. Cytology is not useful for the detection of mild dysplasia (which is also poorly reproducible between frozen and permanent sections). Cytology cannot dependably distinguish between high grade dysplasia, carcinoma in situ and invasive carcinoma.

321 Prediction of Malignant Potential of GIST Based on Immunostaining with Ki-67, bcl-2, and p53 Using FNA Materials

RS Meara, A Sinsir, D Horton, I Eltoum, DC Chhieng. University of Alabama at Birmingham, Birmingham, AL; New York University, New York, NY.

Background: It is difficult to assess the prognosis of gastrointestinal stromal tumors (GISTs) based on morphological features. Immunostaining with bcl-2, Ki-67, and p53 have been shown to aid in predicting the prognosis of GISTs in histologic material. The clinical utility of these immunohistochemical markers in cytologic material has not been adequately addressed. The objective of this study is to evaluate the use of these markers in predicting the biologic behavior of GISTs using FNA material.

Design: Cell blocks from 18 cases of GIST diagnosed by FNA were retrieved. Immunostaining was performed with antibodies against bcl-2, Ki-67, and p53. All cytologic diagnoses were confirmed by positive immunostaining with c-kit (CD117) and/or subsequent histologic evaluation. Positivity for bcl-2 (prediluted, Ventana Inc. Tuscon, AZ), K-67 (prediluted, Ventana Inc.), and p53 (prediluted, Ventana Inc.) was defined as the presence of >10% cytoplasmic staining, >5% nuclear staining, and >1% of nuclear staining, respectively. The results of immunostaining were then correlated with the biologic behavior of the tumors.

Results: The 18 patients consisted of 11 males, 7 females with age ranging from 25 to 84 years (mean: 59 years). The average follow up interval was 38 months with a range of 21 to 96 months. In 4 cases, no diagnostic material was present in the sections used for immunostaining. Of the remaining 14 cases, 3 had a benign course and 11 developed recurrences or metastases. Thirteen (93%) cases showed positive staining for bcl-2. Positive Ki-67 and p53 staining was noted in 3 (21%) and 8 (57%) cases, respectively. Table 1 summarizes the correlation of immunostaining results with biologic behavior of the tumors. The difference in staining for p53 among benign and malignant GISTs was statistically significant (p=0.036, Fisher exact test). However, no statistically significant difference was noted for staining with bcl-2 and Ki-67 among benign and malignant GIST.

Conclusions: p53 immunostaining is useful in predicting the malignant potential of GIST and may be helpful in determining subsequent patient management. Ki-67 and bcl-2 are not useful as prognostic markers for GIST in FNA specimens.

Table 1 Correlation of immunostaining results and biologic behavior

Behavior	p53 (+/-)	bcl-2 (+/-)	Ki-67 (+/-)	Total
Benign	1/4	4/1	1/4	5
Malignant	7/2	7/2	2/7	9
p-value	0.036	> 0.05	> 0.05	

322 p16 and hTERT Staining as a Triage for ASCUS: Can We Forego Molecular Testing

S Mehrotra, S Setty, A Kajdacsy-Balla, HE Gulbache, SE Pambuccian. University of Illinois at Chicago, Chicago, IL; University of Minnesota, Minneapolis, MN.

Background: The introduction of liquid based Pap tests (LBPT) and HPV testing have markedly increased the negative predictive value of the Pap test. Currently, there is a need for tests that could increase the positive predictive value of the PT by predicting the presence or potential for development of CIN 2 or worse lesions in women with PT results of ASC or LSIL. LBPT offers the possibility for performing multiple immunohistochemical stains on sections from cell blocks prepared from the residual sample. p16INK4a (p16) and telomerase reverse transcriptase(hTERT) overexpression are markers of the genomic chaos induced by the E7 and respectively the E6 genes of oncogenic HPV. We assess the value of p16 and hTERT stains on cell block preparations in identifying women at risk for CIN and to determine their sensitivity in comparison to HPV DNA testing.

Design: Cell blocks were prepared from residual samples from 80 consecutive HPV-positive LBPT. The cytologic diagnoses rendered on these Surepath LBPT were as follows: HSIL: 1, LSIL: 19, ASC-US: 26 and NILM 34. HPV DNA testing was performed using PCR with the MY09/11 consensus primers and restriction digestion to obtain

the HPV type. Cell block sections were stained with hematoxylin and eosin and immunostained with antibodies against p16INK4a(Dako) and hTERT (Novacastra). The sections were analyzed for adequacy and for positive nuclear/cytoplasmic staining for p16 and hTERT. The results of the immunostains were correlated with the follow-up biopsy diagnoses obtained within 6 months of the PapTest diagnosis (39/80).

Results: The cellularity of 70/80 cell block preparations was sufficient for performing immunostains. Positive immunostaining of cell blocks for p16 (34/70) was associated with the presence of CIN 1 or greater on cytology/follow-up biopsies. 10/21 ASCUS cases were positive for either p16 or hTERT or both all of which were positive for high-risk HPV by PCR. Overall, also there was also a good association between high risk HPV types and staining for p16 (24/34).

Conclusions: We demonstrate the ability to test for p16INK4a and hTERT expression in residual PapTest material. The current results indicate that p16 and hTERT staining may be useful in increasing the positive predictive value of HPV+ samples diagnosed as ASC or LSIL. While these results are intriguing, further studies are needed to define the place of these tests in the clinical management of women with borderline and mild PapTest abnormalities.

323 Atypical Bronchioalveolar Proliferation: A New Cytologic Category for Lung Aspiration Biopsy Representing a Bronchioalveolar Growth Pattern

JL Morhaim, AL Kramer, MF Vazquez. New York Presbyterian Hospital - Weill Cornell Medical Center, New York, NY.

Background: The cytomorphologic features of atypical bronchioalveolar proliferations (ABP) are not well described. Increased screening of high risk groups and improved CT technology has led to an increase in the diagnosis of ABP. We reviewed the cytologic-histologic correlations for a consecutive series of ABP cases to determine the significance of this diagnosis.

Design: A total of 1855 lung fine needle aspiration (FNA) biopsies were reviewed and 28 cases diagnosed as ABP (1.5%) were found. A diagnosis of ABP was rendered when the following cytologic features were identified: pinpoint nucleoli, nuclear grooves and intranuclear inclusions. The mean nuclear size and mean cell size was determined, using morphometric image analysis.

Results: A total of 28 FNAs were diagnosed as ABP in 25 patients. Surgical excision of 25 lesions was performed in 22 patients. On surgical excision, there were 10 bronchio-alveolar carcinomas (BAC) with a mean size of 1.5 cm. On completion lobectomy, 1 patient had an additional 2 mm BAC and 1 patient had 2 additional BACs measuring 2mm and 3m, and 3 patients had atypical adenomatous hyperplasia (AAH). On surgical excision, there were 11 cases of invasive adenocarcinoma (ADC) with an extensive bronchioalveolar component, mean size 1.8 cm. On completion lobectomy, 5 patients with ADC had AAH and 1 patient had a BAC measuring 2 mm. One case of ABP proved to be 2 adjacent foci of AAH measuring 3 mm and 5 mm. Another case of ABP proved to be an organizing pneumonia. The mean nuclear size and mean cell size for ABP which proved to be BAC or ADC were 10.85 um and 14.51 um, respectively; this was comparable to the mean nuclear and mean total cell size of AAH or BAC found on completion lobectomy. One case of AAH (Clara cell type) showed a mean nuclear size of 10.95 um and a mean total cell size of 20.59 um. One case of organizing pneumonia showed a mean nuclear size of 19.26 um and a mean total cell size of 44.78 um.

Conclusions: A diagnosis of ABP on cytology represents BAC or adenocarcinoma with an extensive bronchioalveolar component, and rarely AAH. Patients with lung cancer diagnosed as ABP on FNA frequently have multifocal lesions on CT scans and on completion lobectomy. Preoperative diagnosis of ABP as a distinct category aids in the surgical management of these patients. A diagnosis of ABP should be limited to cells with a mean nuclear size less than 11 um and a mean total cell size less than 15 um.

324 Improving the Quality of Cytopathology Practice: Root Cause Analysis of False Negative Diagnoses in Thyroid FNA

L Nodit, NP Ohori, D Sudilovsky, SS Raab. University of Pittsburgh Medical Center, Pittsburgh, PA.

Background: Although previous studies have reported cytologic characteristics which may be considered "pitfalls" in the cytopathologic diagnosis of thyroid specimens, no systematic root-cause analysis has been performed for false negative diagnoses.

Design: Twenty-eight thyroid false negative FNAs with histological follow-up (obtained between January 1, 2003 and April 30, 2004) were identified and reviewed. There were 7 cases of papillary carcinomas (larger than 1 cm. in size), 18 follicular neoplasms (4 carcinomas, 14 adenomas), 1 medullary carcinoma and 3 Hurthle cell neoplasms (1 carcinoma and 2 adenomas). Root-cause analysis for possible underlying causes of false negative diagnoses was performed including sampling (method, intra-operative assessment, number of passes), processing (number and type of smears, stains), cytology interpretation (independent review of the cytology specimens by authors), surgical pathology interpretation (type of papillary carcinomas and follicular adenomas), clinical reasons for resection and cytology reporting format.

Results: Sampling was the main cause of false negative diagnosis in 22 out of 28 cases. Collection by US or CT guidance resulted in an adequate specimen in only 4/15 cases (26%), whereas collection by the clinician was successful in 6/13 cases (46%). Intra-operative assessment was performed in only 4 cases. The average number of passes per case was 4. The average number of slides per case was 10. Slides stained by Diff-Quick method were more cellular than those stained by Pap. On review, 18 cases were reclassified as scant cellularity or non-diagnostic. Five papillary carcinomas were encapsulated follicular variants with incomplete cytologic features. Whereas all follicular carcinomas were microfollicular type, 3/14 adenomas were macrofollicular, 9 mixed, and 2 microfollicular. The most common reason for resection was increasing nodular size and 13 reports did not provide the side of the thyroid gland sampled.

Conclusions: There were 13 clinically significant thyroid malignancies missed by FNA at our institution in 16 months. The most frequent underlying cause for false negative diagnoses was sampling. Most of these specimens were collected under the US guidance. Interpretative errors were the result of making a benign diagnosis on specimens with scant cellularity and the absence of intra-procedural feedback. Thus, we advocate improving the sampling technique, intra-procedural assessment and resistance to make negative diagnoses on marginal aspiration specimens.

325 Improving the Quality of Cytopathology Practice: Root-Cause Analysis for Negative Diagnoses in Bronchial Washings and Brushings

L Nodit, SS Raab. University of Pittsburgh Medical Center, Pittsburgh, PA.

Background: Bronchial washings and brushings are a valuable tool in the diagnosis of pulmonary neoplasia. Previous studies have reported cytologic characteristics which may be a source of errors in interpretation of these specimens, but no root-cause analysis has been performed for negative diagnoses with the intention of planning and implementing quality improvement interventions.

Design: Twenty-nine cases of negative bronchial specimens (7 brushings, 22 washings) with malignant histological follow-up, obtained between Jan.-Dec.2002, were reviewed. Root-cause analysis for possible underlying causes of negative diagnoses was performed including collection (bronchoscopic assessment), processing (material submitted, number and type of smears, stains), cytology interpretation (review of the cytology specimens by authors), surgical pathology interpretation (type of neoplasms, location), and cytology reporting format.

Results: There were 9 false negative and 20 true negative specimens after review. Multiple sources of errors were identified in the false-negative category: bland appearance of tumor cells (2 cases), paucity of tumor cell fragments (5 cases showing only 1 or 2 tumor clusters), suboptimal smears and staining (1 case), tumor cells obscured by blood and inflammatory exudate (3 cases) and pattern of tumor shedding (predominantly as single cells -1 case). The causes for the true negative specimens were also multiple: scant cellularity in the presence of an endobronchial mass (2 cases), the sub-bronchial location of the neoplasm (10 cases), neoplasm present only in the lymphatic vessels (1 case) or intra-arterial (2 cases) and necrosis (2 cases). The cause was not apparent in 3 cases (possible sampling). In most of the cases the material collected was bloody fluid or 1 brush in saline and 2 direct smears and 2 cytospins (1 Diff Quick and 3 Papanicolaou) were prepared. Clinical history was not provided in 12 cases and 3 reports did not identify the location from which the specimen was collected.

Conclusions: This study highlights the potential sources of negative bronchial washings and brushings with malignant histological follow-up. It underlines the importance of sampling as a main origin of these results, and the need of a better communication between the clinician and pathologist (to highlight the cases with high clinical suspicion). The interpretative errors suggest the necessity of a diligent search in cases with positive bronchoscopic findings and the use of blood lysing agents to improve the quality of these specimens.

326 HPV Test Should Be Requested in High-Risk Patients as an "Anticipatory" Positive Test

V Padmanabhan, H Farhaly, LQ DuBose, L Christiansen, RS Hoda. Medical University of South Carolina, Charleston, SC.

Background: HPV test is performed for triage of ASC-US Pap smears as a reflex HPV test (R-HPV). However, gynecologists at our institution are also requesting HPV test on clinically high-risk (HR) patients (pts), with a negative (neg) concurrent Pap, as an "anticipatory" positive HPV test (AP-HPV). Herein, we report our experience with AP-HPV test, which to our knowledge, has not previously been reported.

Design: Data on all Pap tests (ThinPreps®) with HR-HPV (R-HPV and AP-HPV) performed by Hybrid Capture 2® test, over a 39 month-period (Jan '01-April '04), and pertinent follow-up (f/u), Pap test or biopsy (bx) were reviewed.

Results: There were 154 AP-HPV and 301 R-HPV tests. Of the 154 AP-HPV tests, HR-HPV was: positive (+), 44; (-), 107, and equivocal (eq), 3. Of the 301 R-HPV tests, HR-HPV was: (+), 148; (-), 138 and eq, 23. F/u (Pap test or bx), was available in 43/154 (28%) AP-HPV test [(+) 16; (-) 27] and 109/301 (36%) R-HPV test [(+) 84; (-) 25]. Eq cases were not included. Seven of 16 AP-HPV (+) cases showed a lesion on f/u, including 2 HSIL cases (sensitivity 44%); while, 24/27 AP-HPV (-) cases had a (-) f/u (specificity 89%); 38 of 84 R-HPV (+) cases showed a lesion on f/u, including 8 HSIL cases (sensitivity 45%); while, 16/25 R-HPV (-) cases had a (-) f/u (specificity 64%).

Follow-up Pap test and bx results in pts with AP-HPV and R-HPV tests

HPV test	Pap				Bx		
	Neg	ASCUS	ASC-H	LSIL	Neg	LSIL	HSIL
AP-HPV (+)	5	-	1	-	4	4	2
AP-HPV (-)	22	1	-	-	2	2	-
R-HPV (+)	16	8	9	1	22	20	8
R-HPV (-)	15	5	-	-	1	4	-

Conclusions: Sensitivity of "anticipatory" positive HPV test in high-risk patients with a negative concurrent Pap was similar to that of R-HPV test (44% vs. 45%). "Anticipatory" positive HPV test should be performed in clinically high-risk patients.

327 *Thrichomas vaginalis* p16 Immunoreactivity in Cervicovaginal Pap Tests: A Diagnostic Pitfall

L Pantanowitz, RR Florence, RA Goulart, CN Otis. Baystate Medical Center, Tufts University, Springfield, MA.

Background: P16 detection in liquid-based cervicovaginal Papanicolaou (Pap) tests has the potential to be a useful biomarker for dysplastic and malignant lesions of squamous and endocervical mucosa. During an ongoing investigation of the utility of p16 immunocytochemistry in the evaluation of Pap tests in our laboratory, we observed

one case in which *Trichomonas vaginalis* stained positive for p16. Therefore, the aim of this study was to determine the frequency of *T.vaginalis* immunoreactivity for p16 in a series of liquid-based Pap tests.

Design: Ten Pap tests (mean patient age 32 years, range 17-47) submitted routinely in PreservCyt™ solution (Cytoc Corporation, Boxborough, MA) diagnosed as negative for an intraepithelial lesion or malignancy with *T.vaginalis* present were studied. *Trichomonas* parasites were scored as abundant (>20 organisms/hpf), moderate (10-20/hpf) or few (<10/hpf). The presence of endocervical and endometrial cells as well as concomitant organisms were noted. For each case a slide prepared from additional material using the ThinPrep™ 2000 processor (Cytoc Corporation) was immunostained with p16 (clone G175-405, BD Biosciences). The immunoreactivity, intensity (strong or weak) and pattern of p16 staining were recorded.

Results: All specimens were satisfactory for evaluation with an endocervical/transformation zone component present in 8 cases. *T.vaginalis* were abundant in 6 cases, moderate in 1 case and few in 3 specimens. No specimen had endometrial cells. Concomitant bacterial vaginosis (n=4), Candida (n=2) and leptofox (n=1) were identified. In all cases (100%) *T.vaginalis* were p16 positive and demonstrated strong (9/10), granular, cytoplasmic staining that was diffuse (8/10) or patchy (2/10). In only one case were some of the parasites negative for p16. The internal structure (nucleus, blepharoplasts, cytoplasmic granules) and flagella of several parasites were discernable with p16 staining. Epithelial and inflammatory cells in all cases were p16 negative, except for occasional weak staining of clue cells in the 4 cases with bacterial vaginosis. Candida and leptofox were p16 negative.

Conclusions: These data document, for the first time, that *Trichomonas vaginalis* in liquid-based Pap tests stain positively with p16 immunocytochemistry. Therefore, p16 immunoreactive *T.vaginalis* may be mistaken for small dysplastic and/or malignant epithelial cells. The presence of this parasite in Pap tests may potentially hinder the use of p16 as an adjunct to liquid-based cervical screening cytology.

328 Hodgkin Lymphoma Versus Reactive Lymph Node: Morphologic Clues for Diagnosis on Fine Needle Aspiration

RY Peng, SL Hirschowitz. University of California Los Angeles, Los Angeles, CA.

Background: Fine needle aspiration (FNA) is a minimally invasive diagnostic tool for evaluating lymphadenopathies. Since the classical Reed-Sternberg cells are not always present, making a FNA diagnosis of Hodgkin lymphoma (HL) can be challenging. A reactive lymph node (RLN) can be a diagnostic pitfall in this scenario. This study identified cytomorphological features useful in distinguishing HL from a RLN on FNA.

Design: 20 FNA cases with corresponding surgical pathology specimens diagnosed as HL and 22 FNA cases of a RLN confirmed by surgical pathology, flow cytometric analysis, or clinical follow up were reviewed. The FNA cases were randomized and the more prominent cells were evaluated for the presence and size of a mononucleus, binucleated nuclei, and multilobular nucleus. The size and quantity of nucleoli in these cells were also analyzed. A large nucleus was defined as having a total nuclear diameter ≥ 4 small mature lymphocytes; a small nucleus had a nuclear diameter < 4 small mature lymphocytes. A large nucleolus was defined as having a nucleolar diameter ≥ 1 small mature lymphocyte; a small nucleolus had a diameter < 1 small mature lymphocyte.

Results: Of the 20 HL FNA cases, 16 cases had cells with a large mononucleus and large nucleolus or nucleoli. 12 of these 16 cases had a large single nucleolus, and 11 had multiple large or multiple small and large nucleoli. 13 HL FNA cases had cells with large binucleated nuclei and large nucleoli, of which 10 had a single large nucleolus per nucleus, and 5 had multiple large or multiple small and large nucleoli per nucleus. 12 HL FNA cases had cells with a large multilobulated nucleus and large nucleoli. 7 of these 12 cases had one large nucleolus per lobe, and 9 cases had multiple large nucleoli or multiple small and large nucleoli per lobe. 19 (95%) of the 20 HL FNA cases demonstrated any combination of large nuclei with large nucleolus or nucleoli. In comparison, none of the 22 RLN FNA cases had cells with a large nucleus and large nucleolus or nucleoli. Small cells with a small nucleolus or multiple small nucleoli were present in both HL (85%) and RLN (100%) FNA cases.

Conclusions: The presence of any cells with a large mononucleus, large binucleated nuclei, or large multilobular nucleus in conjunction with any quantity of large nucleoli was 95% sensitive for HL on FNA. None of these features were seen in RLN FNA. Future studies examining the presence of these parameters in other hematopoietic processes may provide additional useful information.

329 The Lack of Impact of Reflex HPV Testing on Interpretation and Management of Thin-Prep Paps

Y Peng, HH Wang. Beth Israel Deaconess Medical Center (BIDMC) and Harvard Medical School, Boston, MA.

Background: Reflex HPV testing for high-risk types is an accepted option used by most providers to triage women with Atypical Squamous Cells (ASC) on ThinPrep Paps (TPs) for management. A significant percentage of providers at the BIDMC, however, are not requesting reflex HPV testing. This situation offers a unique opportunity to examine its impact on the interpretation of TPs and on the actual management of patients.

Design: Consecutive TPs submitted to the Cytology Lab at the BIDMC for a three-month period were identified retrospectively. HPV testing was determined according to the providers' requests on the requisition. The TPs were divided into those with a request for reflex HPV testing (reflex testing request group), and those without such a request. Cytologic diagnoses, results of HPV testing and subsequent cervical biopsies within six months after the TP were recorded and correlated in these cases.

Results: During this period, 2659 TPs had a request for reflex HPV testing, and 1849 did not have such a request. The number (%) of abnormal TP results in the reflex testing request group was 155 (5.8%), including 81 ASC (3.0%), 68 Squamous

Intraepithelial Lesion (SIL) (2.6%) and 6 Atypical Glandular Cells (0.23%). The number (%) of abnormal TP results in the no request group was 141 (7.6%), including 65 ASC (3.5%) and 76 SIL (4.1%). The abnormal rate for the reflex testing request and no request groups did not differ significantly (P>0.2). The ASC: SIL ratio for these two groups was 1.2 and 0.86, respectively (P=0.16). 38/71 (54%) women with ASC in the reflex testing request group were positive for high-risk HPV types and 10 did not have sufficient materials for testing. 63/155 (41%) and 67/141 (48%) women with abnormal TPs in these two groups, respectively, had cervical biopsies within the subsequent six months (P>0.2). Of those with ASC in these two groups, 18/81 (22%) and 16/65 (25%) had biopsies (P>0.2) with 4 (of 18) and 3 (of 16) showing High-grade SIL on biopsies, respectively.

Conclusions: Our study demonstrates that at our institution a request for reflex HPV testing did not significantly affect cytopathologists' interpretation of TPs. Furthermore, HPV testing did not seem to have reduced the subsequent biopsy rate in the group with reflex testing when compared to the group without such testing.

330 To Triage or Not? A Multi-Institutional Study Examining Prevalence of HPV High-Risk Types in LSIL Cases

MN Qureshi, DR Bolick, N Zafar, SE Pambuccian, RC McGlennen. Lakewood Pathology Associates, Lakewood, NJ; Ameripath, Utah, Sandy, UT; Univ. of Tennessee at Memphis, Memphis, TN; Univ. of Minnesota, Minneapolis, MN; Access Genetics, Eden Prairie, MN.

Background: The prevalence of high-risk HPV types (HR-HPV) in cervical samplings, diagnosed as LSIL, is reported to range between 80-90%, based on testing by the HC2® method.^{1,2} These results have led to the current guidelines recommending immediate colposcopy for all LSIL cases.³ We studied the prevalence of HR-HPV in LSIL cases in 4 geographically distant institutions, ranging from reference laboratories to academic medical centers.

Design: 50 consecutive residual samples from liquid based Pap tests, routinely diagnosed as LSIL from each of the four participating centers (n=200, 50 SurePath® + 150 Thinprep_®) were evaluated for the presence and type of HPV. The patient age ranged from 15-71 years. HPV was detected by PCR performed in two specialized laboratories, either using amplification with multi-type primer cocktail and sequence based typing or with MY09/11 primers and RFLP analysis. HPV types 16, 18, 31, 33, 35, 39, 45, 51, 52, 56, 58, 59, 68 and 70 were classified as HR-HPV. Ten cases had insufficient residual material and were excluded.

Results:

Prevalence of HR-HPV in LSIL Cases

AGE (YEARS)	TOTAL COHORT (n=190)			SITE 1 (n=48)	SITE 2 (n=46)	SITE 3 (n=50)	SITE 4 (n=46)
	HR-HPV (%)	Non-HR (%)	NEG (%)				
<20*	35 (32)	16 (25)	4 (27)	8 (23)	11 (40)	7 (37)	9 (32)
20-30*	47 (43)	20 (31)	5 (33)	14 (40)	13 (46)	6 (32)	14 (50)
>30*	28 (25)	29 (45)	6 (40)	13 (37)	4 (14)	6 (32)	5 (18)
TOTAL**	110 (58)	65 (34)	15 (8)	35 (73)	28 (61)	19 (38)	28 (61)

*Percentage of HR-HPV, Non-HR and negative cases in each cohort, **Percentage of total cases in cohort

Conclusions: The prevalence of HR-HPV in LSIL varied with institution, with a mean of 58% (110/190) and a range of 38-73%. An average of 42% (34% non HR-HPV + 8% negative for HPV) were negative for HR-HPV by PCR. Cohort characteristics, including age and risk factors, and diagnostic thresholds at each institution may influence the prevalence of HR-HPV in LSIL cases. From this multi-center study we conclude that testing for HR-HPV in LSIL cases is a cost-effective method of triaging cases into those that will benefit from immediate colposcopy and those in whom a costly and invasive follow-up procedure can be safely avoided.

¹Diag Cytopathol. 2004, 30:426, ²JNCI. 2000, 92:397, ³JAMA. 2002, 287:2120

331 Urinary Cytology in Pediatric Patients: Clinicopathologic Correlates

N Rekhtman, L Nodit, S Raab, AV Parwani, SZ Ali. The Johns Hopkins Hospital, Baltimore, MD; The University of Pittsburgh Medical Center, Pittsburgh, PA.

Background: Urinary cytology is a valuable tool in the detection of bladder neoplasms and other pathologic processes of the genitourinary system. The present study evaluated the clinical utility of this technique exclusively in pediatric population.

Design: A total of 166 urinary specimens from patients 1 to 21 years of age were analyzed from two large academic institutions {122 from institution A (year 1990-2004) and 46 from institution B (1998-2004)}. In addition, 130 consecutive urine specimens from adults (i.e., age 40 and above) were also studied as a control group. The pathologic and follow-up clinical data was systematically analyzed and correlated.

Results: The mean age was 15.5 years with a gender distribution of 104 male and 64 female (M:F; 1.6:1). The largest diagnostic group consisted of benign/normal cytopathologic findings (45%) or displayed acute inflammation, reactive changes and hematuria (43%). Two (1.2%) cases were diagnostic of malignancy, which were confirmed by surgical specimens as intra-abdominal desmoplastic round cell tumor (age 16) and rhabdomyosarcoma (age 3). Seventeen (10%) cases showed urothelial atypia. Surgical follow-up was done in four of these cases, which showed: renal cell carcinoma, granulomatous epididymitis, kidney stones and ureteropelvic junction abnormality. Thirteen cases with atypia were not followed by either repeat urines or surgical biopsy. No urothelial neoplasm was identified by urinary cytology in the study group. In contrast, the adult group displayed cytologic atypia in 29% of urines, which subsequently correlated with urothelial neoplasm in 35% of the cases. A urothelial neoplasm was diagnosed in 7% of urines in the adult group.

Conclusions: 1) A large majority of urinary specimens (88%) in pediatric age group are benign, display reactive changes or hematuria. 2) Urothelial neoplasms are exceedingly rare and were not present in our study group of 166 patients. 3) Cytologic atypia in pediatric age group is an uncommon category when compared with adults, and is rarely associated with a cancer follow-up unlike the adults. 4) Majority of atypical diagnosis in pediatric age group are in the benign category with no follow-up repeat urines or tissue biopsies.

332 Split Sample Analysis of Throw Away Cells from ThinPrep™ Pap Smear Sampling Devices

A Rinas, B Mittman, L VanLe, K Hartmann, J Cayless, HK Singh. The University of North Carolina, Chapel Hill, NC; University of North Carolina Hospitals, Chapel Hill, NC.

Background: We conducted a split sample study of throw away (TA) cells that are retained on the Pap smear sampling devices after they are rinsed in PreservCyt™ fixative for the ThinPrep™ Pap test. This was done to determine both the number and significance of the cells that are normally discarded after liquid based specimens are collected and to evaluate whether these findings would have an impact on the interpretation of the primary pap smear.

Design: 100 Pap smears from 100 patients were prospectively collected after gynecologic pap smears were collected for the ThinPrep™ Pap test. The sampling end of the collection device(s) was cut off and put into a vial containing Surepath™ preservative fluid and processed using the SurePath™ Prepstain™ slide processor. A single liquid based slide was prepared from the sampling device(s) from each specimen. Slides were reviewed for squamous cells, endocervical component, epithelial cell abnormalities and miscellaneous findings (infectious organisms). The slides were compared with the primary ThinPrep™ slide (PS).

Results: 25% of TA samples had equal or greater number of squamous cells per high power field compared to the PS slide. Endocervical component was present on 42% of the cervical samples. 3/5 cases (60%) interpreted as Atypical Squamous Cells of Undetermined Significance (ASCUS) had similar cells on the TA slide. 12/14 cases (86%) of Low Grade Squamous Intraepithelial Lesion (LSIL) had similar cells on TA slides. 2/4 cases (50%) of High-grade Squamous Intraepithelial Lesions (HSIL) had comparable abnormal cells on the TA slide. Miscellaneous findings on both slides included: benign endometrial cells (1 case), candida infections (4 cases), and trichomonas vaginalis organisms (1 case).

Conclusions: In contrast to split samples studies involving ThinPrep™ and conventional smears, specimens prepared from TA collecting device(s) are not as sensitive as the PS for the detection of cervical lesions. We document the presence of both normal and abnormal cells being discarded in a high percentage of cases. Discarded abnormal cells noted on the TA slides were few in number when compared to the PS, with one exception in a case of HSIL.

333 The Significance of High Risk Human Papillomavirus Detection in Elderly Women

D Rosario, C Zahn, AC Bush, BS Kendall. Wilford Hall Medical Center, Lackland AFB, TX; USUHS, Bethesda, MD.

Background: The use of high risk human papillomavirus (HRHPV) testing in the triage of women with a cytologic diagnosis of atypical squamous cells of undetermined significance (ASCUS) has gained widespread acceptance. Very little has been reported on the significance of the detection of HPV DNA in elderly women, or on the significance of the amount of DNA present when it is detected.

Design: Results of HRHPV testing performed on women \geq age 50 were examined over a 20 month period. Reflex testing for HRHPV was performed on residual liquid-based cytology specimens from women diagnosed with ASCUS, using the Digene Hybrid Capture method. A relative light unit/cutoff (RLU/CO) value of 1.0, corresponding to approximately 1.0 picogram/milliliter of HPV DNA detected, was used as the threshold of detection. Follow-up (FU) information on women with HRHPV detected was obtained from subsequent pathology reports (cytology and surgical). Follow-up ranged from 6-26 months after initial testing. The most significant results were used for analysis in women with more than one FU result. For those patients with follow-up information, RLU/CO values from the initial HRHPV test were recorded.

Results: HRHPV testing was performed on 762 specimens from women \geq 50 years of age; virus was detected in 105 (13.8%). Of those with HRHPV detected, follow-up information was available in 63 (60%). FU results included: negative, 32 (50.8% of those with FU), low grade squamous intraepithelial lesion (LSIL), 26 (41.3%); high grade squamous intraepithelial lesion (HSIL), 5 (7.9%). No glandular neoplasia or invasive carcinoma was identified. Positive predictive value of HRHPV testing for detecting any abnormality was 49%; for the detection of HSIL, it was 7.9%. RLU values were compared between groups with negative versus positive FU, and between those with \leq LSIL vs HSIL. Overall values ranged from 1.0 to 1705.0; no significant differences were identified in RLU/CO values between groups (negative FU vs \leq LSIL; \leq LSIL vs HSIL) using Mann-Whitney tests.

Conclusions: Although HRHPV was detected in a minority of elderly women, HSIL was present in 7.9% of those with HRHPV. This confirms that the presence of HRHPV in elderly women with ASCUS smears needs clinical FU. No significant differences exist in RLU/CO values between women with positive vs negative FU, thus all HRHPV positive results should be pursued.

334 ASC-H: Should We Reflex-Test for HPV DNA Too?

M Roychowdhury, S Setty, HE Gulbahce, EB Stelow, K Kjeldahl, SE Pambuccian. University of Minnesota, Minneapolis, MN.

Background: The current ASCCP management guidelines recommend immediate referral to colposcopy of women diagnosed with ASC-H. However, not all practitioners adhere to this recommendation and the majority of clinics served by our institution currently request reflex HPV testing of all liquid-based Pap tests (LBPT) diagnosed as ASC-H. We review our institution's experience with PCR-based HPV reflex testing of women with ASC-H diagnosed on Surepath LBPT.

Design: All ASC-H diagnoses made during the 18 months interval from 12/01/02 to 5/30/04 as well as their corresponding HPV reflex tests and follow-up biopsies performed within 6 months were retrieved and analyzed. HPV testing was performed by PCR with the MY9/11 primers, while typing was performed by RFLP.

Results: During this interval our institution processed 98,480 Pap tests (PT) (95% LBPT) of which 93% were screening PT and 7% diagnostic PT. 4,872 (4.9%) were diagnosed as ASC, and 411 (8.4%) of these as ASC-H. The ASC/SIL ratio was 2:1. Of the 411 PT diagnosed as ASC-H, 294 (71.5%) were reflex tested for HPV. Two cases had an unsatisfactory HPV test, 161 (55.1%) were negative for HPV and 131 (44.8%) were positive for HPV, 113 (38.7%) for high-risk HPV (hr-HPV) types. The most common HPV type was HPV16 which accounted for 42% of HPV+ cases, followed by HPV31 and 58 (9.7% each).

231/411 women had follow-up biopsies, 3 of which were unsatisfactory. The proportion of women who had follow-up biopsy did not differ between those who had a HPV test (163/294, 56.4%) and those who did not (65/117, 55.6%). Overall, the biopsies showed no dysplasia in 123/228 (53.9%), CIN 1 in 47/228 (20.6%), and CIN2+ in 58/228 (25.4%) (7.9% CIN 2 and 17.5% CIN 3). In HPV-tested cases the results were as follows:

	No dysplasia	CIN I	CIN II and above	Total
hr-HPV +	27 (36%)	13 (17%)	35 (47%)	75 (100%)
hr-HPV -	64 (73%)	13 (15%)	11 (12%)	88 (100%)
HPV not tested	32 (47%)	21 (32%)	12 (18.5%)	65 (100%)

The negative predictive value (NPV) of the HPV test for CIN 2 or worse was 87.5%.

Conclusions: We found high proportion of ASC-H to be associated with hr-HPV types, especially with HPV16. However, the NPV of the PCR-based HPV DNA test (in ASC-H cases) was lower than that obtained in the reflex testing of ASC-US. Our data support the recommendation for immediate colposcopy of women with ASC-H, since a relatively high proportion of these women have significant lesions. Further refinements of the methodology may increase the HPV DNA test's sensitivity and make the triage of ASC-H for colposcopy possible.

335 Utility of Squash Preparations in Grading of Astrocytomas

RS Saad, H Takei, K Fallon, YL Liu, JF Silverman. Allegheny General Hospital, Pittsburgh, PA; Louisiana State University, School of Medicine, New Orleans, LA.

Background: Frozen sections and squash preparations are essential for intraoperative evaluation of brain tumors. However, the soft nature of brain tumor tissues and small sized stereotactic biopsy usually limit the quality of frozen sections. In addition, the development of new cytogenetic techniques, as diagnostic, therapeutic, and prognostic indicators, mandates the pathologist to conserve sufficient tissue for such studies. In this study we investigated the utility of intraoperative squash preparations for grading astrocytomas in comparison to frozen sections.

Design: We included randomly selected 100 cases of astrocytomas from January 2000 to December 2001. Two squash preparations and frozen section slides were prepared for intraoperative consultation, stained with routine H and E. The diagnosis was verified on permanent sections. Cases were reviewed, retrospectively, by two cytopathologists and two neuropathologists, with clinical and radiological data, but without knowledge of the final neuropathological diagnosis or grading. Cases included 3 cases of astrocytoma grade 1, 27 cases astrocytoma grade 2 and 35 cases astrocytoma grade 3 and 38 glioblastoma multiforme (grade 4). Also, cytology specimens were analysed for cellularity, pleomorphism, mitosis, blood vessel proliferation and necrosis.

Results: Original frozen section misdiagnosed/or misgraded the tumors in 32/100 (32%) of cases. Two cases were misdiagnosed as meningioma, 2 cases as infarction, 3 cases as atypical, and 25 had an incorrect grading. In cytology preparations, both cytopathologists and neuropathologists diagnosed astrocytomas, except one case due to hypocellular smears. For cytopathologists, incorrect grading of astrocytoma was seen in 33/100 (33%), while for neuropathologists incorrect grading was in 29/100 (29%). If the grading system divided into two-tiered scale (low for grade 1 & 2, or high grade for grade 3 & 4), cytopathologists showed agreement with the final diagnosis in 86%, neuropathologists showed agreement in 97%, and frozen sections showed agreement in 92% of cases.

Conclusions: 1- Squash preparation is a useful technique for grading astrocytomas and showed superior results compared to frozen section. 2- Neuropathologists showed better correlation with the final diagnosis than cytopathologists for squash preparation diagnoses, indicating the need for more training of cytopathologists in interpreting and grading of brain tumors.

336 Cytomorphologic Analysis and Histological Correlation of High-Grade Squamous Intraepithelial Lesions in Postmenopausal Women

RS Saad, A Kanbour-Shakir, E Lu, J Modery, A Kanbour. Magee Womens Hospital at UPMC, Pittsburgh, PA.

Background: Atrophy-related epithelial changes often pose a diagnostic difficulty during the interpretation of postmenopausal smears. In addition, diagnosing high-grade squamous intraepithelial lesions (HSIL) in atrophic smears can be even more challenging. The objectives of this study are to identify the cytomorphologic features of HSIL in atrophic cervicovaginal smears of postmenopausal women, and to investigate the possible criteria, which leads to an inaccurate interpretation and false positive results.

Design: Forty (40) Pap smears that were reported as HSIL in postmenopausal women, were reviewed. Follow up cervical biopsies were available on all cases, and some had immuno-staining for MIB-1 and P16. The following cytomorphologic features were evaluated: granular background, degree of cellularity, cellular arrangement, nuclear size, nuclear membrane irregularity, nuclear/cytoplasmic ratio; hyperchromasia, and chromatin pattern. In addition, cyto-histological correlation of all cases was performed.

Results: Significant histological abnormalities were present in 35 out of these 40 cases. Of those, 22 (55%) cases had High grade intraepithelial neoplasia (CIN-2 or CIN3), 10 (25%) had Cervical Intraepithelial Neoplasia-1, 5 (12.5%) had reactive changes in the biopsy, and 3 cases had invasive squamous cell carcinoma. The cytomorphologic features that favored HSIL ($p < 0.05$) included: presence of increased number of abnormal cells, nuclear membrane irregularities, and abnormal chromatin pattern. Whereas, features that caused inaccurate interpretation include: granular background, cellular arrangement, nuclear size, higher nuclear/cytoplasmic ratio and hyperchromasia, and can be associated with reactive and atrophic changes.

Conclusions: Our study showed that cytomorphological features favoring HSIL in atrophic smears include the presence of increased number of abnormal cells, nuclear membrane irregularities, and abnormal chromatin pattern. Whereas granular background, cellular arrangement, nuclear enlargement, high nuclear/cytoplasmic ratio and hyperchromasia can be seen in reactive changes of atrophy and may lead to inaccurate interpretation.

337 Atypical Squamous Cells-Cannot Exclude High Grade Squamous Intraepithelial Lesion (ASC-H): Diagnostic Reproducibility, HPV Positivity Rates and Clinical Implications

R Saad, A Kanbour, N Mauser, J Modery, DJ Dabbs. Magee-Womens Hospital of UPMC, Pittsburgh, PA.

Background: Bethesda 2001 terminology recommends the category of ASC-H as a subset of ASC, yet there is a dearth of data that documents interobserver reproducibility of the ASC-H diagnosis. Colposcopic examination and possible biopsy is the recommended follow-up for the diagnosis of ASC-H. This exercise documents diagnostic reproducibility, the HPV status and tissue follow-up of this population with diagnoses of ASC-H among three cytopathologists. Clinical implications are discussed.

Design: This retrospective study for the year Sept. 2002-Aug 2003 focused on 100 cases each of ASC-H and ASC-US. Hybrid Capture II results were available for a portion of each diagnostic category. Cytopathologists (two senior and one junior) each received 200 blinded glass slides to review, one half previously diagnosed as ASC-H and the other half as ASC-US. Diagnostic categories were recorded as: inflammatory/reactive, ASC-US, ASC-H, LSIL or HSIL. Descriptive statistics were used to analyze this data. A selective number of cases in each group had follow-up cervical biopsies. Sensitivity and specificity were determined for the Pap diagnosis of ASC-H and the finding of HSIL on biopsy or any SIL on biopsy.

Results: Overall, there was complete agreement among all 3 observers for 18% of the ASC-US diagnoses and 14% of ASC-H diagnoses.

The sensitivity for HSIL or any SIL on biopsy with a diagnosis of ASC-H was in the range of 50-60%. The HPV positivity rate for the ASC-H diagnosis was only 60%. The table illustrates individual observer agreements with the original diagnoses, HPV positivity rates for ASC-H and the sensitivity/specificity for finding HSIL on biopsy with a Pap diagnosis of ASC-H, and sensitivity/specificity for biopsy result of any SIL with a Pap diagnosis of ASC-H.

Table 1

Pathologist	ASC-US agree Original Dx%	ASC-H agree Original Dx%	ASC-H HPV Positive Rate	Sens/Spec Pap ASC-H for biopsy HSIL	Sens/Spec Pap ASC-H for any biopsy SIL
A	42	58	62	60/46	59/63
B	59	31	60	50/69	43/88
C	27	38	62	22/61	58/74

Conclusions: (1) Interobserver reproducibility of the ASC-H diagnosis is poor, and is similar to the agreement rate for the ASC-US diagnosis. (2) The ASC-H category had an HPV positivity rate of only 60%, suggesting that ASC-H is overcalled on these Pap tests. (3) These results suggest that HPV testing may be a viable cost effective alternative to colposcopy for patients with the ASC-H diagnosis, given the propensity to overcall ASC-H on Pap tests.

338 Assessment of DNA Ploidy in Residual Liquid-Based Cervical/Vaginal Specimens using Laser Scanning Cytometry (LSC)

A Salhadar, CN Booth, R Massarani-Wafai, M Laudermit, EM Wojcik. Loyola University Medical Center, Maywood, IL.

Background: Historically, Pap smear cytology is considered the gold standard screening test for cervical lesions. Unfortunately, not all potentially progressive cervical dysplasias are captured by existing methodologies (i.e., conventional light microscopic examination, high-risk HPV testing). The aim of the study was to evaluate usefulness of DNA ploidy profile as an adjunct test in liquid-based Pap tests.

Design: Residual cells from 63 randomly selected cervical / vaginal samples fixed in PreserveCyt with predetermined cytologic diagnoses: NIL -18, ASC-US -10, LSIL -26 and HSIL -9. Each residual sample was stained with propidium iodide (PI; 5mg/ml) and DNA profile was evaluated using the LSC. For each diagnostic category the percentage of events in Region 1 (DNA index [DI] $>0.7 \leq 1.2$), Region 2 (DI $>1.2 \leq 1.7$), Region 3 (DI $>1.7 \leq 2.5$) and Region 4 (DI >2.5) were recorded. The number of measured events ranged from 156 to 2941 (average number of events per diagnostic category is shown in Tab.1)

Results: All cases were diploid; however, the percentage of events in Regions 1-3 increased with the severity of cytologic findings. The results are presented in Table 1.

Conclusions: Although the results show that ploidy profile is not a practically useful diagnostic test in and of itself, however, it can provide additional useful information. In the emerging era of automated screening technologies, DNA ploidy should be included among an array of other discriminating factors.

Pap diagnosis	# of cases	Avg. # of cells	Region 1 (%)	Region 2 (%)	Region 3 (%)	Region 4 (%)
NIL	18	1144.6	73.4	9.9	13.3	1.3
ASCUS	10	1253.2	67.0	15.9	12.9	1.6
LGSIL	26	1253.3	70.0	11.5	13.9	1.6
HGSIL	9	1066.9	59.7	18.8	16.1	2.9

339 Fluorescence In Situ Hybridization Elucidates Equivocal Lung Cytology

S Savic, B Grilli, P Spieler, P Dalquen, G Feichter, M Tamm, L Bubendorf. University Hospital Basel, Basel, Switzerland; Cantonal Hospital, St. Gallen, Switzerland.

Background: The category of equivocal respiratory cytology is a common diagnostic dilemma to both cytopathologist and clinicians. Chromosomal alterations are a hallmark of cancer but rare or absent in benign conditions. The goal of this study was to test the ability of the recently developed multi-target FISH probe LA Vysion™ (Vysis, Inc.; Downers Grove, Illinois, U.S.A.) in dissecting equivocal respiratory cytology into reactive and into malignant categories.

Design: A consecutive series of 100 Papanicolaou (PAP)-stained cytological specimens of the lung was analyzed. The PAP-stained atypical cell groups were photographed, and the exact locations on the specimens were saved by using an automated stage and a relocation software. The specimens were hybridized with the multi-target FISH probe, which contains a mixture of fluorescent probes to the centromeric region of chromosome 6 and to the 5p15, 8q24 (site of the MYC gene) and 7p12 (site of the EGFR gene) loci. The hybridized atypical cells were selectively scored after relocation.

Results: Hybridization was successful in 54 of 100 specimens and highly dependent on the length of the preceding archival period. The success rate ranged from 7% in the 14 specimens older than 3 years to 90% in the 37 recent specimens collected within 12 months prior to hybridization. A final diagnosis based on morphology or clinical course was available in 45 patients, revealing lung carcinoma in 55.5% (n=25), no evidence of malignancy in 37.8% (n=17) and pulmonary metastasis of a other primary carcinoma in 6.7% (n=3). FISH was negative in all 17 patients with benign pulmonary disease and detected 20 (80%) of the 25 patients with lung carcinoma ($p < 0.0001$). The sensitivity, specificity, positive and negative predictive value for detection of lung carcinoma in equivocal cytology was 80%, 100%, 100%, and 77.3% respectively.

Conclusions: These data suggest that multi-target FISH in conjunction with automated relocation is a powerful approach for the elucidation of equivocal lung cytology.

340 Subsequent Detection of Lymphoid Malignancy in Cerebrospinal Fluid (CSF) Previously Diagnosed as Atypical or Suspicious

M Schinstine, A Filie, W Wilson, M Steller-Stevenson, A Abati. National Cancer Institute, NIH, Bethesda, MD.

Background: There may be a considerable amount of morphologic overlap between benign reactive and malignant lymphoid processes within the CSF; hence, the diagnostic categorizations of "atypical" and "suspicious". At this time, the clinico/pathologic follow up of these cases in patients with suspected lymphoproliferative disorders involving the central nervous system (CNS) has not been reviewed systematically. We chose to evaluate the prospective incidence of lymphoid malignancy, and the role of flow cytometry (FC), in CSFs previously diagnosed as atypical or suspicious.

Design: Our computer files were queried for CSF samples in patients with suspected lymphoma involving the CNS that were diagnosed as "atypical" or "suspicious" between 1/2000 and 7/2004. Patients with an initial malignant diagnosis were excluded. Flow cytometry was used as the gold standard in determining CSF involvement by malignancy. Fisher's exact test was used for statistical analysis (two-sided P value).

Results: A total of 40 patients that fit these criteria were identified. The mean age was 40 years and the mean number of separate CSF samples submitted was 13. Of the patients with an atypical or suspicious CSF, 30% (12/40) were later confirmed by cytology to have CNS involvement with malignant lymphoma. FC was positive in 54% (19/35; $P < 0.005$) and 80% (4/5) of CSFs with an initial diagnosis of atypical or suspicious, respectively. When the atypical and suspicious cases were grouped together, FC was positive in 58% (23/40; $P < 0.005$) of cases. A single case was positive by morphology, but negative by FC. In 26% of the cases diagnosed as atypical (9/35), the qualifier "favor reactive" was used. None of these samples (0/9) were later found by cytology to contain malignant cells. FC was able to detect malignancy in 2 of the 9 cases (22%). These 2 cases were gamma-delta T-cell lymphomas that are morphologically bland.

Conclusions: Cases diagnosed as atypical or suspicious will have malignant cells in 30% or 58% (by cytology or flow cytometry, respectively) of ensuing CSF samples. In our lab, a diagnosis of "atypical, favor reactive" will most likely not contain malignant cells in subsequent samples. Finally, FC is very helpful in the diagnosis of lymphoid malignancy in CSF samples.

341 ASC-H: Can We Do Better?

MJ Schmidt, BS Ducatman. West Virginia University School of Medicine, Morgantown, WV.

Background: The diagnosis of atypical squamous cells cannot exclude high grade squamous intraepithelial lesion (ASC-H) introduced in the Bethesda System 2001 is frustrating to pathologists and clinicians alike. This category is often nebulous and consists of patients whose histology ranges from negative to high grade squamous intraepithelial lesion (HSIL). Treatment options are especially problematic when

colposcopy is negative and the choice is between LEEP or cone and follow-up. In order to determine whether we could further refine this diagnosis, we reviewed all cases of ASC-H collected over a 2-year period, which had histologic follow-up.

Design: There were 47 cases diagnosed by 8 pathologists as ASC-H. Five were conventional pap tests and 42 were liquid-based. An experienced cytopathologist reviewed all pap tests for a review diagnosis, blinded as to the original diagnosis and histology results, and also scored each case for the number of abnormal cells, nuclear irregularity, nuclear hyperchromasia, and n/c ratio on an ordinal scale of 1-3+. The results were compared to the surgical pathology category, scored as negative, atypical (squamous metaplasia), low grade squamous intraepithelial lesion (LSIL), and HSIL and analyzed by Chi-Square using JMP ver 5.1.

Results: The patients ranged in age from 18-55 with a mean of 30.7 years. There was no significant correlation between age or type of pap test and histologic diagnosis. Of the 47 patients with a diagnosis of ASC-H, only 9 had negative histology. However on review, only 17 cases remained in the ASC-H category (See table 1). The number of abnormal cells was not statistically associated with the surgical pathology category (p=0.19). However, nuclear irregularity (p<0.02), nuclear hyperchromasia (p<0.03), n/c ratio (p<0.001), and granular chromatin (p<0.001) were all statistically significant predictors of histology. When all the features or just the nuclear scores were combined, there was marked statistical power (p<0.0001, ANOVA).

Surgical pathology category and Cytologic review diagnosis

Review Diagnosis	SP Category				
	ATYPICAL	HSIL	LSIL	NEGATIVE	
ASC-H	3	6	6	2	17
ASC-US	0	0	0	2	2
HSIL	0	14	3	0	17
LSIL	0	0	6	1	7
NEGATIVE	0	0	0	4	4
	3	20	15	9	47

p<0.0001

Conclusions: The most statistically significant cytologic features predictive of HSIL on histology were n/c ratio and chromatin granularity. These were more powerful than nuclear irregularity and hyperchromasia. However, a combination of features was also very useful. With experience and more stringent review, cases of ASC-H can often be further categorized.

342 K-ras and Microsatellite Marker Analysis of Fine Needle Aspirates from Intraductal Papillary Mucinous Neoplasms of the Pancreas

KE Schoedel, KM McGrath, A Khalid, SD Finkelstein, NP Otori. University of Pittsburgh Medical Center, Pittsburgh, PA.

Background: The preoperative diagnosis of pancreatic intraductal papillary mucinous neoplasm (IPMN) using endoscopic ultrasound guided fine needle aspiration (EUSFNA) remains challenging due to sampling and cytologically bland epithelium when present. The application of microsatellite marker analysis for loss of heterozygosity (LOH) to cyst contents holds promise in predicting the degree of pre-neoplastic and neoplastic change in IPMNs.

Design: There were 14 patients who underwent pre-operatively EUSFNA of the pancreas and/or had cyst fluid aspirated intraoperatively followed by pancreatic surgical resection documenting IPMN. Cyst fluid was submitted for mutational gene analysis targeting K-ras and LOH using a preselected panel of microsatellite markers. The cytology and molecular results were compared to the surgical pathology outcome (and correlated with co-existing pancreatic intraepithelial neoplasia (PanIN)).

Results: Of 14 patients, 7 were IPMN adenoma, two of which showed genetic abnormalities. Two of 4 IPMN Borderline cases had mutations and 3 of 3 carcinoma (in-situ and invasive) showed mutations.

Conclusions: Molecular analysis in IPMN cyst fluid samples showed a correlation between increasing frequency of K-ras mutation and LOH and the degree of pre-neoplastic and neoplastic change in IPMN. The presence of co-existing PanIN in IPMN may be a complicating factor in molecular analysis.

Molecular, Cytologic, and Histologic Features in IPMN

Surgical Pathology	Number of Cases	Cytology	K-ras	LOH	Kras+LOH	PanIN
IPMN Adenoma	7	1Atyp/5 Neg	1/7	2/7	1/7	3/7
IPMN Borderline	4	4 Neg	1/4	2/4	1/4	2/4
IPMN CIS	1	NA	N/A	1/1	N/A	N/A
Invasive AdenoCA	2	1Atyp/1 Neg	2/2	2/2	2/2	1/2

Abbreviations: CIS, carcinoma in situ; AdenoCA, adenocarcinoma; NA, not available

343 Transrectal FNA: An Analysis of 121 Cases

JD Sen, HM Cramer. Indiana University School of Medicine, Indianapolis, IN.

Background: Recent advances in endoscopy have made it possible to perform FNA cytology from a variety of sites within the gastrointestinal tract. In this study, we review our experience with transrectal FNA, a procedure which is not commonly performed.

Design: A computerized search of the cytology database at our institution was performed for the 14 year period extending from July 1, 1990 through June 30, 2004 and all transrectal FNA cases were identified. All of the cytology reports and correlating surgical pathology reports of these cases were retrospectively reviewed and microscopic slides from selected cases were re-examined.

Results: During the past 14 years only 121 transrectal FNA cases were performed at our institution. Corresponding surgical pathology was available for 50 of the 121 cases (41%). A definitive cytologic diagnosis of carcinoma was established in 36 of the 121 cases (28%). These included adenocarcinoma (31 cases), transitional cell carcinoma (2 cases), squamous cell carcinoma (1 case) and metastatic carcinoma (2 cases). Confirmatory surgical pathology follow-up was obtained for 17 of these 36 carcinoma cases (47%). There were 9 mesenchymal neoplasms (7%) diagnosed by transrectal FNA including gastrointestinal stromal tumor [GIST] (4 cases) and leiomyosarcoma [LMS]

(5 cases). Histologic confirmation was obtained in only one of these cases (11%). In addition, there were 4 FNA cases (3%) diagnosed as melanoma and tissue confirmation was obtained in 3 of these cases (75%). There were 72 FNA cases (60%) that were diagnosed as benign, reactive, cystic or inflammatory lesions with 29 (40%) of these having tissue confirmation. The tissue diagnosis matched the cytologic diagnosis in 28 of the 29 cases (97%). One case reported as an epidermal inclusion cyst by FNA proved to be a teratoma on histology.

Conclusions: It appears that transrectal FNA is suitable for the diagnosis of primary and recurrent rectal adenocarcinomas and for the diagnosis of rectal GIST and LMS. Submucosal neoplasms may not be accessible by routine mucosal biopsies and, in this setting, transrectal FNA may be the only method of obtaining a cellular sample for definitive pathologic diagnosis. Increased utilization of transrectal FNA should be considered.

344 Significance of Positive High-Risk HPV DNA Tests in Patients with Cytologic Diagnosis of Atypical Squamous Cells of Undetermined Significance (ASC-US)

S Shen, M Myint, J Bonadio, L de la Maza, M Gu. University of California Irvine Medical Center, Orange, CA.

Background: Repeat cervical cytology has been widely used to manage patients with a diagnosis of ASC-US, but the sensitivity of this approach for detecting high-grade lesions is low. An alternate clinical pathway, which involves "reflex" HPV testing once ASC-US is diagnosed, may help streamline patient care. However, more needs to be learned about patients with ASC-US who test positive for high-risk HPV. To our knowledge, no study has attempted to correlate the results of reflex HPV testing with morphologic findings. A retrospective study was therefore designed to correlate ASC-US cases that tested positive for high-risk HPV with cytologic features and biopsy findings.

Design: All liquid-based cervical/vaginal preparations (SurePath, TriPath) with a diagnosis of ASC-US and a reflex HPV test (Hybrid Capture 2, Digene) at UCIMC between March 2003 and February 2004 were selected. Cytology slides were retrospectively reviewed and re-classified (The Bethesda System 2001). Available follow up cytology and histology slides were also retrieved and reviewed.

Results: Ninety-seven patients were identified. Patient age at diagnosis ranged from 15 to 66 years (average 31.6 years). Fifty-seven samples (57/97) were positive for high-risk HPV. Cytology specimens were re-classified as follows: 32 cases, reactive; 1 case, ASC-H; and 64 cases, ASC-US. Eleven reactive cases (11/32) tested positive for HPV, and 10 of these cases had follow up biopsies that were all negative. One ASC-H case tested positive for HPV DNA, and the biopsy revealed CIN 3. Forty-five ASC-US cases (45/64) tested positive for HPV DNA and 27 of these cases had follow up biopsies, showing no pathologic change in 15 (15/27), CIN1/HPV in 9 (9/27), and CIN2-3 in 3 (3/27). The follow up period ranged from same day to 11.6 months (average 4.5 months). Finally, the cytologic features in our 64 cases of ASC-US were similar regardless of the status of reflex HPV testing.

Conclusions: Although the study population is small, the results suggest that reflex HPV testing will detect subclinical infection with high-risk HPV types in a significant percentage (approximately one-third) of patients with equivocal or abnormal cytology. On the other hand, the relatively small number of high-grade lesions seen in follow up biopsies suggest that the clinical significance and proper management of subclinical infection detected by molecular methods remains uncertain and requires long-term study.

345 Is HER-2/neu (H2N) Status Determined by Immunohistochemistry (IHC) in Cell Block Preparations Accurate and Reliable? A Concordance Study of IHC and Fluorescence In-Situ Hybridization (FISH)

SJ Shin, B Chen, M Vazquez. Weill Medical College of Cornell University, New York, NY; Memorial Sloan Kettering Cancer Center, New York, NY.

Background: Accurate determination of HER-2/neu status in patients with breast cancer has important therapeutic and prognostic implications. There are clinical scenarios such as newly diagnosed distant metastatic disease when cell block material is the only readily available tumor sample for study. We set out to determine whether assessment of H2N status using routine IHC scoring methodology used in surgical samples is reliable in smaller samples typically seen in cell block material by comparing results with HER-2/neu status obtained by FISH analysis.

Design: H2N status was determined in 25 cases of primary or metastatic carcinoma by IHC and FISH. All cases were in the form of formalin-fixed, paraffin embedded cell block preparations. Specimen adequacy for carcinoma cells was confirmed in each case. Sites of disease included liver (5), breast (4), soft tissue (5), lung (3), peritoneum (2), pleural fluid (2), bone (2), and lymph node (2). In all cases, a diagnosis of primary or metastatic breast carcinoma was made or highly favored. Immunohistochemistry for H2N was performed on 4 um thick sections using appropriate positive and negative controls (monoclonal antibody TAB250, Zymed). H2N protein overexpression was defined as 3+ staining (on a scale of 1 to 3+) in >10% of tumor cells. H2N gene amplification was identified by FISH technique with the HER-2 DNA probe kit (Vysis, Inc., Downers Grove, IL). H2N gene amplification was defined as HER-2:CEP 17 signal ratio of 2.0 or greater. Results of IHC and FISH were compared in each case.

Results: 18 of 25 cases studied showed no protein overexpression by IHC (0 or 1+ staining) and no amplification by FISH. 5 cases showed protein overexpression by IHC (3+ staining in >50% of carcinoma cells) and amplification by FISH. The remaining 2 cases showed 2+ staining intensity by IHC in 25% and 50% of carcinoma cells, respectively and both demonstrated lack of amplification by FISH. No cases showed protein overexpression by IHC without FISH amplification or FISH amplification without protein overexpression by IHC.

Conclusions: IHC is a reliable method to use on cell block material for determining H2N status.

346 Altered Recognition of Reparative Changes in ThinPrep® Specimens in the College of American Pathologists Gynecologic Cytology Program

TM Snyder, AA Renshaw, PE Styer, DR Mody, TJ Colgan. College of American Pathologist (CAP); The Methodist Hospital, Houston, TX; Baptist Hospital of Miami, Miami, FL; CAP; Mount Sinai, Toronto, ON, Canada.

Background: Studies have shown that repair and atypical repair are associated with an increased risk of squamous intraepithelial lesions as well as other clinically significant lesions. In the College of American Pathologists (CAP) Interlaboratory Comparison Program in Gynecologic Cytology (PAP), the diagnosis of repair in conventional smears is consistently associated with the highest false positive rate (lowest specificity) of any negative category in the program. It was suspected that in contrast to reparative changes in conventional smears, responses to ThinPrep® (TP) slides with reparative changes were associated with a relatively low false positive rate (high specificity).

Design: We compiled performance data from the CAP-PAP from the 2000 through 2003 program years. Over 400 slides with a reference diagnosis of reparative changes met our study criteria, representing a total of 11,200 individual responses for conventional cases and 1,155 individual responses for TP specimens. We evaluated results of both individual and laboratory participants using two performance criteria: the false positive discordancy rate and the exact match error rate.

Results: Cases with a reference diagnosis of reparative changes comprised 1.2% of all TP slides and 3.7% of all conventional slides in circulation. The false positive discordancy rate of individual responses for conventional smears was significantly higher than the corresponding false positive discordancy rate for TP specimens (11.4% for conventional versus 7.1% for TP specimens, $P=.05$). Laboratory responses on conventional smears and TP slides showed a similar trend, 9.8% for conventional smears versus 2.4% for TP slides ($P=.02$). The exact match error rate on conventional slides was 37.1% for individual responses, while on TP slides the overall error rate was 56.4% ($P<.001$). For laboratory responses, the exact match error rate was 34.3% for conventional smears, versus 58.9% for TP smears ($P<.001$).

Conclusions: These combined findings suggest that reparative changes on TP slides in the CAP-PAP are only a proportion of all possible reparative changes, consisting of the less atypical cases, and that a diagnosis of reparative changes in TP may not share the same clinical significance as one on conventional smears.

347 Atypical Squamous Cells, Cannot Exclude High-Grade Squamous Intraepithelial Lesion (ASC-H): HPV Testing and Histologic Results

M Srodon, HP Dilworth, BM Ronnett. The Johns Hopkins Medical Institutions, Baltimore, MD.

Background: Current guidelines recommend colposcopy rather than high-risk human papillomavirus (HPV) testing for evaluation of abnormal cervical cytology interpreted as ASC-H based on data from the Atypical squamous cells of undetermined significance/Low-grade squamous intraepithelial lesion (ASCUS/LSIL) Triage Study (ALTS) indicating ASC-H has a significantly higher frequency of high-risk HPV positivity and underlying high-grade squamous intraepithelial lesions (HSIL) compared with ASC-US. The cytologic interpretations in ALTS were expert consensus diagnoses rather than routine single-pathologist readings.

Design: We report a comparative analysis of Hybrid Capture 2 high-risk HPV positivity and frequency of histologically diagnosed HSIL for ASC-H and ASC-US to assess the utility of HPV testing for colposcopy triage of ASC-H in routine practice.

Results: 64 of 96 (67%) ASC-H cases were HPV-positive compared with 484 of 1079 (45%) ASC-US cases. Of 43 HPV-positive ASC-H cases with follow-up 18 (41.8%) had HSIL. Of 21 HPV-negative ASC-H cases with follow-up 1 (4.8%) had HSIL. Of 227 HPV-positive ASC-US cases with follow-up 24 (10.6%) had HSIL. Of 79 HPV-negative ASC-US cases with follow-up 5 (6.3%) had HSIL. The frequency of HPV-positivity of ASC-H (67%) was intermediate between that obtained in ALTS (86%) and that of ASC-US in both this study (45%) and ALTS (51%). Underlying HSIL was detected in a similar percentage of HPV-positive ASC-H cases as in ALTS (41-42%). The differences in frequencies of detection of HSIL among HPV-positive ASC-H cases (41.8%) versus HPV-positive ASC-US cases (10.6%) and among HPV-positive ASC-H cases (41.8%) versus HPV-negative ASC-H cases (4.8%) were statistically significant ($p<0.0001$, $p=0.0028$). The risk of HSIL was similarly low for both HPV-negative ASC-H and HPV-negative ASC-US cases (4-6%).

Conclusions: The intermediate frequency of HPV positivity for these routinely diagnosed ASC-H cases, significant risk of HSIL in HPV-positive ASC-H cases, and similarly low risk of HSIL in HPV-negative ASC-H and HPV-negative ASC-US cases indicate that HPV testing for triage of ASC-H in routine practice has the potential to reduce the number of women with ASC-H referred for colposcopy without increased risk of failure to detect HSIL among HPV-negative women, similar to its triage role for ASC-US cases. The HPV-negative cases with biopsy confirmed HSIL warrant investigation to determine whether the discrepancy is due to technical failure or the presence of an HPV type not covered by the assay.

348 Coccobacilli and Cervical Dysplasia: Is There a Link?

S Steinman, R Samuel.

Background and Objectives: Whether or not bacterial vaginosis is increased in women with dyskeratotic cervical smears is a topic of considerable debate. This study further examines this issue by analyzing the presence of bacterial vaginosis in women grouped according to varying degrees of cervical dysplasia.

Design: A retrospective pilot study was performed by microscopically examining 500 PAP cervical cytology slides from Strong Memorial Hospital for the presence of coccobacilli. These slides consisted of the following: 100 negative (no ASCUS or dysplasia) cases, 100 ASCUS high-risk HPV positive cases, 100 high-risk HPV negative cases, 100 LSIL cases and 100 HSIL cases. Two examiners confirmed the presence of coccobacilli; any equivocal cases were regarded as negative. All cases

were selected from the time period between June 2003–December 2003. The patients' ages ranged from 14 to 80 years old with a median age of 29 years old.

Results: The presence of coccobacilli in each of the categories is as follows: atypia/dysplasia free = 9%, ASCUS-HPV negative = 29%, ASCUS-HPV positive = 36%, LSIL = 29%, HSIL = 48%. The chi square value for the distribution of data was statistically significant with a p value of $<.001$. A p value of $<.001$ was also observed when comparing the data from the atypia/dysplasia-free group and the data from every other individual category. The other groups which differed statistically with a p value of $<.005$ were the ASCUS-HPV negative and LSIL groups.

Conclusions: This study shows a statistically significant range of data concerning the incidence of bacterial vaginosis among women grouped according to varying degrees of cervical dysplasia. Bacterial vaginosis may be important as a factor in the development of cervical dysplasia and may act synergistically with other agents in the development of cervical neoplasia.

349 Initial Bronchoalveolar Lavage Cell Counts Correlate with Chest Radiograph Stage in Sarcoidosis

CH Stone, L Stagner, M Maliarik, MC Iannuzzi. Henry Ford Hospital, Detroit, MI; Mount Sinai Medical Center, New York, NY.

Background: The diagnosis of pulmonary sarcoidosis is supported by bronchial biopsy; disease burden is based on clinical and chest radiographic findings. The purpose of our study is to determine if initial total and differential (%) bronchoalveolar lavage (BAL) cell counts correlate with either (1) chest radiographic stage at presentation, or (2) chest radiograph stage following therapeutic intervention, in patients with sarcoidosis.

Design: We prospectively studied 87 previously untreated patients with sarcoidosis, defined by characteristic clinical, radiographic, and bronchial biopsy findings. All patients had initial pulmonary function tests, and initial and follow-up chest radiographs. BAL was performed at the time of initial bronchial biopsy. BAL cell count was performed on 1 mL aliquot and then multiplied by BAL volume; differential cell count, based on 300-cell count, was performed on air-dried, Giemsa stained, cytospin slides. BAL cell counts were compared with chest radiograph stage at presentation and at follow-up, using nonparametric Spearman rank coefficient correlation.

Results: Initial macrophage, lymphocyte, and neutrophil cell count correlated with chest radiograph stage at presentation ($p=0.0216$; $p=0.0354$, $p=0.0079$ respectively). Macrophage% and lymphocyte% did not correlate with chest radiograph stage at presentation ($p=0.998$; $p=0.5657$, respectively). Neutrophil% approached statistical significance in relation to chest radiograph stage at presentation ($p=0.0697$). Higher initial macrophage% correlated with higher chest radiograph stage at follow-up ($p=0.0372$) whereas higher initial lymphocyte% inversely correlated with lower chest radiograph stage at follow-up ($p=0.0185$). 29 patients (33%) had stage 0 chest radiographs at follow-up; of this subset, 25 of 29 (86%) had less than 5% neutrophils and/or less than 10,000 neutrophils/mL in the initial BAL. 23 patients (26%) had 5% or more neutrophils and/or $\geq 10,000$ neutrophils/mL in the initial BAL. Of these 23 patients, 19 (83%) had no resolution of chest radiograph stage and the vast majority had either worse or unchanged chest radiograph stage.

Conclusions: Certain components of the BAL cell count (macrophage, lymphocyte, neutrophil) reflect chest radiograph stage at presentation in sarcoidosis, may be predictive of follow-up chest radiograph stage, and may allow for further stratification of patients in the development of further therapeutic interventions.

350 An Immunohistochemical and Reticulin Study of Liver Fine Needle Aspiration

Y Sun, A Macias, C Sugrue, A Tarectecan, P Wasserman. Long Island Jewish Medical Center, New Hyde Park, NY.

Background: Two common challenges in interpreting liver fine needle aspirations (FNA) are (1) the distinction between hepatocellular carcinoma (HCC) and metastatic carcinoma (MC), and (2) distinguishing well differentiated (WD) HCC from benign hepatocellular lesions. The objective of this study was to use immunohistochemistry and reticulin stains to facilitate the interpretation of liver FNA.

Design: We randomly selected cell blocks of 42 liver FNA cases, 22 HCC (14 WD, 4 moderately and 4 poorly differentiated), 17 MC (1 breast, 2 colon, 3 pancreas, 1 biliary tract, 4 other adenocarcinomas, 6 other malignancies) and 3 normal/reactive liver tissues from the years 2001-2004. The pattern and intensity of reticulin stains and immunostain against CD 34, Heppar 1, CK19, and CA19.9 were evaluated. 11/42 cases were also compared with their corresponding hepatic core biopsies.

Results: With reticulin stains, all 22 HCC cases showed an abnormal architectural pattern or decreased/absent staining, whereas 3/3 normal/reactive liver cases, and 9/9 normal/reactive liver tissues present in the MC cases, had a normal, trabecular reticulin framework. CD34 immunostaining in benign liver tissue was confined to vessels in the portal tract; in HCC cases, it reacted intensely with sinusoidal endothelium, demonstrating diffuse and continuous stain around the broad trabeculae. Heppar 1 reacted with 16 HCC cases (73%) and with all 12 normal/reactive liver tissue, showing focally or diffusely intense cytoplasmic staining. Only 1/17 MC cases (a biliary tract adenocarcinoma) showed staining of tumor cells for Heppar 1. CK 19 was not expressed in WD HCC and normal/reactive liver tissue, although it reacted with 3 poorly differentiated HCC; CK 19 was expressed in 14/17 MC (78%). All metastatic adenocarcinomas from colon, pancreas and breast, as well as benign bile ducts, stained intensely for CK19. CA19.9 was focally and moderately positive in 3 WD HCC and in 5/17 MC (29%).

Conclusions: The combination of reticulin stain and CD 34 immunostain enhances diagnostic accuracy, particularly for WD HCC. Heppar 1 positivity is specific for tissue of hepatic origin, although it does not differentiate benign from malignant liver processes. CK 19 positivity favors a diagnosis of MC over HCC, and it may distinguish cholangiocarcinoma from HCC.

351 ASC-H: Correlation with Reflex HC2 HPV DNA Test and Biopsy Findings

S Taraifi, MT Siddiqui, AM West, W Griffith, W Kabbani, C Werner, R Ashfaq. University of Texas Southwestern Medical Center, Dallas, TX.

Background: Atypical Squamous Cells cannot exclude a high grade squamous intraepithelial lesion (ASC-H) is a new diagnostic category in the 2001 Bethesda System. The American Society for Colposcopy and Cervical Pathology (ASCCP) in the Consensus Guidelines Management of Women with Cytological Abnormalities recommends referral of women with ASC-H for colposcopic evaluation. In this study we evaluate the utility of reflex HPV DNA testing for ASC-H.

Design: ThinPrep® Pap Test (TPPT) interpreted as ASC-H, constituted the cases for the study (257 cases) over a 24-month period. The diagnosis of ASC-H was made according to the 2001 Bethesda System (TBS) for reporting cervical cytology. Reflex HC2 HPV DNA testing was performed on residual samples. Prospective data was collected for the cohort of all ASC-H Paps for HPV DNA status and correlated with subsequent surgical biopsy results. The data was analyzed to evaluate the utility of HPV testing for the detection of histologic HSIL (CIN 2 or worse) in terms of sensitivity, specificity, positive predictive value (PPV), and negative predictive value (NPV).

Results: During the two year period, 257 (0.24%) of 107021 Pap Tests were interpreted as ASC-H. A reflex HPV DNA test in 151 (58.75%) cases was positive and 83 (32.30%) cases was negative for high risk HPV. 148 cases had a tissue biopsy within 12 months of the Pap Test. Of these, 41 (27.7%) were benign, 6 (4.05%) were atypical, 59 (39.86%) were CIN I, 41 (27.7%) were CIN II-III and one case (0.01%) squamous cell carcinoma. Of the 87 ASC-H and HPV positive cases, 17 (19.54%) were negative or benign on biopsy, one (1.14%) atypical, 36 (41.37%) CIN I, 32 (36.78%) were CIN II-III, and one case (1.14%) squamous cell carcinoma. The sensitivity was 70.70% with a PPV of 80.46%, while the specificity was 51.43% with a negative predictive value of 38.30%.

Conclusions: 1. ASC-H diagnostic category leads to a better detection of cervical intraepithelial neoplasia (67.57% had CIN I or higher on a subsequent biopsy in this study).

2. Reflex HPV DNA testing on ASC-H cases has high Positive Predictive Value (80.61%), but low Negative Predictive Value (38.34%).

3. Therefore, the relevance of recommendations of ASCCP to refer all cases of ASC-H to immediate colposcopy is confirmed by our data.

352 Benign Endometrial Cells in Papanicolaou Tests of Women over 40 Have a Low Predictive Value for Endometrial Malignancy

M Thrall, K Savik, K Kjeldahl, HE Gulbahce, SE Pambuccian. University of Minnesota, Minneapolis, MN.

Background: The 2001 Bethesda System recommends that cytologically benign endometrial cells in women aged over 40 years (CBEC>40) be reported. Older studies showed a significant relationship between CBEC>40 and endometrial hyperplasia and malignancy, whereas recent studies have arrived at conflicting results. We have evaluated our recent experience with biopsy outcomes of women >40 with and without CBEC in a population screened with Surepath liquid-based Pap tests (LBPT).

Design: We retrieved the surgical pathology reports that included endometrial sampling obtained 0.5-6 months after a Pap test (PT) from 12/01/02-11/30/03 in women over 40. We grouped the results into benign (including polyps), endometrial hyperplasia without atypia (EMH), atypical hyperplasia (AEMH) and adenocarcinoma (EMAC), and compared the results of women with or without CBEC or with atypical glandular cells (AGC) on PT. We used information provided in surgical pathology and PT reports to determine menopausal status and the reasons for performing the endometrial sampling.

Results: During this one year period we processed 27608 PT (93% LBPT, 7% conventional) from women over 40 (44% of all PT). Most (91%) were screening PT, while 9% were diagnostic. Histologic follow-up was available in 755/27608 (2.7%) cases overall, including 159 women (18.4%) with CBEC, and 563 women (2.1%) without CBEC.

Follow-up Diagnosis	No CBEC or AGC	CBEC Present	AGC Present
Benign	523 (92.9%)	150 (94.3%)	30 (90.9%)
EMH	30 (5.3%)	7 (4.4%)	0 (0%)
AEMH	4 (0.7%)	2 (1.3%)	0 (0%)
EMAC	6 (1.1%)	0 (0%)	3 (9.1%)

No statistically significant differences in the rates of detection of EMH, AEMH, or EMAC were found between women with or without CBEC, even after limiting the analysis to women over 50 or menopausal women. Women with AGC had significantly more EMAC than both of these groups. In 43 women, biopsy was performed solely on the basis of the presence of BEC on PT, with only 2 EMH (4.7%) found.

Conclusions: The very low yield of biopsies performed specifically for CBEC>40, and the lack of follow-up result differences between women >40 with and without CBEC, brings into question the clinical utility of reporting CBEC>40. We speculate that our results differ from those of older studies because of the introduction of LBPT with better morphology, the reporting category of AGC, and higher rates of shedding of endometrial cells due to increased exogenous hormone administration.

353 Cytological Diagnosis of Burkitt Lymphoma

ML Troxell, CD Bangs, AM Cherry, Y Natkunam, CS Kong. Stanford University Medical Center, Stanford, CA.

Background: Diagnosis and classification of Burkitt lymphoma requires correlation of morphologic, immunophenotypic, and cytogenetic studies. Since molecular and immunophenotypic techniques can now be applied to small tissue samples, fine needle aspiration biopsy (FNA) represents a minimally invasive method for obtaining material for ancillary studies.

Design: We report a series of seven FNA cases which were clinically or morphologically suspicious for Burkitt lymphoma. Flow cytometry, immunohistochemistry, and fluorescence in-situ hybridization (FISH) studies for CMYC rearrangement were available for correlation in all cases.

Results: Six of seven cases were positive for CMYC rearrangement by FISH. Five cases had the characteristic CD20 positive, CD10 positive, Ki-67 >90%, light chain monotypic immunophenotype. However, only four of these cases met diagnostic criteria for a diagnosis of Burkitt or atypical Burkitt lymphoma. The other cases represented diffuse large B-cell lymphoma, monomorphic post-transplant B-cell lymphoma (favor diffuse large B-cell lymphoma), and aggressive B-cell lymphoma, with the latter case negative for CMYC rearrangement by FISH.

Case	CMYC FISH	CD19/20	CD10	bcl-2	Light Chain	Ki-67	Final Diagnosis
1	pos	pos	pos	pos	kappa	variable	Large B-cell
2	pos	pos	pos	neg	none	>95%	Atypical Burkitt
3	pos	pos	pos	neg	lambda	>95%	Monomorphic PTLD
4	pos	pos	pos	neg	lambda	100%	Burkitt
5	pos	pos	pos	neg	kappa	100%	Burkitt
6	pos	pos	pos	equiv	lambda	100%	Burkitt
7	neg	pos	N/A	equiv	N/A	>90%	Aggressive B-cell

Conclusions: These cases illustrate the value of fine needle aspiration biopsy in the diagnosis of Burkitt lymphoma, as well as the importance of obtaining material for, and integrating results of, morphologic, immunophenotypic and cytogenetic studies.

354 Clinical Application of a Panel of Immunocytochemical Markers in the Cytological Diagnosis of Thyroid Follicular Lesions

M Volante, E Saggiatoro, R De Pompa, AP Dei Tos, F Orlandi, M Papotti. University of Torino, Torino, Italy; Regional Hospital, Treviso, Italy.

Background: The distinction of benign from malignant follicular thyroid neoplasms remains a difficult task in diagnostic FNA cytology, although several immunocytochemical (ICC) markers have been proposed. Several discrepancies (ie in oncocytic tumors) and possible technical or interpretation pitfalls have been reported for each individual marker, suggesting that the use of an ICC panel could improve the diagnostic accuracy in the preoperative evaluation of follicular neoplasms of the thyroid.

Design: A series of 125 consecutive FNA cytological cases reported as "follicular neoplasm" (and having the corresponding surgical specimen available for review) was retrospectively selected. Classical and oncocytic variants of follicular adenoma (50 cases), follicular carcinoma (33) and follicular variant of papillary carcinoma (42) were included. On both FNA cell blocks and the surgical samples, galectin-3, HBME-1 and cytokeratin 19 were tested by immunohistochemistry, together with thyroperoxidase (TPO) and the novel marker of papillary carcinoma keratan-sulfate (KS). Sensitivity, specificity, diagnostic accuracy and positive/negative predictive values were determined for each marker and for their sequential or simultaneous combinations.

Results: Individually, galectin-3 and HBME-1 confirmed to be the most sensitive (92% and 80%, respectively) and specific (94% and 96%, respectively). The use of these markers sequentially in non-oncocytic lesions (testing HBME-1 as a second marker whenever galectin-3 proved negative) increased the sensitivity and specificity up to 97% and 95%, respectively. In oncocytic lesions, the sequential combination of galectin-3 and cytokeratin 19 reached 100% of both specificity and sensitivity, being HBME-1 less accurate for oncocytic cell tumors. Although their rather high individual sensitivity and specificity, the inclusion of TPO and KS in the ICC panel did not increase the accuracy of the tests.

Conclusions: The use of a two-marker-only panel of ICC markers, tested sequentially, better distinguish malignant from benign thyroid follicular neoplasms, especially in otherwise controversial categories such as oncocytic tumors. The combination of three or more markers does not significantly improve the sensitivity and specificity, and just increases the costs of the test.

355 A 10-Year Review of Pancreatic and Bile Duct Brushings: Findings in over 1,000 Cases

KE Volmar, RT Vollmer, MJ Roubort, AJ Creager. UNC-Chapel Hill, Chapel Hill, NC; Duke University, Durham, NC; M.D. Anderson Cancer Center, Houston, TX.

Background: Duct brushing cytology is an important tool in evaluation of the extrahepatic biliary tract and large pancreatic ducts. Liquid based preparation methods have become commonplace. Distinguishing reactive changes from malignancy remains difficult.

Design: We reviewed findings from bile and pancreatic duct brushings at our institution over the 10-year period 1994-2003. Cytologic material, imaging reports, and clinical data were reviewed, and pathologic and clinical follow-up data were obtained. The technological method employed to prepare the slides was also recorded.

Results: A total of 1118 specimens were identified (1008 bile, 110 pancreatic) from 864 patients. The cytologic findings were as follows: 53.5% Negative, 16.5% Malignant, 18.2% Suspicious, 11% Atypical, 0.8% Inadequate. Follow-up data in the form of either histology or greater than 6 months clinical observation were available for 78% of cases (n=870). The slides were prepared by ThinPrep (82.2%) and Cytospin (17.8%). Operating characteristics (OC) are indicated in the table below. Cases with suspicious or atypical cytology were not included in calculations.

Overall Operating Characteristics	Sensitivity	Specificity	PPV	NPV	False Pos	False Neg
Efficiency	52.6	99.4	98.9	67.1	0.3	24.1

Diagnostic agreement between cytology and follow-up was the main variable analyzed. Agreement was far greater for benign cases than for malignant ones (chi-square=203, p<0.001). There was a slight increase in agreement with an increase in the number of procedures performed, but this was not significant (p>0.2). Diagnostic agreement decreased slightly with patient age, a trend that was significant after controlling for

the presence of malignancy ($p=0.02$). Non-significant associations were noted for site (bile duct versus pancreatic duct) and the exact location of the lesions within each duct. Agreement was slightly higher for ThinPrep than for Cytospin (79% vs 70%) but this was of borderline significance ($p=0.08$).

Conclusions: In a large data set from a single institution, brushing cytology showed high specificity and modest sensitivity. Diagnostic agreement was considerably better for benign cases. Repeated procedures and method of preparation did not significantly alter diagnostic agreement.

356 Image-Guided Fine Needle Aspiration Biopsy of the Mediastinum: A Study of 318 Cases

X Wang, HM Cramer. Indiana University School of Medicine, Indianapolis, IN.

Background: Image-guided fine needle aspiration (FNA) biopsy is a minimally invasive and simple outpatient procedure. It has become a popular method for evaluating deep-seated lesions in different organ systems. This study was undertaken to retrospectively investigate the accuracy and usefulness of FNA for the diagnosis of mediastinal abnormalities.

Design: A computerized search of our cytology database was performed from July 1990 through June 2004 and all cases of FNA of the mediastinum were identified. All cytology reports and correlating surgical pathology reports were retrospectively reviewed and microscopic slides from selected cases were re-examined.

Results: During the 14 years encompassed by this study, a total of 318 FNA cases of the mediastinum were examined. The FNA diagnoses for these cases were classified as follows: malignant in 204 (64%), suspicious/atypical in 10 (3%), benign in 73 (23%) and unsatisfactory in 31 (10%). Malignant cases included metastatic carcinoma (107), thymoma/thymic carcinoma (28), neuroendocrine tumor (8), germ cell tumor (30), lymphoma/leukemia (18), and other rare tumors (13). There were 20 patients diagnosed as small cell carcinoma by FNA who were directly referred for chemotherapy without ever obtaining a confirmatory surgical biopsy. Histologic correlation was available for 143 (44%) cases. In 111 (28 benign, 83 malignant) cases (78%), the FNA diagnoses were confirmed histologically. For 4 malignant FNA cases, surgical pathology confirmation was not obtained due to surgical pathology sampling error. In addition, there were 5 false negative FNA cases including 3 adenocarcinomas, 1 small cell carcinoma and 1 malignant peripheral nerve sheath tumor. Three FNA classification errors included one case of lymphangiomyomatosis misdiagnosed as teratoma on FNA, a case of small cell carcinoma misdiagnosed as large cell lymphoma and a case of sclerosing large cell lymphoma misdiagnosed as thymoma. Histologic follow-up was available for 5 of the FNAs in the atypical/suspicious group. Malignancy was confirmed in 3 of these cases and in 2 cases surgical pathology findings were also inconclusive.

Conclusions: FNA is a safe and valuable diagnostic sampling method. Almost two-thirds of the mediastinal FNAs were malignant and approximately half of these were metastatic carcinomas. FNA has a significant impact on patient management and should be considered as the biopsy method of first choice for the diagnosis of mediastinal metastases as well as for the diagnosis of primary mediastinal neoplasms.

357 Focusing Urovison on Screening Urine Cytology

JL Wise, SL Wenger, BS Ducatman, JE Coad. West Virginia University, Morgantown, WV.

Background: Urine cytology is relatively insensitive for detecting urothelial neoplasia (UN). DNA fluorescent in situ hybridization (FISH) can detect genetic alterations associated with UN. These genetic changes have been shown to predict recurrence in patients with a prior history of bladder cancer. However, in patients without a history of UN, the prevalence of these FISH-detected abnormalities in urine cytology specimens (UC) is not well documented.

Design: Sequential UC with adequate cellularity ($n=113$; 86 voided and 27 washing specimens) were identified prospectively from patients (67F:46M; mean age 54 ± 17 yrs) who were evaluated for calculi ($n=9$), hematuria (58), frequency/dysuria/interstitial cystitis (17), UTI (4), BPH (6), incontinence/neurogenic bladder (4), benign hydronephrosis (1), mass or unknown origin tumor (5) and unknown (9). Mean patient follow up was 4 ± 4 months (range: 0-14months). Cystoscopy, when performed, showed 73 patients without and 8 with suspicious lesions. Thin prep slides were prepared for blinded cytologic evaluation. Blinded FISH analysis was performed on urine sediment (VYSIS-Abbott Laboratories). Chromosomes 3, 7, and 17 were evaluated for additional chromosome numbers. Chromosome 9 was evaluated for deletion of 9p21. FISH results were considered positive when 1) Chromosome 3, 7 and/or 17 showed additional copies of ≥ 2 of these chromosomes in ≥ 4 cells and/or 2) both Chromosome 9 showed deletion of p16 in ≥ 12 cells. The negative cases were provisionally sub-classified as indeterminate when ≥ 4 cells had at least one extra copy of Chromosome 3, 7, and/or 17 or ≥ 6 cells were missing either or both p16.

Results:

Correlation of FISH with Cytology, Cystoscopy and Biopsy:

	Cytology ($p<0.0001$)			Cystoscopy ($p=0.683$)		Biopsy($p=0.086$)	
FISH	Negative	Atypical	Susp/Pos	Normal	Abnormal	Malignant	Benign
Pos	4/75(5%)	4/29(14%)	4/9(44%)	6/73(8%)	1/8(13%)	2/6(33%)	1/17(6%)
Neg	71/75(95%)	25/29(86%)	5/9(56%)	67/73(92%)	7/8(87%)	4/6(67%)	16/17(94%)
Indeter	16/75(21%)	7/29(24%)	1/9(11%)	13/73(18%)	3/8(38%)	1/6(17%)	6/17(35%)

FISH results did not correlate with smoking history ($p=0.853$) or cytology indication ($p=0.467$).

Conclusions: Genetic changes associated with UN were detected in 5 and 14% of the negative and atypical UC, respectively. Parallel FISH evaluation of UC has the potential to provide important additional diagnostic information. Further study is necessary to ascertain the long-term significance of these genetic alterations in the setting of negative or atypical urine cytology.

358 Rapid Assessment of Fine Needle Aspiration and the Final Diagnosis-How Often and Why the Diagnoses Are Changed

C Woon, RH Bardales, MW Stanley, EB Stelow. University of Minnesota, Minneapolis, MN; Hennepin County Medical Center, Minneapolis, MN; University of Virginia, Charlottesville, VA.

Background: On-site rapid interpretation (RI) of fine needle aspiration (FNA) has been shown to increase the diagnostic yield of FNA and decrease the need for repeat diagnostic procedures. Because the pathologist interprets only a fraction of the sample and has limited resources available at such times, an occasional RI diagnosis will be changed at the time of the final diagnosis. We investigated how often these changes in diagnoses occur and the possible reasons for the changes.

Design: All cytology reports from 1/1/02 to 12/31/03 from a single institution were reviewed. Cases with RI with discrepant final diagnoses were noted. The discrepant diagnoses were categorized depending on how they were changed. Possible sources for changed diagnoses were noted including additional smears and cell block, the use of ancillary techniques such as immunohistochemistry and flow cytometry, the use of consultant pathologists, and changes in the pathologist on service at the time of RI versus final diagnosis.

Results: Between 1/1/02 and 12/31/03 there were 1368 RIs of FNAs. Of these 80 (5.8%) had discrepancies between the RIs and final diagnoses. Specimens originally deemed non-diagnostic (ND) were found to be benign/non-neoplastic (BNonN) (10), benign neoplasm (BN) (3), atypical/suspicious (AS) (4), and malignant (M) (21). Specimens deemed BNonN were found to be a different BNonN (7), BN (2), AS (4), and M (12). Specimens deemed BN were found to be BNonN (2). Specimens deemed AS were found to be BNonN (10). A single case deemed M was found to be BNonN. 4 cases deemed M were found to be different M. 78 cases had additional slides and/or cell block at time of final diagnosis. 16 cases had ancillary studies available at final diagnosis. Consultant pathologists were used in 7 cases. Different pathologists interpreted the RI and final diagnosis in 31 cases.

Conclusions: Although uncommon, discrepancies between RIs and final diagnoses occur 5.8% of the time at our institution. Most commonly, this involves a change of diagnosis from either ND or BNonN to M. Although much of this is likely due to the presence of additional material and information at the time of final diagnosis, the number of cases that had different pathologists involved in the RI and final diagnosis suggests that inter-observer variability may also play some role.

359 High Risk HPV DNA by Hybrid Capture II is a Useful Triage Method for Women with ASC-H on ThinPrep Pap Tests

HH Wu, L Allen, J Kirkpatrick, TM Elsheikh. Ball Memorial Hospital, Muncie, IN; Pathologists Associated Medical Laboratory, Muncie, IN.

Background: Reflex DNA testing for high risk human papilloma virus (HR-HPV) is a recommended primary triage method for women with atypical squamous cells of undetermined significance (ASC-US) on Papanicolaou (Pap) test. Although immediate colposcopic biopsy is recommended for women with atypical squamous cells can not exclude high grade squamous intraepithelial lesion (ASC-H), the data on HPV DNA testing in the literature are limited.

Design: A retrospective study was conducted through a computer search of our anatomic pathology database between July 2002 and June 2004. Reflex DNA testing for HR-HPV was performed by using Hybrid Capture II (HC II) method (Digene, Gaithersburg, MD) on the ThinPrep vials (Cytoc, Marlborough, MA). Eighty-eight women, who were diagnosed with ASC-H, and had the reflex HR-HPV tests, were identified. The clinical risk of each woman was assessed. In 42 of 88 patients, the subsequent colposcopic biopsies were available for review.

Results: In our laboratory, 119,659 Pap tests were performed during the study period and 377 cases (0.3%) were diagnosed as ASC-H. Reflex HR-HPV DNA testing was performed on 88 women with ASC-H. The test showed 59 (67%) were HR-HPV positive and 29 (33%) were HR-HPV negative. Of these 88 women, 39 were clinically high risk with 27 (69%) positive for HR-HPV, and 49 were clinically low risk with 32 (65.4%) positive for HR-HPV. Follow-up colposcopic biopsy results were available in 35 of 59 HR-HPV positive women, which revealed 15 (43%) high grade squamous intraepithelial lesions (HSIL), 12 low grade squamous intraepithelial lesions (LSIL), 3 atypia and 5 negative. In 29 HR-HPV negative women, 7 had follow-up biopsies, which showed no evidence of HSIL or LSIL. Five of these 7 women were clinically low risk. The sensitivity, specificity, positive predictive rate, and negative predictive rate for reflex HR-HPV DNA testing to identify HSIL in women with ASC-H are 100%, 26%, 43%, and 100% respectively.

Conclusions: Approximately two thirds of patients with ASC-H on Pap test were HR-HPV positive. The high sensitivity and negative predictive rate provide strong evidence that, instead of automatic referral to colposcopy, reflex HR-HPV DNA testing is an alternative triage method for women with ASC-H on ThinPrep Pap test. Clinical risk history does not add additional value for the primary triage of patients with ASC-H.

360 Immunohistochemical Detection of XIAP in Body Cavity Effusions and Washes

M Wu, S Yuan, AH Szporn, L Gan, V Shitlans, DE Burstein. Mount Sinai School of Medicine, New York, NY.

Background: Malignant body cavity effusions may be the first manifestation of relapse. We surveyed effusions and washes for expression of X-linked inhibitor of apoptosis (XIAP), the most potent of the IAP family of proteins. IAPs prevent apoptosis by blocking the activation of caspases, thereby preventing caspase-mediated cell degradation. Elevated expression of XIAP could be an underpinning of relapse and/or resistance to apoptotic-inducing cancer therapy. We surveyed XIAP expression in benign and malignant body cavity effusions and washes.

Design: 44 malignant or benign formalin post-fixed paraffin-embedded cell block specimens from 33 pleural, 9 peritoneal, and 2 pericardial effusions or cell samples were evaluated immunohistochemically with monoclonal anti-XIAP (#610763, BD Biosciences, San Jose) 1:250, 4 oC x 72 hrs, and developed using EnVision-Plus (Dako) and diaminobenzidine as chromagen. Particulate cytoplasmic staining was considered positive.

Results: Overall, 25 out of 31 (80%) malignant effusions displayed XIAP positivity. Staining for specific tumors was as follows: Ovarian (8/8 =100%, strong and diffuse); lung (6/6, 100%, from focal weak to diffusely strong); breast (4/8=50%, focal weak to strong diffuse); gastrointestinal (4/4=100%, focal weak to strong diffuse), carcinoma, unknown primary (3/5 =60%), strong, diffuse). Benign effusions (n=13) were XIAP-negative, or showed staining of mesothelial and inflammatory cells in two cases displaying marked inflammation.

Conclusions: XIAP immunostaining, when strong, allows for ready distinction of malignant from benign/reactive cell populations. Strong XIAP staining was most prevalent in ovarian carcinomas, and least prevalent in mammary carcinomas. The degree of XIAP staining of tumor cells may also be a means of identifying the most therapy-resistant cases (i.e. those with strong XIAP expression), and allow additional triaging to XIAP-blocking drugs presently being developed and clinically tested.

361 Microtubule-Associated Protein-2 (MAP-2) Is a Sensitive Marker for Small Cell Carcinoma in Bronchial Brushing and Washing Cytology

SX Yan, JF Silverman, B Ujevich, M Tung, RS Saad, YL Liu. Allegheny General Hospital, Pittsburgh, PA.

Background: Accurate identification of pulmonary small cell carcinoma in bronchial brushing and washing cytology is critical since small cell carcinomas are optimally treated by modalities other than surgery. Previous studies have indicated that Microtubule-associated protein-2 (MAP-2) is a sensitive and specific neuroendocrine marker for pulmonary small cell carcinoma in biopsy and in resected specimens. However, the diagnostic value of MAP-2 in bronchial brushing and washing cytology has not been studied. We examined the expression of MAP-2 by small cell carcinoma in cytology specimens and compared MAP-2 with other neuroendocrine markers.

Design: A total of 30 pulmonary small cell carcinomas diagnosed by bronchial brushing and bronchial washing were retrospectively retrieved from the pathology files. Cytology smears as well as cell blocks were immunohistochemically analyzed for MAP-2, synaptophysin (SYN), chromogranin (CHR), TTF-1 and CDX-2. The immunostains were performed on an automated immunostainer with appropriate positive and negative controls.

Results:

CASES	MAP-2	SYN	CHR	NSE	TTF-1	CDX-2
Small Cell Carcinoma	87% (26/30)	76% (23/30)	30% (9/30)	70% (21/30)	60% (18/30)	0% (0/30)

Conclusions: MAP-2 is more sensitive than synaptophysin, chromogranin and NSE in confirming pulmonary small cell carcinoma in bronchial brushing and washing cytology. We recommend that MAP-2 be added to immunohistochemical panel in challenging cases to confirm the diagnosis of small cell carcinoma in bronchial brushing and washing cytology in challenging cases.

362 Endometrial Brushing: An Alternative Method To Assess Endometrial Pathology. Data from 1394 Cases with 7-Year Follow-Up

GCH Yang, LS Wan, J Mierlar, G DelPriore. New York University Medical Center; Gouverneur Hospital; Montefiore Medical Center.

Background: Over the past 50 years, the incidence of cervical cancer has plummeted due to Pap test, whereas the incidence of endometrial cancer is steadily rising and has now become the most common cancer of the female genital tract. The current endometrial biopsy is Pipelle suction curettage, but women often complain of excruciating pain. In addition, Pipelle cannot sample the cornu. In 1996, FDA approved a brush with retractable sheath (Tao brush®; Cook Ob-Gyn) for endometrial sampling. The brush is made of double braided stainless steel, enabling it to bend at an angle to reach the cornu of the uterus and globally sample the endometrium.

Design: The samples were collected in CytoRich Red®(TriPath), and the diagnosis was based on combined cytology via a 1.7 cm cytospin and histology via compact cell block. Over a period of 7.6 years, 1394 endometrial brushings from 1244 women, age 20 to 90 were obtained. Positive cases had hysterectomy. Atypical cases were treated by progesterone and follow-up by endometrial brushing, D&C or hysterectomy (1 case). Negative cases were followed from 7.6 years to 3 months. Clinical history includes postmenopausal bleeding, menometrorrhagia, follow-up of hyperplasia, on Tamoxifen for breast cancer, atypical endometrial cells found in Pap test.

Results: Endometrium brushing detected 14 adenocarcinomas (age:34-84 yrs), including a 2 cm carcinoma at the cornu, 2 endometrial stromal sarcomas and 1 MMMT. In addition, 13 atypia complex hyperplasia (ACH), 1 atypical papillary lesion among benign endometrium (f/u: peritoneal primary), 22 rare atypical cells, and 1196 benign endometrium, including 149 atrophic, 68 sloughing, 221 proliferative, 119 secretory, 85 tubal metaplasia, 22 endometritis, 34 suggestive of polyp, etc. There were 3 discrepant cases: a carcinoma-in-situ in a 0.7 cm polyp (Brush: Negative), a flat 0.8 cm carcinoma in ACH (Brush:ACH), and a 10 cm leiomyosarcoma (Brush:Negative). No diagnosis was rendered in 146 cases (10.5%) due to inadequate sampling (mainly cervical). Our patients tolerated the procedure well: 84 women had it done twice, 19 had it 3 x, 4 had it 4 x, and 4 had it 5 x (1 patient had it yearly from age 73 to age 77).

Conclusions: Endometrial brushing, combined with improved fixative and cell block preparation, offers women a painless yet accurate alternative to assess their endometrial pathology.

363 Utility of CD138 (Syndecan-1) in Distinguishing Carcinomas from Mesotheliomas

SS Yun, AC Borczuk, CA Powell, GH Yu, D Alexis, A Saqi. Columbia Presbyterian Medical Center, New York, NY; University of Pennsylvania Medical Center, Philadelphia, PA.

Background: CD 138 (Syndecan-1) is a transmembrane heparan sulfate proteoglycan present on the surface of plasma cells and epithelial cells. CD 138 is also expressed in some hematopoietic neoplasms and has recently been observed in carcinomas. We characterized CD138 in cellblock preparations of fluids/effusions, focusing on the distinction between carcinomas and mesotheliomas.

Design: One hundred formalin-fixed, paraffin-embedded cellblock sections of fluids/effusions (48 pleural, 32 ascitic, 16 pelvic, 4 pericardial) consisting of 58 metastatic carcinomas (including ovary, lung, breast, pancreas, colon, esophagus, bladder, prostate, stomach, liver), 24 mesotheliomas, 11 reactive mesothelial cell proliferations, 3 lymphomas, 3 metastatic sarcomas, and 1 metastatic melanoma were stained with a monoclonal antibody against CD 138 (clone MI15; dilution 1:80; DAKO). All neoplasms had biopsy proven diagnoses. CD 138 staining in cellblock sections was scored semi-quantitatively. The percentage of stained cells (PSC) was graded from a scale of 0 to 3+: 0 (none / rare cells staining), 1+ (<5%), 2+ (5 - 50%), and 3+ (>50%), while intensity was scored from 1 to 3+: 1+ (weak), 2+ (moderate), and 3+ (strong). Membranous staining with PSC ≥ 1 was considered positive.

Results: CD 138 staining was observed in 32/58 (55%) of metastatic carcinomas and 2/24 (8%) of mesotheliomas; all reactive mesothelial cells, lymphomas, sarcomas, and melanoma were negative. CD138 staining for carcinomas had the following statistic values: positive predictive value = 94%, specificity = 97%, and sensitivity = 55%.

Conclusions: CD 138 is a highly specific marker in the differential diagnosis of carcinomas versus mesotheliomas. Distinct membranous staining without background staining of inflammatory cells makes CD138 an ideal marker for cellblock preparations of fluids/effusions. It should be an integral component of the epithelial-mesothelial antibody panel.

364 Expression of Cytokeratin 20 and p53 in Urothelial Carcinoma: A Perspective Study on Urine Cytology

S Zheng, T Pasha, TA Farkas. University of Pennsylvania Medical Center, Philadelphia, PA.

Background: Previous studies on formalin-fixed, paraffin-embedded bladder biopsies have shown that expression of CK20 and p53 is increased in urothelial carcinoma. In our study, we evaluated if these immunostains would provide additional value in the cytologic diagnosis of urothelial carcinoma. Urine samples were taken from patients with or without urothelial carcinoma and the sensitivity and specificity of CK20 and p53 immunostains were calculated.

Design: Bladder washing or voided urine samples were collected from 31 patients with urothelial carcinoma. The diagnosis of urothelial carcinoma was confirmed by concurrent bladder biopsies. Twenty-four patients with negative cytology diagnoses and negative concurrent biopsies were used as controls. Immunohistochemical studies were performed on urine cytopsins.

Results: Twenty-five of 31 carcinoma cases (80.6%) were positive for CK20, compared to 3 out of 24 positive in control cases (12.5%) (Sensitivity 80.6%, specificity 87.5%). Similarly, 17 of 31 carcinoma cases (54.8%) were positive for p53, whereas none of the control cases showed positivity (0%) (Sensitivity 54.8%, specificity 100%).

Conclusions: Our data are consistent with previous findings obtained from tissue studies. Additional immunostaining of urine cytology samples with CK20 and p53 increases the sensitivity of urine cytology for detecting and monitoring urothelial carcinoma.

365 WT1, Monoclonal CEA, TTF1, and CA125 Antibodies in the Differential Diagnosis of Lung, Breast and Ovarian Adenocarcinomas in Serous Effusions

W Zhu, CW Michael. University of Michigan Hospitals, Ann Arbor, MI.

Background: The distinction between metastatic adenocarcinomas of lung (LAC), breast (BAC) and ovary (OAC) in serous effusions can be difficult since they all can present as tight cell clusters. This is particularly challenging when the malignant effusion is the patient's initial presentation or when the patient has a history of more than one primary. The aim of this study is to evaluate the usefulness of WT1, monoclonal CEA (mCEA), TTF1, and CA125 antibodies in the differential diagnosis of LAC, BAC and OAC in serous effusions.

Design: 47 cases of serous effusions with their corresponding cell blocks were retrieved from our hospital computer system, including 13 BACs, 13LACs, and 21 OACs. The diagnoses were confirmed by the surgical resection. Alcohol-fixed and paraffin embedded cell block sections from the serous effusions were immunostained for WT1, mCEA, TTF1, and CA125. The extent (5-25%/1+, 26-75%/2+, >75%/3+) and intensity (negative/0, weak/1+, moderate/2+, strong/3+) of staining were recorded semiquantitatively.

Results: OACs are diffusely positive to WT1 in 19/21 (90%), and CA125 in 20/20 (100%), and negative for mCEA (0/20, 0%) and TTF1 (0/21, 0%). BACs are diffusely reactive to CA125 in 6/13 (46%), focally to mCEA in 6/13 (46%) and WT1 in 2/13 (15%); however, they were all non-reactive to TTF1 (0/13, 0%). LACs are focally positive to WT1 in 3/13 (23%), and diffusely positive TTF1 in 9/13 (69%), mCEA in 8/12 (67%), CA125 in 8/13 (62%).

Conclusions: Our results demonstrate that the WT1 staining is specific for OACs, in addition to the high sensitivity of WT1; and TTF1 is very specific for LACs. Monoclonal CEA is a useful marker to rule out OACs. Immunohistochemical studies with WT1, mCEA, and TTF1 antibodies performed on paraffin embedded cell blocks of serous effusions are useful in the differential diagnosis between metastatic adenocarcinomas of lung, breast and ovary.

366 HPV Genotypes in 278 Cervical Samples: Evidence for Three Categories of Squamous Intraepithelial Lesions

RE Zuna, R Allen, W Moore, Y Lu, ST Dunn. University of Oklahoma Health Sciences Center, Oklahoma City, OK.

Background: LSIL is thought to represent a reversible HPV-associated lesion distinct from HSIL and invasive carcinoma. We have reported that HSIL-moderate (HM) has a different HPV profile from HSIL-severe (HS) and invasive carcinoma (IC). This study adds LSIL cases to an expanded case list.

Design: Liquid-based cytologic specimens from consensus SIL and verified IC cases were blindly analyzed for HPV type using a PCR-based reverse line blot genotyping method (Roche Molecular Systems, Alameda, CA) that identifies 27 HPV types: high risk (HR) types (16,18,31,45); intermediate risk (IR) types (33,35,39,51,52,56,58,59,68,82,83,73); and low risk (LR) types (6,11,26,40,42,43,44,53,54,55,66,84) in a single test. Cases were grouped according to the highest risk HPV type identified in each case.

Results: The previously reported patterns of HPV in HSIL and IC persisted.

HPV					
Diagnosis (n)	HR (%)	HPV 16 (%)	IR (%)	LR (%)	Multiple HPV (%)
LSIL (63)	18 (27)	10 (16)	30 (45)	15 (22)	38 (60)
HSIL-M (58)	25 (43)	11 (19)	31 (54)	1 (2)	31 (53)
HSIL-S (64)	50 (78)	41 (64)	13 (20)	0 (0)	30 (47)
INV CA (93)	77 (83)	51 (55)	10 (11)	0 (0)	11 (12)

LSIL had two patterns: 1) IR HPV that overlapped with HM; and 2) LR HPV only. χ^2 showed differences of HPV in LSIL vs. HM ($p=.002$), HM vs. HS ($p<.0001$) but not HS vs. IC ($p=.105$)

Conclusions: These data suggest that HS, HM and LSIL have different patterns of HPV types that may reflect differences in biological potential. Only HS had an HPV profile that was indistinguishable from that of IC.

Dermatopathology

367 Loss of S100 Immunoreactivity in Metastatic Melanoma

DL Aisner, SA Rosenberg, DM Berman. National Cancer Institute, Bethesda, MD.

Background: In the evaluation of poorly differentiated malignant tumors, metastatic melanoma is chief among the differential diagnosis. The melanocytic marker S100 (reported false-negative rate of less than 4%), is frequently used in such cases to rule-out melanoma. However, difficulty arises in excluding melanoma when S100 is negative.

Design: In an ongoing NCI clinical trial for metastatic melanoma, and over a 5 year period, we identified 17 cases in 1553 patients (1.1%) that were negative for S100 immunostain. Where possible, these cases were also evaluated for other melanoma markers, including HMB45, MART-1, KBA62, tyrosinase and NSE. Additional factors evaluated include the site of the primary lesion, histologic appearance and prior immunostaining profiles for other lesions from the same patient.

Results: All 17 cases of S100-negative melanoma were metastatic lesions. Of these 17 cases, 11 had prior pathologic specimens evaluated for S100 staining, and in 9 of these 11 (82%) cases, there was a prior documented S100 positive metastasis. The time interval for loss of S100 immunoreactivity ranged from 3 weeks to 3 years (average 13.5 months). Ten of the 17 S100-negative lesions (59%) lesions were immunoreactive for both HMB45 and MART-1. Of the remaining 7 cases, four were immunoreactive for NSE (4/7), two were not tested and one was negative for all markers. Fifteen of the 17 S100-negative cases had a documented primary melanoma. Of the 2 cases with no documented primary lesion, both were immunoreactive for HMB45/MART1. Interestingly, there was a disproportionate representation of ocular melanoma (4 of 17, 23.5%) while primary ocular melanoma represents approximately 2.0% of all melanomas. There was no association between S100-negative status and histologic appearance or site of metastasis.

Conclusions: Approximately 99% of our documented metastatic melanomas are immunoreactive for S100. In our series, 65% of S100-negative melanoma lesions had a prior specimen that was immunoreactive for S100, suggesting either de-differentiation or clonal selection. Furthermore, immunoreactivity for HMB45/MART1 or a history of prior melanoma plus NSE immunoreactivity identified all S100-negative metastatic melanomas. Because 82% of S100-negative melanomas were previously S100-positive, extensive sampling (or multiple biopsies over time) of undifferentiated tumors may increase the possibility of diagnosing metastatic melanoma.

368 Superficial Malignant Peripheral Nerve Sheath Tumors: A Rare and Challenging Diagnosis

KH Allison, RM Patel, JR Goldblum, BP Rubin. University of Washington Medical Center, Seattle, WA; Cleveland Clinic Foundation, Cleveland, OH.

Background: Malignant peripheral nerve sheath tumors (MPNSTs) are generally regarded as sarcomas that occur in the deep soft tissues. Rarely, primary MPNSTs with a cutaneous or subcutaneous (superficial) origin have been reported. We present the clinicopathologic features of 5 cases of MPNST presenting in superficial locations.

Design: Five cases of primary MPNST with a superficial origin were identified and their clinicopathologic features were reviewed. Immunohistochemical studies (IHC) included S-100 protein, neurofilament, CD34, pan-cytokeratin, EMA, SMA, desmin, HMB45, MelanA, tyrosinase, GFAP and microphthalmia transcription factor (MITF).

Results: Four females and 1 male, 18-74 years of age (median = 27) were included in the study. One patient carried a diagnosis of type I neurofibromatosis. The lesions arose in the hip/thigh region (2 cases), distal thigh/knee, wrist and neck. The tumor sizes ranged from 2.6 to 16 cm (median = 3 cm). Four cases appeared to arise from cutaneous neurofibromas and one case was closely associated with a superficial peripheral nerve. Four cases had classic spindled morphology and one was epithelioid.

Two cases had areas of heterologous differentiation; one with rhabdomyosarcoma and angiosarcoma and one with osteosarcoma and chondrosarcoma. Mitotic figures ranged from 2 to 50 per 10 hpfs (median = 10/10 hpfs). The four cases with spindle cell morphology were at least focally positive for S-100 protein, while the associated benign neural elements had more extensive S-100 protein immunoreactivity. The epithelioid tumor was diffusely and strongly positive for S-100 protein. Melanoma markers, EMA, GFAP, neurofilament, pan-cytokeratin, CD34, SMA and desmin were negative in all cases with the exception of the areas of heterologous differentiation, which stained with antibodies appropriate to their histologic type. All were treated with wide local excision, one received chemotherapy, and one radiation. There were no local recurrences but three patients died of metastatic disease within 2 to 30 months (median = 12 months).

Conclusions: Superficial MPNSTs are rare. Immunohistochemical markers are helpful in excluding other lesions in the differential diagnosis including malignant melanoma, dermatofibrosarcoma protuberans, leiomyosarcoma and metaplastic carcinoma. However, identification of a benign precursor or origin from a nerve may be the most definitive way to properly classify these rare and challenging lesions.

369 Three-Dimensional Modeling of Pigmented Lesions Can Distinguish between Benign and Malignant Melanocytes

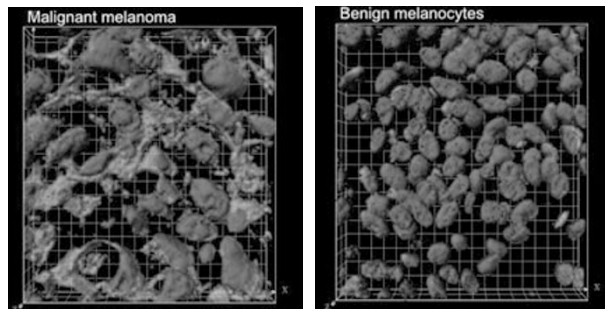
DM Berman, S Wincovitch, S Garfield, MJ Romeo. NCI, Bethesda, MD.

Background: Using the gold-standard of light microscopy, determining the biologic potential of melanocytic lesions may occasionally be difficult and subjective. Despite recent advances, adjunct molecular tests are not yet available to conclusively resolve difficult lesions. We believe that valuable information remains to be discovered using confocal laser scanning microscopy (CLSM) whereby 3-dimensional (3-D) surface renderings of benign and malignant melanocytes can be compared.

Design: Five-micron sections of formalin-fixed, paraffin-embedded benign and malignant melanocytic lesions were deparaffinized, rehydrated and stained with acridine orange (RNA and DNA stain) and DAPI (DNA stain). These lesions were then visualized using a Zeiss LSN 510 confocal laser scanning microscope (0.2-micron intervals). The scanned images were then reconstructed into a 3-dimensional surface rendering using Imaris v4.03 software. Because the intensity of each lesion is normalized to an internal control (nuclear nucleic acid), only the nuclear (DNA + RNA) and cytoplasmic (RNA) surface outlines are used in the analysis.

Results: 3-D surface projections of nuclei and cytoplasm were compared among 8 malignant and 8 benign melanocytic lesions. As expected, malignant nuclei were larger and more irregular than benign nuclei. Notably, in contrast to the more uniform cytoplasmic distribution of RNA in benign cells, the malignant cytoplasmic phenotype is characterized by hierarchical and circumferential branching.

Conclusions: We believe that valuable information on the biologic potential of difficult melanocytic lesions can still be extracted from the standard 5-micron tissue section. While nuclear atypia of melanoma has previously been recognized, we report that melanoma appears to have a more prominent and characteristic cytoplasmic distribution of RNA than do benign melanocytes, perhaps reflecting a higher metabolic rate. We are currently studying whether 3-D surface renderings of atypical (dysplastic) nevi provide diagnostically relevant information.



370 Study of Translocation t(11;18)(q21;q21) (API2/MALT1) and Expression of Bcl-10 in Primary Cutaneous Marginal Zone B-Cell Lymphomas

S Boluda, F Gallardo, C Barranco, A Munne, V Baena, A Ariza, R Pujol, S Serrano. Hospital del Mar-IMAS; Hospital Universitari Germans Trias i Pujol; Autonomous University of Barcelona, Barcelona, Spain.

Background: Primary cutaneous marginal zone B-cell lymphoma (C-MZL), an usually benign low-growth fraction neoplasm, probably is the most frequent form of primary B-cell lymphoma of the skin. API2-MALT1 fusion transcripts due to t(11;18)(q21;q21) and aberrant bcl-10 nuclear expression have been described in some noncutaneous marginal zone lymphoma subtypes, but little is known about cutaneous-MZL genetic alterations. Our aim was to evaluate a possible implication of API2-MALT1 fusion transcripts and bcl-10 expression in primary cutaneous-MZL.

Design: A total of 42 patients diagnosed with cutaneous-MZL on the basis of WHO/EORTC criteria were studied. Skin biopsies from every patient were routinely tested with a wide panel of monoclonal antibodies. Additionally, aberrant nuclear bcl-10 expression was evaluated in all cases and RT-PCR amplification with specific API2-MALT1 fusion transcript primers was performed in 21 instances.

Results: Aberrant nuclear bcl-10 expression, demonstrated in 15 cases, was related to a more aggressive clinical behavior. Translocation t(11;18)(q21;q21) was absent in all evaluated samples.