Cranial surgery dates back to Mesolithic

Alt *et al.* have reported in Scientific Correspondence[1] what they thought to be the first 'unequivocal' evidence for the existence of healed trepanations (cranial surgery) from Ensisheim, Alsace, dated to 5100 BC. However, there is compelling evidence that such *intra vitem* surgery was carried out at an earlier date in eastern Europe, during the preceding Mesolithic period.

Until relatively recently, access to eastern European literature and archaeological material has been limited. Access has now become easier, and the Dnieper Rapids region of the Ukraine, about 400 km south-east of Kiev, yielded the evidence presented here. It comprises one aspect of a multi-disciplinary investigation into the chronology, diet and dental pathology of the human populations living in this area at the transition of the Mesolithic and Neolithic periods[2,3].

During analysis of the crania of about 307 skeletons from cemeteries dating back to each period, two individuals were found to exhibit evidence of trepanation. The cranium of the first individual (Fig.1), a male who was more than 50 years old at death, has a healed lesion on the left side of the frontal bone, about 15 mm anterior to the coronal suture and 30 mm to the left of the sagittal suture.

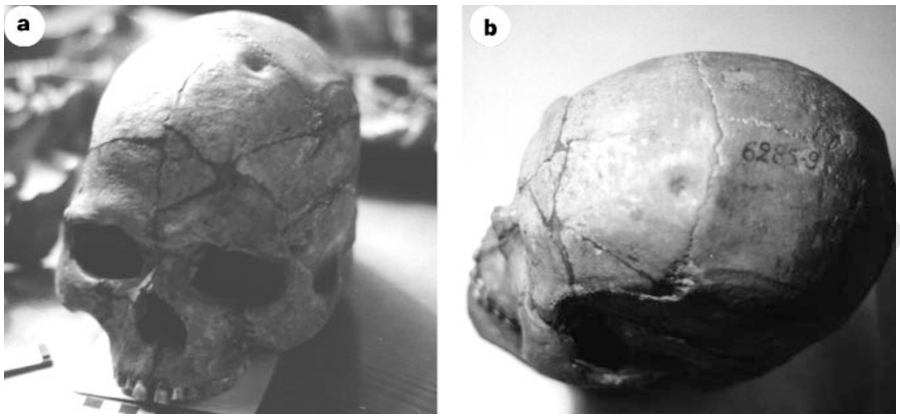

Figure 1 Photographs of cranium of skeleton No. 6285-9 from the cemetery of Vasilyevka II. **a**, front view: the healed trepanation is clearly visible as an area of remodelled bone on the left side. **b**, superior-lateral view: complete closure of the aperture and the 'stepped' nature of progressive stages of healing are apparent.

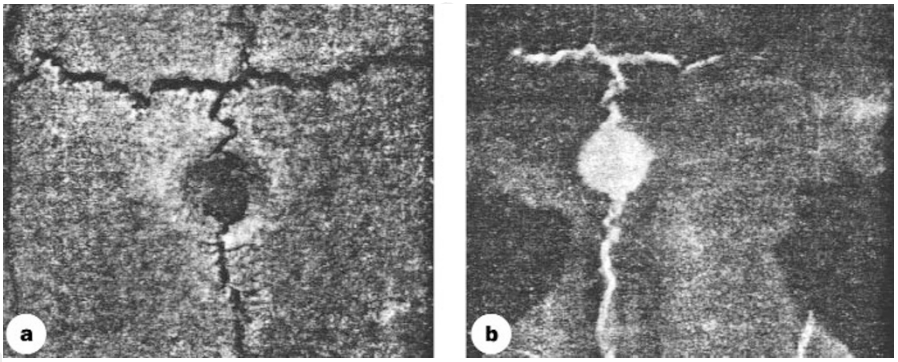

Figure 2 Skeleton No. 54 from the Vovnigi II cemetery (after Gokhman 1966:142). **a**, photograph of the unhealed trepanation, superior view. The front of the cranium is to the top of the picture. **b**, Radiograph of the trepanation highlighting the complete absence of remodelled bone.

The aperture has a pronounced raised border of remodelled bone, and 'stepping' in the central area reflects the progressive stages of closure during life. The central area of the depression is about 6 mm in diameter and the remodelled surface is extremely thin (less than 1mm) at this point. This skeleton (No. 6285-9) was recovered during excavations of the Vasilyevka II cemetery, carried out by A. D. Stolyar in 1953, and was originally reported in Russian in 1966[4].

New accelerator radiocarbon dating of the Dnieper Rapids cemeteries[5,6] has shown that the typological attribution of several of these cemeteries to the Neolithic period is erroneous. Three radiocarbon determinations of Vasilyevka II have placed this cemetery between 8,020 and 7,620 uncalibrated years before present, calibrated at the two sigma level to 7,300–6,220 BC (OxA-3804, OxA-3805 and OxA-3806).

Such dating confirms that this evidence offers the earliest example so far of trepanation, with the complete closure of the aperture indicating survival of the individual after surgery. The Vasilyevka II example predates the Ensisheim Neolithic site by 1,000–2,000 years. The remodelling that has occurred obscures the evidence for the method used to remove the bone, but it is likely that drilling[7] would have been used, as was the case for the second individual found to exhibit evidence of trepanation.

This second trepanation was noted in Russian language texts in 1966 (ref. 4). An adult male (Fig. 2) from the Vovnigi cemetery complex (5,470–4,783 BC) exhibits an almost identical style of trepanation to that evident in Fig. 1. Individual No. 54 from the Vovnigi II cemetery exhibits an unhealed trepanation hole on the sagittal suture about 20 mm above the coronal suture. The bone defect on the external plate of the skull is of a regular circular shape (14 mm in diameter), while on the internal plate the hole is irregular, resembling a rhombus[7]. The diploë is completely closed around the aperture, and the edges of the internal plate are thin, exhibiting scratches made during drilling.

Although it is of a later date, this example confirms the validity of the earlier identification. In this second instance, however, the lesion does not exhibit remodelling to the same extent as that shown in Fig.1a, suggesting that this individual did not survive the surgery for any great period of time.

The trepanations described by Alt *et al.*, although exceptional because of both their size and the survival of the patient after surgery, cannot therefore be viewed as 'the earliest unequivocal evidence of healed trepanations yet discovered'[1]. In the light of the above examples, it is possible that similar finds will emerge in other regions that have offered limited access to western researchers.

Accurate dating also needs to be considered. The recent accelerator radiocarbon dating of the Vasilyevka II cemetery suggests that archaeological cemeteries and sites dated by relative methods — such as typological seriation of artefacts — remain to be accurately dated in absolute terms.

Malcolm C. Lillie
Centre for Wetland Archaeology, University of Hull, Hull, HU6 7RX, United Kingdom
e-mail: M.C.Lillie@geo.hull.ac.uk

1. Alt, K. W. *et al. Nature* **387**, 360 (1997).
2. Lillie, M. C. *Curr. Anthropol.* **37**, 135–142 (1996).
3. Lillie, M.C. in *Invisible People and Processes: Writing Gender and Childhood into European Archaeology* (eds Moore, J & Scott, E.) 213–228 (Leicester Univ. Press, London, 1997) .
4. Gokhman, I. I. *Naselenie Ukrainy v epokhu mezolita i neolita: anthropologicheskiy ocherk (The Population of the Ukraine in the Mesolithic and Neolithic Periods: an Anthropological Outline)* 141–142 (Nauka, Moscow, 1966) .
5. Potekhina, I. D. & Telegin, D. Ya. *Curr. Anthropol.* **36**, 823–826 (1995).
6. Jacobs, K. *Curr. Anthropol.* **34**, 311–324 (1993).
7. Lisowski, F. P. in *Diseases in Antiquity: a Survey of Diseases, Injuries and Surgery of Early Populations* (eds Brothwell, D. and Sandison, A. T.) 651–672 (C. C. Thomas, Illinois, 1967) .