

## Syphilis in a Pleistocene bear?

SIR—Rothschild and Turnbull<sup>1</sup> attribute the cause of exuberant bone formation and periosteal reaction in the humerus, ulnae and three thoracic vertebrae of a Pleistocene bear (*Arcdotus simus*) to a treponemal infection. They use pathological bone morphology and immunofluorescent analysis as a basis for this conclusion. There is another view, that these lesions were caused by a mycotic (fungal) infection, tuberculosis or an unknown pathogen<sup>2</sup>.

The spinal lesions involve vertebrae T3, T4 and T5. Lytic destruction of the anterior half of each vertebral body has left a rough surface which is poorly defined radiographically (see figure). A large mass of hyperplastic bone circles the ventral portion of each vertebra and loosely locks the vertebrae together. The intervertebral disks appear to be destroyed. The neural canals, crests, spines, transverse processes and ribs are not affected. I observed no sequestra, vertebral collapse or rib lesions. There are several round, 'punched-out' lesions on the mandible which are 3 mm in diameter. The distal third of each ulna shows 1-cm diameter ovoid lesions penetrating 2 cm into the bone. There is minor periosteitis and a fistulous tract on the right ulna. Also noted is some periosteal reaction near the head of one humerus.

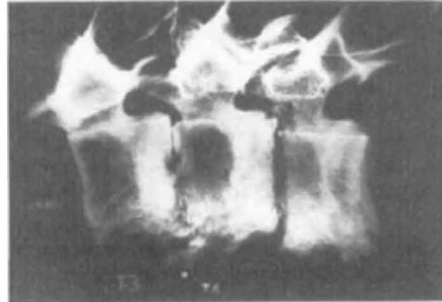
Treponematoses has been reported in man and monkey<sup>3</sup>. To my knowledge, this is the first and only report suggesting infection in modern or prehistoric subprimates. The description of the lesions are atypical for treponemal infections which favour involvement in multi-joints, the skull and tibiae<sup>4</sup>. Five per cent of osseous treponematoses occurs in the spine where proliferation of bone is limited and affects all adjoining structures<sup>4</sup>. Fusion and direct lesion extension is not seen in this specimen. The vertebrae are not fused and exhibit anterior body lysis. There is notable non-involvement of the ribs, neural arches and transverse processes — often seen in tuberculosis<sup>4,5</sup>.

Actinomycosis, blastomycosis and coccidioidomycosis may produce these lesions singly or in combination<sup>4,5</sup>. They may affect the animal locally or systemically. These mycotic agents are endemic throughout the mid-west United States and often infect domestic and wild animals<sup>6</sup>.

The immunofluorescent-histological analysis used indicates treponema; however, the test's reliability is questionable because: (1) the specimen is over 11,000 years old and treponema antigen is unlikely to maintain its reactivity; (2) the specimen was partially fossilized, leaving no fresh bone or soft tissue further reducing the chance of antigen survival; and (3) having been exposed to wildlife, then

buried for thousands of years and handled by innumerable people, there is a high probability of contamination with a cross-reactive agent. It would be helpful if samples from other areas of the *Arcdotus* skeleton, as well as from other skeletons of a similar geological age and geography were histologically analysed and compared.

It is unlikely that this is a case of treponematoses. No authenticated tre-



Radiograph of T3, T4, T5 showing anterior vertebral body destruction; a condition seen in tuberculosis and some fungal infections but absent in trepanematoses.

ponemal infections have been found in a non-primate. The lesions in this prehistoric bear have similar signs to those made by fungal or tubercular disease; either as a single or multiple infection<sup>4,5</sup>. The immunofluorescent analysis is limited to one area of the specimen and depends on the antigen remaining reactive and the bone uncontaminated over a 11,000-year span. Infective organisms tend to change in virulence and mode of action with time. This specimen may have been infected with unknown organisms or an early precursor of modern pathogens which resulted in a different expression of bone repair as compared with modern animals.

E.J. NEIBURGER

Curator-Lake County Museum,  
1000 North Avenue,  
Waukegan, Illinois 60085, USA

1. Rothschild, B. M. & Turnbull, W. *Nature* **329**, 61–62 (1987).
2. Neiburger, E.J. *Paleopathol. Newsletter* **48**, 8–11 (1984).
3. Hackett, C.J. *Bull. WHO* **29**, 7–14 (1963).
4. Steinbock, R.T. *Paleopathologic Diagnosis and Interpretation*. 89–169 (Thomas, Springfield, 1976).
5. Ortner, D. & W. Putschar. *Identification of Pathological Conditions In Human Skeletal Remains* 180–227 (Smithsonian Institution, Washington DC, 1981).
6. West, G.P. (ed.) *Encyclopedia of Animal Care* 11th edn (Williams and Wilkins, London, 1975).

## Right-handed longevity not so sinister after all?

SIR—Smoking, eating saturated fats, stress . . . and now we are told that left-handedness curtails the life-span. As an incurable sinistral, I suppose that I have a vested interest in finding Halpern and Coren's answer to the question "Do right-handers live longer?" (*Nature* **333**, 213; 1988) unconvincing. However, it is well established that nowadays there is considerably less pressure on children to use their right hands than there used to be.

Any 80-year old will tell you that he or she was not given any choice as to which hand to use for writing; I am sure that this was equally true in the teaching of baseball technique. Older baseball players probably have a greater tendency to use their right hands, through 'nurture' rather than 'nature'. This is surely more than adequate as an explanation of the mere eight months difference in the mean age at death of right- and left-handed baseball players, especially in view of the vast standard deviations.

RICHARD J. PERRY

Physiological Laboratory,  
University of Cambridge,  
Cambridge CB2 3EG, UK

SIR—The reason why Porac and Coren, mentioned in the letter from Halpern and Coren (*Nature* **333**, 213; 1988), found fewer left-handers in their 50s and none at the age of 80 or above might be very simple: in former times left-handers were forced to become right-handers — at least in Austria and Germany.

In my youth in Vienna — I was born in 1923 — I never saw anyone writing with

the left hand. I was astonished, in the 1950s, to observe some Americans writing obliquely with their left hand. Obviously, parents and teachers in the United States, on the advice of psychologists, let left-handed children have their way earlier than in Central Europe. Even now, left-handed writing is a rare exception in Austria and found only in the younger generation. Genetic or racial differences cannot be the reason for this difference between Austria and America.

I think that the conclusions of Halpern and Coren are based on wrong assumptions. The "higher environmental risk" they assume existed was only the strong hand of father and mother who did not want their child to be 'abnormal'.

FRIEDRICH KATSCHER

Mariahilfer Strasse 133,  
A-1150 Vienna, Austria

SIR—Perhaps the strenuous movements involved in baseball batting and pitching have graver physiological sequelae for left-handers than right-handers. There are other biases that should make one wary of extrapolating the conclusion of Halpern and Coren (*Nature* **333**, 213; 1988) to other groups of people. Their subjects were presumably men and very likely most of them were raised in North America. We are left with the inference that left-handed women cricketers need not worry unduly.

W.W. NICHOLS

Public Health Laboratory,  
John Radcliffe Hospital,  
Oxford, OX3 9DU, UK