

### Lysosomes in Melanin Phagocytosis and Synthesis

There are two types of pigmented cells in normal human skin, the junctional dendritic melanocyte and the intra-dermal melanosome-phagocytosing melanophage (Fig. 1). In contrast to the melanocyte and its contained melanosome synthesizing process which have been thoroughly investigated, the cellular physiology of the melanophage remains unknown despite recent advances in electron microscopy and gradient biochemistry. The two cells containing melanin appear similar under the light microscope but electron microscopy reveals definite structural differences. The normal melanocyte contains various stages of melanosome synthesis occurring individually in close association with the Golgi apparatus. On the other hand, the actively phagocytosing melanophage concentrates its melanosomes<sup>1-3</sup> as degradative conglomerates into specially developed phagocytic vacuoles structurally resembling the lysosomes found in such tissues as kidney, liver and pancreas<sup>4,5</sup>. Lysosomes were found to be rich in acid phosphatase<sup>4,5</sup>, which predicted the presence of this hydrolytic enzyme in the phagocytic vacuoles of the dermal melanophage<sup>6</sup>. We found subsequently that acid phosphatase activity is concentrated in the melanophages and that there is little or no such activity in the melanocytes at the epidermal-dermal junction<sup>7</sup>. On the other hand, the melanophages contain little if any tyrosinase while the junctional melanocytes are shown to contain an abundance of this oxidative enzyme, primarily within the premelanosomes<sup>8</sup>. It is further observed with the electron microscope, using the modified Gomori reaction, that the electron opaque accumulation of lead sulphide resulting from acid phosphatase activity occurs primarily in the melanosome-concentrating phagocytic vacuoles of the melanophages<sup>7</sup>.

Although normal melanocytes show little phagocytic activity, when the melanocyte assumes melanomatous growth it can develop autophagic vacuoles, concentrate melanosomes in these vacuoles and consequently exhibit an increase in acid phosphatase activity<sup>9</sup>. It has also been shown during a study of Fortner's melanoma that this increase in lysosomal activity appears to be related to clinically observable necrosis and ulceration<sup>9</sup>. As the acid phosphatase activity begins to appear in melanomatous growth the tyrosinase activity also increases, leaving a constant quantitative differential between these enzyme systems. The two enzymes are localized in different organelle systems. Thus a procedure for the simultaneous demonstration of these lytic and oxidative enzymes without abolition or cross contamination or both was developed<sup>10</sup> and shown to distinguish more precisely melanomatous cells as well as melanocytes from melanophages. In addition to these two lysosomal pathways in melanophages and melanomatous cells, the melanosome can follow a third route to complete its ontogeny. Another component of the epidermis, the keratinocyte, can phagocytose melanosomes from the melanocyte and ascend to the keratin layer rich in acid phosphatase where it completes its own ontogeny as well as that of its contained melanosomes (Table 1).

The lysosomal activities which we have found in the ontogeny of melanosomes have the following applications. (a) Melanophages can be clearly differentiated not only from normal junctional melanocytes but also from pre-malignant and malignant melanoma cells, the distinction between which is often critical, particularly after invasion


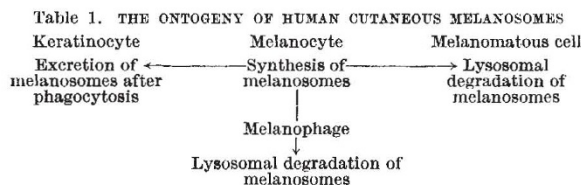


Fig. 1. Ontogeny of melanosomes and melanocyte in the epidermal-dermal structure. A junctional melanocyte actively synthesizing melanosomes shows individual occurrence of premelanosomes and melanosomes in its cytoplasm and transfers these melanosomes to neighbouring keratinocytes and melanophages with or without lysosomal activity. A high level dendritic Langerhans cell synthesizes its characteristic granules within its cytoplasm.

into the dermis. (b) Recent findings that the activity of lysosomes can be labilized and stabilized by various chemicals *in vitro* and *in vivo*<sup>11</sup> suggest a future therapeutic approach to such dermal hyperpigmentations as Riehl's melanosis and poikiloderma Civatte, for these disorders are the result of lysosomal accumulation of melanosomes. (c) It is known that malignant melanoma cells often undergo spontaneous ulceration and necrosis, and spontaneous regression has been observed<sup>12</sup>. We have found that these degradative processes are related to the ability of the melanoma cells to form lysosomes and to degrade themselves, and so the death of melanoma cells can be approached by the hormonal or chemical enhancement of lysosomal activity.

This work was supported in part by grants from the National Cancer Institute and the National Institute of Arthritis and Metabolic Diseases, National Institutes of Health, US Public Health Service.

YUTAKA MISHIMA

Department of Dermatology, Wayne State University School of Medicine, Detroit, and Veterans Administration Hospital, Dearborn, Michigan.

Received June 6; revised August 21, 1967.

<sup>1</sup> Mishima, Y., and Schaub, jun., F. F., *Proc. Twelfth Intern. Cong. Dermatol. Excerpta Med. Intern. Cong.*, Series 55, 1588 (1963).  
<sup>2</sup> Mishima, Y., *J. Invest. Dermatol.*, **39**, 369 (1962).  
<sup>3</sup> Drochman, P., *Intern. Rev. Exp. Pathol.*, **2**, 357 (1963).  
<sup>4</sup> De Duve, C., in *Ciba Foundation Symp.* (edit. by De Reuck, A. V. S., and Cameron, M. P.), **1** (Little, Brown and Co., Boston, 1963).  
<sup>5</sup> Novikoff, A. B., in *Ciba Foundation Symp.* (edit. by De Reuck, A. V. S., and Cameron, M. P.), **36** (Little, Brown and Co., Boston, 1963).  
<sup>6</sup> Mishima, Y., *J. Cell Biol.*, **23**, 122A (1964).  
<sup>7</sup> Mishima, Y., *J. Invest. Dermatol.*, **46**, 70 (1966).  
<sup>8</sup> Mishima, Y., *Arch. Dermatol.* (Chicago), **91**, 519 (1965); **92**, 393 (1965).  
<sup>9</sup> Mishima, Y., in *Advances in Biology of Skin*, **8**, 509 (edit. by Montagna, W.) (Pergamon Press, New York, 1967).  
<sup>10</sup> Mishima, Y., *Acta Derm.-Venereol.*, **46**, 307 (1966).  
<sup>11</sup> Weissmann, G., *Fed. Proc.*, **23**, 1038 (1964).  
<sup>12</sup> Everson, T. C., and Cole, W. H., *Spontaneous Regression of Cancer*, 164 (W. B. Saunders Co., Philadelphia, 1966).