

# Surgery Insight: natural orifice transluminal endoscopic surgery—an analysis of work to date

Mihir S Wagh and Christopher C Thompson\*

## SUMMARY

Traditional flexible endoscopy has been limited to the confines of the gastrointestinal lumen; however, recent developments involving transluminal access to intra-abdominal structures hold the potential to revolutionize flexible endoscopy. Over the past few years various studies have detailed techniques that intentionally breach the lumen and provide endoscopic access to the peritoneal cavity for diagnostic and therapeutic procedures. Unlike standard surgical approaches, which require incisions to be made in the abdominal wall, natural orifice transluminal endoscopic surgery (NOTES) avoids the need for abdominal incisions and can offer specific advantages to select patient populations. Animal models have been used to demonstrate the possible applications of NOTES, including transgastric peritoneoscopy, tubal ligation, gastrojejunostomy, partial hysterectomy, oophorectomy, and transcolonic exploration, liver biopsy and cholecystectomy. In this Review, we highlight important advances in NOTES since it was first described and analyze the hazards and potential benefits associated with this innovative approach.

**KEYWORDS** NOTES, transcolonic, transgastric endoscopy, transluminal surgery

## REVIEW CRITERIA

PubMed was searched in June 2006 for all English-language publications including the terms “transgastric endoscopy”, “transluminal endoscopy”, “transgastric surgery”, or “transluminal surgery”. Full articles from relevant records were obtained. The references listed in the selected articles were also checked. Meeting abstracts were also considered. No time limits were placed on the search so that all past historical references were obtained. The search was updated in April 2007.

## CME

*MS Wagh is a Visiting Assistant Professor of Clinical Medicine in the Section of ERCP, Division of Gastroenterology, Indiana University Medical Center, Indianapolis, IN, USA. CC Thompson is the Director of Developmental Endoscopy in the Division of Gastroenterology at Brigham and Women's Hospital and an Instructor in Medicine at Harvard Medical School, Boston, MA, USA.*

## Correspondence

\*Division of Gastroenterology, Brigham and Women's Hospital and Harvard Medical School, 75 Francis Street, Boston, MA 02115, USA  
ccthompson@partners.org

Received 13 December 2006 Accepted 14 May 2007

www.nature.com/clinicalpractice  
doi:10.1038/ncpgasthep0867

## Medscape Continuing Medical Education online

Medscape, LLC is pleased to provide online continuing medical education (CME) for this journal article, allowing clinicians the opportunity to earn CME credit. Medscape, LLC is accredited by the Accreditation Council for Continuing Medical Education (ACCME) to provide CME for physicians. Medscape, LLC designates this educational activity for a maximum of 1.0 AMA PRA Category 1 Credits™. Physicians should only claim credit commensurate with the extent of their participation in the activity. All other clinicians completing this activity will be issued a certificate of participation. To receive credit, please go to <http://www.medscape.com/cme/ncp> and complete the post-test.

## Learning objectives

Upon completion of this activity, participants should be able to:

- 1 Identify transluminal endoscopic procedures that have been performed in humans.
- 2 Describe how antibiotics may be used during transluminal endoscopic procedures.
- 3 Specify the most frequently used location for gastrostomy during transluminal endoscopic procedures.
- 4 Describe the practice of performing transluminal endoscopic procedures and associated challenges.

## INTRODUCTION

Minimally invasive surgical techniques have been evolving for more than 100 years, with the first experimental laparoscopy reported in 1901 by the German surgeon Georg Kelling.<sup>1</sup> He initially used a cystoscope to insufflate the abdominal cavity of a dog with air and explore its abdomen. He later used filtered atmospheric air to create a pneumoperitoneum in patients with the aim of stopping intra-abdominal bleeding.<sup>1</sup> These studies, however, did not garner the support of the medical community of the time. By the 1930s technical advances in laparoscopes, lenses and insufflation techniques led to widespread acceptance of the technique for diagnostic purposes and a few basic gynecologic therapeutic applications.<sup>2</sup>

In 1985, Erich Muhe reported the first laparoscopic cholecystectomy—the procedure was summarily rejected by the German Surgical Society.<sup>3</sup> Two years later, the French gynecologist Mouret was able to perform laparoscopic

cholecystectomy with only four trocars, and interest in the technique rapidly developed.<sup>4</sup> Laparoscopic cholecystectomy was subsequently performed with great success and became the trendsetter for minimally invasive surgery, leading to revolutionary changes in all fields of surgery.<sup>5</sup> This advance has resulted in a significant expansion of minimally invasive surgical techniques in the past few decades. Hybrid procedures combining flexible endoscopy and laparoscopy are also being performed in increasing numbers. Examples include intraoperative enteroscopy and laparoscopic-assisted endoscopic retrograde cholangiopancreatography (ERCP).<sup>6,7</sup>

A new dimension has now been added to minimally invasive surgery, with the advent of natural orifice transluminal endoscopic surgery (NOTES). The transluminal endoscopic route for surgery has the potential to eliminate complications associated with traditional surgery (e.g. postoperative abdominal wall pain, wound infections, hernias, adhesions, and possibly impaired immune function) and offer 'scarless' surgery. The transluminal approach could be particularly important for morbidly obese patients and others at high risk for standard surgery.

The first reports of transluminal endoscopy in pigs<sup>8</sup> and transgastric appendectomy in humans<sup>9</sup> were followed by a handful of other studies<sup>10–16</sup> that led, in turn, to the formation of the NOSCART (Natural Orifice Surgery Consortium for Assessment and Research) working group in 2006. The proceedings of the working group meeting were reported in the NOTES white paper, published in February 2006, and the first international meeting on NOTES was held by the group in March 2006 (International Conference on Natural Orifice Translumenal Endoscopic Surgery, March 2006, Scottsdale, Arizona).<sup>9</sup> Subsequently, there has been a surge in the number of different procedures performed with NOTES being reported at national meetings and published in the literature.

Various potential benefits of this novel technique have been proposed and debated, and are the driving force for investigative interest in this emerging surgical field. In the remainder of this Review, we examine the current status of NOTES and the implications it has for the future of surgical endoscopy.

## PUBLISHED STUDIES

The basic concept of NOTES was first described in a 1994 methods patent by Peter Wilk,<sup>17</sup>

although there was already an unpublished report of laparoscopic hybrid procedures with transluminal organ retrieval being performed at the Cleveland Clinic. Transvaginal hybrids have also been performed, including transvaginal cholecystectomy in 2003.<sup>18</sup>

True NOTES transgastric peritoneal exploration was reported in 2004 by Kalloo and colleagues, in a pig model.<sup>8</sup> This group went on to describe their experience of performing the first transgastric therapeutic procedure—tubal ligation—in 2005.<sup>10</sup> Swain and colleagues subsequently published the results of their work on nonsurvival transgastric gallbladder surgery.<sup>12</sup> In addition, Wagh *et al.* demonstrated that detailed and systematic endoscopic examination of the peritoneal cavity was possible via the transgastric route; they also reported the first successful application of NOTES for organ resection with survival.<sup>13</sup> Since then various surgical procedures have been performed via transluminal endoscopic access, such as transgastric oophorectomy with survival,<sup>14</sup> partial hysterectomy,<sup>15</sup> transgastric gastrojejunostomy,<sup>11</sup> and splenectomy in a nonsurvival model.<sup>16</sup> Table 1 summarizes the various transluminal endoscopic procedures that have been published thus far.

Rao and Reddy<sup>9</sup> have performed transgastric appendectomy in humans in Hyderabad, India; however, this is the only report of NOTES being performed in humans and the full manuscript of this study has not yet been published.

The initial reports of transgastric endoscopic procedures, as noted above, have led to bolder transluminal ventures. For example, preliminary results of the first transcolonic procedures were presented at the First International Conference on NOTES in March 2006, in Scottsdale, Arizona,<sup>19</sup> and were later published.<sup>20</sup> Experience with transcolonic abdominal exploration<sup>21</sup> and hepatic wedge resection<sup>22</sup> has also been reported. Posterior gastric access procedures have also been explored for evaluating the retroperitoneum<sup>23</sup> and for distal pancreatectomy in a nonsurvival model.<sup>24</sup>

## PROCEDURAL METHODS

### Preparation

In the studies published to date, animals are typically premedicated with sedative anesthetics and given parenteral antibiotics as described,<sup>10,11,14,15</sup> and all procedures are performed under general endotracheal anesthesia with isoflurane. Chemical disinfection and gas sterilization of

**Table 1** Summary of transluminal endoscopic procedures published in full.

Study authors and reference	Procedure	Number of subjects	Type of model
Kalloo <i>et al.</i> <sup>1</sup>	Peritoneoscopy	12	Nonsurvival
	Liver biopsy	5	Survival
Jagannath <i>et al.</i> <sup>3</sup>	Tubal ligation	6	Survival
Kantsevov <i>et al.</i> <sup>4</sup>	Gastrojejunostomy	2	Survival
Park <i>et al.</i> <sup>5</sup>	Gallbladder surgery	11	Nonsurvival
	Gastrotomy closure	8	Survival
Wagh <i>et al.</i> <sup>6</sup>	Exploration	9	Nonsurvival
	Organ resection	6	Survival ( <i>n</i> = 3)
Wagh <i>et al.</i> <sup>7</sup>	Oophorectomy and tubectomy	6	Survival
Merrifield <i>et al.</i> <sup>8</sup>	Partial hysterectomy	5	Survival
Kantsevov <i>et al.</i> <sup>9</sup>	Splenectomy	6	Nonsurvival
Pai <i>et al.</i> <sup>11</sup>	Transcolonic cholecystectomy	5	Survival

endoscopes with ethylene oxide has also been reported,<sup>8,10</sup> as has chemical disinfection with glutaraldehyde alone.<sup>13–15</sup>

### Technique

The procedure itself typically begins with the use of a standard single-channel endoscope for gastroscopy and placement of an overtube. Residual gastric contents are then suctioned and the stomach lavaged to remove particulate matter. The stomach is then disinfected with an antibiotic lavage. In their initial report, Kalloo and colleagues used neomycin and polymyxin B for the gastric lavage.<sup>8</sup> We have typically used cefazolin with good results.<sup>13–15</sup> The exact clinical benefit of reducing the bacterial load by antibiotic lavage has not been studied or quantified; however, intuitively this step seems logical to maintain sterility in the peritoneal cavity.

For transcolonic procedures the reported preparation consists of two sequential sterile-water enemas, followed by the removal of residual stool with snares, aggressive washing, and suctioning. A cefazolin suspension is then instilled endoscopically into the distal colon and the rectum. The distal colon, rectum, and anal orifice are prepared with both internal instillations of Betadine® (Purdue Pharma LP, Stamford, CT) and an external Betadine® scrub.

A second, therapeutic double-channel gastro-scope is then advanced through the overtube to limit contamination of the endoscope with oral microbial flora. Various techniques for gastrotomy have been reported, with the most common location for the incision being the anterior gastric

wall. A needle-knife incision can be made to puncture the wall and the gastrotomy extended by various instruments, including the needle-knife, insulation-tipped (IT) knife, pull-type sphincterotome, or controlled radial expansion (CRE) balloon. Our group initially used endoscopic ultrasound (EUS) to mark the gastrotomy location, but this technique was abandoned after initial experiments found it to not be particularly useful.<sup>13</sup> A percutaneous endoscopic gastrostomy (PEG) technique has also been described to help prevent damage to adjacent structures.

The therapeutic gastroscope is then advanced into the peritoneal cavity and various surgical procedures can be performed with standard endoscopic accessories (e.g. biopsy and grasping forceps, snares, endoloops, endoclips). Once the surgical procedure is complete, the therapeutic endoscope is withdrawn and the gastric incision is closed with endoclips or with specialized, prototype suturing devices placed endoscopically into the stomach. Several promising prototypes have been studied;<sup>25–28</sup> however, at this point no technique has been proven to be superior.

### CHALLENGES

Various groups around the world are now actively researching the use of this novel avenue for abdominal surgery. As with any new technique, NOTES is experiencing teething problems. It has its fair share of skeptics, faces various technical and intellectual challenges and several key issues need to be addressed. For NOTES to be used in the clinical setting, safety and no less than equivalent outcomes (than when procedures are performed via more traditional methods) must be demonstrated; otherwise, the risks associated with NOTES will outweigh the benefits.

### Peritoneal access site

Excellent views of the peritoneal cavity and abdominopelvic organs can be obtained after transluminal endoscopic access (Figures 1 and 2). The views of upper abdominal organs such as the liver and gallbladder are currently limited, and retroflexion is required for any operations on upper abdominal organs, while pelvic organs are better seen as a 'straight shot' without retroflexion. Transcolonic access provides very good views of the upper abdomen without the need for retroflexion.<sup>20,22</sup> The differences in positioning and the views obtained mean that important technical issues regarding the best access site to the various intraperitoneal organs have

to be considered. For example, the transcolonic access needs to be studied further with regards to potential infectious complications. Other inferior access sites could also become relevant for upper abdominal procedures, including transvaginal or perhaps even transvesical routes as they might be safer from an infection standpoint or provide better access to various structures. The potential risks and benefits of these various access sites must be carefully evaluated.

### Closure of the access site

In our experience, closure of the gastrotomy or colotomy site seems to be the most crucial part of transluminal surgery, and various devices are being developed to aid closure. Examples include a novel endoscopic incision and closure device (e.g. The Stringer Device, LSI Solutions, Victor, NY),<sup>25</sup> a three-channel device based on ShapeLock® technology (USGI Medical, Inc., San Clemente, CA),<sup>26,27</sup> EndoCinch (Bard, Murray Hill, NJ), a needle, tag-thread and locking method,<sup>28</sup> and Eagle Claw (Olympus America, Inc., Center Valley, PA).<sup>29</sup> Endoclips are the accessory most commonly used for gastrotomy closure; however, endoclips are primarily designed for hemostasis and are not suited for approximating the edges of the gastrotomy for incision closure.

In some early studies, such as the study by Jagannath *et al.*,<sup>10</sup> the balloon-dilated gastric exit site was not endoscopically closed because it seemed to have closed spontaneously and rapidly on withdrawal of the endoscope, and the animals did well. In other studies, however, such as the study by Merrifield *et al.*,<sup>15</sup> incomplete gastrotomy closure was felt to be responsible for sepsis and peritonitis after transgastric partial hysterectomy. Secure closure of the gastric incision would be prudent and mandatory if transluminal surgery were to be attempted in humans because the risk of peritonitis would be unacceptable. Further work is needed in this area to address the various closure methods (i.e. full versus partial thickness), including different devices (clips versus staples versus sutures). Similar methods would be applicable to rectal or colonic closure.

### Peritoneal insufflation

Adequate peritoneal insufflation is essential for endoscopic visualization and subsequent surgical therapy. Most published reports have used room air, pumped in via the endoscope processor, for

peritoneal insufflation, whereas Swanstrom and colleagues described the use of a standard laparoscopic insufflator for peritoneal insufflation with carbon dioxide.<sup>27</sup> Carbon dioxide is the preferred agent for peritoneal insufflation for laparoscopic surgery: it is nonflammable and rapidly absorbed, thus causing less abdominal distention than room air. In addition, carbon dioxide insufflators have filters that ensure the sterility of the insufflated gas, unlike endoscopic processors. The issue of which gas to use for peritoneal insufflation is now being actively studied by several groups. Reaching an intraperitoneal pressure of more than 15 mmHg during surgery is hazardous and can impair venous return. Published studies on transluminal endoscopy in pigs have not monitored intraperitoneal pressure and its effect on intraoperative and postoperative complications. Intraperitoneal pressure would have to be monitored if the technique was used in humans; a novel device for measuring intraperitoneal pressure and that has a control valve for pressure regulation has been described in abstract form.<sup>28</sup>

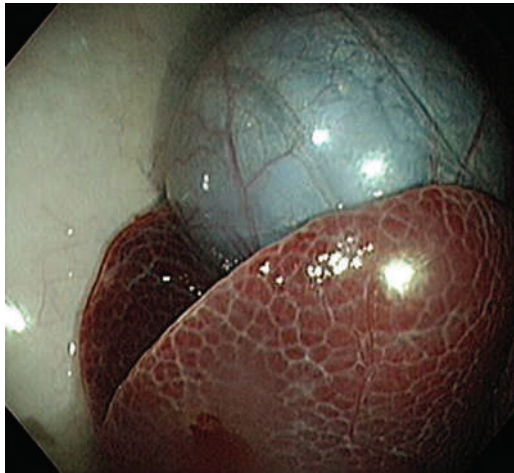
### Clinical outcomes

The entire premise of transluminal surgery is based on the potential advantages associated with scarless access to the peritoneal cavity. So far, however, there have been no studies to show exactly what the advantages are. Studies needed to demonstrate the efficacy of NOTES in preventing postoperative hernias, adhesions and abdominal wall pain would be cumbersome and require years of follow-up. Until the issues surrounding the advantages of NOTES are addressed, the potential benefits of transluminal surgery remain theoretical and without a scientific basis. On the other hand, laparoscopic surgery has a proven track record and is associated with minimal morbidity and mortality.

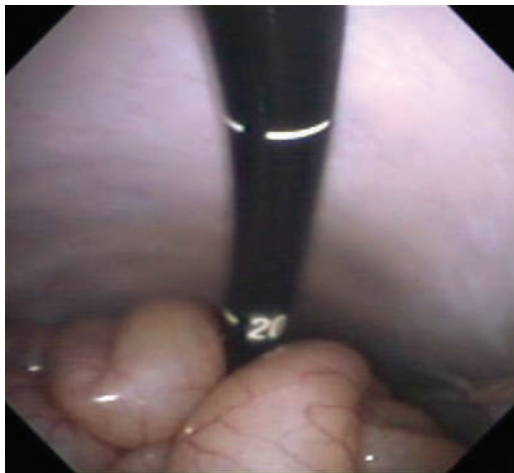Some complications are to be expected with any procedure, but there should be a low threshold for tolerating complications arising from NOTES procedures. A policy of zero or low-tolerance for complications that are unique to the method (e.g. peritoneal infection, bleeding and damage to surrounding structures related to gastrotomy and its closure) must, therefore, be a priority when translating NOTES to human use.

### Tools and accessories

Endoscopic devices currently used for NOTES are designed for intraluminal use (e.g. for biopsy, polypectomy, hemostasis, etc.). These tools are



**Figure 1** An excellent view of the peritoneal cavity obtained by transluminal endoscopy. The liver and gallbladder are shown in this photograph as seen after exiting the gastrointestinal lumen.



**Figure 2** A retroflexed view after transgastric access showing the parietal peritoneum and bowel loops.

not intended to be used for organ resection, tissue retraction or apposition, suturing, or other surgical procedures. Basic necessities for minimally invasive surgery such as triangulation cannot be achieved with standard therapeutic endoscopes. The use of intraluminal accessories for transluminal surgery is somewhat analogous to driving a nail with a screwdriver. The lack of appropriate tools has led to increased collaboration among surgeons, gastroenterologists and industry experts for the development of tools specifically designed for transluminal surgery. NOTES tools would address issues

of triangulation, tissue retraction, apposition, and so on.

### Training

Gastroenterologists are medical doctors by training and transluminal endoscopy is surgery. This difference in specialization and training poses an ethical, political and financial conundrum. Although fellowship training in gastroenterology enables gastroenterologists to perform traditional endoscopy safely, the same training does not encompass transluminal surgery. The ability to manage potentially life-threatening intra-abdominal complications, such as bleeding, perforation and organ damage, appropriately lies in the surgical domain. Similarly, most surgical training programs do not equip surgeons with the endoscopy skills needed to perform NOTES-type procedures, and these skills will probably take years to develop.

If NOTES is to be performed in humans, the structure of training programs in gastroenterology and surgery must change. Introducing an advanced tier of training in NOTES will probably be a necessity. This advanced tier of training could be offered to aspiring gastroenterologists or surgeons and must focus on rectifying the deficiencies in each respective program.

### Indications

Specific defined indications for transluminal endoscopy need to be determined. Intuitively, patient populations most likely to benefit from these procedures include the critically ill, morbidly obese and other patients at high risk for surgery. For these same reasons it is imperative that NOTES procedures in these patients meet the highest standards of safety. Clinical studies that define criteria for appropriate NOTES indications are needed to serve as guidelines when considering NOTES as a therapeutic option.

### Immune function

Surgery induces alterations in local and systemic immune responses. Postoperative systemic immunosuppression occurs in patients who undergo open abdominal surgery and still occurs, albeit to a lesser degree, after laparoscopic surgery.<sup>30,31</sup> If the degree of immunosuppression correlates with the extent of abdominal wall trauma, then the choice of abdominal access could affect immunologic outcome.<sup>31</sup> The effect of NOTES on the immune system is currently unknown.

## THE FUTURE OF NOTES

The enthusiasm for NOTES seems to be outpacing scientific evaluation of this new technique. It is too early to determine which conditions will be best treated by NOTES. The ideal application for NOTES will probably need to show that NOTES provides a significant incremental benefit over existing procedures that leads to its broad adoption, and this application must inspire further innovation that makes other NOTES procedures reasonable options. The NOSCARGroup has attempted to manage the development of this new field prospectively, thereby averting the problems seen during the maturation of laparoscopic surgery. In the early days of laparoscopic surgery, rapid and premature adoption of new techniques by individuals still near the beginning of the learning curve led to complications that could have been prevented.

NOSCARGroup is attempting to limit the number of preventable errors that occur with NOTES, by emphasizing the need for institutional review board approved protocols, patient registries, and close collaboration across disciplines. Some specific guidelines on the safe pursuit of the field are offered in the NOTES White Paper.<sup>9</sup> The NOSCARGroup now exists as a joint committee of the American Society for Gastrointestinal Endoscopy (ASGE) and the Society of American Gastrointestinal Endoscopic Surgeons (SAGES), and more information about NOTES can be obtained on the NOSCARGroup website.<sup>32</sup> Several academic centers now have institutional review board approved protocols for various NOTES procedures and we will probably see the resulting preliminary reports and case series in the very near future.

## CONCLUSIONS

We are currently witnessing the advent of a brave new dimension for endoscopy. Various transluminal procedures have been successfully performed in animal models but have not yet been translated to humans, with the exception of an anecdotal report of human transgastric appendectomy. These early advances are, however, hampered by various technical and scientific hurdles. With the availability of improved endoscopic tools, NOTES could become an acceptable alternative—and the preferred approach—for the management of certain abdominopelvic conditions in select patients. The proposed benefits and safety of having scarless access to the peritoneal cavity need to be conclusively demonstrated in clinical studies before NOTES is universally accepted.

## KEY POINTS

- Endoscopic access to the peritoneal cavity via transgastric and transcolonic routes has been recently described in animal models and termed Natural Orifice Transluminal Endoscopic Surgery (NOTES)
- This 'scarless' surgery avoids abdominal incisions and could be advantageous in specific patient populations
- With improved endoscopic tools, NOTES could become an acceptable alternative and the preferred approach for management of certain abdominopelvic conditions in select cases
- The proposed benefits and safety of scarless access to the peritoneal cavity need to be conclusively demonstrated in clinical studies before universal acceptance of NOTES

## References

- 1 Litynski GS (1999) Endoscopic surgery: the history, the pioneers. *World J Surg* **23**: 745–753
- 2 Decker A *et al.* (1944) Culdoscopy: A new method in the diagnosis of pelvic disease—a preliminary report. *Am J Surg* **64**: 40–44
- 3 Litynski GS (1998) Erich Muhe and the rejection of laparoscopic cholecystectomy (1985): a surgeon ahead of his time. *J Soc Laparoendosc Surg* **2**: 341–346
- 4 Mouret P (1991) From the first laparoscopic cholecystectomy to the frontiers of laparoscopic surgery: the future perspectives. *Dig Surg* **8**: 1124–1125
- 5 Keus F *et al.* Laparoscopic versus open cholecystectomy for patients with symptomatic cholelithiasis. *Cochrane Database of Systematic Reviews* 2006, Issue 4. Art. No.: CD006231. DOI: 10.1002/14651858.CD006231
- 6 Ceppa FA *et al.* (2007) Laparoscopic transgastric endoscopy after Roux-en-Y gastric bypass. *Surg Obes Relat Dis* **3**: 21–24
- 7 Peters M *et al.* (2002) Laparoscopic transgastric endoscopic retrograde cholangiopancreatography for benign common bile duct stricture after Roux-en-Y gastric bypass. *Surg Endosc* **16**: 1106
- 8 Kalloo AN *et al.* (2004) Flexible transgastric peritoneoscopy: a novel approach to diagnostic and therapeutic interventions in the peritoneal cavity. *Gastrointest Endosc* **60**: 114–117
- 9 ASGE/SAGES Working Group on Natural Orifice Transluminal Endoscopic Surgery White Paper 2005 (2006) *Gastrointest Endosc* **63**: 199–203
- 10 Jagannath SB *et al.* (2005) Peroral transgastric endoscopic ligation of fallopian tubes with long-term survival in a porcine model. *Gastrointest Endosc* **61**: 449–453
- 11 Kantsevov SV *et al.* (2005) Endoscopic gastrojejunostomy with survival in a porcine model. *Gastrointest Endosc* **62**: 287–292
- 12 Park PO *et al.* (2005) Experimental studies of transgastric gallbladder surgery: cholecystectomy and cholecystogastric anastomosis. *Gastrointest Endosc* **61**: 601–606
- 13 Wagh MS *et al.* (2005) Endoscopic transgastric abdominal exploration and organ resection: initial experience in a porcine model. *Clin Gastroenterol Hepatol* **3**: 892–896
- 14 Wagh MS *et al.* (2006) Survival studies after endoscopic transgastric oophorectomy and tubectomy in a porcine model. *Gastrointest Endosc* **63**: 473–478

**Acknowledgments**

Charles P Vega, University of California, Irvine, CA, is the author of and is solely responsible for the content of the learning objectives, questions and answers of the Medscape-accredited continuing medical education activity associated with this article.

**Competing interests**

The authors declared they have no competing interests.

- 15 Merrifield BF *et al.* (2006) Peroral transgastric organ resection: a feasibility study in pigs. *Gastrointest Endosc* **63**: 693–697
- 16 Kantsevov SV *et al.* (2006) Transgastric endoscopic splenectomy: is it possible? *Surg Endosc* **20**: 522–525
- 17 Wilk PJ (1994) Method for use in intra-abdominal surgery. US Patent 5,297,536
- 18 Tsin DA *et al.* (2003) Culdolaparoscopic cholecystectomy during vaginal hysterectomy. *J Soc Laparoendosc Surg* **7**: 171–172
- 19 Natural Orifice Surgery Consortium for Assessment and Research (NOSCAR™) International Conference on Natural Orifice Transluminal Endoscopic Surgery (NOTES™)[<http://www.noscar.org/conference06.html>]
- 20 Pai RD *et al.* (2006) Transcolonic endoscopic cholecystectomy: a NOTES survival study in a porcine model (with video). *Gastrointest Endosc* **64**: 428–434
- 21 Fong DG *et al.* (2007) Transcolonic endoscopic abdominal exploration: a NOTES survival study in a porcine model. *Gastrointest Endosc* **65**: 312–318
- 22 Fong DG *et al.* (2006) Transcolonic hepatic wedge resection in a porcine model [abstract]. *Gastrointest Endosc* **63**: AB102
- 23 Chak A *et al.* (2006) EUS Guided natural orifice transvisceral endoscopic surgical (NOTES) approach to the retroperitoneum [abstract]. *Gastrointest Endosc* **63**: AB264
- 24 Matthes K *et al.* (2006) Feasibility of endoscopic transgastric distal pancreatectomy (ETDP) in the pig [abstract]. *Gastrointest Endosc* **63**: AB229
- 25 Fong DG *et al.* (2006) Transcolonic access to the peritoneal cavity using a novel incision and closure device [abstract]. *Gastrointest Endosc* **63**: AB233
- 26 Pasricha P *et al.* (2005) A next generation therapeutic endoscope: development of a novel endoluminal surgery system with “birds-eye” visualization and triangulating instruments [abstract]. *Gastrointest Endosc* **61**: AB106
- 27 Swanstrom LL *et al.* (2005) Development of a new access device for transgastric surgery. *J Gastrointest Surg* **9**: 1129–1137
- 28 Park PO *et al.* (2006) Measurements of intraperitoneal pressure during flexible transgastric surgery and the development of a feed-back control valve for regulating pressure [abstract]. *Gastrointest Endosc* **63**: AB101
- 29 Hu B *et al.* (2005) Endoscopic suturing without extracorporeal knots: a laboratory study. *Gastrointest Endosc* **62**: 230–233
- 30 Kuhry E *et al.* (2004) Effect of laparoscopy on the immune system. *Semin Laparosc Surg* **11**: 37–44
- 31 Sylla P *et al.* (2005) Immunological advantages of advanced laparoscopy. *Surg Clin North Am* **85**: 1–18
- 32 NOSCAR website [[www.noscar.org](http://www.noscar.org)]