

Expression of the ELAV-like protein HuR in human colon cancer: association with tumor stage and cyclooxygenase-2

Carsten Denkert, Ines Koch, Nora von Keyserlingk, Aurelia Noske, Silvia Niesporek, Manfred Dietel and Wilko Weichert

Institute of Pathology, Charité University Hospital, Berlin, Germany

There is growing body of evidence that post-translational events contribute—in addition to genetic changes—to the progression of malignant tumors. These post-translational alterations may provide targets for new therapeutic approaches. The ELAV-like protein HuR stabilizes a group of cellular mRNAs which contain AU-rich elements in their 3' untranslated region. To investigate a possible contribution of post-translational changes to the progression of colon cancer and to overexpression of COX-2, we studied expression of HuR and COX-2 a cohort of colorectal adenocarcinomas and in colon cancer cell lines. All cell lines showed an expression of HuR mRNA and protein. In tumor tissue of colon carcinomas we observed two different staining patterns of HuR: A nuclear expression in 98% as well as an additional cytoplasmic expression in 53% of cases. COX-2 was expressed in 63% of carcinomas. Cytoplasmic expression of HuR was significantly associated with increased COX-2 expression as well as with high tumor stage. In univariate Kaplan–Meier analysis, grading, tumor stage and nodal status but not HuR or COX-2 expression were prognostic factors for overall survival. Our results suggest that the overexpression of HuR in colon cancer may be part of a regulatory pathway that controls the mRNA stability of cyclooxygenase-2 and provides an interesting example for a contribution of a dysregulation of mRNA stability to the progression of colorectal cancer. Based on our results, further studies are necessary to investigate whether HuR might be a potential target for a molecular tumor therapy.

Modern Pathology (2006) 19, 1261–1269. doi:10.1038/modpathol.3800645; published online 23 June 2006

Keywords: ELAV-like proteins; COX-2; HuR; colon cancer; prognosis

Colorectal cancer is the third most common cancer for both sexes, with an estimated number of 144 000 new cases and 56 000 estimated deaths in the US in 2005.¹ Despite advances in diagnosis and surgical treatment of colorectal cancer, incidence as well as mortality of colorectal cancer has decreased only slightly in the last 20 years. While the disease is curable in early stages, the risk of recurrence and metastasis is substantially higher for advanced tumors. Various chemotherapeutic approaches such as treatment with 5-fluorouracil (5-FU) have led only to a weak to moderate decline in mortality. To improve outcome and to plan an individualized chemotherapy adapted to the requirements of each patient, it would be necessary to use additional

parameters such as biological tumor markers to assess the individual risk of recurrence. Furthermore, it would be interesting to use new therapeutic options in addition to the conventional chemotherapeutic approaches.

In colorectal carcinoma as well as in other types of tumors, various genetic alterations have been described that contribute to the development of the malignant phenotype.² In addition to these alterations on the DNA level, there is growing body of evidence that changes involving post-translational events contribute to the progression of malignant tumors and to the modulation of tumor–host interactions.^{3,4} These dysregulations in post-translational regulation may provide additional targets for new therapeutic approaches.

The human family of ELAV-like proteins is involved in nuclear export and post-translational stabilization of a set of mRNAs that are tightly regulated in normal tissues. This protein family consists of four members that are highly homologous to the *Drosophila* nuclear protein embryonic-lethal

Correspondence: Dr C Denkert, MD, Institute of Pathology, Charité University Hospital, Campus Mitte, Schumannstr. 20/21, D-10117 Berlin, Germany.

E-mail: carsten.denkert@charite.de

Received 9 January 2006; revised 5 May 2006; accepted 8 May 2006; published online 23 June 2006

abnormal vision (ELAV).⁵⁻⁷ While three of the four human ELAV-like proteins are expressed preferentially in terminally differentiated neurons, the fourth protein HuR (HuA) is ubiquitously expressed in many cell types.^{8,9} Hu proteins have been found to shuttle between the nucleus and the cytoplasm and to regulate the expression of labile mRNAs containing AU-rich elements in their 3'/untranslated regions. It has been shown that the cyclooxygenase-2 (COX-2) mRNA as well as other mRNAs of cytokines and proteins related to cell proliferation have AU-rich element in 3' untranslated regions that serve as a binding site for HuR, resulting in an increased mRNA half life.¹⁰⁻¹² In a study of the function of Hu proteins in colorectal cancer cell lines, Dixon *et al*¹³ have found that HuR is involved in regulation of mRNA stability of COX-2 and other target mRNAs. Based on these cell culture experiments, we evaluated the hypothesis that the overexpression of COX-2 in human malignant tumors might be the result of a dysregulation of function and expression pattern of Hu proteins. Thus, the regulation of COX-2 expression in malignant tumors, such as colorectal carcinoma, may provide an interesting example for a possible contribution of a dysregulation of mRNA stability to the progression of cancer. To investigate whether the findings of Dixon *et al* in colorectal cancer cell lines are also present in human colon cancer, we analyzed expression as well as cellular localization of HuR and cyclooxygenase-2 in a cohort of primary colorectal adenocarcinomas. Expression of the immunohistochemical markers was correlated with clinical pathological parameters as well as with patient outcome.

Materials and methods

Study Population and Histopathological Evaluation

A total of 106 patients with colorectal adenocarcinomas who were diagnosed at the Institute of Pathology of the Charité University Hospital (Berlin, Germany) between 1996 and 1999 were included in this retrospective study. Only patients with primary colorectal adenocarcinomas and no other known malignancies and no preoperative radiochemotherapies were included in this study. Tissue samples were fixed in 4% buffered formaldehyde, embedded in paraffin and histological diagnosis was established on standard H&E stained sections according to the WHO guidelines. Mucinous carcinomas were defined as tumors containing >50% mucin. For all patients a minimum of 12 lymph nodes were investigated. Clinical follow-up data were available for all patients. The mean follow-up time of patients alive at the end of observation was 60 months (range 5.5-90 months). 27 patients died at the end of observation. The patient characteristics are shown in Table 1. In addition to the cancer tissues, 14 cases of normal colon mucosa were investigated.

Table 1 Clinicopathological characteristics of 106 patients with colorectal adenocarcinomas

Characteristic	All cases
<i>pT</i>	
pT1	6 (5.7%)
pT2	28 (26.4%)
pT3	65 (61.3%)
pT4	7 (6.6%)
<i>pN</i>	
pN0	67 (63.2%)
pN1	20 (18.9%)
pN2	19 (17.9%)
<i>pM</i>	
pMX	98 (92.5%)
pM1	8 (7.5%)
<i>Lymphangiosis (pL)</i>	
PL0	94 (88.7%)
PL1	12 (11.3%)
<i>Venous invasion (pV)</i>	
PV0	101 (95.3%)
PV1	5 (4.7%)
<i>Histological grade</i>	
G1	5 (4.7%)
G2	83 (78.3%)
G3	18 (17.0%)
<i>DUKES stage</i>	
A	28 (26.4%)
B	37 (34.9%)
C	33 (31.1%)
D	8 (7.6%)
<i>AJCC stage</i>	
I	30 (28.3%)
II	36 (34%)
III	32 (30.2%)
IV	8 (7.5%)
<i>Sex</i>	
Male	54 (50.9%)
Female	52 (49.1%)
<i>Histological type</i>	
Adenocarcinoma	94 (88.7%)
Mucinous adenocarcinoma	12 (11.3%)

Immunohistochemistry

For HuR immunohistochemistry, we used the mouse monoclonal anti-human HuR antibody (3A2, Santa Cruz Biotechnology, Santa Cruz, CA, USA, 1:1000) with antigen-retrieval in citrate buffer in a pressure cooker for 5 min. Slides were incubated with a biotinylated anti-mouse secondary antibody using the multilink biotin-streptavidin-amplified detection system (Biogenex, San Ramon, CA, USA). Staining was visualized using fast-red chromogen (Sigma, St Louis, MO, USA).

The intensity of cytoplasmic and nuclear immunostaining in tumor cells were evaluated

independently by two investigators (WW and CD), who were blinded to patient characteristics and outcome. Cases with a disagreement of both investigators on the immunoreactive score were discussed using a multiheaded microscope until consensus was achieved. The cytoplasmic and nuclear staining patterns of HuR were evaluated separately, each according to the percentage of positive cells and the intensity of staining. For each case one complete histological section was evaluated. The percentage of positive cells was scored as: 0 (0%); 1 (<10%); 2 (10–50%); 3 (51–80%); 4 (>80%). The staining intensity was scored as: 0 (negative), 1 (weak), 2 (moderate) and 3 (strong). For the immunoreactive score (IRS) the scores for the percentage of positive cells and the staining intensity were multiplied, resulting in a value between 0 and 12.¹⁴ To separate cases with a low or a strong expression of cytoplasmic or nuclear HuR, we combined cases with an IRS of 0–6 to one group with negative to low HuR expression ('HuR-negative'), while cases with an IRS of 7–12 were combined into a 'HuR-positive' group. These cut points were chosen in analogy to studies of HuR in other types of cancer, to ensure the comparability of the results.¹⁵ Immunohistochemical staining of COX-2 was performed according to standard procedures as previously described.¹⁶ To evaluate the specificity of the COX-2 antibody (Cayman Chemical, Ann Arbor, MI, USA) we and others have already performed blocking experiments with the COX-2 blocking peptide (Cayman Chemicals) according to the manufacturer's instructions.¹⁵ In addition, we used control tissue and cell lines for control of immunohistochemical staining procedures.

Cell Lines and Polymerase Chain Reaction

The human colorectal adenocarcinoma cell lines SW480, Caco-2, SW707, HT-29, HRT-18, CX-2, LoVo were cultured in DMEM supplemented with 10% fetal bovine serum. Subconfluent carcinoma cells were harvested and total RNA was prepared with RNeasy Kit (Qiagen, Hilden, Germany) and reverse transcribed. PCR cycling conditions for HuR were 30 cycles of denaturation, annealing and extension (94°C for 60 s, 55°C for 60 s and 72°C for 60 s). The primers used were human HuR sense 5'-ATAC AATGTCTAATGGTTATGAAGACC-3' and antisense 5'-GTTATTTGTGGGACTTG-3' (generating an 986 bp band)¹⁰ as well as GAPDH sense 5'-CCATGGCA CCGTCAAGGCTG-3' and antisense 5'-GCCATGT GGGCCATGAGGTC-3' (generating a 827 bp band).

Immunoblotting

Western blots were performed as previously described, using a mouse monoclonal anti-HuR (Santa Cruz Biotechnology, Santa Cruz, CA, USA, 1:1000) and an anti- β -actin antibody (Chemicon, Temecula, CA, USA, 1:3000).

Confocal Microscopy

Immunofluorescence staining was performed according to standard procedures. Briefly, cells were fixed in methanol for 10 min at -20°C. Slides were blocked in PBS/10% BSA/1% normal goat serum for 30 min at 21°C and were incubated for 90 min at 21°C with mouse monoclonal anti-HuR antibody diluted 1:100 in PBS/1% BSA, followed by incubation with a Cy3-conjugated anti-mouse antibody (Dianova, Hamburg, Germany) diluted 1:200 in PBS/1% BSA. Cell nuclei were counterstained with DAPI (1:1000). Confocal laser scanning microscopy was performed using a Leica confocal microscope.

Statistical Analysis

The statistical significance of the association between expression of HuR and several clinicopathological parameters as well as COX-2 was assessed by Fisher's exact test, χ^2 test or χ^2 test for trends, as indicated. The probability of overall survival as a function of time was determined by the Kaplan-Meier method and the log rank test. Generally, *P*-values smaller than 0.05 were considered significant. For the statistical evaluation the SPSS software Version 11.0 was used.

Results

Expression of HuR in Colorectal Cancer Cell Lines

We investigated HuR expression in seven colorectal cancer cell lines (SW480, Caco-2, SW707, HT-29, HRT-18, CX-2, LoVo) using RT-PCR and Western Blot. In Western Blot analysis, all cell lines showed positivity for HuR protein (Figure 1a). Similarly, we found an expression of HuR mRNA by RT-PCR in all cell lines (Figure 1b). As HuR has been suggested to be a predominantly nuclear protein, we investigated the cellular localization in HT-29 cells by confocal immunofluorescent microscopy. As shown in Figure 1c, HuR showed a predominantly nuclear expression in these cells, with only a very faint cytoplasmic staining.

Clinical and Pathological Characteristics of Patients with Colorectal Adenocarcinomas

Tumor samples of 106 patients were investigated for COX-2 expression. Clinicopathological parameters are shown in Table 1. The mean age of these patients was 66 years (range 42–87 years). 52 patients (49%) were female, the majority of tumors were diagnosed in tumor stage pT3 (65 cases, 61%). 28 cases (26%) were pT2 and the remaining cases were pT1 (six cases, 6%) or pT4 (seven cases, 7%). Most carcinomas (78%) were moderately differentiated, while 17% were poorly differentiated and 5% were well differentiated.

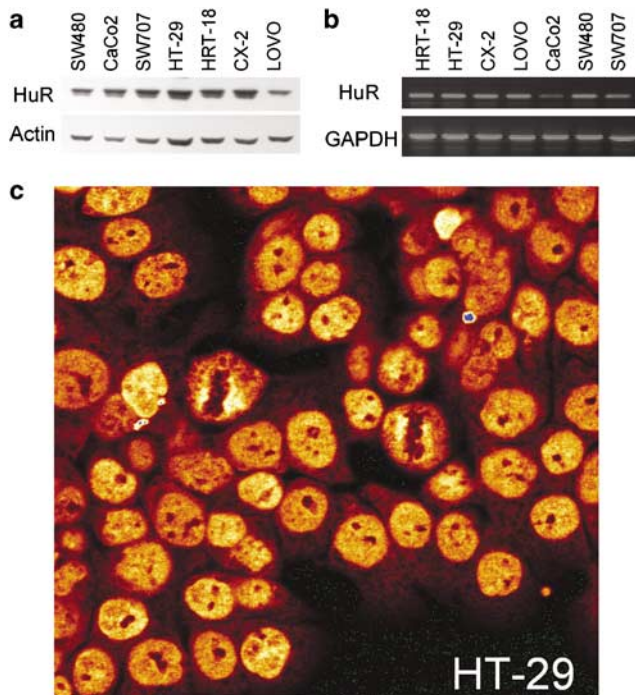


Figure 1 Expression of HuR protein in seven human colon cancer cell lines cell lines investigated by Western blot (a) and RT-PCR (b). On the protein and mRNA level, HuR was expressed in all cell lines. Using confocal laser-scanning microscopy, HuR was found to be predominantly located in the nucleus in HT-29 cells (c).

In all, 67 patients (63%) had no lymph node metastasis (pN0), while 20 patients (19%) had metastases in 1–3 lymph nodes (pN1) and 19 patients (18%) had at least four positive nodes (pN2). For determination of HuR expression, a total of 87 cases have been investigated. The distribution of the clinico-pathological parameters was comparable to the samples investigated for COX-2.

COX-2 and HuR Protein Expression in Human Colorectal Adenocarcinomas

As shown in Table 2, 67 cases (63%) were positive for COX-2 (IRS 7–12). COX-2 expression was observed as a peri-nuclear enhanced granular cytoplasmic staining (Figure 2a). COX-2 expression was increased in carcinoma tissue compared to adjacent normal mucosa (Figure 2b).

For HuR, we observed two different staining patterns. In line with the observation in cell culture that HuR is a predominantly nuclear protein, a nuclear staining was observed in 85 cases (98%) of the primary colorectal carcinomas (Table 2, Figure 2e, f). In addition to this nuclear staining, a cytoplasmic staining of HuR was observed in a subset of 46 (53%) carcinomas (Table 2, Figure 2c, d). As it has been suggested that HuR may serve as a nuclear shuttling protein, we hypothesized that the intracellular distribution of HuR in tumor tissue

Table 2 Expression of COX-2 and HuR (cytoplasmic and nuclear) in colorectal adenocarcinomas

	Number of cases (%)
<i>COX-2 expression (n = 106)</i>	
Negative	39 (36.8%)
Positive	67 (63.2%)
<i>Cytoplasmic HuR expression (n = 87)</i>	
Negative	41 (47.1%)
Positive	46 (52.9%)
<i>Nuclear HuR expression (n = 87)</i>	
Negative	2 (2.3%)
Positive	85 (97.7%)

may be critical for its function in the interaction with AU-rich elements and its mRNA stabilizing activity. Therefore, the cytoplasmic and the nuclear staining were investigated separately in all cases and a separate statistical analysis was performed.

To investigate the expression pattern of HuR in normal colon tissue, we studied 14 cases of normal colon mucosa. All cases showed a nuclear, but no cytoplasmic expression of HuR. This suggests that the cytoplasmic expression observed in some of the carcinomas is an indicator of a dysregulation of HuR in carcinoma tissue.

Association between Cytoplasmic HuR Immunostaining and COX-2 Expression as well as Other Clinical and Pathological Parameters

In the statistical analysis, we studied associations between cytoplasmic HuR expression and expression of COX-2 as well as various clinical pathological factors (Table 3). We observed a significant correlation between cytoplasmic HuR expression and expression of COX-2 ($P=0.015$, Fisher's exact test, Table 3, Figure 3a). In contrast, there was no significant association between nuclear expression of HuR and COX-2 (data not shown). Cytoplasmic but not nuclear expression of HuR was correlated with increased Duke's stage ($P=0.028$, χ^2 test for trends, Table 3, Figure 3b). Similar correlations were observed for the AJCC staging system (Table 3). Furthermore, we found a decreased cytoplasmic expression of HuR in the subtype of mucinous adenocarcinomas ($P=0.041$, Fisher's test, Table 3). We did not observe any association between HuR expression and histological grade (Table 3) as well as with other clinico-pathological parameters such as nodal status, lymphangiosis, venous invasion (not shown).

For COX-2 expression, we investigated the association of COX-2 with all clinical pathological parameters. We did not find any positive correlation between increased COX-2 expression and any clinico-pathological parameter (data not shown).

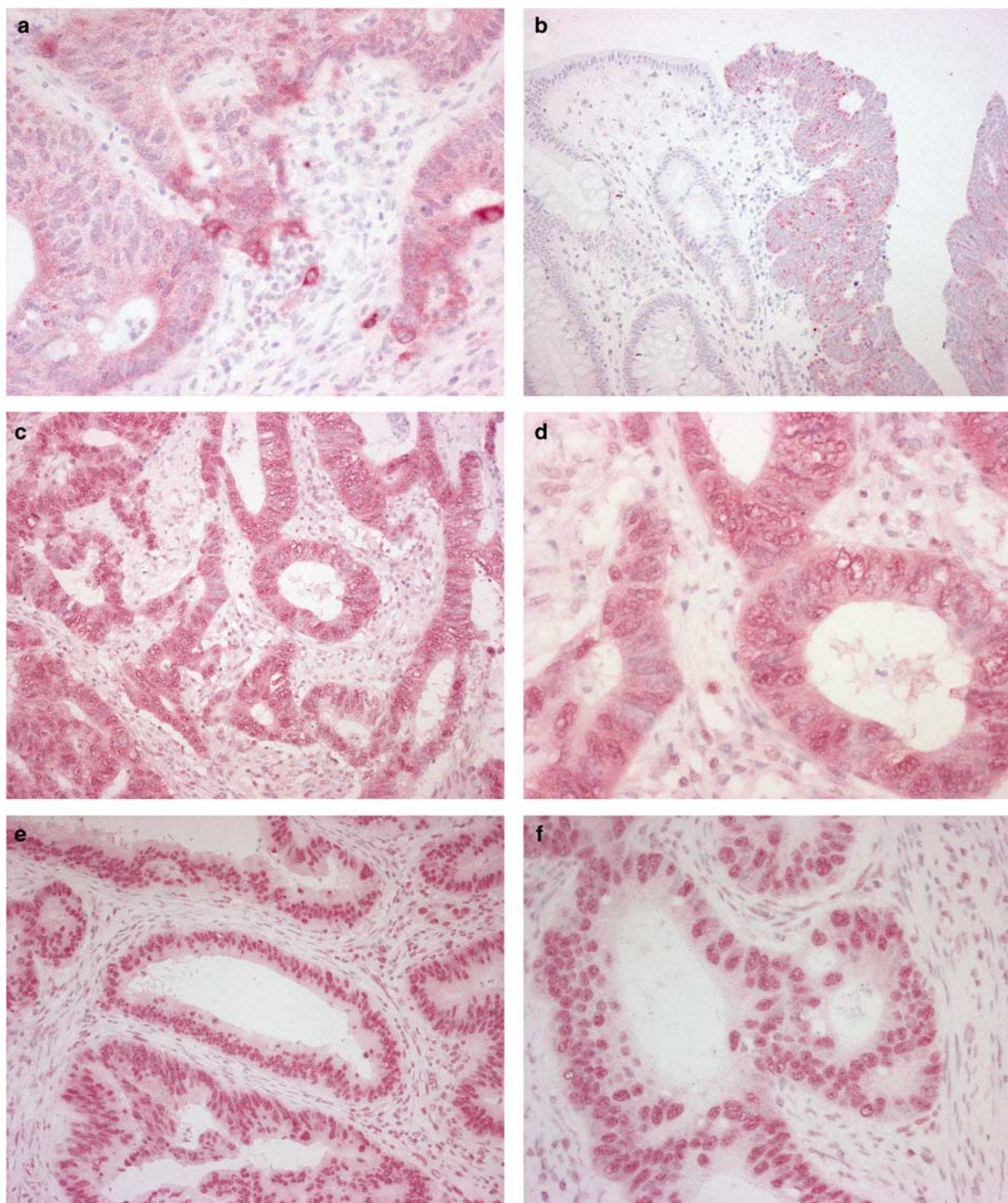


Figure 2 Expression of COX-2 and HuR in colorectal cancer as investigated by immunohistochemistry. COX-2 expression in a moderately differentiated colon cancer (**a**). In contrast, normal colon mucosa is negative for COX-2 (**b**). Cytoplasmic (**c**, **d**) and nuclear (**e**, **f**) expression of HuR in colon carcinomas.

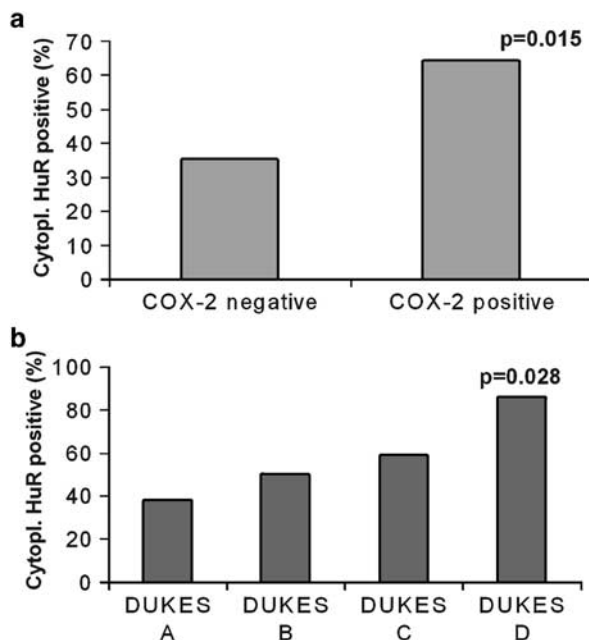
Survival Analysis

As we observed a significant association between HuR and tumor stage, we investigated whether this association would translate into a prognostic effect of overexpression of HuR. In univariate survival analysis of overall survival of all patients with

colorectal adenocarcinomas, we did not observe any prognostic impact of expression of nuclear or cytoplasmic HuR or of COX-2 expression. In contrast, the known prognostic factors of colorectal carcinoma like nodal status, tumor stage or tumor grade were prognostic factors in our study cohort as well (Figure 4). In a multivariate survival analysis

Table 3 Association of cytoplasmic HuR expression with COX-2 expression and selected clinicopathological factors in patients with colorectal adenocarcinoma

Characteristic	All cases	HuR cytoplasmic negative	HuR cytoplasmic positive	Significance
All carcinomas	87 (100%)	41 (47.1%)	46 (52.9%)	
<i>COX-2</i> expression				0.015 ^a
Negative	34 (100%)	22 (64.7%)	12 (35.3%)	
Positive	53 (100%)	19 (35.8%)	34 (64.2%)	
<i>Histological type</i>				0.041 ^a
Adenocarcinoma	77 (100%)	33 (42.9%)	44 (57.1%)	
Mucinous adenocarcinoma	10 (100%)	8 (80.0%)	2 (20.0%)	
<i>DUKES stage</i>				0.028 ^b
A	21 (100%)	13 (61.9%)	8 (38.1%)	
B	30 (100%)	15 (50.0%)	15 (50.0%)	
C	29 (100%)	12 (41.4%)	17 (58.6%)	
D	7 (100%)	1 (14.3%)	6 (85.7%)	
<i>AJCC stage</i>				0.039 ^b
I	23 (100%)	14 (60.9%)	9 (39.1%)	
II	29 (100%)	14 (48.3%)	15 (51.7%)	
III	28 (100%)	12 (42.9%)	16 (57.1%)	
IV	7 (100%)	1 (14.3%)	6 (85.7%)	
<i>Histological grade</i>				NS ^b
G1	5 (100%)	3 (60.0%)	2 (40.0%)	
G2	67 (100%)	31 (46.3%)	36 (53.7%)	
G3	15 (100%)	7 (46.7%)	8 (53.3%)	

^aFisher test two sided.^b χ^2 test for trends.**Figure 3** Association of cytoplasmic HuR expression and COX-2 expression (a, $P=0.015$, Fisher's exact test) as well as Dukes stage (b, $P=0.028$, χ^2 test for trends).

using a COX regression model, patient age, nodal status as well as metastasis were independent variables, while tumor stage and grading were not significant (data not shown).

Discussion

In this study, we investigated the expression of the human ELAV-like protein HuR as well as expression of COX-2 in human colorectal carcinomas and colon cancer cell lines. In our cell culture studies, we found that HuR is expressed in colorectal cancer cell lines with a predominantly nuclear expression. Based on these cell culture data on the function of HuR, we have systematically evaluated the cellular distribution of HuR in primary colorectal adenocarcinomas and found an increased cytoplasmic expression of HuR in 53% of cases. We observed a strong association between increased cytoplasmic expression of HuR and increased COX-2 expression in colon carcinoma tissue. Furthermore, we found that increased expression of HuR was significantly associated with more advanced cases of colon cancer.

To our knowledge, this is the first study investigating expression of HuR and its association with COX-2 and clinicopathological parameters in a large cohort of primary human colorectal adenocarcinomas. Furthermore, HuR is the first example of an mRNA stabilizing protein that is involved in progression of colon cancer.

Lopez de Silanes *et al*¹⁷ have investigated expression of HuR in 15 cases of normal and neoplastic colon tissue. In agreement with our observations, they found a significant increase of cytoplasmic HuR in carcinomas compared to adenomas and

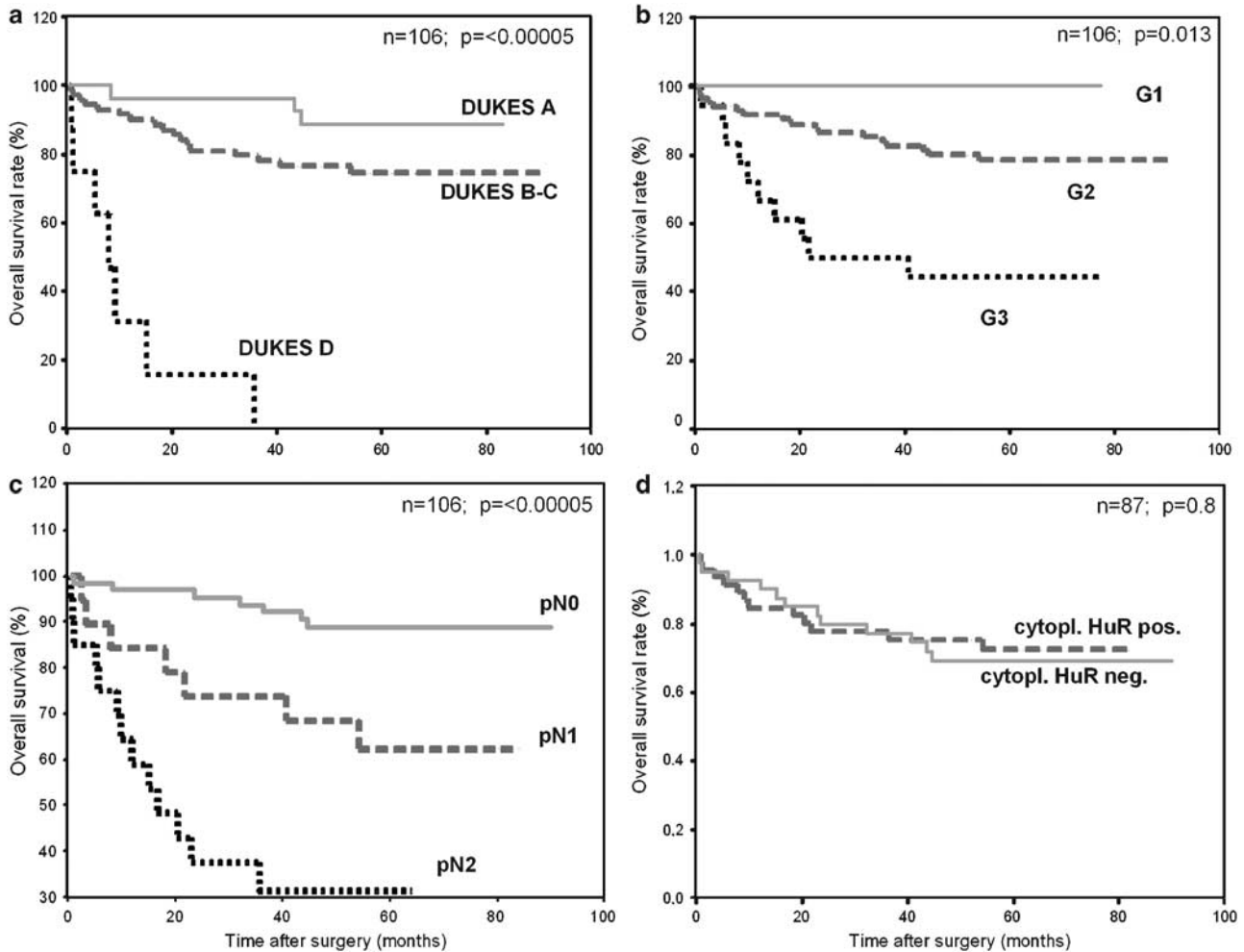


Figure 4 Kaplan–Meier univariate survival analysis according to Dukes stage (a), grading (b), nodal status (c) and cytoplasmic HuR (d). In contrast to the established clinicopathological prognostic parameters, cytoplasmic HuR is no prognostic marker.

normal colon mucosa. In addition, tumor growth of colorectal tumor cells in a mouse model was increased by elevated expression of HuR.¹⁷ Several previous studies have characterized HuR as a nuclear shuttling protein involved in cytoplasmic export and stabilization of mRNA and have shown in different cell culture models that HuR and COX-2 are causally related *in vitro*. In addition to COX-2, other mRNAs such as the mRNA of the angiogenic factor VEGF,^{18,19} the protein kinase C substrate Marcks²⁰ and various cytokines²¹ are regulated by HuR. These target proteins are products of immediate early genes that are involved in inflammation and stress response.

From the combination of the results of our study together with previous cell culture investigations and the animal experiments a complex model of HuR in colorectal cancer is emerging, that suggests that a dysregulation of mRNA stabilization by increased cytoplasmic expression of HuR might lead to increased cell proliferation and increased expression of mRNA involved in tumor-associated inflammation and angiogenesis. In this model, HuR

would play a central role in this network, which would make it an interesting target for future therapeutic approaches.

In other types of cancer, we and others have shown in recent studies that HuR is increased in breast cancer,^{22,23} ovarian cancer,^{15,24} glioblastoma multiforme and medulloblastoma²⁵ as well as in lung carcinoma cell lines.²⁶

In our study, we found that COX-2 is increased in a subset of colorectal adenocarcinomas. Based on similar results by other groups^{27–29} as well as on the results of epidemiologic^{30,31} and *in vitro* cell culture studies, inhibitors of COX-2 have been regarded as one of the most promising potential new therapeutic options for malignant tumors.^{32,33} These substances have been shown to reduce tumor growth in various *in vitro* studies as well as *in vivo* animal experiments.³⁴ They have been approved for long-term prophylaxis of adenomas and carcinomas in patients with familial adenomatous polyposis (FAP).³⁵

However, data from several recent clinical studies investigating chemopreventive approaches suggests

that as least some COX-2 inhibitors have significant side effects related to cardiovascular toxicity.^{36,37} These results have been discouraging for the use of COX-2 inhibitors for chemoprevention in populations with low to moderate risk of colon cancer. However, there might be other indications for the use of COX-2 inhibitors as an adjuvant treatment for patients with advanced colorectal cancer. For these patients there are currently only a limited number of therapeutic options so that for certain groups of patients with low cardiovascular risk the incorporation of COX-2 inhibitors in an adjuvant combination therapy might be considered. Owing to the side effects it is mandatory to restrict administration of COX-2 inhibitors to those subgroups of patients that may have benefit from the therapy. As a consequence of the reports on adverse effects of some COX-2 inhibitors, research efforts should be increased to develop predictive markers for therapy response to COX inhibitors. In addition to COX-2, HuR might be tested as an additional putative predictive marker to identify those tumors that show an increased expression of COX-2 based on a dysregulation of mRNA stability. These approaches would lead to an individualized therapy using all possible treatment options based on assessment of the prognosis of the individual patient as well as on predictive markers in tumor tissue.

As a conclusion, the cytoplasmic expression of HuR may be part of a regulatory pathway that controls the mRNA stability of several important targets. One of these targets is cyclooxygenase-2. Based on our results, further studies are necessary to investigate the regulatory network control of HuR and to investigate whether HuR might be a predictive marker as well as a potential target for molecular tumor therapy.

References

- Jemal A, Murray T, Ward E, *et al*. Cancer statistics, 2005. *CA Cancer J Clin* 2005;55:10–30.
- Fearon ER, Vogelstein B. A genetic model for colorectal tumorigenesis. *Cell* 1990;61:759–767.
- Wajed SA, Laird PW, DeMeester TR. DNA methylation: an alternative pathway to cancer. *Ann Surg* 2001;234:10–20.
- Sager R. Expression genetics in cancer: shifting the focus from DNA to RNA. *Proc Natl Acad Sci USA* 1997;94:952–955.
- Ma W-J, Chung S, Furneaux H. The Elav-like proteins bind to AU-rich elements and to the poly(A) tail of mRNA. *Nucleic Acids Res* 1997;25:183564–183569.
- Ma W-J, Cheng S, Campbell C, *et al*. Cloning and Characterization of HuR, a Ubiquitously Expressed Elav-like Protein. *J Biol Chem* 1996;271:148144–148151.
- Keene JD. Why is Hu where? Shuttling of early-response-gene messenger RNA subsets. *Proc Natl Acad Sci USA* 1999;96:5–7.
- Nabors L, Furneaux H, King P. HuR, a novel target of anti-Hu antibodies, is expressed in non-neural tissues. *J Neuroimmunol* 1998;92:152–159.
- Good PJ. The role of elav-like genes, a conserved family encoding RNA-binding proteins, in growth and development. *Sem Cell Develop Biol* 1997;8:577–584.
- Fan XC, Steitz JA. Overexpression of HuR, a nuclear-cytoplasmic shuttling protein, increases the *in vivo* stability of ARE-containing mRNAs. *EMBO J* 1998;17:3448–3460.
- Peng SS, Chen CY, Xu N, *et al*. RNA stabilization by the AU-rich element binding protein, HuR, an ELAV protein. *EMBO J* 1998;17:3461–3470.
- Dixon DA, Kaplan CD, McIntyre TM, *et al*. Post-transcriptional control of cyclooxygenase-2 gene expression. The role of the 3'-untranslated region. *J Biol Chem* 2000;275:11750–11757.
- Dixon DA, Tolley ND, King PH, *et al*. Altered expression of the mRNA stability factor HuR promotes cyclooxygenase-2 expression in colon cancer cells. *J Clin Invest* 2001;108:1657–1665.
- Remmele W, Stegner HE. Recommendation for uniform definition of an immunoreactive score (IRS) for immunohistochemical estrogen receptor detection (ER-ICA) in breast cancer tissue. *Pathologie* 1987;3:138–140.
- Denkert C, Weichert W, Pest S, *et al*. Overexpression of the embryonic-lethal abnormal vision-like protein HuR in ovarian carcinoma is a prognostic factor and is associated with increased cyclooxygenase 2 expression. *Cancer Res* 2004;64:189–195.
- Denkert C, Kobel M, Pest S, *et al*. Expression of cyclooxygenase 2 is an independent prognostic factor in human ovarian carcinoma. *Am J Pathol* 2002;160:893–903.
- Lopez de Silanes I, Fan J, Yang X, *et al*. Role of the RNA-binding protein HuR in colon carcinogenesis. *Oncogene* 2003;22:7146–7154.
- Levy NS, Chung S, Furneaux H, *et al*. Hypoxic stabilization of vascular endothelial growth factor mRNA by the RNA-binding protein HuR. *J Biol Chem* 1998;273:6417–6423.
- Nabors LB, Suswam E, Huang Y, *et al*. Tumor necrosis factor alpha induces angiogenic factor up-regulation in malignant glioma cells: a role for RNA stabilization and HuR. *Cancer Res* 2003;63:4181–4187.
- Wein G, Rossler M, Klug R, *et al*. The 3'-UTR of the mRNA coding for the major protein kinase C substrate MARCKS contains a novel CU-rich element interacting with the mRNA stabilizing factors HuD and HuR. *Eur J Biochem* 2003;270:350–365.
- Suswam EA, Nabors LB, Huang Y, *et al*. IL-1beta induces stabilization of IL-8 mRNA in malignant breast cancer cells via the 3' untranslated region: Involvement of divergent RNA-binding factors HuR, KSRP and TIAR. *Int J Cancer* 2005;113:911–919.
- Denkert C, Weichert W, Winzer KJ, *et al*. Expression of the ELAV-like protein HuR is associated with higher tumor grade and increased cyclooxygenase-2 expression in human breast carcinoma. *Clin Cancer Res* 2004;10:5580–5586.
- Heinonen M, Bono P, Narko K, *et al*. Cytoplasmic HuR expression is a prognostic factor in invasive ductal breast carcinoma. *Cancer Res* 2005;65:2157–2161.
- Erkinheimo TL, Lassus H, Sivula A, *et al*. Cytoplasmic HuR expression correlates with poor outcome and

- with cyclooxygenase 2 expression in serous ovarian carcinoma. *Cancer Res* 2003;63:7591–7594.
- 25 Nabors LB, Gillespie GY, Harkins L, *et al*. HuR, a RNA stability factor, is expressed in malignant brain tumors and binds to adenine- and uridine-rich elements within the 3' untranslated regions of cytokine and angiogenic factor mRNAs. *Cancer Res* 2001;61:2154–2161.
- 26 Blaxall BC, Dwyer-Nield LD, Bauer AK, *et al*. Differential expression and localization of the mRNA binding proteins, AU-rich element mRNA binding protein (AUF1) and Hu antigen R (HuR), in neoplastic lung tissue. *Mol Carcinog* 2000;28:76–83.
- 27 Eberhart CE, Coffey RJ, Radhika A, *et al*. Up-regulation of cyclooxygenase 2 gene expression in human colorectal adenomas and adenocarcinomas. *Gastroenterology* 1994;107:1183–1188.
- 28 Sano H, Kawahito Y, Wilder RL, *et al*. Expression of cyclooxygenase-1 and -2 in human colorectal cancer. *Cancer Res* 1995;55:3785–3789.
- 29 Maekawa M, Sugano K, Sano H, *et al*. Increased expression of cyclooxygenase-2 to -1 in human colorectal cancers and adenomas, but not in hyperplastic polyps. *Jpn J Clin Oncol* 1998;28:421–426.
- 30 Thun MJ, Namboodiri MM, Calle EE, *et al*. Aspirin use and risk of fatal cancer. *Cancer Res* 1993;53:1322–1327.
- 31 Thun MJ, Namboodiri MM, Heath CW. Aspirin use and reduced risk of fatal colon cancer. *N Engl J Med* 1991;325:1593–1596.
- 32 Tsujii M, Kawano S, DuBois RN. Cyclooxygenase-2 expression in human colon cancer cells increases metastatic potential. *Proc Natl Acad Sci USA* 1997;94:3336–3340.
- 33 Thun MJ, Henley SJ, Patrono C. Nonsteroidal anti-inflammatory drugs as anticancer agents: mechanistic, pharmacologic, and clinical issues. *J Natl Cancer Inst* 2002;94:252–266.
- 34 Taketo MM. Cyclooxygenase inhibitors in tumorigenesis (Part II). *J Natl Cancer Inst* 1998;90:1609–1620.
- 35 Steinbach G, Lynch PM, Phillips RKS, *et al*. The effect of celecoxib, a cyclooxygenase-2 inhibitor, in familial adenomatous polyposis. *N Engl J Med* 2000;342:1946–1952.
- 36 Solomon SD, McMurray JJ, Pfeffer MA, *et al*. Adenoma Prevention with Celecoxib (APC) Study Investigators. risk associated with celecoxib in a clinical trial for colorectal adenoma prevention. *N Engl J Med* 2005;352:1071–1080.
- 37 Bresalier RS, Sandler RS, Quan H, *et al*. Adenomatous Polyp Prevention on Vioxx (APPROVe) Trial Investigators. Cardiovascular events associated with rofecoxib in a colorectal adenoma chemoprevention trial. *N Engl J Med* 2005;352:1092–1102.