

Corrigendum

Ezrin in primary cutaneous melanoma

Suvi Ilmonen, Antti Vaheri, Sirpa Asko-Seljavaara and Olli Carpen

Modern Pathology (2005) 18, 872. doi:10.1038/modpathol.3800429

Correction to: Modern Pathology (2005) 18, 503–510, advance online publication, 8 October 2004; doi:10.1038/modpathol.3800300

Following the publication of the above paper, the author has identified an error in part (b) of Figure 2 legend. The correct Figure 2 legend is below.

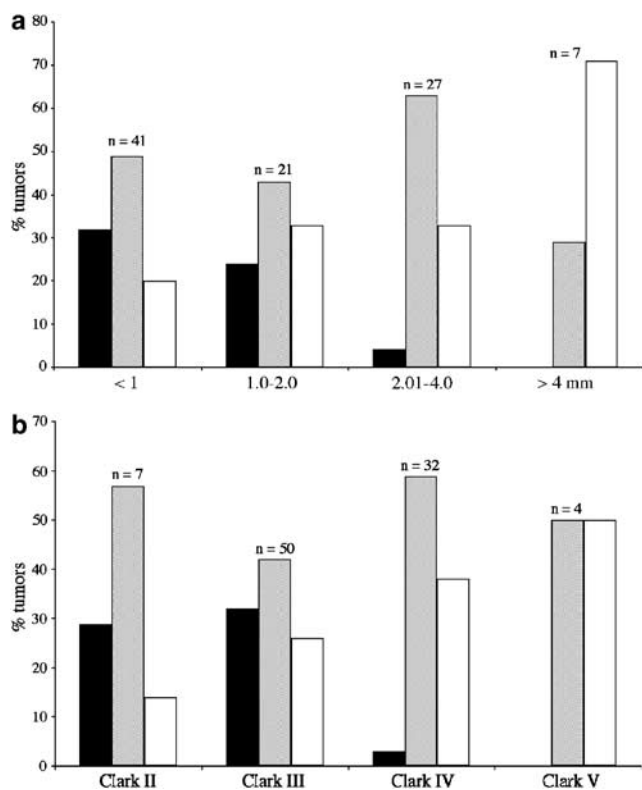


Figure 2 Correlation between ezrin immunoreactivity and melanoma thickness or invasion level. (a) Tumors were categorized according to the Breslow classification. Intensity of ezrin immunoreactivity increased with tumor thickness ($P=0.0008$). (b) Ezrin immunoreactivity was compared with Clark classification. Increased ezrin staining was seen in higher Clark categories ($P=0.004$). White bar = immunoreactivity 2; gray bar = immunoreactivity 1; black bar = immunoreactivity 0; n = number of tumors in each category.