

Expression of CD117 (c-kit) receptor in dysgerminoma of the ovary: diagnostic and therapeutic implications

Michael Sever¹, Timothy D Jones¹, Lawrence M Roth¹, Fadi W Abdul Karim², Wenxin Zheng³, Helen Michael¹, Eyas M Hattab¹, Robert E Emerson¹, Lee Ann Baldrige¹ and Liang Cheng¹

¹Department of Pathology and Laboratory Medicine, Indiana University, Indianapolis, IN, USA; ²Department of Pathology, Case Western Reserve University, Cleveland, OH, USA and ³Department of Pathology, Yale University, New Haven, CT, USA

The proto-oncogene *c-kit* encodes a tyrosine kinase receptor, c-kit (CD117), which has been implicated in the development of a number of human malignancies. While the preferential expression of this protein has been well documented in testicular seminomas, there is little data concerning its expression in dysgerminomas of the ovary. We examined the expression of c-kit in 30 cases of ovarian dysgerminomas using immunohistochemical staining with a polyclonal anti-CD117 antibody. Staining was graded in a semiquantitative manner as follows: negative (no staining), 1+ (1–10% staining), 2+ (10–29% staining), 3+ (30–50% staining), or 4+ (>50% staining). Of the 30 cases examined, 26 (87%) demonstrated immunoreactivity for CD117. In total, 10 (33%) demonstrated 4+ staining; 9 (30%) demonstrated 3+ staining; 3 (10%) demonstrated 2+ staining; 4 (13%) demonstrated 1+ staining; and 4 (13%) demonstrated no staining. In conclusion, CD117 immunoreactivity was detected in 87% of ovarian dysgerminomas, a finding that correlates with previously reported frequencies of CD117 expression in seminomas (78–100%). Thus, antibodies to c-kit may be a useful diagnostic marker for ovarian dysgerminoma. Although the prognosis of patients with dysgerminoma is generally good, this receptor could potentially serve as a target for site-specific immunotherapy as an alternative and/or complement to conventional treatment options.

Modern Pathology (2005) 18, 1411–1416. doi:10.1038/modpathol.3800463; published online 22 July 2005

Keywords: ovary; germ cell tumors; c-kit (CD117); differential diagnosis; OCT4; dysgerminoma

The proto-oncogene *c-kit* encodes a 145–160 kDa, type III transmembrane tyrosine kinase receptor known as c-kit or CD117,^{1,2} which belongs to the same family of receptors as platelet-derived growth factor and colony-stimulating factor-1.³ The binding of stem cell factor, the ligand for this receptor, leads to the dimerization of c-kit proteins, thus initiating a signaling cascade that ultimately induces cell growth.¹ Expression of c-kit is essential in the development of some cell types, including melanocytes, germ cells, mast cells, erythrocytes, and interstitial cells of Cajal.^{1,4–6} In addition, expression of this receptor may be seen in other histologically

normal cell types, such as breast epithelial cells, renal tubule cells, astrocytes, Purkinje cells, parotid acini, and endometrial cells.^{6–8} Aberrant expression of this receptor, however, has been implicated in the development of a number of human cancers, including malignancies of the lung, skin, breast, uterus, endometrium, urinary bladder, and ovary, as well as in certain types of leukemia, Ewing tumor, gastrointestinal stromal tumors (GISTs), and germ cell tumors.^{8–28} The advent of therapies targeted to c-kit have proven highly effective in treating some cancers that overexpress this receptor, such as chronic myeloid leukemia and GISTs.^{29–32}

Dysgerminoma is an uncommon primitive germ cell tumor of the ovary, comprising 0.5–5% of all ovarian malignancies.^{33–37} This tumor is histologically and biologically similar to testicular seminoma. Accurate diagnosis of dysgerminoma is important as its treatment and prognosis differ significantly from those of other ovarian tumors.^{36,38–41} Thus, an immunohistochemical marker

Correspondence: Dr L Cheng, MD, Department of Pathology and Laboratory Medicine, Indiana University Medical Center, University Hospital, Room 3465, 550 North University Boulevard, Indianapolis, IN 46202, USA.
E-mail: lcheng@iupui.edu

Received 28 December 2004; revised 31 May 2005; accepted 1 June 2005; published online 22 July 2005

sensitive for this type of tumor could serve as a useful diagnostic tool. While current therapeutic regimens consisting of chemotherapy and radiation are highly effective in eradicating the disease,^{41,42} reproductive compromise is a common side effect of treatment and is a major concern given the young age at which this tumor typically presents. The identification of cellular proteins, such as c-kit, that may be overexpressed in this tumor could potentially lead to targeted therapies with less devastating side effects. While aberrant expression of c-kit has been well documented in testicular seminoma,^{2,5,11,13,14,43–46} little data concerning its expression in ovarian dysgerminoma are available. Therefore, we analyzed the immunohistochemical expression of c-kit in 30 cases of dysgerminoma of the ovary.

Materials and methods

In all, 30 cases of dysgerminoma of the ovary accessioned from 1982 to 2002 were retrieved from the surgical pathology files of three institutions: Indiana University Medical Center (Indianapolis, IN, USA), University Hospitals of Cleveland (Cleveland, OH, USA), and Yale University (New Haven, CT, USA). Medical records for the cases were reviewed. Formalin-fixed paraffin-embedded tissue specimens were available for all cases. Sections (4 μ m thick) were cut from paraffin blocks and stained with hematoxylin and eosin for microscopic examination. Pathologic staging was performed according to the FIGO staging system for ovarian neoplasms.⁴⁷ This research was approved by the Institutional Review Boards in accordance with the Institutional Committee for the Protection of Human Subjects (Figure 1).

Additional paraffin sections of selected blocks were obtained for immunohistochemical studies, which were performed on an automated immunostainer. Immunohistochemical staining was performed with the avidin–biotin complex method of Hsu *et al.*^{48,49} In brief, serial 4- μ m-thick sections of formalin-fixed, paraffin-embedded tissue samples were used for the studies. Slides were deparaffinized twice in xylene for 5 min and rehydrated through graded ethanol solutions to distilled water. Antigen retrieval was performed by heating sections in citrate buffer (DAKO Target Retrieval Solution S1699, DAKO corporation, Carpinteria, CA, USA) for 15 min. Inactivation of endogenous peroxidase activity was achieved by incubation in 3% H₂O₂ for 15 min. Nonspecific binding sites were bound using Protein Block (DAKO) for 20 min. Tissue sections were then incubated with the purified rabbit polyclonal antibody against the C-terminus of the p145 human c-kit protein (IgG, 1:50 dilution; Oncogene, Boston, MA, USA) for 30 min at room temperature. This was followed by biotinylated secondary antibody (DAKO) and peroxidase-labeled streptavidin.

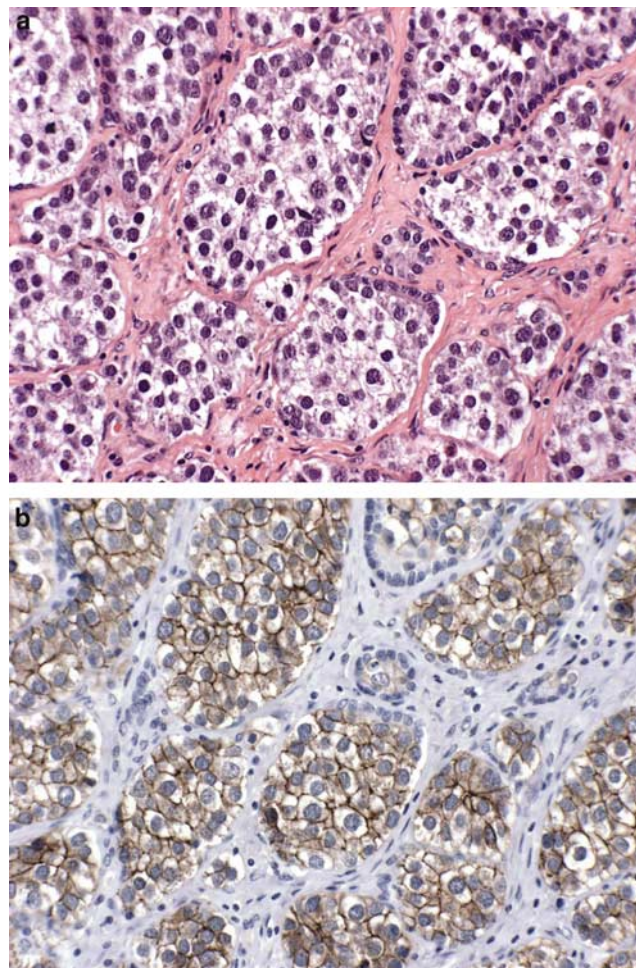


Figure 1 Dysgerminoma of the ovary (a). Positive membranous c-kit immunostaining was noted (b).

The chromogen 3,3-diaminobenzidine was used in the presence of hydrogen peroxide. Sections from GISTs were used as positive controls. Negative controls were performed using blocking serum in place of primary antibody. Positive and negative controls were run in parallel with each batch, and appropriate results were obtained.

The expression of c-kit was evaluated in a semiquantitative manner as follows: no staining (0), 1–10% staining (1+), 11–29% (2+), 30–50% (3+), and greater than 50% (4+). Given that c-kit is a membrane-bound tyrosine kinase receptor, only membranous staining pattern was considered positive.⁵⁰

Results

The 30 patients examined had a mean age of 22 years (range of 6–50 years). In all, 21 of the patients (70%) presented with stage Ia or Ib disease; two (7%) presented with stage IIa disease; and seven (23%) presented with more advanced disease (stage

IIIb or IIIc). Five of the patients (17%) were found to have lymph node metastasis at presentation. Tumor sizes ranged from 2.5 to 21 cm in greatest dimension. Of 30 cases, 26 (87%) demonstrated positive staining with antibodies to c-kit. In all, 10 (33%) showed diffuse staining (> 50%), while nine (30%) demonstrated 30–50% staining. Three cases (10%) showed 11–29% staining and four cases (13%) showed 1–10% staining. Only four of 30 cases (13%) were immunohistochemically negative for c-kit. There was no statistically significant correlation between c-kit staining and pathologic stage or tumor size, as summarized in Table 1. Two lymph nodes from two patients with metastatic disease demonstrated strong c-kit reactivity.

Discussion

The expression of c-kit (CD117) has been demonstrated in a wide variety of human malignancies, including those of the lung, breast, endometrium, gastrointestinal tract, urinary bladder, and hematopoietic system.^{1,2,4–15,17–28,43–46} In addition, c-kit has also been shown to be overexpressed in specific types of malignant germ cell tumors, such as seminoma.^{2,5,11,13,14,43–46} Dysgerminoma of the ovary is a neoplasm that is histologically, biologically, and clinically similar to testicular seminoma. While, the immunohistochemical expression of the transmembrane receptor c-kit in seminoma has been well documented, its expression in dysgerminoma has not been extensively explored. In this study, we analyzed 30 cases of ovarian dysgerminoma with anti-c-kit antibodies and found that, like seminoma, these tumors frequently (87%) exhibit immunoreactivity for c-kit.

The accurate diagnosis of dysgerminoma is of critical importance as the therapy and prognosis for these patients is significantly different from that of other ovarian malignancies.³⁷ Dysgerminoma has a better prognosis than other malignant ovarian tumors, as it is highly sensitive to cisplatin- or carboplatin-based chemotherapy and to radiotherapy.^{39,42,51,52} Cure rates approach 95% with treatment strategies employing adjuvant chemotherapy, even in advanced metastatic disease.^{14,33–41}

Histologically, the differential diagnosis for dysgerminoma includes other germ cell tumors, most notably the solid variants of yolk sac tumor and embryonal carcinoma, as well as clear-cell adenocarcinoma, granulosa cell tumor, lymphoma, and metastatic tumors, such as melanoma. Immunohistochemical stains can often aid in discriminating between these morphologically similar lesions. Immunostaining for placental-like alkaline phosphatase in the ovary, although relatively specific for dysgerminoma, can show positivity in other types of primitive germ cell tumors, as well as in benign germ cells.⁵³ Cytokeratins can show focal staining in dysgerminoma.⁵⁴ OCT4 has recently been shown to

be a sensitive and relatively specific biomarker for the detection of dysgerminoma, although focal staining in clear-cell adenocarcinoma has been noted.⁵⁵ Likewise, stains for c-kit may prove to be a useful diagnostic tool in histologically difficult cases of dysgerminoma.

Previous studies demonstrating expression of c-kit in ovarian tumors, let alone dysgerminoma in particular, have included only small numbers of cases. In a broad study of c-kit expression in numerous tumors, Went *et al* demonstrated that dysgerminoma (two cases) and gonadoblastoma (one case) both demonstrate c-kit expression. Additionally, Brenner tumor (33% staining), cervical adenocarcinoma (33% staining), and, less frequently, ovarian carcinoma, cervical squamous carcinoma, and vulvar carcinoma all demonstrate minimal c-kit expression.⁵⁰ Klein *et al*⁵⁶ demonstrated the lack of c-kit expression in ovarian mesenchymal tumors, including leiomyosarcoma, carcinosarcoma, endometrial stromal tumors and clear-cell ovarian sarcoma. Similarly, Raspollini *et al*⁵⁷ demonstrated that 51% of advanced ovarian serous carcinoma demonstrated c-kit expression. Schmandt *et al*⁹ found that low-grade serous carcinoma of the ovary demonstrated no c-kit expression, and only 26% of high-grade serous tumors showed some reactivity. Ramalingam *et al*⁵⁸ recently reported that yolk sac tumors of the ovary, often included in the differential diagnosis of dysgerminoma, demonstrated no c-kit expression.

Natali *et al*⁶ investigated c-kit expression in a number of benign and malignant neoplasms using immunohistochemistry, including a single case of dysgerminoma, which was found to be immunoreactive for c-kit. Tsuura *et al*⁵ similarly investigated c-kit expression in 884 solid tumors and found c-kit positivity in three of four (75%) dysgerminomas. Sakuma *et al*⁵⁹ studied 16 intracranial germinomas and found membranous c-kit immunoreactivity in the majority of tumor cells from all cases.

Our study of 30 cases of ovarian dysgerminoma is, to our knowledge, the largest series of cases to be analyzed for c-kit expression. Our finding of c-kit positivity in 87% of dysgerminoma suggests that this marker may serve as a useful marker for dysgerminoma, especially when other germ cell tumors and clear-cell adenocarcinoma fall in the differential diagnosis.

Those cases that failed to exhibit c-kit expression may actually represent heterologous expression of the receptor in each tumor or variance among individuals. Review of the hematoxylin and eosin-stained sections revealed no morphologic qualities that served as a predictor of c-kit status, although areas of necrosis did fail to highlight with the antibody. Technical inadequacy may also serve as a less likely explanation. The stage of disease at presentation, too, was not a statistically significant predictor of c-kit expression. Of the cases that failed to show c-kit reactivity, all demonstrated strong

OCT4 expression, as reported previously, which may serve as an alternative marker in those cases that fail to show c-kit reactivity.⁵⁵ We should emphasize that OCT4 is also positive in embryonal carcinoma and clear-cell adenocarcinoma of the ovary;^{55,60–62} therefore, its utility in the differential diagnosis of these tumors is limited. Furthermore, embryonal carcinoma has been noted to rarely demonstrate c-kit expression.⁴⁴

With the advent of c-kit-targeted therapy with imatinib mesylate (Gleevec; Novartis), and the proven success of this drug in the treatment of chronic myelogenous leukemia (CML) and GIST,^{29–32} c-kit expression may no longer be merely of diagnostic relevance but may also have therapeutic significance. Anti-c-kit compounds have been shown in *in vitro* and *in vivo* studies to inhibit effectively receptor autophosphorylation and subsequent MAP kinase activity and Akt activation.¹⁶ The responsiveness of tumors to imatinib mesylate has been shown to correlate with specific *c-kit* gene mutations rather than with immunohistochemical expression.^{50,63} Therefore, c-kit positivity on immunostaining does not necessarily indicate that a patient's tumor will respond to therapy targeted against c-kit. A number of *c-kit* mutations have been identified in GISTs in exons 9, 11, 13, and 17, resulting in a protein product with constitutive kinase activity.^{15,16,64,65} Tian *et al*² discovered a novel missense mutation (D816H) in the phosphotransferase domain of the *c-kit* gene in tumors of seminoma/dysgerminoma type, providing the first evidence that the c-kit signal transduction cascade may be important in the pathogenesis of these neoplasms as well. Subsequently, Przygodzki *et al*⁶⁶ and Sakuma *et al*⁴³ identified *c-kit* gene mutations in primary mediastinal seminomas and testicular seminomas, respectively. Kemmer *et al*⁶⁷ examined the frequency and spectrum of *c-kit* gene mutations in 54 testicular seminomas, one ovarian dysgerminoma, and 37 nonseminomatous germ cell tumors and found *c-kit* mutations in 26% of seminomas. Neither the single dysgerminoma nor any of the nonseminomatous germ cell tumors harbored a *c-kit* gene mutation. Given the histologic, biologic, and immunohistochemical similarities between seminoma and dysgerminoma, it is reasonable to speculate that some *c-kit* mutations would be discovered in dysgerminoma if more than one case were analyzed. In fact, Pauls and associates⁶⁸ studied the expression and mutational status of a pure dysgerminoma and found an exon 17 D816V mutation in the *c-kit* gene and strong immunohistochemical c-kit expression. Sakuma *et al*⁵⁹ analyzed 16 intracranial germinomas and found *c-kit* gene mutations in four cases (25%). While *c-kit* mutations have been found in dysgerminomas, it is not clear if these mutations make these tumors amenable to treatment with anti-c-kit-targeted therapies.

Dysgerminoma is highly radiosensitive, and cure rates approach 95% with adjuvant chemotherapy,

even in advanced metastatic disease.⁵¹ Reproductive difficulties following treatment are a common adverse side effect.³³ Therefore, current therapeutic development has focused on reduction in morbidity with fertility-sparing treatments.^{33–41} This is often of great concern to patients with dysgerminoma given the young mean age at presentation. Given the successful treatment of CML and GIST with imatinib mesylate, anti-c-kit compounds could prove to be an additional treatment option in patients with dysgerminoma, allowing for conservative therapy with a potentially less-devastating impact on post-treatment fertility. It has been suggested, although not rigorously proven, that tumor resistance to carboplatin-based chemotherapy may result from exon 17 *c-kit* gene mutations.⁶⁸ Similarly, Raspollini *et al*⁵⁷ demonstrated that advanced ovarian carcinoma that expressed c-kit was resistant to current chemotherapeutic regimens.

Dysgerminoma is a relatively rare malignant germ cell tumor of the ovary seen in young adults. In this study, we demonstrate that 87% of these tumors exhibit immunohistochemical expression of the transmembrane tyrosine kinase receptor c-kit (CD117), much like its male counterpart, seminoma. Thus, immunostains for c-kit may be potentially useful in distinguishing between dysgerminoma and other ovarian neoplasms. With the advent and success of c-kit-directed therapies in chronic myeloid leukemia and GIST, c-kit expression in dysgerminoma may provide a new target for conservative, fertility-sparing therapy.

References

- 1 Vliagoftis H, Worobec AS, Metcalfe DD. The proto-oncogene c-kit and c-kit ligand in human disease. *J Allergy Clin Immunol* 1997;100:435–440.
- 2 Tian Q, Frierson Jr HF, Krystal GW, *et al*. Activating *c-kit* gene mutations in human germ cell tumors. *Am J Pathol* 1999;154:1643–1647.
- 3 Yarden Y, Kuang WJ, Yang-Feng T, *et al*. Human proto-oncogene c-kit: a new cell surface receptor tyrosine kinase for an unidentified ligand. *EMBO J* 1987;6:3341–3351.
- 4 Zsebo KM, Williams DA, Geissler EN, *et al*. Stem cell factor is encoded at the Sl locus of the mouse and is the ligand for the c-kit tyrosine kinase receptor. *Cell* 1990;63:213–224.
- 5 Tsuura Y, Hiraki H, Watanabe K, *et al*. Preferential localization of c-kit product in tissue mast cells, basal cells of skin, epithelial cells of breast, small cell lung carcinoma and seminoma/dysgerminoma in human: immunohistochemical study on formalin-fixed, paraffin-embedded tissues. *Virchows Arch* 1994;424:135–141.
- 6 Natali PG, Nicotra MR, Sures I, *et al*. Expression of c-kit receptor in normal and transformed human nonlymphoid tissues. *Cancer Res* 1992;52:6139–6143.
- 7 Elmore LW, Domson K, Moore JR, *et al*. Expression of c-kit (CD117) in benign and malignant human endometrial epithelium. *Arch Pathol Lab Med* 2001;125:146–151.

- 8 Natali PG, Nicotra MR, Sures I, *et al*. Breast cancer is associated with loss of the c-kit oncogene product. *Int J Cancer* 1992;52:713–717.
- 9 Schmandt RE, Broaddus R, Lu KH, *et al*. Expression of c-ABL, c-KIT, and platelet-derived growth factor receptor-beta in ovarian serous carcinoma and normal ovarian surface epithelium. *Cancer* 2003;98:758–764.
- 10 Jorgensen N, Muller J, Jaubert F, *et al*. Heterogeneity of gonadoblastoma germ cells: similarities with immature germ cells, spermatogonia and testicular carcinoma *in situ* cells. *Histopathology* 1997;30:177–186.
- 11 Rajpert-De Meyts E, Skakkebaek NE. Expression of the c-kit protein product in carcinoma-*in-situ* and invasive testicular germ cell tumors. *Int J Androl* 1994;17:85–92.
- 12 Kollmannsberger C, Mayer F, Pressler H, *et al*. Absence of c-KIT and members of the epidermal growth factor receptor family in refractory germ cell cancer. *Cancer* 2002;95:301–308.
- 13 Looijenga LH, de Leeuw H, van Oorschot M, *et al*. Stem cell factor receptor (c-KIT) codon 816 mutations predict development of bilateral testicular germ-cell tumors. *Cancer Res* 2003;63:7674–7678.
- 14 Izquierdo MA, Van der Valk P, Van Ark-Otte J, *et al*. Differential expression of the c-kit proto-oncogene in germ cell tumours. *J Pathol* 1995;177:253–258.
- 15 Antonescu CR, Sommer G, Sarran L, *et al*. Association of KIT exon 9 mutations with nongastric primary site and aggressive behavior: KIT mutation analysis and clinical correlates of 120 gastrointestinal stromal tumors. *Clin Cancer Res* 2003;9:3329–3337.
- 16 Heinrich MC, Rubin BP, Longley BJ, *et al*. Biology and genetic aspects of gastrointestinal stromal tumors: KIT activation and cytogenetic alterations. *Hum Pathol* 2002;33:484–495.
- 17 Scobie JV, Acs G, Bandera CA, *et al*. C-kit immunoreactivity in endometrial adenocarcinomas and its clinicopathologic significance. *Int J Gynecol Pathol* 2003;22:149–155.
- 18 Rossi G, Cavazza A, Marchioni A, *et al*. Kit expression in small cell carcinomas of the lung: effects of chemotherapy. *Mod Pathol* 2003;16:1041–1047.
- 19 Burger H, den Bakker MA, Stoter G, *et al*. Lack of c-kit exon 11 activating mutations in c-KIT/CD117-positive SCLC tumour specimens. *Eur J Cancer* 2003;39:793–799.
- 20 Naeem M, Dahiya M, Clark JL, *et al*. Analysis of c-kit protein expression in small-cell lung carcinoma and its implication for prognosis. *Hum Pathol* 2002;33:1182–1187.
- 21 Micke P, Basrai M, Faldum A, *et al*. Characterization of c-kit expression in small cell lung cancer: prognostic and therapeutic implications. *Clin Cancer Res* 2003;9:188–194.
- 22 Miettinen M, Sarlomo-Rikala M, Lasota J. KIT expression in angiosarcomas and fetal endothelial cells: lack of mutations of exon 11 and exon 17 of c-kit. *Mod Pathol* 2000;13:536–541.
- 23 Yamasaki T, Shimazaki H, Aida S, *et al*. Primary small cell (oat cell) carcinoma of the breast: report of a case and review of the literature. *Pathol Int* 2000;50:914–918.
- 24 Akintola-Ogunremi O, Pfeifer JD, Tan BR, *et al*. Analysis of protein expression and gene mutation of c-kit in colorectal neuroendocrine carcinomas. *Am J Surg Pathol* 2003;27:1551–1558.
- 25 Potti A, Moazzam N, Ramar K, *et al*. CD117 (c-KIT) overexpression in patients with extensive-stage small-cell lung carcinoma. *Ann Oncol* 2003;14:894–897.
- 26 Scotlandi K, Manara MC, Strammiello R, *et al*. C-kit receptor expression in Ewing's sarcoma: lack of prognostic value but therapeutic targeting opportunities in appropriate conditions. *J Clin Oncol* 2003;21:1952–1960.
- 27 Wang L, Felix JC, Lee JL, *et al*. The proto-oncogene c-kit is expressed in leiomyosarcomas of the uterus. *Gynecol Oncol* 2003;90:402–406.
- 28 Pan CX, Yang XJ, Lopez-Beltran A, *et al*. c-kit expression in small cell carcinoma of the urinary bladder: prognostic and therapeutic implications. *Mod Pathol* 2005;18:320–323.
- 29 Joensuu H, Roberts PJ, Sarlomo-Rikala M, *et al*. Effect of the tyrosine kinase inhibitor STI571 in a patient with a metastatic gastrointestinal stromal tumor. *N Engl J Med* 2001;344:1052–1056.
- 30 Mesters RM, Padro T, Bieker R, *et al*. Stable remission after administration of the receptor tyrosine kinase inhibitor SU5416 in a patient with refractory acute myeloid leukemia. *Blood* 2001;98:241–243.
- 31 O'Dwyer ME, Druker BJ. Chronic myelogenous leukaemia—new therapeutic principles. *J Intern Med* 2001;250:3–9.
- 32 Heinrich MC, Griffith DJ, Druker BJ, *et al*. Inhibition of c-kit receptor tyrosine kinase activity by STI 571, a selective tyrosine kinase inhibitor. *Blood* 2000;96:925–932.
- 33 Mitchell MF, Gershenson DM, Soeters RP, *et al*. The long-term effects of radiation therapy on patients with ovarian dysgerminoma. *Cancer* 1991;67:1084–1090.
- 34 Zaghoul MS, Khattab TY. Dysgerminoma of the ovary: good prognosis even in advanced stages. *Int J Radiat Oncol Biol Phys* 1992;24:161–165.
- 35 LaPolla JP, Benda J, Vigliotti AP, *et al*. Dysgerminoma of the ovary. *Obstet Gynecol* 1987;69:859–864.
- 36 Gallion HH, van Nagell Jr JR, Donaldson ES, *et al*. Ovarian dysgerminoma: report of seven cases and review of the literature. *Am J Obstet Gynecol* 1988;158:591–595.
- 37 Susnerwala SS, Pande SC, Shrivastava SK, *et al*. Dysgerminoma of the ovary: review of 27 cases. *J Surg Oncol* 1991;46:43–47.
- 38 Talerma A. Germ cell tumors of the ovary. *Curr Opin Obstet Gynecol* 1997;9:44–47.
- 39 Bjorkholm E, Lundell M, Gyftodimos A, *et al*. Dysgerminoma: the Radiumhemmet series 1927–1984. *Cancer* 1990;65:38–44.
- 40 Gordon A, Lipton D, Woodruff JD. Dysgerminoma: a review of 158 cases from the Emil Novak Ovarian Tumor Registry. *Obstet Gynecol* 1981;58:497–504.
- 41 Williams SD. Ovarian germ cell tumors: an update. *Semin Oncol* 1998;25:407–413.
- 42 De Palo G, Lattuada A, Kenda R, *et al*. Germ cell tumors of the ovary: the experience of the National Cancer Institute of Milan. I. Dysgerminoma. *Int J Radiat Oncol Biol Phys* 1987;13:853–860.
- 43 Sakuma Y, Sakurai S, Oguni S, *et al*. Alterations of the c-kit gene in testicular germ cell tumors. *Cancer Sci* 2003;94:486–491.
- 44 Leroy X, Augusto D, Leteurtre E, *et al*. CD30 and CD117 (c-kit) used in combination are useful for distinguishing embryonal carcinoma from seminoma. *J Histochem Cytochem* 2002;50:283–285.

- 45 Bokemeyer C, Kuczyk MA, Dunn T, *et al*. Expression of stem-cell factor and its receptor c-kit protein in normal testicular tissue and malignant germ-cell tumours. *J Cancer Res Clin Oncol* 1996;122:301–306.
- 46 Strohmeyer T, Reese D, Press M, *et al*. Expression of the c-kit proto-oncogene and its ligand stem cell factor (SCF) in normal and malignant human testicular tissue. *J Urol* 1995;153:511–515.
- 47 Greene FL, Page DL, Fleming ID, *et al*. American Joint Committee on Cancer Staging Manual. Springer: New York, 2002.
- 48 Hsu SM, Raine L, Fanger H. The use of antiavidin antibody and avidin–biotin–peroxidase complex in immunoperoxidase techniques. *Am J Clin Pathol* 1981; 75:816–821.
- 49 Hsu SM, Raine L, Fanger H. Use of avidin–biotin–peroxidase complex (ABC) in immunoperoxidase techniques: a comparison between ABC and unlabeled antibody (PAP) procedures. *J Histochem Cytochem* 1981;29:577–580.
- 50 Went PT, Dirnhofer S, Bundi M, *et al*. Prevalence of KIT expression in human tumors. *J Clin Oncol* 2004;22:4514–4522.
- 51 Williams SD, Blessing JA, Hatch KD, *et al*. Chemotherapy of advanced dysgerminoma: trials of the Gynecologic Oncology Group. *J Clin Oncol* 1991;9: 1950–1955.
- 52 Thomas GM, Dembo AJ, Hacker NF, *et al*. Current therapy for dysgerminoma of the ovary. *Obstet Gynecol* 1987;70:268–275.
- 53 Burke AP, Mostofi FK. Placental alkaline phosphatase immunohistochemistry of intratubular malignant germ cells and associated testicular germ cell tumors. *Hum Pathol* 1988;19:663–670.
- 54 Pesce M, Wang X, Wolgemuth DJ, *et al*. Differential expression of the Oct-4 transcription factor during mouse germ cell differentiation. *Mech Dev* 1998;71: 89–98.
- 55 Cheng L, Thomas A, Roth LM, *et al*. OCT4: a novel biomarker for dysgerminoma of the ovary. *Am J Surg Pathol* 2004;28:1341–1346.
- 56 Klein WM, Kurman RJ. Lack of expression of c-kit protein (CD117) in mesenchymal tumors of the uterus and ovary. *Int J Gynecol Pathol* 2003;22:181–184.
- 57 Raspollini MR, Castiglione F, Rossi Degl’innocenti D, *et al*. Tumour-infiltrating gamma/delta T-lymphocytes are correlated with a brief disease-free interval in advanced ovarian serous carcinoma. *Ann Oncol* 2005; 16:590–596.
- 58 Ramalingam P, Malpica A, Silva EG, *et al*. The use of cytokeratin 7 and EMA in differentiating ovarian yolk sac tumors from endometrioid and clear cell carcinomas. *Am J Surg Pathol* 2004;28:1499–1505.
- 59 Sakuma Y, Sakurai S, Oguni S, *et al*. *c-kit* gene mutations in intracranial germinomas. *Cancer Sci* 2004; 95:716–720.
- 60 Cheng L. Establishing a germ cell origin for metastatic tumors using OCT4 immunohistochemistry. *Cancer* 2005;101:2006–2010.
- 61 Jones TD, Ulbright TM, Eble JN, *et al*. OCT4 staining in testicular tumors: a sensitive and specific marker for seminoma and embryonal carcinoma. *Am J Surg Pathol* 2004;28:935–940.
- 62 Looijenga LH, Stoop H, de Leeuw HP, *et al*. POU5F1 (OCT3/4) identifies cells with pluripotent potential in human germ cell tumors. *Cancer Res* 2003;63:2244–2250.
- 63 Heinrich MC, Corless CL, Blanke CD. KIT mutational status predicts clinical response to STI571 in patients with metastatic gastrointestinal stromal tumors (GISTs). *Proc Am Soc Clin Oncol* 2002;20:1692–1703.
- 64 Lasota J, Wozniak A, Sarlomo-Rikala M, *et al*. Mutations in exons 9 and 13 of KIT gene are rare events in gastrointestinal stromal tumors. A study of 200 cases. *Am J Pathol* 2000;157:1091–1095.
- 65 Hirota S, Isozaki K, Moriyama Y, *et al*. Gain-of-function mutations of c-kit in human gastrointestinal stromal tumors. *Science* 1998;279:577–580.
- 66 Przygodzki RM, Hubbs AE, Zhao FQ, *et al*. Primary mediastinal seminomas: evidence of single and multiple KIT mutations. *Lab Invest* 2002;82:1369–1375.
- 67 Kemmer K, Corless CL, Fletcher JA, *et al*. KIT mutations are common in testicular seminomas. *Am J Pathol* 2004;164:305–313.
- 68 Pauls K, Wardelmann E, Merkelbach-Bruse S, *et al*. c-KIT codon 816 mutation in a recurrent and metastatic dysgerminoma of a 14-year-old girl: case study. *Virchows Arch* 2004;445:651–654.