

The overexpression of polycomb group proteins Bmi1 and EZH2 is associated with the progression and aggressive biological behavior of hepatocellular carcinoma

Motoko Sasaki¹, Hiroko Ikeda¹, Keita Itatsu¹, Junpei Yamaguchi¹, Seiko Sawada^{1,2}, Hiroshi Minato², Tetsuo Ohta³ and Yasuni Nakanuma¹

Polycomb-group proteins Bmi1 and EZH2 are involved in the malignant transformation and biological aggressiveness of several human carcinomas. We herein examined the significance of the Bmi1 and EZH2 expression in hepatocellular carcinoma (HCC) and its preneoplastic lesions, dysplastic nodules. The expression of Bmi1 and EZH2 were examined immunohistochemically in HCC ($n = 27$) and dysplastic nodules ($n = 14$), and combined hepatocellular and cholangiocarcinoma (HC-CC) ($n = 14$). The effect of Bmi1 and EZH2 knockdown was examined in cultured HCC cells (HuH7 and HepG2) using siRNA. It was determined that Bmi1 was constantly expressed in cholangiocytes, but not in hepatocytes, and EZH2 was detected in neither cholangiocytes nor hepatocytes. Bmi1 and EZH2 were overexpressed in HCC and more extensively in HC-CC ($P < 0.01$). Interestingly, Bmi1 and EZH2 were not overexpressed in the dysplastic nodules. The expression of Bmi1 and EZH2 was heterogeneous and associated with vascular infiltration, the histological grades, and the cell proliferation activity in HCC and HC-CC. In cultured carcinoma cells overexpressing Bmi1 and EZH2, knockdown of Bmi1 and EZH2 resulted in decreased cell proliferation activities. Therefore, the overexpression of polycomb-group proteins Bmi1 and EZH2 is associated with the malignant progression of HCC, thereby reflecting the aggressive biological behavior in HCC and HC-CC.

Laboratory Investigation (2008) **88**, 873–882; doi:10.1038/labinvest.2008.52; published online 30 June 2008

KEYWORDS: Bmi1; combined hepatocellular and cholangiocarcinoma; cytokeratin19; EZH2; hepatocellular carcinoma; polycomb group protein

Hepatocellular carcinoma (HCC) is the fifth most common cancer in the world, accounting for approximately 500 000 deaths annually.¹ The majority of HCC are associated with either HBV or HCV infection. There have been several studies reporting that HCC associated with chronic liver diseases, particularly hepatitis virus-related cirrhosis, which is known to evolve through multistep carcinogenesis. Among several preneoplastic lesions proposed so far, dysplastic nodule (DN)s have been recently studied from both pathological and radiological aspects. For example, there have been many studies on malignant transformation in dysplastic nodules, based on cellular atypia and phenotypes such as the aberrant expression of glypican 3 and resistance to iron accumulation. A reduction of sinusoidal reticulin fibers is also a reliable

marker of malignant change within DN.s. However, the exact molecular and genetic mechanisms of the malignant transformation of dysplastic nodules remain to be explored.

Combined hepatocellular and cholangiocarcinoma (HC-CC) is a rare type of liver cancer displaying hepatocellular and cholangiocellular components.^{2,3} Patients with HC-CC are also reported to have a worse prognosis in comparison to patients with ordinary HCC, reportedly.^{4–6}

Polycomb group (PcG) proteins are epigenetic chromatin modifiers involved in cancer development.⁷ PcG proteins are part of the conserved cellular memory system that prevents changes in cell identity by repressing the transcriptional state of several loci in the genome. Bmi1 is overexpressed in several carcinomas,^{7–11} including liver carcinoma.¹²

¹Department of Human Pathology, Kanazawa University Graduate School of Medicine, Kanazawa, Japan; ²Department of Diagnostic Pathology, Kanazawa University Graduate School of Medicine, Kanazawa, Japan and ³Department of Surgery (II), Kanazawa University Graduate School of Medicine, Kanazawa, Japan
Correspondence: Dr Y Nakanuma, MD, Department of Human Pathology, Kanazawa University Graduate School of Medicine, Kanazawa 920-8640, Japan.
E-mail: pbcpsc@kenroku.kanazawa-u.ac.jp

Received 24 January 2008; revised 23 March 2008; accepted 24 March 2008

Polycomb-Repressive Complex 2 (PRC2) members, for example EZH2, are also associated with cancer^{9,13,14} and several studies have shown that EZH2 is highly expressed in aggressive prostate and breast carcinomas.^{13–15}

A previous study showed the expression of p16^{INK4a} a tumor suppressor gene, which is frequently observed in low-grade biliary dysplasia, to decrease in high-grade biliary dysplasia and carcinoma *in situ* and invasive carcinoma, while the EZH2 expression showed stepwise increase from biliary dysplasia and *in situ* carcinoma to invasive carcinoma (paper in submission). These data suggest that the overexpression EZH2 may therefore induce the hypermethylation of p16^{INK4a} promoter followed by decreasing expression of p16^{INK4a} in the process of multistep cholangiocarcinogenesis through intraepithelial neoplasm in hepatolithiasis. Although there have been a few studies describing the expression of PcG proteins Bmi1¹² and EZH2^{16,17} in HCC, so far no studies have investigated the role of Bmi1 and EZH2 expression in the progression of HCC and their association with the biological behavior of this disease is available.

We herein hypothesized that an overexpression of Bmi1 and EZH2 may be related to the malignant transformation of HCC and that it may also reflect the biological aggressiveness of HCC. To clarify these points, we examined the immunohistochemical expression of Bmi1 and EZH2 and their association with pathological parameters. In addition, we took advantage of cultured HCC cells and small interference (si)RNA and examined the effect of a knockdown of the Bmi1 and EZH2 on the proliferation activity of carcinoma cells.

MATERIALS AND METHODS

Human Tissue Studies

Definition of dysplastic nodules and HC–CC

HC–CC was composed of HCC and CC areas which was contiguous and intervening. The latter was tubular, solid-like

or micropapillary adenocarcinoma with dense stromal desmoplasia. Dysplastic nodules which range from 0.8 to 2 cm in diameter, are composed of liver cells with a moderate increase in cell density, a slightly irregular trabecular pattern and various degrees of cellular and structural atypia.^{18,19} However, dysplastic nodules lack features of definite malignancy.^{18,19}

Patients and the preparation of tissue specimens

Fifty-five liver tissue specimens including dysplastic nodules ($n=14$), HCC ($n=27$) and HC–CC ($n=14$) were examined, and their clinicopathological backgrounds are summarized in Table 1. They were either surgically resected or biopsied materials. Ten histologically normal livers obtained from surgically resected livers for a traumatic hepatic rupture or metastatic tumor and 30 non-neoplastic, background liver specimens from surgical cases of HCC and HC–CC were used as a control. All of these specimens were obtained from the Liver Disease File of Department of Human Pathology, Kanazawa University Graduate School of Medicine, Kanazawa, Japan and affiliated hospitals and were fixed in 10% buffered formalin and embedded in paraffin. More than 20 serial sections, 3 μ m in thickness, were cut from each paraffin block. Several sections were processed routinely for histopathologic studies, while the remainders were processed for the following immunohistochemistry.

Immunohistochemistry

The expression of Bmi1, EZH2 and cyclin A was examined by immunostaining as described previously,²⁰ using the antibodies shown in Table 2. Cyclin A was used as a S-phase cell cycle marker thus indicating the cell proliferation activity. A similar dilution of the control mouse or control rabbit IgG (Dako) was applied instead of the primary antibody as a negative control. Positive and negative controls were routinely included.

Table 1 The main clinicopathological findings of dysplastic nodule, hepatocellular carcinoma and combined hepatocellular-cholangiocarcinoma examined

Disease	n	Age		Gender		Serology for Hepatitis viruses				Background liver	
		Range	Mean \pm s.d.	M	F	B	C	C?	BC–	F0–2	F3, 4
Dysplastic nodule	14 ^a	46–68	59.5 \pm 10.6	9	5	4	9	0	1	2	12
HCC	27 ^b	57–75	68.3 \pm 5.5	25	2	2	20	2	3	3	24
Well-diff.	8	55–82	66.4 \pm 10.8	7	1	0	5	1	2	0	8
Moderate and poorly-diff.	19	57–81	70.0 \pm 6.6	18	1	2	15	1	1	3	16
HC–CC	14	52–78	66.2 \pm 7.5	12	2	2	7	5	0	4	10

HCC, hepatocellular carcinoma; HC–CC, combined hepatocellular-cholangiocarcinoma; n, number of cases examined; C?, C? includes the patients whose liver histology was consistent with cirrhosis and chronic hepatitis C, but whose anti-HCV has not been tested. HBsAg was histochemically negative in liver tissue; BC–, negative for HBsAg and HCV; F0–4, the degree of fibrosis (F0, no fibrosis; F1, portal fibrosis; F2, bridging fibrosis; F3, bridging fibrosis with lobular distortion; F4, cirrhosis).

^aNeedle biopsy.

^bIncluding 11 needle biopsy.

Table 2 Primary antibodies used in this study

Primary antibody	Type (clone)	Pre-treatment	Dilution	Source
Bmi1	Mouse mono (229F6)	eARI-EDTA (121°C, 5 min)	1:100	Upstate biotech (Lake Placid, NY)
EZH2	Mouse mono (11)	eARI-EDTA (121°C, 5 min)	1:100	Transduction (San Jose, CA)
p16 ^{INK4a}	Mouse mono (JC2)	eARI-BA (121°C, 5 min)	1:100	Neomarkers (Freemont, CA)
Cyclin A	Mouse mono (6E6)	eARI-BA (121°C, 5 min)	1:100	NovoCastra (New Castle, UK)

EZH2, enhancer of zeste homolog 2; eARI, electronic antigen retrieval instrument (pascal, Dako); MW, microwave treatment; EDTA, 0.05 M EDTA buffer (pH 8); BA, 0.05 M boric acid buffer (pH8).

Semi-quantitative analysis for the immunohistochemical expression of Bmi1 and EZH2

The percentages of immunohistochemically positive cells were examined under microscopy in 50 randomly selected foci composed of over 100 cells in the dysplastic nodules, HCC and HC-CC.

Cell proliferation activity in HCC and HC-CC with respect to Bmi1 and EZH2 expression

The percentage of cyclin A-positive cells; cyclin A-labelling index (LI) was regarded as a marker for the cell proliferation activity. Cyclin A-LI was assessed in 25 representative foci composed of over 100 HCC cells with or without Bmi1 expression and those with or without EZH2 expression from HCC (three cases) and the HCC component of HC-CC (two cases).

Cell Culture Studies

Carcinoma cell lines

Two HCC cell lines, HepG2 and HuH7, were obtained from the RIKEN Cell Resource Center, Tsukuba, Japan. Fibroblast cell line WI-38, embryonic lung fibroblasts were obtained from Cell Resource Center for Biochemical Research (Tohoku University Sendai, Japan) were also used as a control. WI-38 cells were maintained in RPMI-1640 containing 10% fetal calf serum (FCS) (Gibco-BRL, Grand Island, NY), and penicillin-streptomycin-glutamine (Gibco-BRL). HuH7 was maintained in DMEM containing 10% FCS and HepG2 was maintained in MEM containing 10% FCS and 1% non-essential amino acids (Gibco-BRL).

Real-time quantitative reverse transcriptase-polymerase chain reaction

After cDNA was synthesized, a real-time quantitative reverse transcriptase (RT)-PCR analysis for *bmi1* and *EZH2* was performed in duplicate for each sample using the ABI PRISM 7700 Sequence Detection System instrument and software (PE Applied Biosystems Inc., Foster City, CA, USA). Sequence-specific primers and probes for human *Bmi1*, *EZH2* and *GAPDH* as the internal control were purchased from Applied Biosystems. The amplifications were performed under standard conditions.

Knockdown of Bmi1 and EZH2 by small interfering RNA

Validated small interfering (si)RNA for *Bmi1* and *EZH2* and negative control siRNA were purchased from Santa Cruz biotech (Santa Cruz, CA, USA) and Qiagen (Hilden, Germany), respectively. One day before transfection, carcinoma cells were plated in 35 mm-dishes (5×10^5 cells) or Lab-Tek chambers (5×10^4 cells per well), and then the cells were transiently transfected with either *Bmi1*, *EZH2* or control siRNA (100 nM) using lipofectamine™ 2000 (Invitrogen, Carlsbad, CA, USA) according to the manufacturer's protocol.

Immunoblotting

The cell lysate samples (15 μ l) were solubilized, resolved by SDS-PAGE and transferred to a nitrocellulose membrane as described previously.²¹ After transfer, the membranes were processed for immunoblotting as described previously.²¹ The primary antibodies for *Bmi1* and *EZH2* are described above. α -Tubulin as an internal control was detected using mouse monoclonal anti- α -tubulin (clone TU-01, Zymed, South San Francisco, CA, USA).

Immunofluorescence staining for cultured cells

The cells growing in a Lab-Tek chamber were immunostained for *Bmi1*, *EZH2* or control mouse IgG (described above) as described previously.²⁰

Cell growth and BrdU incorporation

The cell proliferation activity was assessed on day 3 after siRNA transfection using a 5-bromo-2'-deoxy-uridine (BrdU) Labeling and Detection Kit I (Roche, Nonenwald, Germany), according to the manufacturer's protocol. The nuclei were simultaneously stained with 4' and 6-diamidino-2-phenylindole (DAPI). At least 1×10^3 total cells were checked and counted to determine the BrdU-labeling index using a conventional fluorescence microscope (Olympus).

Statistics

The statistical analysis to determine the difference in the human study was performed using the Wilcoxon rank sum test. The statistical analysis of the difference in the *in vitro* assays was performed using the Student's *t*-test. A *P*-value less than 0.01 was considered to indicate a significant difference.

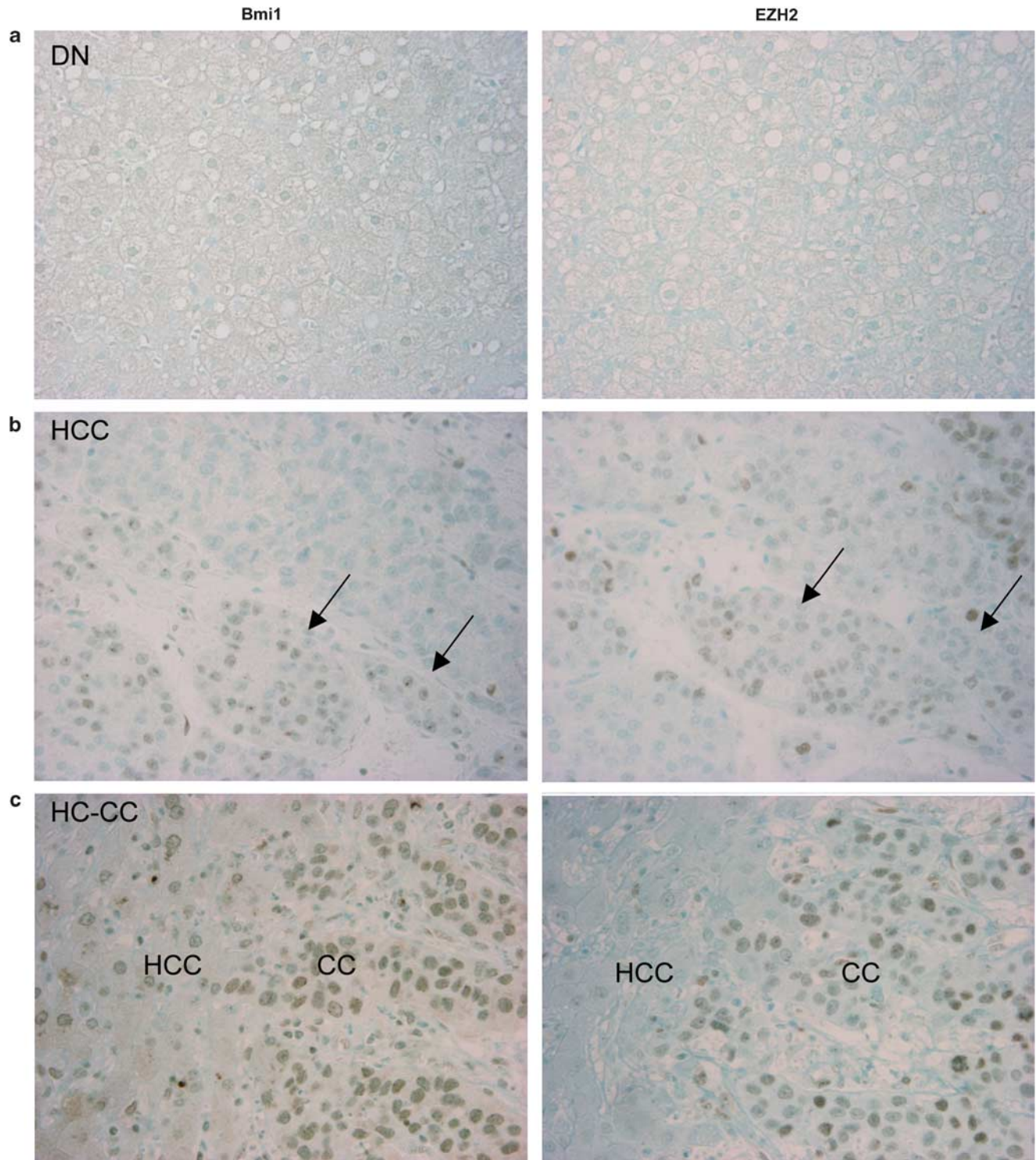


Figure 1 Expression of Bmi1 and EZH2 in dysplastic nodule (DN), hepatocellular carcinoma (HCC) and combined hepatocellular cholangiocarcinoma (HC-CC). **(a)** Neoplastic hepatocytes of dysplastic nodules are negative for either of Bmi1 or EZH2. **(b)** Bmi1 and EZH2 are expressed in the nuclei of carcinoma cells. In moderately differentiated HCC showing trabecular sinusoidal growth pattern, Bmi1 and EZH2 are expressed in a proportion of carcinoma cells (arrows). **(c)** In HC-CC, Bmi1 and EZH2 are more strongly expressed in the cholangiocarcinoma component (CC), in comparison to the HCC component (HCC). Immunostaining for Bmi1 (left column) and EZH2 (right column). Original magnification, $\times 400$.

RESULTS

The Expression of Bmi1 and EZH2 in Dysplastic Nodules, HCC and HC-CC

Non-tumorous control livers

Bmi1 was consistently expressed in the nuclei of biliary epithelial cells, as described previously²⁰ while its expression in hepatocytes in the background livers was not evident. EZH2 was rarely expressed in the biliary epithelial cells and hepatocytes of the background livers.

Liver tumors

Bmi1 and EZH2 were expressed in the nuclei of carcinoma cells (Figure 1b and c). Bmi1 was expressed in most carcinoma cells in a CC component in HC-CC, while the expression of Bmi1 was heterogeneous in HCC and a HCC component of HC-CC. The distribution of EZH2 expression was similar to that of the Bmi1 expression. However, the number of EZH2-positive cells tended to be rather small, in comparison to that of the Bmi1-positive cells in HC-CC and HCC. The expression of Bmi1 and EZH2 was not evident at all in the neoplastic hepatocytes of the dysplastic nodules (Figure 1a).

Figure 2 summarizes the semi-quantitative analysis of Bmi1 and EZH2 expression in dysplastic nodules, HCC and HC-CC. The expression level of Bmi1 and EZH2 was significantly higher in HC-CC, in comparison to HCC ($P < 0.01$). The extent of EZH2 expression was lower, in comparison to the extent of Bmi1 expression in HC-CC and HCC. The extent of Bmi1 and EZH2 expression was significantly higher in the CC component than in the HCC component in HC-CC, respectively ($P < 0.01$). The extent of Bmi1 and EZH2 expression was significantly higher in poorly differentiated HCC and relatively low in well-differentiated HCC, and intermediate in moderately differentiated HCC, respectively ($P < 0.01$).

The Bmi1 and EZH2 Expression is Closely Associated with an Increased Cell Proliferation Activity

Many cyclin A-positive cells were detected in the area with a high Bmi1 expression and in the area with a high EZH2 expression in HCC, while the number of cyclin A-positive cells was small in the area without Bmi1 and EZH2 expression (Figure 3a). As shown in Figure 3b, cyclin A-LI indicated the cell proliferation activity to be significantly higher in the foci with high Bmi1 and in the foci with high EZH2 expression in comparison to the foci negative for Bmi1 and EZH2, respectively ($P < 0.01$). The EZH2 expression was more closely related to the cell proliferation activity than to Bmi1 expression.

Overexpression of Bmi1 and EZH2 is Associated with Vascular Invasion in HCC and HC-CC

As shown in Table 3, the extent of EZH2 expression (percentage of positive cells) was significantly higher in the cases of HC-CC with lymphatic and vascular invasion, in com-

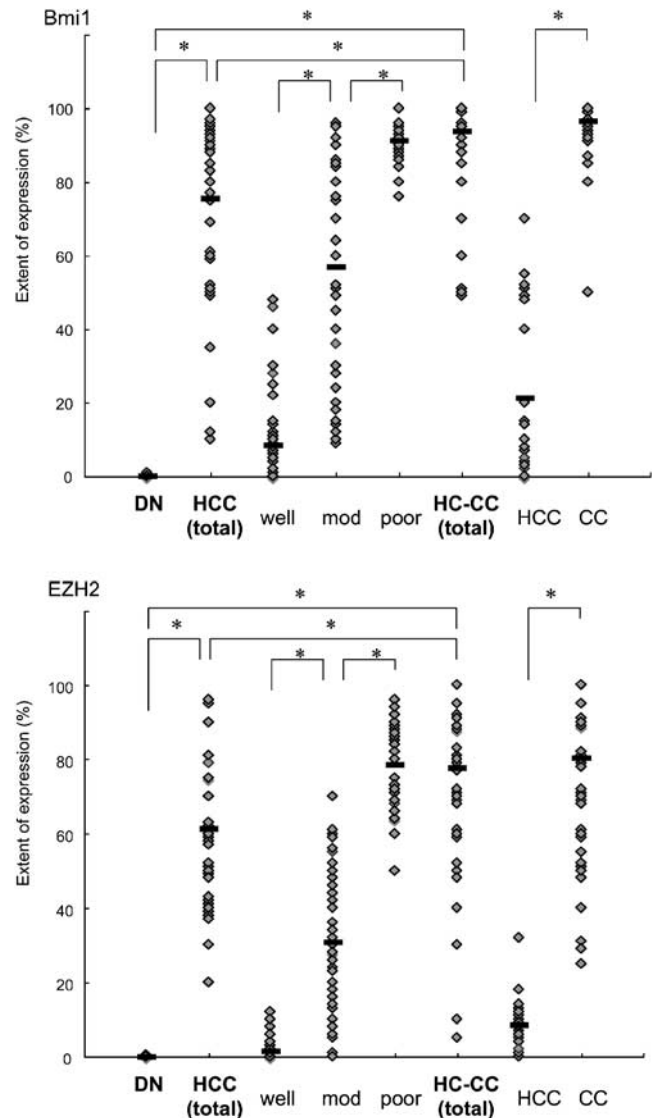


Figure 2 Semi-quantitative analysis of Bmi1 and EZH2 expression in dysplastic nodules, hepatocellular carcinoma (HCC) and combined hepatocellular cholangiocarcinoma (HC-CC). The results are shown as scattering plots of 50 randomly selected foci in dysplastic nodules (DN), HCC, and HC-CC, respectively. In dysplastic nodules, most foci are negative for either of Bmi1 and EZH2. The extent of the expression of Bmi1 and EZH2 (percentage of positive cells) is significantly higher in HC-CC (Bmi1, $93.80 \pm 13.65\%$; and EZH2, $77.7 \pm 28.43\%$) as a whole in comparison to HCC as a whole (Bmi1, $75.53 \pm 24.39\%$; and EZH2, $61.22 \pm 19.37\%$). In HCC, the extent of the expression of Bmi1 and EZH2 is significantly higher in moderately (Bmi1, $56.94 \pm 28.55\%$; and EZH2, $30.68 \pm 20.97\%$) and poorly differentiated HCC (Bmi1, $91.22 \pm 5.64\%$; and EZH2, $78.5 \pm 12.92\%$) than in well-differentiated HCC (Bmi1, $8.48 \pm 11.97\%$; and EZH2, $1.48 \pm 2.91\%$). In HC-CC, the extent of the expression of Bmi1 and EZH2 is higher in the CC component (including mixed component) (Bmi1, $96.56 \pm 8.19\%$ and EZH2, $80.30 \pm 22.98\%$) than in the apparent HCC component (Bmi1, $21.23 \pm 21.30\%$; and EZH2, $8.41 \pm 6.56\%$). Black bar, the mean, * $P < 0.01$.

parison to those without lymphatic and vascular invasion, respectively. The extent of Bmi1 and EZH2 expression were significantly higher in HCC with vascular invasion, when compared with those without vascular invasion, respectively.

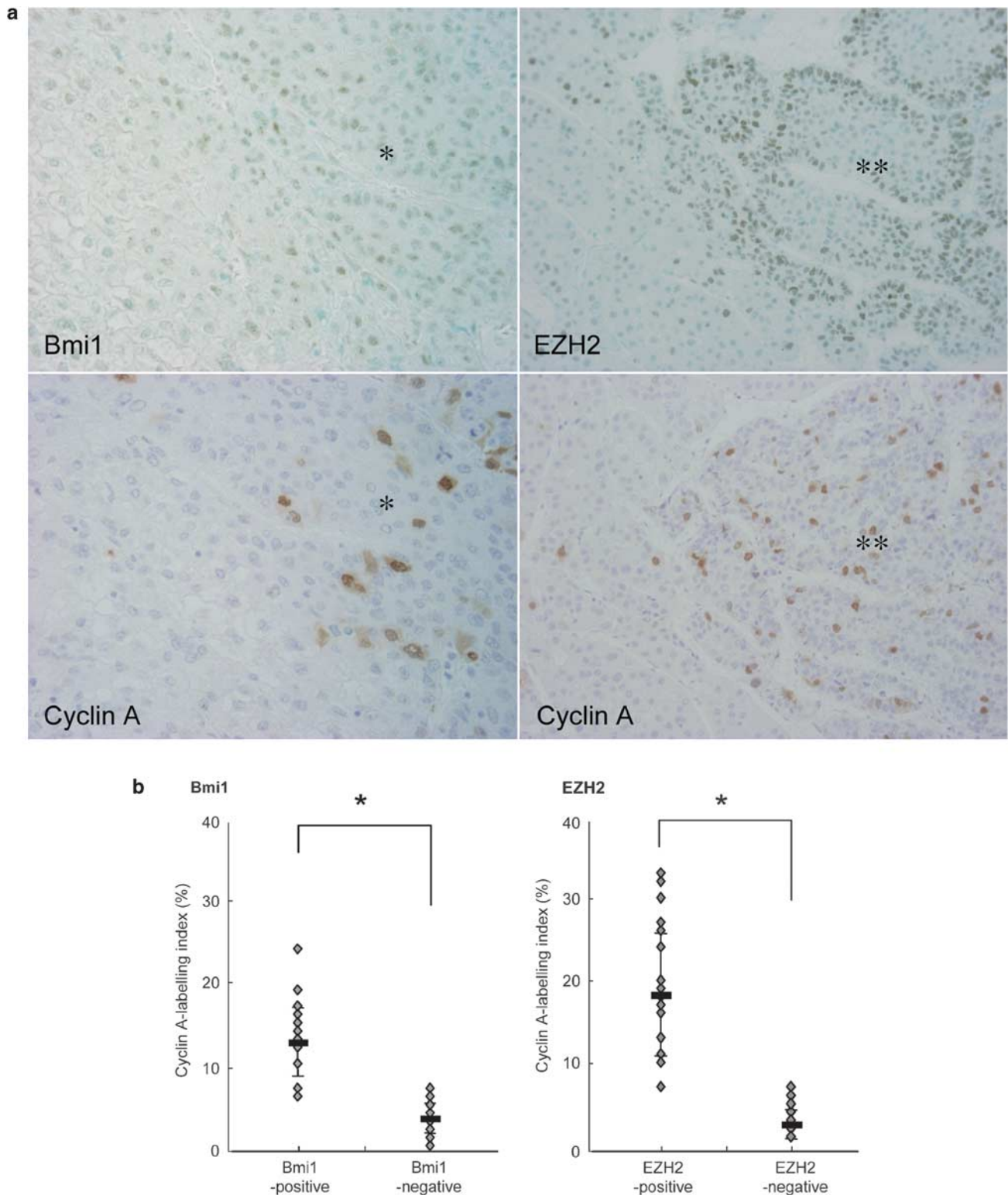


Figure 3 Association between the Bmi1 and EZH2 expression with cell proliferation activity in hepatocellular carcinoma (HCC) and combined hepatocellular cholangiocarcinoma (HC-CC). **(a)** Many cyclin A-positive cells are detected in the areas with a high Bmi1 expression (one asterisk) and also in the areas with a high EZH2 expression (two asterisks) in HCC, while cyclin A-positive cells were few in the area without Bmi1 and EZH2 expression. Immunostaining for Bmi1 (top left), EZH2 (top right) and cyclin A (down). Original magnifications, $\times 400$. **(b)** A semi-quantitative analysis of the cell proliferation activity to determine the cyclin A-labelling index (LI) in HCC and HC-CC. The results are shown as scattering plots of 25 randomly selected foci with or without Bmi1 or EZH2 expression in HCC and HC-CC. Cyclin A-LI is higher in Bmi1- and EZH2-positive cells (Bmi1, $12.64 \pm 4.48\%$; and EZH2, $18.20 \pm 7.42\%$) than in Bmi1- and EZH2-negative cells (Bmi1, $3.36 \pm 1.84\%$; and EZH2, $2.48 \pm 1.78\%$). $*P < 0.05$. Columns, the mean; bars, s.d. $*P < 0.01$.

Table 3 The association of the extent of Bmi1 and EZH2 expression with the presence of lymphatic and vascular infiltration in hepatocellular carcinoma and combined hepatocellular-cholangiocarcinoma

	HCC (n = 16)			HC-CC (n = 14)		
	n	Mean ± s.d.	P-values	n	Mean ± s.d.	P-values
<i>Bmi1</i>						
Ly-positive	NA	NA		11	87 ± 17	ND
Ly-negative	NA	NA		3	73 ± 21	
V-positive	6	76 ± 21 ^a	ND	10	86 ± 18	ND
V-negative	10	57 ± 25		4	77 ± 19	
<i>EZH2</i>						
Ly-positive	NA	NA		11	58 ± 32	<0.01
Ly-negative	NA	NA		3	12 ± 12	
V-positive	6	55 ± 23	<0.05	10	64 ± 28	<0.01
V-negative	10	31 ± 24		4	10 ± 10	

HCC, hepatocellular carcinoma; HC-CC, combined hepatocellular-cholangiocarcinoma; Ly, lymphatic invasion; V, vascular invasion; n, number of cases examined; NA, not available; ND, no difference.

^aThe extent (percent) of positive cells in each case is expressed as mean ± standard deviation in individual groups.

The Knockdown of Bmi1 and EZH2 Results in a Decreased Activity of Cell Proliferation

As the expression levels of Bmi1 and EZH2 were closely associated with the cell proliferation activity in HCC and HC-CC, we examined whether the knockdown of Bmi1 and EZH2 expression by siRNA may affect the cell proliferation of cultured HCC cells (HuH7 and HepG2).

Bmi1 and EZH2 are overexpressed in CC and HCC cell lines

The expression level of Bmi1 and EZH2 mRNA was high in HuH7 and HepG2 in comparison to that in WI-38 (Figure 4a). Bmi1 and EZH2 were expressed in the nuclei of carcinoma cells when detected by an immunofluorescent study (Figure 4b).

Effect of Bmi1 and EZH2 knockdown on cell proliferation

Immunoblotting showed the effective knockdown of Bmi1 and EZH2 by Bmi1 and EZH2 siRNA treatment in comparison to the control siRNA treatment 2 and 3 days after siRNA treatment (Figure 4c). The *in vitro* BrdU assay was performed 3 days after the siRNA treatment in cultured HCC cells. The cell proliferation activity was significantly low in cultured HCC cells (HuH7 and HepG2) after Bmi1 and EZH2 siRNA treatment in comparison to that in control siRNA (Figure 4d), respectively ($P < 0.01$).

DISCUSSION

Although a few studies have been reported regarding the overexpression of Bmi1 mRNA in HCC,^{12,22} the present study is the first attempt to elucidate in detail the characteristic expression of Bmi1 and EZH2 in HCC and HC-CC. This study showed that in the normal livers and the background non-tumorous livers, Bmi-1 and EZH2 were not found in the hepatocytes. In HCC and HC-CC, these two molecules were frequently but variably expressed in the nuclei of carcinoma cells. The distribution patterns of Bmi1 and EZH2 tended to closely parallel one another.

Interestingly, these two molecules were not found in the neoplastic hepatocytes of dysplastic nodules, a preneoplastic lesion of HCC arising in chronic advanced liver diseases.^{23,24} Furthermore, while these molecules were rather infrequent and focal in well-differentiated HCC, their expression became more frequent and widespread in moderately and poorly differentiated HCC and HC-CC, thus suggesting the aberrant expression of Bmi1 and EZH2 to be involved in the malignant progression from dysplastic nodules and in dedifferentiation from well-differentiated HCC to moderately and poorly differentiated HCC. The aberrant expression of several molecules and the biological features involved in malignant transformation from dysplastic nodules to HCC have been reported, though the exact genetic mechanism remains to be explored.²³⁻²⁵ Recently, several studies have also shown EZH2 to be highly expressed in aggressive tumors, including human breast cancer, prostate cancer and lymphomas.^{9,13-15,26,27}

The present study showed PcG proteins Bmi1 and EZH2 which are epigenetic chromatin modifier involved in cancer development,⁷ to be involved in this malignant progression of HCC. PcGs are chromatin modifiers which have been reported to affect the expression of a number of genes.⁷ One of candidate downstream molecules of Bmi1 and EZH2 is p16^{INK4a}, which works as a tumor suppressor. A recent study demonstrated the ability of Bmi1 to repress the INK4A-ARF locus is dependent on the continued presence of the EZH2-containing PRC2 complex.²⁸ A recent report suggests the presence of a conserved Bmi-1-driven pathway to be related to a marked propensity toward metastatic dissemination²⁹ and a high EZH2 expression localizes to more primitive malignant cell types, often in combination with a high Bmi1 expression.^{15,27} Taken together, the aberrant expression of Bmi1 and EZH2 may be involved in the malignant progression of HCC and its aggressive behaviors, and more genetic and molecular studies are thus necessary to elucidate the exact mechanism in this process.

Our previous study showed that Bmi1 was constantly expressed in a majority of carcinoma cells of intrahepatic cholangiocarcinoma and also in non-neoplastic biliary epithelial cells (in submission), and the present study showed that Bmi1 was frequently overexpressed in the CC components of HC-CC, while it was also expressed to a lesser degree in HCC and a HCC component of HC-CC. Therefore, it

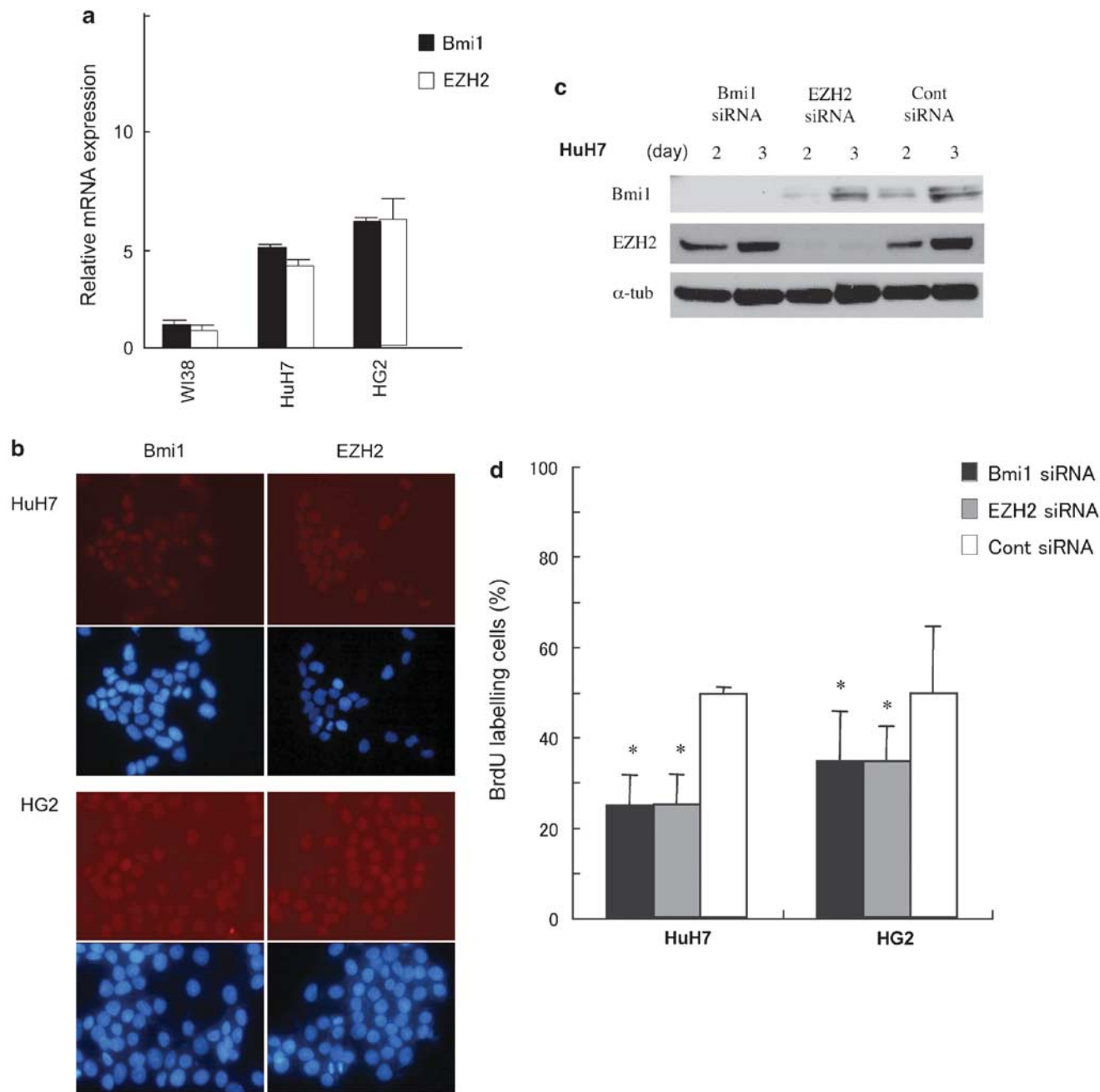


Figure 4 The knockdown of Bmi1 and EZH2 results in a decreased cell proliferation activity in cultured hepatocellular carcinoma (HCC) cells. **(a)** Both Bmi1 and EZH2 mRNA are expressed in the cultured HCC cells of both cell lines (HuH7 and HepG2) to various degrees, and their expression level are high in HuH7 cells (Bmi1, 4.31 ± 0.03 folds; and EZH2, 3.51 ± 0.17 folds) and HepG2 cells (Bmi1, 5.42 ± 0.10 folds; and EZH2, 5.41 ± 0.89 folds), in comparison to WI38 non-neoplastic fibroblasts. The expression of mRNA is quantified with real-time PCR. The expression is normalized as a ratio using GAPDH as a housekeeping gene. The data are expressed as the mean \pm s.d. **(b)** Bmi1 and EZH2 are expressed in the nuclei in cultured HCC cells of two HCC cell lines (HuH7 and HG2). Immunofluorescent staining for Bmi1 and EZH2, counterstained by DAPI. **(c)** An immunoblot analysis of Bmi1, EZH2 and α -tubulin protein expression in HuH7 carcinoma cells after Bmi1 siRNA, EZH2 siRNA and control siRNA treatment. The successful knockdown of Bmi1 and EZH2 by corresponding siRNA is evident at day 2 and day 3 after siRNA treatment in comparison with control siRNA treatment. **(d)** Cell proliferation activities of cultured HCC cells (HuH7 and HepG2) are assessed by a 5-bromo-2'-deoxyuridine (BrdU) assay. The labeling index of BrdU (BrdU-LI) is counted for at least 1,000 cells in each group. BrdU-LI is significantly low in cultured cells of two HCC cell lines (HuH7, 50.19 ± 6.72 and $50.69 \pm 6.60\%$; and HepG2, 69.47 ± 11.09 , $69.50 \pm 7.79\%$) examined at day 3 after Bmi1 and EZH2 siRNA treatment, when compared with cells after control siRNA treatment. Data are expressed as the mean \pm s.d. * $P < 0.01$ vs control siRNA.

seems conceivable that Bmi1 expression may be a marker of cholangiocyte lineage and its expression in HCC and HC-CC may reflect biliary differentiation in HCC cells. An aggressive behavior and poor prognosis have been reported in another subgroup of HCC, cytokeratin (CK)19-positive HCC and HC-CC.^{4–6,30} This may be the case regarding the high expression of Bmi1 in HCC and HC-CC as disclosed in the present study, because CK19 is also known to be a biliary cytokeratin. The relationship between the expression of biliary marker such as CK19 and Bmi1 in HCC and its biological behaviors should therefore be clarified in the future.

Interestingly, Bmi1 and EZH2 were expressed heterogeneously in HCC and the extent of their expression was closely associated with increased cell proliferation activity in HCC and HC-CC. Our *in vitro* study using Bmi1 and EZH2 siRNA also suggested that Bmi1 and EZH2 may play an important role in the cell proliferation of HCC cells. In particular, the expression of EZH2 was more closely associated with an increased cell proliferation activity as well as in the lymphatic and vascular infiltration in HCC and HC-CC, in comparison to Bmi1. The findings of this study indicate that the EZH2 mRNA expression was upregulated in human HCC and it may therefore play an important role in tumor progression, especially by vascular invasion. These findings are compatible with those of a previous study in which the upregulated expression of EZH2 mRNA was shown to be associated with tumor progression, especially facilitating portal vein invasion in human HCC.¹⁶ EZH2 was not expressed in either the cholangiocyte or hepatocytes in non-tumorous livers, it is conceivable that the EZH2 expression in addition to the Bmi1 expression may therefore be a predictor of the biological aggressiveness and poor prognosis in HCC and HC-CC as reported in carcinomas in other organs.^{9,13–15,26,27,29}

Since the extensive expression of Bmi1 and EZH2 was demonstrated in HCC and HC-CC, especially in an aggressive subgroup, Bmi1 and EZH2 may therefore be an effective therapeutic target molecule for advanced HCC and HC-CC. The findings of both the present study and several previous studies showed that the knockdown of Bmi1 and EZH2 using siRNA can induce growth inhibition while reducing metastasis.^{13,31,32} Furthermore, Chen *et al*¹⁷ reported a dramatic inhibition of cell growth *in vitro* when they suppressed the EZH2 expression in HCC cells by Lenti-shEZH2. They also demonstrated that the knockdown of the EZH2 expression in HCC cells is sufficient to significantly reverse HCC tumorigenicity *in vivo* in a nude mouse model. Taken together, the knockdown of Bmi1 and EZH2 may therefore be a powerful therapeutic strategy for advanced HCC and HC-CC.

In conclusion, the present study suggested that the overexpression of polycomb-group proteins Bmi1 and EZH2 is associated with the malignant progression of HCC and the aggressive biological features of HCC and HC-CC, and that

the Bmi1 expression may therefore reflect the biliary differentiation of HCC and a CC component of HC-CC. Bmi1 and EZH2 could thus be a target molecule in the development of new treatment strategies against advanced HCC and HC-CC.

- Okuda K. Hepatocellular carcinoma. *J Hepatol* 2000;32(1 Suppl): 225–237.
- Wittekind C, Fischer H, Ponchon T. Combined Hepatocellular and Cholangiocarcinoma. World Health Organization Classification of Tumours: Pathology and Genetics of Tumours of the Digestive System. IARC Press: Lyon, 2000, pp 181–182.
- Goodman ZD, Ishak KG, Langloss JM, *et al*. Combined hepatocellular-cholangiocarcinoma. A histologic and immunohistochemical study. *Cancer* 1985;55:124–135.
- Aishima S, Nishihara Y, Kuroda Y, *et al*. Histologic characteristics and prognostic significance in small hepatocellular carcinoma with biliary differentiation: subdivision and comparison with ordinary hepatocellular carcinoma. *Am J Surg Pathol* 2007;31:783–791.
- Koh KC, Lee H, Choi MS, *et al*. Clinicopathologic features and prognosis of combined hepatocellular cholangiocarcinoma. *Am J Surg* 2005;189:120–125.
- Kobayashi M, Ikeda K, Saitoh S, *et al*. Incidence of primary cholangiocellular carcinoma of the liver in Japanese patients with hepatitis C virus-related cirrhosis. *Cancer* 2000;88:2471–2477.
- Valk-Lingbeek ME, Bruggeman SW, van Lohuizen M. Stem cells and cancer; the polycomb connection. *Cell* 2004;118:409–418.
- Park IK, Morrison SJ, Clarke MF. Bmi1, stem cells, and senescence regulation. *J Clin Invest* 2004;113:175–179.
- Raaphorst FM, Otte AP, Meijer CJ. Polycomb-group genes as regulators of mammalian lymphopoiesis. *Trends Immunol* 2001;22:682–690.
- Tateishi K, Ohta M, Kanai F, *et al*. Dysregulated expression of stem cell factor Bmi1 in precancerous lesions of the gastrointestinal tract. *Clin Cancer Res* 2006;12:6960–6966.
- Gunster MJ, Raaphorst FM, Hamer KM, *et al*. Differential expression of human Polycomb group proteins in various tissues and cell types. *J Cell Biochem* 2001;81(S36):129–143.
- Neo SY, Leow CK, Vega VB, *et al*. Identification of discriminators of hepatoma by gene expression profiling using a minimal dataset approach. *Hepatology* 2004;39:944–953.
- Varambally S, Dhanasekaran SM, Zhou M, *et al*. The polycomb group protein EZH2 is involved in progression of prostate cancer. *Nature* 2002;419:624–629.
- Kleer CG, Cao Q, Varambally S, *et al*. EZH2 is a marker of aggressive breast cancer and promotes neoplastic transformation of breast epithelial cells. *Proc Natl Acad Sci USA* 2003;100:11606–11611.
- Collett K, Eide GE, Arnes J, *et al*. Expression of enhancer of zeste homologue 2 is significantly associated with increased tumor cell proliferation and is a marker of aggressive breast cancer. *Clin Cancer Res* 2006;12:1168–1174.
- Sudo T, Utsunomiya T, Mimori K, *et al*. Clinicopathological significance of EZH2 mRNA expression in patients with hepatocellular carcinoma. *Br J Cancer* 2005;92:1754–1758.
- Chen Y, Lin MC, Yao H, *et al*. Lentivirus-mediated RNA interference targeting enhancer of zeste homolog 2 inhibits hepatocellular carcinoma growth through down-regulation of stathmin. *Hepatology* 2007;46:200–208.
- International Working Party. Terminology of nodular hepatocellular lesions. *Hepatology* 1995;22:983–993.
- Hirohashi S, Ishak K, Kojiro M, *et al*. Hepatocellular carcinoma. In: Hamilton S, Aaltonen L (eds). Pathology and Genetics Tumours of the Digestive System World Health Organization of Tumours Liver Cancer. IARC Press: Lyon, 2000, pp 159–172.
- Sasaki M, Ikeda H, Sato Y, *et al*. Decreased expression of Bmi1 is closely associated with cellular senescence in small bile ducts in primary biliary cirrhosis. *Am J Pathol* 2006;169:831–845.
- Sasaki M, Van De Water J, Kenny TP, *et al*. Immunoglobulin gene usage and immunohistochemical characteristics of human monoclonal antibodies to the mitochondrial autoantigens of primary biliary cirrhosis induced in the XenoMouse. *Hepatology* 2001;34(Part 1): 631–637.

22. Ma S, Chan KW, Hu L, *et al*. Identification and characterization of tumorigenic liver cancer stem/progenitor cells. *Gastroenterology* 2007;132:2542–2556.
23. Terada T, Terasaki S, Nakanuma Y. A clinicopathologic study of adenomatous hyperplasia of the liver in 209 consecutive cirrhotic livers examined by autopsy. *Cancer* 1993;72:1551–1556.
24. Nakanuma Y, Terada T, Ueda K, *et al*. Adenomatous hyperplasia of the liver as a precancerous lesion. *Liver* 1993;13:1–9.
25. Yuan RH, Jeng YM, Chen HL, *et al*. Stathmin overexpression cooperates with p53 mutation and osteopontin overexpression, and is associated with tumour progression, early recurrence, and poor prognosis in hepatocellular carcinoma. *J Pathol* 2006;209:549–558.
26. Zeidler M, Kleer CG. The Polycomb group protein Enhancer of Zeste 2: its links to DNA repair and breast cancer. *J Mol Histol* 2006;37:219–223.
27. Breuer RH, Snijders PJ, Smit EF, *et al*. Increased expression of the EZH2 polycomb group gene in BMI-1-positive neoplastic cells during bronchial carcinogenesis. *Neoplasia* 2004;6:736–743.
28. Bracken AP, Kleine-Kohlbrecher D, Dietrich N, *et al*. The Polycomb group proteins bind throughout the INK4A-ARF locus and are disassociated in senescent cells. *Genes Dev* 2007;21:525–530.
29. Gliinsky GV, Berezovska O, Glinskii AB. Microarray analysis identifies a death-from-cancer signature predicting therapy failure in patients with multiple types of cancer. *J Clin Invest* 2005;115:1503–1521.
30. Lee JS, Heo J, Libbrecht L, *et al*. A novel prognostic subtype of human hepatocellular carcinoma derived from hepatic progenitor cells. *Nat Med* 2006;12:410–416.
31. Cui H, Hu B, Li T, *et al*. Bmi-1 is essential for the tumorigenicity of neuroblastoma cells. *Am J Pathol* 2007;170:1370–1378.
32. Liu S, Dontu G, Mantle ID, *et al*. Hedgehog signaling and Bmi-1 regulate self-renewal of normal and malignant human mammary stem cells. *Cancer Res* 2006;66:6063–6071.