

# A Practical Guide to Scalp Disorders

Ramon Grimalt<sup>1</sup>

The scalp is unique among skin areas in humans, with high follicular density and a high rate of sebum production. The relatively dark and warm environment on the scalp surface provides a welcoming environment for the superficial mycotic infections associated with many scalp conditions and for parasitic infestation. Infections and infestations can occur when items such as fingers, combs, hats, or styling implements come into contact with the hair and scalp and introduce microorganisms. Inflammatory conditions may also produce changes in the scalp. Many common scalp conditions have similar symptoms and clinical features, complicating diagnosis, but a correct diagnosis is critical to determining proper treatment. This paper describes the symptoms, etiology, and treatment strategies for a number of common scalp conditions, including dandruff, seborrheic dermatitis, tinea capitis, pediculosis capitis, and psoriasis.

*Journal of Investigative Dermatology Symposium Proceedings* (2007) **12**, 10–14. doi:10.1038/sj.jidsymp.5650048

## INTRODUCTION

Although hair and scalp disorders generally are not associated with significant physical morbidity, the psychological impact of visible scalp problems may be very high. In human societies, hair now plays an important role in appearance and sexual signaling to which the original functional roles of protection and heat conservation are secondary, and changes in the appearance of skin and hair affect self-esteem and confidence in social settings. It should also be recognized that scalp changes in some cases may be a sign of a more substantial medical problem, so correct diagnosis is important.

The scalp is unique among skin areas in humans, with high follicular density and a high rate of sebum production. Fingers, combs, hats, styling implements come into contact with the hair and scalp and can introduce microorganisms, increasing the likelihood of infections and infestations. The dark and warm environment of the scalp surface is favorable for the superficial mycotic infections that play a role in dandruff, seborrheic dermatitis, and tinea capitis, and for parasitic infestations such as pediculosis capitis. Scalp changes may also be seen in inflammatory conditions such as psoriasis. The similarities in clinical signs and symptoms of many scalp conditions can complicate accurate diagnosis. This paper describes the etiology, signs and symptoms, and treatment strategies for these common scalp conditions.

## DANDRUFF AND SEBORRHEIC DERMATITIS

Dandruff (or pityriasis capitis) and seborrheic dermatitis may be considered to be the same condition, yet on different ends of the disease severity spectrum. Both have been linked to the lipophilic, putative yeast, *Malassezia*, previously known as *Pityrosporum* (Shuster, 1984). Common features of dandruff and seborrheic dermatitis are summarized in Table 1.

Dandruff and seborrheic dermatitis are extremely common, affecting close to 50% of the world's population (Cardin, 1998). They are overwhelmingly afflictions of adults, occurring most commonly between the ages of 15 and 50 years and very rarely before adolescence, although seborrheic dermatitis can continue to occur in extreme old age. Although dandruff and seborrheic dermatitis usually become apparent during the second and third decades following increased sebum production at the onset of puberty, the severity and duration of the symptoms vary widely. The prevalence is higher in immuno-compromised patients than in healthy adults (Smith *et al.*, 1994). For example, seborrheic dermatitis has been reported to occur in 3–5% of immuno-competent adults, compared with 30–33% of AIDS patients (Farthing and Staughtom, 1985).

## Clinical features

Patients with dandruff and seborrheic dermatitis often experience one or more additional symptoms in addition to skin flaking. These other symptoms may be pruritus (66%), irritation (25%), and the feeling of a tight or dry scalp (59%) (Elewski, 2005). The classical signs of dandruff are loosely adherent, small white or gray flakes, whereas seborrheic dermatitis is often associated with yellowish, oily scales. The flakes or scales may accumulate in localized patches or may be distributed diffusely on the scalp surface. The range of visible flakes along the disease spectrum is shown in the Figure 1. When inflammatory changes such as erythema and pruritus are seen along with scalp flaking, the clinical picture is typical of seborrheic dermatitis.

## Etiology

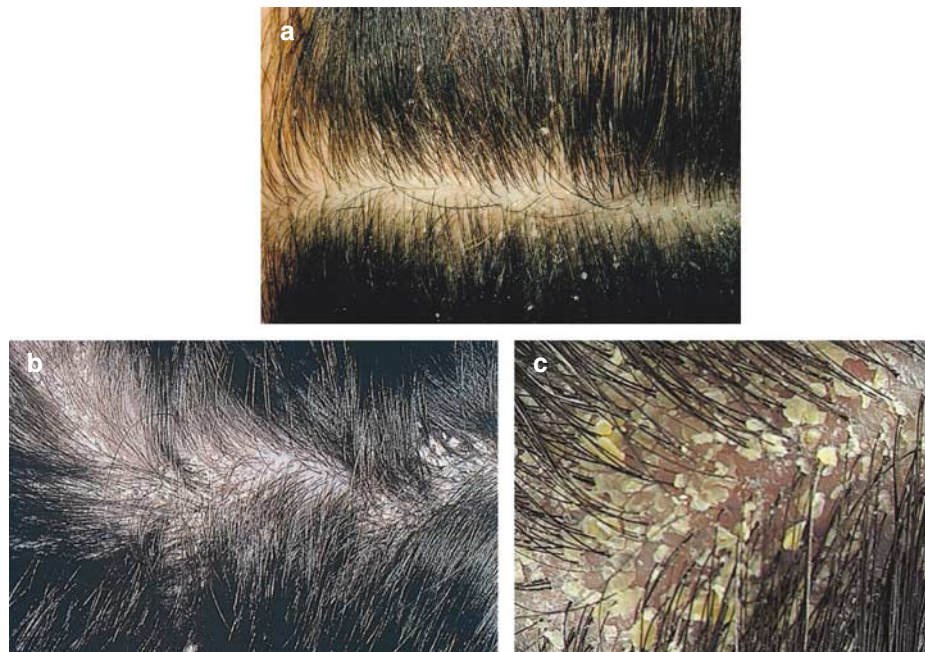
Research in recent years has provided an increased understanding of the etiology of dandruff and seborrheic dermatitis,

<sup>1</sup>Department of Dermatology, University of Barcelona, Barcelona, Spain

Correspondence: Dr Ramon Grimalt, Department of Dermatology, University of Barcelona, Villarroel 170, 08036 Barcelona, Spain. E-mail: grimalt@ub.edu

**Table 1. Clinical features, associated organisms, and treatment strategies for common scalp disorders**

| Disorders             | Scaling                    | Pruritus                 | Inflammation | Alopecia | Organisms                                | Treatment Strategies  |
|-----------------------|----------------------------|--------------------------|--------------|----------|--|---|
| Dandruff              | Yes, white or gray         | Possible, generally mild | No           | No       | <i>Malassezia</i>                        | Topical treatments: antifungal, keratolytic, antiproliferatives   |
| Seborrheic Dermatitis | Yes, large, greasy, yellow | Yes, varies              | Yes          | No       | <i>Malassezia</i>                        | Topical treatments: antifungal, keratolytic, antiproliferatives   |
| Psoriasis             | Yes, silver-gray           | Mild                     | Yes          | Possible | Unknown                                  | Topical treatments such as coal tar, keratolytics, corticosteroids for milder cases. Phototherapy and systemic treatments for more severe cases |
| Tinea capitis         | Variable, mild to dense    | Possible                 | Possible     | Yes      | <i>Microsporum</i> , <i>Trichophyton</i> | Systemic antifungals, topical antifungal treatments, corticosteroids  |
| Pediculosis capitis   | No, but nits are visible   | Yes, severe              | Possible     | No       | <i>Pediculosis humanus capitis</i>       | Insecticide-containing topical treatments, mechanical treatment   |



**Figure 1.** Range of visible flakes along dandruff/seborrheic dermatitis disease spectrum. (a) ASFS = 20, mild dandruff; (b) ASFS = 30, moderate dandruff/seborrheic dermatitis; (c) ASFS = 42, severe dandruff/seborrheic dermatitis.

with recognition that microbial activity plays a key role in the development of these conditions. As noted above, dandruff and seborrheic dermatitis have been linked to yeasts of the species *Malassezia* (previously *Pityrosporum*). *Malassezia globosa* and *Malassezia restricta* have been identified as the predominant fungal species present on both normal and dandruff-affected scalps (Gemmer *et al.*, 2002). The lipophilic yeast is believed to digest sebaceous triglycerides, producing free fatty acids such as oleic acid. The free fatty acids penetrate the stratum corneum and disrupt the skin barrier function (Schwartz *et al.*, 2004), leading to the range of typical symptoms.

#### Treatment strategies

Before the recognition of the role of *Malassezia* in dandruff etiology, it was hypothesized that seborrheic dermatitis was akin to psoriasis; however, success with antifungal treatments differentiated those suffering seborrheic dermatitis from those with psoriasis (Aron-Brunetiere *et al.*, 1977). Dandruff and seborrheic dermatitis can be treated with products that have both efficacy and cosmetic benefits, and can be conveniently incorporated into a patient's routine hair-care regimen.

Treatments to control dandruff and seborrheic dermatitis can be divided into three main classes on the basis of their mechanisms of action; these include keratolytic, antimicro-

bial, and antiproliferative agents. Simple shampooing and keratolytic treatments (e.g., salicylic acid) will remove a considerable proportion of flakes in patients with milder conditions. The majority of commercially available treatments for dandruff and seborrheic dermatitis contain antifungal agents. These treatments (e.g., pyriithione zinc, selenium sulfide, ketoconazole, and ciclopirox) have been shown to improve the visible symptom of flaking and restore the underlying skin condition (Warner *et al.*, 2001). Antiproliferatives (e.g., coal tar) decrease epidermal proliferation and dermal infiltrates (Schwartz *et al.*, 2004). Adjunctive treatment with topical steroids may also be helpful in patients whose condition includes evidence of an inflammatory component. Given that many dandruff and seborrheic dermatitis patients may require regular, long-term use of therapeutic agents, it is important that the treatments be formulated so as to be aesthetically and cosmetically acceptable to the patient.

### TINEA CAPITIS

Another common mycotic condition of the scalp is tinea capitis, which is also known as ringworm of the scalp because of the characteristic ring-like rash that develops on infected skin. This dermatophytosis is especially common in childhood, unlike dandruff and seborrheic dermatitis, which are more prevalent in adults. Ringworm can be spread by exposure to desquamated cells or through contact with infected people, animals, or soil (Hainer, 2003).

#### Clinical features

Symptoms of tinea capitis include well-demarcated or irregular alopecia, scaling, pruritus, and broken hairs. Sporulation inside the hair shaft causes breakage of the hair near the scalp surfaces, leading to “black dot” alopecia (Hainer, 2003). The infection can be inflammatory or noninflammatory. The inflammatory form may produce kerions, boggy, inflammatory scalp masses; these lesions are most often associated with infection by *Trichophyton mentagrophytes* or *Trichophyton verrucosum*. Without early treatment, scarring alopecia may result from kerion formation (Arenas *et al.*, 2006).

#### Etiology

Dermatophytes are grouped into three genera: *Microsporum*, *Trichophyton*, and *Epidermophyton*. Unlike the dandruff-related *Malassezia*, dermatophytes require keratin for growth and are able to invade the hair shaft. *Microsporum* and *Trichophyton* are the genera most commonly associated with tinea capitis, although the prevalent species will vary by geography and over time. Dermatophytes can be grouped according to their preferred habitat: anthropophilic (infecting humans), zoophilic (infecting animals), or geophilic (infecting soil). Members of all of these groups can infect hair, explaining the vulnerability of humans to infection resulting from exposure to infected humans, animals, or soil.

Wood’s lamp examination is useful for detection of *Microsporum*-related tinea capitis cases, as these infections will emit green light upon UV illumination. The majority of

tinea capitis cases, however, can be linked to *Trichophyton* species (Abdel-Rahman and Nahata, 1997), which are nonfluorescent and can be more challenging to diagnose. Recent diagnostic advances use molecular biology techniques, such as PCR analysis of the DNA sequences of nuclear ribosomal components, to identify specific species (Yoshida *et al.* 2006).

#### Treatment strategies

Systemic treatments for ringworm are considerably more effective than topical treatments, as the antifungal remedy needs to penetrate into the hair follicle. The most common regimen consists of prolonged dosing with griseofulvin, with addition of topical steroids if needed to control inflammation (Elewski, 2000). Adjunctive topical antifungal therapy, such as shampoos containing pyriithione zinc, selenium sulfide, or ketoconazole, can decrease the number of viable fungi shed from an infected scalp (Higgins *et al.*, 2000) and reduce the risk of transmission of the infection to other people.

### PSORIASIS

Psoriasis is a chronic, relapsing inflammatory disease that affects at least 2% of the population worldwide, with 50% of those cases involving the scalp (Sinclair *et al.*, 1999). The lack of UV exposure and frequency of friction injury to the scalp may contribute to the scalp’s propensity to develop clinically evident psoriatic features (Elewski, 2005). Psoriasis observed on the scalp could be an indication of psoriatic arthritis, as anywhere from 6 to 39% of those with psoriasis develop inflammation of the joints (Myers *et al.*, 2006).

#### Symptoms

Psoriasis of the scalp most commonly presents as well-circumscribed, red, scaly plaques, and papules covered by a silver-gray scale. Similar lesions may appear on other body parts, which can aid in diagnosis. Pruritus and burning may accompany the lesions and the severity can fluctuate with time. Hair shafts may appear funneled together, producing what is known as the “tepee sign” (DeVillez, 1994). Hair shafts may also be dry and brittle, and, in some cases, the disease process leads to telogen effluvium, causing extensive hair loss (Comaish, 1969).

Videodermoscopy has recently been used clinically to assess features of psoriasis. This technique revealed an extensive array of red dots, believed to relate to tortuous capillaries in the dermal papilla, in all cases of psoriasis. This approach may offer a new diagnostic option for assessment of clinically challenging cases (Ross *et al.*, 2006).

#### Etiology

The etiology of psoriasis is not clearly understood; however, individual genetic predisposition is generally acknowledged to play a role (Mrowietz *et al.*, 2006). Therefore, a complete family history should be taken and evaluated with regard to previous skin and rheumatologic conditions. Like seborrheic dermatitis, psoriasis involves hyperproliferation, or rapid cell turnover in the epidermis (Sinclair *et al.*, 1999).

### Treatment strategies

Psoriasis is often a life-long condition that warrants long-term treatment strategies and it can be difficult to treat. Shampoos containing keratolytics, such as salicylic acid, can be useful for assisting in the removal of built-up scales. Other common treatments include corticosteroids, vitamin D<sub>3</sub> analogs, retinoids, topical coal tar preparations, anthralin, phototherapy, and immunobiologic agents. Many of these agents are either unpleasant to use (e.g., coal tar shampoos) or can be associated with adverse effects (e.g., drug therapies). Topical treatments are common for milder forms of psoriasis, whereas phototherapy and systemic treatments are used for more severe cases (Gottlieb, 2005). It is commonly thought that tachyphylaxis, the decreasing response to a drug after administration of a few doses, is often seen during treatment with corticosteroids (du Vivier and Stoughton, 1975). However, a recent report suggests that the failure of corticosteroids to clear psoriasis may not be tachyphylaxis but, instead, related to therapeutic efficacy and/or patient compliance (Miller *et al.* 1999).

### PEDICULOSIS CAPITIS

Pediculosis capitis, otherwise known as head lice, is the infestation of the scalp and hair by *Pediculus humanus capitis*; this infestation afflicts millions of people worldwide. It occurs across all socioeconomic groups and may be more common in crowded urban areas (Orion *et al.*, 2006). Girls aged 3–12 are affected most often. In the United States, African Americans have a lower rate of infestation than other races, possibly due to the use of pomades and the curled-shape of the hair (Ko and Elston, 2004). Like tinea capitis, the prevalence is highest among school-aged children, and appears to be on the rise (Chosidow, 2000). Transmission occurs through shared combs and brushes and direct contact with infected hairs, headgear, pillows, and clothing.

### Clinical features

In cases of pediculosis capitis, close visual examination of the scalp will reveal the eggs of the lice as small white nits adhering to the hair shafts, most commonly behind the ears and at the nape of the neck. Microscopic assessment of an infected hair can easily confirm the diagnosis. Movement of adult lice may be visible with the naked eye. However, the search for live adult lice may take time as the majority of infected scalps may have no more than 10 adult insects (Orion *et al.*, 2006). Pruritus is consistently reported and can lead to excoriations and secondary infections. The infestation may be accompanied by erythema, and papules may also be observed on the back of the patient's neck (Powell *et al.*, 2002).

### Etiology

*Pediculus humanus capitis* are blood-sucking insects that live on the head of the host. A sheath 1–2 mm from the scalp envelops the nit and the hair shaft, so the nit is firmly cemented to the hair. Lice hatch within a week and mature to adults within the following week. The spread of the disease is most dependent on the matured adult lice (Ko and Elston, 2004).

### Treatment strategies

Treatment involves a combination of chemical and mechanical approaches. Malathion, natural pyrethrins, permethrin, phenothrin, and lindane, are commonly used insecticides that can be delivered through shampoos or topical treatments. Emerging resistance of the insect to these chemicals is a concern, though, and resistance appears to vary with geography. Therefore, a combination of chemical agents with adjunctive mechanical treatment is common. Hair should be combed with a fine-toothed comb every 3–4 days for 2 weeks to remove lice as they hatch and before they reach maturity (Orion *et al.*, 2006). The environment must also be addressed to avoid reinfestation from contaminated hats, hair brushes, or bedding. People living in close proximity to infested individuals should also be examined and treated as appropriate to prevent the spread of lice.

### SUMMARY

In many cases, careful clinical examination and consideration of the signs and symptoms will permit determination of the cause, whereas other cases have benefited from advances in diagnostic and microbiological techniques (i.e., videodermoscopy for psoriasis confirmation and PCR for identification of *Microsporum* or *Trichophyton* in the diagnosis of tinea capitis). Similar scientific advances have also aided classification of the specific microbes involved in dandruff/seborrheic etiology: *Malassezia globosa* and *Malassezia restricta*.

Although not typically associated with systemic medical effects, scalp conditions with visible flaking have a negative impact on the patient's quality of life, and should be diagnosed and treated. Accurate diagnosis is important to ensure proper treatment as a number of common scalp conditions are characterized by flaking and itch. Furthermore, treatments for these conditions need to be both convenient and cosmetically acceptable to the patient to promote patient compliance and adherence to treatment.

### CONFLICT OF INTEREST

The author received an honorarium for consultant's services from Procter & Gamble towards the preparation of this article.

### REFERENCES

- Abdel-Rahman SM, Nahata MC (1997) Treatment of tinea capitis. *Ann Pharmacother* 31:338–48
- Arenas R, Toussaint S, Isa-Isa R (2006) Kerion and dermatophytic granuloma. Mycological and histopathological findings in 19 children with inflammatory tinea capitis of the scalp. *Int J Dermatol* 45:215–9
- Aron-Brunetiere R, Dompmartin-Pernot D, Drouhet E (1977) Treatment of pyiriais capitis (dandruff) with econazole nitrate. *Acta Derm Venereol (Stockh)* 57:77–80
- Cardin C (1998) Isolated dandruff. In: Baran R, Maibach H (eds). *Text book of Cosmetic Dermatology*. Malden, MA: Blackwell Science, 193–200
- Comaish S (1969) Autoradiographic studies of hair growth in various dermatoses: investigations of a possible circadian rhythm in normal hair growth. *Br J Dermatol* 81:283–5
- Chosidow O (2000) Scabies and pediculosis. *Lancet* 355:819–26
- DeVilleville RL (1994) Infectious, physical, and inflammatory causes of hair and scalp abnormalities. In: Olsen EA (ed). *Disorders of Hair Growth: Diagnosis and Treatment*. New York: McGraw-Hill Inc., 71–90

- Elewski BE (2000) Tinea capitis: a current perspective. *J Am Acad Dermatol* 42:1–20
- Elewski BE (2005) Clinical diagnosis of common scalp disorders. *J Investig Dermatol Symp Proc* 10:190–3
- Farthing CF, Staughton RCD (1985) Skin disease in homosexual patients with acquired immune deficiency syndrome (AIDS) and lesser forms of human T cell leukaemia virus (HTLV III) disease. *Clin Exp Dermatol* 10:3–12
- Gemmer CM, DeAngelis YM, Theelen B, Boekhout T, Dawson TL (2002) Fast, non-invasive method for molecular detection and differentiation of *Malassezia* yeast species on human skin and application of the method to dandruff microbiology. *J Clin Microbiol* 40:3350–7
- Gottlieb AB (2005) Therapeutic options in the treatment of psoriasis and atopic dermatitis. *J Am Acad Dermatol* 53:S3–16
- Hainer BL (2003) Dermatophyte infections. *Am Fam Physician* 67:101–8
- Higgins EM, Fuller LC, Smith CH (2000) Guidelines for the management of tinea capitis. *Br J Dermatol* 143:53–8
- Ko CJ, Elston DM (2004) Pediculosis. *J Am Acad Dermatol* 50:1–12
- Miller JJ, Roling D, Margolis D, Guzzo C (1999) Failure to demonstrate therapeutic tachyphylaxis to topically applied steroids in patients with psoriasis. *J Am Acad Dermatol* 41:546–9
- Mrowietz U, Elder JT, Barker J (2006) The importance of disease associations and concomitant therapy for the long-term management of psoriasis patients. *Arch Dermatol Res* 298:309–19
- Myers WA, Gottlieb AB, Mease P (2006) Psoriasis and psoriatic arthritis: clinical features and disease mechanisms. *Clin Dermatol* 24: 438–447
- Orion E, Marcos B, Davidovici B, Wolf R (2006) Itch and scratch: scabies and pediculosis. *Clin Dermatol* 24:168–75
- Powell J, Stone N, Dawber RPR (2002) Infections and infestations of the hair and scalp. In: *An Atlas of Hair and Scalp Diseases*. New York: The Parthenon Publishing Group, 53–70
- Ross EK, Vincenzi C, Tosti A (2006) Videodermoscopy in the evaluation of hair and scalp disorders. *J Am Acad Dermatol* 55:799–806
- Shuster S (1984) The aetiology of dandruff and the mode of action of therapeutic agents. *Br J Dermatol* 111:235–42
- Schwartz JR, Cardin CW, Dawson TL (2004) Dandruff and seborrheic dermatitis. In: Baron R, Maibach HI (eds). *Textbook of Cosmetic Dermatology*. 3rd edn Taylor & Francis Inc.: New York, 259–72
- Sinclair RD, Banfield CC, Dawber RPR (1999) Inflammatory dermatoses of the scalp. In: *Handbook of diseases of the hair and scalp*. Oxford: Blackwell Science, 205–6
- Smith KJ, Skelton HG, Yeager J, Ledsky R, McCarthy W, Baxter D (1994) Cutaneous findings in HIV-1 positive patients: a 42-month prospective study. *J Am Acad Dermatol* 31:746–54
- du Vivier A, Stoughton RB (1975) Tachyphylaxis to the action of topically applied corticosteroids. *Arch Dermatol* 111:581–3
- Warner RR, Schwartz JR, Boissy Y, Dawson TL (2001) Dandruff has an altered stratum corneum ultrastructure that is improved with zinc pyrithione shampoo. *J Am Acad Dermatol* 45:897–903
- Yoshida E, Makimura K, Mirhendi H, Kaneko T, Hiruma M, Kasai T *et al.* (2006) Rapid identification of *Trichophyton tonsurans* by specific PCR based on DNA sequences of nuclear ribosomal internal transcribed spacer (ITS) 1 region. *J Dermatol Sci* 42:225–30