

- 2 Marsh RJ, Cooper M. Acyclovir and steroids in herpes zoster keratouveitis. *Br J Ophthalmol* 1984; **68**(12): 904–905.
- 3 McGill J, Chapman C. A comparison of topical acyclovir with steroids in the treatment of herpes zoster keratouveitis. *Br J Ophthalmol* 1983; **67**(11): 746–750.
- 4 Herbort CP, Buechi ER, Piguet B, Zografos L, Fitting P. High-dose oral acyclovir in acute herpes zoster ophthalmicus: the end of the corticosteroid era. *Curr Eye Res* 1991; **10**(Suppl): 171–175.
- 5 Dworkin RH, Schmader KE. Treatment and prevention of postherpetic neuralgia. *Clin Infect Dis* 2003; **36**(7): 877–882.

L Clearkin

Eye Department, Arrowse Park Hospital, Wirral University Teaching Hospital NHST, Wirral, UK  
E-mail: clearl@liv.ac.uk

*Eye* (2014) **28**, 1522–1523; doi:10.1038/eye.2014.204;  
published online 5 September 2014

### Sir, Response to Dr Clearkin

We thank Dr Clearkin for his comments<sup>1</sup> on our recent editorial with regard to the implementation of shingles vaccine in UK.<sup>2</sup> Our intention was to comment on the potential benefits of vaccination rather than provide an overview of evidence-based practice for the management of zoster-associated anterior uveitis.

However, we mention in the paper the use of topical steroids in the treatment of zoster-associated anterior uveitis, a practice that is recommended in the current *Oxford Handbook of Ophthalmology*.<sup>3</sup>

This is a contentious area and differences of opinion remain in the use of topical steroids in the treatment of zoster-related anterior uveitis. It is sadly not as clear cut as Clearkin's comments would suggest. The papers cited from Marsh and Cooper<sup>4</sup> and McGill and Chapman<sup>5</sup> refer to studies evaluating topical acyclovir *vs* topical steroid in the treatment of zoster keratouveitis and not just zoster-related anterior uveitis. Although they show a statistical benefit of topical antiviral over topical steroid in the management of keratitis, the data for those with anterior uveitis did not show a statistical benefit. The authors themselves agree that there remains a role for topical steroids in patients who do not respond adequately to topical acyclovir.<sup>4,5</sup>

As Clearkin mentions, Herbort *et al*<sup>6</sup> show that the use of oral acyclovir in the treatment of early zoster is beneficial, has extensive external evidence to support, and has been generally adopted as best practice by all. Many other authors<sup>7–9</sup> however continue to advocate the use of topical steroids in the treatment of zoster-related anterior uveitis. We therefore feel this area will remain open for discussion until more robust data, specific for zoster-associated anterior uveitis, are available.

We would however agree about Clearkin's comments on the potential benefits of the use of gabapentin for pain control in post-herpetic neuralgia.<sup>10</sup>

### References

- 1 Clearkin L. Comment on 'Herpes zoster ophthalmicus reduction: implementation of shingles vaccination in the UK'. *Eye* 2014; **28**(12): 1522–1523.
- 2 Potts A, Williams GJ, Olson JA, Pollock KG, Murdoch H, Cameron JC. Herpes zoster ophthalmicus reduction: implementation of shingles vaccination in the UK. *Eye (Lond)* 2014; **28**(3): 247–248.
- 3 *Oxford Handbook of Ophthalmology*. Oxford University Press 2009, Print ISBN-13 9780199552641. 10.1093/med/9780199552641.001.0001.
- 4 Marsh RJ, Cooper M. Acyclovir and steroids in herpes zoster keratouveitis. *Br J Ophthalmol* 1984; **68**(12): 904–905.
- 5 McGill J, Chapman C. A comparison of topical acyclovir with steroids in the treatment of herpes zoster keratouveitis. *Br J Ophthalmol* 1983; **67**(11): 746–750.
- 6 Herbort CP, Buechi ER, Piguet B, Zografos L, Fitting P. High-dose oral acyclovir in acute herpes zoster ophthalmicus: the end of the corticosteroid era. *Curr Eye Res* 1991; **10**(Suppl): 171–175.
- 7 Van der Lelij A, Ooijman FM, Kijlstra A, Rothova A. Anterior uveitis with sectoral iris atrophy in the absence of keratitis. A distinct clinical entity among herpetic eye diseases. *Ophthalmology* 2000; **107**: 1164–1170.
- 8 Cunningham Jr, ET. Diagnosing and treating herpetic anterior uveitis. *Ophthalmology* 2000; **107**(12): 2129–2130.
- 9 Miserocchi E, Nadia K, Waheed NK, Dios E, Christen W, Jesus Merayo J *et al*. Visual outcome in herpes simplex virus and varicella zoster virus uveitis: a clinical evaluation and comparison. *Ophthalmology* 2002; **109**(8): 1532–1537.
- 10 Dworkin RH, Schmader KE. Treatment and prevention of postherpetic neuralgia. *Clin Infect Dis* 2003; **36**(7): 877–882.

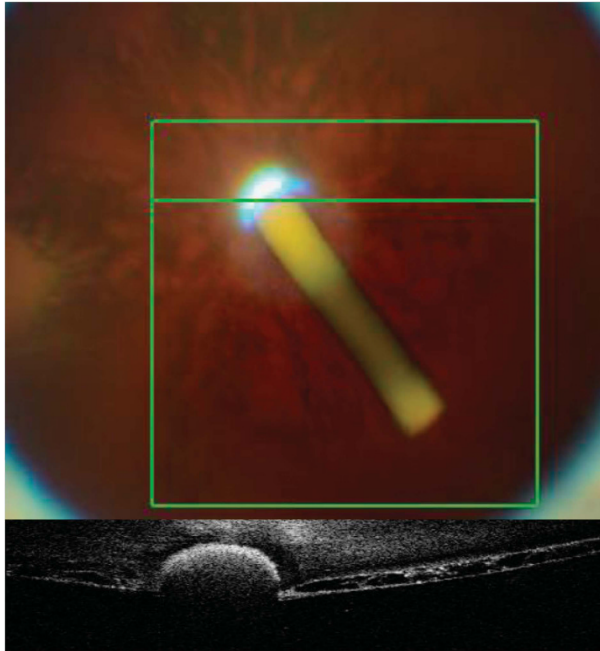
G Williams<sup>1</sup> and JA Olson<sup>2</sup>

<sup>1</sup>Tennant Institute of Ophthalmology, Gartnavel General Hospital, Glasgow, UK  
<sup>2</sup>The Eye Clinic, Aberdeen Royal Infirmary, Aberdeen, UK  
E-mail: graeme.williams@nhs.net

*Eye* (2014) **28**, 1523; doi:10.1038/eye.2014.205; published online 5 September 2014

### Sir, Vitreoretinal surgery for inadvertent intralenticular Ozurdex implant

We read with interest the recent report by Chhabra *et al*.<sup>1</sup> We would like to share a similar rare case that required early vitreoretinal intervention. In our case, a 62-year-old with left branch retinal vein occlusion and macular oedema underwent an Ozurdex injection in another eye unit. The implant was inadvertently injected into the crystalline lens, and the patient presented 2 weeks later



**Figure 1** (Upper) Transillumination photograph showing posterior subcapsular cataract and intralenticular Ozurdex implant. (Lower) OCT scan of the crystalline lens showing posterior lens thickening and vacuolation, with the Ozurdex implant embedded within a posterior capsular defect.

to our clinic. The OCT scan confirmed an intralenticular location of the steroid implant with a posterior subcapsular cataract (Figure 1). The OCT scan of the lens confirmed the posterior capsular defects and extent of the cataract. Visual acuity was 2/60 and the OCT scan was unable to penetrate the cataract for macular evaluation. There was no fundus view, and the ultrasound scan showed no retinal breaks. On the basis of the significant cataract, inability to visualise the retina and evaluate the macular oedema, surgery was planned. Intraoperatively, the Ozurdex implant was adherent to the posterior capsule with entry and exit capsular defects present (Figure 1). After nucleus removal, a larger capsule rupture was noted around the Ozurdex implant impact site, and soft lens matter dropped into the vitreous. A complete 23-G vitrectomy was performed, and the Ozurdex implant was resited within the vitreous cavity and a sulcus lens implant inserted. Visual acuity 1 week post surgery was 6/24 with macular oedema, and the patient remains under follow-up at Moorfields. The case by Chhabra *et al*<sup>1</sup> and our report demonstrate two different scenarios for the management of such a rare complication. We believe that the clinical decision to observe or operate early should be based on the ability of the clinician to manage the primary underlying condition of macular oedema, and this requires relatively clear media.

#### Conflict of interest

The authors declare no conflict of interest.

#### Reference

- 1 Chhabra R, Kopsidas K, Mahmood S. Accidental insertion of dexamethasone implant into the crystalline lens—12 months follow-up. *Eye (Lond)* 2014; **28**: 624–625.

K Chalioulias<sup>1</sup> and MMK Muqit<sup>1,2</sup>

<sup>1</sup>Vitreoretinal Service, Moorfields Eye Hospital, London, UK

<sup>2</sup>Institute of Ophthalmology, University College London, London, UK

E-mail: Mahi.Muqit@Moorfields.nhs.uk

*Eye* (2014) **28**, 1523–1524; doi:10.1038/eye.2014.192; published online 8 August 2014

#### Sir, Reply to 'Vitreoretinal surgery for inadvertent intralenticular Ozurdex implant'

It is with great interest that we read another case of Ozurdex implant malpositioned in the crystalline lens, as reported by Chalioulias and Muqit.<sup>1</sup>

Although the complication is rare, with increasing use of intravitreal implants, the number of accidental malpositioning in the crystalline lens may also increase.

Cataract formation is evidently the major consideration in such cases, due to the active pharmacological ingredient being a steroid in close proximity to the lens matter in addition to the mechanical trauma. The two cases however suggest a variable pace of cataract progression underpinning relevant management decisions.

We fully agree with the authors that clinical management of each case should be individualized and based on concomitant findings and the development of any side effects.

The authors have taken an approach of early intervention prompted by rapid formation of dense cataract precluding fundal view. In our case, however, gradual cataract progression and media clarity for an extended period of time allowed for an approach of careful watch and wait.

During this course the therapeutic effects of the implant, albeit intralenticular, became quite obvious with resolution of CMO.

As an update on our case, we report no recurrence of CMO at 21 months follow-up with no need for any additional therapeutic intervention.

It was an engrossing case report and we commend the authors on a positive outcome.

#### Conflict of interest

The authors declare no conflict of interest.

#### Reference

- 1 Chalioulias K, Muqit MMK. Vitreoretinal surgery for inadvertent intralenticular Ozurdex implant. *Eye* 2014; **28**(12): 1523–1524.