

**Sir,
Response to Dr Soleimani**

My co-authors and I thank Dr Soleimani¹ for his comments on our article.² We share the same opinion regarding the possible role of an ischemia of the iris root.^{3,4} The mydriasis induced by topical atropine 1% is indeed one of the possible causes of iris ischemia in the UZS. Its implication was actually suspected for many cases of UZS, including the first description of this syndrome.⁵⁻⁷ But these cases are anecdotal compared to the number of patients treated with atropine eye drops for anterior uveitis and who never developed any definite mydriasis. Thus, we believe that topical atropine eye drops are not sufficient enough to cause UZS. They only serve as a 'revealer'. But it requires a prior impairment of the iris root and/or of the ciliary body due to a surgery procedure, a pathology, or some other circumstances. It is this prior impairment of the ciliary body that we attribute to cidofovir.

Conflict of interest

The authors declare no conflict of interest.

References

- 1 Soleimani M, Tabatabaei SA, Moghimi S. Urrets – Zavalía syndrome as a complication of ocular hypotonia due to intravenous cidofovir treatment. *Eye* 2014; **28**(11): 1384.
- 2 Orssaud C, Wermert D, Roux A, Laccourreye O, Sors H, Roche O *et al.* Urrets-Zavalía syndrome as a complication of ocular hypotonia due to intravenous cidofovir treatment. *Eye (Lond)* 2014; **28**(6): 776–777.
- 3 Maurino V, Allan BDS, Stevens JD, Tuft SJ. Fixed dilated pupil (Urrets-Zavalía syndrome) after air/gas injection after deep lamellar keratoplasty for keratoconus. *Am J Ophthalmol* 2002; **133**(2): 266–268.
- 4 Aralikatti AKV, Tomlins PJ, Shah S. Urrets-Zavalía syndrome following intracameral C3F8 injection for acute corneal hydrops. *Clin Exp Ophthalmol* 2008; **36**(2): 198–199.
- 5 Urretz Zavalía AJ. Fixed dilated pupil, iris atrophy and secondary glaucoma. *Am J Ophthalmol* 1963; **56**: 257–265.
- 6 Bourcier T, Laplace O, Touzeau O, Moldovan SM, Borderie V, Laroche L. Syndrome d'Urrets-Zavalía. *J Fr Ophthalmol* 2001; **24**(3): 303–308.
- 7 Fournié P, Ponchel C, Malecaze F, Arné J. Fixed dilated pupil (urrets-zavalía syndrome) and anterior subcapsular cataract formation after descemet stripping endothelial keratoplasty. *Cornea* 2009; **28**(10): 1184–1186.

C Orssaud¹, D Wermert², A Roux^{2,3}, O Laccourreye^{3,4}, H Sors², O Roche⁵ and JL Dufier^{1,3,5}

¹Consultation d'Ophtalmologie, Hôpital Européen Georges Pompidou, Assistance Publique Hôpitaux de Paris, Paris, France

²Service de Pneumologie-soins intensifs, Hôpital Européen Georges Pompidou, Assistance Publique Hôpitaux de Paris, Paris, France

³Faculté de Médecine Paris Descartes, Université Paris Descartes, Paris, France

⁴Service d'ORL, Hôpital Européen Georges Pompidou, Assistance Publique Hôpitaux de Paris, Paris, France

⁵Service d'Ophtalmologie, Hôpital Necker—Enfants Malades, Assistance Publique Hôpitaux de Paris, Paris, France

E-mail: christophe.orssaud@egp.aphp.fr

Eye (2014) **28**, 1385; doi:10.1038/eye.2014.167; published online 25 July 2014

**Sir,
Intraoperative modifications required during femtosecond laser-assisted cataract surgery for lamellar cataracts**

Lamellar cataract usually develops after the establishment of fixation, involves the lamellae surrounding the fetal nucleus peripheral to the Y sutures, and is usually progressive and bilateral.¹ Herein, we describe challenges in intraoperative imaging and the software modifications required for successful femtosecond laser cataract surgery (FLACS) in such cataracts.

Case report

A 26-year-old male presented with bilateral lamellar cataracts visualized on slitlamp examination and Scheimpflug Imaging (Figure 1). His best-corrected visual acuity was 20/60 OD and 20/40 OS. He elected to undergo bilateral FLACS followed by implantation of a multifocal intraocular lens (IOL).

During femtosecond laser treatment (Catalys Precision Laser System, Optimedica, Sunnyvale, CA, USA), in-built

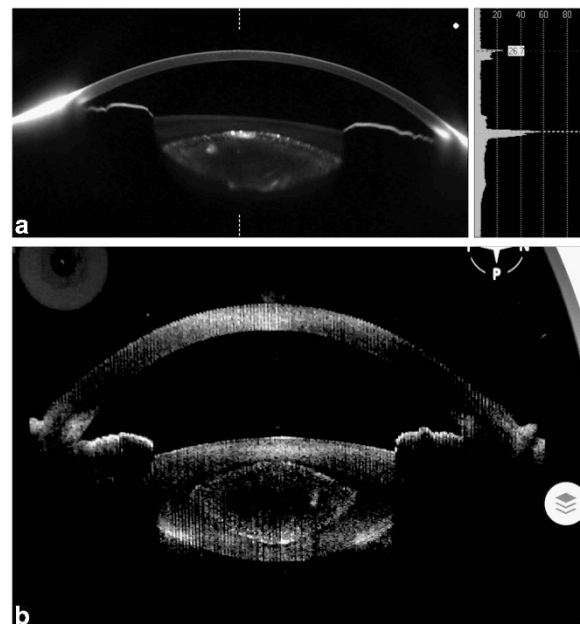


Figure 1 Preoperative Scheimpflug image (a) and intraoperative anterior-segment optical coherence tomography (AS-OCT) (b) demonstrating the lamellar cataract.

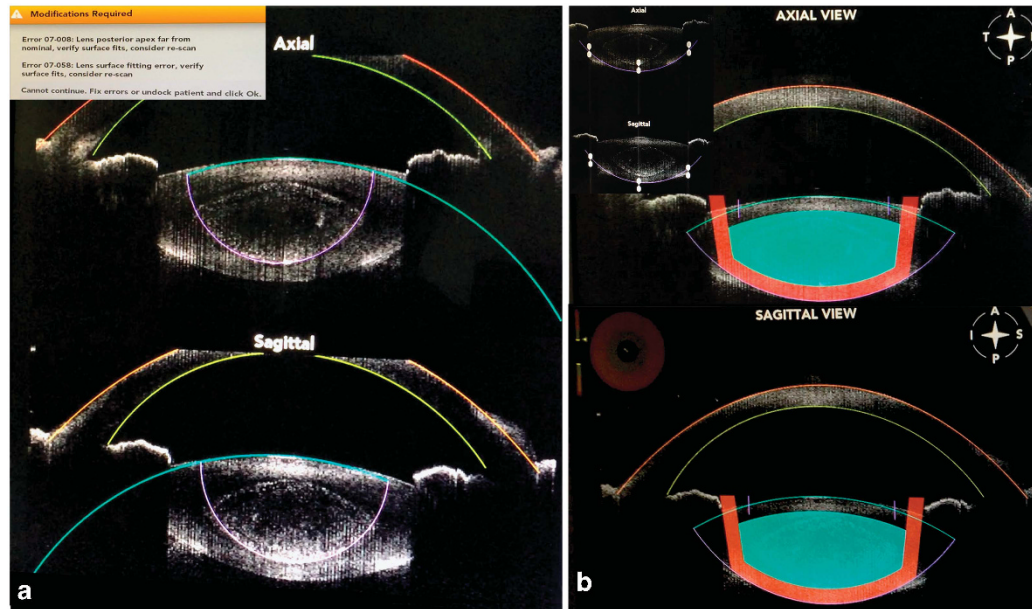


Figure 2 (a) Segmentation error (inset) using intraoperative AS-OCT that incorrectly identified the posterior boundary of the lamellar portion of the cataract as the posterior lens margin. (b) Manual segmentation (inset) permitted accurate delineation of anatomical landmarks including the posterior lens margin with an adequate safety zone, which allowed the femtosecond laser to proceed with clear corneal incisions, limbal relaxing incisions, anterior capsulotomy, and lens fragmentation.

spectral-domain anterior-segment optical coherence tomography imaging software incorrectly detected the posterior margins of the lamellar portion of the cataract and the posterior lens margin. Lens surface fitting error messages were noted precluding further treatment (Figure 2a). Adjustments were made with the software calipers to manually delineate the correct posterior boundary of the lens with adequate safety zones (Figure 2b). Both eyes had similar lens morphology and densitometry on Scheimpflug images and a similar error was encountered in the other eye as well. The laser energy settings were maximized with three passes and set at five micro-joules. Lens fragmentation was performed using the quadrant grid pattern with a 350- μm grid size.

Following the femtosecond procedure, the capsulotomy was found to be free floating and nuclear removal was completed using the irrigation–aspiration probe only. A single-piece multifocal IOL ZMBOO with a +4D add was placed in the capsular bag. At the 2-week follow-up his best-corrected vision was 20/20 OU and J1 OU.

Comment

FLACS has been used for pediatric cataracts.^{2,3} Primary multifocal IOL implantation has been shown to be effective for teenage-onset bilateral cataracts.^{4,5} This report highlights intraoperative modifications required in cases of lamellar cataracts to accurately identify the lens anatomic boundaries permitting successful FLACS. It is possible that this issue can be encountered with other types of congenital and acquired cataracts as well and warrants careful confirmation of the anatomical boundaries and readjustment as required. It is important for surgeons using FLACS to be aware of how laser and

software settings may need to be modified intraoperatively.

Conflict of interest

The authors declare no conflict of interest.

Acknowledgements

This study was supported in part by unrestricted funds to the Department of Ophthalmology from Research to Prevent Blindness (RPB, NY) and the Heed Ophthalmic Foundation.

References

- 1 Parks MM, Johnson DA, Reed GW. Long-term visual results and complications in children with aphakia. A function of cataract type. *Ophthalmology* 1993; **100**(6): 826–840.
- 2 Dick HB, Schultz T. Femtosecond laser-assisted cataract surgery in infants. *J Cataract Refract Surg* 2013; **39**(5): 665–668.
- 3 Schultz T, Ezeanosike E, Dick HB. Femtosecond laser-assisted cataract surgery in pediatric Marfan syndrome. *J Refract Surg* 2013; **29**(9): 650–652.
- 4 Wilson ME, Johnson WJ, Trivedi RH. Primary multifocal intraocular lens implantation for teenage-onset bilateral cataracts: visual results a decade after surgery in 3 siblings. *J AAPOS* 2013; **17**(6): 623–625.
- 5 Wilson ME, Trivedi RH, Burger BM. Eye growth in the second decade of life: implications for the implantation of a multifocal intraocular lens. *Trans Am Ophthalmol Soc* 2009; **107**: 120–124.

DS Grewal^{1,2,3}, S Basti² and SPS Grewal¹

¹Grewal Eye Institute, Chandigarh, India

²Department of Ophthalmology, Northwestern University Feinberg School of Medicine, Chicago, IL, USA

³Department of Ophthalmology, Duke University Medical Center, Durham, NC, USA
E-mail: dilraj@gmail.com

Eye (2014) **28**, 1385–1387; doi:10.1038/eye.2014.184;
published online 1 August 2014

Sir,
Choroidal thickness alterations in obstructive sleep apnea–hypopnea syndrome (OSAS)

We would like to congratulate Xin *et al*¹ on their prospective, observational case–control study of retinal and choroidal thickness (CT) evaluation by spectral domain optical coherence tomography in patients with obstructive sleep apnea–hypopnea syndrome (OSAS). The study presents, for the first time, CT alterations in OSAS patients; however, we think that some important issues need more thorough discussion.

The choroid of the eye is one of the most highly vascularized tissues of the body, and it is the major blood supply to the retina.² It is known that the choroid is prone to suffer from microvascular atherosclerotic changes and changes inherent to other microvascular systems.³ However, the authors did not exclude the subjects having systemic diseases except diabetes, and about 50% of the participants were indicated to have hypertension. Also, hyperlipidemic subjects and smokers were not excluded, although both of them were shown to affect CT.^{4,5} As body mass index of OSAS group in their study is significantly higher than that of controls and systemic diseases are often comorbid with OSAS, expecting hypercholesterolemia more in OSAS group is reasonable. It is obvious that including patients having hypertension and other systemic diseases may affect the conclusion of the CT studies. Although the number of the patients and controls having the hypertension are matched, severity and duration of the systemic diseases could not be standardized. Therefore, it should be kept in mind that, CT alterations seen in Xin *et al*'s study might be due to the underlying systemic diseases and concomitant treatment in patients.

Not only systemic diseases, but also ocular conditions including axial length and refractive error are known to influence CT.⁶ The authors stated in their study that age and diopter were corrected using covariance analysis before comparing CT between the groups. However, spherical equivalent refraction is not stable throughout life. Myopic shifts can occur especially in elderly patients because of nuclear cataract progression. In this study, OSAS patients tended to be older than controls, although not significantly. So, considering axial length measurements instead of refractive status would be more accurate particularly in old population. Thus, we also wonder that whether the authors paid attention to the concomitant nuclear sclerosis in their patients that might

influence the refractive status and consequently the results of their study.

Conflict of interest

The authors declare no conflict of interest.

References

- Xin C, Wang J, Zhang W, Wang L, Peng X. Retinal and choroidal thickness evaluation by SD-OCT in adults with obstructive sleep apnea-hypopnea syndrome (OSAS). *Eye* 2014; **28**: 415–421.
- Nickla DL, Wallman J. The multifunctional choroid. *Prog Retin Eye Res* 2010; **29**: 144–168.
- Wong IY, Koizumi H, Lai WW. Enhanced depth imaging optical coherence tomography. *Ophthalmic Surg Lasers Imaging* 2011; **42**: S75–S84.
- Wong IY, Wong RL, Zhao P, Lai WW. Choroidal thickness in relation to hypercholesterolemia on enhanced depth imaging optical coherence tomography. *Retina* 2013; **33**: 423–428.
- Sızmaç S, Küçükerdönmez C, Pınarcı EY, Karalezli A, Canan H, Yılmaz G. The effect of smoking on choroidal thickness measured by optical coherence tomography. *Br J Ophthalmol* 2013; **97**: 601–604.
- Goldenberg D, Moisseiev E, Goldstein M, Loewenstein A, Barak A. Enhanced depth imaging optical coherence tomography: choroidal thickness and correlations with age, refractive error, and axial length. *Ophthalmic Surg Lasers Imaging* 2012; **43**: 296–301.

HA Bayhan and S Aslan Bayhan

Ophthalmology Department, Bozok University Faculty of Medicine, Yozgat, Turkey
E-mail: alihanbayhan@hotmail.com

Eye (2014) **28**, 1387; doi:10.1038/eye.2014.191; published online 1 August 2014

Sir,
Transient visual loss due to reversible ‘pending’ central retinal artery occlusion in occult giant cell arteritis

Giant cell arteritis (GCA) or temporal arteritis can cause profound and irreversible visual loss through anterior ischemic optic neuropathy (AION), posterior ischemic optic neuropathy, central retinal artery occlusion (CRAO), branch retinal artery occlusion (BRAO), choroidal infarction, and central nervous system stroke.¹ We present a case where permanent vision loss was prevented by prompt recognition of the condition seen on fluorescein angiography (FA). To our knowledge, this is the first report of fluorescein angiographic evidence of reversible retinal circulatory abnormalities associated with GCA.

Case report

A 62-year-old woman presented with complaints of complete loss of vision in the right eye on waking in the