

# Vitreous levels of somatostatin in patients with chronic uveitic macular oedema

A Fonollosa<sup>1</sup>, E Coronado<sup>2</sup>, R Catalan<sup>3</sup>,  
 M Gutierrez<sup>3</sup>, C Macia<sup>2</sup>, MA Zapata<sup>2</sup>,  
 N Martinez-Alday<sup>1</sup>, R Simo<sup>4</sup> and J Garcia-Arumi<sup>2</sup>

## Abstract

**Purpose** Intravitreal somatostatin (SST) levels are decreased in patients with diabetic macular oedema. This deficit may be involved in the pathogenesis of this condition. The aim of the present study was to determine SST concentration in the vitreous fluid of patients with chronic uveitic macular oedema (CUMO) and quiescent intraocular inflammation.

**Methods** Plasma and vitreous fluid samples were obtained during vitrectomy from 11 eyes of patients with CUMO and from 42 eyes of control subjects (idiopathic epiretinal membrane, macular hole). SST concentration was measured by radioimmunoassay. **Statistics:**  $\chi^2$ -square test, Mann–Whitney *U*-test, Wilcoxon test, Spearman's rank correlation coefficient, and multivariate linear regression models.

**Results** Plasma SST concentrations were similar in uveitic patients and controls (28.25 pg/ml (21.3–31) vs 28.7 pg/ml (22–29.5);  $P = 0.869$ ). A higher vitreous concentration of proteins was found in uveitic patients ( $1.59 \pm 0.38$  mg/ml vs  $0.73 \pm 0.32$  mg/ml,  $P < 0.0001$ ). Vitreous SST was markedly lower in uveitic patients, both in absolute terms and after adjusting for total intravitreal protein concentration (39.37 pg/ml (6.16–172) vs 486.73 pg/ml (4.7–1833),  $P < 0.0001$ ; 33.1 pg/mg (3.9–215.74) vs 629.75 pg/mg (6.91–2024),  $P < 0.0001$ ). No correlations were found between plasma and vitreous concentration of SST in either group ( $\rho = 0.191$ ,  $P = 0.57$  and  $\rho = 0.49$ ,  $P = 0.66$ ). There were no correlations between vitreous SST concentration and visual acuity or macular thickness in uveitic patients ( $\rho = 0.302$ ,  $P = 0.31$  and  $\rho = 0.45$ ,  $P = 0.13$ ).

**Conclusions** Intravitreal SST is decreased in patients with CUMO and quiescent intraocular inflammation. The deficit of SST

may have a role in the pathogenesis of this condition.

Eye (2012) 26, 1378–1383; doi:10.1038/eye.2012.161; published online 10 August 2012

**Keywords:** somatostatin; uveitic macular oedema; uveitis; blood-retinal barrier; inflammation

## Introduction

Macular oedema is a major cause of visual loss in patients with uveitis.<sup>1</sup> This condition occurs in two very different clinical scenarios: one in which intraocular tissues are actively inflamed, as in acute vitritis, retinitis, vasculitis, or anterior uveitis, and the other in which the inflammation is quiescent, but macular oedema persists as a chronic condition. The pathogenesis of uveitic macular oedema is not completely understood. The release and diffusion of cytokines may have a predominant role in the first scenario, but the exact factors and events responsible for the development of chronic macular oedema without active inflammation have not yet been identified.<sup>2</sup>

Somatostatin (SST) is a ubiquitous hormone that was initially identified as an inhibitory factor on the growth hormone axis.<sup>3</sup> SST and its receptors are expressed in the uvea, retinal pigment epithelium (RPE) and neuroretina, and the receptors are expressed in the vascular endothelium.<sup>4–6</sup> A role for SST in the maintenance of blood-retinal barrier integrity has been suggested based on its positive effect on apical-to-basal fluid transport across RPE cells.<sup>4</sup> In a previous study, we found lower vitreous levels and lower intraocular production of SST in patients with diabetic macular oedema, suggesting that SST deficit may contribute to oedema formation.<sup>7</sup> In addition, we showed that retinal neurodegeneration, which occurs before

<sup>1</sup>Department of Ophthalmology, Hospital de Cruces, Universidad del País Vasco, Barakaldo, Spain

<sup>2</sup>Department of Ophthalmology, Hospital Vall d'Hebron, Universidad Autonoma de Barcelona, Barcelona, Spain

<sup>3</sup>Department of Biochemistry, Hospital Vall d'Hebron, Universidad Autonoma de Barcelona, Barcelona, Spain

<sup>4</sup>Diabetes Research Unit, Endocrinology division, Hospital Vall d'Hebron, Universidad Autonoma de Barcelona, Barcelona, Spain

Correspondence: A Fonollosa, Department of Ophthalmology, Hospital de Cruces: Plaza de Cruces s/n, Universidad del País Vasco, Barakaldo, Vizcaya CP: 48903, Spain  
 Tel: +34 64 684 43 28;  
 Fax: +34 94 600 60 76.  
 E-mail: 36427afc@comb.es  
 or alejandro.fonollosacalduch@osakidetza.net

Received: 9 December 2011  
 Accepted in revised form: 9 July 2012  
 Published online: 10 August 2012

The present study was presented at the Association for Research in Vision and Ophthalmology (ARVO) Annual Meeting, Fort Lauderdale, Florida, May 2–6 2010.

vascular alterations develop, could be responsible for the decreased SST production in diabetic patients.<sup>5</sup> The aim of the present study was to determine the vitreous levels of SST in patients with chronic uveitic macular oedema (CUMO) and quiescent intraocular inflammation to evaluate whether there is a relationship between SST deficit and the development of this complication. As SST-28 is the main molecular variant in the vitreous fluid<sup>8</sup> it was selected as the best candidate to examine for this purpose.

The study and data accumulation were carried out with the approval of the ethics committee of hospital Vall d'Hebron and in accordance with the ethical standards laid down in the 1964 Declaration of Helsinki. Informed consent for the research was obtained from the patients before their inclusion in the study.

## Material and methods

### Patients

The study included 11 eyes from 11 patients with CUMO and 42 eyes from 42 control subjects in whom vitrectomy was performed. As vitrectomy is reported to be effective in the management of uveitic macular oedema,<sup>9</sup> we apply this therapeutic option in refractory cases. Vitrectomy in the controls was performed to treat idiopathic epiretinal membrane (19 patients) or idiopathic macular hole (23 patients). Macular oedema was diagnosed by optical coherence tomography (Stratus OCT 4.0, Zeiss-Humphrey Ophthalmic Systems, Dublin, CA, USA). Only patients with inactive intraocular inflammation for the previous 3 months were included. Anterior uveitis was considered inactive based on the criteria recommended by the SUN (Standardization of Uveitis Nomenclature) study group: Grade 0 cells in the anterior chamber.<sup>10</sup> Vitritis grade was assessed using Nussenblatt's standard photographs.<sup>11</sup>

Only cases with grade +1 or less were included. Patients with vasculitic changes considered to be active, such as perivascular sheathing with leakage on fluorescein angiography, retinal infiltrates, papillitis, or choroiditis, were not included. Patients who had previously undergone retinal photocoagulation, intravitreal treatments in the last 6 months, or intraocular surgery in the last 3 months were excluded, as were diabetic patients.

The clinical data of patients with uveitis, including demographics, type of uveitis according to the International Uveitis Study Group classification,<sup>12</sup> specific uveitic disease, systemic treatment at the time of vitreous tap, most recent visual acuity (VA, logMAR), macular thickness, and the duration of uveitis are shown in Table 1.

### Vitreous and blood samples

Standard 20-G three-port pars plana vitrectomy was performed in all patients. Undiluted vitreous samples (~1 ml) were obtained at the beginning of vitrectomy by aspiration into a 2 ml syringe attached to the vitreous cutter (Accurus 800 CS, Alcon, Irvine, CA, USA) with air infusion. Vitreous samples were transferred to sterile Eppendorf tubes, placed immediately on ice, and centrifuged at 12 000 g for 4 min; supernatants were stored at -80 °C. For the plasma determinations, blood samples were collected at the same time as vitrectomy. Blood was collected in BD Vacutainer tubes (Becton Dickinson, Madrid, Spain) containing aprotinin to prevent proteolysis and K3E as anticoagulant. Samples were centrifuged at 3000 g for 10 min at 4 °C and the separated plasma was stored at -80 °C until analysis.

### SST-28 assessment

SST-28 was measured by a competitive radioimmunoassay (RIA) (Phoenix Pharmaceuticals Inc., Burlingame, CA, USA)

**Table 1** Clinical data of patients with chronic uveitic macular oedema

Case	Age (years)	Sex	IUSG <sup>a</sup>	Aetiology	Treatment	Duration of uveitis (months)	VA (logMAR)	OCT ( $\mu$ m)
1	45	F	IU	Multiple sclerosis		108	0.7	348
2	59	F	PU	Idiopathic		96	0.3	531
3	51	M	PU	Behçet	Steroids methotrexate infliximab	36	1.3	624
4	47	M	PoU	Eales		102	1.3	565
5	56	M	IU	Idiopathic		38	0.4	310
6	77	F	IU	Sarcoid	Steroids	108	1	508
7	40	F	IU	Idiopathic	Steroids	42	0.7	545
8	32	F	IU	Idiopathic		11	1.3	670
9	86	M	IU	Sarcoid	Steroids	100	1	560
10	77	M	IU	Sarcoid	Steroids	98	0.3	555
11	75	M	PU	Idiopathic		132	1	425

Abbreviations: F, female; IU, intermediate uveitis; IUSG, International Uveitis Study Group; M, male; OCT, optical coherence tomography; PoU, posterior uveitis; PU, panuveitis; VA, visual acuity.

<sup>a</sup>Type of uveitis according to the International Uveitis Study Group.

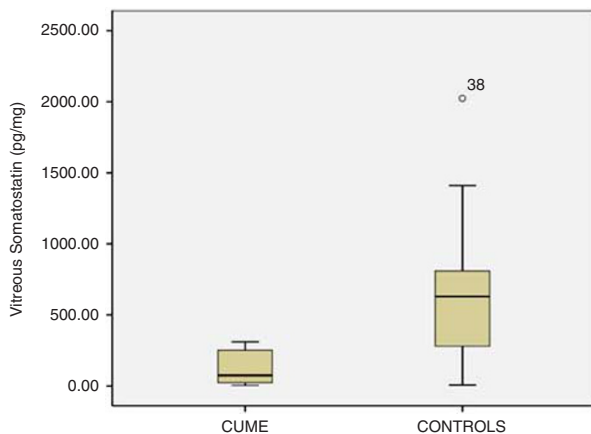
after an extraction-concentration procedure with octadecylsilyl silica columns. Briefly, samples were acidified with 1% trifluoroacetic acid (TFA, HPLC grade) in water and centrifuged. Columns were activated first with a solution of 60% acetonitrile in 1% TFA, and then with 1% TFA. After loading the samples, columns were slowly washed with 1% TFA and the peptide was eluted with 60% acetonitrile in 1% TFA. Eluates were lyophilized and reconstituted with RIA buffer. The SST-28 antiserum showed 100% cross-reaction with SST-28. The detection limit of the assay was 3.49 pg/tube at 20% binding and the 50% binding intercept was 9.39 pg/tube.

**Protein assessment**

The concentration of vitreous proteins was determined by a turbidimetric method (Cobas 6000, Roche Diagnostics, Basel, Switzerland) based on the benzethonium chloride reaction. The detection limit of the assay was 0.04 mg/ml.

**Statistical analysis**

Data are expressed as the mean and SD or as the median and range. Categorical variables were compared with the  $\chi^2$ -square test and continuous variables with the Mann-Whitney *U*-test or Wilcoxon test, when appropriate.



**Figure 1** Vitreous levels of SST after adjusting for intravitreal proteins in patients with CUMO and control patients.

Correlations were examined with Spearman’s rank correlation coefficient. A multivariate linear regression model was used to assess whether age had an influence on vitreous SST levels. Statistical significance was set at  $P < 0.05$ . All statistical analyses were performed with SPSS, version 13.0 (SPSS Inc., Chicago, IL, USA).

**Results**

There were 6 women and 5 men in the CUMO group and 17 women and 25 men in the control group. Median age in uveitic patients was 56 (32–86) years and 55 (28–86) in control subjects. Age and sex distribution showed no statistical differences between the groups ( $P = 0.801$ ,  $P = 0.765$ ). There were no significant differences in SST-28 plasma levels between controls and uveitic patients (28.25 pg/ml (21.3–31) vs 28.7 pg/ml (22–29.5),  $P = 0.869$ ). Concentration of vitreous proteins was higher in patients with CUMO than in control subjects ( $1.59 \pm 0.38$  mg/ml vs  $0.73 \pm 0.32$  mg/ml,  $P < 0.0001$ ). Vitreous SST-28 levels were strikingly lower in patients with CUMO than in controls in both absolute terms and after correcting for vitreous protein concentration (39.37 pg/ml (6.16–172) vs 486.73 pg/ml (4.7–1833),  $P < 0.0001$ ; 33.1 pg/mg (3.9–215.74) vs 629.75 pg/mg (6.91–2024),  $P < 0.0001$ ) (Figure 1). In the control subjects, SST-28 levels were 17-fold higher in vitreous fluid than in plasma ( $P < 0.0001$ ), whereas in uveitic patients the difference was only 1.4-fold higher ( $P = 0.091$ ). No correlations were found between vitreous and plasma SST-28 levels in either uveitic or control subjects ( $\rho = 0.191$ ,  $P = 0.57$  and  $\rho = 0.49$ ,  $P = 0.66$ ).

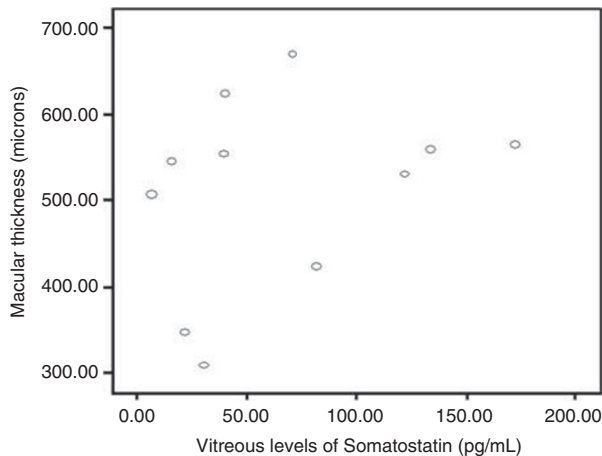
We investigated whether age had an influence on local production of SST. A multivariate linear regression model was performed, which showed that such relation did not exist ( $P = 0.207$ ). Table 2 shows clinical data and results from laboratory determinations from both the groups.

Mean VA in CUME patients was  $0.84 \pm 0.39$  and mean macular thickness was  $512.82 \pm 110 \mu\text{m}$ . There were no statistical correlations between SST-28 vitreous levels and VA or macular thickness ( $\rho = 0.302$ ,  $P = 0.31$  and  $\rho = 0.45$ ,  $P = 0.13$ ). Figure 2 shows the relationship between macular thickness and SST levels.

**Table 2** Comparative table of clinical and laboratory data from patients with chronic uveitic macular oedema and control subjects

	Age	Sex (F/M)	Macular pathology (MEM/IMH)	Vitreous proteins (mg/ml)	SST (vitreous) (pg/mg)	SST (plasma) (pg/ml)	Ratio vitreous SST/plasma SST
Uveitic patients	58.6 ± 17	5/6	—	1.59 ± 0.38	33.1 (3.9–215.74)	28.25 (21.3–31.1)	1.4
Controls	57.2 ± 15	17/25	19/23	0.73 ± 0.32	629.75 (6.91–2024)	28.7 (22–29.5)	17
<i>P</i> -value	0.801	0.765	—	<0.0001	<0.0001	0.869	—

Abbreviations: F, female; IMH, idiopathic macular hole; M, male; MEM, macular epiretinal membrane; SST, Somatostatin.



**Figure 2** Relationship between macular thickness and vitreous levels of SST in patients with CUMO.

## Discussion

In this study, vitreous and plasma levels of SST-28, the main molecular variant of this hormone in the vitreous, were measured in patients with CUMO and quiescent intraocular inflammation and in control subjects. In both uveitic patients and controls, vitreous levels of SST-28 were higher than plasma levels, a finding shown in previous studies that is consistent with reports demonstrating that SST is produced intraocularly.<sup>6–8,13</sup> We found that vitreous SST-28 is markedly lower in patients with CUMO than in controls, a result that merits further investigation. In a previous study, we found that patients with diabetic macular oedema and no significant ischaemia on angiography had lower vitreous SST-28 levels than controls, and that this deficit may be attributable to decreased production by neuroretina and RPE cells due to degeneration.<sup>5,6</sup> Chronic inflammation can cause retinal degeneration. Cytokines with pivotal roles in inflammatory processes such as tumour necrosis factor- $\alpha$  and interferon- $\gamma$  induce apoptosis in RPE cells.<sup>14</sup> Furthermore, interferon- $\gamma$  has been shown to induce degeneration of human RPE cells through stimulation of intracellular production of reactive oxygen species and activation of caspases.<sup>15</sup> It can be argued that degeneration of neuroretina and RPE cells due to chronic inflammation might be the cause of deficient intraocular expression of SST-28.

SST may be involved in regulating the permeability of endothelial and epithelial barriers. SST inhibits nitric oxide production,<sup>16,17</sup> which was found to be involved in disruption of tight junctions in Chinese hamster ovary endothelial cells.<sup>18</sup> The human receptor of SST 3, a subtype of SST receptor, physically interacts with an epithelial tight junction protein known as MUPP1 (multiple PDZ domain protein-1), which enables SST to

regulate transepithelial permeability.<sup>19</sup> Moreover, SST inhibits insulin-like growth factor I-mediated expression of vascular endothelial growth factor (VEGF) in human RPE cells.<sup>20</sup> Thus, if SST participates in blood-retinal barrier homeostasis, a deficit of this hormone might be involved in the pathogenic events leading to macular oedema in uveitic patients.

Experimental studies have shown that SST has immunosuppressive properties within the eye. Taylor *et al*<sup>21</sup> found that SST from rabbit aqueous humour suppressed IFN- $\gamma$  production by effector T cells and mediated the induction of regulatory T cells. Hence, low levels of SST in uveitic patients may contribute to chronic inflammation, which could promote macular oedema. This could have happened in our study: although we included patients with quiescent intraocular inflammation, low-grade inflammatory activity promoting macular oedema may be present as determination of vitreous proteins showed higher levels in uveitis patients, which may be presumably due to inflammation related vascular leakage.

Interestingly, the SST analogue octreotide has shown efficacy in the treatment of CUMO in some case series and in postsurgical cystoid macular oedema in a clinical trial. Missotten *et al*<sup>4</sup> studied the effect of 20 mg octreotide LAR (Novartis Pharmaceuticals, Basel, Switzerland) monthly intramuscular injections in a group of 20 uveitis patients with persistent macular oedema in an otherwise quiescent eye. Reduction of macular oedema was achieved in 14 of 20 episodes. The effect of octreotide LAR was obtained after 3 or 4 injections. Papadaki *et al*<sup>22</sup> reported partial resolution of macular oedema and improved VA in a patient with intermediate uveitis treated with subcutaneous octreotide injections. Shah *et al*<sup>23</sup> reported an increase in VA in a group of patients with postsurgical cystoid macular oedema treated with intramuscular octreotide compared with a placebo group. However, there were no differences between the two groups regarding retinal thickening or angiographic leakage.

SST may also have a role in retinal physiology. Kouvidi *et al*<sup>24</sup> reported that SST causes an increase in dopamine release in rat retinal explants. As retinal levels of dopamine are known to positively correlate with light sensitivity, SST control of dopamine release may be important for regulation of light adaptation. Dal Monte *et al*<sup>25</sup> showed that activation of an SST receptor subtype, SST receptor 2, inhibits K<sup>+</sup>-induced glutamate release in mouse retinal explants. As glutamate is the major excitatory neurotransmitter in the mammalian retina and is implicated in neurotransmission along the vertical pathway from photoreceptors to bipolar cells to ganglion cells, SST may be involved in regulating this part of the visual pathway. All these data suggest that low SST

production in patients with CUMO may have an impact on their visual function.

Regarding the use of vitrectomy for the treatment of CUME, it should be kept in mind that this might imply complete removal of an already deficient factor that can act against oedema. Hence, the indication for vitrectomy might be restricted to cases that are more active, in which proinflammatory cytokines are likely to have a predominant role in the blood-retinal barrier alteration.

The sample of uveitic patients in this study was small and this may have contributed to the lack of statistical correlations between vitreous SST-28 concentrations and macular thickness or VA. However, other factors may account for these results. Other peptides, such as VEGF, which is also involved in the pathogenesis of uveitic macular oedema,<sup>26</sup> may have a greater influence on vascular permeability. Structural complications, such as corneal opacities or lens/intraocular lens opacities are also determinants for VA.

A possible relation between age and vitreous levels of SST was explored as production of the hormone may be lower due to an expected age-related decline in the number or retinal cells. However, we did not find such relation.

Perhaps this relation could be found in a study with a larger sample of patients.

Another limitation of the study was the heterogeneity of the sample in terms of aetiology. Posterior uveitis and panuveitis may be more likely to affect the source of SST, that is, RPE cells and neuroretina.

Finally, another limitation of our work is the cross-sectional nature of the study. Reliable deductions about the levels of SST as a cause of oedema and inflammation or as a possible effect of them cannot be established in this type of studies.

In conclusion, intravitreal SST-28 levels are decreased in patients with CUMO and quiescent intraocular inflammation. Further studies are needed to clarify the cause of this deficit and its potential contribution to the pathogenesis of CUMO.

## Summary

### What was known before

- Vitreous levels of SST are decreased in diabetic macular oedema. SST has anti-oedema properties. Octreotide, a SST analogue, has been shown to be effective in the treatment of CUMO.

### What this study adds

- Vitreous levels of SST are decreased in patients with uveitic macular oedema, which provides more consistent data to support the use of SST analogues in the treatment of patients with this condition.

## Conflict of interest

The authors declare no conflict of interest.

## Acknowledgements

This study was financially supported by: Instituto de Salud Carlos III, Ministerio de Ciencia e Innovación, Madrid, Spain, grant numbers FIS PI/070414 and RETICS RD07/0062, and Gobierno vasco, grant number IT-437-10. We gratefully acknowledge Lorea Martínez-Indart for her assistance in the statistical analysis.

## References

- 1 Lardenoye CW, van Kooij B, Rothova A. Impact of macular edema on visual acuity in uveitis. *Ophthalmology* 2006; **113**: 1446–1449.
- 2 Rothova A. Inflammatory cystoid macular edema. *Curr Opin Ophthalmol* 2007; **18**: 487–492.
- 3 Brazeau P, Vale W, Burgus R, Lingn N, Butcher M, Rivier J *et al*. Hypothalamic polypeptide that inhibits the secretion of immunoreactive pituitary growth hormone. *Science* 1973; **179**: 77–79.
- 4 Missotten T, van Laar JAM, van der Loos TL, van Daele PL, Kuijpers RW, Baarsma GS *et al*. Octreotide long-acting repeatable for the treatment of chronic macular edema in uveitis. *Am J Ophthalmol* 2007; **144**: 838–843.
- 5 Carrasco E, Hernandez C, Miralles A, Huguet P, Farres J, Simo R. Lower somatostatin expression is an early event in diabetic retinopathy and is associated with retinal degeneration. *Diabetes Care* 2007; **30**: 2902–2908.
- 6 Klisovic DD, O'Dorisio MS, Katz SE, Sall JW, Balster D, O'Dorisio TM *et al*. Somatostatin receptor gene expression in human ocular tissues: RT-PCR and immunohistochemical study. *Invest Ophthalmol Vis Sci* 2001; **42**: 2193–2201.
- 7 Simo R, Carrasco E, Fonollosa A, Garcia-Arumi J, Casamitjana R, Hernandez C. Deficit of somatostatin in the vitreous fluid of patients with diabetic macular edema. *Diabetes Care* 2007; **30**: 725–727.
- 8 Hernandez C, Carrasco E, Casamitjana R, Deulofeu R, Garcia-Arumi J, Simo R. Somatostatin molecular variants in the vitreous fluid: a comparative study between diabetic patients with proliferative diabetic retinopathy and nondiabetic control subjects. *Diabetes Care* 2005; **28**: 1941–1947.
- 9 Becker M, Davis J. Vitrectomy in the treatment of uveitis. *Am J Ophthalmol* 2005; **140**: 1096–1105.
- 10 The SUN working group. Standardization of uveitis nomenclature for reporting clinical data. Results of the first international workshop. *Am J Ophthalmol* 2005; **140**: 509–516.
- 11 Nussenblatt RB, Palestine AG, Chan CC, Roberge F. Standardization for vitreal inflammatory activity in intermediate and posterior uveitis. *Ophthalmology* 1985; **92**: 467–471.
- 12 Bloch-Michel E, Nussenblatt RB. International Uveitis Study Group recommendations for the evaluation of intraocular inflammatory disease. *Am J Ophthalmol* 1987; **103**: 234–235.
- 13 van Hagen PM, Baarsma GS, Mooy CM, Ercoskan EM, ter Averst E, Hofland LJ *et al*. Somatostatin and somatostatin

- receptors in retinal diseases. *Eur J Endocrinol* 2000; **143**(Suppl 1): S43–S51.
- 14 Li R, Maminishkis A, Wang FE, Miller SS. PDGF-C and -D induced proliferation/migration of human RPE is abolished by inflammatory cytokines. *Invest Ophthalmol Vis Sci* 2007; **48**: 5722–5732.
- 15 Elner SG, Yoshida A, Bian ZM, Kindezelskii AL, Petty HR, Elner VM. Human RPE cells apoptosis induced by activated monocytes is mediated by caspase-3 activation. *Trans Am Ophthalmol Soc* 2003; **101**: 77–89.
- 16 Leal EC, Manivannan A, Hosoya K, Terasaki T, Cunha Vaz J, Ambrosio AF *et al*. Inducible nitric oxide synthase isoform is a key mediator of leukostasis and blood-retinal barrier breakdown in diabetic retinopathy. *Invest Ophthalmol Vis Sci* 2007; **48**: 5257–5265.
- 17 Olson N, Greul AK, Hristova M, Bove PF, Kasahara DI, van der Vliet A. Nitric oxide and air way epithelial barrier function: regulation of tight junctions proteins and epithelial permeability. *Arch Biochem Biophys* 2009; **484**: 205–213.
- 18 Arena S, Pattarozzi A, Corsaro A, Schettini G, Florio T. Somatostatin receptor subtype-dependent regulation of nitric oxide release: involvement of different intracellular pathways. *Mol Endocrinol* 2005; **19**: 255–267.
- 19 Liew CW, Vockel M, Glassmeier G, Brandner JM, Fernandez-Ballester GJ, Schwartz JR *et al*. Interaction of the human somatostatin receptor 3 with the multiple PDZ domain protein MUPP1 enables somatostatin to control permeability of epithelial tight junctions. *FEBS Lett* 2009; **583**: 49–54.
- 20 Sall JW, Klisovic DD, O'Dorisio MS, Katz SE. Somatostatin inhibits IGF-1 mediated induction of VEGF in human retinal pigment epithelial cells. *Exp Eye Res* 2004; **79**: 465–476.
- 21 Taylor AW, Yee DG. Somatostatin is an immunosuppressive factor within aqueous humor. *Invest Ophthalmol Vis Sci* 2003; **44**: 2644–2649.
- 22 Papadaki T, Zacharopoulos I, Iaccheri B, Fiore T, Foster CS. Somatostatin for Uveitic Cystoid Macular Edema (CME). *Ocul Immunol Inflamm* 2005; **13**: 469–470.
- 23 Shah SM, Nguyen QD, Mir HS, Polito A, Hafiz G, Tatlipinar S *et al*. A randomized, double-masked controlled clinical trial of Sandostatin long-acting release depot in patients with postsurgical cystoid macular edema. *Retina* 2010; **30**: 160–166.
- 24 Kouvidi E, Papadopoulou-Daifoti Z, Thermos K. Somatostatin modulates dopamine release in rat retina. *Neurosci Lett* 2006; **391**: 82–86.
- 25 Dal Monte M, Petrucci C, Cozzi A, Allen JP, Bagnoli P. Somatostatin inhibits potassium-evoked glutamate release by activation of the sst(2) somatostatin receptor in the mouse retina. *Naunyn Schmiedebergs Arch Pharmacol* 2003; **367**: 188–192.
- 26 Fine HF, Baffi J, Reed GF, Csaky KG, Nussenblatt RB. Aqueous humor and plasma vascular endothelial growth factor in uveitis-associated cystoid macular edema. *Am J Ophthalmol* 2001; **132**: 794–796.