

communications should be integrated allowing for the success of nanophthalmology. This also involves proving the value of emerging technologies to concerned people, promoting use of technology and sorting out the barriers.<sup>10</sup> This process will bring new horizons to the understanding and practice of ophthalmology.

### Competing interests

The author has no competing interests in any of the devices or methodology mentioned in the manuscript.

### Acknowledgements

This work was supported by Whitfeld Fellowship from University of Western Australia and Dr Jack Hoffman Scholarship from Lions Save Sight Foundation.

### References

- 1 <http://www.medicalnewstoday.com/medicalnews.php?newsid=11567>, accessed 05 February 2006.
- 2 Krol S, Diaspro A. Nanocapsules: coating for living cells. *IEEE Trans Nanobiosci* 2004; **3**(1): 32–38.
- 3 [http://www.medgadget.com/archives/2005/04/diamond\\_coating.html](http://www.medgadget.com/archives/2005/04/diamond_coating.html), accessed 05 February 2006.
- 4 [http://www.eurekalert.org/pub\\_releases/2005-10/you-nc101405.php](http://www.eurekalert.org/pub_releases/2005-10/you-nc101405.php), accessed 05 February 2006.
- 5 <http://www.fightaging.org/archives/000314.php>, accessed 05 February 2006.
- 6 [http://www.foresight.org/UTF/Unbound\\_LBW/chapt\\_10.html](http://www.foresight.org/UTF/Unbound_LBW/chapt_10.html), accessed 05 February 2006.
- 7 Jordan A. Nanotechnology and consequences for surgical oncology. *Kongressbd Dtsch Ges Chir Kongr* 2002; **119**: 821–828.
- 8 Mehta MD. The future of nanomedicine looks promising, but only if we learn from the past. *Health Law Rev* 2004; **13**(1): 16–18.
- 9 Bottini M, Bruckner S, Nika K, Bottini N, Bellucci S, Magrini A *et al.* Multi-walled carbon nanotubes induce T lymphocyte apoptosis. *Toxicol Lett* 2006; **160**(2): 121–126.
- 10 Sajeesh KR, Yogesan K. Internet- based Eye Care: Vision 2020. *Lancet* 2005; **366**: 1244–1245.

S Kumar

Centre of Excellence in e-Medicine, Lions Eye Institute, The University of Western Australia, Perth, WA, Australia

Correspondence: S Kumar,  
Lions Eye Institute,  
Centre of Excellence in e-Medicine,  
University of Western Australia,

2 Verdun Street, Nedlands, Perth,  
Western Australia 6009WA, Australia  
Tel: +61 8 9381 0760;  
Fax: +61 8 9381 0700.  
E-mail: [sajeesh@cyllene.uwa.edu.au](mailto:sajeesh@cyllene.uwa.edu.au)

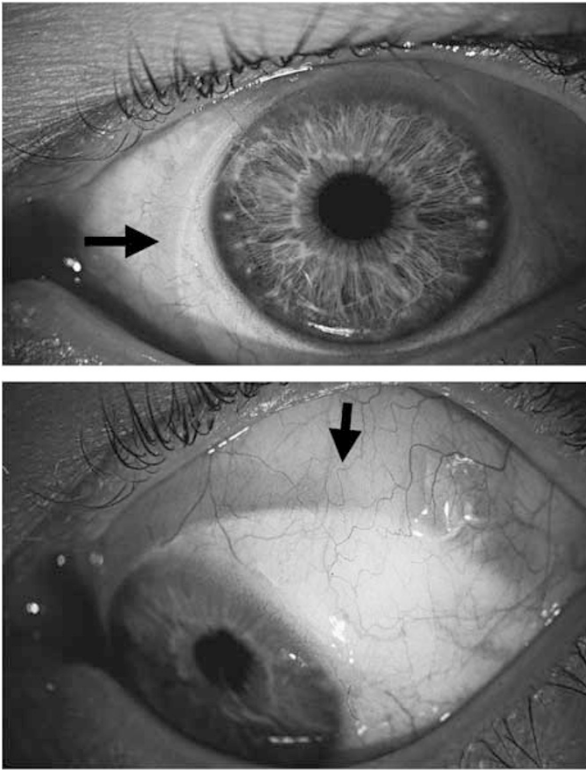
*Eye* (2006) **20**, 1455–1456. doi:10.1038/sj.eye.6702333;  
published online 24 March 2006

Sir,  
**Transmuscular migration of 240 silicone encircling band**

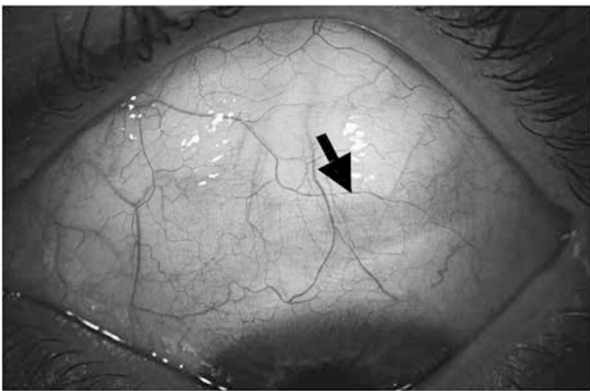
The migration of an encircling band through the extraocular muscles is an extremely rare complication of retinal detachment surgery, which may give rise to ocular motility disturbances and trophic changes at the cornea-scleral junction. This report describes the cheese wiring of a 240 silicone encircling band through the superior and the lateral rectus muscles of a highly myopic eye over a period of seven years. Removal of the explant in local anaesthesia alleviated the visual symptoms with no surgical complications.

### Case report

A 44-year-old gentleman was admitted with an inferior rhegmatogenous retinal detachment in his left myopic eye (−10 D). A silicone 240 band (Labtician, Oakville, Ontario, Canada) was placed under the four rectus muscles and fixed with a braided non-resorbable suture in all four quadrants. In addition, cryocoagulation, external drainage, and injection of 0.5 ml of air through the pars plana was performed. At 5 months after successful reattachment, the patient presented with a new retinal break and detachment at 7 o'clock anterior to the encircling band. The 240 silicone band was replaced anteriorly and cryocoagulation of the new retinal break was applied. During the next 4 months, the retina remained attached, and the patient was lost to follow-up afterwards. After 7 years, he presented again with a foreign body sensation in his operated eye. This was associated with vertical diplopia, which the patient had noticed for about 1 year before seeking advice. Clinical examination showed a visual acuity of 1.0 OS and the 240 encircling band in the subconjunctival space at the level of the limbus (Figure 1a and b). Ophthalmoscopy showed a completely attached retina. Intermittent hypotropia of the left eye with vertical diplopia was revealed using the Hess–Weiss test. The encircling band was surgically removed in local anaesthesia without incident and no local irritation was present 1 month



**Figure 1** (a and b) 240 Silicone encircling band well visible in the subconjunctival space (arrows) of the left eye at the nasal (top) and superior limbus (bottom).



**Figure 2** The bed of the encircling band (arrow) can still be seen 2 months postoperatively with a thinned sclera. Note that no local irritation is present anymore.

postoperatively (Figure 2). A postoperative Hess–Weiss test showed a reduction in left hypertropia with possible fusion. Clinical follow-up for more than 1 year has shown no recurrence of diplopia.

#### Comment

Although the pathophysiological mechanism remains unknown, it has been suggested that the encircling band

may ‘cheese wire’ forward through the superior and internal rectus insertions.<sup>1–3</sup> It has been hypothesised that the extraocular muscles form adhesions with the implanted material, and may thus remain firmly attached to the globe despite erosion of the buckle through the muscle insertions. It has been suggested that risk factors for migration of the silicone band include a placement of the band anterior to the equator, too much tightening of the band, or an insufficiently anchored band to the sclera.<sup>3</sup> In high myopia, extensive intraoperative cryocoagulation may alter tissue configurations with consecutive band migration.<sup>4,5</sup> An alternative explanation for the migration may be that the silicone band had been mistakenly placed over the muscle insertion instead of underneath the muscle. However, this seems very unlikely in our case given the expertise of the surgeon. Contrary to our case, the migrating encircling band is not usually linked to ocular motility disturbance.<sup>1,2</sup> Patients retain a full range of ocular movements and usually normal binocular fusion, indicating that the muscle tendon was not recessed from its insertion and that the scar tissue did not limit its action. The clinical prognosis after replacement or removal of the irritating silicone band is excellent.

#### Acknowledgements

We thank Mr Zdenek Gregor, FRCS, FRCOphth for very helpful remarks on the literature. None of the authors has a financial interest in any product mentioned in this paper.

#### References

- 1 Lanigan LP, Wilson-Holt N, Gregor ZJ. Migrating scleral implants. *Eye* 1992; 6: 317–321.
- 2 Ahn CS, Goldstein DA, Solomon MJ, Kurtz RM, Tessler HH, Resnick KI. Erosion and migration of a Watzke sleeve into the anterior chamber. *Retina* 1997; 17: 71–73.
- 3 Maguire AM, Zarbin MA, Elliott D. Migration of solid silicone encircling element through four rectus muscles. *Ophthalmic Surg* 1993; 24: 604–607.
- 4 Ashkenazi I, Moisseiev J, Bartov E, Treister G. Preserved action of a rectus muscle after transection by an encircling solid silicone band. *Br J Ophthalmol* 1991; 75: 508–509.
- 5 Schepens C. *Retinal Detachment and Allied Diseases*, 2 vols. Saunders: Philadelphia, 1983, pp 1024–1052.

AJ Kreis, G Klainguti, EH Bovey and TJ Wolfensberger

Department of Vitreoretinal Surgery, Hôpital Ophtalmique Jules Gonin, University of Lausanne, 15 Av. de France, CH-1004 Lausanne, Switzerland

Correspondence: TJ Wolfensberger,  
Tel: +41 21 626 81 11;  
Fax: +41 21 626 88 88.  
E-mail: thomas.wolfensberger@ophthal.vd.ch

*Eye* (2006) **20**, 1456–1458. doi:10.1038/sj.eye.6702334;  
published online 17 March 2006

Sir,  
**Intractable glaucoma following posterior sub-tenon's  
triamcinolone acetonide for central retinal vein  
occlusion in a young adult**

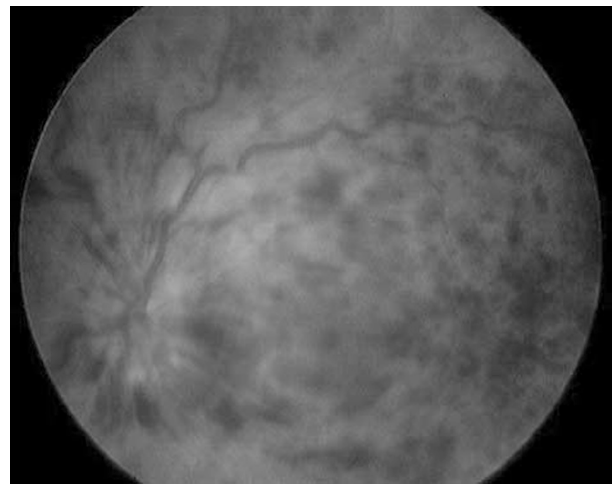
Recently, intravitreal triamcinolone acetonide (TA) has been used to treat neovascular, proliferative, edematous and inflammatory ocular diseases.<sup>1,2</sup> The most concerned adverse effect of intravitreal injection of TA except for endophthalmitis is elevated intraocular pressure (IOP). Accumulative studies have shown that the incidence of an IOP over 21 mmHg is about 30–40% in patients receiving intravitreal TA.<sup>1–4</sup> Although most of these patients can be treated systemically or topically, there was still about 1% with intractable glaucoma must undergo filtering or vitrectomy to normalize IOP.<sup>2–4</sup>

Posterior sub-Tenon's (PST) injection of steroid is an alternative route with proven effectiveness in resolution of cystoid macular oedema and only few patients developed IOP raised.<sup>5–7</sup> Herein, we report a young adult receiving PST injection of TA for central retinal vein occlusion (CRVO) who developed intractable glaucoma despite maximal antiglaucoma medication and surgical excision of the depot TA. He underwent trabeculectomy and IOP was well controlled rapidly after surgery.

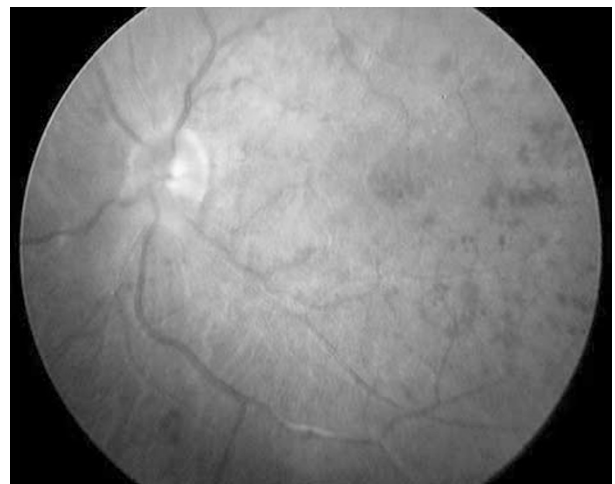
**Case report**

A 38-year-old man with an insignificant medical and ocular history presented with a sudden decrease in vision of left eye for 2 days. Best-corrected visual acuity (BCVA) was 20/200 in the left eye and 20/20 in the right eye. IOP was normal in both eyes. The patient was diagnosed with CRVO in the left eye (Figure 1). The right eye was normal. The patient received conservative treatment with eye drop (0.1% flumetholone, FML<sup>®</sup>; Allergan, Westport, County Mayo, Ireland) and oral medication (streptokinase and streptodornase, Varidase<sup>®</sup>; Wyeth, Princeton, NJ). Two months later, there was no improvement in BCVA. IOP was also normal in left eye. After being advised of risks and

benefits, the patient was treated with PST injection of TA (1 ml, 40 mg) in the left eye. Treatment was repeated at 2-week interval for a total of three injections. Two weeks after the second injection, her BCVA was 20/100 in the left eye. Her visual acuity continued to improve, and 2 weeks after the third injection, BCVA in the left eye was 20/50. Fundus examination at that time in the left eye showed almost resolution of retinal haemorrhages (Figure 2). One month after the 3rd injection, IOP started rising, from 25 to 55 mmHg. Iris neovascularization was not observed and the gonioscopy revealed a wide-open angle with absence of triamcinolone accumulation at 360 degrees. It was uncontrolled despite maximal antiglaucoma mediation



**Figure 1** Preinjection colour fundus photograph demonstrates a central retinal vein occlusion with intraretinal haemorrhage in all quadrants. The veins are dilated and tortuous.



**Figure 2** At 2 weeks after the third injection, the colour fundus photograph in the left eye showed almost resolution of retinal haemorrhages except for little haemorrhage in posterior pole.