

used for two reasons. Firstly, this was considered a closer simulation of what was likely to occur in a clinical environment and secondly the risk of consequent reduction of intraocular pressure due to repeated indentations was reduced.

Leung and Lam make a very good point about the subjects' visual field status. Their visual field status was not described as the subjects were all patients sourced from a general ophthalmology clinic and could be assumed to have no or minimal visual field loss. However, those patients for whom the PPT is intended are more likely to have glaucomatous field loss.

As a result of the wide limits of agreement there seemed to be little merit in doing tests of reliability on these data. Furthermore, it needs to be noted that 31% of the subjects were unable to have their intraocular pressures measured using the PPT as they were unable to perceive a pressure phosphene.

When the data were analysed for those younger than the median *vs* those older, the difference between the tests and the limits of agreement were similar for the two age groups.

ACB Molteno

Department of Medical and Surgical Sciences,
Ophthalmology Section,
University of Otago Dunedin School of Medicine, PO
Box 913,
Dunedin, New Zealand

Correspondence: ACB Molteno,
Tel: +64 3 474 7970;
Fax: +64 3 474 7628.
E-mail: tui.bevin@stonebow.otago.ac.nz

Eye (2005) **19**, 1227–1228. doi:10.1038/sj.eye.6701736;
published online 29 October 2004

Sir,
Endophthalmitis following 25-gauge vitrectomy

Postoperative endophthalmitis remains a rare, albeit serious, complication of ophthalmic surgery, with an incidence of approximately 0.1%.^{1,2} It is acknowledged to be less common following vitrectomy than other intraocular surgery and the incidence of endophthalmitis following conventional 20-gauge vitrectomy has been reported as 0.07% by Cohen *et al.*³ in their 10-year survey published in 1995.

The 25-gauge transconjunctival sutureless vitrectomy (TSV) system is a relatively recent innovation^{4,5} that may

have several advantages over traditional vitrectomy surgery. We present what we believe to be the first reported case of endophthalmitis following 25-gauge vitrectomy.

Case report

In October 2003, an 81-year-old pseudophakic gentleman underwent a routine 25-gauge transconjunctival sutureless vitrectomy of his right eye at Moorfields Eye Hospital, London, after persistently complaining of floaters. He had no predisposing ocular or systemic risk factors for endophthalmitis. Aqueous povidine-iodine 5% was applied pre-operatively and 125 mg cefuroxime was injected subconjunctivally at the end of the procedure. G. chloramphenicol 0.5% qid and G. dexamethasone 0.1% qid were prescribed postoperatively.

At 1-day postoperatively, ocular examination revealed minimal inflammation and an intraocular pressure of 10 mm Hg. At day 7, his visual acuity was 6/6 and the intraocular pressure had stabilised at 14 mmHg. He was noted to have increased anterior chamber activity and the frequency of his topical G. dexamethasone 0.1% was increased. The sclerostomies appeared to be healing well at both visits.

He returned the next day with hand movements vision, although the eye remained pain-free. There was a marked anterior uveitis with the presence of a small hypopyon as well as fibrin deposition on the intraocular lens; the vitreous was also markedly cellular and provided a poor view of the retina. B-scan ultrasound demonstrated only dispersed vitreous opacities.

A clinical diagnosis of bacterial endophthalmitis was made and he underwent an anterior chamber and vitreous tap followed by standard first-line treatment with intravitreal vancomycin 0.1 mg in 0.1 ml and amikacin 0.4 mg in 0.1 ml. He also commenced a 7-day course of ciprofloxacin 750 mg p.o. b.d. and a 4-week tapering course of prednisolone at a starting dose of 60 mg p.o. o.d. Initial microscopy and gram stain of the taps revealed no organisms.

The clinical picture improved greatly within 3 days with resolution of the hypopyon and much of the anterior chamber activity. Visual acuity improved to 6/12 within 1 week and 6/6 within 3 weeks. It remained 6/6 and the eye quiet at his most recent review, 3 months postoperatively.

Microbiological examination of the anterior chamber and vitreous specimens revealed no bacterial or fungal isolates at 14-days incubation.

Discussion

We believe that this case represents the first reported case of endophthalmitis following 25-gauge vitrectomy

surgery. It has been suggested that the 25-gauge system may reduce the risk of endophthalmitis owing to the smaller incision size, reduced operating time, lack of foreign-body suture material, and reduced conjunctival manipulation. However, the unsutured sclerostomy wounds may provide a conduit for bacterial ingress and the lower flow-rates of the 25-gauge system (reduced by approximately 6 times¹) allow bacteria an increased opportunity to gain a foothold perioperatively.

We believe that this case emphasises that postoperative endophthalmitis is still a complication, albeit rare, of this form of vitrectomy surgery.

Acknowledgements

Proprietary interest: None.

References

- 1 Aaberg TM, Flynn HW, Schiffman J, Newton J. Nosocomial acute-onset postoperative endophthalmitis survey. *Ophthalmology* 1998; **105**: 1004–1010.
- 2 Mamalis N, Kearsley L, Brinton E. Postoperative endophthalmitis. *Curr Opin Ophthalmol* 2002; **13**(1): 14–18.
- 3 Cohen SM, Flynn HW, Murray TG, Smiddy WE. (The Postvitrectomy Endophthalmitis Study Group). Endophthalmitis after pars plana vitrectomy. *Ophthalmology* 1995; **102**(5): 705–712.
- 4 Fujii GY, De Juan Jr E, Humayun MS, Pieramici DJ, Chang TS, Awh C *et al*. A new 25-gauge instrument system for transconjunctival sutureless vitrectomy surgery. *Ophthalmology* 2002; **109**(10): 1807–1812.
- 5 Fujii GY, De Juan Jr E, Humayun MS, Chang TS, Pieramici DJ, Barnes A *et al*. Initial experience using the transconjunctival sutureless vitrectomy system for vitreoretinal surgery. *Ophthalmology* 2002; **109**(10): 1814–1820.

SRJ Taylor and GW Aylward

Vitreoretinal Service,
Moorfields Eye Hospital, City Road,
London EC1V 2PD, UK

Correspondence: GW Aylward,
Vitreoretinal Service,
Moorfields Eye Hospital,
City Road, London,
EC1V 2PD, UK
Tel: +44 207 253 3411.
E-mail: bill.aylward@moorfields.nhs.uk

Eye (2005) **19**, 1228–1229. doi:10.1038/sj.eye.6701737;
published online 22 October 2004

Sir,

Anterior capsular phimosis with complete occlusion of the capsulorhexis opening

We describe a case of anterior capsular phimosis with complete occlusion of the capsulorhexis opening following routine phacoemulsification and implantation with an AcrysofÂ® intraocular lens (IOL) (Alcon laboratories, Fort Worth, TX, USA). The patient had no relevant predisposing ocular pathology. Histologically, the occluding membrane was composed of proliferated fibrocytic cells, derived from residual lens epithelial cells within the capsular bag. The extent of this exaggerated response is very unusual in the presence of a hydrophobic acrylic IOL.

Case report

A 90-year-old lady was admitted for daycase cataract surgery. She underwent routine left phacoemulsification and lens implantation with a 22.5 Dioptre AcrysofÂ® MA30 lens. She was noted to have a small pupil of 5 mm diameter, but did not require iris manipulation to carry out the capsulorhexis. Her capsulorhexis was thus slightly smaller than 5 mm but was sufficient to continue with uneventful surgery. Her visual acuity at 1 week was 6/18, which improved to 6/12 after a refraction at 1 month. She had dry age-related macular changes.

At 2 months after surgery she presented for right cataract surgery and was noted to have a marked deterioration in vision in her previously operated left eye. She was only able to see 1/60. Examination of her left eye revealed a markedly thickened anterior capsule with impressive capsular contraction and complete occlusion of the capsulorhexis opening (Figure 1). Arrangements were made to clear the visual axis with a surgical capsulotomy.

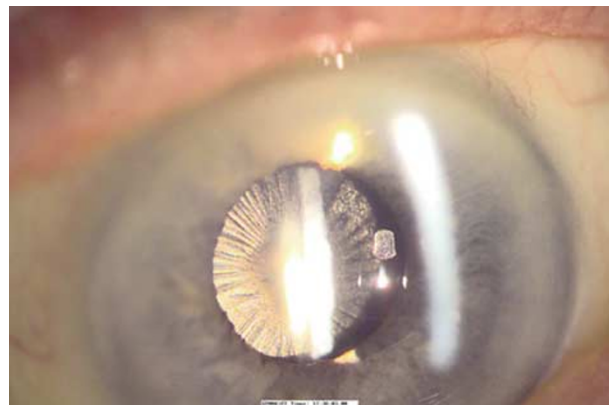


Figure 1 Capsular phimosis with central occluding membrane.