

Comment

This patient demonstrates two complications of blunt ocular trauma:¹ epiretinal membrane formation and SRN.^{1,2} The sequential development of these complications has not previously been reported in the same patient. The case supports previous reports of successful management of subretinal neovascular membranes secondary to blunt ocular trauma by surgical removal.^{3,4} The clinical behaviour and pathological appearance of the subretinal neovascular membrane in this case suggests that it was a 'type 2' membrane⁵ (ie neovascularisation below neurosensory retina but internal to viable RPE), increasing the likelihood of a good visual outcome from subretinal surgery. Gass has previously noted that choroidal neovascularisation arising at the site of an old choroidal rupture is usually type 2.⁶

Glial proliferation has a central role in epiretinal membrane formation—retinal glial cells can extend through defects in the inner limiting membrane (ILM), and may also be capable of producing ILM breaks through which they can extend processes onto the ILM surface.⁷ In the case we have described, the epiretinal membrane appeared to extend from the choroidal rupture towards the fovea. It is likely that inner retinal disruption and microscopic breaks in the ILM at the time of traumatic choroidal rupture provided the basis for subsequent glial extension and epiretinal membrane formation. In addition, the fibroglial scar at the site of the choroidal rupture provides an anchor for the epiretinal membrane, any subsequent membrane contraction enhancing the clinical appearance of the membrane extending from the rupture.

Management of epiretinal membranes invariably involves vitrectomy surgery; however, other treatment options are now available for SRN. Photodynamic therapy (PDT) may limit progression (although not widely available at the time of presentation of this case) in some age-related macular degeneration SRN; however, the value of PDT in post-trauma SRN is unproven. Likewise, trans-pupillary thermotherapy may offer a benefit in SRN treatment, but its efficacy requires further investigation. It is uncertain whether any of the alternative novel treatment options for SRN could result in a visual improvement from 6/24 to 6/9, which was achieved by surgical management of the SRN in this case.

References

- 1 Williams DF, Mieler WF, Williams GA. Posterior segment manifestations of ocular trauma. *Retina* 1990; **10**: S35-S44.

- 2 Smith RE, Kelley JS, Harbin TS. Late macular complications of choroidal ruptures. *Am J Ophthalmol* 1974; **77**: 650-658.
- 3 Aguilar JP, Green WR. Choroidal rupture: a histopathologic study of 47 cases. *Retina* 1984; **4**: 269-275.
- 4 Gross JG, King LP, de Juan Jr E, Power T. Subfoveal neovascular membrane removal in patients with choroidal rupture. *Ophthalmology* 1996; **103**: 579-585.
- 5 Grossniklaus HE, Gass JDM. Clinicopathological correlations of surgically excised type 1 and type 2 submacular choroidal neovascular membranes. *Am J Ophthalmol* 1998; **126**: 59-69.
- 6 Gass JDM. Traumatic choroidopathy. In: *Stereoscopic Atlas of Macular Diseases*, Vol 1, 4th ed. CV Mosby: St Louis, 1997, pp 206-208.
- 7 McLeod D, Hiscott P, Grierson I. Age-related cellular proliferation at the vitreoretinal juncture. *Eye* 1987; **1**: 263-281.

EV Gotzaridis, AN Vakalis, CS Sethi and DG Charteris

Vitreoretinal Research Department
Moorfields Eye Hospital
City Road, London EC1V 2PD, UK

Correspondence: D Charteris
Tel: + 44 20 7566 2285
Fax: + 44 20 7566 2285
E-mail: david.charteris@moorfields.nhs.uk

Sir,

Return of the cosmopolitan worm

Eye (2003) **17**, 791-793. doi:10.1038/sj.eye.6700405

We present a rare case of recurrent subconjunctival infection with the dog heart-worm *Dirofilaria*. This parasite is transmitted via mosquito bites^{1,2} and is well known to the veterinary profession as a parasite of cats and dogs.^{1,3} Humans are an accidental host. This zoonotic infection is increasing in incidence in Italy and France.⁴

Case report

A 25-year-old lady from West Africa came into the eye casualty complaining of an intermittent feeling of 'something moving under her eyelid'. She had a past ocular history of a parasitic conjunctival infection with the dog heart-worm *Dirofilaria*. She had travelled to West Africa and France in the past year.

On examination a mobile mass was visible under the conjunctiva. She was immediately taken to theatre and given topical and subconjunctival anaesthesia. An incision was made into the inferior conjunctiva where a live worm was visible in the subconjunctival space

(Figure 1). On making the incision, the worm started to move further towards the inferior fornix, but was prevented from doing so by grasping it gently with a pair of toothed forceps. As it was being held in the forceps, the worm made several twisting movements in an attempt to free itself, but was successfully extracted using firm, steady traction (Figure 2) and sent for histology. It was identified as a female *Dirofilaria*, possibly *Dirofilaria repens*.

She was given chloramphenicol ointment to apply four times a day for a week and asked to return for review in a fortnight. On her return visit, the eye was quiet with no signs of recurrence.

Comment

Dirofilaria has been termed the 'cosmopolitan parasite' as it has its highest incidence in the Mediterranean basin.¹ Italy has the highest prevalence of *D. repens* with the number of cases increasing in the past 10 years.^{4,5} This is possibly because of a climate alteration that favours the mosquito population.⁴ Southern France and Sri Lanka have reported several cases of human infestation. A handful of human cases have also emerged in Australia, Thailand, Malaysia, Africa, Spain, Greece, the Netherlands, Israel, and ex-USSR countries. *Dirofilaria immitis*, *D. tenuis*, and *D. ursi* have been observed in humans in North America.¹

Dirofilaria is a nematode that predominantly inhabits dogs and cats. The adult filaria lives in cutaneous connective tissue and emits blood microfilaria. These are transmitted by mosquitoes of the genus *Aedes*, *Anopheles*, or *Culex*.^{1,3} Dogs and cats are the final hosts. Humans are rarely infected and are accidental hosts. After an infected mosquito transmits the disease, the microfilaria becomes encysted into a subcutaneous nodule where it matures. The parasite is able to survive for several years in humans. Female worms outnumber

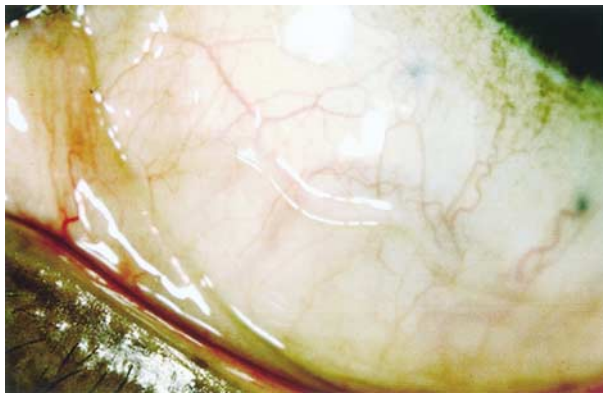


Figure 1 Worm visible in the subconjunctival space

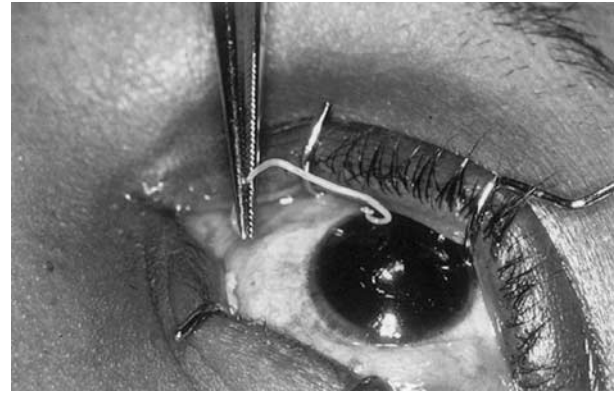


Figure 2 The worm is removed with gentle traction

male infestations by 5:1.⁴ Extracted worms are often immature.

The nematode is able to migrate and shows a preference for the upper body, especially the head and upper limbs. An Italian review⁴ of 60 cases found that 49 were subcutaneous, two in the omentum, two in breast tissue, two in lung, two in the epididymus, two in the spermatic cord, and one in the conjunctiva. Around the eye, sites most commonly affected are the subcutaneous tissue of the eyelids and the periorbital region.² If ocular, it tends to appear in the eyelid or under the conjunctiva. An Australian report described an anterior chamber worm and an intravitreal worm was found in Malaysia.⁶

Patients with ocular *Dirofilaria* can present with pain and itching or awareness of an intermittent or continuous mass. On examination, the eye may be quiet or an area of hyperaemia and raised conjunctiva may be seen. Enlargement of satellite lymph nodes is occasionally seen.

Treatment is by surgical removal. No antiparasitical treatment is necessary.^{1,6}

References

- 1 Rouhette H, Marty P, Zur C, Bain O, Fenollar S, Gastaud P. Ocular filariasis: not strictly tropical. *Ophthalmologica* 1999; **213**: 206–208.
- 2 Font RL, Neafie RC, Perry HD. Subcutaneous dirofilariasis of the eyelid and ocular adnexa. *Arch Ophthalmol* 1980; **98**: 1079–1083.
- 3 Arvantis PG, Vakalis NC, Damanakis AG, Theodossiadis GP. Ophthalmic dirofilariasis. *Am J Ophthalmol* 1997; **123**: 689–691.
- 4 Pampiglione S, Rivasi F, Angeli G, Boldorini R, Incensati RM, Pastormerio M et al. Dirofilariasis due to *Dirofilaria repens* in Italy. *Histopathology* 2001; **38**: 344–354.
- 5 Ruiz-Moreno JM, Bornay-Llinares FJ, Maza PG, Medrano M, Simon F, Eberhard ML. Subconjunctival infection with *Dirofilaria repens*. *Arch Ophthalmol* 1998; **116**: 1370–1372.

- 6 D'Heurle D, Kwa BH, Vickery AC. Ophthalmic dirofilariasis. *Ann Ophthalmol* 1990; **22**: 273–275.

AJ Knapman, AJ Booth and D Farnworth

Department of Ophthalmology
Queen Alexandra Hospital
Portsmouth PO3 6LY, UK

Correspondence: AJ Knapman
Tel: +44 2380 286000 ext 185
E-mail: Andreaknapman@hotmail.com

Sir,

Ophthalmic features of idiopathic intracranial hypertension

Eye (2003) **17**, 793–795. doi:10.1038/sj.eye.6700443

Idiopathic intracranial hypertension (IIH), also called 'pseudotumour cerebri', is a syndrome characterized by increased intracranial pressure with associated signs and symptoms, but without localizing neurologic findings. Although it is usually a self-limiting condition, some patients may lose their vision. It was not until the 1980s that studies began to document this high incidence of visual loss. Moderate-to-severe vision loss has since been reported in over 50% of patient referral groups.^{1–3} IIH is not a rare disease.¹ Population-based studies have documented annual incidence rates of 1–2 per 100 000 people.⁴ For the high-risk group of obese women in their reproductive age, the annual incidence climbs to 19–20 per 100 000 people.⁴ Important risk factors, including female gender, reproductive age, obesity, recent weight gain, and menstrual irregularities, have also been well documented.

Unfortunately, current knowledge of IIH is largely limited to information gained from Western studies. There has been no study describing the features of Oriental patients. Therefore, the goal of this study is to delineate the clinical course of this disorder with an emphasis on visual prognosis and other associated factors.

Methods and results

We reviewed all cases diagnosed as IIH between 1990 and 2000 in Chang Gung Memorial Hospital. In all, 10 cases met the modified Dandy's criteria. Epidemiological

data were collected according to medical records. Symptoms and a detailed medical history were also recorded. All the patients were examined at the Department of Neuro-ophthalmology at the time of diagnosis and on follow-up visits. Visual acuity was measured using the Snellen chart. An ophthalmoscopic examination was performed on each visit and recorded by photographs. The degree of papilloedema was graded using Frisén's scheme. Grade 0 represents a normal optic disc without swelling, grade 1 represents early disc swelling, and grade 5 means severe papilloedema—a transitional stage towards progressive atrophy. The Goldmann perimetry was performed before July 1991 to evaluate visual field defects. In the following years, automated perimetry, the Humphrey 30-2 programme, was employed. Visual function was determined by both visual acuity and the result of visual field testing using the simplified grading system defined by Wall and George. Visual outcome of each patient was defined according to grading of the worse eye at the last visit. All patients had brain computed tomography (CT) scans conducted to rule out any intracranial mass lesions. They also had blood and cerebrospinal fluid (CSF) tests to exclude other disorders known to cause elevated intracranial pressure. CSF opening pressure was also well documented in each case. Body weight and height were measured at diagnosis. Obesity was defined as a body-mass index (the weight in kilograms divided by the square of the height in metres) of 30 or more.

Of the 10 patients, nine were female (female: male ratio was 9:1). The average age at onset was 34 years (range 22–49 years). The duration of follow-up ranged from 2 to 22 months with an average of 13.1 months. The average BMI was 26.8 kg/m² (range 20.45–32.68). Three patients (30%) were obese. One patient reported a weight gain of 6 kg over 3 months from the onset of symptoms. Four patients had a history of systemic hypertension, among them one had unstable blood pressure. One had iron-deficiency anaemia without replacement therapy at the time of the initial evaluation. One had been taking contraceptive pills regularly prior to the onset of symptoms. One had menstrual irregularity and chronic renal failure. Another patient had endometriosis and received Ladogol (danazol) therapy. However, we could not find any possibly associated medical conditions in four of our patients.

Transient visual obscuration was reported by five patients as the presenting symptom, while another three patients first noted diplopia, and two had blurred vision initially. Six patients (60%) noted headaches, six patients (60%) reported transient visual obscurations, three patients (30%) experienced diplopia, and two patients (20%) noted tinnitus (intracranial noise).