



SHORT REPORT

Autosomal recessive retinal dystrophy associated with two novel mutations in the *RPE65* gene

Françoise Marlhens¹, Jean-Michel Griffoin¹, Corinne Bareil², Bernard Arnaud³, Mireille Claustres² and Christian P Hamel^{1,3}

¹Laboratoire de Neurobiologie de l'Audition, Plasticité Synaptique

²Laboratoire de Biochimie Génétique, Institut de Biologie

³Service d'Ophthalmologie, Hôpital Gui de Chauliac, Montpellier, France

Retinal dystrophies are a complex set of hereditary diseases of the retina that result in the degeneration of photoreceptors. Recent studies have shown that mutations in *RPE65*, a gene that codes for a retinal pigment epithelium (RPE)-specific protein thought to be involved in the 11-*cis*-retinoid metabolism, a key process in vision, cause severe, early onset retinal dystrophy. We describe two novel missense *RPE65* mutations, L22P and H68Y, in a compound heterozygote with autosomal recessive retinal dystrophy. The relatively mild phenotype associated with these mutations suggests a possible link between the severity of the disease and the type of mutations in the *RPE65* gene.

Keywords: *RPE65*; retinal pigment epithelium; photoreceptor; retinitis pigmentosa; retinal dystrophy; gene mutation

Introduction

Retinal dystrophies are hereditary disorders whose common feature is the degeneration of photoreceptors, rods and/or cones. Retinitis pigmentosa (RP) is the most frequent retinal dystrophy that affects 1 in 3 to 4000 individuals in developed countries.^{1,2} Early stages of typical RP are characterised by night blindness and loss of midperipheral visual field that reflect primary rod impairment. As the disease progresses, patients lose far peripheral and central vision, eventually leading to blindness. Prominent clinical findings are the presence

of bone spicule-shaped pigment in the retina and abnormal electroretinogram (ERG) responses. In addition to typical RP, there are less frequent forms of retinal dystrophy which appear to involve either primarily cones or equally rods and cones.^{3,4} Clinical varieties of retinal dystrophy are most frequently non-syndromic and can be inherited as autosomal dominant, autosomal recessive, X-linked or digenic diseases, with extensive allelic and nonallelic heterogeneity.^{5,6}

The retinal pigment epithelium (RPE) is a single cell-layered tissue in close contact with the photoreceptor outer segments which performs many functions important for the physiology of photoreceptors. Among them, the periodic phagocytosis of the outer segment tips,⁷ a process whose defect leads to retinal degeneration,⁸ and the metabolism of 11-*cis*-retinoids⁹ are key processes to vision. *RPE65* is a 65-kDa protein specific to the RPE.¹⁰ While the precise role of *RPE65* remains

Correspondence: Christian P Hamel, INSERM U. 254, Laboratoire de Neurobiologie de l'Audition-Plasticité Synaptique, 300, rue Auguste Broussonnet, 34295 Montpellier cedex 5, France. Tel: (33) 467 33 69 75; Fax: (33) 467 52 56 01; E-mail: biomol@mnet.fr

Received 11 November 1997; revised 6 February 1998; accepted 18 February 1998

unclear, its involvement in retinoid metabolism seems certain¹¹ and implies a functional relationship with photoreceptor physiology. It was recently found that mutations in *RPE65* cause childhood onset of severe retinal dystrophy.^{12,13} In an effort to further characterise mutations in this gene, we screened 184 unrelated patients with various types of retinal dystrophies. We report here two novel missense mutations in a compound heterozygote with autosomal recessive retinal dystrophy.

Materials and Methods

Single-strand Conformation Analysis (SSCA)

Unlabelled SSCA Each of the 14 exons of the *RPE65* gene was amplified by combining 20 pmoles of forward and reverse intronic primers,¹² 200 ng of genomic DNA, 1 U of *Taq* DNA polymerase (Eurogentec, Belgium) in a 50 µl volume containing 75 mM Tris-HCl pH 9.0, 20 mM (NH₄)₂SO₄, 2.0 mM MgCl₂, 20 µM of each dNTP and 0.01% Tween 20. Following a denaturation step (94°C for 5 min) amplification was carried out for 35 (exons 3, 11, 12) or 40 (exons 1, 2, 4–10, 13, 14) cycles at 94°C for 1 min, 56°C or 60°C for 1 min¹² and 72°C for 2 min. Twelve µl of PCR products were mixed with 4 µl of stop solution (95% formamide, 10 mM NaOH, 0.05% bromophenol blue, 0.05% xylene cyanol) and denatured for 2 min at 100°C. Seven µl of each sample were then loaded on a Hydrolink MDE gel (FMC, USA) and electrophoresed at room temperature in 0.6 × TBE. Gels were silver stained and air dried.

Labelled SSCA To study the familial segregation of the L22P mutation, exon 2 of the *RPE65* gene was ³²P-labelled and amplified by PCR as previously described.¹⁴ Five µl of labelled PCR products were mixed with 7 µl of stop solution (95% formamide, 10 mM NaOH, 0.05% bromophenol blue, 0.05% xylene cyanol) and denatured for 2 min at 92°C. 2.8 µl of each sample were then loaded on a 5% acrylamide, 5% glycerol gel, and electrophoresed at room temperature in 0.6 × TBE. Gels were dried and autoradiographed at room temperature for 6–12 h.

Direct Sequencing

Each strand of DNA was amplified by asymmetric PCR with one of the two primers reduced 50-fold in amount. The asymmetric PCR products were then filter-purified, concentrated, and 7 µl were sequenced by the dideoxynucleotide chain-termination method using sequenase (USB, USA) and ³⁵S dATP.

Results

Mutations in *RPE65* were sought in 184 unrelated patients with various types of retinal dystrophies from whom informed consent had been obtained. For each patient the entire coding and flanking sequences¹² were

amplified by polymerase chain reaction (PCR) from genomic DNA and screened using single-strand conformation analysis (SSCA). Two major DNA sequence changes were noticed.

In one patient, direct sequencing of an aberrant migration pattern of the exon 9 revealed a 3-bp insertion at position 1047 (ins1047TGG) in one allele (not shown). The resulting protein should have an additional tryptophan at position 351, following tryptophan at position 350. A G to A substitution at position 1131 in exon 10 that does not change the encoded amino acid, was also found.¹² The codon duplication ins1047TGG was not found in any of the other 183 unrelated patients. However, since it did not follow the segregation of the disease in the family, we conclude that it was not pathogenic.

In a second patient, an aberrant migration pattern was detected in exon 3 (patient II₂ in Figure 1c). Direct sequencing of this exon revealed a substitution of two consecutive nucleotides, changing G to T and C to T at cDNA positions 255 and 256, respectively (Figure 1a). This substitution resulted in a missense mutation, H68Y. Following this finding, the 13 other exons from this patient were sequenced who was found to carry a second alteration in exon 2, substituting T to C at cDNA position 119, and resulting in a second missense mutation, L22P (Figure 1b). The segregation of the mutations was followed in the patient's family by SSCA using Hydrolink MDE gels for H68Y and 5% acrylamide, 5% glycerol gels for L22P. This analysis revealed that H68Y and L22P were from maternal and paternal origins, respectively, confirming that the patient was a compound heterozygote (Figure 1c). The heterozygous carriers of either one of the two mutations were asymptomatic.

Amino acid substitutions in patient II₂ are non conservative. Indeed, H68Y results in the loss of one positive charge and the substitution of a leucine to a proline at codon 22 might disorganise the C-terminal end of a hypothetical, amphipathic alpha helix.¹⁵ Both L22 and H68 are conserved in human,¹⁶ bovine¹⁵ and rat [GenBank accession number AF035673] *RPE65*, suggesting that they may be important for the protein function. In addition, these mutations have not been found in the other 183 unrelated patients nor in 50 normal individuals, strongly supporting that they are responsible for the disease in patient II₂.

Patient II₂ reported night blindness since early childhood and later on, in his second decade, complained of difficulties in reading, along with altered

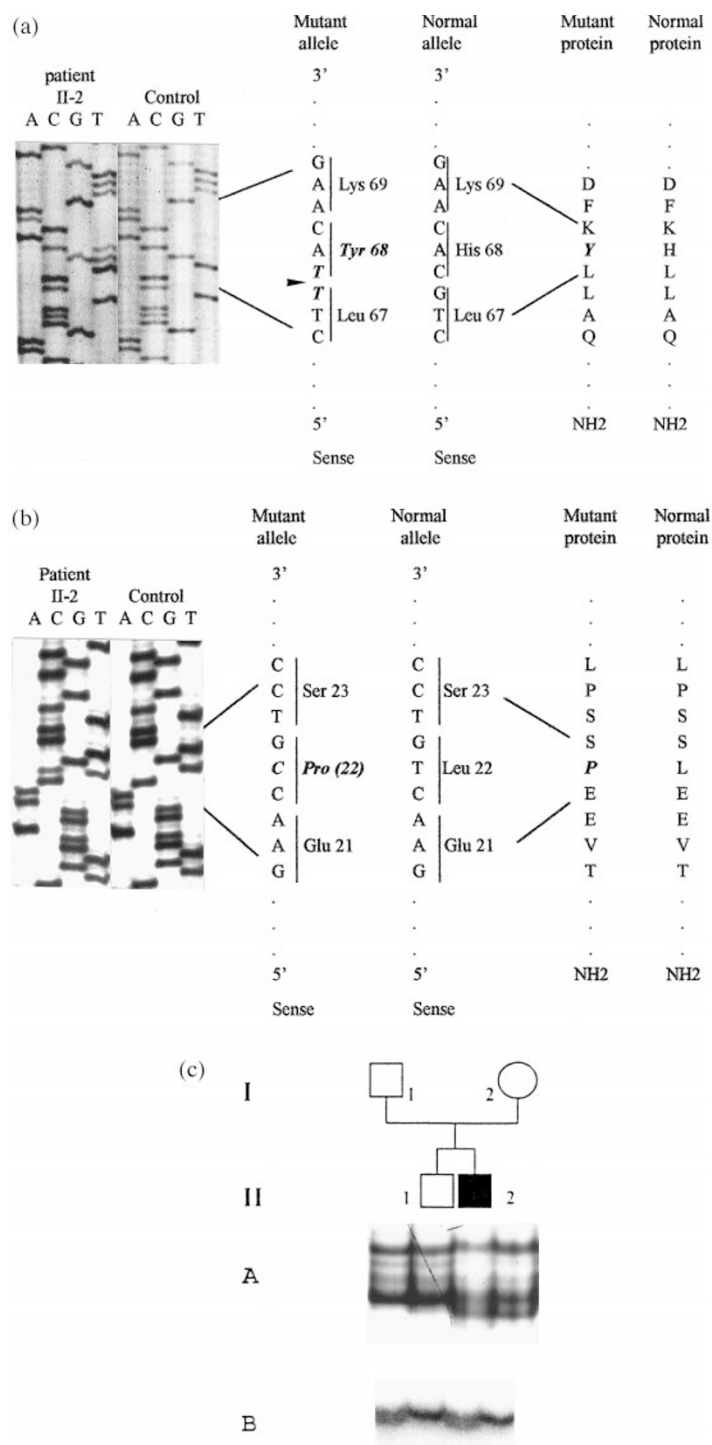


Figure 1 Identification of two missense RPE65 mutations in a single individual from one family. (a) sequences of RPE65 exon 3 in patient II₂ and an unaffected control. Two consecutive heterozygous substitutions at positions 255 (G → T) and 256 (C → T) are present in patient II₂ (black arrow). G → T does not change the encoded amino acid whereas C → T results in the substitution of histidine for tyrosine at codon 68. (b) sequences of RPE65 exon 2 from the same individuals. A heterozygous T → C substitution at position 119 is present in patient II₂ changing a leucine residue for a proline at codon 22. (c) inheritance pattern of RPE65 mutations followed by SSCA analysis. Black symbol in the pedigree indicate the patient, white symbols unaffected family members. (A) SSCA of exon 3 displaying the shifted band associated with the heterozygote mutation H68Y present in patient II₂ and in his unaffected mother. (B) SSCA of exon 2 displaying a shifted band associated with the heterozygote L22P mutation present in patient II₂ and his unaffected father.

colour discrimination. At the time of the examination, aged 40 years, he was unable to find his way outside and exhibited marked peripheral field loss. Fundus examination revealed the triad, waxy pallor of optic discs, attenuated retinal vessels and bone-spicule pigment in midperipheral retina along with bilateral, extended dystrophy of the macular area. ERG responses for the scotopic system were undetectable ($< 10 \mu\text{V}$) and profoundly affected for the photopic system (flicker responses barely detectable). His medical history and clinical findings were suggestive of a degenerative process involving both rods and cones.

Discussion

Results from this study and recent findings^{12,13} demonstrate that mutations in a RPE-specific gene lead to retinal dystrophies (Figure 2). Shared phenotypic features in patients with *RPE65* mutations are early onset of the disease along with rapid progression of the degenerative process. The most severe clinical picture was described in two patients¹² as Leber's congenital amaurosis (LCA), a retinal dystrophy characterised by severe visual impairment at birth with extinguished ERG responses.¹⁷ In contrast, patient II₂ described in this study exhibited a milder phenotype in childhood and a slower progression of the disease. LCA patients were compound heterozygotes for nonsense mutations implying that the truncated *RPE65* products were either absent or nonfunctional. In the case of patient II₂ described in this study, the two missense mutations probably result in misfolded or functionally impaired but full-length *RPE65* products. One can speculate that the level of impairment of the RPE65 protein might control the rate at which the photoreceptors degen-

erate. Following this hypothesis, the absence of *RPE65* products would cause a massive, early degeneration of photoreceptors while substitution of amino acids would lead to a slower pace of degeneration. In fact, brief description of phenotypes with *RPE65* mutations reported by Gu *et al*¹³ suggests that premature stop codon or frameshift lead to more severe phenotype than inactivated splice site or amino acid substitutions.

Understanding of the pathogenesis of retinal dystrophy in the case of *RPE65* mutations will require a knowledge of the function of the protein itself. Because of its strict specificity for the RPE and of its conservation in vertebrates, RPE65 is a good candidate for one of the few specialized functions of the RPE. Among these, the metabolic pathway that processes the all-*trans*-retinol to 11-*cis*-retinoids and that takes place in the RPE represents a key to the proper functioning of the photoreceptors.⁹ Important steps of this metabolism involve a lecithin:retinol acyltransferase that esterifies dietary-derived all-*trans*-retinol (vitamin A), an isomerase that directly converts the retinyl ester to 11-*cis*-retinol and an 11-*cis*-retinol dehydrogenase that oxidises 11-*cis*-retinol to 11-*cis*-retinal¹⁸ which eventually associates with opsins to form photopigments. The isomerase and the 11-*cis*-retinol dehydrogenase are both RPE-specific microsomal enzymes,^{19,20} as is RPE65. In addition, RPE65 appears to form a protein complex with the 11-*cis*-dehydrogenase and with at least two unidentified products of 50 and 52 kDa.²¹ These observations and the recent demonstration that addition of anti-RPE65 antibodies to RPE extracts causes a decrease in the *de novo* generation of 11-*cis*-retinoids¹¹ suggest that RPE65 is an enzyme involved in the 11-*cis*-retinoid metabolism. Therefore, a defect in

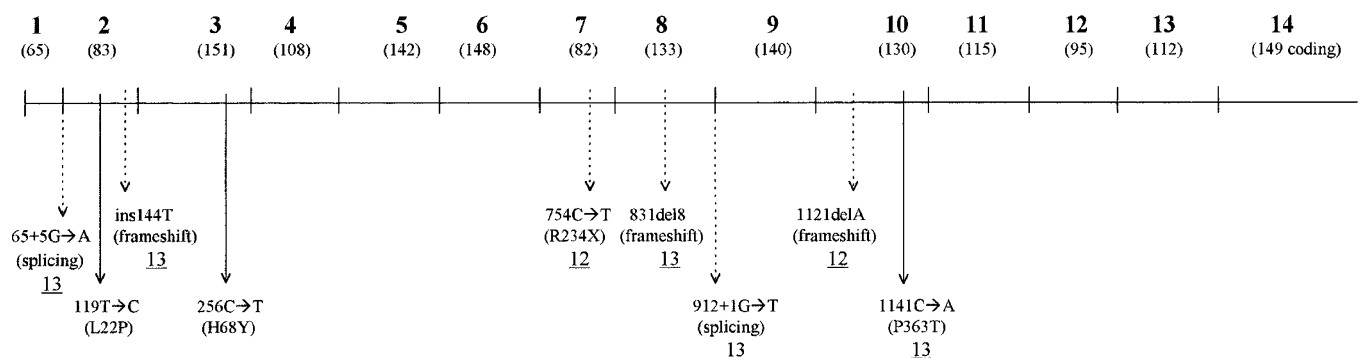


Figure 2 Mutations in RPE65. Schema depicting the 14 exons of RPE65. Number of each exon is indicated as well as its size in bp in brackets. Reported RPE65 mutations are described; underlined numbers refer to references in this paper; solid line arrows indicate amino acid substitutions, dashed line arrows are for translation terminating mutations.

the RPE65 function could lead to decreased or abnormal rod and cone photopigments resulting in degeneration of photoreceptors. The medical history of patient II₂ described in this study as well as clinical findings from recent reports^{12,13} indeed suggest that both rods and cones are involved in the degenerative process. Animal models are needed to examine these hypotheses and to give further insight into the interactions between photoreceptor and RPE in retinol metabolism.

Acknowledgements

J-MG and CB are supported by SOS Rétinite, Montpellier, France. Research was sponsored in part by SOS Rétinite, IRRP and Retina France, and by the CHU de Montpellier, France. We gratefully thank Jean-Louis Pasquier for artwork.

References

- 1 Boughman JA, Conneally PM, Nance WE: Population genetic studies of retinitis pigmentosa. *Am J Hum Genet* 1980; **32**: 223–234.
- 2 Pagon RA: Retinitis pigmentosa. *Surv Ophthalmol* 1988; **33**: 137–177.
- 3 Heckenlively JR: RP cone-rod degeneration. *Trans Am Ophthalmol Soc* 1987; **85**: 438–470.
- 4 Kaplan J, Bonneau D, Frézal J, Munnich A, Dufier J-L: Clinical and genetic heterogeneity in retinitis pigmentosa. *Hum Genet* 1990; **85**: 635–642.
- 5 Dryja TP, Li T: Molecular genetics of retinitis pigmentosa. *Hum Mol Genet* 1995; **4**: 1739–1743.
- 6 Sullivan LS, Daiger SP: Inherited retinal degeneration: exceptional genetic and clinical heterogeneity. *Mol Med Today* 1996; **2**: 380–386.
- 7 Young RW, Bok D: Participation of the retinal pigment epithelium in the rod outer segment renewal process. *J Cell Biol* 1969; **42**: 392–403.
- 8 Bok D, Hall MO: The role of the pigment epithelium in the etiology of inherited retinal dystrophy in the rat. *J Cell Biol* 1971; **49**: 664–682.
- 9 Wald G: The molecular basis of visual excitation. *Nature* 1968; **219**: 800–807.
- 10 Hamel CP, Tsilou E, Harris E *et al*: A developmentally regulated microsomal protein specific for the pigment epithelium of the vertebrate retina. *J Neurosci Res* 1993; **34**: 414–425.
- 11 Crouch RK, Goletz P, Yu S, Redmond TM: A possible role for RPE65 in retinoid processing. *Invest Ophthalmol Vis Sci* 1997; **38**: S304.
- 12 Marlhens F, Bareil C, Griffoin J-M *et al*: Mutations in RPE65 cause Leber's congenital amaurosis. *Nat Genet* 1997; **17**: 139–141.
- 13 Gu S-M, Thompson DA, Srisailapathy Srikumari CR *et al*: Mutations in RPE65 cause autosomal recessive childhood-onset severe retinal dystrophy. *Nat Genet* 1997; **17**: 194–197.
- 14 Tuffery S, Moine P, Demaille J, Claustres M: Base substitutions in the human dystrophin gene: detection by using single-strand conformation polymorphisms (SSCP) technique. *Hum Mut* 1993; **2**: 368–374.
- 15 Hamel CP, Tsilou E, Pfeffer BA, Hooks JJ, Detrick B, Redmond TM: Molecular cloning and expression of RPE65, a novel retinal pigment epithelium-specific microsomal protein that is post-transcriptionally regulated *in vitro*. *J Biol Chem* 1993; **268**: 15751–15757.
- 16 Nicoletti A, Wong DJ, Kawase K *et al*: Molecular characterization of the human gene encoding an abundant 61 kDa protein specific to the retinal pigment epithelium. *Hum Molec Genet* 1995; **4**: 641–649.
- 17 Leber T: Über retinitis pigmentosa und angeborene Amaurose. *Graefes Arch Klin Exp Ophthalmol* 1869; **15**: 13–20.
- 18 Rando RR: Membrane phospholipids as an energy source in the operation of the visual cycle. *Biochemistry* 1991; **3**: 595–602.
- 19 Hubbard R: Retinene isomerase. *J Gen Physiol* 1956; **39**: 935–962.
- 20 Lion F, Rotmans JP, Daemen FJM, Bonting SL: Biochemical aspects of the visual process. XVII Stereospecificity of ocular retinol dehydrogenase and the visual cycle. *Biochim Biophys Acta* 1975; **384**: 283–292.
- 21 Simon A, Hellman U, Wernstedt C, Eriksson U: The retinal pigment epithelial-specific 11-*cis* retinol dehydrogenase belongs to the family of short chain alcohol dehydrogenases. *J Biol Chem* 1995; **270**: 1107–1112.