

ARTICLE

PUF60 variants cause a syndrome of ID, short stature, microcephaly, coloboma, craniofacial, cardiac, renal and spinal features

Karen J Low^{1,2}, Morad Ansari³, Rami Abou Jamra⁴, Angus Clarke⁵, Salima El Chehadeh⁶, David R FitzPatrick³, Mark Greenslade⁷, Alex Henderson⁸, Jane Hurst⁹, Kory Keller¹⁰, Paul Kuentz¹¹, Trine Prescott¹², Franziska Roessler⁴, Kaja K Selmer¹², Michael C Schneider¹³, Fiona Stewart¹⁴, Katrina Tatton-Brown¹⁵, Julien Thevenon¹¹, Magnus D Vigeland¹², Julie Vogt¹⁶, Marjolaine Willems¹⁷, Jonathan Zonana¹⁰, DDD Study¹⁸ and Sarah F Smithson^{*,1,2}

PUF60 encodes a nucleic acid-binding protein, a component of multimeric complexes regulating RNA splicing and transcription. In 2013, patients with microdeletions of chromosome 8q24.3 including **PUF60** were found to have developmental delay, microcephaly, craniofacial, renal and cardiac defects. Very similar phenotypes have been described in six patients with variants in **PUF60**, suggesting that it underlies the syndrome. We report 12 additional patients with **PUF60** variants who were ascertained using exome sequencing: six through the Deciphering Developmental Disorders Study and six through similar projects. Detailed phenotypic analysis of all patients was undertaken. All 12 patients had *de novo* heterozygous **PUF60** variants on exome analysis, each confirmed by Sanger sequencing: four frameshift variants resulting in premature stop codons, three missense variants that clustered within the RNA recognition motif of **PUF60** and five essential splice-site (ESS) variant. Analysis of cDNA from a fibroblast cell line derived from one of the patients with an ESS variants revealed aberrant splicing. The consistent feature was developmental delay and most patients had short stature. The phenotypic variability was striking; however, we observed similarities including spinal segmentation anomalies, congenital heart disease, ocular colobomata, hand anomalies and (in two patients) unilateral renal agenesis/horseshoe kidney. Characteristic facial features included micrognathia, a thin upper lip and long philtrum, narrow almond-shaped palpebral fissures, synophrys, flared eyebrows and facial hypertrichosis. Heterozygote loss-of-function variants in **PUF60** cause a phenotype comprising growth/developmental delay and craniofacial, cardiac, renal, ocular and spinal anomalies, adding to disorders of human development resulting from aberrant RNA processing/spliceosomal function.

European Journal of Human Genetics (2017) 25, 552–559; doi:10.1038/ejhg.2017.27; published online 22 March 2017

INTRODUCTION

In 2009, Verheij *et al.*¹ reported overlapping interstitial microdeletions of chromosome 8q24 in two patients who had colobomata, congenital heart defects, limb abnormalities, developmental delay and seizures (MIM 615583). Dauber *et al.*² later described five patients who also had microdeletions of 8q24.3 and similar phenotypes including ocular colobomata, microcephaly, developmental delay, short stature, craniofacial, cardiac and renal defects. All five patients had in common a 78-kb deleted region containing three genes: *SCRIB*, *NRBP2* and *PUF60*. A further patient with a missense variant in *PUF60*² and a foetus with an 8q24.3 deletion encompassing *PUF60* occurring in association with an atrioventricular septal defect, a hypoplastic aortic arch, facial dysmorphism

and other anomalies³ strongly implicated this single gene as the cause of the phenotype.

The poly-U-binding splicing factor gene (*PUF60*) encodes a nucleic acid-binding protein, which through interaction with other proteins such as SF3B4, regulates pre-RNA splicing and transcription.^{2,4} In 2013 a single patient with an intragenic variant in *PUF60* was identified² and recently five other cases have been reported.⁵ Here, we present clinical and molecular data from 12 additional patients with *de novo* variants in *PUF60* identified via exome sequencing undertaken for undiagnosed developmental disorders. The clinical features we observed in these patients and those previously published suggest that there is an emerging *PUF60*-related phenotype, although this is variable and may be difficult to recognize.

¹Department of Clinical Genetics, St Michaels Hospital, Bristol, UK; ²School of Clinical Sciences, University of Bristol, Bristol, UK; ³MRC Human Genetics Unit, MRC Institute of Genetics and Molecular Medicine, University of Edinburgh, Edinburgh, UK; ⁴Institute of Human Genetics, University of Leipzig Hospitals and Clinics, Leipzig, Germany; ⁵Institute of Medical Genetics, University Hospital of Wales, Cardiff, UK; ⁶Service de Génétique Médicale, Hôpital de Haute-pierre, Strasbourg, France; ⁷Bristol Regional Genetics Laboratory, Southmead Hospital, Bristol, UK; ⁸Northern Genetics Service, Newcastle upon Tyne Hospitals, Newcastle, UK; ⁹Department of Clinical Genetics, Great Ormond Street Hospital, London, UK; ¹⁰Department of Molecular and Medical Genetics, Oregon Health and Sciences University, Portland, OR, USA; ¹¹Centre de Génétique, CHU Dijon Bourgogne—Hôpital François Mitterrand, Dijon, France; ¹²Department of Medical Genetics, Oslo University Hospital, Oslo, Norway; ¹³Genetics and Metabolism, Pediatric Subspecialties, Carle Physicians Group, Urbana, IL, USA; ¹⁴Northern Ireland Regional Genetics Service, Belfast City Hospital, Belfast, UK; ¹⁵SW Thames Regional Genetics Service, St Georges University Hospital Trust, London, UK; ¹⁶West Midlands Regional Genetics Service, Birmingham, UK; ¹⁷Service de Génétique Médicale, Hôpital Arnaud de Villeneuve, CHRU de Montpellier, Montpellier, France; ¹⁸Wellcome Trust Sanger Institute, Cambridge, UK

*Correspondence: Dr SF Smithson, Department of Clinical Genetics, University Hospitals Bristol NHS Foundation Trust, St Michaels Hospital, Southwell Street, Bristol BS2 8EG, UK. Tel: +44 1173425652; Fax: +44 1173421508; E-mail: sarah.smithson@uhbristol.nhs.uk

Received 5 December 2016; revised 18 January 2017; accepted 31 January 2017; published online 22 March 2017

METHODS

Patient ascertainment

Six of the affected patients were recruited via the Deciphering Developmental Disorders (DDD) study⁶ (<http://www.ddduk.org>) open to the UK NHS Regional Genetics Services. Five patients were recruited via locally based exome sequencing services by Clinical Geneticists in Norway, France and the United States and one via an exome sequencing study for patients with Cornelia de Lange Syndrome (CdLS; MIM 122470).⁶ All patients were assessed by their Clinical Geneticist who assisted with systematic detailed phenotyping. Patient growth centiles and *z*-scores were calculated using the UK WHO data (<http://www.rcpch.ac.uk/growthcharts>).

Genomic analysis

Trio-based exome sequencing was undertaken for the six affected patients and their parents were identified via the DDD study.⁷ High-resolution analysis for copy number abnormalities using array-based comparative genomic hybridization was also performed. Putative *de novo* variants were identified from exome data using the DeNovoGear software⁸ and then validated by targeted Sanger sequencing. For patients 7–12, alternative but similar trio exome sequence approaches were used, for example, for patient 10 a proband-based exome sequencing as described previously,⁸ for patient 11 exome capture with Nextera Rapid Capture Exome Kit (Illumina Inc., San Diego, CA, USA) and sequencing with HiSeq4000 (Illumina). For patient 12, Agilent Clinical Research Exome Kit (Agilent Technologies, Santa Clara, CA, USA) identified exonic and perixonic fragments, followed by massive parallel next-generation sequencing. Analysis of exome data was undertaken with DeNovoGear⁹ or FILTUS,¹⁰ and for patient 11, raw data was processed using an end-to-end in-house database. Identified variants were annotated using standard databases and were filtered based on the established criteria. Detailed descriptions of the wet and dry laboratory pipelines are published elsewhere.¹¹ For patient 12, analysis was performed with a custom-developed Xome Analyser (Gene Dx, Bethesda, MD, USA). Mean depth of coverage for the analysis was $\times 121$; and quality threshold ($\geq 10\times$) was achieved for 95.5% of the target sequence. As for DDD patients, significant variants were confirmed by targeted Sanger sequencing. Variant data has been submitted to ClinVar (<https://www.ncbi.nlm.nih.gov/clinvar/>) – submission ID SUB2319251.

Analysis of aberrant PUF60 splicing

Dermal fibroblasts were obtained from patient 8 (3781–3781) by skin punch biopsy and cultured in amnioMAX C-100 complete medium (Life Technologies, Carlsbad, CA, USA) as described previously.¹² RNA was extracted from primary skin-derived fibroblast cell lines from patient 8 (3781–3781) and two sex-matched controls using RNeasy Kit (Qiagen, Hilden, Germany) and treated with DNaseI to eliminate genomic DNA, according to the manufacturer's instructions. Complementary DNA (cDNA) synthesis was carried out using random oligomer primers and AMV Reverse Transcriptase (Roche, Penzberg, Germany). The cDNA samples were resolved on an E-Gel electrophoresis system and extracted according to the manufacturer's instructions (Thermo Fisher Scientific, Waltham, MA, USA) to sequence the amplicons corresponding to the normal and mutant alleles. Sequences of primers used for cDNA amplification and Sanger sequencing of *PUF60* are available upon request.

RESULTS

The clinical features and *PUF60* variants in the 12 patients compared with the previously reported cases^{2,5} are presented in Table 1.

Variants

The distribution of the heterozygous *de novo* variants (DNV) is shown in context of the genomic structure of *PUF60* in Figure 1. Nine of the DNV were predicted to cause loss-of function suggesting haplo-insufficiency as the likely mutational mechanism. Four patients (1 (DDD275875),¹³ 5 (DDD270021), 9 and 11) had frameshift variants resulting in early stop codons. Five patients (2 (DDD273705), 7 (who had the most complex phenotype), 8 (3781–3781), 10 and 12) had essential splice-site variants. In patient 8 (3781–3781), a *de novo*

c.604 – 2A > C variant occurred in the exon 8 splice-acceptor site and was predicted to alter splicing of *PUF60* mRNA. The effect of this variant was investigated as above: analysis of cDNA confirmed abnormal inclusion of the complete intron 7 in the mutant allele resulting in an apparent in-frame inclusion of 39 amino acids in the open reading frame of the transcript (Figure 2). It is thus not clear whether this essential splice-site variant will result in complete loss of function. Nonetheless, her phenotype is consistent with respect to developmental delay, short stature and cardiac involvement. Patient 12 was the only one to have a variant outside of the exon 6–12 region. The wild-type donor site is predicted to be disrupted resulting in skipping of exon 1; however, little is known about the exon 1 function (Human Splicing Finder score of – 31.86 – probably affecting splicing; <http://www.umd.be/HSF3/HSF.html>).

Three patients in this study had missense variants located in regions encoding one of the three RNA recognition motif (RRM) domains of the protein (Alamut, c.541G > A(p.(Glu181Lys)) and c.475G > A(p.(Asp159Asn)) are located in RRM1 and c.1472G > A(p.(Gly491Glu)) in RRM3. CADD scores¹⁴ are shown in Table 1 and support effect on function of all three variants.

None of the *PUF60* variants we identified are listed in the Exome Variant Server, Exome Aggregation Consortium or the dbSNP population databases.

Growth

Birthweight was normal except for patients 6 (DDD263362; *Z*-score – 2.14), 8 (3781–3781; *Z*-score – 2.11) and 11 (*Z*-score – 3.24). Body weight in childhood remained in the normal range in all patients apart from patients 7 and 8 (3781–3781; *Z*-scores – 4.47 and – 3.52 respectively) in both of whom other growth parameters were also significantly reduced. Nine patients had short stature defined as height below 5th centile and five had *Z*-scores below – 2. Head circumference was proportionate to stature, apart from in five patients (1 (DDD275875), 6 (DDD263362), 7, 10 and 11) who had true microcephaly (*Z*-scores – 2.48, – 4.22, – 2.09, – 2.99, – 2.53 respectively).

Musculoskeletal

Skeletal abnormalities, especially in the spine, were seen in seven patients. In patient 3 (DDD271317), there was fusion of the whole vertebral bodies of C6 and C7 and the anterior part of C5 (Figure 3) and the posterior spinous processes of T6, T7 and T1 were unusually prominent. His cervical spine stability requires neurosurgical monitoring. Patient 7 had several cervical and thoracic hemivertebrae, spina bifida, thoracic kyphosis, bilateral rudimentary ribs at C7 and pectus excavatum (possibly exacerbated by sternotomy during cardiac surgery). In patient 9, the conus terminated at the L2–L3 disc space and the filum, 2 mm in width, extended from L3 to S2 associated with posterior osseous dysraphism of the sacrum. Patients 6 (DDD263362), 10 and 12 had pectus excavatum. Patient 1 (DDD275875) had a lower thoracic scoliosis and pes planus. He also had shoulder subluxation and generalized joint laxity, which was a common feature in the cohort. Patients 2 (DDD273705), 7, 9, 10 and 12 also had joint hypermobility; in one case this was associated with bilateral hip and interphalangeal joint dislocations. Digital anomalies in the group included unilateral preaxial polydactyly of the left hand with a broad proximal phalanx and duplicated distal phalanx (patient 7), short broad hands with bilateral fifth finger clinodactyly (patient 5 (DDD270021)), left talipes, broad thumbs/halluces, fifth finger clinodactyly, 2–3 toe syndactyly with an overriding second toe on the left (patient 6 (DDD263362)) and bilateral hypoplasia of the fifth fingers (patient 9).

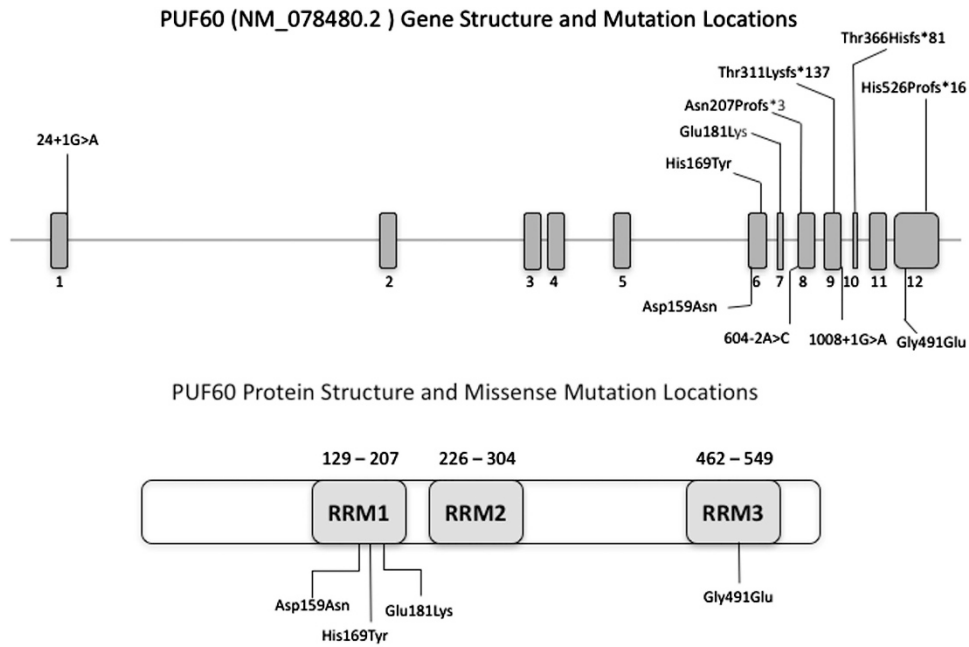


Figure 1 *PUF60* gene diagram (above) indicating mutations found in our cohort which cluster in the second half of the coding region, apart from the single variant in exon 1. Note recurrent splicing variant in exon 8. Below is pictured the known protein structure and location of RRM domains in relation to the missense variants.

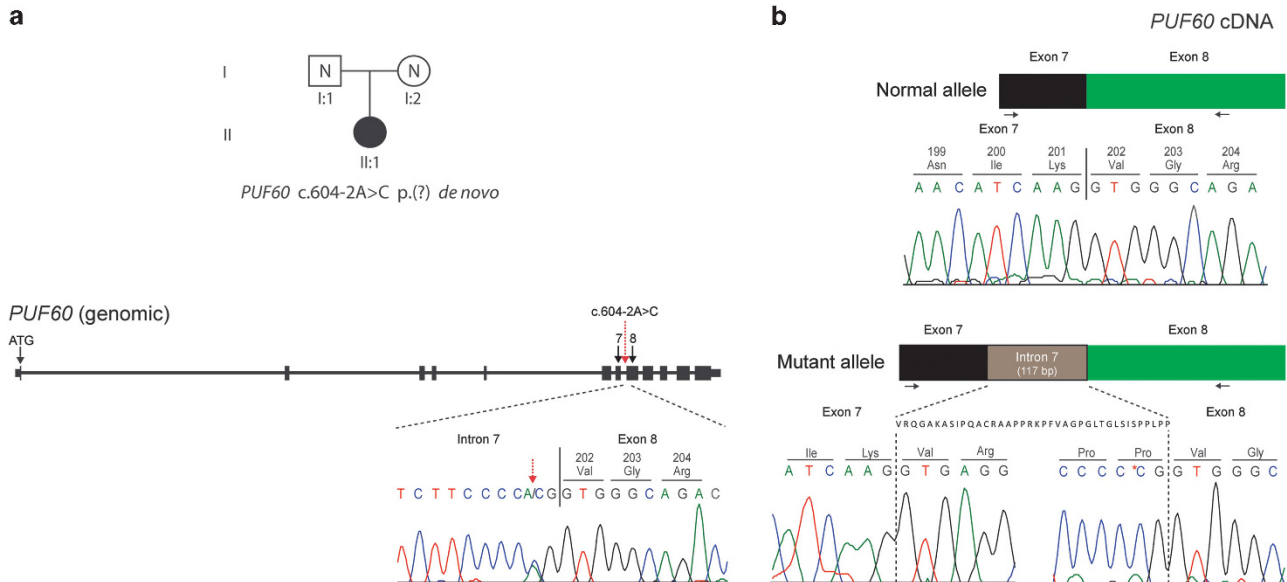


Figure 2 A *de novo* variant in *PUF60* results in aberrant splicing at exon 8 splice-acceptor site. (a) The heterozygous, *de novo* *PUF60* variant, c.604-2A>C was identified in patient II:1 through trio-based exome sequencing of family 3781. (b) Sequencing of skin-derived cDNA from patient II:1 (family 3781) showed normal splicing of exons 7 and 8 from one allele (top) and aberrant splicing with inclusion of the complete intron 7 from the mutant allele (bottom). Black arrows show the position of the oligonucleotide primers used for cDNA amplification and sequencing. The genomic context of the *PUF60* gene is shown, with exons indicated as black boxes. The location of the *PUF60* c.604-2A>C variant in intron 7 is indicated by a dotted red arrow, with the Sanger sequence trace from patient II:1 (family 3781) presented underneath. Variant nomenclature, exon numbering and the *PUF60* messenger RNA sequence are based on sequence accession numbers NM_078480.2 (mRNA) and NP_510965.1 (protein) and GenBank accession number NG_033879.1.

Auditory

Two patients had very narrow and easily occluded external auditory meatus, two had severe otitis media with episodic conductive hearing loss and two wear hearing aids for bilateral conductive hearing loss.

Development

All patients had mild to moderate global developmental delay. Most walked by 24 months and the latest did so by 30 months (patient 12 was not yet walking at 24 months). Most spoke their first word by 30 months. Three patients had difficulties forming a pincer grip and

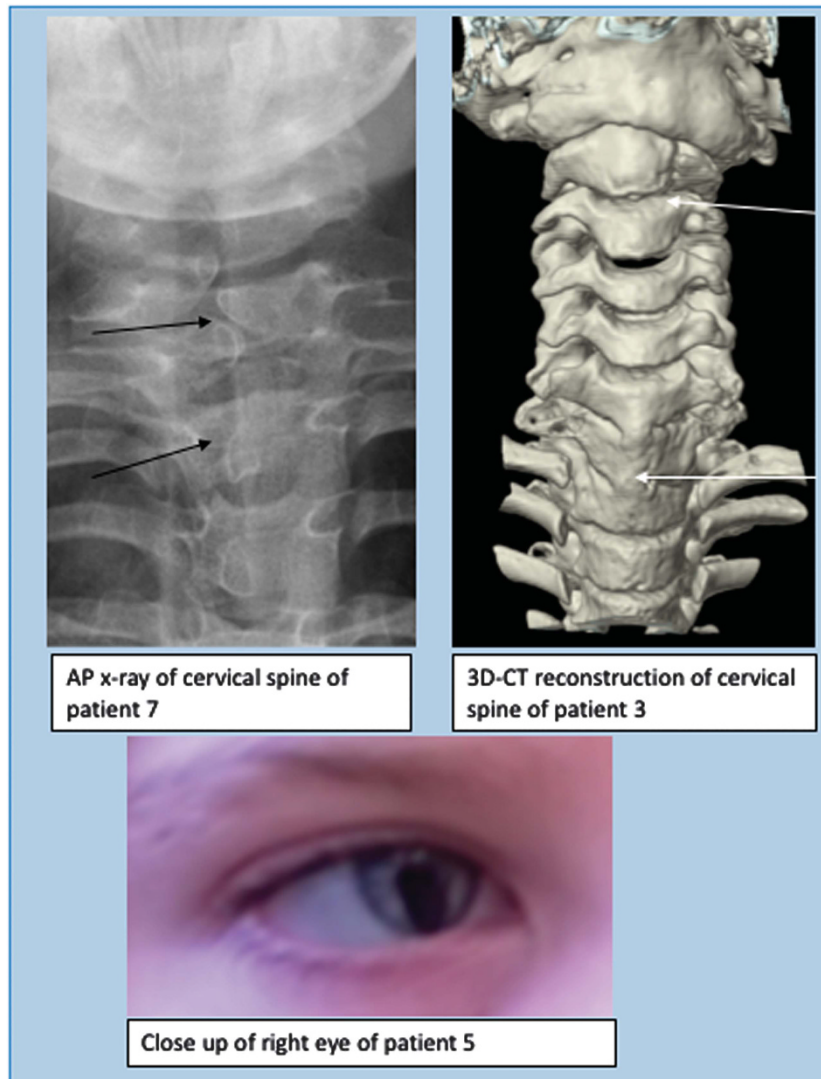


Figure 3 Spinal features (above): AP x-ray of cervical spine of patient 7 demonstrating hemivertebrae (left) and 3D-CT reconstruction of cervical spine of patient 3 demonstrating abnormalities of articulation of atlas with C1, vertebral bodies of C2/C3 and fusion of bodies of C6/C7/T1 and ocular features (below): right iris coloboma in patient 5.

with fine motor coordination for activities such as handwriting. For those who are currently of school age, all receive additional educational support and four attend either a special needs school or class. Some episodes of difficult or immature behaviour including attention deficit disorder, head-banging, self-injury or temper tantrums were reported by parents of five patients.

Neurology

Patient 6 (DDD263362) had a stormy postnatal course during which bilateral intraventricular haemorrhages occurred, later associated with mild diplegia. An MRI brain scan showed periventricular leukomalacia, a thin corpus callosum and a cyst at the right cerebellopontine angle. Patient 7 had a cardiac catheterization at 9 months of age and following a right middle cerebral artery occlusion had a left-sided hemiparesis and right facial weakness. A brain MRI scan of patient 11 showed mild periventricular gliosis. Patient 12 had an MRI scan, which showed cerebral ventriculomegaly, partial agenesis corpus

callosum and loss of white matter in the periventricular regions. Two patients have developed seizures.

Facial features

The facial features (Figure 4) included a short neck in five >patients, a high forehead in six, micrognathia in four, a long philtrum in five, bushy eyebrows in four and a thin upper lip in four patients. One patient had synophrys and long eyelashes, another had bilateral preauricular pits and a third, a right accessory auricle and skin tag on the contralateral side of the neck. Two patients had facial features initially suggesting CdLS. Two other patients were tested for mutations in *CREBBP* and *EP300* initially. One patient was tested for Coffin–Siris syndrome.

Other

Recurrent ocular, cardiac and renal features occurred and are detailed in Table 1. Five patients had hypertrichosis of the face. Two patients had macrodontia, one with ectopic teeth and one

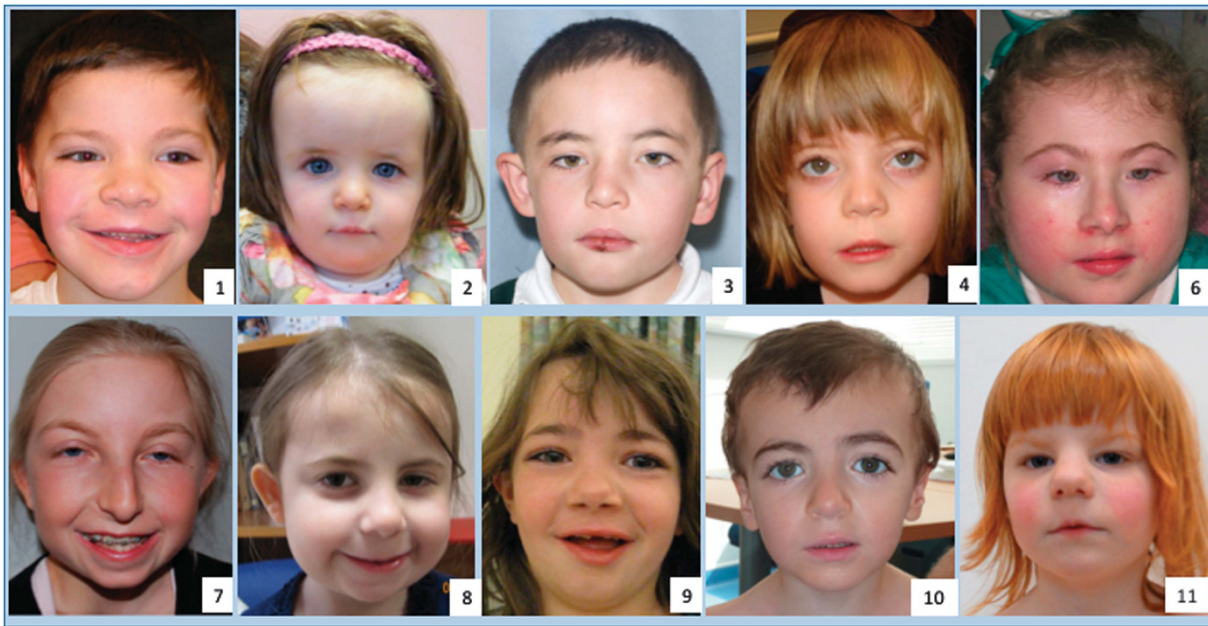


Figure 4 Faces of patients (1, 2, 3, 4, 6, 7, 8, 9, 10 and 11) with *PUF60* variants, illustrating the thin upper lip, long philtrum, micrognathia and the flaring of eyebrows and narrow almond-shaped palpebral fissures, which are variably present. Patients 6 and 8 were assessed for CdLS and patients 7 and 10 had *CREBBP* analysis because of facial similarities with Rubinstein–Taybi syndrome. Patient 9 was investigated for Coffin–Siris syndrome.

early secondary dentition. Early feeding problems were very common: in one patient a gastrostomy was required from 9 months to 7 years of age and three patients were prone to aspiration episodes and complications in infancy, this resolved in two of them by late infancy.

DISCUSSION

The clinical and molecular data we observed in 12 patients suggest that variants in *PUF60* cause a syndrome characterized by short stature, developmental delay, dysmorphic facial features and structural malformations of the heart, eye and variably other organs. We are aware of 14 *PUF60*-related published cases: six with intragenic *de novo* missense variants^{2,5} and eight with chromosome 8q24.3 deletions encompassing *PUF60*.^{1–3} The pattern of their congenital malformations and perturbation of growth and development shows some common themes.

Comparison of our patients with the six previously published for whom data are available (Table 1) suggests that short stature, relative microcephaly and developmental/cognitive delay are consistent findings. The only exception is patient 12 who had macrocephaly, hydrocephalus and normal stature, and in whom the variant was at the exon 1 boundary. A previously published patient had an identical variant⁵ but their phenotype was more typical, thus predictions on phenotype based on position of specific variants are not possible at this stage. We observed other similarities: a high proportion of cases overall had abnormal segmentation of the vertebrae, which occurred at different levels of the spine. One of our patients and two published patients⁵ had cervical vertebral fusion/abnormal cervical spines. Other authors found more distal lesions such as fusion of L5–S1, sacral dysplasia and agenesis of the coccyx,² and other patients, including patients 7, had hemivertebrae in the thoracic and lumbar spine. We and others found minor developmental abnormalities of the distal limbs, including brachydactyly of the fifth fingers, clinodactyly and preaxial polydactyly. Ocular coloboma involving the anterior segment of the eye, choroid and/or the retina, were described in three previous as well as in two of our patients. Renal

malformations such as ectopic fused kidneys, pelvic kidney, a unilateral polycystic kidney and renal hypoplasia or unilateral agenesis have been observed,^{2,5} and in our cohort there was one case each of a unilateral kidney and a horseshoe kidney. Five of our patients had significant congenital heart defects and other authors⁵ have also reported ventricular septal defects in combination with truncus arteriosus coarctation or the aorta and bicuspid aortic valve² and atrioventricular septal defects and hypoplastic aortic arch.³

While all 26 patients with deletions or variants of *PUF60* had developmental delay and intellectual disability, those with deletions appear to be more severely affected.^{1,2} The reported microdeletions of chromosome 8q24.3 may include other currently unknown genes that contribute to neurological and cognitive development. It is interesting that seizures were observed in our patients as well as in previous reports. Feeding difficulties and recurrent respiratory infections were common to some patients in both groups.

Previous authors commented on phenotypic similarity of *PUF60*-deleted patients with *SF3BF4*-related Nager syndrome (MIM 154400) and *EFTUD2*-related mandibulofacial dysostosis (MIM 610536) and suggested that *PUF60* deficiency can be considered within the spectrum of craniofacial disorders resulting from spliceosome malfunction.¹⁵ However, coloboma, optic nerve hypoplasia and facial hirsutism have not hitherto been reported in syndromes ascribed to spliceosomal dysfunction. We and others noticed that some patients had features reminiscent of CdLS, particularly where facial hypertrichosis and prominent eyebrows were present. Comparison of the facial features in all patients with *PUF60* deletions or variants where data were available indicated that micrognathia, a long philtrum and thin upper lip, synophrys, preauricular pits and cranial asymmetry were common findings. Additionally, two of our patients had very narrow external auditory canals, consistent with abnormal branchial arch development during embryogenesis, also thought to be a process disturbed in mandibulofacial dysostosis and Nager syndromes; however, the facial

dysmorphology of patients with *PUF60* variants is far more subtle than in *EFTUD2* and *SF3B4*-related phenotypes and mandibulofacial dysostosis was not present in the patients we report. Furthermore, it is interesting to note that none of the patients were clinically suspected of a known spliceosomopathy. We conclude that the facial features associated with *PUF60* might be recognized independently, but the diagnosis is more likely to be considered in a child with short stature, developmental delay and additional malformations described.

There is accumulating evidence from this and other phenotypic studies that *PUF60* is important in human embryonic development. *PUF60* belongs to the RRM half pint family and contains three RRM domains. Consistent with a developmental role, *PUF60* encodes a DNA- and RNA-binding protein that is involved in diverse nuclear processes such as pre-mRNA splicing and regulation of transcription. During pre-mRNA splicing, *PUF60* interacts with *U2AF2* to promote splicing of an intron with a weak 3' splice site⁴ and has a role in alternative splicing.² *PUF60* is one of the non-core components that can ally with the U2 spliceosomal small nuclear ribonucleoprotein particles, or U2 spliceosome complex.¹⁶ Finally, *PUF60* has been associated with the transcriptional repression of *MYC* through association with *FUBP1*. The mechanism by which reduced *PUF60* expression affects cellular functions are not yet understood and beyond the scope of this study. It is an interesting thought that the *PUF60*-related phenotype is more diverse than some others determined by spliceosomal genes, where very specific and recognizable malformations arise.¹⁷ Presumably, specific tissues are *PUF60* dose-sensitive at specific times during early human development.

The similar phenotypes in 8q24.3 deletions encompassing the entire *PUF60* gene and the point variants in our series, including both missense and null variants, suggest that haploinsufficiency is the common mechanism in all. Loss-of-function variants are predicted to result in altered dosage of different *PUF60* isoforms and consequently abnormal splicing of target genes.² Variants in this gene would therefore be expected to have widespread phenotypic effects. Previous researchers found that patient-derived cells demonstrated expression of a truncated specific isoform of *PUF60*.² They also showed that suppression of *puf60* in developing zebrafish resulted in reduced body length, microcephaly, craniofacial defects and cardiac anomalies. Additionally, they found evidence that suppression of the *scrib* gene (syntenic and adjacent to *PUF60* in humans) caused defects such as colobomata and renal anomalies, and thus concluded that some features of the 8q24.3 deletion phenotype might be due to this contiguous gene. Our data together with the other six reported cases suggest that *PUF60* deficiency itself could account for these features in humans. We anticipate that more patients with *PUF60* variants will be described, which, in association with functional studies, will help to delineate the characteristics of this complex syndrome.

CONCLUSIONS

Chromosome 8q24.3 deletions have been associated with a phenotype encompassing microcephaly and short stature, developmental delay, colobomata, craniofacial, skeletal, cardiac and renal anomalies. Our findings demonstrate a very similar pattern of mild or moderate intellectual disability and physical characteristics observed in patients with variants in *PUF60*. We suggest that loss or reduction of expression of *PUF60* results in a complex human phenotype with subtle facial features and a consistent pattern of congenital malformations, especially involving the heart and spine.

CONFLICT OF INTEREST

The authors declare no conflict of interest.

ACKNOWLEDGEMENTS

The DDD study presents independent research commissioned by the Health Innovation Challenge Fund (grant number HICF-1009-003), a parallel funding partnership between the Wellcome Trust and the Department of Health and the Wellcome Trust Sanger Institute (grant number WT098051). The views expressed in this publication are those of the author(s) and not necessarily those of the Wellcome Trust or the Department of Health. The study has UK Research Ethics Committee approval (10/H0305/83, granted by the Cambridge South REC, and GEN/284/12, granted by the Republic of Ireland REC). The research team acknowledges the support of the National Institute for Health Research, through the Comprehensive Clinical Research Network. The work of KKS and MDV was funded by the South-Eastern Norway Regional Health Authority (grant number 2012066). We thank Geoff Woodward and Marc Wadsley, bioinformaticians at the Bristol Genetics Laboratory, for their assistance with CADD scores. We would also like to thank all the local clinicians and health-care professionals involved with these children. We would especially like to thank the families of all the patients described here for working with us on this project and for consenting to this publication.

AUTHOR CONTRIBUTIONS

KJL: phenotypic analysis of patients, data collection and interpretation and first author of manuscript; MA: laboratory work and RNA work patient 8 and input to manuscript; RAJ: senior clinician patient 10 and review of manuscript; AC, clinician patient 1 and review of manuscript; SEC, referral of patient 10, input to manuscript; DRF: head of lab patient 8 and DDD senior collaborator; MG: lab collaborator, CADD score input, review of manuscript; AH: clinician patient 2, review of manuscript; JH: clinician patient 4, review of manuscript; KK: genetic counsellor patient 9, review of manuscript; PK: laboratory scientist patient 10, review of manuscript; TP: clinician patient 7, input to manuscript and review; FR: clinician patient 11, input to manuscript and review; KKS: laboratory scientist patient 7, review of manuscript; FS: clinician patient 5, review of manuscript; KT-B: clinician patient 8, review of manuscript; JT: laboratory scientist patient 10, review of manuscript; MDV: laboratory scientist patient 7, input to manuscript and review; JV: clinician patient 6, review of manuscript; JZ: clinician patient 9, review of manuscript; DDD study: exome analysis and reporting of all named DDD patients; SFS, clinician patient 3, phenotypic analysis, significant input in to manuscript and review, senior author and supervisor of project.

- 1 Verheij JBG, de Munnik SA, Dijkhuizen T *et al*: An 8.35 Mb overlapping interstitial deletion of 8q24 in two patients with coloboma, congenital heart defect, limb abnormalities, psychomotor retardation and convulsions. *Eur J Med Genet* 2009; **52**: 353–357.
- 2 Dauber A, Golzio C, Guenot C *et al*: *SCRIB* and *PUF60* are primary drivers of the multisystemic phenotypes of the 8q24.3 copy-number variant. *Am J Hum Genet* 2013; **93**: 798–811.
- 3 Wells C, Spaggiari E, Malan V *et al*: First fetal case of the 8q24.3 contiguous genes syndrome. *Am J Hum Genet* 2016; **170A**: 239–242.
- 4 Hastings ML, Allemand E, Duelli DM, Myers MP, Krainer AR: Control of pre-mRNA splicing by the general splicing factors *PUF60* and *U2AF(65)*. *PLoS One* 2, 2007; e538.
- 5 El Chehadeh S, Kerstjens-Frederikse WS, Thevenon J *et al*: Dominant variants in the splicing factor *PUF60* cause a recognizable syndrome with intellectual disability, heart defects and short stature. *Eur J Hum Genet* 2016; **25**: 43–51.
- 6 Ansari M, Poke G, Ferry Q *et al*: Genetic heterogeneity in Cornelia de Lange syndrome (CdLS) and CdLS-like phenotypes with observed and predicted levels of mosaicism. *J Med Genet* 2014; **51**: 659–668.
- 7 Wright CF, Fitzgerald TW, Jones WD *et al*: Genetic diagnosis of developmental disorders in the DDD study: a scalable analysis of genome-wide research data. *Lancet* 2014; **385**: 1305–1314.
- 8 Thevenon J, Duffourd Y, Masurel-Paulet A *et al*: Diagnostic odyssey in severe neurodevelopmental disorders: toward clinical whole-exome sequencing as a first-line diagnostic test. *Clin Genet* 2016; **89**: 700–707.
- 9 Ramu A, Noordam MJ, Schwartz RS *et al*: DeNovoGear: *de novo* indel and point mutation discovery and phasing. *Nat Methods* 2013; **10**: 985–987.
- 10 Vigeland MD, Gjølterud KS, Selmer KK: FILTUS: a desktop GUI for fast and efficient detection of disease-causing variants, including a novel autozygosity detector. *Bioinformatics* 2016; **32**: 1592–1594.
- 11 Trujillano D, Bertoli-Avella A, Kandaswamy K *et al*: Clinical exome sequencing – results from 2819 samples reflecting 1000 families. *Eur J Hum Genet* 2017; **25**: 176–182.
- 12 Martin CA, Ahmad I, Klingseisen A *et al*: Mutations in *PLK4*, encoding a master regulator of centriole biogenesis, cause microcephaly, growth failure and retinopathy. *Nat Genet* 2014; **46**: 1283–1292.

- 13 Firth HV, Richards SM, Bevan AP *et al*: DECIPHER: Database of Chromosomal Imbalance and Phenotype in Humans using Ensembl Resources. *Am J Hum Genet* 2009; **84**: 524–533.
- 14 Kircher M, Witten DM, Jain P, O’Roak BJ, Cooper GM, Shendure J: A general framework for estimating the relative pathogenicity of human genetic variants. *Nat Genet* 2014; **46**: 310–315.
- 15 Lehalle D, Wieczorek D, Zechi-Ceide RM *et al*: A review of craniofacial disorders caused by spliceosomal defects. *Clin Genet* 2015; **88**: 405–415.
- 16 Patel SB, Bellini M: The assembly of a spliceosomal small nuclear ribonucleoprotein particle. *Nucleic Acids Res* 2008; **36**: 6482–6493.
- 17 Tooley M, Lynch D, Bernier F: Cerebro-costo-mandibular syndrome: clinical, radiological and genetic findings. *Am J Med Genet* 2016; **170**: 1115–1126.



This work is licensed under a Creative Commons Attribution 4.0 International License. The images or other third party material in this article are included in the article’s Creative Commons license, unless indicated otherwise in the credit line; if the material is not included under the Creative Commons license, users will need to obtain permission from the license holder to reproduce the material. To view a copy of this license, visit <http://creativecommons.org/licenses/by/4.0/>

© The Author(s) 2017