

CORRIGENDUM

A defect in the *CLIP1* gene (*CLIP-170*) can cause autosomal recessive intellectual disability

Farzaneh Larti, Kimia Kahrizi, Luciana Musante, Hao Hu, Elahe Papari, Zohreh Fattahi, Niloofar Bazazzadegan, Zhe Liu, Mehdi Banan, Masoud Garshasbi, Thomas F Wienker, H Hilger Ropers, Niels Galjart and Hossein Najmabadi

European Journal of Human Genetics (2015) **23**, 416; doi:10.1038/ejhg.2014.152

Correction to: *European Journal of Human Genetics* (2015) **23**, 331–336; doi:10.1038/ejhg.2014.13; published online 26 February 2014

Upon revisiting their published work on a defect in the *CLIP1* gene, the authors noted that the brain MRI obtained from the affected girl

(IV: 7), which was reported to be normal at that time, showed a local white matter around fornices with abnormal signal of the frontal horns' 'focal leukoencephalopathy'. They would like to report focal leukodystrophy in the brain MRI of the patient with *CLIP1* mutation as a migration role of this gene in cortical neurons (Figure 1).

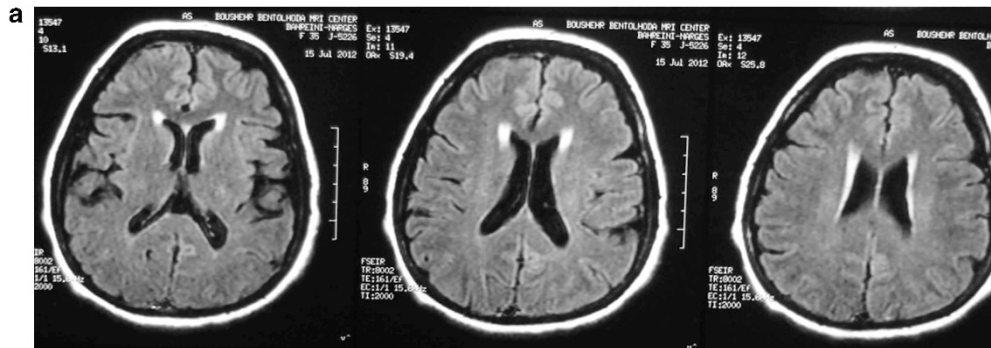


Figure 1 (a) Axial section of flair showed local white matter around fornices with abnormal signal of frontal horns' 'focal leukodystrophy'.