

ARTICLE

Redefining the MED13L syndrome

Abidemi Adegbola^{1,2,3}, Luciana Musante⁴, Bert Callewaert⁵, Patricia Maciel^{6,7}, Hao Hu⁴, Bertrand Isidor^{8,9}, Sylvie Picker-Minh^{10,11}, Cedric Le Caignec^{8,9}, Barbara Delle Chiaie⁵, Olivier Vanakker⁵, Björn Menten⁵, Annelies Dheedene⁵, Nele Bockaert¹², Filip Roelens¹³, Karin Decaestecker¹⁴, João Silva¹⁵, Gabriela Soares¹⁶, Fátima Lopes^{6,7}, Hossein Najmabadi¹⁷, Kimia Kahrizi¹⁷, Gerald F Cox¹⁸, Steven P Angus¹⁹, John F Staropoli²⁰, Ute Fischer⁴, Vanessa Suckow⁴, Oliver Bartsch²¹, Andrew Chess^{1,2,3}, Hans-Hilger Ropers⁴, Thomas F Wienker⁴, Christoph Hübner¹⁰, Angela M Kaindl^{10,11} and Vera M Kalscheuer^{*,4}

Congenital cardiac and neurodevelopmental deficits have been recently linked to the mediator complex subunit 13-like protein MED13L, a subunit of the CDK8-associated mediator complex that functions in transcriptional regulation through DNA-binding transcription factors and RNA polymerase II. Heterozygous MED13L variants cause transposition of the great arteries and intellectual disability (ID). Here, we report eight patients with predominantly novel MED13L variants who lack such complex congenital heart malformations. Rather, they depict a syndromic form of ID characterized by facial dysmorphism, ID, speech impairment, motor developmental delay with muscular hypotonia and behavioral difficulties. We thereby define a novel syndrome and significantly broaden the clinical spectrum associated with MED13L variants. A prominent feature of the MED13L neurocognitive presentation is profound language impairment, often in combination with articulatory deficits.

European Journal of Human Genetics (2015) **23**, 1308–1317; doi:10.1038/ejhg.2015.26; published online 11 March 2015

INTRODUCTION

Cardiovascular and central nervous system malformations are among the most common birth defects.¹ Although numerical chromosome aberrations and microdeletion/duplication syndromes are a well-known cause of congenital heart disease, few single genes have been associated with isolated congenital heart disease.² The mediator complex subunit 13-like gene *MED13L* (MIM^{*}608771; previously known as *THRAP2*, *PROSIT240*, *TRAP240L* and *KIAA1025*) is one of few genes linked to the pathogenesis of more severe cyanotic forms of non-syndromic congenital heart disease including dextro-looped transposition of the great arteries (d-TGA; MIM #608808)³ and other complex congenital cardiac defects.^{3,4}

MED13L encodes a subunit of the mediator complex that functions as a transcriptional coactivator for nearly all RNA polymerase II-dependent genes.^{5–8} MED13 (and likely MED13L) links mediator complex activity regulating cyclin-dependent kinase 8 (CDK8) module to core mediator and thus also regulates the complex activity.⁹

The involvement of *MED13L* in congenital heart defects, in particular in isolated d-TGA, was first shown in a study reporting an interruption of this gene as well as three missense

variants in four patients.³ At the same time, Musante *et al*¹⁰ reported a Noonan-like phenotype in a boy with a paternally inherited balanced translocation with one of the breakpoints mapping 28-kb upstream of *MED13L* exon 1. Heterozygous variants in *MED13L* have been described in a small number of patients presenting with dysmorphic features, developmental delay and complex cardiac defects.⁴ On the basis of these findings, *MED13L* is currently considered to be a single-gene cause of complex cyanotic heart defects. Two patients with non-syndromic intellectual disability (ID) and homozygous *MED13L* gene variants have been recently reported.¹¹ Despite the knowledge that common molecular mechanisms can cause congenital heart defects and neurodevelopmental diseases, complications of a congenital heart defect and possible surgical procedures have been held responsible for later apparent developmental delay in many cases. Here, we report a cohort of eight patients with mutant *MED13L* who lack complex congenital heart malformations but display facial dysmorphism, ID, speech impairment, motor developmental delay with muscular hypotonia and behavioral difficulties. This strongly supports a broader clinical spectrum of the *MED13L* syndrome than previously acknowledged.

¹Department of Developmental and Regenerative Biology, Icahn School of Medicine at Mount Sinai, New York, NY, USA; ²Department of Genetics and Genomic Sciences, Icahn School of Medicine at Mount Sinai, New York, NY, USA; ³Department of Neuroscience, Icahn School of Medicine at Mount Sinai, New York, NY, USA; ⁴Department of Human Molecular Genetics, Max Planck Institute for Molecular Genetics, Berlin, Germany; ⁵Center for Medical Genetics, Ghent University Hospital, Ghent, Belgium; ⁶Life and Health Sciences Research Institute (ICVS), School of Health Sciences, University of Minho, Campus de Gualtar, Braga, Portugal; ⁷ICVS/3B's – PT Government Associate Laboratory, Braga/Guimarães, Portugal; ⁸CHU Nantes, Service de Génétique Médicale, Institut de Biologie, Nantes, France; ⁹INSERM, UMR 957, Pathophysiology of Bone Resorption and Therapy of Primary Bone Tumours, Equipe Ligue Contre le Cancer 2012, Université de Nantes, Nantes, France; ¹⁰Department of Pediatric Neurology, Charité University Medicine, Berlin, Germany; ¹¹Institute of Cell Biology and Neurobiology, Charité University Medicine, Berlin, Germany; ¹²Pediatric Neurology, Ghent University Hospital, Ghent, Belgium; ¹³Pediatrics Department, Heilig Hart Hospital, Roeselare, Belgium; ¹⁴Pediatrics Department, Stedelijk Ziekenhuis, Roeselare, Belgium; ¹⁵Institute for Molecular and Cellular Biology (IBMC), Porto, Portugal; ¹⁶Center for Medical Genetics Dr Jacinto Magalhães, Porto Hospital Centre, Porto, Portugal; ¹⁷Genetic Research Center, University of Social Welfare and Rehabilitation Sciences, Tehran, Iran; ¹⁸Division of Genetics, Department of Pediatrics, Boston Children's Hospital, Boston, MA, USA; ¹⁹Department of Pharmacology, Lineberger Comprehensive Cancer Center, University of North Carolina School of Medicine, Chapel Hill, NC, USA; ²⁰Biogen Idec, 12 Cambridge Center, Building 6, Cambridge, MA, USA; ²¹Institute of Human Genetics, University Medical Center of the Johannes Gutenberg-University Mainz, Mainz, Germany

*Correspondence: Dr VM Kalscheuer, Department of Human Molecular Genetics, Max Planck Institute for Molecular Genetics, Ihnestr. 63-73, Berlin 14195, Germany. Tel: +49 30 8413 1293; Fax: +49 30 8413 1383; E-mail: kalscheu@molgen.mpg.de

Received 23 July 2014; revised 19 December 2014; accepted 6 January 2015; published online 11 March 2015

PATIENTS AND METHODS

Patients

Local ethics committees approved genetic studies, and their parents provided written informed consent for the molecular genetic analysis and the publication of clinical and radiological data as well as photographs. Mutations and phenotypic details were submitted to DECIPHER (<https://decipher.sanger.ac.uk/>).¹²

Genetic studies: molecular karyotyping and whole-exome sequencing

Genomic DNA and RNA samples were extracted from peripheral blood and lymphoblastoid cell lines according to standard protocols, respectively. For index 1, CGH microarray analysis was performed using the Agilent 244 K microarray chip. Parental DNA was assessed for the presence of the same microduplication using multiplex ligation-dependent probe amplification. Proband genomic DNA was sequenced for variants in *PTPN11*, *SOS1*, *RAF1*, *KRAS*, *BRAF*, *MAP2K1*, *HRAS*, *MAP2K2*, *SHOC2*, *NRAS*, *CBL* and *SPRED1*. No variants predicted to be deleterious were discovered (data not shown). For indexes 2, 3 and 5, copy number profiling was performed on 180 K oligonucleotide arrays (Agilent Technologies Inc., Diegem, Belgium) according to the manufacturer's instructions or with minor modifications as described.¹³ Copy number variation was evaluated using the in-house developed software tool arrayCGHbase.¹⁴ For indexes 4 and 8, CGH microarray analysis was performed on a human genome CGH Agilent 180 K custom array designed by the Low Lands Consortium (Dr Klas Kok) for the analysis of children with ID/developmental delay (AMADID:023363; Agilent Technologies Inc., Santa Clara, CA, USA). DNA labeling was performed using the ENZO Labeling Kit for Oligo Arrays (Enzo Life Sciences, Inc., Farmingdale, NY, USA) and MegaPoll reference DNA from Kretech Diagnostics (Amsterdam, The Netherlands). Arrays were hybridized using the Agilent SurePrint G3 Human CGH Microarray Kit, and data were extracted with the Agilent Feature Extraction (FE) Software v10.5 using default settings for CGH hybridizations. Image analysis was performed using the across-array methodology described previously.¹⁵ CGH data were analyzed using Nexus Copy Number 5.0 software (BioDiscovery, Hawthorne, CA, USA) with FASST Segmentation algorithm. For index 6 and her parents, genomic DNA was enriched using the Agilent SureSelect and whole-exome sequencing was performed, followed by bioinformatic analysis.^{11,16} The variant in *MED13L* was confirmed by PCR and Sanger sequencing. For index 7, Baylor BAC array CGH Version V6 and Agilent 105 K oligonucleotide array were performed. Interphase FISH (clone RP11-902D13) further confirmed a one-copy gain (data not shown). *MED13L* exons are numbered according to NG_023366.1.

Reverse transcription PCR (RT-PCR)

RT-PCR on index 2 and control cDNA was performed with *MED13L* primer set 5'-CGCGGAGGATCATGACTG-3' and 5'-TCCCAACTCGTCTTCCTCT-3'. Specific PCR products were Sanger sequenced using the same primer set.

Quantitative PCR analysis

Primers for qPCR were designed for *MED13L* (ENSG00000123066) and the reference genes *SDCA4* (ENSG00000124145) and *ZNF80* (ENSG00000174255). Primers and PCR conditions are available from the authors on request. Quantification was performed as described elsewhere.¹⁷

RESULTS

Patients with *MED13L* variants present with syndromic ID

By applying array CGH and whole-exome sequencing, we identified novel heterozygous *MED13L* variants, including microdeletions, microduplications and a *de novo* exonic dinucleotide deletion (Supplementary Figures 1 and 2A). These patients presented with strikingly consistent facial dysmorphism, variable degree of ID, speech impairment, motor developmental delay with muscular hypotonia, motor coordination difficulties, ataxia and behavioral difficulties. Remarkably, none of the patients had complex congenital heart defects (Table 1, Figure 1).

Index patient 1 was born at 37 weeks as the only affected child of a dizygotic twin pair of healthy, non-consanguineous American Caucasian parents (DECIPHER no. 296364). Her birth length was 48 cm (10–25 centile, –0.9 SD), weight was 2810 g (10–25 centile, –0.9 SD) and occipito-frontal head circumference (OFC) was 33 cm (10 centile, –1.2 SD), all normal. She presented with facial dysmorphism including a triangular face with low set ears and a bulbous nose, upslanted palpebral fissures, hypertelorism, ptosis, widely spaced teeth and prognathism, as well as a short neck. Clinical evaluation further revealed a high arched palate, bilateral cubitus valgus, adduction of feet, muscular hypotonia, poor coordination without ataxia and normal deep tendon reflexes. Language and motor development were severely delayed (first words spoken after 15 months, unaided walking after 3 years), and mild-to-moderate ID was present. Testing at 6 years with the Peabody Picture Vocabulary Test revealed a standard score of 70 (2 centile), equivalent to that expected at a chronological age of 3.5 years. On the CELF-Preschool test, she demonstrated sentence structure and expressive vocabulary skills significantly below her age with challenges particularly in speech intelligibility and verbal comprehension, but with strengths in her social communications skills. At 5.5 years, her Peabody Developmental Motor Scale revealed a Fine Motor Quotient of 73 (12 centile), and her Beery Test of Visual Motor Integration score was 66 (1 centile). She is myopic. Chronic ear infections in early childhood ceased after insertion of tympanostomy tubes at age 2. Echocardiography revealed a structurally normal heart. She displays normal, non-autistic behavior. Her current height at 11 years is 143 cm (25–50 centile, –0.5 SD), weight 46 kg (75–90 centile, 0.8 SD), and OFC 55.5 cm (90–97 centile, +2 SD). Array CGH analysis identified a *de novo* heterozygous likely intragenic duplication of *MED13L* exons 2–4 (180 kb, chr12. hg19:g.(116,484,299_116,497,981)_(116,681,549_116,695,774)dup) predicted to disrupt the gene.

Index patient 2 was born at term as the fourth child of healthy, non-consanguineous Caucasian parents of Belgium descent following a pregnancy complicated by gestational diabetes (DECIPHER no. 257915). Birth weight (3050 g; 10–25 centile, –0.7 SD), length (49 cm; 10–25 centile, –0.8 SD) and OFC (35 cm; 25–50 centile, –0.3 SD) were normal. He had a broad forehead, mild bitemporal narrowing, epicanthal folds, flat and broad nasal bridge, rounded nasal tip, broad columella, low set, posteriorly rotated ears with an uplift of the ear lobule, marked philtrum and full lips. He showed fifth finger clinodactyly. Language and motor development were severely delayed (first words spoken at 3 years, unaided sitting and walking at 13 and 24 months, respectively). Cognitive development was delayed by 8 months at the age of 22 months (Bayley's Scale of Infant Development) and by 20 months at the age of 40 months (Bayley's scale II of infant development: developmental index < 55). Clinical evaluation revealed muscular hypotonia including poor feeding as an infant and facial hypotonia with drooling. In addition, he displayed unilateral cryptorchidism, hyperreflexia without spasticity or pyramidal signs, ataxia, and autistic behaviors (stereotypic movements, avoidance of eye contact). Weight (12.5 kg, 10 centile), height (93 cm, 10 centile) and OFC (49.5 cm, 25 centile) were normal at the age of 3 years. He suffered from recurrent upper respiratory tract infections during childhood treated with prophylactic inhalation steroids. Cranial magnetic resonance imaging (cMRI) revealed delayed (cortical) myelination. No heart defect was identified through echocardiogram. Array CGH followed by RT-PCR of patient derived RNA (Supplementary Figure 2B and data not shown) identified a *de novo* heterozygous deletion of *MED13L* exons 3–4 (125 kb, chr12.hg19:g.

Table 1 Phenotype and genotype of patients with MED13L syndrome

	Index 1	Index 2	Index 3	Index 4	Index 5	Index 6	Index 7	Index 8
Sex	F	M	F	M	F	F	M	F
Origin	USA	Belgium	France	Portugal	Belgium	Germany	Scotland, Ireland, Ashkenazi Jewish, USA	Portugal
Genotype	Likely intragenic duplication (180kb) 116,497,982_116,681,549 Exons 2-4	Intragenic deletion (125 kb) 116,466,743_116,591,383 Exons 3-4	Likely intragenic duplication (64 kb) 116,405,600_116,469,708 Exons 5-28	Likely intragenic duplication (296 kb) 116,408,736_116,704,303 Exons 2-26	Intragenic deletion (276 kb) 116,420,188_116,695,775 Exons 2-22	Intragenic deletion (2 bp) 116,408,516_116,408,517 Exon 27	Duplication including MED13L (3 Mb) 115,067,028_118,264,352 All	Deletion including MED13L (1.9 Mb) 115,497,811_117,432,905 All
Inheritance	<i>De novo</i>	<i>De novo</i>	<i>De novo</i>	<i>De novo</i>	<i>De novo</i>	<i>De novo</i>	Maternally derived	<i>De novo</i>
Growth								
Short stature, post-natal onset		(+)10%			+			
Low IGF1					ND			
Retarded bone age					ND			
Pregnancy and birth								
Complications		+ (Gestational diabetes)		+ (Preclampsia, pre-term birth 35. GW, congenital pneumonia)				+ (Prenatal: increased nuchal translucency, single umbilical artery)
Head and neck								
Brachycephaly	+		+					+
Plagiocephaly			+					
Bitemporal narrowing	+	+			+			+
Hair upsweep								
Upslanted palpebral fissures	+		+ (Frontal)	+ (Frontal)				+
Hypertelorism	+		+			+		
Ptosis	+							
Bulbous nasal tip/short nose	+	+		+	+			+
Nasal bridge abnormal	+ (Flat/broad)	+		+ (Wide)	+ (Broad)			+ (Depressed)
Macrostomia	+	+	+	+	+		+	
Wide-spaced teeth	+							
High palate	+					+		
Frontal bossing	+		+	+				+
Low set ears	+	+		+			+	+
Short neck	+		+					
Other	Low hairline, prognathism, triangular face	Broad forehead, epicanthus	Periauricular tags	Down-turned mouth corners	Broad forehead, epicanthus	Flat midface	Triangular facies	Round face, downturned mouth corners

Table 1 (Continued)

	Index 1	Index 2	Index 3	Index 4	Index 5	Index 6	Index 7	Index 8
<i>Vision</i>								
Hypermetropia		+	+					
Myopia	+							
<i>Auditory</i>								
Hearing impairment							+ (High-tone hearing loss)	+ (Unilateral hearing loss)
<i>Heart</i>								
Congenital heart defect						+ (PFO)	+ (PFO)	+ (VSD)
<i>Abdomen and genitourinary</i>								
Hepatic abnormality					+ (Cysts)			
Hernia						+ (Umbilical)		
Cryptorchidism	+	+					(Small testes)	
<i>Skeletal</i>								
Scoliosis								
Hip dysplasia								
Clinodactyly		+						
Arthrogryposis		+						
Camptodactyly		+						
Syndactyly								
<i>Neurologic</i>								
Intellectual disability	+ (Mild-moderate)	+ (Moderate)	+ (Moderate)	+ (Moderate)	+ (Mild-moderate)	+ (Mild-moderate)	(Learning disability)	+ (Moderate)
Delayed speech and language development and/or poor speech	+	+	+	+	+	+		+
Motor delay	+	+	+	+	+	+	+	+
Muscular hypotonia	+	+		+	+			
Coordination deficit	+	+ (Ataxia)		+				
Behavioral problems		+ (Autism)		+ (Restlessness, agitation, hyperactivity, overfriendliness)	+ (Aggression)	+ (Autism)		
EEG abnormalities	NK	NK	NK	NK	No	Multifocal epileptiform discharges	Generalized slowing and occasional frontal sharp waves; no organized seizure activity	NK
cMRI abnormality		Myelination delay	Corpus callosum malformation, cavum vergae and arachnoid cyst		Periventricular small round signal alterations (myelination defect)		Normal MRI and MRS	
<i>Immunological</i>								
Recurrent infections in early childhood	+	+		+	+			

Abbreviations: dB, decibel; GW, gestational week; MRS, magnetic resonance spectroscopy; ND, not done; NK, not known; PFO, patent foramen ovale; VSD, ventricular septum defect.

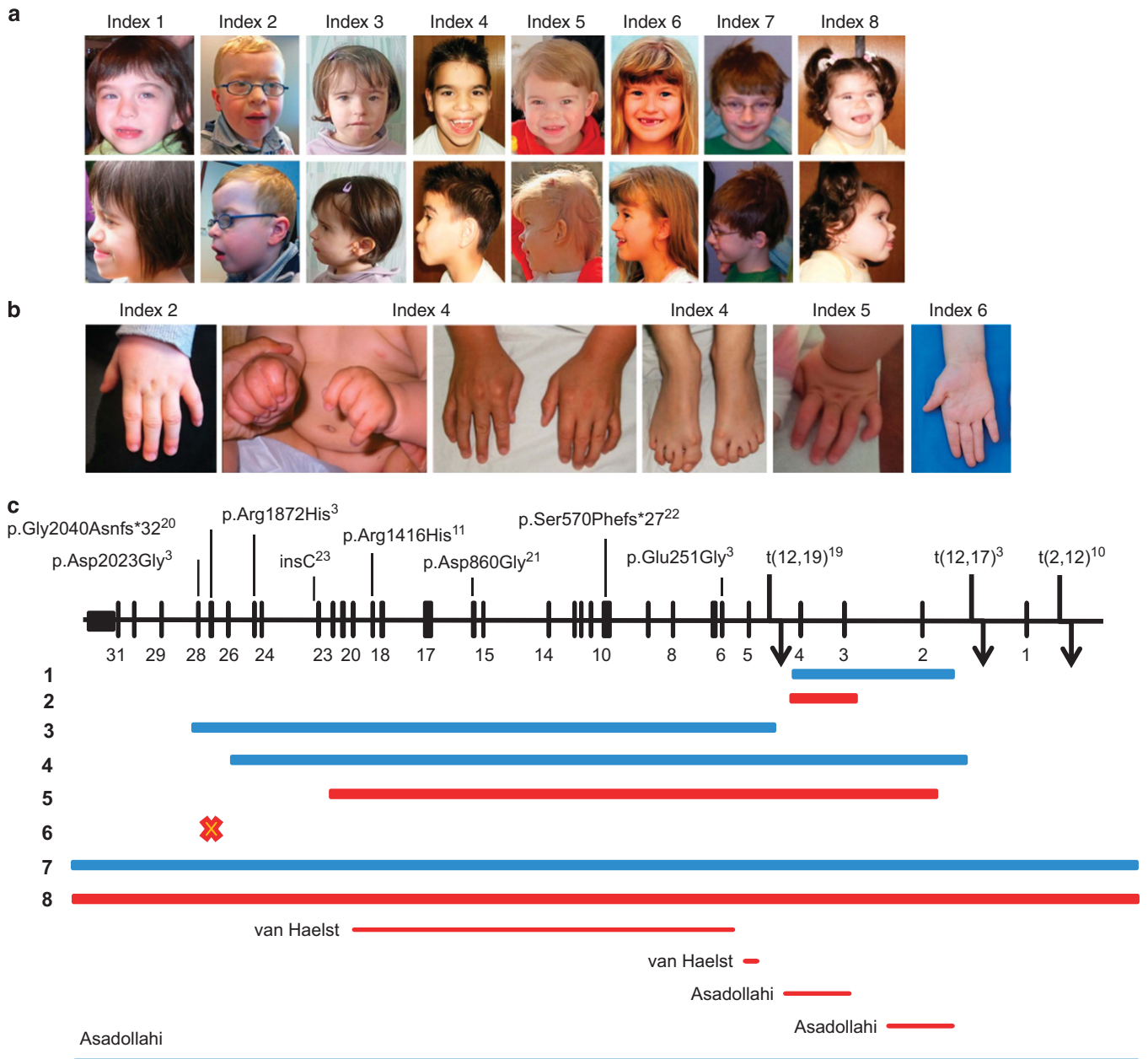


Figure 1 Phenotype and genotype of patients with *MED13L* gene mutations. (a) Pictures of index patients 1–9 illustrating the typical facial features including a broad forehead, bitemporal narrowing, low set ears, upslanted palpebral fissures, flat nasal root, broad nasal tip, macrostomia with an open-mouth appearance and frontal bossing. (b) Skeletal features include fifth finger clinodactyly (index patient 2), arthrogyposis and ulnar deviated club hands, as well as camptodactyly of the toes and cutaneous syndactyly of toes 2–3 (index patient 5), clinodactyly of the fifth rays of both hands (index patient 6) and short thumbs (index patient 7). (c) Diagrammatic presentation of the *MED13L* gene with exons 1–31 (intronic regions are not drawn to scale). The mutations identified in the index patients reported here are highlighted in bold print, and previously published mutations are indicated in normal print.

(116,440,087_116,466,743)_(116,591,383_116,616,387)del predicted to produce a frameshift leading to a truncated protein.

Index patient 3 was born at term as the first child of healthy, non-consanguineous Caucasian parents of French descent (DECIPHER no. 255109) with congenital torticollis and preauricular tags. Birth weight, length and OFC were 2590 g (5–10 centile, –1.4 SD), 47.5 cm (10–25 centile; –1.1 SD) and 33 cm (10 centile, –1.1 SD). Facial dysmorphism at 20 months included plagiocephaly, brachycephaly, frontal bossing, frontal hair upsweep, large anterior fontanel, facial asymmetry with macrostomia, upslanting small palpebral fissures and

strabismus. She had a short neck, was severely hyperopic and had astigmatism. Global psychomotor delay was present with a severe speech delay and moderate ID. She did not speak any word at 4 years but understood simple orders, sat at 10 months and walked at 3 years. Her anthropometric data at that time were: weight 14.6 kg (25–50 centile, –0.5 SD), length 96 cm (10–25 centile, –0.9 SD) and OFC 51 cm (75 centile, +1 SD). No autistic behavior could be detected. A short and thick corpus callosum, a cyst from cavum vergae and an arachnoid cyst were evident on cMRI. Cardiac and abdominal ultrasounds revealed normal results. Array CGH analysis revealed a

heterozygous likely intragenic duplication of *MED13L* exons 5–28 (60 kb, chr12:hg19:g.(116,403,831_116,405,600)_(116,469,708_116,470,897)dup), predicted to disrupt the gene. Quantitative PCR confirmed the duplication and showed that it was *de novo*.

Index patient 4 was born at 35 weeks of gestation, by cesarean section due to preeclampsia, as the only child of non-consanguineous parents of Portuguese descent (DECIPHER no. 272268). His mother, who received carbamazepine for epilepsy, had ceased her anticonvulsant therapy starting 3 months pre-conception. Birth weight (2330 g; 25 centile), length (47 cm; 25–50 centile) and OFC (33 cm; 75 centile) were normal. Facial dysmorphism included frontal hair upsweep, upslanting palpebral fissures, thick eyebrows with medial flare, wide and depressed nasal bridge, broad nasal tip, low set ears, frontal bossing, wide and often open mouth with downturned corners, and bulbous macrostomia with thick lip vermilion. Arthrogyriposis of the hands, ulnar deviated club hands, camptodactyly of the toes, cutaneous syndactyly of toes 2–3 and decreased palmar creases were noted. In the neonatal period, he developed hyaline membrane disease, and congenital pneumonia was diagnosed, requiring 3 weeks at the neonatal intensive care unit. Other transitory problems at this time were neonatal jaundice and one seizure. Results of cranial ultrasound were normal. Recurrent mostly respiratory infections (including another episode of pneumonia at the age of 4 years) improved significantly after the age of 6 years. At the age of 15 years, he still has wheezing episodes, requiring prophylactic medication with the H1-antihistamine and mast cell stabilizer ketotifen. Global developmental delay was noticed early on. He had severe speech delay or poor speech (only few words spoken at 15 years), moderate ID (IQ 43; Ruth Griffiths developmental scale) and motor delay with muscular hypotonia (unaided sitting and walking at 12 and 20 months, respectively). Clinical examination further revealed an uncoordinated gait, agitation, restlessness, overfriendliness and hyperactivity with a Vineland Adaptive Behavior Scale (VABS) score of 27 indicating severely deficient adaptive behavior and a Conner's questionnaire revealing a hyperkinesia score of 21. Growth parameters were normal at the age of 15 years (50 centile for weight/stature and 10 centile for OFC). His visual and auditory function is normal, and results of abdominal ultrasound and cMRI were normal. Neurological examination was otherwise normal. Array CGH revealed a *de novo* 0.3 Mb likely intragenic duplication of *MED13L* exons 2–26 (chr12:hg19:g.(116,420,188_116,397,305)_(116,695,775_116,712,831)dup), predicted to disrupt the gene.

Index patient 5 was born at term as the first child of non-consanguineous healthy parents of Belgian descent after an uneventful pregnancy induced by ICSI. Her birth weight (3250 g, 25–50 centile, –0.1 SD), length (50 cm, 25–50 centile, –0.2 SD) and OFC (35 cm, 50 centile, 0 SD) were normal. Motor development was delayed with unaided sitting and walking at 10 and 21 months, respectively. Speech delay was observed (first words spoken at 24 months and further impaired expression). Clinical examination at the age of 35 months revealed facial dysmorphism with a broad forehead, slight bitemporal narrowing, epicanthal folds, broad nasal bridge, rounded nasal tip, marked philtrum, full lips and slight uplift of the ear lobules. A proportionate and congruent short stature developed during the first year of life, but, thereafter, anthropometric values followed the respective centile curves. At the age of 3 years, her height was 88 cm (3–10 centile, –1.3 SD), weight 12.4 kg (below 3 centile, –2.6 SD) and OFC 48 cm, (25–50 centile, –0.3 SD). Her global development was delayed by 1 year (Bayley's II Scale of Infant Development score <55), and muscular hypotonia, intoeing, hypermetropia (+4 dtp), strabismus and bilateral clinodactyly of the fifth rays of her hands was present. She also showed aggressive behavior but had otherwise normal results on neurological examination. She suffered from

recurrent upper airway infections and one episode of pyelonephritis. Three small liver cysts were revealed by abdominal ultrasound, whereas echocardiography results were normal. cMRI revealed periventricular small round signal alterations of the white matter in line with a myelination disorder (data not shown). Array CGH identified a *de novo* deletion of *MED13L* exons 2–22 (276 kb, chr12:hg19:g.(116,392,761_116,420,188)_(116,695,775_116,712,831)del), predicted to result in a smaller protein of 509 amino acids.

Index patient 6 was born at term without complications as the second of two children of healthy, non-consanguineous parents of German descent (DECIPHER no. 295729). She had facial dysmorphism (hypertelorism, flat midface), a simian crease, short thumbs and an umbilical hernia. A global developmental delay was present with delayed motor milestones (unaided sitting and walking at 15 and 24 months, respectively), ID (IQ of Snijders-Oomen non-verbal intelligence test subcategories 58–85), speech delay or poor speech (50 words at the age of 6 years, communication with single words only) and autistic behavior. A discrete bilateral high-tone hearing loss was present, but her hearing threshold level was normal. Anthropometric data were normal at 6 years (height 109 cm, 5–10 centile, –3.2 SD; weight 18 kg, 10–25 centile, –0.9 SD; OFC 51 cm, 25–50 centile, –0.2 SD). Echocardiogram revealed no significant abnormality except for small patent foramen ovale (PFO). EEG disclosed irregular multifocal spike and wave complexes. Results of cMRI, abdominal ultrasound and ophthalmological exam were normal. Whole-exome sequencing revealed a *de novo* heterozygous 2-bp deletion in *MED13L* exon 27 (chr12:116,408,516_116,408,517delGA) leading to a frameshift and premature stop codon (p.(Gln1984A-lafs*31)) in the patient.

Index patient 7 is the 8-year-old son of non-consanguineous parents of Scottish, Irish and Ashkenazi Jewish American descent (DECIPHER no. 296365). Facial dysmorphism include triangular facies, short philtrum, prominent columella, low set ears with irregular antihelices and widely spaced teeth. The patient had delayed motor development, a speech delay, and a learning disability, but no ID. Further, tics, unilateral conductive hearing loss, pectus excavatum and small but fully descended testes were noted. Echocardiogram revealed a small PFO with left-to-right shunt. Anthropometric values were normal (height 127 cm, 10–25 centile; weight 25 kg, 25 centile; OFC 54 cm, 75 centile). Two other family members, the index's mother and a female sibling, had the same facial appearance (Supplementary Figure 3), but with delayed menarche only and no other significant medical issues. Array CGH revealed an approximately 3-Mb microduplication that includes *MED13L* as well as 11 other genes co-segregating with facial dysmorphism in the family (chr12:hg19:g.(114,948,852_115,057,027)_(118,248,051_118,272,276)dup).

Index patient 8 was born at term, by ventouse delivery, as the only child of non-consanguineous, healthy parents of Portuguese descent (DECIPHER no. 272267). During pregnancy increased nuchal translucency and a single umbilical artery were detected. Somatometric parameters were normal: weight 3269 g (50 centile, –0.04 SD), length 49.5 cm (25–50 centile, –0.4 SD), OFC 33 cm (10 centile, –1.1 SD). Motor development was delayed (unaided sitting and walking at 12 and 36 months, respectively), and ID was moderate with an IQ of 49. She had an expressive language delay with 5–6 words spoken at the age of 4 years. Clinical examination revealed facial dysmorphism characterized by a round face, brachycephaly, bitemporal narrowing, deeply set eyes, horizontal and laterally extended eyebrows, lower lid entropion, depressed nasal bridge, low set and posteriorly rotated ears, and an open mouth with downturned corners. Further anomalies present included inverted and hypoplastic nipples and an anteriorly

Table 2 Phenotype of patients with MED13L variants reported so far

Variant	Exon	Inheritance	Sex	Phenotype	Ref
46,XX,t(12,17)(q24.1;q21)	Intron 1	De novo	F	d-TGA, pVSD, PFO, mild coarction of the aorta, birth length 75 centile, weight/OFC 10 centile, postnatal microcephaly at 2 months, motor development delayed, ID, severe speech delay, ataxia, cMRI normal	3
g.(116,671,374_116,674,265)_(116,691,122_116,691,954) del	17-kb encompassing Exon 2	De novo	F	Supracardial total anomalous pulmonary venous connection, pulmonary atresia, VSD, oligohydramion, hypotrophic newborn, dysmorphism: macroglossia, micrognathia, anteriorly positioned anus, broad forehead, bitemporal narrowing, ling eyelashes, upslanting palpebral fissures, large/low set ears, flat nasal root, bulbous nose with short alae nasi, deep philtrum, moderate ID, coordination problems, motor developmental delay, muscular hypotonia and hypertonia of extremities, monotonous movements, shy, otherwise social, cMRI and abdominal ultrasound normal	4
g.(116,422,574_116,476,615)_(116,591,442_116,632,333) del	115-kb encompassing Exons 3–4 (out of frame)	De novo	F	Tetralogy of fallot (TOF), hypotrophic newborn (weight < 3 centile), gross global developmental delay, muscular hypotonia, prominent occipital protuberance, broad forehead, upslanting palpebral fissures, flat nasal root, bulbous nasal tip with small nares, deep and short philtrum, large/low set ears, micrognathia, overlapping of 5th toe over 4th toe, bowed legs	4
t(12;19)(q24;q12)(g:116,487,351_116,487,361)	Intron 4	De novo	F	Pierre-Robin sequence at birth, multiple limb contractures and camptodactyly, including metatarsus adductus of the thumb, and bilateral equinovarus foot deformity, electroencephalogram showed epileptiform discharges with absence seizures, moderate ID, developmental milestones significantly delayed, global speech delay in isolated, cMRI showed ventricule enlargement in correlation with global atrophy, dysmorphic features: flat occiput, hypertelorism, flat philtrum, bulbous nose, and broad nasal bridge, strabismus, hirsutism, scoliosis	20
NM_015335.4:c.480-1G>T	Exon 5	De novo	F	Facial dysmorphism, dizygotic twin, brother healthy, unilateral clubfoot, bilateral sandal gap, delayed motor development, speech delay, hypertonia of extremities, dysmorphism: short, upslanted fissures, bulbous nasal tip, tongue protrusion, bilateral accessory nipples, abnormal palmar creases with extra phalangeal crease of index fingers, cMRI normal	19
c.752A>G p.(Glu251Gly)	Exon 6	Maternally inherited	?	d-TGA, healthy mother	3
NC_000012.11:g.(?_116,419,988)_(116,460,600_?)del	Exons 6–20	De novo	M	Increased nuchal translucency, neonatal feeding problems, gastroesophageal reflux, recurrent ear infections, motor delay, ID, speech delay, muscular hypotonia, facial dysmorphism: small eyelids, mild retrognathia, short stature, no behavioral problems, PFO	19
g.116,446,509_116,446,510delCT c.1708_1709delAG p.(Ser570Phefs*27)	Exon 10	De novo	F	Global developmental delay, could walk at the age of 3 years, could make short, incomplete sentences at the age of 5 years, overweight, strabismus, moderate ID, brain CT scan performed at the age of 2 years showed mildly increased extra-axial CSF spaces.	23
g.116435026T>C c.2579A>G p.(Asp860Gly)	Exon 16	De novo	M	Feeding problems, epilepsy, IQ 50, Small dysplastic low set ears, a bulbous nasal tip a large mouth and a simean crease of his right hand	22
g.116424162C>T c.4247G>A p.(Arg1416His)	Exon 19	Autosomal recessive	?	Mild ID	11
g.116,418,553_116,418,554insC or g.116,418,554_116,418,555insC	Intron 23	De novo	M	Autism spectrum disorder	24
c.5615G>A, p.(Arg1872His)	Exon 25	?	?	d-TGA	3
g.116,406,845_116,406,852del c.6118-6125del p.(Gly2040Asnfs*32)	Exons 27–28	De novo	M	ID, open mouth, muscular hypotonia	21
c.6068A>G p.(Asp2023Gly)	Exon 28	?	?	d-TGA	3
g.(116,022,988_116,024,060)_(117,043,341_117,044,193)rr1	1 Mb	De novo	F	pVSD (closed spontaneously), fetal hydrops (GW16-25), hypotrophic preterm, postnatal anthropometric data normal at 6.5 years, dysmorphism: broad nasal bridge, mild pectus excavatum, learning difficulties, muscular hypotonia, motor developmental delay, unsteady gait, normal speech development, good social skills	4

All genomic positions given in this table refer to hg19.

placed anus. Results of neurological examination were otherwise normal. A small perimembranous ventricular septum defect without hemodynamic repercussion, revealed by echocardiography at the age of 2 months, had closed spontaneously at 3 years. Anthropometric values were normal (50 centile for height, weight and OFC). cMRI results were normal. Array CGH revealed a *de novo* 1.9-Mb deletion that includes *MED13L* as well as seven other genes (chr12.hg19:g.(115,513,181_115,497,819)_(117,432,905_117,450,462)del).

DISCUSSION

In this study, we report seven patients with protein truncating variants caused by *MED13L* exon deletions or duplications (indexes 1–6 and 8) and a family with a large duplication including *MED13L* (index 7, discussed below) (Table 1, Figure 1). All individuals with *MED13L* truncating variants have ID and display common characteristic facial features characterized by a broad prominent forehead, bitemporal narrowing, low set ears, upslanted palpebral fissures, flat nasal root, broad nasal tip and macrostomia with an open-mouth appearance. Further common clinical features are delayed speech and language development typically with near-totally absent speech, motor developmental delay with muscular hypotonia as well as coordination problems (often with ataxia), and behavioral difficulties. Individual patients developed postnatal short stature. None of the patients had a complex congenital heart defect.

These results argue strongly against the previous notion that *MED13L* haploinsufficiency is a single-gene cause for complex congenital heart defects only (for an overview of previously reported *MED13L* patients see Table 2). Indeed, the extent to which the cardiac phenotype is a feature of the *MED13L* syndrome is unclear. In the initial study on 97 patients with complex congenital heart disease (d-TGA), *MED13L* missense variants and a gene interruption were identified in four patients. However, one of the missense changes was

also present in the healthy mother, for the remaining two additional evidence for pathogenicity was not provided, and the patient with *MED13L* interruption did not have ‘isolated’ d-TGA as suggested in the abstract of the paper, but rather a syndromic form reminiscent of that in our patients.³ Moreover, in a study of 102 patients with d-TGA, no variant in the *MED13L* gene could be identified arguing at least against a high incidence of *MED13L*-associated heart disease.¹⁸ Recent reports of individuals with *MED13L* variants who lacked a cardiac phenotype provided some evidence to argue against the *MED13L*-heart phenotype hypothesis.^{19–23} Similarly, a study on 343 patients with autism spectrum disorder, reported one potential splice-site change in an affected individual.²⁴ Unfortunately, clinical information on this patient is not available. In view of our study, these results merge nicely into the extended spectrum of the *MED13L* syndrome that we propose with both the cardiac phenotype and autism being possible but not required features for diagnosis.

The *MED13L* phenotype appears to underlie a gradient. Although some patients suffer from a severe phenotype with dysmorphism, global developmental delay and complex congenital heart disease, other patients with *MED13L* variants do not display a recognizable cardiac phenotype. This also applies to individuals with apparently identical exon deletions. For example, *de novo* deletions of *MED13L* exons 3 and 4 are associated with the typical facial features of *MED13L* syndrome in two individuals that are, however, discordant with respect to the cardiac phenotype (index patient 2 in this study and patient 2 reported in Asadollahi *et al*⁴). Here, the genetic background or stochastic factors may have a role in the penetrance of the cardiac phenotype. Going further, the cardiac phenotype may be the least susceptible to *MED13L* perturbation and the least useful marker of the condition because both individuals are otherwise phenotypically identical. Although two patients with non-syndromic ID carried a homozygous *MED13L* missense variant, no record of a phenotype in the respective parents, who are

Table 3 Key phenotype features of mediator complex-associated diseases

Domains	<i>MED12</i> (Opitz–Kaveggia)	<i>MED12</i> (Lujan–Fryns)	<i>MED13L</i>
Cognitive	Intellectual disability, usually severe	Intellectual disability	Intellectual disability
Head	Macrocephaly (relative)	Macrocephaly (enlarged skull) with a prominent forehead	Brachycephaly, frontal bossing
	Upswept frontal hairline		Frontal hair upsweep or low anterior hairline
Ears	Small, underdeveloped ears	Low set ears with some apparent retroversion	Low set ears
Eyes	Down-slanting palpebral fissures Widely set eyes (hypertelorism),		Upslanting palpebral fissures Mild hypertelorism
Muscle	Severe hypotonia; A characteristic facial appearance due to hypotonia, giving a droopy, ‘open-mouthed’ expression A thin upper lip, a full or pouting lower lip	Hypotonia	Hypotonia Facial hypotonia with droopy open-mouthed expression
Brain	Partial or complete loss of the corpus callosum	Partial or complete loss of the corpus callosum	
Cardiac	Heart defects	Dilation of the aortic root, ventricular and atrial septal defect	Some cases with d-TGA, other complex cardiac defects
Genitalia	Cryptorchidism (males)	Slightly enlarged to normal testicular size in males	Cryptorchidism or micropenis
Chest		Pectus excavatum	
Miscellaneous features unique to each syndrome	Hyperactive behavior; severe constipation, with or without structural anomalies in the anus such as imperforate anus, broad thumbs and wide first (big) toes	Maxillary hypoplasia, seizures, Marfanoid habitus	Autistic and/or hyperactive behavior (not always present)

heterozygous carriers for the same variant, is noted.¹¹ Increased *MED13L* dosage appears not to confer the same degree of disease risk as haploinsufficiency. The phenotype was surprisingly mild in index patient 7, his mother and sister with duplication of chromosome 12q24.2.q24.23 and in a previously reported patient with a triplication of chromosome 12, both involving the *MED13L* gene and several other genes.⁴ Although in these cases, the individual effect of increased *MED13L* dosage cannot be determined because of the involvement of several genes, it further underlines a possible gene dosage effect.

MED13L is only one component of the mediator complex linked to human disease: (i) *MED12* gene variants cause Lujan-Fryns syndrome (MIM #309520),²⁵ Ohdo syndrome (MIM #300895),²⁶ Opitz-Kaveggia syndrome (MIM #305450),²⁷ and profound ID that in contrast to the aforementioned syndromes resulted in affected female carriers and truncation of the *MED12* protein,²⁸ (ii) a recurrent homozygous *MED17* missense variant has been linked to postnatal progressive microcephaly with seizures and brain atrophy (MIM #613668),²⁹ (iii) a homozygous *MED23* variant causes autosomal recessive non-syndromic ID (MIM #614249),³⁰ (iv) a homozygous *MED25* variant causes autosomal recessive adult onset axonal Charcot-Marie-Tooth neuropathy (CMT2B2, MIM #605589)³¹ and (v) a truncation of *CDK19* caused by a chromosome inversion is associated with bilateral congenital retinal folds, microcephaly, and mild ID (MIM #614720).³²

We observe that the *MED13L* phenotype displays similarities to Opitz-Kaveggia syndrome, along with key differences (see Table 3). Indeed, *MED12* and *MED13/MED13L* are closely associated with the CDK8 module, which has a distinct role in regulating mediator function and transcription.^{5,33} Mammalian mediator exists primarily in two forms distinguished by the presence or absence of the CDK8 module, the latter containing the four subunits CDK8, CCNC, *MED12* and *MED13*. *MED13* physically links the CDK8 module to the mediator core, and it is suspected that the less-characterized *MED13L* has similar functions.⁹ Although mediator proteins in general are associated with diverse functions and, when dysfunctional, with various disease phenotypes, we hypothesize that components that show some degree of functional overlap may be more likely to share phenotypic features with each other.

In conclusion, deleterious *MED13L* variants cause a recognizable dysmorphic syndrome, but contradictory to what is presented in the majority of the literature cardiac disease is not an invariable feature of the phenotype. We suggest that there is a *MED13L* phenotypic gradient given the observations of a variable phenotype from severe dysmorphism with global developmental delay to non-syndromic ID. There is phenotype overlap between *MED13L* syndrome and *MED12* syndromes, and it is likely that variants in further complex components will be identified with similar phenotypes. Beyond the emerging recognition of a *MED13L* syndrome, our findings also underline common molecular factors associated with neurodevelopmental diseases and congenital heart defects.

CONFLICT OF INTEREST

The authors declare no conflict of interest.

ACKNOWLEDGEMENTS

We thank all families for participation in this study, Bettina Lipkowitz and Susanne Freier for excellent technical assistance. This work was supported by the Deutsches Humangenom-Programm (DHGP, grant number 01KW9908), the Nationales Genomforschungsnetzwerk (NGFN, project number 01GR0105), the German Research Foundation (SFB665), the Brain and Behavior Foundation (AA), the Berlin Institute of Health (BIH), the Sonnenfeld Stiftung, the Senate of

Berlin by funds to the Berlin Institute for Medical Systems Biology (BIMSB), the Iranian National Science foundation, FEDER funds through the COMPETE program, Portuguese national funds through FCT - Fundação para a Ciência e Tecnologia (project PIC/IC/83026/2007, scholarship to FL SFRH/BD/84650/2010), the Max Planck Society and the EU FP 7 project GENCODYS (grant number 241995).

- Parker SE, Mai CT, Canfield MA *et al*: Updated National Birth Prevalence estimates for selected birth defects in the United States, 2004–2006. *Birth Defects Res A Clin Mol Teratol* 2010; **88**: 1008–1016.
- Andersen TA, Troelsen Kde L, Larsen LA: Of mice and men: molecular genetics of congenital heart disease. *Cell Mol Life Sci* 2014; **71**: 1327–1352.
- Muncke N, Jung C, Rudiger H *et al*: Missense mutations and gene interruption in PROSIT240, a novel TRAP240-like gene, in patients with congenital heart defect (transposition of the great arteries). *Circulation* 2003; **108**: 2843–2850.
- Asadollahi R, Oneda B, Sheth F *et al*: Dosage changes of *MED13L* further delineate its role in congenital heart defects and intellectual disability. *Eur J Hum Genet* 2013; **21**: 1100–1104.
- Davis MA, Larimore EA, Fissel BM, Swanger J, Taatjes DJ, Clurman BE: The SCF-Fbw7 ubiquitin ligase degrades *MED13* and *MED13L* and regulates CDK8 module association with mediator. *Genes Dev* 2013; **27**: 151–156.
- Schiano C, Casamassimi A, Vietri MT, Rienzo M, Napoli C: The roles of mediator complex in cardiovascular diseases. *Biochim Biophys Acta* 2014; **1839**: 444–451.
- Borggreve T, Yue X: Interactions between subunits of the mediator complex with gene-specific transcription factors. *Semin Cell Dev Biol* 2011; **22**: 759–768.
- Hentges KE: Mediator complex proteins are required for diverse developmental processes. *Semin Cell Dev Biol* 2011; **22**: 769–775.
- Knuessel MT, Meyer KD, Bernecky C, Taatjes DJ: The human CDK8 subcomplex is a molecular switch that controls mediator coactivator function. *Genes Dev* 2009; **23**: 439–451.
- Musante L, Bartsch O, Ropers HH, Kalscheuer VM: cDNA cloning and characterization of the human *THRAP2* gene which maps to chromosome 12q24, and its mouse ortholog *Thrap2*. *Gene* 2004; **332**: 119–127.
- Najmabadi H, Hu H, Garshabi M *et al*: Deep sequencing reveals 50 novel genes for recessive cognitive disorders. *Nature* 2011; **478**: 57–63.
- Firth HV, Richards SM, Bevan AP *et al*: DECIPHER: database of Chromosomal Imbalance and Phenotype in Humans using Ensembl Resources. *Am J Hum Genet* 2009; **84**: 524–533.
- Buysse K, Delle Chiaie B, Van Coster R *et al*: Challenges for CNV interpretation in clinical molecular karyotyping: lessons learned from a 1001 sample experience. *Eur J Med Genet* 2009; **52**: 398–403.
- Menten B, Pattyn F, De Preter K *et al*: ArrayCGHbase: an analysis platform for comparative genomic hybridization microarrays. *BMC Bioinform* 2005; **6**: 124.
- Buffart TE, Israeli D, Tijssen M *et al*: Across array comparative genomic hybridization: a strategy to reduce reference channel hybridizations. *Genes Chromosomes Cancer* 2008; **47**: 994–1004.
- Hu H, Wienker TF, Musante L *et al*: Integrated sequence analysis pipeline provides one-stop solution for identifying disease-causing mutations. *Hum Mutat* 2014; **35**: 1427–1435.
- Hoebbeck J, van der Luijt R, Poppe B *et al*: Rapid detection of *VHL* exon deletions using real-time quantitative PCR. *Lab Invest* 2005; **85**: 24–33.
- Lei L, Lin H, Zhong S *et al*: Analysis of mutations in 7 candidate genes for dextro-transposition of the great arteries in Chinese population. *J Thorac Dis* 2014; **6**: 491–496.
- van Haelst MM, Monroe GR, Duran K *et al*: Further confirmation of the *MED13L* haploinsufficiency syndrome. *Eur J Hum Genet* 2014; **23**: 135–138.
- Utami KH, Winata CL, Hillmer AM *et al*: Impaired development of neural-crest cell-derived organs and intellectual disability caused by *MED13L* haploinsufficiency. *Hum Mutat* 2014; **35**: 1311–1320.
- Redin C, Gerard B, Lauer J *et al*: Efficient strategy for the molecular diagnosis of intellectual disability using targeted high-throughput sequencing. *J Med Genet* 2014; **51**: 724–736.
- Gilissen C, Hehir-Kwa JY, Thung DT *et al*: Genome sequencing identifies major causes of severe intellectual disability. *Nature* 2014; **511**: 344–347.
- Hamdan FF, Srour M, Capo-Chichi JM *et al*: *De novo* mutations in moderate or severe intellectual disability. *PLoS Genet* 2014; **10**: e1004772.
- Iossifov I, Ronemus M, Levy D *et al*: *De novo* gene disruptions in children on the autistic spectrum. *Neuron* 2012; **74**: 285–299.
- Schwartz CE, Tarpey PS, Lubs HA *et al*: The original Lujan syndrome family has a novel missense mutation (p.N1007S) in the *MED12* gene. *J Med Genet* 2007; **44**: 472–477.
- Vulto-van Silfhout AT, de Vries BB, van Bon BW *et al*: Mutations in *MED12* cause X-linked Ohdo syndrome. *Am J Hum Genet* 2013; **92**: 401–406.
- Risheg H, Graham Jr JM, Clark RD *et al*: A recurrent mutation in *MED12* leading to R961W causes Opitz-Kaveggia syndrome. *Nat Genet* 2007; **39**: 451–453.
- Lesca G, Moizard MP, Bussy G *et al*: Clinical and neurocognitive characterization of a family with a novel *MED12* gene frameshift mutation. *Am J Med Genet Pt A* 2013; **161A**: 3063–3071.

- 29 Kaufmann R, Straussberg R, Mandel H *et al*: Infantile cerebral and cerebellar atrophy is associated with a mutation in the MED17 subunit of the transcription preinitiation mediator complex. *Am J Hum Genet* 2010; **87**: 667–670.
- 30 Hashimoto S, Boissel S, Zarhrate M *et al*: MED23 mutation links intellectual disability to dysregulation of immediate early gene expression. *Science* 2011; **333**: 1161–1163.
- 31 Leal A, Huehne K, Bauer F *et al*: Identification of the variant Ala335Val of MED25 as responsible for CMT2B2: molecular data, functional studies of the SH3 recognition motif and correlation between wild-type MED25 and PMP22 RNA levels in CMT1A animal models. *Neurogenetics* 2009; **10**: 275–287.
- 32 Mukhopadhyay A, Kramer JM, Merx G *et al*: CDK19 is disrupted in a female patient with bilateral congenital retinal folds, microcephaly and mild mental retardation. *Hum Genet* 2010; **128**: 281–291.
- 33 Taatjes DJ: The human mediator complex: a versatile, genome-wide regulator of transcription. *Trends Biochem Sci* 2010; **35**: 315–322.

Supplementary Information accompanies this paper on European Journal of Human Genetics website (<http://www.nature.com/ejhg>)