

ARTICLE

# Mutation screening of the Ectodysplasin-A receptor gene *EDAR* in hypohidrotic ectodermal dysplasia

Annemarie H van der Hout<sup>\*1</sup>, Gréte G Oudesluijs<sup>1,3</sup>, Andrea Venema<sup>1</sup>, Joke BGM Verheij<sup>1</sup>, Bart GJ Mol<sup>1</sup>, Patrick Rump<sup>1</sup>, Han G Brunner<sup>2</sup>, Yvonne J Vos<sup>1</sup> and Anthonie J van Essen<sup>1</sup>

<sup>1</sup>Department of Genetics, University Medical Centre Groningen, University of Groningen, Groningen, The Netherlands;  
<sup>2</sup>Department of Human Genetics, University Medical Centre St Radboud, Nijmegen, The Netherlands

Hypohidrotic ectodermal dysplasia (HED) can be caused by mutations in the X-linked ectodysplasin A (*ED1*) gene or the autosomal ectodysplasin A-receptor (*EDAR*) and *EDAR*-associated death domain (*EDARADD*) genes. X-linked and autosomal forms are sometimes clinically indistinguishable. For genetic counseling in families, it is therefore important to know the gene involved. In 24 of 42 unrelated patients with features of HED, we found a mutation in *ED1*. *ED1*-negative patients were screened for mutations in *EDAR* and *EDARADD*. We found mutations in *EDAR* in 5 of these 18 patients. One mutation, p.Glu354X, is novel. In *EDARADD*, a novel variant p.Ser93Phe, probably a neutral polymorphism, was also found. Clinically, there was a difference between autosomal dominant and autosomal recessive HED patients. The phenotype in patients with mutations in both *EDAR* alleles was comparable to males with X-linked HED. Patients with autosomal dominant HED had features comparable to those of female carriers of X-linked HED. The teeth of these patients were quite severely affected. Hypohidrosis and sparse hair were also evident, but less severe. This study confirms Chassaing *et al's* earlier finding that mutations in *EDAR* account for approximately 25% of non-*ED1*-related HED. Mutations leading to a premature stop codon have a recessive effect except when the stop codon is in the last exon. Heterozygous missense mutations in the functional domains of the gene may have a dominant-negative effect with much variation in expression. Patients with homozygous or compound heterozygous mutations in the *EDAR* gene have a more severe phenotype than those with a heterozygous missense, nonsense or frame-shift mutation.

*European Journal of Human Genetics* (2008) 16, 673–679; doi:10.1038/sj.ejhg.5202012; published online 30 January 2008

**Keywords:** hypohidrotic ectodermal dysplasia; mutation screening; *ED1* gene; *EDAR* gene; *EDARADD* gene; genotype–phenotype correlation

## Introduction

Hypohidrotic ectodermal dysplasia (HED; MIM no. 305100) is characterized by absent or a diminished number

of eccrine sweat glands, missing and malformed teeth, and thin and sparse hair. The severity of symptoms can vary between and within families. The incidence is estimated to be 1 per 100 000 births.<sup>1</sup> Most cases are X-linked and are caused by mutations in the ectodysplasin A gene (*ED1*; MIM \*300451). However, some families show autosomal dominant or autosomal recessive inheritance. Mutations in the ectodysplasin A-receptor gene (*EDAR*; MIM \*604095) on 2q11–13 were found in HED families with transmission compatible with autosomal dominant and autosomal recessive inheritance,<sup>2–7</sup> and in one consanguineous

\*Correspondence: Dr AH van der Hout, Department of Genetics, University Medical Centre Groningen, PO Box 30 001, 9700 RB Groningen, The Netherlands.

Tel: +31 50 3617233; Fax: +31 50 3617231;

E-mail: a.h.van.der.hout@medgen.umcg.nl

<sup>3</sup>Current address: Department of Clinical Genetics, Erasmus Medical Centre, Rotterdam, The Netherlands.

Received 2 October 2007; revised 27 November 2007; accepted 20 December 2007; published online 30 January 2008

family with recessive HED, a homozygous mutation in the EDAR-associated death domain gene (*EDARADD*; MIM \*606603) on 1q42.2–43 was described.<sup>8</sup> In this study, we present the results of mutation scanning of the *ED1* gene in 42 HED patients, and scanning of the *EDAR* and *EDARADD* genes in *ED1*-negative patients. We describe the clinical features of affected individuals in five families with mutations in *EDAR*. In addition, we provide possible explanations for the observation (made by ourselves and others) that some mutations act in a dominant manner and others in a recessive.

## Materials and methods

### Patients

The *ED1* gene was screened in 42 unrelated index cases from The Netherlands, Belgium, Italy, Portugal, Sweden and Finland, with features suggestive for a diagnosis of HED. If no mutation was detected in *ED1*, the *EDAR* and *EDARADD* genes were screened. In five families (all Dutch) in which a mutation in the *EDAR* gene was found, patients were clinically re-evaluated. They were screened for missing or malformed teeth, and thin or sparse hair. Hydrosis was measured with an iodine sweat test in two patients. The remaining patients were questioned about their decreased sweating and heat intolerance. A written consent for use of photographs was obtained from all individuals concerned.

### Mutation detection

DNA was isolated from peripheral blood leukocytes using standard laboratory methods. The *ED1* gene was screened by Denaturing Gradient Gel Electrophoresis (exons 3, 4, 6, 7, 8 and 9) and direct sequencing (exons 1 and 5). Primer

sequences are available upon request. All exons and flanking intronic sequences of the *EDAR* and *EDARADD* genes were amplified by PCR using previously published primers.<sup>2,8</sup> Products were directly sequenced using an ABI 3100 Genetic Analyzer (Applied Biosystems, Foster City, CA, USA).

## Results

In 24 of 42 unrelated patients with a clinical diagnosis or strong suspicion of having HED, a mutation in the *ED1* gene was detected. Mutations are summarized in Table 1. In the remaining 18 patients (9 male, 9 female), the *EDAR* and *EDARADD* genes were screened. A pathogenic mutation in *EDAR* was detected in five families. Table 2 summarizes our data and mutations published earlier.

A novel variant in the *EDARADD* gene was found in a sporadic female patient with conical teeth and sparse downy hair: c.278C>T/p.Ser93Phe (A of the first ATG codon = 1, based on reference sequence NM\_080738). Mutations in the *ED1* and *EDAR* genes were excluded. This variant was also found in the mother, who shows no signs of HED.

### Patients with mutations in *EDAR*

All the parents of affected children were unrelated and their family history was non-contributory unless otherwise stated. Intelligence and development, besides their symptoms of HED, were normal in all patients.

**Family 1, patients 1 and 2** In this family, there are two affected brothers (1 and 2). At the ages of 2 years and 6 months, respectively, they were clinically examined, and

**Table 1** Mutations identified in the *ED1* gene in this study<sup>a</sup>

Nucleotide change <sup>b</sup>	Protein change <sup>b</sup>	Location	Mutation type	No. of families
c.1-?_396+?del		Exon 1	Exon deletion	1
c.2T>A	p.Met1Lys	Exon 1	Loss initiation site	1
c.77delG	p.Gly26fs	Exon 1	Frameshift	1
c.463C>T	p.Arg155Cys	Exon 3	Missense	3
c.466C>T	p.Arg156Cys	Exon 3	Missense	1
c.467G>A	p.Arg156His	Exon 3	Missense	3
c.546_581del36	p.Gly183_Pro194del	Exon 5	In-frame deletion	1
c.553_588del36	p.Asn185_Pro196del	Exon 5	In-frame deletion	1
c.559_576del18	p.Pro184_Gly189del	Exon 5	In-frame deletion	1
c.741+1G>T		Intron 6	Splice	1
c.793+2T>C		Intron 7	Splice	1
c.795_796insTTAT	p.Gly268fs	Exon 8	Frameshift	1
c.871G>A	p.Gly291 Arg	Exon 8	Missense	1
c.892G>T	p.Asp298Tyr	Exon 8	Missense	1
c.920T>G	p.Val307Gly	Exon 9	Missense	1
c.924+8C>A		Intron 8	Splice	1
c.925-3C>G		Intron 8	Splice	1
c.1114A>G	p.Asn372Asp	Exon 9	Missense	1
c.1119G>A	p.Met373Ile	Exon 9	Missense	1
c.1061_1110del50	p.Leu354fs	Exon 9	Frameshift	1

<sup>a</sup>Novel mutations in bold.

<sup>b</sup>Mutation nomenclature is according to reference sequence NT\_011669.16 with numbering starting at the A of the first ATG.

**Table 2** Summary of known mutations in the *EDAR* gene

Nucleotide change <sup>a</sup>	Protein change <sup>a</sup>	Location	Mutation type	Inheritance	Family no. this study	Reference
c.52-25_52-8del		Intron 2	Splice	AR		Monreal <i>et al</i> <sup>2</sup>
c.51+1G>A		Intron 2	Splice	AR		Shimomura <i>et al</i> <sup>5</sup>
c.140G>A	p.Cys47Tyr	Exon 3	Missense	AR		Chassaing <i>et al</i> <sup>3</sup>
c.259T>C	p.Cys87Arg	Exon 4	Missense	AR		Monreal <i>et al</i> <sup>2</sup>
c.266G>A	p.Arg89His	Exon 4	Missense	AR		Monreal <i>et al</i> <sup>2</sup> Chassaing <i>et al</i> <sup>3</sup>
> exon 4 del			Large deletion	AD	1	This study
c.329A>C	p.Asp110Ala	Exon 4	Missense	AR	1	Chassaing <i>et al</i> <sup>3</sup> and this study
c.399_404del6	p.Met133_Cys135delinslle	Exon 5	In-frame deletion	AR		Tariq <i>et al</i> <sup>7</sup>
c.442T>C	p.Cys148Arg	Exon 5	Missense	AR		Chassaing <i>et al</i> <sup>3</sup>
c.528+1G>A		Intron 6	Splice	AR		Chassaing <i>et al</i> <sup>3</sup>
c.718_721del	p.Lys740fs	Exon 8	Frameshift	AR		Naeem <i>et al</i> <sup>4</sup>
c.1060G>T	p.Glu354X	Exon 12	Nonsense	AD	2	This study
c.1072C>T	p.Arg358X	Exon 12	Nonsense	AD	3, 4	Monreal <i>et al</i> , <sup>2</sup> Lind <i>et al</i> , <sup>6</sup> and this study
c.1124G>A	p.Arg375His	Exon 12	Missense	AR		Shimomura <i>et al</i> <sup>5</sup>
c.1129C>T	p.Leu377Phe	Exon 12	Missense	AD		Chassaing <i>et al</i> <sup>3</sup>
c.1144G>A	p.Gly382Ser	Exon 12	Missense	AR		Naeem <i>et al</i> <sup>4</sup>
c.1208C>T	p.Thr403Met	Exon 12	Missense	AR		Chassaing <i>et al</i> <sup>3</sup>
c.1237A>C	p.Thr413Pro	Exon 12	Missense	AD		Chassaing <i>et al</i> <sup>3</sup>
c.1253T>C	p.Ile418Thr	Exon 12	Missense	AD?		Chassaing <i>et al</i> <sup>3</sup>
c.1259G>A	p.Arg420Gln	Exon 12	Missense	AD	5	Monreal <i>et al</i> , <sup>2</sup> Chassaing <i>et al</i> <sup>3</sup> and this study
c.1302G>T	p.Trp434Cys	Exon 12	Missense	AR		Chassaing <i>et al</i> <sup>3</sup>

AD, autosomal dominant; AR, autosomal recessive.

<sup>a</sup>Mutation nomenclature is according to reference sequence NT\_022171 with numbering starting at the A of the first ATG.

again 18 months later. They both had conical teeth and hypodontia, thin and sparse hair, and decreased sweating, comparable to boys with X-linked recessive HED. An X-ray revealed that the oldest boy has only two permanent teeth. He has recurrent atrophic rhinitis, and has had multiple respiratory infections. The father has no features of HED, while the mother has only some mild features. She had hypohidrosis and only a few permanent teeth, with milk teeth that had remained. Two *EDAR* mutations, p.Arg89His and p.Asp110Ala, were found in both the affected boys. The unaffected father was a carrier of the p.Asp110Ala mutation and the mother of the p.Arg89His mutation.

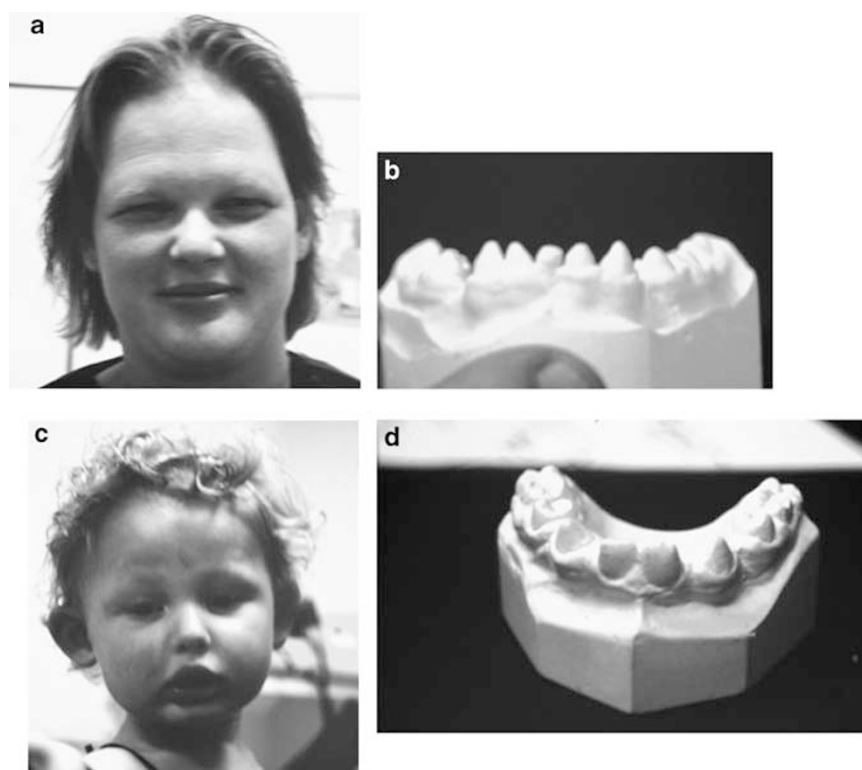
**Family 2, patients 3 and 4** Patient 3, a boy aged 18 months is the only child of these parents. The patient's history mentioned that his sweating was decreased. When the weather is warm, he has syncopal episodes and tries to crawl into the refrigerator. He had thin, brittle, curly, scalp hair, sparse eyebrows and eyelashes, retrognathia, and prominent ears. There were two small conical teeth in the maxilla (Figures 1c and d). The nails had longitudinal grooves and the skin was dry and eczematous. He was 82 cm tall (<0 SD), weighed 9.4 kg (<2 SD) and his OFC was 45.3 cm (2 SD).

His father has no features of HED but his mother's case history (patient 4) mentioned delayed eruption of milk teeth, although, unfortunately, no exact data could be given. The mandibular and maxillary cuspids and first

bicuspid of her permanent teeth had not erupted (Figures 1a and b). Sweating was also decreased. Clinical examination of the mother showed sparse and thin, brittle scalp hair, sparse eyebrows and eyelashes. All her maxillary teeth were partial dentures, and her mandibular cuspids and first bicuspid were absent. Her mammary glands were underdeveloped and areolae were hypoplastic. The skin was dry and eczematous. Axillary and pubic hair was sparse. The mother's family history was inconclusive for features of HED. One allele in the mother had a p.Glu354X mutation; her son (3) was not tested.

**Family 3, patients 5 and 6** In this family, the female index patient 5 had one brother and two sisters; her eldest sister had died shortly before birth (probably due to an intrauterine infection). The girl's case history mentioned slightly decreased sweating and a mild sensorineural hearing loss of 10–20 and 20–40 dB in the right and left ears, respectively. Clinical evaluation of the girl at 13 years of age showed thin and sparse scalp hair, sparse eyebrows and eyelashes, hypoplastic alae nasi, thin upper lip, maxillary hypoplasia, and a high frontal hairline (Figures 2c and d). Several teeth were missing and only two maxillary and mandibular incisors were present. There were no nail or skin abnormalities. She was 147.5 cm tall (–2 SD), weighed 31.2 kg (–2 SD), and her OFC was 52 cm (–1 SD).

Her father had no features of HED but her mother's history (patient 6) mentioned decreased sweating and that



**Figure 1** Patient 4 (a and b) and patient 3 (c and d) of family 2. Note the sparse scalp hair and oligodontia and conical teeth.

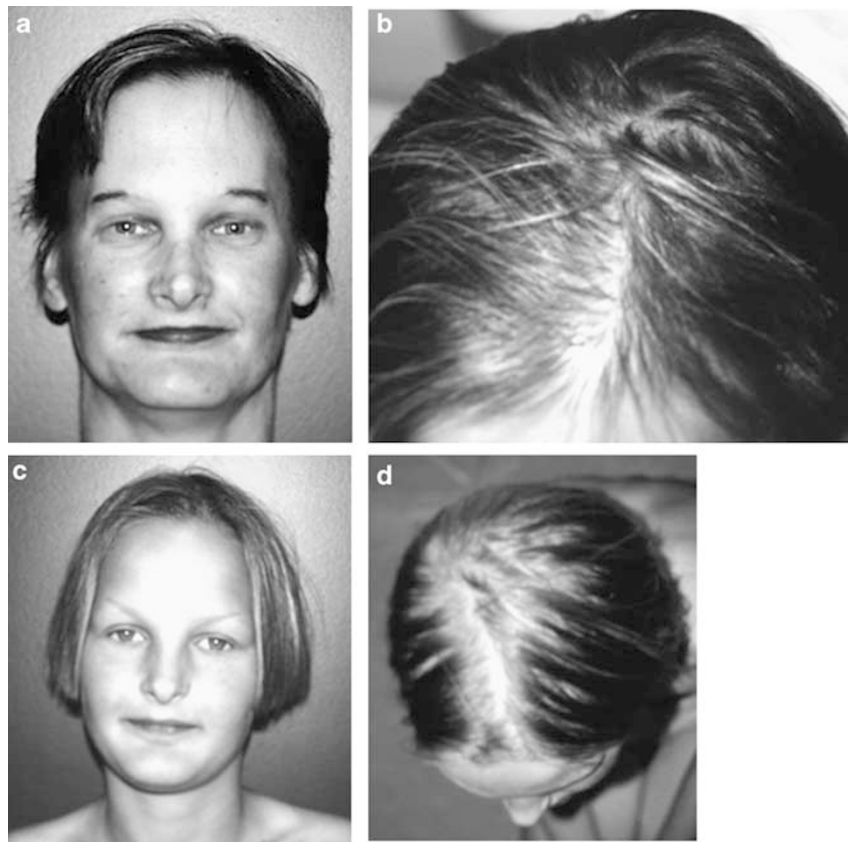
all permanent teeth had failed to erupt. Clinical investigation showed sparse scalp hair, eyebrows and eyelashes, hypoplastic alae nasi, thin upper lip, and a high frontal hairline (Figures 2a and b). Maxillary and mandibular dentures had been placed. Pubic hair was normal but axillary hair was patchy. Her nails and skin were normal. There is no information about her parents. However, her sister and her nephew from this sister have similar clinical features, although the boy has less severe symptoms. His hair is fairly full, but several of his permanent teeth are missing.

A heterozygous *EDAR* mutation p.Arg358X was identified in both the index case (5) and her mother (6).

**Family 4, patients 7 and 8** The female index patient 7 in family 4 has one brother and one sister. Her case history mentioned decreased sweating and failure of some of her permanent teeth to erupt, although the permanent maxillary central incisors, and two maxillary and mandibular molars bilateral had erupted. The girl was clinically examined at age 9.5 years. She had sparse scalp hair, eyebrows and eyelashes (Figures 3c–e). There were no nail abnormalities, but her skin was dry and eczematous, and she had five café au lait spots (>1 cm) on her trunk. Nipples and areolae were normal. An iodine sweat test showed diffuse hypohidrosis. She was 144 cm tall (0/+1 SD). Her father had no features of HED but her mother's

case history (patient 8) mentioned insufficient breast milk, decreased sweating and heat intolerance. Some of the mother's teeth had failed to erupt: only bilateral two molars maxillary and mandibular, one conical cuspid mandibular, and four conical incisors maxillary had erupted. Clinical examination of the mother showed sparse scalp hair, eyebrows and eyelashes (Figures 3a and b). Her pubic hair was normal, but axillary hair was sparse; her nails and skin were normal, as were her mammary glands, nipples and areolae. An iodine sweat test showed diffuse hypohidrosis. A heterozygous *de novo EDAR* mutation p.Arg358X was found in the mother who passed it on to her daughter. The mother's parents were unaffected and did not carry this mutation.

**Family 5, patients 9 and 10** The male index patient 9 has one younger, unaffected sister. He was clinically examined at 16 months of age. He had frontal bossing and retrognathia, thin, sparse scalp hair and eyebrows; and there were two conical teeth in the maxilla. His nails were normal, and his skin was dry and eczematous. He was 88.7 cm tall (+2 SD). His father had no features of HED but his mother's case history (patient 10) mentioned decreased sweating and a reduced number of milk and permanent teeth. Only a bilateral cuspid maxillary and mandibular, one molar mandibular at the left, and a bilateral molar maxillary and mandibular had erupted. The maxillary teeth were



**Figure 2** Patient 6 (a and b) and patient 5 (c and d) of family 3. Note the sparse scalp hair and eyebrows, hypoplastic alae nasi, maxillary hypoplasia, and high frontal hairline. Eyebrows of patient 6 have been dyed.

conical. Clinical examination of the mother showed sparse scalp hair and eyebrows, normal nails, and dry skin. Mandibular and maxillary dentures had been placed.

The mother's family history was positive for features of HED: her brother had sparse hair, teeth abnormalities and eczema. The maternal grandmother of the male index patient and her sister also have sparse hair, teeth abnormalities, and eczema. At least nine other family members have symptoms consistent with HED. The index patient 9 was not tested, but his mother (10) carries an *EDAR* mutation p.Arg420Gln.

## Discussion

### Mutation screening in the *ED1* gene

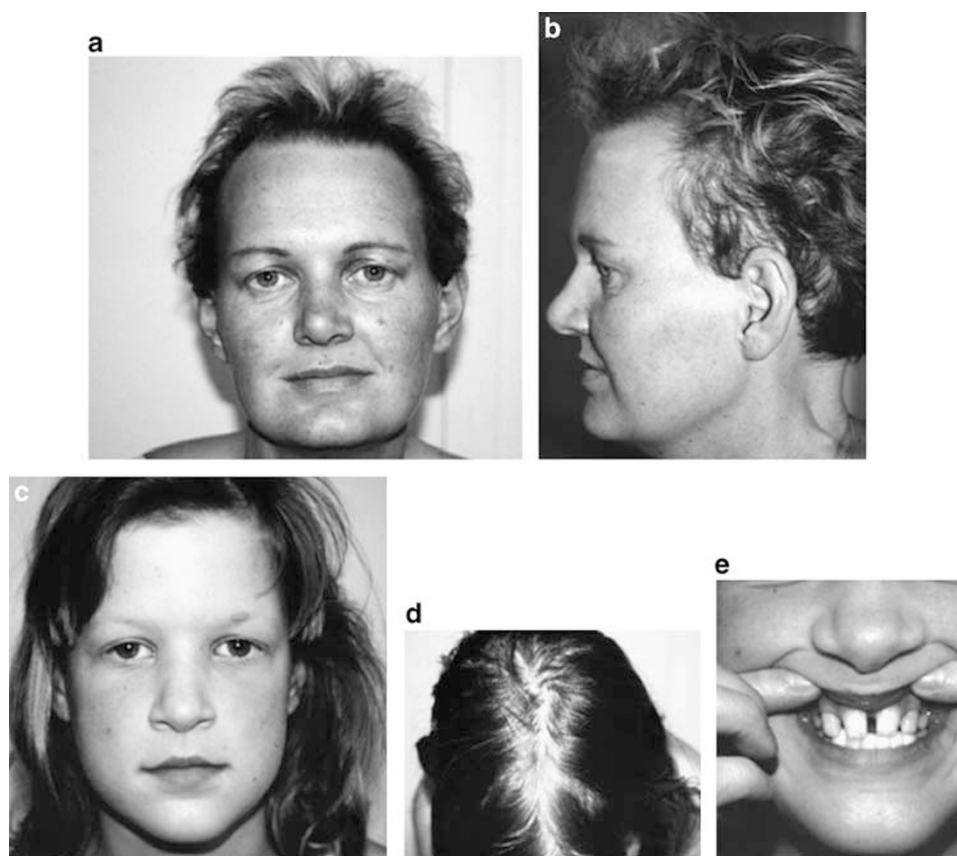
In 24 out of 42 (57%) of the suspected HED families, all with a male index case, we detected a mutation in the *ED1* gene. There are 20 different mutations, 10 of these are novel. The spectrum of mutations is comparable to series published before.<sup>9</sup>

### Mutation screening in the *EDAR* gene

Five of the 18 *ED1*-negative index patients (28%) had mutations in the *EDAR* gene. In four of these families, the

pedigree was compatible with an autosomal dominant inheritance pattern, and in three of them, we found mutations already described as causing autosomal dominant HED: p.Arg358X in families 3 and 4, and p.Arg420Gln in family 5.<sup>2,3,6</sup> In the fourth dominant family (family 2), a novel mutation, p.Glu354X, was found. The inheritance pattern in one family (family 1) was less clear: the two severely affected brothers were compound heterozygous for two separate mutations, p.Arg89His and p.Asp110Ala, their asymptomatic father carries the p.Asp110Ala mutation, whereas the mildly affected mother carries the p.Arg89His mutation. Sequencing of the complete *EDAR* gene in the mother revealed no other mutations. Both mutations have been described in combination with other mutations *in trans*, in families showing autosomal recessive inheritance.<sup>2,3</sup> However, these reports do not mention whether the carrier parents had been extensively clinically evaluated. Subtle abnormalities, as in the mother of these two boys, may have been missed. The severity of the phenotype in the brothers is in favor of two inactive alleles. Thus, a seemingly recessive mutation can also give rise to phenotypic expression in a carrier.

So far 20 HED families, carrying 20 different *EDAR* mutations, have been described in the literature.<sup>2-7</sup>



**Figure 3** Patient 8 (a and b) and patient 7 (c, d and e) of family 4. Note the sparse scalp hair and eyebrows, and missing teeth. Make up has been applied to the eyebrows of patient 8.

Chassaing *et al*<sup>3</sup> found an *EDAR* mutation in 9/37 (24%) of their *ED1*-negative cases, compared to 5/18 (28%) in our population. Thus, our study confirms their finding that mutations in *EDAR* account for approximately 25% of non-*ED1*-related HED cases.

For genetic counseling purposes, it is important to predict the mode of inheritance for any novel mutation found. A correlation between the location and nature of the mutations and the mode of inheritance is now emerging. Mutations leading to a premature stop codon in the mRNA have a recessive effect, because the mutant mRNA is expected to be degraded by the nonsense-mediated mRNA decay (NMD) pathway. Only mutations causing premature stop codons in the last exon, such as p.Glu354X and p.Arg358X, do not cause NMD, because this is depending on an upstream exon–exon junction (for a review of NMD see Maquat<sup>10</sup>). The truncated protein products formed by these mutants, missing the death domain (DD), can have a dominant-negative effect on the protein function, presumably due to lack of homotrimerization of the DDs.

All missense mutations are located in the functional ligand binding domain or the DD, except p.Trp434Cys,

which is located shortly after the DD. In most cases, the mode of inheritance of these mutations seems to be recessive, although the mother in our family 1, who is a heterozygous carrier of p.Arg89His, shows very mild signs of HED. Chassaing *et al*<sup>3</sup> described an affected girl and her very mildly affected father who both carry p.Ile418Thr. We suspect all missense mutations may have a dominant effect with extensive phenotypic variability. The phenotype is more severe if a mutation is present on both alleles. Further examination of the carrier relatives of patients with apparently recessive disease could yield support for this hypothesis.

In the European/American population, there are several recurrent mutations, p.Arg89His, p.Asp110Ala, p.Arg358X, and p.Arg420Gln. Of the six mutations found in our study of 42 Dutch patients, only one (p.Glu354X) is novel (Table 2). In contrast, in four Asian families, five mutations have been described, all exclusive for one family.<sup>4,5,7</sup>

#### Mutation screening in the *EDARADD* gene

In one of our patients, we found a variant p.Ser93Phe. This novel variant is most likely a neutral polymorphism and

not a pathogenic mutation. Serine 93 is not evolutionary conserved between human and mouse, whereas there is more than 75% homology between human and murine EDARADD.<sup>8</sup> This amino-acid residue is not located in the functionally important DD. p.Ser93Phe is unlikely to be a dominant mutation because the mother of this patient is also a carrier of this variation, but she has no symptoms of HED.

### Phenotype

Phenotypically the autosomal dominant HED families show a relatively mild phenotype in comparison to autosomal recessive and X-linked families. In most patients, the teeth are quite severely affected (missing or malformed), in contrast to the relatively mild hypohidrosis and hypotrichosis seen in some patients. These last two features might have been missed in other studies if an extensive clinical evaluation was not performed. There is a wide intrafamilial and interfamilial variability.

### Acknowledgements

We thank the patients and their families for their kind cooperation. Clinicians are acknowledged for sending DNA samples from their HED patients to our laboratory. We thank Mrs Jackie Senior for critically reviewing the paper.

### References

- 1 Stevenson AC, Kerr CB: On the distribution of frequencies of mutation to genes determining harmful traits in man. *Mutat Res* 1967; **4**: 339–352.
- 2 Monreal AW, Ferguson BM, Headon DJ, Street SL, Overbeek PA, Zonana J: Mutations in the human homologue of mouse dl cause autosomal recessive and dominant hypohidrotic ectodermal dysplasia. *Nat Genet* 1999; **22**: 366–369.
- 3 Chassaing N, Bourthoumieu S, Cossee M, Calvas P, Vincent MC: Mutations in EDAR account for one-quarter of non-ED1-related hypohidrotic ectodermal dysplasia. *Hum Mutat* 2006; **27**: 255–259.
- 4 Naeem M, Muhammad D, Ahmad W: Novel mutations in the EDAR gene in two Pakistani consanguineous families with autosomal recessive hypohidrotic ectodermal dysplasia. *Br J Dermatol* 2005; **53**: 46–50.
- 5 Shimomura Y, Sato N, Miyashita A, Hashimoto T, Ito M, Kuwano R: A rare case of hypohidrotic ectodermal dysplasia caused by compound heterozygous mutations in the EDAR gene. *J Invest Dermatol* 2004; **123**: 649–655.
- 6 Lind KL, Stecksén-Blicks C, Lejon K, Schmitt-Egenolf M: EDAR mutation in autosomal dominant hypohidrotic ectodermal dysplasia in two Swedish families. *BMC Med Genet* 2006; **7**: 80.
- 7 Tariq M, Wasif N, Ahmad W: A novel deletion mutation in the EDAR gene in a Pakistani family with autosomal recessive hypohidrotic ectodermal dysplasia. *Br J Dermatol* 2007; **157**: 207–209.
- 8 Headon DJ, Emmal SA, Ferguson BM *et al*: Gene defect in ectodermal dysplasia implicates a death domain adapter in development. *Nature* 2001; **414**: 913–916.
- 9 Vincent MC, Biancalana V, Ginisty D, Mandel JL, Calvas P: Mutational spectrum of the ED1 gene in X-linked hypohidrotic ectodermal dysplasia. *Eur J Hum Genet* 2001; **9**: 355–363.
- 10 Maquat LE: Nonsense-mediated mRNA decay in mammals. *J Cell Sci* 2005; **118**: 1773–1776.