



Case report

Allogeneic hematopoietic stem cell transplantation for advanced mycosis fungoides: evidence of a graft-versus-tumor effect

RK Burt¹, J Guitart², A Traynor¹, C Link³, S Rosen¹, T Pandolfino² and TM Kuzel¹

Northwestern University Medical Center, ¹The Robert H Lurie Comprehensive Cancer Center, Department of Medicine, Division of Hematology Oncology and ²Dermatology Department; and ³Human Gene Therapy Institute, Iowa Methodist Medical Center, Des Moines, IA, USA

Summary:

Allogeneic hematopoietic stem cell transplantation should be considered as a therapeutic option for patients with generalized erythroderma or tumor stage MF. Indeed, the only curative option for MF may be an allogeneic transplant. *Bone Marrow Transplantation* (2000) 25, 111–113.

Keywords: allogeneic hematopoietic stem cell transplant; mycosis fungoides; cutaneous T cell lymphoma

Case report

A 27-year-old black woman was diagnosed with mycosis fungoides (stage T3 N1 M0). She had failed multiple prior therapies including PUVA, PUVA and interferon, six cycles of CHOP (cyclophosphamide, adriamycin, vincristine, prednisone), and two cycles of 9-aminocamptothecin. The patient's skin was diffusely infiltrated with patches, plaques and tumors. Lymphatic and visceral organs were involved. An allogeneic HLA matched sibling transplant was performed using an unmanipulated marrow and CD34 immunoselected blood graft. Conditioning was with cyclophosphamide (200 mg/kg) and total body irradiation (1200 cGy). The post-transplant course was complicated by acute graft-versus-host disease (grade II) that resolved on corticosteroid and cyclosporine immunosuppressive therapy.

The patient remained in complete remission for 9 months when new plaques were noted over the right thigh and chest (Figure 1a). Relapse of MF was confirmed by skin biopsy (Figure 1b and c). Since there was no clinical evidence of GVHD, prophylactic immunosuppression with cyclosporine was discontinued. Within 1 month, the plaques resolved and were replaced by flat and scaly hypopigmented patches. Repeat skin biopsy at the site of prior relapse demonstrated GVHD (Figure 2a and b) without evidence of lymphocyte atypia. Since discontinuation of prophylactic cyclosporine, the patient has remained in remission for 8 months, and peripheral blood mononuclear cells are 100% donor. Beta-actin related pseudogene H-beta-Ac-psi-2 (ACTBP2) VNTR sequence analysis revealed that six donor clones and three recipient clones were 257 bp and identical and three donor clones and two recipient clones were 249 bp and identical.

Discussion

No therapy has been documented that alters the natural history of advanced stage MF. A randomized trial of aggressive combination chemotherapy plus electron beam irradiation vs palliative interventions demonstrated no survival advantage to early aggressive therapy.⁸ Patients with aggressive and/or refractory MF have been treated with

Mycosis fungoides (MF) is a low-grade lymphoma that primarily manifests as cutaneous plaques or tumors.^{1,2} Progression is accompanied by spread to lymph nodes and visceral organs. Histopathology reveals an epidermotropic lymphocytic infiltrate composed of atypical lymphocytes.³ The atypical cells may also be seen in the peripheral blood and are characterized by their cerebriform or hyperconvoluted nuclear detail. MF cells are of the T cell lineage and usually have a CD4⁺CD45RO⁺ memory-helper phenotype.⁴

The natural history of MF is usually indolent. Over many years MF may evolve from premalignant cutaneous lesions and scaly erythematous patches into palpable plaques and finally tumors. The mean survival for patients with early patch lesions may exceed 10–15 years. However, patients with generalized erythroderma or tumor at the time of presentation have a poorer prognosis with a median survival of 2–4 years. Early stage lesions are treated with psoralen and ultraviolet light A (PUVA), topical chemotherapy, extracorporeal photopheresis, interferon, and/or electron beam irradiation.^{5,6} Advanced disease is treated with interferon, retinoids or combination chemotherapy regimens, with mixed results.^{5,7}

To our knowledge, we report the first case of reinduction of clinical and histologic remission following withdrawal of immunosuppressive medication after allogeneic hematopoietic stem cell transplantation, providing evidence for an immunologic graft-versus-MF effect.

Correspondence: Dr R Burt, Wesley Pavilion, Room 162, Chicago, IL 60611, USA

Received 10 May 1999; accepted 4 August 1999

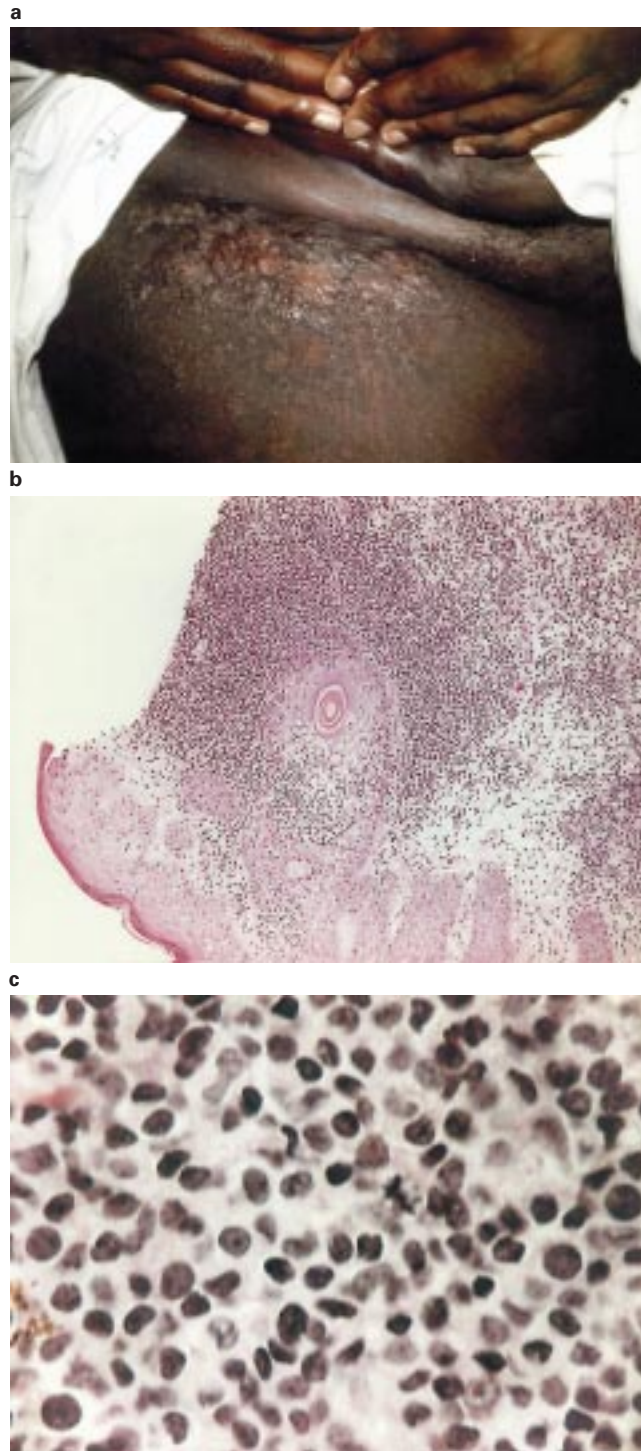


Figure 1 (a) Right inguinal fold showing confluent papules and plaques corresponding to relapse of mycosis fungoides after allogeneic hematopoietic stem cell transplantation. (b) Skin biopsy from the inguinal plaque showing recurrent mycosis fungoides. There is a dense dermal lymphocytic infiltrate with prominent epidermotropism towards the hair follicle. (c) High power view of the infiltrate showing pleomorphic mononuclear cell infiltrate with mitotic figures.

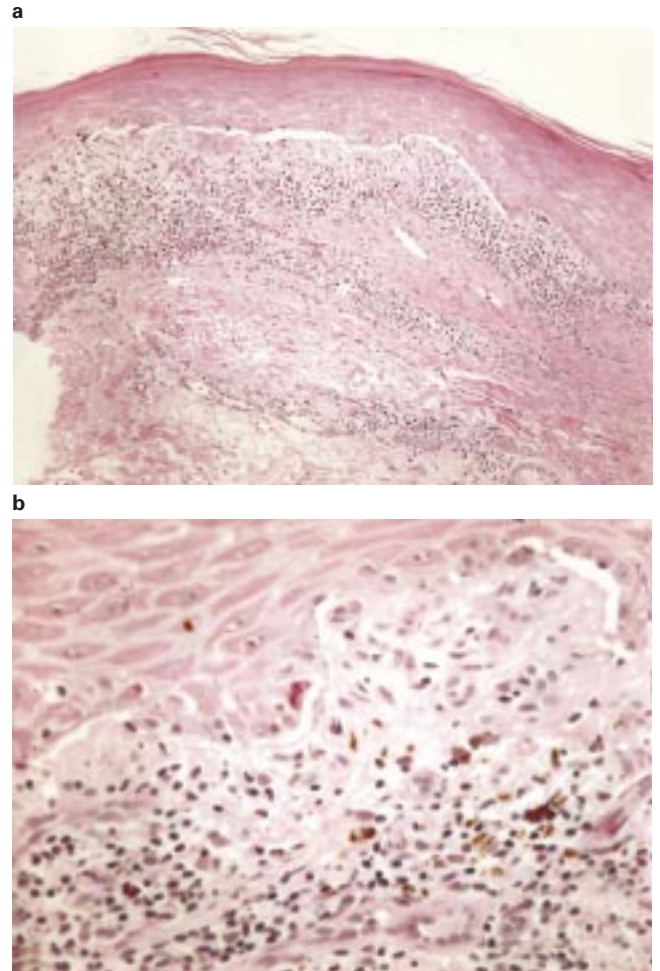


Figure 2 Right inguinal fold (site of relapsed CTCL) with resolution of CTCL 1 month after withdrawal of immunosuppression. (a) Skin biopsy at the site of right inguinal fold relapse 1 month after stopping cyclosporine showing chronic graft-versus-host disease, lichenoid-type. The epidermis is acanthotic with hyperkeratosis and hypergranulosis. There is a band-like lymphoid infiltrate with squamotization of the basal cell layer. (b) High power view showing squamotization of the basal cell layer with necrotic keratinocytes. Numerous small round lymphocytes without atypia are noted in the upper dermis. Melanin laden macrophages are also seen.

autologous hematopoietic stem cell transplantation.^{9,10} Complete remissions ensued but were of short duration.

Immunologic control of mycosis fungoides has been considered reasonable for several reasons. It has been recognized that patients with early stage skin lesions often have reactive tumor infiltrating CD8⁺ T lymphocytes admixed with the neoplastic T cells. Advanced stage of disease is associated with a decreased percentage of infiltrating reactive lymphocytes, and, within stages, patients with greater proportions of CD8⁺ cells have better survival.¹¹ Extracorporeal photopheresis has been used to treat erythrodermic patients, and it has been suggested that this therapy's effectiveness is due to generation of tumor-specific immunity.¹² Response to this therapy has been associated with adequate numbers of CD8⁺ cells. A number of systemic cytokines such as interferon gamma, interleukin-2 and interleukin-12 act through immune mechanisms and have been reported to have anti-MF activity.¹³⁻¹⁷ To our

knowledge, this is the first reported evidence for an allogeneic graft-versus-mycosis fungoides effect.

References

- 1 Diamandidou E, Cohen PR, Kurzrock R. Mycosis fungoides and Sezary syndrome. *Blood* 1996; **88**: 2385–2409.
- 2 Edelson RL. Cutaneous T-cell lymphoma: mycosis fungoides, Sezary syndrome and other variants. *J Am Acad Dermatol* 1980; **2**: 89–106.
- 3 Shapiro PE, Pinto FJ. The histiologic spectrum of mycosis fungoides Sezary syndrome (cutaneous T cell lymphoma). *Am J Surg Pathol* 1994; **18**: 645–667.
- 4 Wood GS, Weiss LM, Warnke RA, Sklar J. The immunopathology of cutaneous lymphomas: immunophenotypic and immunogenotypic. *Semin Dermatol* 1986; **5**: 334–345.
- 5 Kuzel TM, Roenigk HH, Rosen ST. Mycosis fungoides and the Sezary syndrome—a review of pathogenesis, diagnosis, and treatment. *J Clin Oncol* 1991; **9**: 1298–1313.
- 6 Herrman JJ, Roenigk HH, Hurria A *et al*. Treatment of mycosis fungoides with photochemotherapy (PUVA)—long term follow-up. *J Amer Acad Dermatol* 1995; **33**: 234–242.
- 7 Bunn PA Jr, Hoffman SJ, Norris D *et al*. Systemic therapy of cutaneous T-cell lymphoma (mycosis fungoides and Sezary syndrome). *Ann Int Med* 1994; **121**: 592–602.
- 8 Kaye FJ, Bunn PA Jr, Steinberg SM *et al*. A randomized trial comparing combination electron-beam radiation and chemotherapy with topical therapy in the initial treatment of mycosis fungoides. *New Engl J Med* 1989; **321**: 1784–1790.
- 9 Bigler RD, Crilley P, Micaily B *et al*. Autologous bone marrow transplantation for advanced mycosis fungoides. *Bone Marrow Transplant* 1991; **7**: 133–137.
- 10 Sterling JC, Marcus R, Burrows NP, Roberts SO. Erythrodermic mycosis fungoides treated with total body irradiation and autologous bone marrow transplantation. *Clin Exp Dermatol* 1995; **20**: 73–75.
- 11 Hoppe RT, Medeiros J, Warnke RA, Wood GS. CD-8 positive tumor infiltrating lymphocytes influences long term survival of patients with mycosis fungoides. *J Am Acad Derm* 1995; **32**: 448–453.
- 12 Heald PW. Photophoresis for cutaneous T-cell lymphoma. *Ann NY Acad Sci* 1991; **636**: 171–177.
- 13 Kuzel TM, Rosen ST, Gordon L *et al*. Phase I trial of the diphtheria toxin/interleukin-2 fusion protein DAB486IL-2: efficacy in mycosis fungoides and other non-Hodgkin's lymphomas. *Leuk Lymphoma* 1993; **11**: 369–379.
- 14 Kuzel TM, Roenigk HH, Samuelson E *et al*. Effectiveness of interferon alfa-2a combined with phototherapy for mycosis fungoides and Sezary syndrome. *J Clin Oncol* 1995; **13**: 257–263.
- 15 Marolleau JP, Baccard M, Flageul B *et al*. High dose recombinant interleukin-2 in advanced cutaneous T-cell lymphoma. *Arch Dermatol* 1995; **131**: 574–579.
- 16 Rook AH, Kubin M, Cassin M *et al*. IL-12 reverses cytokine and immune abnormalities in Sezary syndrome. *J Immunol* 1995; **154**: 1491–1498.
- 17 Kaplan EH, Rosen ST, Norris DB. Phase II study of recombinant human interferon gamma for treatment of cutaneous T-cell lymphoma. *J Natl Cancer Inst* 1990; **82**: 208–212.