

Oral diagnosis and treatment planning: part 6. Preventive and treatment planning for periodontal disease

E. Corbet¹ and R. Smales²

VERIFIABLE CPD PAPER

A high level of sustained personal plaque control is fundamental for successful treatment outcomes in patients with active periodontal disease and, hence, oral hygiene instructions are the cornerstone of periodontal treatment planning. Other risk factors for periodontal disease also should be identified and modified where possible. Many restorative dental treatments in particular require the establishment of healthy periodontal tissues for their clinical success. Failure by patients to control dental plaque because of inappropriate designs and materials for restorations and prostheses will result in the long-term failure of the restorations and the loss of supporting tissues. Periodontal treatment planning considerations are also very relevant to endodontic, orthodontic and osseointegrated dental implant conditions and proposed therapies.

PRINCIPLES OF PERIODONTAL TREATMENT PLANNING

The aim of periodontal therapy is to preserve for a patient's lifetime a dentition which, although affected by periodontitis,

ORAL DIAGNOSIS AND TREATMENT PLANNING*

- Part 1. Introduction to oral diagnosis and treatment planning
- Part 2. Dental caries and assessment of risk
- Part 3. Periodontal disease and assessment of risk
- Part 4. Non-caries tooth surface loss and assessment of risk
- Part 5. Preventive and treatment planning for dental caries
- Part 6. Preventive and treatment planning for periodontal disease**
- Part 7. Treatment planning for missing teeth
- Part 8. Reviews and maintenance of restorations

*This series represents chapters 1, 7, 8, 9, 14, 15, 16 and 19 from the *BDJ* book *A Clinical Guide to Oral Diagnosis and Treatment Planning*, edited by Roger Smales and Kevin Yip. All other chapters are published in the complete clinical guide available from the *BDJ* Books online shop.

¹Professor in Periodontology, Faculty of Dentistry, The University of Hong Kong, Hong Kong; ²Visiting Research Fellow, School of Dentistry, Faculty of Health Sciences, The University of Adelaide, Adelaide, South Australia 5005, Australia

*Correspondence to: Roger J. Smales
Email: roger.smales@adelaide.edu.au

Accepted 7 June 2012

DOI: 10.1038/sj.bdj.2012.837

©British Dental Journal 2012; 213: 277-284

IN BRIEF

- Highlights the aim of periodontal therapy: to preserve dentition, with acceptable appearance and function, for a patient's lifetime.
- Stresses the ability of patients to achieve effective plaque control is an extremely important factor for subsequent periodontal treatment planning.
- Discusses the close interdependence between restorative treatments and periodontal treatments.

has levels of appearance and function that are acceptable to the patient. This is a long-term aim, which only on death comes to be recognised as having been realised, or not. Because of this, indeterminate outcomes or intermediate stand-in (surrogate) goals are usually set for periodontal therapy.

- The first and foremost is the attainment of sustained high levels of achievement in personal plaque control, reflected as sustained full-mouth bleeding on probing scores below, say, 20-25%. The absence of bleeding on probing over repeated examinations is the best indicator of periodontal stability currently available
- Probing pocket depths of no greater than 5 mm, including horizontal probing in furcations of less than 5 mm, is another worthwhile aim which renders long-term care a more practical proposition. Furcations fully exposed and involved in a through-and-through manner should be fully cleansable by the patient on a daily basis
- Tooth hypermobility should be such that it does not impair the patient's plaque control efforts and allows the patient to function to an acceptable level in comfort.

To achieve the aim and the intermediate goals, the treatment of patients presenting with periodontitis, perhaps including

various sequelae of periodontitis such as tooth drifting and tooth loss, may be described under headings for various phases of treatment.

Emergency care phase of periodontal therapy

As far as periodontitis is concerned, the emergency care phase usually is for the relief of pain due to pericoronitis and abscesses within the periodontal tissues and, perhaps less commonly, pain due to acute necrotising ulcerative gingivitis (ANUG). ANUG should be differentiated from acute gingivitis, and any possible association with systemic diseases or immuno-suppressive drugs should be investigated as appropriate.

Risk management phase of periodontal therapy

This phase of periodontal treatment, which can run concurrently with the following phases, seeks to address all modifiable risk factors associated with susceptibility to periodontal destruction. Obviously in this phase, counselling for smoking cessation for those patients who smoke will take place. Consultations with specialists regarding diabetes control in patients with diabetes mellitus is another example. Encouraging patients under stress to receive counselling on stress management could also be considered in this phase. Of course, less-than-adequate

personal plaque control is a major modifiable risk factor for periodontitis, but sustained improvements in plaque control form the cornerstone of all phases of periodontal therapy, as is explained below.

Fundamental phase of periodontal therapy

This phase is also commonly referred to as the 'initial phase' or 'hygiene phase' of periodontal therapy. The term 'initial' means 'of, or occurring at, the beginning'. Thus, in many senses this term is misleading in that while this phase does occur at the beginning, what this phase entails actually continues throughout all phases of treatment and is not confined to only the beginning of treatment. Also, this term is misleading because often this is the only phase of active therapy required and is, therefore, both the beginning and the end. Another common term for this phase of therapy is 'cause-related therapy'. Again, this term implies that it is only in this phase of periodontal therapy in which attention is paid to the cause of periodontitis, namely plaque, and this is patently misleading. 'Fundamental' means 'forming the basis on which others depend or from which others derive' and, hence, seems appropriate to describe this phase.

The fundamental aspect of periodontal therapy is the control of plaque. In the fundamental phase of periodontal therapy, the patient is both instructed on how and motivated to perform optimal personal plaque control. All plaque retentive factors such as calculus, overhanging restorations, etc. are managed appropriately through scaling, reshaping, etc. All subgingival plaque on root surfaces is disrupted through root surface debridement. All that constitutes non-surgical periodontal therapy is completed in this fundamental phase of therapy. This phase may be completed within 24 hours, in the so-called 'full-mouth debridement' approach. Sufficient time must be given to allow for all tissue changes consequent to this fundamental periodontal therapy to occur fully, before conducting a periodontal re-evaluation, which forms the assessment stage for the planning of further phases of periodontal therapy. This phase of periodontal therapy can be repeated with benefit, as periodontal tissue healing responses following a previous round of fundamental therapy will have reduced

periodontal pocket probing depths, allowing for greater accessibility to root surfaces in previously deep pocket depths.

Corrective phase of periodontal therapy

In the corrective phase of periodontal therapy, the treatment approaches to be adopted depend heavily on the patient's success in controlling plaque on a daily basis and on the response to the preceding fundamental phase of therapy. For example, periodontal surgical approaches for 'correcting' residual periodontal defects are not successful in patients with plaque-infected dentitions, who are not performing adequate oral hygiene. In addition to the 'correction' of residual periodontal defects amenable to treatment, this corrective phase may also entail the orthodontic repositioning of drifted teeth and the replacement, by whatever means, of missing teeth.

This phase can often be a period during which periodontal defects heal and remodel in response to fundamental therapy, and sufficient time must be allowed for the healing to be completed.

Supportive care phase of periodontal therapy

This phase of periodontal therapy is also called the 'maintenance phase' or sometimes 'supportive periodontal therapy'. However, 'care' implies more than 'therapy' in supporting periodontally susceptible patients in the retention of aesthetically and functionally acceptable periodontally affected dentitions for life. The highest aim of supportive periodontal care is the prevention of new or recurrent periodontitis lesions. In practice, however, supportive periodontal care often, through appropriately timed recalls, additionally allows for the early diagnosis of and prompt intervention for new, recurrent or residual periodontal lesions. Supportive periodontal care also entails the prevention and management of the sequelae of periodontal destruction, such as cervical dentine sensitivity (dentine hypersensitivity, root sensitivity), root surface caries, tooth hypermobility, etc.

CONTROL OF DENTAL PLAQUE

The ability of patients to achieve effective, or otherwise, plaque control is an extremely important factor for subsequent

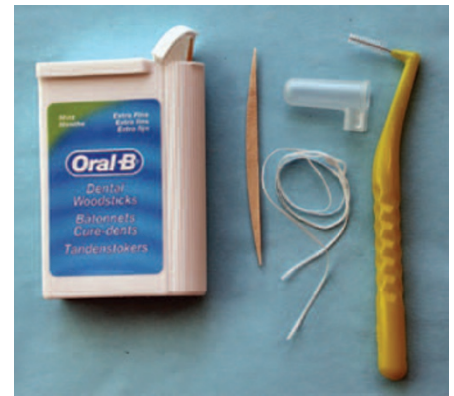

Fig. 1 Examples of oral hygiene aids for removing dental plaque from proximal tooth surfaces



Fig. 2 Plaque disclosing gels, such as the one shown, allow patients to monitor the effectiveness of plaque removal

periodontal treatment planning. Effective long-term repeated removal of dental plaque is fundamental to the provision of periodontal therapy and the control of inflammatory periodontal disease. To achieve effective plaque removal daily at home, patients must be sufficiently educated and motivated, have adequate dexterity, and be able to obtain access to all tooth surfaces using appropriate mechanical and chemical cleaning methods. It should be made clear to patients that they are responsible for the continued control of their dental plaque. The acceptance of a behavioural change by the patient is usually required for effective plaque control, which is demonstrated by the normal colour and firmness of gingival tissues and the absence of bleeding on gentle probing.

Mechanical cleaning methods should

be both practical and effective when used in a systematic manner, without causing damage to the periodontal tissues, tooth enamel and exposed root surfaces, and restorations. Manual and powered toothbrushes are not capable of removing plaque from all tooth surfaces, even when carried out correctly using a small soft multi-tufted brush. The bristles have a limited penetration into inter-proximal gingival embrasures, root furcations, gingival crevices and periodontal pockets. Proximal tooth surfaces are cleaned more effectively using dental floss or tape (waxed or unwaxed) when dental papillae fill the gingival embrasures, or using thin triangular woodsticks when space permits their gentle insertion. Larger interdental spaces with exposed root surfaces may be cleaned with various-sized small interdental brushes, which can also be used to convey casein-derived pastes, fluoride dentifrices and fluoride gels to proximal tooth surfaces (Fig. 1).

Unlike dental floss, the brushes are effective in cleaning plaque from proximal root surface concavities and root furcations, and there is less risk of damaging periodontal tissues and cutting grooves into root surfaces, which may occur with improper use of dental floss. The use of dental floss also requires more manual dexterity, and there are often problems with the floss fraying and breaking when attempting to use it on restored proximal tooth contacts. Removing jammed frayed fibres from between the teeth is often very difficult for patients. The thicker fibres of Superfloss (Oral-B) have an embedded floss-threader to pass the Superfloss through the gingival embrasures when space permits. Superfloss can also be used to clean the undersurfaces of pontics of fixed prostheses and the proximal surfaces of teeth adjacent to edentulous spaces. Single-tufted brushes are very useful for cleaning tooth root surfaces with concavities and furcation entrances. Pulsating streams of water can physically remove loose debris from around orthodontic bands. Oral irrigating devices such as the Ultra Dental Waterjet (Waterpik Technologies, Inc.) may also be useful for gently flushing periodontal pockets with antimicrobials, such as 0.12% chlorhexidine solution, although this would not be a usual practice.

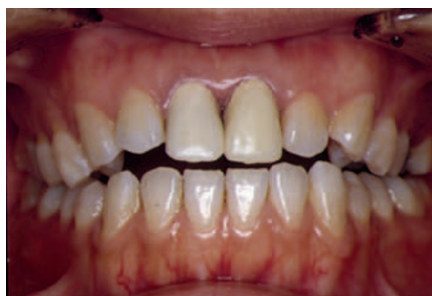

Fig. 3 Poorly fitting margins of interim crowns placed on the maxillary central incisor tooth preparations have resulted in plaque retention and gingivitis

Chemical plaque control approaches include the daily use of chlorhexidine or essential-oils mouthrinses in particular. Routine use is not a prerequisite for good gingival health. The antimicrobial effects of mouthrinses are largely limited to supragingival plaque, unless the solutions are used for the subgingival irrigation of periodontal pockets, though any bleeding inactivates chlorhexidine.

During the learning phase of effective plaque removal, disclosing agents (solutions, gels, chewable tablets) that stain the plaque will provide useful feedback to patients (Fig. 2). The agents should be used in combination with a systematic cleaning method that focuses on removing dental plaque from all tooth surfaces adjacent to the gingival tissues. Brushing the dorsum of the tongue, though not having been shown to be required, completes the routine for many. Learning effective plaque control occurs in stages, with continued reinforcement and re-instruction required.

PERIODONTAL CONSIDERATIONS RELATED TO RESTORATIVE DENTISTRY

There is a close interdependent association between restorative treatments and periodontal treatments that affects the biological health, function and appearance of the teeth and supporting tissues.

Periodontal tissue handling

The periodontal tissues should be as healthy as is possible, without bleeding on probing, before elective restorative procedures are undertaken that impinge on the free gingival margins. The potential for iatrogenic tissue damage occurs during all operative dental treatment procedures. The gingival tissues should be handled gently, with care taken not to damage them unnecessarily

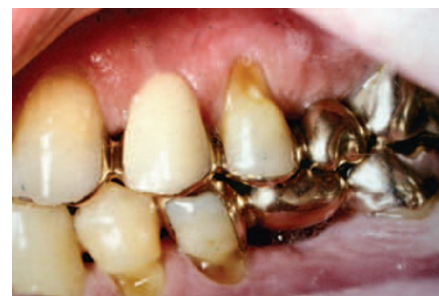

Fig. 4 Margins of these 12-year-old fixed prostheses have been placed supragingival where possible. Open gingival embrasures facilitate access for plaque removal

during tooth preparations and the placement of restorative materials. Correct contouring of matrix bands and their careful subgingival placement, together with the careful placement of anatomic wedges, should result in minimal gingival tissue damage. Care also should be taken when placing rubber dam clamps to avoid unintended damage to the gingival tissues. A thin, narrow band of keratinised attached gingiva is easily damaged during gingival retraction and impression taking, and by poorly fitting plaque-retentive gingival margins of interim (temporary) restorations (Fig. 3), leading to subsequent gingival recession that may expose discoloured root surfaces in aesthetically critical regions of the mouth. Thus, special care and attention should be paid to the preservation of healthy gingival tissues during the aesthetic restoration of teeth in aesthetically critical areas of the mouth, in particular when the gingival tissue is of a thin and scalloped bio-type.

Where possible, tooth preparation margins should be placed supragingival, ideally 1–2 mm coronal to the free gingival margins (Fig. 4). However, in many instances this is not possible because of previous damage and discoloration of tooth structure, the requirement for adequate retention of the restorations, and the dictates of an attractive appearance. In taking impressions that aim to capture the subgingivally prepared tooth margins, retraction cords, often with various haemostatic agents incorporated, are frequently placed in the gingival sulcus. Care should be taken to remove fully any retraction cords or other materials placed.

Preparation of deep subgingival margins on root surfaces will encroach upon the biologic width of the periodontal tissues. The biologic width, approximately 2 mm,

comprises the supra-alveolar crestal connective tissue attachment and the junctional epithelium (epithelial attachment). When encroached upon, the periodontal tissues may become inflamed. The biologic width is generally re-established with the loss of alveolar crestal bone, and pocket formation in thick gingival tissues, but recession in thin gingival tissues. In some instances, clinical crown lengthening may offer a satisfactory solution to this problem. Orthodontic root extrusion is another viable approach if the patient accepts the plan. However, these procedures lead to the exposure of tapered roots, resulting in narrower root cross-sections and wider interdental gingival embrasure spaces. This creation of unsightly 'black holes' or 'black triangles' between the teeth may also occur following periodontal therapy and when large diastemas are present, and often results in food impaction and even in occasional speech problems. The combination of narrow tooth roots and wide interdental gingival spaces, together with long clinical crowns, creates a difficult restorative situation. Overcontouring the proximal surfaces of restorations to improve the appearance of the patient by reducing the size of the triangular spaces must be performed with care to avoid overhanging margins, which would cause difficulties in removing plaque deposits, leading to chronic gingivitis (Fig. 5).

After periodontal surgery, plaque accumulation on the exposed proximal root surfaces of teeth may on occasions lead to root surface caries which, again, creates a difficult restorative situation for posterior teeth in particular. In some instances the patients, usually elderly, may be unable to remove the plaque effectively when using mechanical methods, because of deteriorating physical and/or mental capabilities. This deterioration may occur quite rapidly. Such patients require regular recall appointments and vigorous preventive dental treatments, often also enlisting the assistance of another person's help at home. The home-use application of GC Tooth Mousse Plus (GC Corp.) crème/paste to exposed root surfaces promotes the remineralisation of demineralised dentine and also reduces any dentine sensitivity present.

Restoration contours

The correct placement, contouring, and finishing and polishing of restorations is

important for the physical protection of the periodontal tissues, and to reduce the accumulation and facilitate the removal of dental plaque. Overcontoured restorations result in increased challenges to plaque control at the gingival margin areas, while undercontoured restorations and open approximal contact areas may result in lateral and vertical food impaction which, while uncomfortable for the patient, may not itself adversely affect the periodontal health (Fig. 6).

Opposing occlusal contacts should be examined carefully in all instances of fibrous food wedging, which usually affects the terminal tooth in the arch. Deflective cusp inclines may displace the affected tooth distally during chewing, causing a slight opening of the approximal contact between adjacent teeth, which then allows the fibrous food to enter the space, and attempted return of the distal tooth to its original position traps the fibrous food. In restoring the adjacent surfaces of approximating teeth, the marginal ridges should be placed at the same height to reduce the likelihood of food wedging caused by an opposing so-called 'plunger cusp'. Contouring of restoration surfaces should reproduce the correct occlusal, gingival, facial and lingual embrasure forms, and the correct approximal contact area forms, for the particular tooth site. Dental floss should pass through the contacts without jamming and fraying. The gingival emergence angles of the tooth surfaces should be retained when replacing damaged tooth structure with restorations. The margins of the restorations should blend smoothly with those of the adjacent remaining sound tooth structure.

In some instances, old plastic restorations and artificial crowns may be recontoured and repolished (refurbished) satisfactorily to enable plaque control at gingival margins in particular, to improve access for plaque removal (Figs 7 and 8). Care must be taken not to damage the periodontal tissues and tooth structure during such procedures.

Restoration surfaces

Rough restoration surfaces, irrespective of the material, and open marginal gaps between restorations and contiguous tooth surfaces favour the attachment and growth of dental plaque. The surfaces of

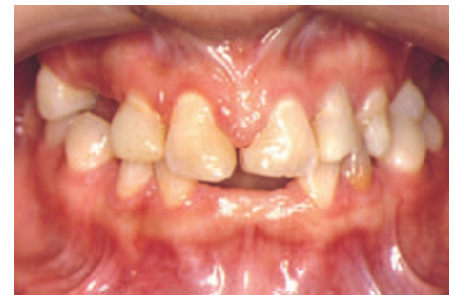

Fig. 5 Overhanging proximal margins of the resin composite restorations placed on the maxillary central incisors have resulted in plaque-induced gingivitis with gingival hyperplasia

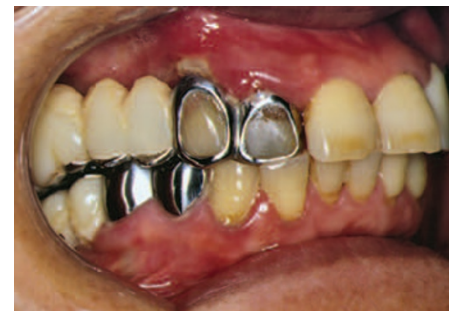

Fig. 6 Incorrect contours and overhanging margins of these preformed stainless steel prostheses, together with poor oral hygiene, have resulted in chronic periodontitis

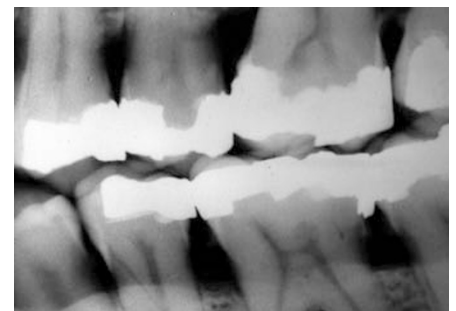


Fig. 7 Poor contours and overhanging amalgam restoration margins, together with subgingival calculus, are associated with alveolar bone loss

restorative materials adjacent to gingival tissues and in contact with adjacent teeth in particular should be no rougher than sound tooth enamel. Glazed and highly polished dense porcelain surfaces retain less plaque than sound tooth enamel. Other materials may retain the same or greater amounts of plaque than sound enamel. Plaque colonisation increases significantly at an average surface roughness of approximately 0.2 µm, which is exceeded by conventional glass-ionomer cements after polishing and also after the application of 1.23% acidulated phosphate fluoride gel. The initial antibacterial effect of glass-ionomer restorations also is lost soon after their placement, because of

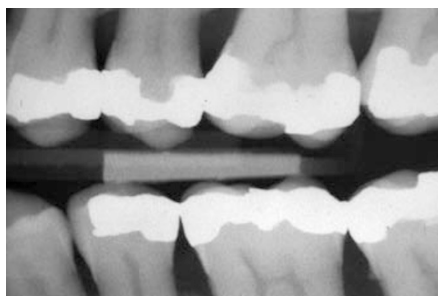


Fig. 8 Several of the amalgam restorations shown in Fig. 7 have been recountoured to facilitate the removal of plaque from proximal tooth surfaces

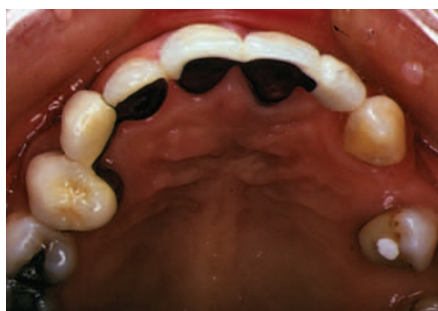

Fig. 9 In these two different fixed prosthesis designs, modified ridge lap pontics that facilitate plaque control have replaced a maxillary left lateral incisor and a right canine

diminishing fluoride release, and plaque retention is not obviously less than on other plastic restorative materials placed in similar tooth sites. For some materials, mastication of foods of varying abrasiveness leads to roughening of the occlusal surfaces of highly polished restorations, and to some polishing of rough restoration surfaces.

Restoration occlusion

The placement of non-yielding restorations that are 'high' usually results in some acute discomfort, which varies with the level of occlusal forces transmitted to the periodontal and other tissues and the adaptive capacity of the patient. If untreated, then in some instances the affected overloaded teeth may become increasingly mobile following alveolar bone resorption at sites of tissue injury, but there is no associated clinical attachment loss. Excessive occlusal forces, resulting in trauma from occlusion (occlusal trauma) as diagnosed by various clinical indicators, alone do not initiate either gingivitis or the formation of periodontal pockets. However, the presence of persistent occlusal discrepancies may result in persistent tooth mobility and less favourable reductions in

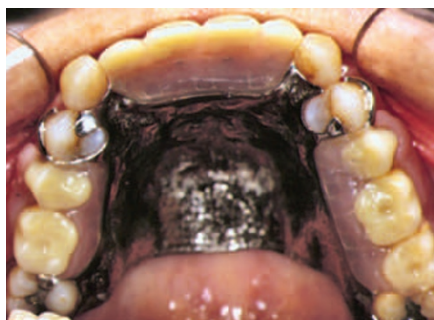

Fig. 10 The patient is wearing a tooth-supported upper removable partial denture

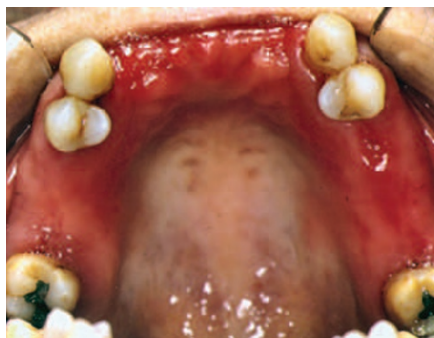

Fig. 11 Removal of the denture shown in Fig. 10 reveals that poor oral and denture hygiene have resulted in inflamed gingival and palatal tissues

periodontal probing depths and gains in clinical attachment in response to periodontal therapy, due to the lesser resistance to probing offered by periodontal tissues surrounding mobile teeth. In instances of very advanced periodontal destruction resulting from periodontitis, increased (or even normal) occlusal forces may become tantamount to extraction forces leading to progressively increasing tooth mobility, with the surrounding tissues offering less and less resistance to periodontal probing. Hence, though not necessarily related to the progression of periodontal disease, occlusal adjustments of high restorations and of functionally overloaded teeth improve the 'occlusal comfort' of patients by distributing occlusal forces to include other teeth.

Fixed and removable prostheses

Dental implant and natural tooth abutments for fixed partial dentures (FPDs) and removable partial dentures require particular attention for adequate plaque control. The design of the prostheses should minimise the accumulation of plaque and, for fixed tooth and implant supported superstructures also provide optimal access for plaque removal. Where

appearance is not critical, then an ovate or spheroidal pontic is preferred for FPDs. Buccolingually narrowed 'sanitary' pontics should be well clear of or lightly contact and follow the contours of the edentulous ridge, avoiding excessively wide-open gingival embrasures that lead to food stagnation and retention (Fig. 4). Where appearance is important, then the modified ridge-lap pontic is used to minimise contact with soft tissues (Fig. 9), but efforts should be made to ensure that the entire undersurface of the pontic can be cleaned. Connectors should not displace the dental papillae, and all soft and hard tissue contacting surfaces must be highly polished and non-porous.

Following cementation, all adherent excess cement on tooth/implant and restoration surfaces, and loose cement fragments in the gingival crevices, must be removed. Permanent, fixed and removable cast metal splints are seldom required to stabilise mobile and drifted teeth following periodontal treatment, orthodontic tooth repositioning and minor occlusal adjustments.

Removable partial dentures are associated with an increased risk of periodontal disease and dental caries affecting the remaining teeth in contact with the prostheses, and an increased resorption of alveolar bone beneath non-tooth borne mucosal-supported denture bases (saddles). These problems are more closely related with denture hygiene than with the material from which the denture is made (Figs 10 and 11). In middle-aged and older patients, following tooth extractions, there is often relatively little movement of the adjacent teeth and, hence, the need to replace the extracted teeth to maintain occlusal stability in older adults may be reduced. Therefore, in many instances, 'the shortened dental arch is preferable to the extended prosthetic arch'. A shortened dental arch has sufficient teeth for the patient's comfortable function and to satisfy the aesthetic requirements of the patient for the dentition.

PERIODONTAL CONSIDERATIONS RELATED TO ENDODONTICS

The periodontal tissues and the dental pulp are intimately linked. Communication between the two structures may occur via apical root canal foramina, accessory

lateral and furcal canals, patent exposed dentine tubules, root fractures, and root canal perforations caused by root resorption and operative procedures.

Though a vital inflamed pulp may be associated with small clinically-detectable regions of periodontitis adjacent to root canal and accessory root canal foramina, the periodontitis is usually caused by infection spreading from a non-vital pulp. Subsequently, a periapical, lateral or furcal abscess may form within the periodontal tissues. Occasionally, the abscess may drain into an existing periodontal pocket, or track coronally along the periodontal ligament to discharge via a narrow sinus in the gingival sulcus. (The tubular tract formed may be confused with the narrow periodontal pocket found in association with a developmental radicular groove, which may be present on the palatal root surfaces of maxillary central and lateral incisors in particular). This coronal drainage route is also likely to occur with abscesses associated with root fractures and root canal perforations. Although usually draining buccally, an abscess may also drain lingually or palatally, sometimes at a distance of one or two teeth removed from the non-vital tooth.

In all situations it is important to determine the correct sensibility status of the pulp and the cause of the abscess, so as to exclude inappropriate treatment planning based on the incorrect assumption of a periodontal origin for the abscess. False-positive sensitivity tests can occur in multi-rooted teeth where one or more root canals may contain some nerve tissue even though there is no blood supply within the pulp chamber and the other root canals. False-positive sensibility tests have also been reported in teeth associated with advanced angular and furcation periodontal lesions. False-negative sensibility tests may occur from narrowed root canals and pulp chambers following extensive deposition of dentine or calcified material, and from insulation of the pulp by restorations. A gutta-percha point (cone) inserted into a sinus tract before taking one or more periapical radiographs is useful to assist in the diagnosis of the origin of the abscess.

Over-instrumentation of root canals with the extrusion of infected root-canal contents, and overfilling or extrusion of restorative materials, into the periodontal

ligament will result in periodontitis to varying degrees. Usually, the clinical signs and symptoms resolve within a short period. Operative procedures such as root canal and post channel (post space) preparations may result in root canal perforations and, subsequently, root fractures may occur from weakening of tooth structure. Ancillary pin placements for the retention of restorations also may perforate tooth structure to enter the periodontal ligament. Depending on their site, size and access to them, perforations may be repaired in favourable circumstances. The prognosis for success diminishes with delayed diagnosis, extensive perforations, inaccessibility, and the presence of infection. If the perforation is into a pre-existing periodontal pocket, then periodontal therapy is required following sealing of the perforation. The likely long-term prognosis for the tooth following such treatments, its strategic importance and financial considerations are important factors for determining its retention or otherwise. In some instances, after root canal therapy in a strategic molar tooth, it may be possible to retain the tooth by resection of the root that has a hopeless prognosis. It is worthwhile noting that with careful plaque control and regular 3–6-monthly recalls, root resection for the treatment of furcation-involved molar teeth may result in 10-year tooth survivals of more than 90%; failures usually occurring because of endodontic and other non-periodontal disease complications in patients undergoing regular and careful supportive periodontal care.

Despite the extensive loss of periodontal attachment associated with infected deep pockets, there is usually little clinical evidence of pulpitis being present. Provided that the vascular supply remains intact, then the dental pulp remains vital. On occasions, deep periodontal pockets and scaling and root surface debridement may lead to the exposure of patent accessory canals and dentine tubules, which may result in tooth sensitivity. Where periodontal pockets are present and the root canal system is also infected, then intracanal non-toxic medicaments are required to destroy micro-organisms within the dentine tubules before the canals are obturated, and before any cementum is removed during root surface debridement.

Root resorption may be either

physiological, as during exfoliation of the primary teeth, or pathological. The latter may be classified as trauma-induced, infection-induced, and hyper-plastic. Pathological internal root resorption is thought to commence within the dental pulp, though it may be maintained via large accessory canals from the periodontal tissues. The process may follow trauma and infection of the pulp, leading to chronic pulpitis and hard tooth tissue destruction by multinucleated giant cells. A 'pink spot' observed in the tooth crown, or the chance finding of a widened root canal space in a radiograph may be the first indication of a lesion. Pathological external root resorption originates from the periodontal tissues.

There are three principal forms:

- External progressive inflammatory resorption is common and may occur following pulpal infection and necrosis, trauma, periodontal disease, expanding lesions and rapid orthodontic tooth movement. In other instances there are no plausible explanations
- External replacement resorption (ankylosis) occurs after extensive necrosis of the periodontal ligament, when bone replaces cementum and dentine, which may occur following tooth avulsion and subsequent re-implantation. The affected teeth may be in infra-occlusion, are non-mobile and have a high-pitched sound when percussed
- External invasive (cervical) resorption may follow trauma, orthodontic tooth movement, and internal bleaching when using 30% hydrogen peroxide solution. The invasive tissue is very vascular and derived from the periodontal ligament. The lesion may first be detected by chance on a routine radiograph, or when it becomes infected.

A self-limiting surface resorption (repair-related resorption) due to tissue injury may be followed by cemental repair, and no treatment is required.

PERIODONTAL CONSIDERATIONS RELATED TO ORTHODONTICS

Orthodontic repositioning of drifted, tilted, extruded and rotated teeth not only

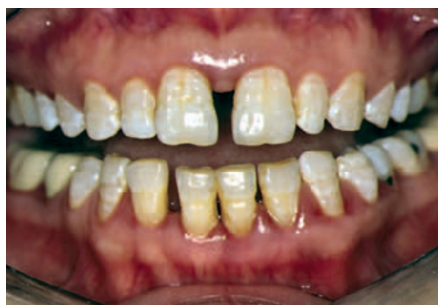

Fig. 12 A wide anterior diastema resulting from tooth drifting is present between the maxillary central incisor teeth in this patient with evident chronic periodontitis

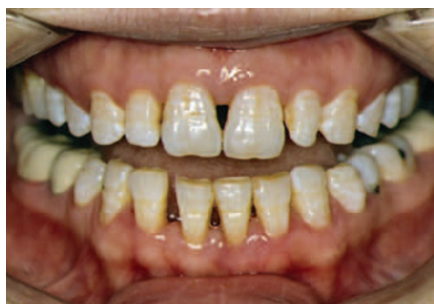

Fig. 14 Both central incisors have moved slightly bodily and are tilted mesially. The lateral incisors also have moved mesially, but to a lesser extent

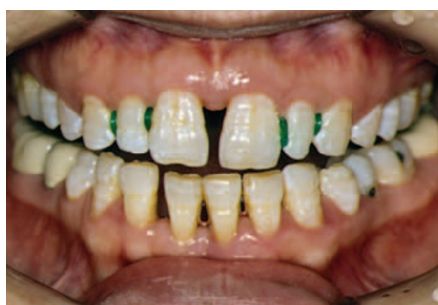

Fig. 13 Following comprehensive periodontal therapy, orthodontic elastic separators are placed interproximally to effect minor tooth realignment

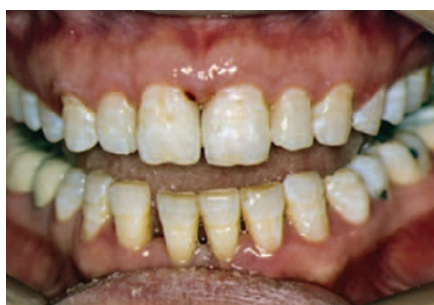

Fig. 15 The patient's appearance immediately following resin composite build-up restorations of the proximal tooth surfaces of the central and lateral incisor teeth

assists restorative treatment, but may also improve the subsequent long-term health of the periodontal tissues. Adjunctive orthodontic treatment should generally only commence once adequate plaque control has been achieved and periodontal therapy has been performed, and the periodontal tissues observed for resolution of inflammation and for healing. Care must be taken during orthodontic treatment to avoid adverse biomechanical forces being applied to teeth having reduced periodontal support. Inappropriate orthodontic treatment may result in gingival recession, clinical attachment loss, and extensive bone and root resorption.

Orthodontic treatment is an essential component of the management of advanced periodontitis where pathological tooth migration has resulted in labial flaring, extrusion and irregular spacing of the anterior teeth (Part 3, Fig. 14). A large diastema present between the maxillary central incisor teeth may be closed partially by using, for example, interdental elastic separators to distribute interproximal spaces more evenly between all of the maxillary incisor teeth. This partial space closure results in reduced overcontouring of the proximal tooth surfaces when placing resin composite build-up restorations.

The appearance of the patient is improved without unduly compromising periodontal health (Figs 12 to 15). Correction of gingival margin discrepancies in critical anterior aesthetic regions may occasionally require orthodontic tooth extrusion or intrusion. The uprighting of a mesially tilted molar tooth in particular not only reduces the depth of the gingival sulcus or pseudopocket on the mesial coronal tooth surface, but also reduces the mesial vector of non-axial occlusal loads (whether this is of benefit or not is not established), and simplifies the design of fixed and removable prostheses. Substantial occlusal changes may be required to prevent traumatic damage to periodontal tissues from a deep anterior overbite (vertical overlap). Intrusion of extruded teeth associated with infrabony defects may lead to reductions of probing depths, and gains in clinical attachment and in bone re-modelling.

PERIODONTAL CONSIDERATIONS RELATED TO DENTAL IMPLANTS

Many clinical studies have been published that show high long-term survival (retention) rates for osseointegrated dental implants. Fewer clinical studies have been published on the long-term success rates of dental implants, which are usually much

lower than survival rates because of marginal bone loss occurring around the dental implants. Persons with previous tooth loss from periodontitis have significantly more long-term peri-implantitis and peri-implant marginal bone loss, leading to lower implant survival and success rates. Therefore, patients who are susceptible to periodontal disease are also at higher risk for long-term implant complications and failure rates, as both the teeth and the implants share the same environment and predisposing risk factors (Part 3).

Before dental implants are inserted as tooth replacements, periodontal disease in all patients must be actively treated and stabilised, and then monitored for success over at least three months. Periodontitis-associated microbial flora may be transmitted to implants from residual pockets around natural teeth. The full-mouth plaque score should be maintained at <20% and the bleeding score at <20-25%, and there should be few residual probing pocket depths >5 mm. Surgery may be required to eliminate or reduce residual pocket probing depths where periodontal disease is progressing. Predisposing risk factors should be reduced or eliminated. Continued poor compliance by patients with instructions and a continued high risk profile for progressive periodontitis may postpone or preclude the placement of dental implants.

Advanced periodontal disease is associated with considerable loss of alveolar bone, and the volume is reduced further by post-extraction remodelling. Periodontally involved maxillary incisor teeth in particular may also have drifted far mesially, altering the original position of the anterior alveolar ridge. Horizontal and vertical deficiencies in alveolar bone volume may cause difficulties in dental implant selection, placement and alignment. Though there are many surgical procedures available for surmounting these deficiencies to varying degrees, not all patients want or can afford extensive surgical alveolar bone augmentation.

Rigid osseointegrated implants and mobile periodontally treated teeth with reduced support respond very differently to occlusal stresses. This situation has implications for restorative treatments. Meta-analysis found that the long-term survival rates of combined short-span

tooth-implant-supported FPDs were lower than the survival rates reported for solely implant-supported FPDs. Intrusion occurred in 5.2% of the abutment teeth after five years, almost exclusively where non-rigid connections had been used. Several long-term studies, involving both short-span and complete-arch fixed partial dentures connecting teeth and implant abutments, support the use of rigid connections for abutment teeth with both normal and reduced periodontal support. While perhaps not the first choice of treatment, joining teeth to implants in fixed reconstructions by rigid prostheses can be considered if extensive surgery, required to augment alveolar ridge deficiencies or to overcome anatomical challenges prior to implant placement to secure implant-to-implant connections, can be avoided.

PROGNOSIS FOR PERIODONTAL TREATMENT RESPONSE

The overall prognosis is usually relatively straightforward either for patients with simple gingivitis that can be controlled, or for those with advanced destructive periodontal disease that cannot be controlled. The prognosis for patients depends very much on the effectiveness of long-term plaque removal, which is largely related to the personal commitment of the patient. And, the larger the numbers of uncontrolled risk factors present (Part 3), the more important the attention to meticulous plaque control becomes. If plaque cannot be adequately controlled, then the poorer is the prognosis. Prognosis can be considered from the perspective of two levels; the patient level at which many risk factors such as tobacco smoking and systemic diseases and drug consumption act, and the tooth level at which local factors such as anatomical features and plaque retentive situations act. However, a constant at both levels is plaque control at the full-mouth level and the tooth/site level.

Heavy occlusal loading of the remaining teeth from tooth grinding and clenching, especially if the tooth roots are short and tapered and have reduced alveolar bone support following loss of the periodontal

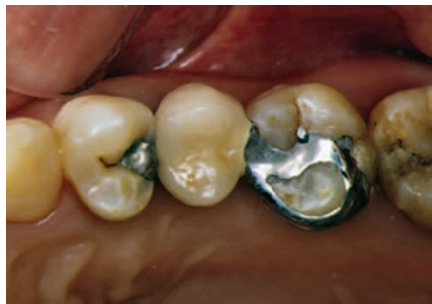

Fig. 16 A simple cantilever fixed prosthesis, which facilitates plaque control, replaces a second premolar tooth that was extracted because of a non-restorable situation

attachment apparatus, may result in increased tooth mobility. Individual abutment teeth for fixed and removable prostheses also are subjected to increased functional stresses, which may result in increased tooth mobility when the centres of rotation of the teeth have moved apically following the loss of bone support. However, a meta-analysis of six studies found that fixed partial dentures constructed on abutment teeth with severely reduced but healthy periodontal tissue support had similar ten-year survivals (93%) to those constructed in persons without severely periodontally compromised dentitions.

Other factors influencing the periodontal treatment prognosis at a tooth level include the level of attachment loss or, more correctly, the amount of attachment remaining, and the ability to gain access to debride root surfaces, including root furcation involvements in multirooted teeth and palato-gingival grooves in incisor teeth. A retrospective study involving the assessment of the periodontal health of 172 patients after a mean time of 11.3 years of active and supportive periodontal therapy found that a residual probing pocket depth of ≥ 6 mm resulted in a significantly increased risk for disease progression and tooth loss.

Teeth with a hopeless short-term (approximately 1–5 years) prognosis because of advanced periodontal disease may be extracted, if irrational to treat. It is faster, less stressful and less expensive to place simple, easily cleansable cantilever

FPDs as single-tooth replacements, if these are required, than to persist with the often prolonged, costly treatments needed for the retention of teeth having a poor prognosis and little functional significance for the patient (Fig. 16).

However, many apparently hopeless teeth can be maintained for many years in comfortable function following non-surgical periodontal therapy and careful supportive periodontal care. This approach for extending the functional retention of teeth should mostly be preferred over extraction and replacement. Holistic treatment planning and consultations with the 'end-providers' of specialist dental treatment items at the outset could avoid problems. Strategic tooth extraction of teeth with advanced periodontal destruction, if irrational to treat, is often followed by partial reduction of pockets on adjacent periodontally involved teeth, which may improve the prognosis of useful and strategic teeth that should be retained.

FURTHER READING

- Heithersay G S. Management of root resorption. *Aust Dent J Endod* 2007; **52**(1 Suppl): S105–S121.
- Lai S M-L, Zee K-Y, Corbet E F. Implant reconstructions in periodontally susceptible patients. *Hong Kong Dent J* 2008; **5**: 11–18.
- Lang N P, Pjetursson B E, Tan K, Bragger U, Egger M, Zwahlen M. A systematic review of the survival and complication rates of fixed partial dentures (FPDs) after an observation period of at least 5 years. II. Combined tooth-implant-supported FPDs. *Clin Oral Implants Res* 2004; **15**: 643–653.
- Lulic M, Bragger U, Lang N P, Zwahlen M, Salvi G E. Ante's (1926) law revisited: a systematic review on survival rates and complications of fixed dental prostheses (FDPs) on severely reduced periodontal tissue support. *Clin Oral Implants Res* 2007; **18**(Suppl 3): 63–72. (Erratum: 2008; **19**: 326–328).
- Rotstein I, Simon J H S. Diagnosis, prognosis and decision-making in the treatment of combined periodontal-endodontic lesions. *Periodontol* 2000 2004; **34**: 165–203.
- Sanders N L. Evidence-based care in orthodontics and periodontics: a review of the literature. *J Am Dent Assoc* 1999; **130**: 521–527.
- Schou S. Implant treatment in periodontitis-susceptible patients: a systematic review. *J Oral Rehabil* 2008; **35**(Suppl 1): 9–22.
- Summitt J D, Robbins J W, Hilton T J, Schwartz R S, Dos Santos Jr J. *Fundamentals of operative dentistry: a contemporary approach*. 3rd ed. Chicago: Quintessence, 2006.
- Vanarsdall R L. Orthodontics and periodontal therapy. *Periodontol* 2000 1995; **9**: 132–49.
- Weston P, Yaziz Y A, Moles D R, Needleman I. Occlusal interventions for periodontitis in adults. *Cochrane Database Syst Rev* 2008; CD004968.