DISAPPOINTINGLY LITTLE EVIDENCE

Sir, the *BDJ* has played a significant role introducing the concept of evidence-based dentistry. It is disappointing therefore to read so little scientific evidence supporting the processes and materials recommended in *Impressions in implant dentistry* (*BDJ* 2011; **211:** 361-367). I have to say at the outset that 'Dispatching the impression(s) in a sealed box, rather than a polythene bag will ensure that they are not damaged and delicate components are not dislodged' does not engender much confidence where any science is concerned!

Nowhere in the article do we find any scientific evidence in support of the chosen materials and methods used for taking accurate impressions and manufacturing a precise replica or 'working model'.

Historically, the choice of dental impression and model materials in practice is often made on an empirical basis and as the article acknowledges, the replication of the geometry of the clinical landmarks is pretty critical. Any errors in location of the implant supported frameworks may result in loosening of the implants themselves. It is incredibly difficult choosing the right combination of materials to use in conjunction with a customised impression matrix to capture reliable data for use in the manufacturing of precisely fitting dental prostheses. The dental impression is only the beginning of a complex set of operations that must be the subject of an overall manufacturing process control (CADCAM) designed to create and harvest validated clinical data.

A significant amount of research has been carried out at Renishaw Plc into the veracity of impression and replicating materials where we have been able to compare the replicated models with the clinical geometry using Mitutoyo Coordinate Measuring Machinery (CMM) and Incise Contact Scanners calibrated to ISO 10360 Pt IV. A property that is not mentioned in the article, but which we found to be of very great significance, is the viscosity of the impression materials themselves and the design of the impression trays, which should be perforated. The best results were consistently within an error budget of 25 microns and this research has been reported in a Monograph.[1]

Now that we have the computerised tools to engineer dental prostheses and mill implant frameworks to fit within precise metrology limits, it would be beneficial for *BDJ* readers to see the scientific evidence in support of methods prescribed for taking accurate impressions and creating precise replica models for use in dentistry.

N. J. Knott
Chippenham

1. Knott N J. *A precise metrology comparison of dental impression materials.* Eschenburg: Kettenbach GmbH, 2010.

DOI: 10.1038/sj.bdj.2012.5

SUBPERIOSTEAL IMPLANTS

Sir, a 74-year-old patient was referred to the oral surgery department by her general dental practitioner. On consultation, the patient complained of a loose lower complete denture. She reported that she had undergone implant placement some 20 years previously in South Africa and that she had not attended for dental examination since.

Clinical and radiographic examination revealed a subperiosteal mandibular implant (Figs 1-2). The bar was firm and the patient reported that she was experiencing no pain. There were multiple mucosal dehiscences anteriorly and posteriorly, with the exposure of necrotic bone. There appeared to be some deposits of calculus associated with the abutments.

Radiographic examination showed a metal framework spanning the entire edentulous mandible. It sat approximately 2-2.5 mm above the alveolar ridge. Due to the smooth bony border and the even loss across the mandible, this is most likely to be due to continued resorption over time rather than pathological bone loss due to infection. The framework was secured to the bone by four retaining screws: two anteriorly and two posteriorly. The mandible itself was atrophic, with radiolucencies evident around the two anterior retaining screws.

Complete subperiosteal implant placement was first described as a treatment for the atrophic mandible in the 1940s. A mucoperiosteal flap would be raised to allow an impression to be made of the surface of the mandible. CT scans were also used to allow CAD/CAM fabrication of the framework, negating the need for impressions. The framework usually rests on the mandible, with no penetration into the bone.

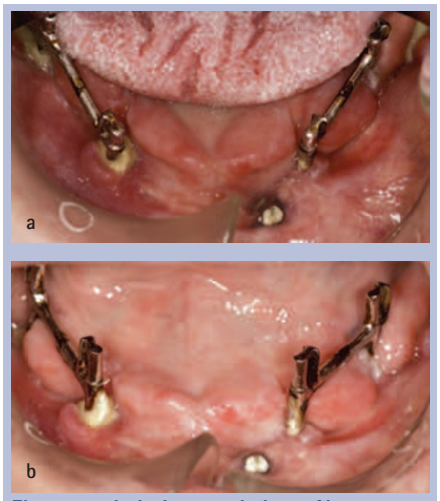

Figs 1a and 1b Intraoral views. Note dehiscences with bone exposure posteriorly, exposure of a screw in the lower left anterior region and calculus deposits around the posts

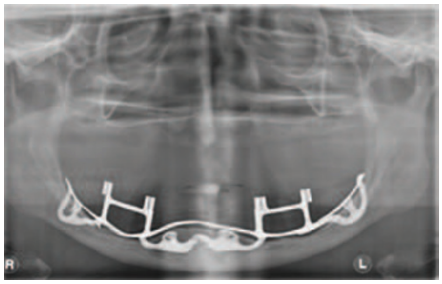

Fig. 2 Radiographic view showing mandibular full arch subperiosteal implant, with anterior and posterior retaining screws. Note radiolucencies adjacent to the anterior screws. The generalised lack of close fit to bony surface is likely related to continued ridge resorption

Due to the high success rates in atrophic mandibles of osseointegrated implants facilitated by the placement of autogenous grafts, subperiosteal implants are no longer used. However, as this case highlights, there may still be some *in situ* which could present to the general dental practitioner.

H. Beddis, S. Lello, J. Cunliffe, P. Coulthard
Manchester

DOI: 10.1038/sj.bdj.2012.6

SUGAR-COATED DENTISTRY

Sir, I could not stop myself writing in for the first time to express myself about the annual BDTA meeting at Birmingham NEC last year.