

Oro-antral fistulae and fractured tuberosities

G. Bell¹

IN BRIEF

- Most oro-antral fistulae and tuberosity fractures are predictable and avoidable.
- Simple modification of surgical technique will reduce the incidence of complications.
- Antral communications should be treated promptly to avoid a fistula and chronic sinusitis.
- It is very unlikely that an established oroantral fistula will close spontaneously.
- Displaced roots should be removed from the maxillary sinus as soon as possible.

This paper, in discussing oro-antral fistulae and fractured tuberosities, aims to guide the dentist through the assessment and reduction of risk when removing maxillary molar teeth that are closely related to the maxillary sinus. However, complications are inevitable and the management of these will also be discussed.

INTRODUCTION

Most maxillary molar teeth are not related to the maxillary sinus and may be removed without difficulty or complication. However, individual anatomical variation exists and dentists will encounter patients where not just the maxillary molars but also premolars and very occasionally canines are closely related to the maxillary sinus.¹ There are specific features of the clinical and radiographic assessment that will alert the dentist to the increased risk of either a fractured tuberosity or antral communication if exodontia were to proceed with standard forceps removal.

PATIENT ASSESSMENT

When treating a patient there are many factors in relation to human disease to be taken into consideration in determining if the patient will be able to cope with the proposed treatment. Equally, the dentist in assessing the general health of the patient has to decide if they have the experience or practice facilities to provide an acceptable level of care.² It is not the aim of this paper to present a summary of the management of human disease and interested readers are directed to a more authoritative text.³

There may be local anatomical factors that will increase the difficulty of surgery or the risk of complications when removing a posterior maxillary tooth (Table 1). Enlargement of the maxillary sinus through the natural process of pneumatization is possibly the most common localised anatomical feature that dentists will have to assess. The assessment of the sinus in relation to the teeth is very subjective and will be influenced by the operator's experience and ability. Figure 1 outlines particular features of radiographic assessment to guide the practitioner. As a general guide, an oro-antral communication is unlikely unless the maxillary sinus floor extends beyond one quarter of the length of the roots of the teeth, or between the roots of adjacent teeth. However, radiographic assessment alone does have some limitations.⁴

The thickness of the buccal plate of bone is of particular importance as it is that portion of bone that has to expand to allow lateral movement of the tooth using standard forceps removal. There will be significant anatomical variation in the thickness and density of the buccal plate and the flexibility of bone, and dentists should be particularly aware in older patients with multi-rooted teeth or divergent roots of the risk of either fracture of the tooth rather than buccal plate expansion, or a traumatic fracture of the buccal plate including the antral floor and lateral wall.

The lone standing molar tooth in the presence of a large sinus is a feature that all dentists will be aware of, as the risk

Table 1 Anatomical factors that may influence difficulty during removal of posterior maxillary teeth

Enlarged maxillary sinus
Lone standing maxillary premolar or molar tooth
Bone volume especially thickness of buccal plate
Unerupted, impacted third molar, lying apical and distal to second molar
Mesio-distal space loss in case of grossly carious tooth
Heavily restored tooth
Fused teeth (conrescence)
Hypercementosis
Multi-rooted teeth
Divergent roots

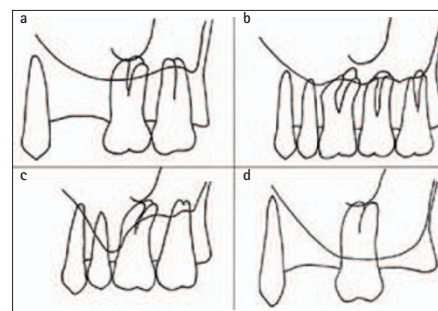


Fig. 1 Diagrammatic illustration of variation in maxillary sinus morphology in relation to adjacent teeth. Images a and b do not show a close relation between the teeth and the sinus but c and d do

of tuberosity or sinus floor and lateral wall fracture is increased. However, the presence of an unerupted, impacted third molar, particularly when the adjacent second molar is to be removed, increases the risk not only of a tuberosity fracture but

¹Maxillofacial Associate Specialist, Dumfries & Galloway Royal Infirmary, Dumfries, DG1 4AP
^{*}Correspondence to: Dr Garmon Bell
Email: garmon.bell@nhs.net

Refereed Paper
Accepted 10 June 2011
DOI: 10.1038/sj.bdj.2011.620
©British Dental Journal 2011; 211: 119-123

also exposure or tear of the maxillary sinus lining (Fig. 2).

Hypercementosis and conrescence are uncommon but well acknowledged abnormalities of maxillary molar morphology and dentists will be able to identify this on radiographs.⁵ Pre-operative radiographs should be regarded as mandatory before the removal of any posterior maxillary tooth as failure to have such may result in the dentist not having been able to make a full pre-operative assessment of risk.²

SURGICAL REMOVAL

The majority of maxillary molar teeth to be removed will not be related to the maxillary sinus or pre-dispose to maxillary tuberosity fracture and can be safely removed by the general dentist in their own practice.

Once the practitioner has decided that they are competent in removal of a tooth that is intimately related to the maxillary sinus the emphasis will be on provision of care such that damage to the oral soft tissues, alveolus or maxillary sinus lining is minimised.² This will usually require a modification of surgical technique away from that of a simple forceps removal.

To minimise force on the alveolus and adjacent maxillary sinus floor and lateral wall during removal of the tooth it is helpful to raise a two sided buccal flap, followed by removal of buccal bone, with or without division of the tooth or roots. Dentists who remove teeth without a buccal flap and subsequently fracture the alveolus and cause a tear of the buccal tissues will experience difficulty should it be necessary to advance a flap to close any sinus communication. Designing the buccal flap as one would for an advancement flap avoids unnecessary change to technique at a later stage. Care should be taken when dividing the roots or removing bone with a bur in an effort to avoid drilling through and perforating the sinus floor. Division of the tooth including the roots may be necessary when there has been mesio-distal space loss or if the roots are divergent. Simple modification of surgical technique in this way will reduce

the force required to elevate the tooth and minimise the risk of fracture of the lateral wall or floor of the maxillary sinus with exposure of the lining.

An important aspect of surgical technique when a tooth is closely related to the maxillary sinus is the need to avoid use of an elevator or luxator in the vertical plane along the axis of the root. Use of an elevator in this way particularly with excessive force may inadvertently displace a root or tooth into the maxillary sinus. Elevators are best used at an angle perpendicular to the long axis of the tooth with downward rotational force only.

If following removal of the tooth the maxillary sinus lining is exposed the decision must be taken as to whether or not primary soft tissue closure is necessary to protect the sinus lining (Fig. 3). If the lining is exposed over an area of more than a few square millimetres then primary epithelial closure will be necessary to avoid herniation through into the oral cavity or formation of a fistula and subsequent contamination of the sinus with oral microorganisms and food debris (Fig. 4). Attempts to simply drag the soft tissues over an extraction site without performing a formal buccal advancement flap using sutures with excessive tension will result in failure, and further soft tissue trauma complicating accurate repair at a later date. If a dental practitioner unexpectedly exposes the sinus lining during exodontia and is unable to perform a buccal advancement flap referral is indicated. However, in practice, small sinus lining exposures will occur without the dentist or patient ever being aware and healing occur without complication. If the exposure of lining is at the apex of a deep socket with stable bone walls, and the coagulum is not displaced or breaks down, then it may not be necessary to make arrangements for complete soft tissue closure but to simply inform the patient, give advice on post-operative care and review as necessary.

If the sinus lining has been torn during the removal of the tooth then primary soft tissue closure is mandatory (Fig. 5). It has been recognised for many years that some small oro-antral communications will heal without the formation of a fistula or chronic sinusitis.⁶ However, this will depend upon many factors including the health of the patient and their oral soft

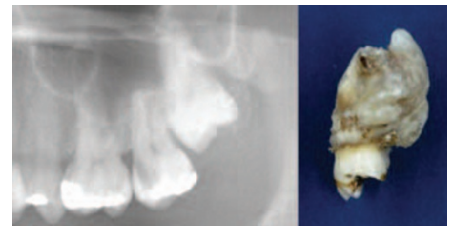


Fig. 2 Radiograph showing unerupted third molar adjacent to a carious second molar. The specimen demonstrated (not same clinical case) includes a second and third molar along with the tuberosity and maxillary sinus floor

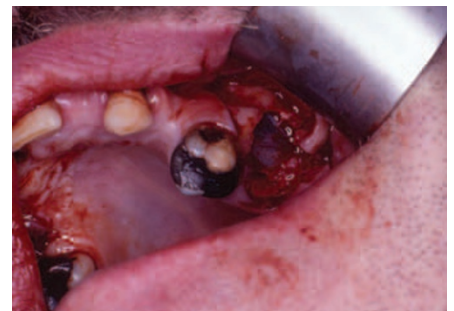

Fig. 3 Exposed but intact and healthy maxillary sinus lining after elevation of UL7 tooth

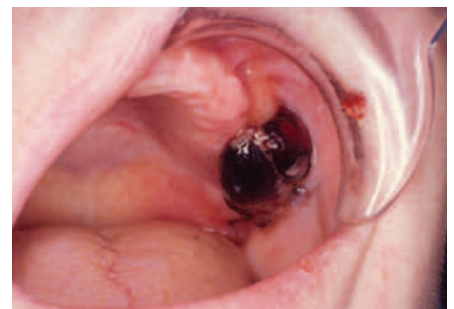

Fig. 4 Herniation of maxillary sinus lining through UL6 extraction site

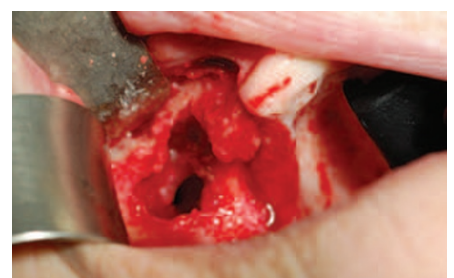

Fig. 5 Obvious oro-antral communication with torn sinus lining following removal of odontome from right maxillary alveolus

tissues, the presence or absence of pre-existing infection, the dimensions of the tooth socket and the post-operative care provided by the patient. However, many surgeons will electively close any antral communication at the time of surgery in an effort to avoid later complications.

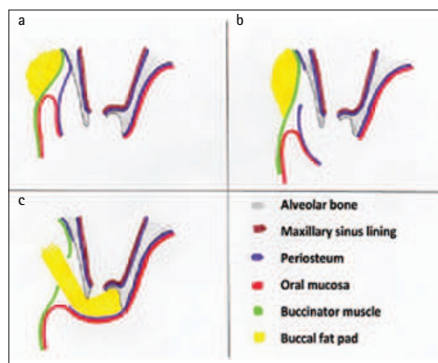


Fig. 6 Diagrams from a through to c illustrating stages and technique of release of inelastic periosteum for buccal advancement flap closure, along with mobilisation of buccal fat pad in image c. Note the increased length of flap provided by release of periosteum, but also the loss of buccal sulcus depth in images b and c

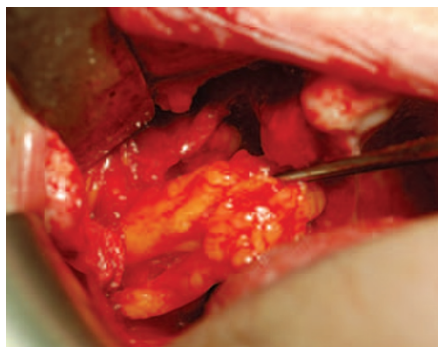


Fig. 7 Dissection and advancement of buccal fat pad to facilitate closure of oro-antral communication with buccal advancement mucosal flap on right side

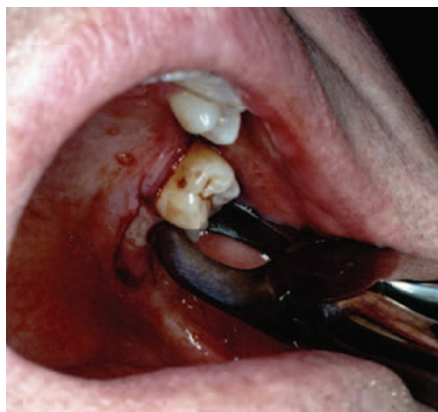

Fig. 8 Tear of palatal mucosa during elevation of UL7 tooth that resulted in a tuberosity fracture

Many general practitioners will not routinely inspect maxillary molar extraction sockets for potential antral communications on the basis that they are not anticipating such. If direct inspection of the socket with fine tipped suction is not possible then placing a standard broad

suction device over the socket will produce a change in noise if an antral communication exists as air rushes from one air space through a narrow opening into another. The sound resembles that heard when wind passes through a narrow opening or window. Alternatively a loose portion of sterile gauze may be placed in the extraction site and the patient asked to exhale through the nose with the dentist pinching the nostrils and observing if the gauze is displaced as air is diverted and passes from the maxillary sinus into the oral cavity. However, this latter technique while useful in confirming the presence of an established fistula does risk tearing the intact but exposed sinus lining, and for that reason most specialists would not advocate it immediately after extraction.

To obtain primary epithelial closure, if it has not already been performed a two sided buccal flap is raised. The inelastic periosteum is identified and divided with a scalpel along the whole width of the base of the flap (Fig. 6). Often two horizontal and parallel cuts along the flap are necessary to gain enough release of the soft tissues to allow a tension free closure that is supported on bone. Care should be taken that only the periosteum is divided and not the whole thickness of the mucosal flap. Once the soft tissues are gently approximated various styles of suturing and materials may be employed but the emphasis is on obtaining isolation of the maxillary sinus from the oral cavity. Occasionally, particularly if one has been too vigorous when releasing the periosteum troublesome post-operative bleeding can occur from the buccal space tissues. Patients will often experience this as an epistaxis a few hours after surgery rather than the bleeding presenting in the oral cavity, as the blood passes into the sinus and then into the nasal cavity via the ostium. If this does not stop with patient rest then exploration of the wound to obtain haemostasis will be necessary.

Buccal fat pad pedicle flaps may be used when larger antral communications exist and generally work best when a two layer technique of closure is used with the advanced buccal fat then being overlaid with a standard buccal advancement mucosal flap⁷ (Fig. 7).

MAXILLARY TUBEROSITY FRACTURE

Fracture and loss of the maxillary tuberosity not only risks exposure and tearing of the maxillary sinus lining but also changes the shape of the alveolus such that subsequent prosthodontic management may be difficult. The identification of risk factors for maxillary tuberosity fracture such as outlined in Table 1 along with the modified surgical technique described above should minimise complications. A tear of the palatal mucosa adjacent to the molar being elevated is usually a sign of tuberosity fracture, and an indicator for the dentist to stop, and if possible discuss the matter with the patient, and if indicated refer (Fig. 8).

However, tuberosity fractures will occur and the dentist's dilemma is: how best to manage the problem? Possibly the best way to consider the treatment approach is to determine the reason for the extraction, and the mobility of the hard and soft tissues, and the size of the fracture.

If the patient was in acute pain then it is possibly best to continue with the removal of the tooth and portion of bone on the basis that the volume of bone is not excessive, as relief of pain will benefit the patient. However, to remove excessive soft tissue and bone en-bloc is inappropriate and specialist referral is indicated rather than continuing.⁸

If the patient was asymptomatic and the tooth being removed electively then there is possibly a strong case for stopping the procedure, and delaying the removal of the tooth, until the bone has had an opportunity to heal when an elective surgical approach can be undertaken. Unless the tooth and tuberosity are particularly mobile it is possibly reasonable to attend to the patient's need for analgesia and oral care and make an appropriate referral. In cases where there is excessive mobility of the fragment that would cause the patient discomfort then splinting should be provided and the choice of this will depend on the dentist and their patient, and the presence and condition of adjacent teeth.

DISPLACEMENT OF TEETH AND ROOTS INTO THE MAXILLARY SINUS

Despite preventative measures teeth or their roots may be inadvertently displaced into the maxillary sinus. If it is not possible

to immediately retrieve the tooth or root through the extraction site and provide primary epithelial closure then referral is mandatory. Displaced teeth may act as foci of infection within the sinus and should in most circumstances be removed. The patient must be immediately informed of any such event.

Teeth may be removed through the extraction site or alternatively by a high labial antrostomy (Fig. 9). This later surgical approach has the disadvantage of causing post-operative parasthesia of the maxillary teeth and soft tissues on the affected side along with facial swelling.⁹ In an effort to avoid this it is also possible for foreign bodies to be removed from the maxillary sinus in conjunction with Ear Nose and Throat (ENT) colleagues using fibre-optic devices through the middle meatus, although formal closure of the oral communication into the sinus will still be required.¹⁰

POSTOPERATIVE CARE

When any surgical dental procedure has been performed that has involved the maxillary sinus lining, it is important that optimal conditions are provided for healing. In the absence of established acute infection there is no indication for post-operative antibiotics although the patient may benefit from a single dose at or just before surgery.¹¹ Chlorhexidine or a saline based mouthwash preparation will facilitate in the shifting of superficial debris and limit bacterial overgrowth. Of importance is the avoidance of any change in air pressure between the oral and nasal cavities including sinus air space. Abstinence of certain actions will facilitate this (Table 2).

Most patients that have had a dental surgical procedure performed involving the maxillary sinus will require follow-up at an appropriate interval to review the healing process.

THE NON-HEALING SOCKET

There will be cases where despite adequate surgical care the extraction site will not heal and the possible causes are outlined in Table 3. It is not the intention of this paper to discuss maxillary sinus disease including malignancy as this has been covered in a recent article in this journal.¹² However, when a patient presents with a non-healing extraction site in the maxillary molar area referral to an appropriate specialist is

recommended to facilitate accurate diagnosis and appropriate care. If there is a high index of suspicion for malignant disease then the referral should be highlighted as urgent, and to a secondary care unit.

When a patient presents with an established oro-antral fistula there is almost certainly established chronic maxillary sinus infection of bacterial origin and treatment will involve the excision and closure of the fistula along with irrigation of the maxillary sinus. In a small number of occasions this will not resolve the problem as the oral soft tissues will not heal because of persistent sinus infection. Once it has been confirmed that there is no other disease process taking place restoration of maxillary sinus lining function may be facilitated with surgery to the middle meatus by ENT colleagues.¹³ Repeated attempts at repair of only the oral aspect of an oro-antral fistula without consideration of the health or function of the sinus lining are inappropriate. Dental professionals should be aware that the diameter of the soft tissue defect in an oro-antral fistula is only a fraction of the size of the bone defect (Fig. 10). While some very small oro-antral communications will close spontaneously following exodontia, a significant proportion will not, particularly when a fistula has become established, and referral for excision and closure should not be delayed on the basis that the fistula may close spontaneously as this will only exacerbate maxillary sinus infection.¹⁴

CONCLUSION

Despite the identification of clinical or radiographic features that will increase the risk of an oro-antral communication or tuberosity fracture there will be many dentists that will safely remove teeth without complication. Some of the recommendations in this paper should therefore be regarded not as prescriptive but rather facilitative.

The instruments and equipment necessary to perform an elective surgical removal of a maxillary tooth that is closely related to the maxillary sinus are possibly already within the armamentarium of most practices. However, because of insufficient exposure to surgery of this nature some dentists may choose to refer to a specialist.

Detailed management of oro-antral fistulas and sinus infection, including

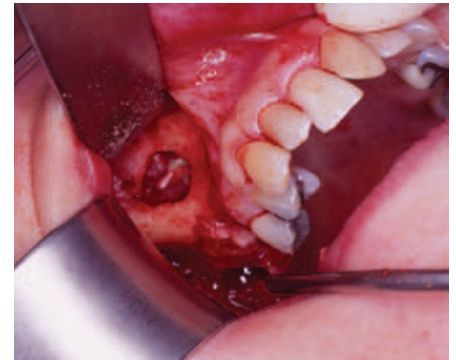

Fig. 9 High labial antrostomy for removal of a displaced tooth fragment. Note the inflamed, thickened sinus lining as compared to Figure 3

Table 2 Actions to be avoided after dental surgery involving the maxillary sinus

Nose blowing
Pinching nostrils during sneezing
Sucking liquid through a straw
Blowing up balloons or any inflatable device using exhaled air

Table 3 Possible causes of a non-healing maxillary extraction site

Oro-antral fistula
Infected granulation tissue
Foreign body response to suture or socket dressing material
Residual cyst
Maxillary sinus malignancy
Oral mucosal malignancy
Intra-osseous malignancy
Osteochemonecrosis (includes bisphosphonate related osteonecrosis)
Osteoradionecrosis (where previous radiation field will have included alveolus)
Osteomyelitis
Infective maxillary sinus disease (bacterial and fungal)

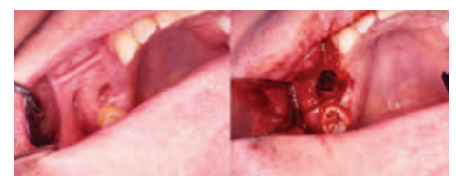


Fig. 10 Photographs taken during excision and closure of an oroantral fistula demonstrating the size of the bone defect as compared to the fistulous tract

malignancy, have not been covered in this paper as this is more the remit of the specialist and described more accurately in specialist books and journals.¹⁵⁻¹⁷

1. Eberhardt J A, Torabinejad M, Christiansen E L. A computed tomographic study of the distances between the maxillary sinus floor and the apices of the maxillary posterior teeth. *Oral Surg Oral Med Oral Pathol* 1992; **73**: 345–346.
2. Henderson S J. Risk management in clinical practice. Part 11. Oral surgery. *Br Dent J* 2011; **210**: 17–23.
3. Scully C. *Medical problems in dentistry*, 6th ed. Churchill Livingstone Elsevier Ltd, 2010.
4. Nedbalski T R, Laskin D M. Use of panoramic radiography to predict possible maxillary sinus membrane perforation during dental extraction. *Quintessence Int* 2008; **39**: 661–664.
5. Sugiyama M, Ogawa I, Suei Y, Tohmori H, Hiqashikawa K, Kamata N. Concrescence of teeth: cemental union between the crown of an impacted tooth and the roots of an erupted tooth. *J Oral Pathol Med* 2007; **36**: 60–62.
6. Awang M N. Closure of oroantral fistula. *Int J Oral Maxillofac Surg* 1988; **17**: 110–115.
7. Abuabara A, Cortez A L V, Passeri L A, de Moraes M, Moreira R W. Evaluation of different treatments for oroantral/oronasal communications: experience of 112 cases. *Int J Oral Maxillofac Surg* 2006; **35**: 155–158.
8. Shah N, Bridgman J B. An extraction complicated by lateral and medial pterygoid tethering of a fractured maxillary tuberosity. *Br Dent J* 2005; **198**: 543–544.
9. Low W K. Complications of the Caldwell–Luc operation and how to avoid them. *Aust NZ J Surg* 1995; **65**: 582–584.
10. Chandrasena F, Singh A, Visavadia B G. Removal of a root from the maxillary sinus using functional endoscopic sinus surgery. *Br J Oral Maxillofac Surg* 2010; **48**: 558–559.
11. Lawler B, Sambrook P J, Goss A N. Antibiotic prophylaxis for dentoalveolar surgery: is it indicated? *Aust Dent J* 2005; **50**: S54–S59.
12. Bell G W, Joshi B B, Macleod R I. Maxillary sinus disease: diagnosis and treatment. *Br Dent J* 2011; **210**: 113–118.
13. Khalil H, Nunez D A. Functional endoscopic sinus surgery for chronic rhinosinusitis. *Cochrane Database Syst Rev* 2006; **3**: CD004458.
14. Ehrl P A. Oroantral communication: epicritical study of 175 patients, with special concern to secondary operative closure. *Int J Oral Surg* 1980; **9**: 351–358.
15. Schaefer S D. *Rhinology and sinus disease: a problem-oriented approach*. St Louis: Mosby, 1998.
16. Katzenmeyer K, Pou A. *Neoplasms of the nose and paranasal sinuses*. 7 June 2000. <http://www.otohns.net/default.asp?id=14054>.
17. Schow C. Odontogenic diseases of the maxillary sinus. In Peterson L J, Ellis E, Hupp J R, Tucker M R (eds) *Contemporary oral and maxillofacial surgery*. 4th ed. Ch 19. pp 417–433. St. Louis: Mosby, 2003.