

IN BRIEF

- The use and benefits of antimicrobial prophylaxis in third molar surgery is controversial and there are no definite recommendations on the role of prophylactic antibiotics.
- Medically compromised patients are a group which may benefit from antimicrobial use.
- Antibiotic administration is not without risks including anaphylaxis, development of resistant bacteria and unjustified medical costs.

Antibiotic prophylaxis and third molar surgery

M. V. Martin,¹ A. N. Kanatas² and P. Hardy³

The issue of prophylactic antibiotic therapy in third molar surgery is highly controversial. The current evidence questions the benefits of routine prophylactic antibiotic therapy which does not appear to overcome the risk of undesirable outcomes after third molar removal. In our opinion there is no justification for routine antibiotic prophylaxis for third molar surgery.

INTRODUCTION

Third molar surgery is one of the most commonly performed procedures in oral and maxillofacial units and in general practice.¹ Prophylactic antibiotic therapy is defined as 'the administration of any antimicrobial agent that prevents the development of disease';² the antibiotic must be present in the systemic circulation at a high level at the time of surgery and is usually given as one dose. Peterson³ set the following five principles (Table 1) of antibiotic prophylaxis:

- 1) The surgical procedure should have a significant risk of infection.
- 2) The correct antibiotic for the surgical procedure should be selected.
- 3) The antibiotic level must be high.
- 4) The timing of the antibiotic administration must be correct.
- 5) The shortest antibiotic exposure must be employed.

For best possible practice and patient care, all of the above criteria must be fulfilled. The use and benefits of antimicrobial prophylaxis in third molar surgery is controversial and there are still no definite recommendations on the role of prophylactic antibiotics.

Controversies surround the role of antibiotics in relation to removal of soft tissue, full or partial bony impacted third molar, optimal timing, dose, duration and route of administration. Here, we aim to present the current evidence and critically review the literature regarding the routine use of antibiotic therapy in the removal of third molars.

Complications after third molar surgery

Pain, swelling, and trismus are common, non-infection related complications of third molar surgery. Other complications may be associated with infection and include exposed necrotic bone, ulceration, soft tissue swelling and erythema, intraoral/extraoral sinus, localised / generalised lymphadenopathy (Table 2). Post-operative infection usually presents with dry socket and less commonly may manifest with severe fascial space involvement.⁴ Factors which appear to be associated with post-operative infection include full or partial bony impaction, rather than the routine extraction of teeth,⁵ and the presence of preoperative infection.⁶ The reported incidence of postoperative infection varies between 1–12.60%^{7–18} (Table 3) There was also variation in the reported rate of alveolar osteitis ranging from 1% to 6.3%.^{16,19–20}

Post-operative complications and prophylactic antibiotics

There is a considerable volume of evidence that advocates antibiotics for the prevention of infection following third molar surgery.^{13,21–26} Other articles do not specifically comment on infection rates but support the use of antibiotics on the basis

of reduced postoperative complications.²⁷ Improvement from trismus, reduction of pain and swelling with improved healing are outcomes that have been used to assess the success of antibiotics.^{28–30} Many workers recommend the use of prophylactic antibiotics for extractions, including third molar surgery, only when active infection is present at the time of surgery.^{31,32} But Barclay³³ compared the use of metronidazole versus a placebo involving non-acute pericoronitis patients in a randomised controlled study.

Development of pain and alveolar osteitis postoperatively were examined. No significant difference between the two groups was found. In a randomised, double-blind, placebo controlled clinical trial examining the prophylactic use of penicillin and tinidazole in third molar surgery Happonen *et al.*¹⁴ reported no advantages over the placebo after third molar surgery. Kazino *et al.*³⁴ compared the administration of metronidazole with a placebo and a homeopathic remedy. Parameters such as pain, swelling, trismus and wound healing were evaluated. Between these groups there was no significant difference up to the eighth day postoperatively. After the eighth day the patients receiving metronidazole demonstrated better wound healing and less pain and swelling compared with the other groups.

Many authors do not support the indiscriminate administration of antibiotics prophylactically since the incidence of postoperative infections is too low to justify such action.^{11,20} Goldberg *et al.*¹⁰ in a series of 500 patients reported that antibiotic prophylaxis was not useful in preventing postoperative infection. Curran *et*

¹Senior Lecturer in Oral Microbiology, Department of Clinical Dental Sciences, University of Liverpool School of Dentistry; ²Hospital Practitioner in Oral and Maxillofacial Surgery, Liverpool University Dental Hospital; ³Consultant Oral Surgeon, Liverpool University Dental Hospital.

*Correspondence to: Dr Michael Martin, Department of Clinical Dental Sciences, University of Liverpool School of Dentistry, Daulby Street, L69 3GN
Email: m.v.martin@liverpool.ac.uk

Refereed Paper

Received 12.05.04; Accepted 09.06.04

doi: 10.1038/sj.bdj.4812170

© British Dental Journal 2005; 198: 327–330

Table 1 Criteria for antibiotic prophylaxis

- A strong link between surgical procedure and infection
- The appropriate antibiotic for the surgical procedure must be selected
- The antibiotic level must be high at the time of surgery
- The shortest effective antibiotic exposure must be employed

Table 2 Complications following third molar surgery that may be associated with infection

- Exposed necrotic bone
- Wound breakdown
- Soft tissue swelling and erythema
- Trismus
- Pain
- Intraoral and/or extraoral sinus
- Localised/generalised lymphadenopathy

*al.*⁹ also concluded that antibiotic prophylaxis was not useful for the prevention of postoperative infection. Mitchell¹³ also reported no significant difference between the incidence of infection in the study and placebo groups, although methodological discrepancies made the data difficult to interpret. Some laboratory markers of infection have been used to evaluate antibiotic prophylaxis for impacted third molars. Recently, Bulut *et al.*³⁵ measured the levels of C-reactive protein and alpha-1 antitrypsin pre-operatively and post-operatively in patients who received either prophylactic antibiotics or placebos. They concluded that antibiotic prophylaxis is not always indicated in patients who undergo surgery for the removal of third molars. Capuzzi *et al.*³⁶ compared postoperative amoxicillin for four days with no antibiotics in 146 patients and found no statistical difference when postoperative swelling and pain were evaluated. Monaco *et al.*³⁷ examined the incidence of dry socket and antibiotics; they reported no significant difference between the group receiving amoxicillin and the group with no administration of antibiotics. Prophylactic antibiotics given beyond the perioperative period in other forms of 'clean-contaminated' surgery provided no additional benefit.³⁴

In the most recent prospective, double blind, randomised, placebo-controlled clinical study Sekhar *et al.*³⁸ reported results from three patient groups. One hundred and fifty one patients who were to have lower wisdom teeth removed under local anaesthesia were included in that study. One group was given 1 g oral metronidazole one hour preoperatively; the second group was given 400 mg of oral metronidazole eight-hourly for five days

postoperatively and the third group was the placebo. Parameters such as pain, swelling, trismus between days 1 and 6 postoperatively, and state of the wound were evaluated. They reported no significant differences in the outcome between the three groups and concluded that antimicrobial prophylaxis did not seem to reduce morbidity after removal of third molars. The results in a study by Yoshii *et al.*³⁹ suggested that 1-day therapy with lenampicillin may at least be recommended as a prophylaxis for mandibular third molar surgery in medically healthy patients. However this study was unable to detect post-operative complications in patients with no antibiotic prophylaxis since such group was not included in the comparison.

Poeschl *et al.*⁴⁰ designed a prospective study involving three groups of patients requiring the removal of third molars. The patients in the first group received antibiotic treatment with amoxicillin/clavulanic acid as an oral medication carried out for five days postoperatively. In the second group clindamycin was used. In the third group, the patients received no antibiotic treatment. They concluded that the specific postoperative oral prophylactic antibiotic treatment after the removal of lower third molars did not contribute to a better wound healing, less pain, or increased mouth opening and could not prevent the cases of inflammatory problems after surgery, and therefore was not recommended for routine use.

Parenteral antibiotics, support for their use and timing

Parenteral therapy is indicated if the oral route is impractical and particularly for the urgent treatment of severe infections (fig 1). Considering the value of preoperative parenteral antibiotics, a body of evidence favours their use^{21-23,41} in third molar surgery. Extensive studies of third molar removal in patients with fully or partial bony infection of third molars favour the use of prophylactic parenteral antibiotics, since lower postoperative infection rates have been reported.⁵ Piecuch *et al.*⁵ in their study involving bony impacted third molars the use of preoperative parenteral antibiotics resulted in a significantly reduced post-operative infection rate. However, no advantage has been shown in soft tissue impaction alone.³⁷

The timing of parenteral antibiotic prophylactic administration appears to be important.^{17,37} When considering the analogy of surgical removal of third molars to 'clean-contaminated surgery' it is reasonable to assume that the optimal time for the administration of antibiotics is up to two hours preoperatively.^{36,42}

Thomas *et al.*⁴³ after an audit of antibiotic prescribing practises suggested that preoperative parenteral antibiotics are unwarranted for routine third molar surgery in medically fit patients. Support however was given to conclusions by others²⁹ about the use of parenteral and broad spectrum antibiotics in the management of medically compromised patients. In that study, however, the timing of parenteral antibiotic administration was not clear and this may explain their findings.

Antibiotic choice and dose and parenteral prophylaxis

Considering infections after the removal of third molars, the organisms most commonly isolated included streptococci, anaerobic gram-positive cocci and anaerobic gram-negative rods. For optimal prophylaxis the antibiotic agent used must have good bone penetrance, be active against the required micro-organisms and should be widely distributed in body fluids. Clindamycin has proven efficacy for treatment of bone / joint infections.⁴⁴ Clindamycin is a lincosamide antibiotic with a primarily bacteriostatic action against Gram-positive aerobes and a wide range of anaerobic bacteria. High concentrations may be weakly bacteriocidal against sensitive strains. Following parenteral administration clindamycin is widely distributed in body fluids and tissues including bone. When 600 mg are infused intravenously, peak concentrations of 10 µg ml⁻¹ are achieved by the end of the infusion.⁴⁵

Prophylactic antibiotics and systemic complications

Systemic antibiotic administration is the most common form of antibacterial prophylaxis in clinical practice.⁴⁵ Antibiotic administration is not without risks including anaphylaxis, development of resistant bacteria and unjustified medical costs.^{37,46} Other undesirable consequences include

Table 3 Infection rates for mandibular third molars reported in the literature

Investigator	Infections (%)
Hochwald <i>et al.</i> ⁷	1.0
Rud ⁸	4.0
Curran <i>et al.</i> ⁹	8.2
Goldberg <i>et al.</i> ¹⁰	4.2
Osborne <i>et al.</i> ¹¹	3.4
Sisk <i>et al.</i> ¹²	1.2
Mitchell <i>et al.</i> ¹³	11.0
Happonen <i>et al.</i> ¹⁴	11.8
Loucota ¹⁵	1-5.0
Chiapasco <i>et al.</i> ¹⁶	1.5
Piecuch <i>et al.</i> ¹⁷	3.5
Nordenram <i>et al.</i> ¹⁸	12.6

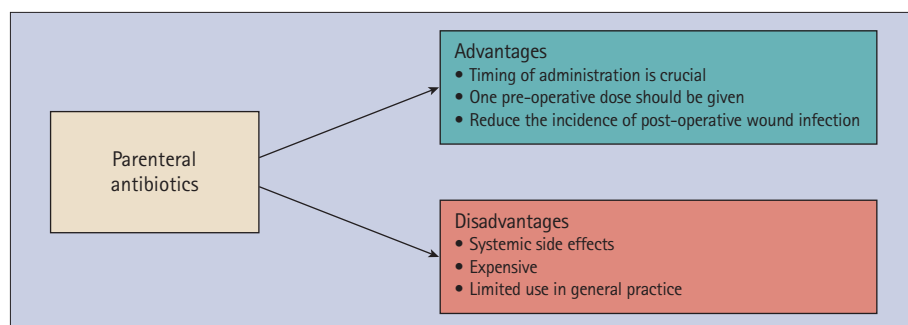


Fig. 1 Parenteral antibiotic prophylaxis

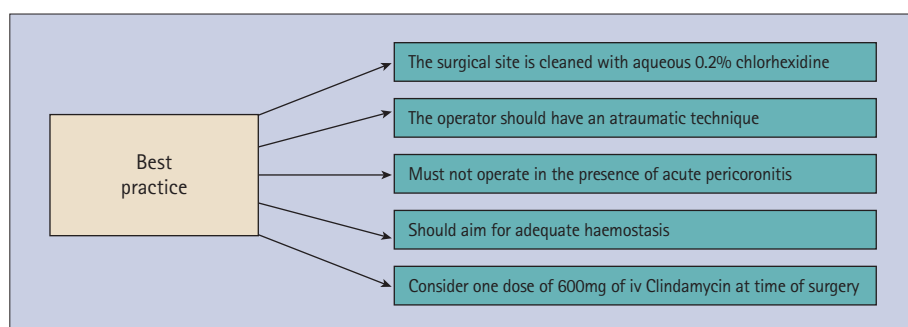


Fig. 2 Practical approach for the prevention of infection following third molar surgery

patients allergic to penicillin, 600 mg of oral clindamycin 1h pre-operatively should be used.

Practical approach for the prevention of postoperative infection for third molar surgery

Many reports in the literature have explored the efficacy of antibiotics in reducing post-operative pain, trismus and oedema. The results favour aspects such as an aseptic surgical site and an established technique aiming to minimise trauma.²⁰ In the oral cavity, patient and operation characteristics may influence the risk of a post-operative infection. Factors that increase the possibility of post-operative infection include age, nutritional status, diabetes, smoking, obesity, coexisting infections elsewhere in the body, colonisation with pathogens and a compromised immune response.⁵²⁻⁵⁴ Operational factors that may contribute to a post-operative infection include poor operative site preparation, duration of operation, foreign body in the surgical site, poor haemostasis, failure to obliterate dead space, extensive tissue trauma.⁵⁴ For best practice therefore we suggest that the surgical site is cleaned with aqueous 0.2% chlorhexidine. The operator should have an established technique, must not operate in the presence of acute pericoronitis and aim for minimal trauma and adequate haemostasis (Fig. 2). In the literature rare but serious complications of exodontias, such as a submasseteric abscess following the uneventful extraction of a non-infected maxillary third molar⁵⁵ may provide a case for prophylaxis. However we feel that such complications are so rare and may be prevented as suggested by the authors by careful injection of local anaesthetic with aspiration. It is important to emphasise that surgical antibiotic prophylaxis can be an adjunct to and not a substitute for a good surgical technique.

In our opinion

There is a plethora of studies that advocate or disapprove of the use of antibiotics in the removal of third molar surgery. Many have been criticised for methodological shortcomings, fuelling an ongoing controversy in antimicrobial use. Most of the studies focus on a potential relationship between antibiotics and post-operative complications and avoiding issues such as use of aseptic technique, and surgical procedure to minimise trauma. By evaluating the literature it appears that antibiotics may provide benefits in some instances and little or no benefit in others. Medically compromised patients are a group which may benefit from antimicrobial use. There

the interaction with other medical products and therefore an indirect effect in the management of other medical conditions. Direct toxicity may affect the gastrointestinal tract with nausea, vomiting, diarrhoea and abdominal pain. Haematological complications include neutropenia, thrombocytopenia and haemolysis. Alteration in the normal flora may result in candidiasis and pseudomembranous colitis. Antibiotic administration may result in nephrotoxicity with proteinuria and renal failure. The hepatobiliary tract may be affected with jaundice hepatitis and alteration in the liver function tests. Neuropathy -VIIITH nerve dysfunction and peripheral neuropathy may complicate antibiotic administration.

For best patient care the benefits and risks of antibiotic prophylaxis must be considered closely. The final decision regarding the administration of prophylactic antibiotics for an individual patient must depend on:⁴⁷ 1) the patient's risk of surgical site infection 2) the severity of complications of surgical site infection 3) the effectiveness of prophylaxis in that operation 4) the consequences of prophylaxis for the patient such as the increased risk of colitis.

Prophylactic antibiotics and the patient with a history of radiotherapy

Patients with a history of previous radiotherapy for head and neck cancer are at risk of developing osteoradionecrosis (ORN) following even 'simple' extractions

or biopsies that overlie bone.⁴⁸ Although the role of infection in the development of ORN has been brought into question in recent years most publications concerning exodontia following radiotherapy favour their use. The most appropriate antimicrobial regime is controversial and in a recent survey of oral and maxillofacial consultants in this country⁴⁹ there was a wide variation in practice. Most supported pre-operative antimicrobial use for the surgical removal of lower posterior teeth and 89% included a post-operative course. A wide range of bacteria may be isolated in the oral cavity and may be involved in infection under suitable conditions. The microbial involvement in the pathogenesis of ORN has not been fully elucidated. Scanning electromicroscopy of the bacterial colonisation in specimens obtained during head and neck resections⁵⁰ implicated oral streptococci including *Strep. intermedius*, *Strep. constellatus*, *Strep. oralis*, *Strep. mitis*, *Strep. sanguis*, *Strep. salivarius*. Facultative enteric bacteria including *Enterococcus*, *Escherichia*, and *Klebsiella* were also isolated. Others included *Staphylococcus epidermidis*, *Neisseria species*, *Capnocytophaga*, *Peptostreptococcus species*, *Gemella morbillorum* as well as *Fusobacterium nucleatum*. Taking into account the above a broad spectrum antibiotic should provide adequate prophylaxis in the patient at risk of ORN. Recent recommendations⁵¹ suggested that a single dose of either 3 g oral amoxicillin or in those

appears to be very little clinical gain by the administration of a postoperative oral antibiotic alone. When contemplating the surgical removal of bone-impacted third molars, one dose of parenteral prophylactic antibiotics at induction may be considered. However there is no advantage in patients where bone removal is not required. Taking into account the above finding, there is no justification for the routine use of prophylactic antimicrobials in third molar surgery and therefore it cannot be recommended.

1. Thomas D W, Smith A T, Walker R, Shepherd J P. The provision of oral and maxillofacial surgery services in England and Wales 1984–1991. *Br Dent J* 1994; **176**: 215–219.
2. Mums C A, Playfair, J H L; Roitt, I M, Wakelin D, Williams S R. *Medical Microbiology*, 2nd edn, pp. 32–35, Mosby, St Louis, 1998.
3. Peterson L J. Antibiotic prophylaxis against wound infections in oral and maxillofacial surgery. *J Oral Maxillofac Surg* 1990; **48**: 617.
4. MacGregor A J. Aetiology of dry socket. *Br J Oral Surg* 1968; **6**: 49–58.
5. Piecuch J F, Arzadon J, Lieblich S E. Prophylactic antibiotics for third molar surgery. *J Oral Maxillofac Surg* 1995; **53**: 53–60.
6. MacGregor A J, Hart P. Effect of bacteria and other factors on pain and swelling after removal of ectopic mandibular third molars. *J Oral Surg* 1969; **27**: 175–179.
7. Hochwald D A, Davies W H, Martinoff J. Modified distolingual splitting technique for removal of impacted mandibular third molars: incidence of postoperative sequelae. *Oral Surg Oral Med Oral Pathol* 1983; **56**: 9–11.
8. Rud J. The split bone technique for removal of impacted mandibular third molars. *J Oral Surg* 1970; **28**: 416.
9. Curran J B, Kenneth S, Young A R. An assessment of the use of prophylactic antibiotics in third molar surgery. *Int J Oral Surg* 1974; **3**: 1.
10. Goldberg M H, Nemarich A N, Marco W P. Complications after mandibular third molar surgery: a statistical analysis of 500 consecutive procedures in private practice. *J Am Dent Assoc* 1985; **111**: 277–279.
11. Osborn T P, Frederickson G J, Small I A, Torgerson T S. A prospective study of complications related to mandibular third molar surgery. *J Oral Maxillofac Surg* 1985; **43**: 767–769.
12. Sisk A L, Hammer W B, Shelton D W, Joy E D. Complications following removal of impacted third molars: the role of experience of the surgeon. *J Oral Maxillofac Surg* 1986; **44**: 855–859.
13. Mitchell D A. A controlled clinical trial of prophylactic tinidazole for chemoprophylaxis in third molar surgery. *Br Dent J* 1986; **160**: 284.
14. Happonen R P, Nemarich A N, Marco W P. Comparison after mandibular third molar surgery: A statistical analysis of 500 consecutive procedures in private practice. *J Am Dent Assoc* 1990; **28**: 12.
15. Loukota R A. The incidence of infection after third molar removal. *Br J Oral Maxillofac Surg* 1994; **32**: 165–167.
16. Chiapasco M, Cicco L D, Marrone G. Side effects and complications associated with third molar surgery. *Oral Surg Oral Med Oral Path* 1993; **76**: 412.
17. Piecuch J F, Arzadon J, Lieblich S E. Prophylactic antibiotics for third molar surgery: a supportive opinion. *J Oral Maxillofac Surg* 1995; **53**: 53–60.
18. Nordenram A, Sydnes G, Odegaard J. Neomycin-bacitracin cones in impacted third molar sockets. *Int J Oral Surg* 1973; **2**: 279.
19. Van Gool V V, Ten Bosch J J, Boering G. Clinical consequence of complaints and complications after removal of the mandibular third molar. *Int J Oral Surg* 1977; **6**: 29.
20. Zeitler D L. Prophylactic antibiotics for third molar surgery: A dissenting opinion. *J Oral Maxillofac Surg* 1995; **53**: 61–66.
21. Burke J F. The effective period of preventive antibiotic action in experimental incisions and dermal lesions. *Surg* 1961; **50**: 161–168.
22. Polk Jr H C, Lopez-Mayor J F. Postoperative wound infection: a prospective study of determinant factors and prevention. *Surg* 1969; **66**: 97–103.
23. Shapiro M, Shimon D, Freund U, Sacks T. A decisive period in the antibiotic prophylaxis of cutaneous lesions caused by *Bacteroids fragilis* in guinea pigs. *J Infect Dis* 1980; **141**: 532.
24. Hall H D, Bildman B S, Hand C D. Prevention of dry socket with local application of tetracycline. *J Oral Surg* 1971; **29**: 35.
25. Swanson A E. A double-blind study on the effectiveness of tetracycline in reducing the incidence of fibrinolytic alveolitis. *J Oral Maxillofac Surg* 1989; **47**: 165.
26. Nordenram A, Sydnes G, Odegaard J. Neomycin-bacitracin cones in impacted third molar sockets. *Int J Oral Surg* 1973; **2**: 279.
27. MacGregor A J. Anti-prophylactic antibiotics. *J Oral Surg* 1976; **34**: 1063.
28. Hellem S, Nordenram A. Prevention of postoperative symptoms by general antibiotic treatment and local bandage in removal of mandibular third molars. *Int J Oral Surg* 1973; **2**: 273.
29. MacGregor A J, Addy A. Value of penicillin in the prevention of pain, swelling and trismus following the removal of ectopic mandibular third molars. *Int J Oral Surg* 1980; **9**: 66.
30. Bystedt H, von Konow L, Nord C E. A comparison of the effect of phenoxymethylpenicillin and azidoicillin on post-operative complications after surgical removal of impacted mandibular third molars. *Swed Dent J* 1981; **5**: 225.
31. Marciani R. Antibiotics for head and neck infections. In Peterson L J (ed) *Principles of Oral and Maxillofacial Surgery*. pp 206–207. Philadelphia: Lippincott, 1992.
32. Alling C A. Impacted teeth. In Hardin J (ed) *Clark's clinical dentistry*. pp 11. Philadelphia: Lippincott, 1993.
33. Barclay J K. Metronidazole and dry socket: Prophylactic use in mandibular third molar removal complicated by non-acute pericoronitis. *NZ Dent J* 1987; **83**: 71.
34. Kazino G S N. Metronidazole (Flagyl) and arnica Montana in the prevention of postsurgical complications, a comparative placebo controlled clinical trial. *Br J Oral Maxillofac Surg* 1984; **22**: 42.
35. Bulut E, Bulut S, Etican I, Koseoglu O. The value of routine antibiotic prophylaxis in mandibular third molar surgery: acute-phase protein levels as indicators of infection. *J Oral Sci* 2001; **43**: 117–122.
36. Capuzzi P, Montebugnoli L, Vaccaro M A. Extraction of impacted third molars: A longitudinal prospective study. *Oral Surg* 1994; **77**: 341.
37. Monaco G, Staffolani C, Gatto M R, Checchi L. Antibiotic therapy in impacted third molar surgery. *Eur J Oral Sci* 1999; **107**: 437–441.
38. Sekhar C H, Narayanan V, Baig M F. Role of antimicrobials in third molar surgery: prospective, double blind, randomized, placebo-controlled clinical study. *Br J Oral Maxillofac Surg* 2001; **39**: 134–137.
39. Yoshii T, Hamamoto Y, Muraoka S, Furudo S, Komori T. Differences in postoperative morbidity rates, including infection and dry socket, and differences in the healing process after mandibular third molar surgery in patients receiving 1-day or 3-day prophylaxis with lenampicillin. *J Infect Chemother* 2002; **8**: 87–93.
40. Poeschl P W, Eckel D, Poeschl E. Postoperative prophylactic antibiotic treatment in third molar surgery – a necessity? *J Oral Maxillofac Surg* 2004; **62**: 3–8.
41. Worrall S F. Antibiotic prescribing in third molar surgery. *Br J Oral Maxillofac Surg* 1998; **36**: 74–76.
42. Classen D C, Evans R S, Pestotnik S L, Horn S D, Menlove R L, Burke J P. The timing of prophylactic administration of antibiotics and the risk of surgical-wound infection. *N Engl J Med* 1992; **326**: 281–286.
43. Thomas D W, Hill C M. An audit of antibiotic prescribing in third molar surgery. *Br J Oral Maxillofac Surg* 1997; **35**: 126–128.
44. Long M P, Patterson M J, Murray D L, Kumar A. Cluster causes of septic arthritis caused by *Streptococcus Pneumoniae* in the era of penicillin resistance. *Int Paediatr* 2000; **15**: 170–173.
45. *ABPI compendium of data sheets and summaries of product characteristics*. p 1180. Datapharm Publications Limited. 1999–2000.
46. Stone H H, Haney B B, Kolb L D, Geheber C E, Hooper C A. Prophylactic and preventive antibiotic therapy: timing, duration and economics. *Ann Surg* 1979; **189**: 691–699.
47. Scottish Intercollegiate Guidelines Network, SIGN. *Antibiotic prophylaxis in surgery. A national clinical guideline*. London: Royal College of Physicians, 2000.
48. Clayman L. Clinical controversies in oral and maxillofacial surgery: Part two. Management of dental extractions in irradiated jaws: a protocol without hyperbaric oxygen therapy. *J Oral Maxillofac Surg* 1997; **55**: 275–281.
49. Kanatas A N, Rogers S N, Martin M V. A survey of antibiotic prescribing by maxillofacial consultants for dental extractions following radiotherapy to the oral cavity. *Br Dent J* 2002; **192**: 157–160.
50. Sakamoto H, Naito H, Ohta Y, Tanakna R, Maeda N, Sasaki J, Nord C A. Isolation of bacteria from cervical lymph nodes on patients with oral cancer. *Arch Oral Biol* 1999; **44**: 789–793.
51. Martin M V, Longman L P, Palmer N A O. *Adult antimicrobial prescribing in primary dental care for general dental practitioners*. London: Faculty of General Dental Practitioners (UK), 2000.
52. SHEA, APIC, CDS, SIS. Consensus paper on the surveillance of surgical wound infections. *Infect Control Hosp Epidemiol* 1992; **13**: 599–605.
53. Cruse P J. Surgical wound infection. In Wonsiewicz M J. (ed.) *Infectious diseases*. pp 758–764. Philadelphia: W.B Saunders, 1992.
54. Mangram A J, Horan T C, Pearson M I, Silver L C, Jarris W R. Guidelines for prevention of surgical site infection. *Infect Control Hosp Epidemiol* 1999; **20**: 247–280.
55. Gallagher J, Marley J. Infratemporal and submasseteric infection following extraction of a non-infected maxillary third molar. *Br Dent J* 2003; **194**: 307–309.