

current scenario in relation to MI use and its effects on oral health.¹¹ As such, we reiterate the fragility of the findings of the published review and suggest that future reviews on the subject follow eligibility criteria for study inclusion in order to obtain more reliable conclusions about MI in general dental practice.

B. Carriconde Colvara, C. Stein, D. Demétrio Faustino-Silva, R. Soares Rech, Porto Alegre - RS, Brazil

- Jönsson B, Öhrn K, Oscarson N, Lindberg P. The effectiveness of an individually tailored oral health educational programme on oral hygiene behaviour in patients with periodontal disease: A blinded randomized controlled clinical trial (one-year follow-up). *J Clin Periodontol* 2009; **36**: 1025–1034.
- Jönsson B, Öhrn K, Lindberg P, Oscarson N. Evaluation of an individually tailored oral health educational programme on periodontal health. *J Clin Periodontol* 2010; **37**: 912–919.
- Jönsson B, Öhrn K, Lindberg P, Oscarson N. Cost-effectiveness of an individually tailored oral health educational programme based on cognitive behavioural strategies in non-surgical periodontal treatment. *J Clin Periodontol* 2012; **39**: 659–665.
- Kakudate N, Morita M, Sugai M, Kawanami M. Systematic cognitive behavioral approach for oral hygiene instruction: A short-term study. *Patient Educ Couns* 2009; **74**: 191–196.
- Miller W R. Motivational interviewing with problem drinkers. *Behav Psychother* 1983; **11**: 147–172.
- Halvari A E M, Halvari H, Bjornebekk G, Deci E L. Self-determined motivational predictors of increases in dental behaviors, decreases in dental plaque, and improvement in oral health: a randomized clinical trial. *Health Psychol* 2012; **31**: 777–788.
- Clarkson J E, Young L, Ramsay C R, Bonner B C, Bonetti D. How to influence patient oral hygiene behavior effectively. *J Dent Res* 2009; **88**: 933–937.
- Fjellström M, Yakob M, Söder B. A modified cognitive behavioural model as a method to improve adherence to oral hygiene instructions—a pilot study. *Int J Dent Hyg* 2010; **8**: 178–182.
- Kasila K, Poskiparta M, Kettunen T, Pietilä I. Oral health counselling in changing schoolchildren's oral hygiene habits: A qualitative study. *Community Dent Oral Epidemiol* 2006; **34**: 419–428.
- Miller W R, Rollnick S. Ten things that motivational interviewing is not. *Behav Cogn Psychother* 2009; **37**: 129–140.
- Gao X, Lo E C M, Kot S C C, Chan K C W. Motivational interviewing in improving oral health: a systematic review of randomized controlled trials. *J Periodontol* 2013; **85**: 426–437.

DOI: 10.1038/sj.bdj.2017.844

Health policy

Hospital cutbacks

Sir, I read with interest the letter from R. S. Randhawa *et al.*¹ which highlighted the neglect of dental care on hospital wards.

Back in the 1970s I was employed as an in-patient dental officer at Guy's Hospital where my duties were to look after the dental care of hospital in-patients. A large part of my work included pre-operative assessment and treatment of cardiothoracic patients and dealing with dental emergencies when they arose, not just at Guy's but the associated hospitals and care homes in the Guy's group. I had a standalone surgery in the main

hospital and a dental nurse to assist me.

Informal seminars were also given to nurses about the importance of the oral health of patients in their care.²

Unfortunately, the job eventually fell victim to one of the early cutbacks in NHS funding in the 1980s. This was a short-sighted expediency and resulted in a lost opportunity to improve patient care at a relatively low cost.

Perhaps it is time to revisit this aspect of holistic care so aptly raised by your correspondent.

G. Feaver, London

- Randhawa R S, Chandan J S, Thomas T. Oral health: Dental neglect on wards. *Br Dent J* 2017; **223**: 238.
- Feaver G P. The dental care of cardiothoracic and radiotherapy patients. *Nursing Mirror* 1977.

DOI: 10.1038/sj.bdj.2017.845

Oral surgery

The drug holiday

Sir, we read with interest *Aggressive denosumab-related jaw necrosis – a case series.*¹ It highlighted the contentious role of the drug holiday in the treatment of MRONJ in patients taking denosumab.

It is a clinical challenge to determine the risks *versus* benefits of stopping denosumab for dental treatment in patients with metastatic disease.

Denosumab-related osteonecrosis of jaw is rare. In some cases it can cause significant morbidity.¹ According to the literature, skeletal related events (SREs) such as pathologic fractures and spinal cord compression in patients with metastatic disease are common and reduce quality of life.² In our clinical experience some patients have been placed on a pre-emptive denosumab drug holiday by their oncologists to presumably reduce the risk of MRONJ if they require dental extraction. The evidence for the efficacy of drug holidays is poor and it is not supported by published guidance.³

However, performing dental treatment before denosumab therapy has started is a recognised preventive approach.⁴ The skeletal complications of bone metastases are responsible for a range of complications and costs and decreased quality of life.² The role of denosumab in delaying SREs and thus maintaining quality of life is clear.

Therefore, by stopping denosumab temporarily we may be increasing the risk of SREs in these patients and ultimately reducing their longevity.

Therefore, is it prudent to stop this therapy at all? Are we at risk of losing focus holistically speaking? Further research and evidence-based guidance is needed to aid oncologists and dentists on the effects of drug holidays in patients with metastatic disease.

D. Shiels, A. Goodall, by email

- Badr M, Kyriakidou E, Atkins A, Harrison S. Aggressive denosumab-related jaw necrosis – a case series. *Br Dent J* 2017; **223**: 13–16.
- Clemons M, Gelmon K A, Pritchard K I, Paterson A H. Bone-targeted agents and skeletal-related events in breast cancer patients with bone metastases: the state of the art. *Curr Oncol* 2012; **19**: 259–268.
- Ruggiero S L, Dodson T B, Fantasia J *et al.* American Association of Oral and Maxillofacial Surgeons position paper on medication-related osteonecrosis of the jaw – 2014 update. *J Oral Maxillofac Surg* 2014; **72**: 1938–1956.
- Scottish Dental Clinical Effectiveness Programme. *Oral health management of patients at risk of medication related osteonecrosis of the jaw.* March 2017.

DOI: 10.1038/sj.bdj.2017.846

Dental radiography

Short roots

Sir, this radiograph (Fig. 1) was taken of a fit young man and we were both surprised to discover that all his teeth have such short roots. Trawling through books and Internet searches has provided no explanation and so I hope that one of your readers will be able to provide an explanation.

There are concerns that this could be an expression of some genetic problem as he has just got married and intends to have a family in a few years.

C. Marks, by email

DOI: 10.1038/sj.bdj.2017.847

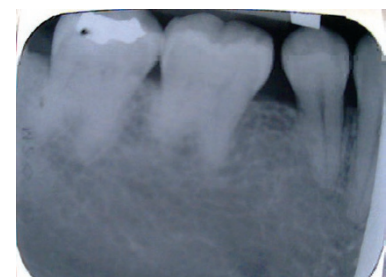


Fig. 1 Radiograph of a young adult male showing short roots

Erratum

Quick release mechanism

In the original version of the above letter (*Br Dent J* 2017; **223**: 237), only one author was given, N. Uppal.

The correct author listing should have been: M. Kumar, N. Uppal.

DOI: 10.1038/sj.bdj.2017.848