

longer to have their treatment due to only working every other week.

My overall experience through GPT has been extremely positive. I believe by completing GPT I have gained vast amounts of knowledge and experience in the hospital setting as well as carrying out my foundation training. It has allowed me to build a comprehensive portfolio and experience broader insight to more aspects of dentistry. The staff have been extremely supportive and ultimately provided a springboard for a career as a competent hospital dentist. I highly recommend GPT as an excellent route for new graduates who may be unsure if they want their careers in a hospital or practice setting.

G. Jones, by email

DOI: 10.1038/sj.bdj.2017.1005

## Oral health

### Ever increasing pressures

Sir, we read with interest the letter entitled *Oral health: Dental neglect on wards* (2017; 223: 238).

From our experience of oral health care of medical patients over the last 15 years, we would concur with the authors' main points that oral health is commonly neglected or not prioritised in an inpatient population. However, most clinicians working within busy NHS hospitals would agree that the neglect of oral health is not an isolated problem; it is simply part of the ever increasing pressures on clinical staff.<sup>1</sup>

The demand for hospital inpatients has only increased over the last 10 to 15 years.<sup>2</sup> With associated decreases in nursing and medical staff, inpatient care often feels as if it is buckling under the strain. It can be difficult to identify the healthcare professional looking after a particular ward patient and this may change regularly over a working day. It is not uncommon, on busy medical and surgical wards, to find basic inpatient requirements are not carried out in a timely fashion – such as routine observations, fluid management and mobility assessments.

We agree that oral healthcare is vital and particularly in older patients for the reasons the author commented on. However, if these trends continue, the importance of oral healthcare will simply fall by the wayside as the daily demands on healthcare professionals ever increases.

A. Cant, B. Collard, by email

1. Buchan J. Vacancies at all time high. *Nurs Stand* 2017; **32**: 28.
2. Hughes H, Churchill N. Speaking up in the NHS in England: the work of the National Guardian and NHS England. *Br J Gen Pract* 2017; **67**: 198–199.

DOI: 10.1038/sj.bdj.2017.1006

## Restorative dentistry

### An innovative handling approach

Sir, handling of small ceramic glazed restorations can always be troublesome to many practitioners due to their small size and slippery nature. Many times clinicians find themselves delivering an indirect restoration to the wrong quadrant under pressure especially with cements exhibiting a short working time. Handling of single or multiple ceramic restorations with fingers prior to seating can incur several problems as well. First, fiddling with the restoration using fingers may result in a slip away during seating. Second, during the surface treatment and particularly prior to silane application, debris present on the gloves could contaminate the high surface energy intaglio surface which is particularly critical after etching.<sup>1</sup> Third, during silane application, it is not uncommon for excess amount to spread and cover the glazed surface of the restoration due to silane's high wetting ability.<sup>2</sup> This is clearly evident when the restoration is treated on a napkin as the saline wets the napkin and the napkin in turn wets the glazed surface especially after air thinning. This is problematic since it complicates excess cement removal after

the cementation because of the affinity of the cement to the 'treated' glazed surface. Therefore, it is recommended to suspend the restoration in the air using a holder while performing salinisation. Commercially available sticks are not cost effective and their availability is limited in many countries. These sticks are also available in a single colour and therefore don't allow for colour coding restorations. Jogad *et al.* described using composite adapted to a microbrush as a holder for indirect restorations.<sup>3</sup> However, using composite for such purpose is non-environmental and is a waste of valuable material since the holder will be disposed after light curing. To overcome the previous difficulties, we propose a simple method to create custom holders for easy pick up and handling of ceramic restorations using tacky putty. This is demonstrated in Figs 1–4 by cutting the tip of the microbrush (Fig. 1), then adapting a piece of tacky putty to the microbrush with dry hands (Figs 2 and 3), and finally adapting the tacky putty to the dry glazed surface of the restoration (Fig. 4). The tacky putty could be removed by laterally peeling the holder after seating.

A. Abyad, Beirut, Lebanon

1. Jardel V, Degrange M, Picard B, Derrien G. Surface energy of etched ceramic. *Int J Prosthodont* 1999; **12**: 415–418.
2. Matinlinna P, Lassila V, Özcan M, Yli-Urpo A, Vallittu K. An introduction to silanes and their clinical applications in dentistry. *Int J Prosthodont* 2004; **17**: 155–164.
3. Jogad N, Patil P G, Gade V, Patil S. Alternative technique for handling indirect restorations during evaluation and cementation. *J Prosthet Dent* 2015; **114**: 458–459.

DOI: 10.1038/sj.bdj.2017.1007




Fig. 1 Cutting the tip of the microbrush



Fig. 2 Adapting a piece of tacky putty to the microbrush with dry hands




Fig. 3 Adapting a piece of tacky putty to the microbrush with dry hands

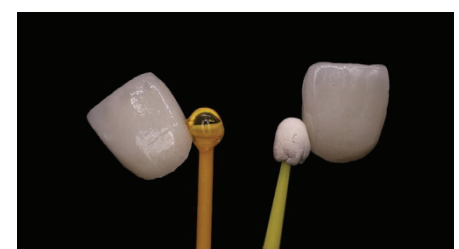

Fig. 4 Adapting the tacky putty to the dry glazed surface of the restoration