

patients with expertise on this topic. Currently, its interpretations remain at odds with pertinent stakeholders, including international guideline committees in Europe and the USA.

M. H. Thornhill, M. Dayer, P. B. Lockhart, M. McGurk, D. Shanson, B. Prendergast, J. B. Chambers, S. Jones, L. M. Baddour: Sheffield, Taunton, Charlotte NC USA, London, London, London, New York USA, Rochester MN USA.

1. Alderson P, Baker M. Prophylaxis guidelines: Repeated points. *Br Dent J* 2016; **220**: 324.
2. Alderson P, Baker M. Prophylaxis guidelines: Repeated points. *Br Dent J* 2016; **220**: 429.
3. Thornhill M H, Dayer M, Lockhart P B *et al*. Guidelines on prophylaxis to prevent endocarditis. *Br Dent J* 2016; **220**: 51-56.
4. Dayer M J, Jones S, Prendergast B, Baddour L M, Lockhart P B, Thornhill M H. Incidence of infective endocarditis in England, 2000-13: a secular trend, interrupted time-series analysis. *Lancet* 2015; **385**: 1219-1228.
5. Thornhill M H, Lockhart P B, Prendergast B, Chambers J B, Shanson D. NICE and antibiotic prophylaxis to prevent endocarditis. *Br Dent J* 2015; **218**: 619-621.
6. National Institute for Health and Care Excellence (NICE). Prophylaxis against infective endocarditis 2015 [NICE Clinical Guideline No 64]. Available at: <http://www.nice.org.uk/guidance/cg64/chapter/Recommendations>. DOI: 10.1038/sj.bdj.2016.470

Dental radiography

Embarrassing foreign objects

Sir, panoramic radiography (PR) is used worldwide for the screening of oral and maxillofacial diseases. One of the main considerations, before PR, is the removal of the patient's personal objects (piercings, glasses etc). To our knowledge, there are no studies that focus on this aspect, especially in private dental surgeries, and so we evaluated the presence of radiopaque objects in PR made by dentists.

All PR performed by dentists at the Dental Clinic of Brescia from 2005 to 2015 were evaluated to detect foreign objects. A total of 1,584 PR were reviewed by two calibrated clinicians, and in 43 cases (2.7%) radiopaque objects were detected: piercings (22 cases), earrings (14), glasses (7). These numbers are almost embarrassing. When metal jewellery is present during radiographic examination, it

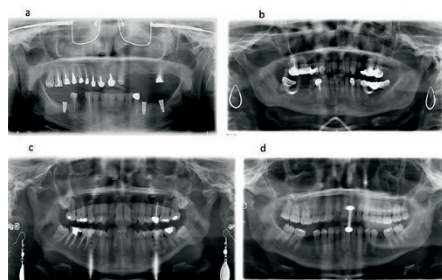


Fig. 1 Personal objects in panoramic radiographs: a) glasses b) earrings c) earrings d) lingual piercing

may prevent visualisation of normal anatomy and/or pathologic findings (Fig. 1). Dentists should be strongly advised to remove any objects in the head area and oral cavity from patients before X-ray exposure. Non-diagnostic images may lead to retakes, with an increase of the patient's ionising radiation exposure.

*G. Conti, Milan
E. Bardellini, F. Amadori, Brescia*
DOI: 10.1038/sj.bdj.2016.471

Anaesthesia

Pause for palsy

Sir, we wish to report an unusual case of facial nerve palsy. A 33-year-old female presented complaining of swelling on the left-hand side of her face which was visibly swollen over her cheek and tracked down to her submandibular region. Endodontic treatment had recently been carried out on tooth 25, but the tooth was asymptomatic prior to obturation and was asymptomatic on presentation.

Intra-orally, no sinus was evident, and teeth 34 and 38 were tender to percussion. There were heavy plaque deposits in the lower arch, and the gingivae appeared erythematous. It was felt that there may be a periodontal component to the patient's pain and swelling, so one cartridge of 2% lidocaine hydrochloride with 1:80,000 adrenaline was administered as an inferior dental block (IDB) using an aspirating syringe. Ultrasonic debridement was carried out on the lower arch and the patient was prescribed 500 mg amoxicillin and 200 mg metronidazole as local drainage was not possible. The patient was to be reviewed the next day, and advised to seek medical advice if the swelling became worse overnight.

The patient then presented to the local A&E department in the early hours of the morning with no toothache but left sided facial nerve weakness, pulsing facial pain and a sore throat, which started around 1-2 hours whilst at work, post-administration of the IDB. On clinical examination, there was no obvious swelling or cervical lymphadenopathy, but a clinically apparent dry left eye and left sided facial nerve weakness. Teeth 24 and 25 were slightly tender to percussion but no other abnormalities were detected. A diagnosis of left-sided facial nerve palsy was reached, and the patient was prescribed low dose oral steroids to take once a day for seven days and Xailin and Hylo-forte eye drops to use morning and night to prevent any eye dryness. She was advised to use

transpore tape and a patch to cover the affected eye. However, it was unclear if the patient's symptoms were due to the local anaesthetic she received at her dental appointment or due to an alternative coincidental cause. The patient's symptoms have now thankfully resolved.

Facial palsy following local anaesthetic administration has been reported to have an incidence between 1:42 and 1:750,000,¹ and can have several causes, including direct trauma, injection into a lobe of the parotid gland near where the facial nerve branches, neurotoxic effects of the local anaesthetic, and also type I (immediate) and type IV (delayed) hypersensitivity reactions, with the onset of facial nerve paralysis sometimes delayed for over two hours.

J. McKay, E. Ford, Inverness

1. Blair N F, Parratt J D E, Garsia R, Brazier D H, Cremer P D. Inflammatory trigeminal nerve and tract lesions associated with inferior alveolar nerve anaesthesia. *J Clin Neurosci* 2013; **20**: 1608-1610. DOI: 10.1038/sj.bdj.2016.472

Branches and sections

Here's to the future...

Sir, people are any organisation's most important asset; the future rests with those just setting foot on their career path. So it was with much pleasure that Yasmin Aydin stood and was duly elected as the Chair of Lancaster & Morecambe BDA Section. Already a qualified hygienist/therapist, Yasmin is studying at UCLAN's Morecambe Dental Education Centre. Since joining, Yas has sent a breath of air through the section; her pub quizzes have brought students and local dentists together in a whole new way.

Our section is also proud to be the home of the BDA's national President-elect. Peter Dyer has, throughout his career as a maxfac surgeon, been an active member of the BDA. Dental students locally know him for his gentle mentoring style and hospital-based junior dentists know him for his staunch support during the recent contract negotiations. There may even be some colleagues reading this who recall him being student president of the BDA (back in the same year that Prince Philip was the national BDA president). Peter's advocacy for those during the early stages of their careers has resulted in excellent engagement of young dentists in this area.

As a section, we would like to congratulate Yasmin and Peter on their recent appointments!

W. Thompson,

BDA Lancaster & Morecambe Section

DOI: 10.1038/sj.bdj.2016.473