Root perforations: aetiology, management strategies and outcomes. The hole truth

S. Mohammed Saed,*[1] M. P. Ashley[2] and J. Darcey[3]

VERIFIABLE CPD PAPER

IN BRIEF

- Explains the aetiology of root perforations.
- Reviews factors associated with the success of perforation repair.
- Discusses the management of perforations.
- Highlights prevention strategies for practitioners to follow.

PRACTICE

The purpose of this clinical article is to emphasise that root perforations can occur both during and after endodontic treatment. These reduce the chance of a successful treatment outcome and can jeopardise the survival of the tooth. The aetiology and diagnosis of root perforations are described. The article also focusses on the non-surgical and surgical management of root perforations and describes how selection of the appropriate treatment depends on an accurate diagnosis.

INTRODUCTION

A perforation is a communication that arises between the periodontium and the root canal space. Perforations can be pathological, resulting from caries or resorptive defects, but most commonly occur iatrogenically (during or after root canal treatment). Indeed, perforations occurring during root canal therapy may account for as many as 10% of all failed endodontic cases.[1]

AETIOLOGY

Iatrogenic perforations

Perforations of the coronal third:

Perforations of the coronal third often result whilst attempting to locate and open canals (Fig. 1). Calcifications of the pulp chamber and the orifices, misidentification of canals, significant crown-root angulations and excessive removal of coronal dentine can easily result in perforations in the coronal or furcation regions.

Perforations of the middle third:

Strip perforations of the middle third may occur if there is overzealous instrumentation in this region. Typically this will follow an aggressive crown-down approach with large instruments such as Gates Glidden burs, used in narrow canals. It may also occur during preparation of the canals, if files are too large or the filing technique shapes the

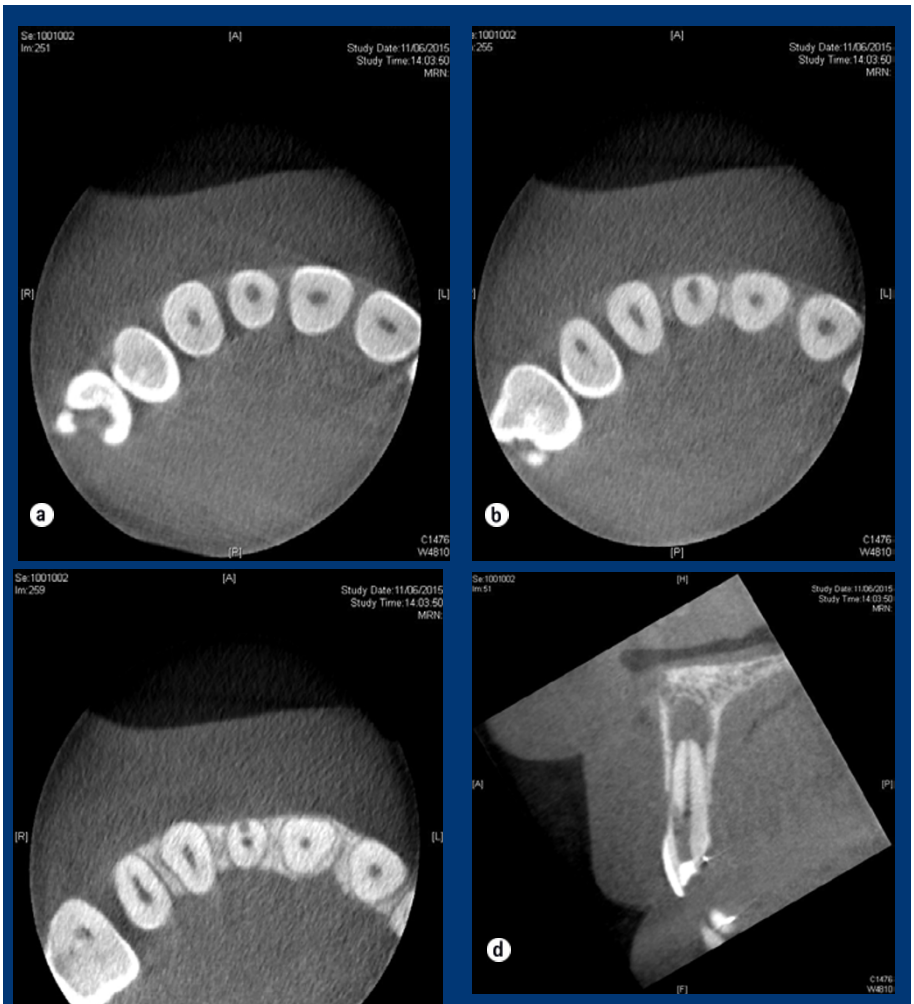

Fig. 1 In an attempt to locate the canal of the 12 the dentist has perforated through the buccal aspect of the tooth. The figures clearly demonstrate the divergence of the access cavity from the canal structure

[1]Dental Core Trainee, Oral and Maxillofacial surgery, Bradford Royal Infirmary; [2]Consultant and Honorary Senior Lecturer in Restorative Dentistry, Associate Clinical Head of Division, University Dental Hospital of Manchester, Higher Cambridge Street, Manchester, M15 6FH; [3]Consultant and Honorary Lecturer in Restorative Dentistry, University of Manchester
*Correspondence to: S. Mohammed Saed
Email: sarasaed1234@hotmail.co.uk

Refereed Paper
Accepted 15 January 2016
DOI: 10.1038/sj.bdj.2016.132

canals too aggressively away from the centre of the root. Classically, this occurs in curved molar roots when the instrumentation is too heavy on the inside curvature resulting in a furcational strip perforation (Figs 2a and 2b). Perforations of the middle third may also occur during the pursuit of sclerosed canals. In these instances the dentist may need to use rotary or ultrasonic instruments well into the root of the tooth risking lateral perforation.

Perforations of the apical third:

Inadequate cleaning and shaping of the canal can lead to blockages and ledges. Once formed, these can cause instruments to deviate, transporting the canal away from the centre of the root, until a perforation occurs. Stiff instruments placed into curved canals may also straighten the canal, causing zip perforations (Figs 3a and 3b). An apical perforation occurs when the clinician does not respect the apical anatomy and passes endodontic files too aggressively through the apical constriction (Fig. 4).

Post-space preparation:

Following obturation, careless post space preparation may result in perforation.[2] Traditional approaches to placement of post retained restorations focus on achieving good length and width for the post. This creates the risk of both apical and strip perforation. Sometimes the post is not placed into the root canal but the adjacent dentine, resulting in catastrophic consequences (Fig. 5).

Pathological perforations

These can result from root resorption or caries. Root resorption is the progressive loss of dentine and cementum by the continued action of osteoclastic cells.[3] When occurring within the root canal system it is known as internal inflammatory root resorption. It is seen radiographically as an oval shape enlargement of the root canal system. The exact cause is not known, but this process can follow trauma, pulpal inflammation and pulpotomy procedures. Though the process is uncommon and often self-limiting, it can progress into a perforation. Thus, early detection and intervention is essential to control the disease before such an event occurs.[4,5]

External inflammatory root resorption can occur following damage to the cementum and periodontal ligament cells on the root surface. There are different types of external resorption, but all have the potential to continue until the resorptive defect communicates with the root canal (Fig. 6). The ability to control the resorption is dependent upon the type, site and extent. Readers are referred to more comprehensive papers on the management of resorption.[4,5,6]

Extensive carious lesions can also lead to perforations. These lesions are defined by a destruction of dental tissues as a result of microbial action. An untreated carious lesion may either perforate the pulp chamber floor or extend along the root, resulting in perforation of the root. Treatment of these perforations may require root canal treatment, crown lengthening, and either root extrusion or root resection in order to retain valuable radicular segments. Unfortunately, perforation in most of these cases renders the tooth unrestorable.[7]

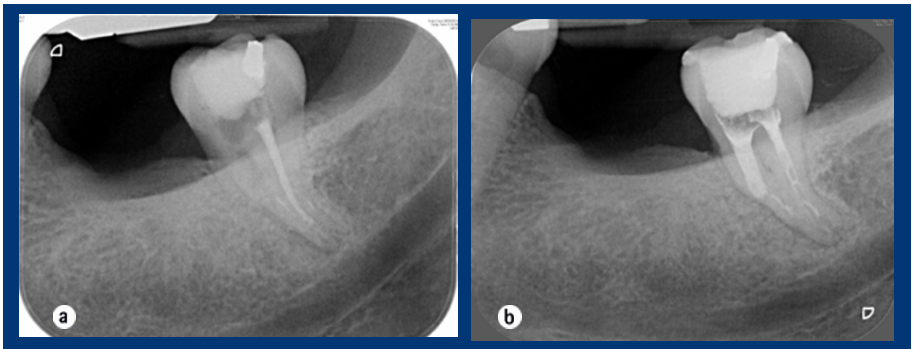

Fig. 2 Not only has an instrument fractured in the mesiobuccal canal of the 37 but there has been a perforation of the middle third of the tooth in an attempt to remove and/or bipass the instrument

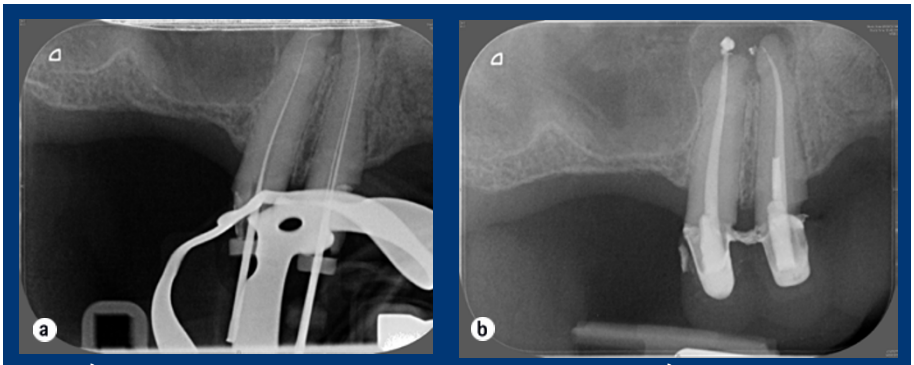

Fig. 3 a) There is an acute curve distally in the apical region of the 24. b) This has not been respected during instrumentation resulting in straightening of the canal and apical perforation

Fig. 4 A lack of control during the distal canal preparation of the 46 has resulted in over preparation and significant over extension of the gutta percha (as well as separation of an instrument in the mesial canal)

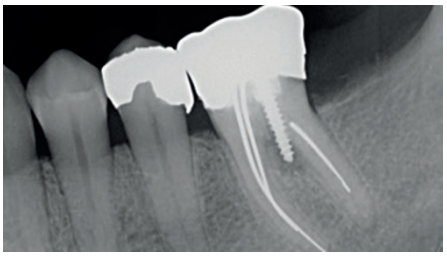

Fig. 5 It's a boy! A threaded post has been placed though the furcation

Fig. 6 External cervical resorption of the 13. The lesion has perforated into the pulp canal space

EPIDEMIOLOGY

The frequency of root perforations has been reported to range from 3% to as high as 10%.[1,8,9] However, as more complex endodontic treatment cases are being attempted, it is not an unrealistic expectation that there will be an increased frequency of perforations in the future.[1] According to Kvinnsland *et al.*,[2] 53% of iatrogenic perforations occur during insertion of posts, the remaining 47% occur during routine endodontic treatment. 73% of all cases occur in the maxilla and the rest in the mandibular arch. In maxillary anterior teeth the study found that all perforations were located at the labial root aspect due to the operator's underestimation of the palatal root inclination. In multi-rooted teeth, however, furcation perforations may occur whilst searching for the canal orifices, as dentine is removed from the pulpal floor.

DIAGNOSIS

Iatrogenic perforations are invariably identified from the profuse bleeding that follows the injury (Fig. 7). This can often be seen directly when a perforation occurs in the coronal portion of the tooth, but sometimes, when a strip or apical perforation occurs further within the canal, a paper point inserted into the canal reveals the bleeding. If no local anaesthetic is given, sudden unexpected pain during treatment may also indicate a perforation.

Apex locators are very useful in detecting perforations. By placing the file onto the perforation this will give a zero reading, indicating a communication with the periodontal ligament. Operating microscopes are becoming increasing popular in identifying perforations. The bright operating light and magnification make it excellent for visualising the position and extent of the perforation. Radiographs can be used at the time of perforation, but do have their limitations: they are only a two-dimensional representation and so it may be difficult to accurately assess the site and extent of the perforation. Taking a second film and shifting the radiographic beam angulation to the mesial or distal aspect can partly overcome this.

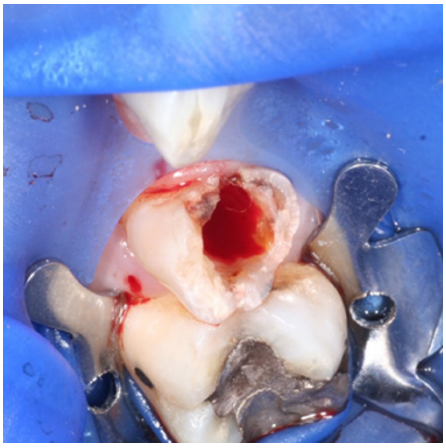

Fig. 7 Profuse bleeding resulting from a perforation during endodontic access of the 15

Late diagnosis of pathological perforations is largely a combination of clinical assessment, radiographs and the nature of the presenting complaint. Untreated perforations may be revealed by the presence of serous exudate or sinus from the site of perforation, sensitivity to percussion, localised periodontal pocketing and chronic inflammation of the gingiva when the inflammation has penetrated the alveolar bone.[10] In addition to the methods described above, radiographs may reveal radiolucent lesions that have developed since the perforation occurred, as there may be local osteolysis (Fig. 8).

Fig. 8 The post in the 45 perforates the mesial aspect of the root wall. A periodontal pocket has resulted from the chronic inflammation

Cone beam computed tomography is increasingly important in the assessment of perforations (Figs 9a-c). There is evidence that resorptive lesions and post perforations can be accurately identified and assessed using CBCT. These 3-dimensional scans are, however, associated with increased exposure to ionising radiation and as such, referral for CBCT must only be considered if it could change the clinical outcome.[11] The presence of pre-existing GP, posts and core restorative materials will create artefacts and both the referred patient and the practitioner must be aware that this may compromise the diagnostic yield.

Sequelae and outcomes

Following the initial acute inflammatory response there may follow destruction of periodontal fibres, bone resorption and the formation of granulomatous tissue. In the mid and apical portions of the root this may manifest as a radiolucency adjacent to the perforation. If this is in close proximity to the supra crestal attachment there may be proliferation of epithelium and, ultimately, the

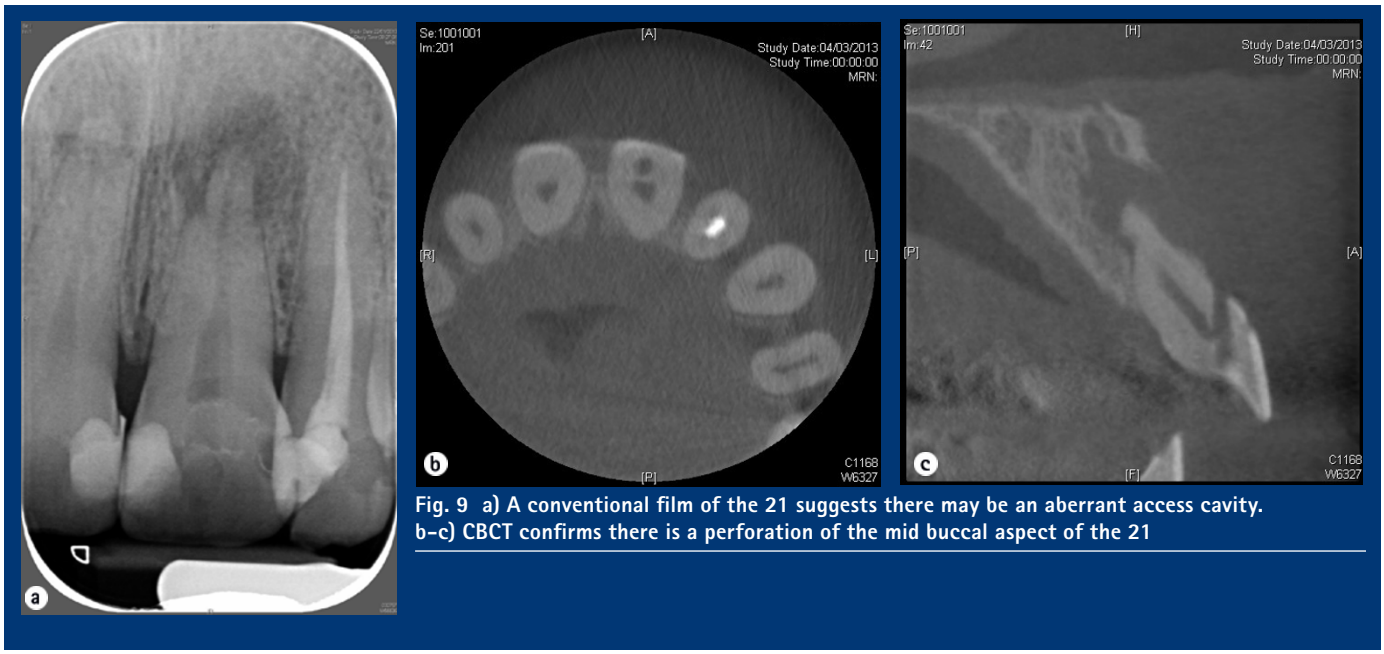

Fig. 9 a) A conventional film of the 21 suggests there may be an aberrant access cavity. b-c) CBCT confirms there is a perforation of the mid buccal aspect of the 21

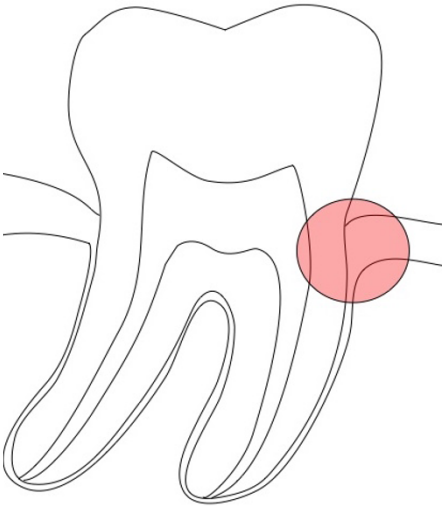

Fig. 10 The critical zone: a perforation into the gingival sulcus and the crestal attachment may have the most significant consequences as bacterial entry and pocket formation can quickly ensue. It is important to recognise the critical zone may not necessarily be at the CEJ but rather follows the biological width, thus if there is recession, the critical zone will be located more apically accordingly

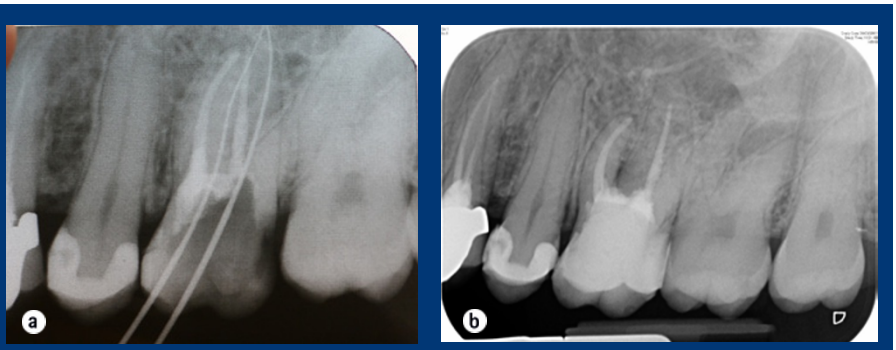

Fig. 11 a) In an attempt to locate the disto-buccal canal of the 26, there were multiple perforations of the pulp chamber floor. b) Upon re-entry the disto-buccal canal could not be located but the perforation was repaired with MTA. There was radiographic evidence of furcational bone loss. The tooth remained symptomatic and the tooth was removed

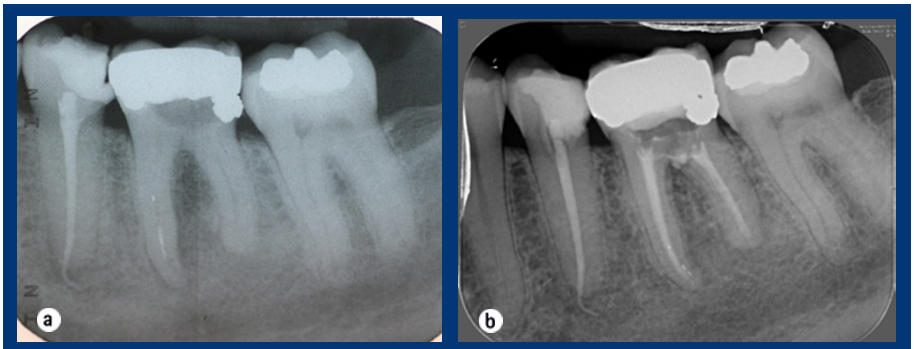

Fig. 12 In an attempt to locate the distobuccal canal of the 36 the operator perforated into the furcation. The perforation was immediately repaired with MTA and the RCT completed (to date) successfully

Table 1 The prognosis for success when considering site, size and time to repair of perforations

Prognosis	Site	Size	Time to repair
Favourable	Apical or supra-crestal	Small	Immediate
Unfavorable	Equi-crestal	Large	Delayed

formation of a periodontal pocket (Fig. 8).[8] If the perforation is not detected early and repaired, then the breakdown of the periodontium may ultimately lead to a loss of tooth. Though irreversible inflammation may not always result, if an irritating restoration is present or a microbial infection ensues, it is unlikely that healing will take place.[1] Indeed, it can significantly reduce the odds of success of root canal treatment by 56%, largely attributable to bacterial contamination during or after treatment.[12] Several key factors have been associated with the pathological sequelae and thus the prognosis of the tooth. These include the site of the perforation, the size of the perforation, the time to repair and, most recently, the material with which the repair is made (Table 1).[13]

Site

The position of the perforation relative to the level of the crestal bone and the epithelial attachment is critical when assessing prognosis. This is named the critical zone (Fig. 10). The worst prognosis lies when the perforation is within this critical zone. The close proximity to the gingival tissues can lead to the contamination of the perforation with bacteria from the oral cavity.[1] A periodontal defect will be created if there is apical migration of the epithelium into the perforation site.[14,15] This rapid pocket formation leads to the lowest success rate of repair.[2,16] If the perforation occurs in the furcation of multi-rooted teeth, then this can also be regarded in the critical zone due to its proximity to the epithelial attachment and the gingival sulcus (Figs 11a and 11b).[8,17,18]

Perforations that are coronal to the critical zone have a good prognosis. This is because they are easily accessible and an adequate seal with conventional materials is possible without periodontal involvement. If the canal is accessible and root canal treatment possible, perforations that are located apical to the critical zone also have a more favourable prognosis as they can be cleaned and sealed with a much lower risk of bacterial entry from the oral cavity and a chronic inflammatory lesion developing.[18,19]

Size

A small perforation is usually associated with less tissue destruction and inflammation. Therefore, healing is more predictable and has a better prognosis.[20] Smaller perforations are easier to seal effectively, preventing bacteria from reaching the peri-radicular tissues.[1]

Time

The time delay between the occurrence of the perforation and repair has been found to be an important factor in healing. The most favourable healing is found when the perforations are sealed immediately; thereby reducing the likelihood of an infection and chronic granulation tissue or periodontal pocket occurring (Figs 12a and 12b).[8,14,21]

Appropriate repair material

Historically, used repair materials are amalgam, zinc oxide – eugenol cement, calcium hydroxide, gutta percha, glass-ionomer cement, IRM, composite resin and SuperEBA cement. Best practice suggests that perforations should now be treated using a bioactive material such as mineral trioxide aggregate (MTA (ProRoot, Dentsply/Tulsa Dental, Tulsa, OK, USA)).[22] This material

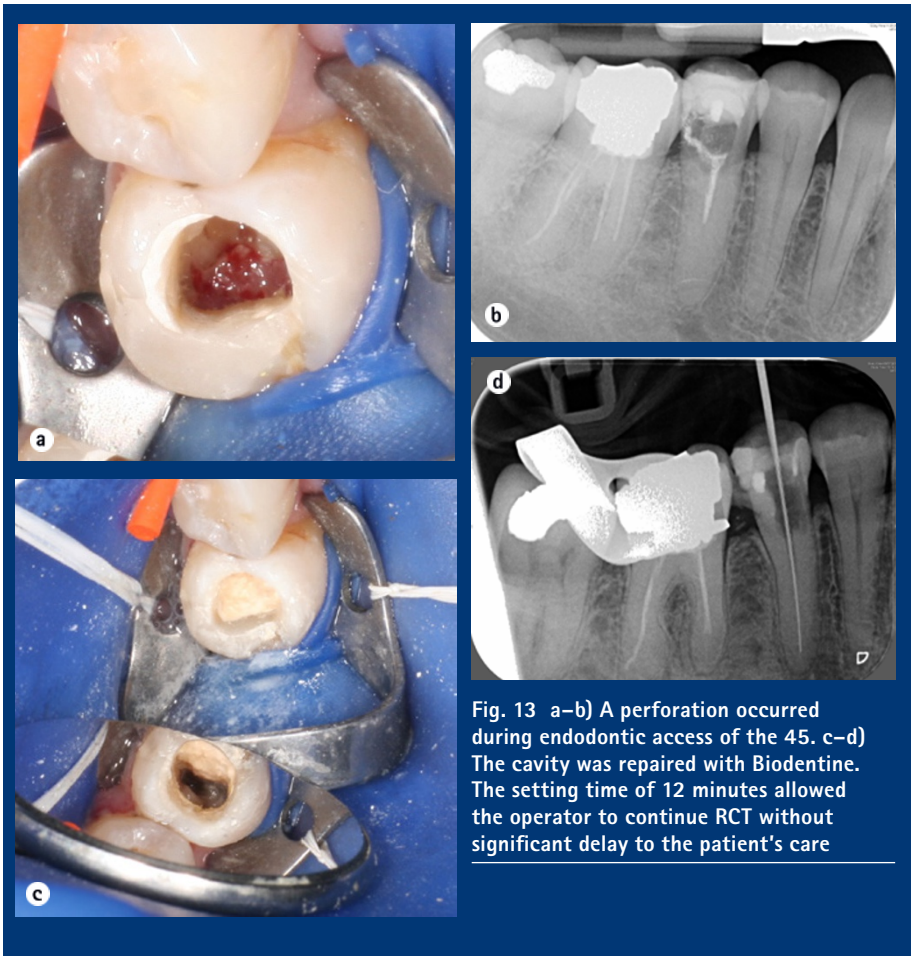

Fig. 13 a–b) A perforation occurred during endodontic access of the 45. c–d) The cavity was repaired with Biodentine. The setting time of 12 minutes allowed the operator to continue RCT without significant delay to the patient's care

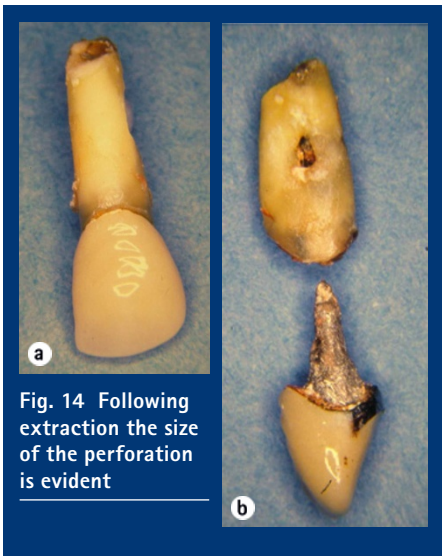

Fig. 14 Following extraction the size of the perforation is evident

consists of fine particles of tricalcium silicates, which are hydrophilic and set in the presence of moisture. It is biocompatible and promotes tissue repair and regeneration.[23] Either under or over filling a perforation defect with MTA does not appear to affect the ability to seal the root.[24] With most dental materials, the bond strength significantly reduces when it is contaminated with moisture, but MTA requires the presence of water when setting. Therefore, set MTA can acquire its optimal strength and produce excellent sealability in the inherently wet environment of the perforation.[25] Once placed, MTA is biocompatible and can result in new cementum formation and periodontal regeneration, despite its extrusion into periradicular tissues.[26,27]

There are however, disadvantages of using MTA:

- It is difficult to manipulate and handling requires both time and practice
- The setting time of around four hours may compromise the application. In supra-crestal cases the material may be washed out before it has set[28]
- Both grey and white MTA can discolour the tooth and therefore compromise aesthetics. This needs to be considered especially in the anterior region and with those patients who have a high lip line.

Newer similar materials such as Biodentine (Septodont) may overcome these handling problems: it is a calcium silicate with calcium chloride to speed the setting time. As such it can be prepared, placed and set within 12 minutes. (Figs 13a-d) Furthermore, it has improved handling ability with a consistency closer to IRM or Kalzinol facilitating placement. As yet there is however a paucity of data to support the use of such materials.[13,29,30]

MANAGEMENT

The aim of perforation management is regeneration of healthy periodontal tissues against the perforation without persistent inflammation or loss of periodontal attachment. If there is a case of periodontal breakdown, then the aim here is to re-establish tissue attachment.[26,31] Therefore, successful perforation repair depends on the ability to seal the perforation and re-establishing a healthy periodontal ligament.[8]

Clearly, irrespective of site, size or time to repair, if a tooth is symptomatic, treatment must be offered. There are only two options in this case: repair or extraction. The tooth must first be assessed for restorability. Extensive pathological perforations invariably render the tooth unrestorable. If the tooth is unrestorable or endodontic treatment deemed impossible to complete, the patient must be counselled upon the benefits of extraction and possible prosthodontic options. For some teeth, access to the perforation may be impossible without significant risk of collateral damage or risk of failure, therefore, extraction may be the only option (Figs 14a and b).

If the tooth is considered restorable, repair may be considered. An important factor to consider is good visibility as this is essential to see the damaged site. Access to an operating microscope is recommended.[13]

Non-surgical management of perforations

General principles:

If possible, root canal treatment and definitive obturation should be completed. If not, the canals should be protected with an easily removable material such as Cavit (3M ESPE, Seefeld, Germany), cotton wool, gutta percha or paper points. This prevents iatrogenic blockage of the canals with the reparative material.

One must then consider the time-lapse between the development of the perforation and the repair. If a non-contaminated perforation is repaired immediately then this prevents breakdown of the periodontal ligament. If the perforation has been long standing then it may be chronically infected. Any restorative material within the perforation defect should be removed (Figs 15a-c and 16a-c). The success of treatment for infected perforations depends on removing the contaminants and repairing under aseptic conditions.[32] If dentine must be removed then this can be done with burs or ultrasonic instruments under magnification. Ultrasonic tips are the preferred choice as they are least destructive to the adjacent tissues. Arens & Torabinejad[33] described further enlargement and cleaning of the infected

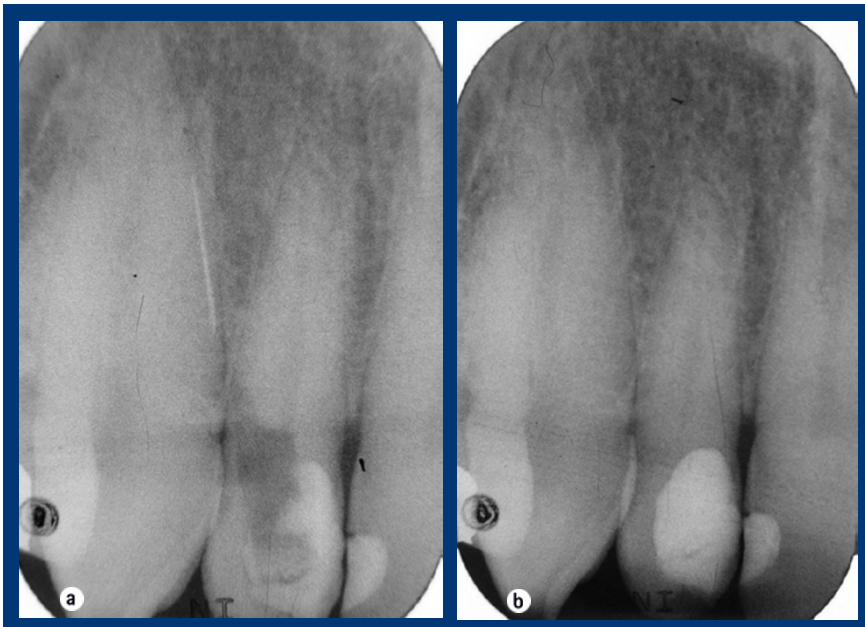



Fig. 15 Careless access with no consideration to the position of the root resulted in a distal perforation of the 12 distally. Furthermore an instrument separated during preparation. This was removed before conventional RCT and perforation repair was undertaken

perforation and the wound site with copious irrigation of 2.5% sodium hypochlorite before placement of the repair material. Sodium hypochlorite should be used with caution due to the increased risk of severe complications. Sterile water can be used if the operator is concerned about extrusion into peri-radicular tissues, but they must be aware this will not help decontaminate the site. Chlorhexidine may be a preferable alternative if the patient is not sensitised to this.

When the lesions are larger they can often present with hyperplastic and vascular granulation tissue, which then protrudes into the defect. This granulation tissue should be carefully curetted and removed. Endodontic excavators, probes and rose-head long shank burs may also aid the clinician in achieving a clean cavity, but can result in further profuse bleeding. Commonly used clotting agents such as ferric sulphate can cause irreversible damage to the delicate alveolar bone and delay healing, as such their use is not recommended.[34-36] It is preferable to achieve haemostasis using collagen, calcium sulphate or calcium hydroxide. If bleeding cannot be controlled it may be sensible to dress the tooth and provisionally fill the resorption defect with Cavit or non-setting calcium hydroxide and arrange a further appointment for the repair.

Controlling haemostasis and skillful placement of a restorative material is essential in achieving a seal. In cases of delayed repair there is invariably breakdown of the periodontal ligament and surrounding bone into which granulation tissue proliferates. Removal of such granulation tissue may therefore leave a bone cavity around the perforation site.[37] The operator must anticipate extrusion of repair material into this cavity. In the past, attempts have been made to control this and to increase the sealing ability of the repair materials with internal biocompatible barriers/matrices such as collagen or calcium sulphate (Fig. 17).[38-41] However, there is some evidence to suggest that an excellent success rate is achievable when MTA is used without a barrier.[20] Furthermore, when MTA was accidently extruded into the periradicular area, it was shown that hard tissue was deposited over the material with the presence of a healthy periodontium. All this confirms that MTA works favourably when it is extruded into the periradicular tissues. Thus, the use of barriers is not strictly necessary with calcium silicates such as MTA. If, however, there is a large cavity it may be worth considering placing a barrier to facilitate control of the material. Propriety cellulose materials used in surgical haemostasis control are inexpensive, easy to manipulate and ideal for this. Once placed, the MTA or other such material can be condensed against the barrier permitting improved control of the repair.

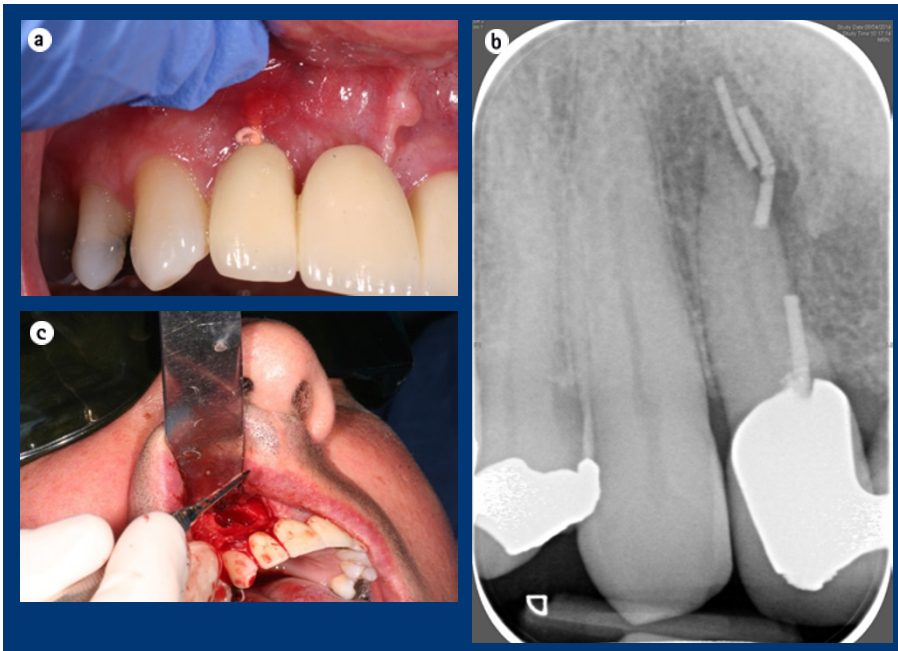

Fig. 16 a –b) The treating practitioner perforated through the mid buccal of of the 12. The root canal treatment was completed but the referring practitioner was completely unaware they were obturating the periodontal tissues. c) Orthograde root canal treatment was completed and the perforation repaired with composite as the defect was supra gingigval. The site was surgically explored to remove extruded GP. Note the significant bone loss around the apex of the 12

Coronal third perforations:

The location of the perforation will determine which access technique is used and how the perforation is sealed. Supracrestal perforations have no periodontal involvement as they communicate directly with the oral environment. Conventional restorative materials such as glass ionomer and composite may be used but care should be taken to ensure the margins of the repair are smooth externally and do not become a plaque-trap.

If feasible, MTA or equivalents should be used for those lesions in and just apical to the critical zone. The root canal treatment may be completed and the repair performed or, if the perforation is bleeding and impairing RCT, it may be sensible to repair the perforation before completing RCT (Fig. 18). MTA can be delivered to the perforation using micro-syringes such as the MTA MAPS System or Dogvan Carrier. Micro pluggers or micro spatulas can then be used to condense the material. Though ultrasonic instruments can be used to help 'slump' the material into the site and improve adaptation, it is in the authors' belief that this can irritate the tissues and result in unwanted bleeding.[13]

Once MTA is placed precisely, a paper point or cotton pledget can be used to remove the excess moisture, which further solidifies the material.[42] After placement is complete, a damp cotton pledget is placed on top allowing MTA to set, as it needs more moisture during setting. This protracted setting time dictates a delay in the placement of the final restoration. The recommendations vary from one day to one week.[33] Sluyk *et al.*[43] showed that at a time range of 72 h, the resistance to dislodgement improves significantly. During the next visit, it is recommended to check if the material is set and whether it has remained correctly positioned at the perforation site. Immediate adhesive reconstruction of the tooth provides less possibility for coronal leakage and strengthens the tooth. In the authors' opinion, when MTA is used it is not unreasonable to place a barrier of resin modified GIC over the MTA and restore the tooth immediately. If Biodentine is used, the restoration may be placed immediately onto the repair. Indeed it may be sensible to initially restore the whole tooth completely with Biodentine (Figs 19a and 19b).

Middle third perforations:

These are usually ovoid in shape and typically consist of a large surface area to seal.[32] Strip perforations are frequent problems in thin and concave roots.[44] These defects are almost impossible to repair in a truly controlled manner (Fig. 17). If only a small defect is suspected, and haemostasis is achieved immediately, it may be sensible to obturate conventionally. If the defect is larger this may prevent adequate healing and some attempt must be made to repair it. It is necessary to be vigilant in placing the instruments in the original canal and not the perforation. This is facilitated by pre-bending root canal instruments and filing away from the defect.

Fig. 17 During the repair of the perforation in Figure 2, MTA was extruded into the peri radicular tissues. Arguably, though challenging to place, a barrier may have prevented this

There are two options for repairing these perforations:

1. Sealing the defect with MTA after obturating the canal apical to the perforation. The gutta percha can be heated and placed against the canal wall opposing the perforation. This eases the application of MTA to the perforation, which is placed at the level of the defect and condensed by hand. The disadvantage that comes with this technique is the risk of extruding the obturation material into the perforation
2. Clean and shape the canals then, after hemostasis has been achieved, use a 'space-maintainer' to protect the canal from obstruction with the repair material. This must be placed deeper than the perforation. Different space-maintainers have been recommended including severed files,[42] but a GP cone or paper points are readily available, inexpensive and easy to remove once the repair is complete.

Fig. 18 The root canal treatment of the 21 and 11 (from Figure 9) was completed and the buccal perforation to the 21 was repaired with MTA

These operators feel it is invariably easier to obturate the canal apical to the defect, repair the defect then backfill the canal around the repair with warm flowable gutta percha, but this is clearly personal preference and clinical flexibility is essential.

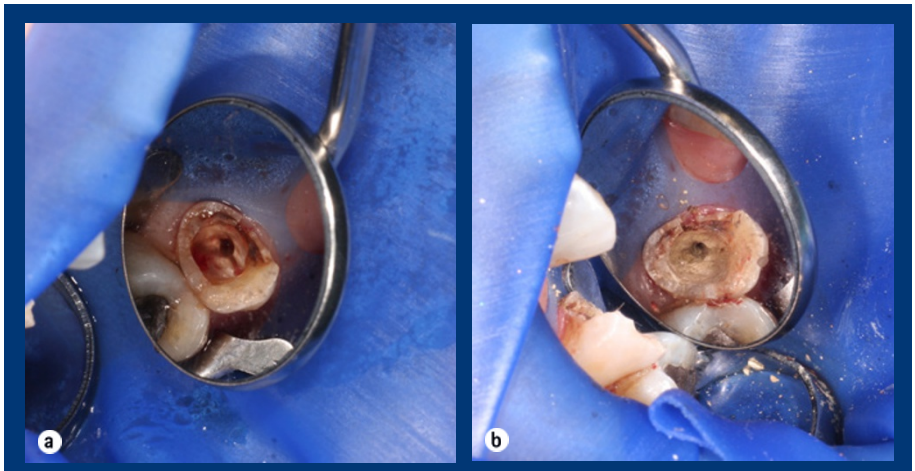

Fig. 19 Once the bleeding in Figure 7 was controlled (using adrenalin containing local anaesthetic injected interproximally and gentle pressure with cotton wool pledgets) the perforation was repaired with Biodentine. Again, this permitted the clinician to continue endodontic therapy during that visit

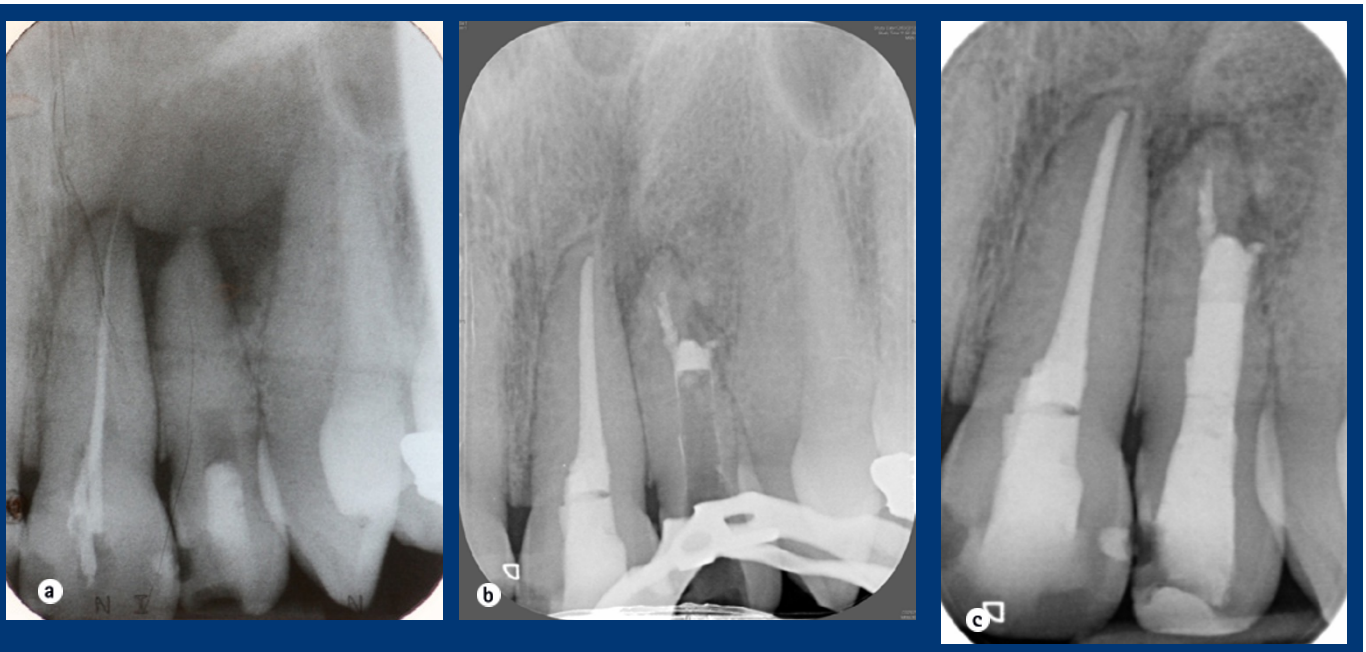

Fig. 20 a) Whilst attempting to locate the canal of the 22 the operator perforated the distal aspect of the apical third. b) The canal was correctly identified and shaped. Following this GP was used to obturate the apical canal before MTA was placed over the perforation. c) The canal was backfilled with warm flowable GP

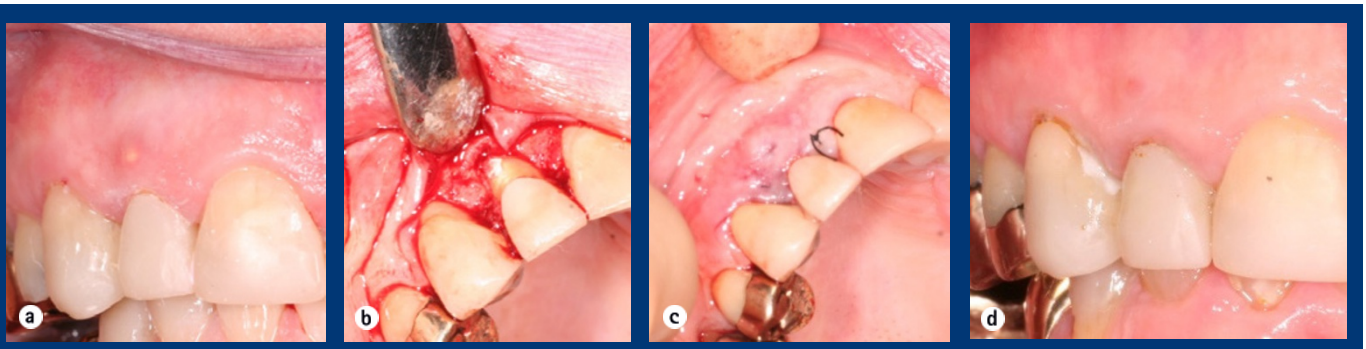

Fig. 21 a) A perforation occurred during RCT of the 12 resulting in a persistent sinus. b–c) An intra-sulcular incison was made and a flap raised without relieving incisions. Surgical repair with MTA was performed. d) There was evidence of healing and no pocketing at a 4 week review

Apical third perforations

These perforations can be difficult to manage. They often occur during cleaning and shaping of the root canal.[32] Access is invariably limited and negotiating these frequently blocked and ledged canals is difficult. Using MTA to restore these defects may be impossible unless it is a straight wide canal and the operator can sufficiently visualise the lesion (Figs 20a-c). We advocate attempting to re-access the original anatomy and, following cleaning and shaping, obturation with warm vertical compaction of gutta percha, relying upon the sealer and some GP to flow into the defect. If re-access is not possible then obturation to the defect may be carried out, with warm vertical compaction of gutta percha. It must be noted, however, that apical perforations with uninstrumented canals may face a much poor prognosis and cannot be managed successfully in all cases. Consideration should be given to the options of apical surgery or extraction, should pathology and symptoms persist.[42]

Surgical management of perforations

In the past, before technology such as magnification and illumination became readily available, perforations were often managed surgically. With these advances, it is now considered appropriate to use a non-surgical approach whenever possible.[13] However, surgical intervention may be considered when:

- There is uncertainty about the shape/nature of the defect
- The defect is sub-crestal and associated with pathology and/or symptoms
- Internal access is not possible because of an extensive intracoronal/extra coronal restoration
- There is a large defect preventing control over materials
- There is an apical third perforation with persistent disease that cannot be adequately cleaned and repaired
- There is external cervical resorption not amenable to internal repair

Essentially, surgical management is indicated if either the case is not amenable or not responding to non-surgical treatment, or if management of the affected periodontium is required.[13,45] Root canal treatment should be completed. A surgical flap is then reflected at the perforation site to provide access for surgical repair. In instances when the defect is in the coronal half of the tooth it is prudent to lift a full mucoperiosteal flap. It provides good access and can be a rectangular flap with mesial and distal vertical relieving incisions, triangular with just one or, if the flap can be mobilised sufficiently, it may be possible to access the lesion without a relieving incision (Figs 21a-d). In cases where the lesion is located more apically it

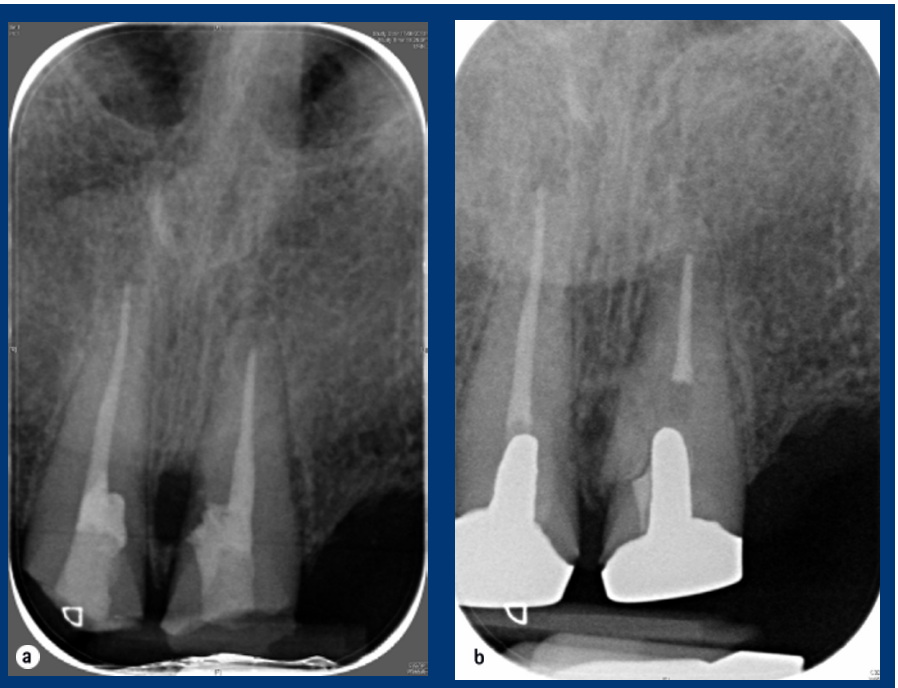

Fig. 22 a) Localised chronic inflammation around a perforation on the mesial aspect of the 21. The lesion was surgically accessed after definitive restoration and repaired with Biodentine. b) Radiographic review at 6 months reveals evidence of bony healing and the suggestion of the formation of new periodontal ligament

Use magnification and good illumination when providing endodontic treatment.[48]

Remove impediments to straight-line access: this reduces the curvature of the canal.

Begin a crown down approach before apical instrumentation. This facilitates instrumentation, prevents instruments locking in the canal and allows improved irrigation.

Negotiate canals initially with size 10 ISO files and progress to size 20 ISO files before introducing rotary instruments.

Use 'fine files frequently' between larger files to prevent blockages and ledging.

Use copious irrigation with 1%-5.25% sodium hypochlorite to remove debris.

In curved canals use balanced force technique for hand filing.

Always follow manufacturer guidelines on rotary instrument protocols.

Never force a file.

If you suspect a blockage or ledge, do not use rotary instruments.

In teeth with multiple roots always file away from the furcation with brush strokes of the instruments.

If there is any doubt about access, working length or possible perforation, take a check radiograph.

Fig. 23 Key concepts to avoid perforation during endodontic treatment

may be sensible to use papilla base preservation techniques or sub marginal incisions.

Preparation of the perforation site may be performed with a piezo-electric ultrasonic hand piece or a small round bur can be used, but often, simple hand instrumentation with curettes will suffice. Haemostasis should then be achieved before the restorative material is placed in the perforation defect. As described above, a biologically compatible material should be thoroughly compacted into the cavity to ensure a dense fill. If haemostasis cannot be achieved the operator must make a decision about how to proceed. MTA type materials 'wash out' in wet environments and it may not be possible to manipulate them adequately. Resin bonded materials require immaculate moisture control. The fall back option remains resin-modified glass-ionomer cement. Though this material is also moisture sensitive its handling properties, setting time and self-adhesive nature permit a compromised repair in difficult circumstances. If there is a bony cavity it should then be carefully debrided and all the debris is removed before the flap is replaced (Figs 22a and 22b).[45]

It is reported that success rates may vary between 30% and 80% which further reiterates the fact that non-surgical repair should always be carried out whenever possible.[46,47]

CONCLUSION

Perforations can result in chronic infection and ultimately tooth loss. Prevention of iatrogenic damage is an essential part of all healthcare interventions. Table 2 contains some tips on good preventive strategies. Nonetheless, perforations can and do occur for a variety of reasons. It is essential the clinician recognises when a perforation has occurred and has knowledge of the best strategy for correcting the damage. A referral to a more experienced colleague may result in a delay in treatment, which may have serious impact upon the outcome of treatment, therefore, all clinicians should consider immediate repair with the appropriate materials. Patients must be informed that long standing perforations may be unpredictable to repair and consent must include the risks and benefits of either leaving the tooth unrepaired or extraction and prosthetic replacement.

1. Fuss Z, Trope M. Root perforations: classification and treatment choices based on prognostic factors. *Dent Traumatol* 1996; **12:** 255–264.
2. Kvinnsland I, Oswald R J, Halse A, Grønningsaeter A G. A clinical and roentgenological study of 55 cases of root perforation. *Int Endod J* 1989; **22:** 75–84.
3. Patel S, Duncan H F. *Pitt Ford's Problem-Based Learning in Endodontology.* Wiley-Blackwell, 2011.
4. Darcey J, Qualtrough A. Resorption: part 1. Pathology, classification and aetiology. *Br Dent J* 2013; **214:** 439–451.
5. Darcey J, Qualtrough A. Resorption: part 2. Diagnosis and management. *Br Dent J* 2013; **214:** 493–509.
6. Tait C M E, Ricketts D N J, Higgins A J. Restoration of the root-filled tooth: pre-operative assessment. *Br Dent J* 2005; **198:** 395–404.
7. Gulabivala, K, Ng Y L. The restorative-endo interface. *In Endodontics.* 4th ed. pp 334–360. St Louis: Mosby, 2014.
8. Seltzer S, Sinai I, August D. Periodontal effects of root perforations before and during endodontic procedures. J Dent Res 1970; **49:** 332–339.
9. Eleftheriadis G I, Lambrianidis T P. Technical quality of root canal treatment and detection of iatrogenic errors in an undergraduate dental clinic. *Int Endod J* 2005; **38:** 725–734.
10. Alhadainy H A. Root perforations: a review of literature. *Oral Surg Oral Med Oral Pathol* 1994; **78:** 368–374.
11. Sedentext. Radiation protection: cone beam CT for dental and maxillofacial radiology. Evidence based guidelines. 2011. Information available online at www.sedentexct.eu (accessed January 2016).
12. Ng Y L, Mann V, Gulabivala K. A prospective study of the factors affecting outcomes of nonsurgical root canal treatment: part 1: periapical health. *Int Endod J* 2011; **44:** 583–609.
13. Clauder T, Shin S J. Repair of perforations with MTA: clinical applications and mechanisms of action. *Endod Topics* 2006; **15:** 32–55.
14. Beavers R A, Bergenholtz G, Cox C F. Periodontal wound healing following intentional root perforations in permanent teeth of Macaca mulatta. *Int Endod J* 1986; **19:** 36–44.
15. Hartwell G R, England M C. Healing of furcation perforations in primate teeth after repair with decalcified freeze-dried bone: a longitudinal study. *J Endod* 1993; **19:** 357–361.
16. Petersson K. Hasselgren G, Tronstad L. Endodontic treatment of experimental root perforations in dog teeth. *Endod Dent Traumatol* 1985; **1:** 22–28.

17. Strömberg T. Hasselgren G, Bergstedt H. Endodontic treatment of traumatic root perforations in man. A clinical and roentgenological follow-up study. *Swed Dent J* 1972; **65:** 457–466.
18. Sinai I H. Endodontic perforations: their prognosis and treatment. *J Am Dent Assoc* 1977; **95:** 90–95.
19. Frank AL. Resorption, perforations, and fractures. *Dent Clin North Am* 1974; **18:** 465–487.
20. Himel V T, Brady J, Weir J. Evaluation of repair of mechanical perforations of the pulp chamber floor using biodegradable tricalcium phosphate or calcium hydroxide. *J Endod* 1985; **11:** 161–165.
21. Lantz B, Persson P A. Periodontal tissue reactions after root perforations in dog's teeth. A histologic study. *Odontol Tidskr* 1967; **75:** 209–237.
22. Holland R, Filho J A, De Souza V, Nery M J, Bernabe P F E, Junior E D. Mineral trioxide aggregate repair of lateral root perforations. *J Endod* 2001; **27:** 281–284.
23. Torabinejad M, Chivian N. Clinical applications of mineral trioxide aggregate. *J Endod* 1999; **25:** 197–205.
24. Lee S J, Monsef M, Torabinejad M. Sealing ability of a mineral trioxide aggregate for repair of lateral root perforations. *J Endod* 1993; **19:** 541–544.
25. Torabinejad M, Higa R K, McKendry D J, Pitt Ford T R. Dye leakage of four root end filling materials: effects of blood contamination. *J Endod* 1994; **20:** 159–163.
26. Pitt Ford T R, Torabinejad M, Hong C U, Kariyawasam S P. Assessment of mineral trioxide aggregate as a retrograde root filling. *J Dent Res* 1994; **73:** 804.
27. Torabinejad M, Hong C U, Lee S J, Monsef M, Pitt Ford T R. Investigation of mineral trioxide aggregate for root-end filling in dogs. *J Endod* 1995; **21:** 603–608.
28. Torabinejad M, Hong C U, McDonald F, Pitt Ford T R. Physical and chemical properties of a new root-end filling material. *J Endod* 1995; **21:** 349–353.
29. Kratchman SI. Perforation repair and one-step apexification procedures. *Dent Clin North Am* 2004; **48:** 291–307.
30. Bargholz C. Perforation repair with mineral trioxide aggregate: a modified matrix concept. *Int Endod J* 2005; **38:** 59–69.
31. Pitt Ford T R, Torabinejad M, McKendry D J, Hong C U, Kariyawasam S P. Use of mineral trioxide aggregate for repair of furcal perforations. *Oral Surg Oral Med Oral Pathol Oral Radiol Endod* 1995; **79:** 756–763.
32. Ruddle C J. Nonsurgical endodontic retreatment. *J Calif Dent Assoc* 2004; **32:** 474–484.
33. Arens D E, Torabinejad M. Repair of furcal perforations with mineral trioxide aggregate: two case reports. *Oral Surg Oral Med Oral Pathol Oral Radiol Endod* 1996; **82:** 84–88.
34. Jeansonne B G, Boggs W S, Lemon R R. Ferric sulfate hemostasis: effect on osseous wound healing. II. With curettage and irrigation. *J Endod* 1993; **19:** 174–176.
35. Lemon R R, Steele P J, Jeansonne B G. Ferric sulfate hemostasis: effect on osseous wound healing. I. Left in situ for maximum exposure. *J Endod* 1993; **19:** 170–173.
36. Carr GB. Ch. 24: retreatment. *In* Cohen S, Burns RC (eds). *Pathways of the pulp.* 7th ed. St. Louis: Mosby, 1998.
37. Al-Daafas A, Al-Nazhan S. Histological evaluation of contaminated furcal perforation in dogs' teeth repaired by MTA with or without internal matrix. *Oral Surg Oral Med Oral Pathol Oral Radiol Endod* 2007; **103:** 92–99.
38. Auslander W P, Weinberg G. Anatomic repair of internal perforations with indium foil and silver amalgam: outline of a method. *NY J Dent* 1969; **39:** 454–457.
39. Imura N, Otani S M, Hata G, Toda T, Zuolo M L. Sealing ability of composite resin placed over calcium hydroxide and calcium sulphate plugs in the repair of furcation perforations in mandibular molars: a study *in vitro*. *Int Endod J* 1998; **31:** 79–84.
40. Jantarat J, Dashper S G, Messer H H. Effect of matrix placement on furcation perforation repair. *J Endod* 1999; **25:** 192–196.
41. Rafter M, Baker M, Alves M, Daniel J, Remeikis N. Evaluation of healing with use of an internal matrix to repair furcation perforations. *Int Endod J* 2002; **35:** 775–783.
42. Roda R, Gettleman B H. Nonsurgical retreatment. In S. Cohen K M. Hargreaves (eds) *Pathways of the Pulp.* 9th ed. St. Louis: Mosby, 2006.
43. Sluyk S R, Moon P C, Hartwell G R. Evaluation of setting properties and retention characteristics of mineral trioxide aggregate when used as a furcation perforation repair material. *J Endod* 1998; **24:** 768–771.
44. Allam C R. Treatment of stripping perforations. *J Endod* 1996; **22:** 699–702.
45. Carrotte P. Surgical endodontics. *Br Dent J* 2005; **198:** 71–79.
46. Rud J, Andreasen J O, Jensen J E. Radiographic criteria for the assessment of healing after endodontic surgery. *Int J Oral Surg* 1972; **1:** 195–214.
47. Jansson L, Sandstedt P, Laftman A C, Skoglund A. Relationship between apical and marginal healing in periradicular surgery. *Oral Surg Oral Med Oral Pathol Oral Radiol Endod* 1997; **83:** 596–601.
48. Ricketts D N, Tait C M, Higgins A J. Tooth preparation for post-retained restorations. *Br Dent J* 2005; **198:** 463–471.