Spinal Cord (2008) 46, 716–721

www.nature.com/sc

ORIGINAL ARTICLE

Effect of intrathecal papaverine on blood flow and secondary injury in injured cord

T Yong[1], S Huiyong[1], H Lin[1], W Yanfeng[1], Y Wei[2], M Yuanchen[3], Y Rui[1], L Jie[4] and W Peng[1]

[1]*Institute of Spinal Cord Injury of Sun Yat-sen University, GuangZhou, China;* [2]*Department of Pharmacology, GuangDong Medical College, ZhanJiang, China;* [3]*Department of Orthopaedics, GuangDong Province People's Hospital, GuangZhou, China and* [4]*Department of Anesthesia, The Second Affiliated Hospital of Sun Yat-sen University, GuangZhou, China*

Study design: Experimental laboratory investigations with a model of neurotrauma in *Macaca rhesus*.
Object: The present study evaluates whether intrathecal papaverine induces changes in spinal cord blood flow (SCBF) of injured spinal cord and prevents secondary injury.
Setting: Institute of Spinal Cord Injury, Sun Yat-sen University, China.
Methods: After laminectomy was performed and contusive spinal cord injuries were induced in adult female *Macaca rhesus*, three received intrathecal papaverine, and three received saline 0.9% for control. SCBF was registered by laser-Doppler recording technique continuously for 180 min after injection. Histological analyses and microvessel density (MVD) were used for evaluation of spinal cord injury, and the percentage of spared spinal cord area was calculated.
Results: Mean arterial blood pressure showed no significant change in both groups. In the papaverine group, SCBF recovered to 81.35 ± 7.8% of baseline at 15 min, 75.24 ± 6.3% at 30 min, 73.38 ± 2.3% at 90 min and 72.57 ± 4.1% at 180 min after the completion of infusion. SCBF was significantly higher than the control groups ($P<0.01$). There was no occlusion of the arteries, but occluded veins were identified at the injured site. The MVD in the spinal cord of the control group was significantly lesser than the papaverine group ($P<0.01$). Luxol Fast Blue staining showed that intrathecal papaverine reduced myelin loss in the lesion 2 weeks after injury ($P<0.05$).
Conclusion: Intrathecal administration of papaverine increased SCBF in non-human primates. It is likely that the effects of papaverine can reduce secondary injury in spinal cord injured *Macaca rhesus*.
Spinal Cord (2008) **46,** 716–721; doi:10.1038/sc.2008.30; published online 15 April 2008

Keywords: acute spinal cord injury; spinal cord blood flow; papaverine; intrathecal injection

Introduction

The pathophysiology of acute spinal cord injury (SCI) is complex and has not been fully elucidated. There are two mechanisms of damage to the spinal cord after acute SCI: the primary mechanical injury, and a secondary injury due to ischemia, biochemical alterations, apoptosis, excitotoxicity, calpain proteases, neurotransmitter accumulation, free radical injury and inflammatory responses.[1] There is histological and physiological evidence that the primary injury, the mechanical deformation and the destruction of neurons may be progressively worsened by the secondary injury.[2] Pharmacological intervention in SCI aims at interrupting these secondary mechanisms and arresting the progression of the pathological changes.

Papaverine relaxes the smooth musculature of the larger blood vessels, including the coronary, cerebral, peripheral and pulmonary arteries. This action is particularly evident when such vessels are in spasm, induced by reflex or drugs.[3] Intrathecal administration of papaverine would permit the drug to act directly on the adventitial surface of the larger vessels, the larger intramedullary vessels and capillary bed in the spinal cord. Another potential advantage is the avoidance or minimization of significant systemic side effects, such as hypotension, which occur after systemic administration.[4] The aim of the present study was to evaluate if early intrathecal papaverine can alter spinal cord blood flow (SCBF) and prevent secondary injury in spinal cord injured *Macaca rhesus*.

Materials and methods

Contusive SCI in Macaca rhesus

Six adult female *Macaca rhesus* were used: three received intrathecal papaverine after injury, and three received saline 0.9% for control. Continuous mean arterial blood pressure

Correspondence: Dr S Huiyong, Institute of Spinal Cord Injury of Sun Yat-sen University, YanJiangXi Road 107, GuangZhou 510120, China.
E-mail: tangyong8888@hotmail.com
Received 29 May 2007; revised 20 February 2008; accepted 2 March 2008; published online 15 April 2008

using the femoral artery, pulse rate, rectal temperature and SaO_2 were monitored. After an intramuscular injection of ketamine (50 mg kg^{-1}) to induce anesthesia, laminectomy was performed at T9–T11 level and the spinal cord was exposed. Contusive SCIs were induced by using a home-made weight-drop device (3 mm dia; a modified New York University weight-drop impactor device). A total of 25 g weights were dropped from a height of 125 mm onto the exposed dura mater at the T10 level. A spinal needle (24-gauge $\times 1\frac{1}{2}$; Becton Dickinson, Franklin Lakes, NJ, USA) was inserted into the subarachnoid space at the T11 level. The needle position was confirmed by cautious aspiration of cerebrospinal fluid. A 1 ml (30 mg) quantity of papaverine in dextrose water solution was administered slowly intrathecally 5 min after injury through the spinal needle within 30 s in the papaverine group, and 1 ml saline 0.9% in the control group. The Sun Yat-sen University Ethics Committee and the Animal Experimentation Committee of the Central Institute for Experimental Animals approved all animal procedures, which were in accordance with the NIH (National Institutes of Health) Guide for the Care and Use of Laboratory Animals.

Laser-Doppler recordings
Spinal cord blood flow was monitored both pre- and post-injury using the laser flow blood perfusion monitor (model PeriFlux4001Master, Sweden). A 0.84-mm diameter probe was fixed above the spinal cord. The laser-Doppler probe was positioned 2 mm rostrally to the lesion point, and secured using a clamp attached to the operating table. Care was taken to avoid areas with large dorsal vessels to prevent falsely elevated recordings. Blood flow was recorded as LDU (laser-Doppler units), because the laser-Doppler technique is not a true measure of absolute flow, a measure of changes in flow expressed as percentage of blood flow. The average of the 5-min SCBF readings prior to injury was used as the control value for each animal. Readings from each of the 5-min post-injury periods were compared with the pre-injury control value.

Histological analyses
At 2 weeks after injury, each animal was perfused intracardially with 4% paraformaldehyde (pH 7.4). The injured spinal cord tissues were removed, post-fixed in 4% paraformaldehyde, and section blocks were prepared and cut into 20-μm-thick coronal sections. These sections were stained with hematoxylin–eosin for general histological examinations.

Evaluation of the microvessel density
The sections were deparaffinized and hydrated, and endogenous peroxidase activity was blocked by 3% hydrogen peroxide in PBS. The slides were washed three times, 2 min each, and then incubated with blocking serum for 10 min to block nonspecific binding, and the sections were incubated with monoclonal anti-CD34 antibody (DaKo Corp., Denmark, Germany) at a 1/100 dilution, for 1 h at room temperature. After washing, a biotinylated secondary antibody (Boster Tech Led, Wuhan, China) was used as a second layer for 10 min. Streptavidin–peroxidase complex was applied for 10 min. The sections were washed in PBS and the peroxidase signal was developed in 0.05% diaminobenzidine and 0.01% hydrogen peroxide in PBS. The sections were lightly counterstained with hematoxylin. The microvessel density (MVD) was assessed by light microscopy using the counting method. Microvessels were counted in five fields at a magnification of $\times 200$. The final MVD was the mean value obtained from the counts of the five fields. MVD was expressed as mean (s.d.) (vessels mm^{-2}).

Spared white matter area
Starting from the injury epicenter in the coronal plane, sections were obtained at 1-mm intervals around the injury epicenter. Sections were mounted on gelatinized slides and stained with Luxol Fast Blue (Sigma Chemical, St Louis, MO, USA). Percentage of spared white matter area (spared white matter area/total spinal cord area $\times$ 100) was calculated using NIH Image J software version 1.3 (US NIH, Bethesda, MD, USA); data were expressed as means ± s.e.m. All slides were assessed blindly with respect to the treatment.

Statistics
Student's *t*-test was applied to the data. Data were expressed as mean ± s.e.m. with $P<0.05$ regarded as statistically significant.

Results

Physiological parameters
The mean arterial blood pressure showed no significant change ($P>0.05$; Table 1), although a temporary small decrease in blood pressure could be seen in the two groups after SCI. There were no differences in rectal temperature and SaO2 between groups during the experiment ($P>0.05$; Table 1).

SCBF
The decline in SCBF was significant 5 min after the injury, when the infusion was 65.21 ± 9.3% of baseline (Figure 1). In the papaverine group, SCBF recovered to 81.35 ± 7.8% of baseline at 15 min, 75.24 ± 6.3% at 30 min, 73.38 ± 2.3% at 90 min and 72.57 ± 4.1% at 180 min after the completion of infusion. In the control group, SCBF decreased to 65.89 ± 4.3% at 15 min, 58.57 ± 7.6% at 30 min, 55.46 ± 5.8% at 90 min and 53.58 ± 3.7% at 180 min after injury. There was significant difference between the two groups ($P<0.01$).

Histological findings
At 2 weeks after the spinal contusion, necrosis in the spinal cord was observed in all animals. Marked hemorrhages were present in the gray matter at the site of contusion. Parts of hemorrhages at the compressed sites were resolved, leaving central areas of necrosis in the gray matter. The major arteries on the surface of the spinal cord, including the anterior and posterior spinal arteries, were patent at

Table 1 Physiological parameters

Group	*Parameter*	*Baseline*	*Time after injury (min)*				
			5	*15*	*30*	*90*	*180*
Papaverine	MABP (mm Hg)	103.00 ± 3.62	98.21 ± 3.65	101.01 ± 2.89	100.16 ± 2.97	101.32 ± 4.87	102.17 ± 3.03
	Temperature (°C)	38.3 ± 0.2	38.0 ± 0.2	38.1 ± 0.1	38.2 ± 0.3	37.9 ± 0.3	38.0 ± 0.2
	SaO_2 (%)	98.5 ± 0.8	97.8 ± 0.4	97.5 ± 0.6	98.0 ± 0.7	98.7 ± 0.5	98.3 ± 0.6
Control	MABP (mm Hg)	105.35 ± 7.39	100.34 ± 3.95	101.00 ± 3.27	101.67 ± 4.02	103.23 ± 3.55	102.57 ± 3.64
	Temperature (°C)	38.1 ± 0.2	38.2 ± 0.2	38.0 ± 0.1	38.3 ± 0.1	38.5 ± 0.2	38.7 ± 0.3
	SaO_2 (%)	98.7 ± 0.5	98.8 ± 0.2	98.5 ± 0.3	98.4 ± 0.4	98.5 ± 0.5	98.3 ± 0.8

Mean arterial blood pressure (MABP) showed no significant change ($P>0.05$); there were no differences in rectal temperature and SaO_2 between groups during the experiment ($P>0.05$).

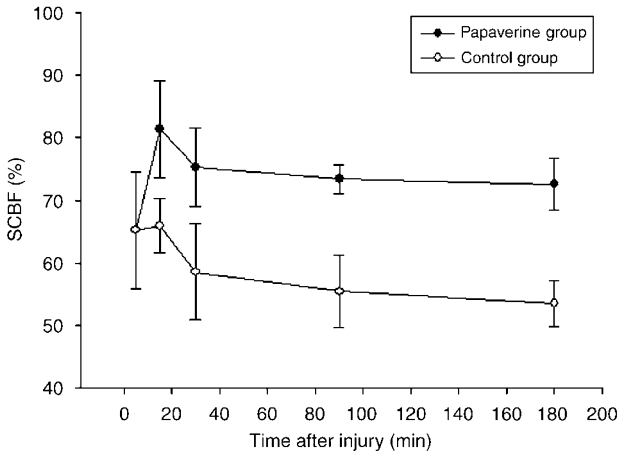

Figure 1 Spinal cord blood flow (SCBF) over time as assessed by the laser flow blood perfusion monitor. The decline in SCBF was significant 5 min after injury in both groups, but papaverine produced an improvement in SCBF; there was significant difference between the two groups ($P<0.01$).

the injured site, or remotely, after injury, but the veins were occluded and filled with red blood cells (Figures 2a and b).

MVD

The MVD in the spinal cord of the control group was significantly lesser than the papaverine group (Figures 2c and d). The MVD varied from 36.12 to 69.25 (mean 52.83 ± 13.22) in the papaverine group, whereas it varied from 16.23 to 53.06 (mean 36.25 ± 15.02) in the controls. There was a significant difference in the mean MVD between the two groups ($P<0.01$).

Spared white matter area

The calculated mean percentage of spared white matter area at 2 weeks after injury in the papaverine and control groups is shown in Figure 3. The amount of spared white matter area tended to be highest at 5 mm rostral and 4 mm caudal to the lesion center in the papaverine group, but at 7 mm rostral and 5 mm caudal to the lesion center in the control group. Compared with the control group, the papaverine group showed significant spared white matter area both at the site of the injury (80.7 ± 8.1 vs 64.9 ± 11.2%) and in the adjacent zone ($P<0.05$).

Discussion

Spinal cord injury is commonly caused by traumatic injuries, such as industrial or car accidents, violence or sports injuries. We chose a contusive SCI model at the thoracic level in non-human primates because the pathophysiology of contusion injuries is more similar in these to that of human SCI. Previous contusive SCI models have been used at the C5 level of common marmoset,[5] but neither has there been any contusive SCI model at the thoracic level in non-human primates, nor any objective functional evaluation parameter or a multifaceted analysis for such a model. Vascular injury plays an important role in secondary injury mechanisms that cause damage to the spinal cord.[6] Primary mechanical trauma is followed by secondary injury mechanisms that contribute to the necrotizing process due to vascular injuries. Experimental studies have reported significant post-traumatic ischemia at the injured segment and adjacent areas after severe SCI.[7] Vessel rupture, compression, intravascular thrombosis and vasospasm contribute to the ischemia of spinal cord, in which 80% decrease of post-injury blood flow is caused by vasospasm alone.[8] Studies also reported that in human SCI, traumatic occlusion or thrombosis of the major arteries on the surface of the cord is extremely rare. None of the major arteries on the surface of the human spinal cord, including the anterior and posterior spinal arteries, were occluded at the injury site, or remotely, at any time after the trauma,[9] suggesting that vasospasm was the important factor causing ischemia of the spinal cord. Our study confirmed that few of the arteries on the surface of the spinal cord were occluded at the injury site or remotely. There have been many studies on the effects of intrathecal administration of various drugs on SCBF.[10,11] Nimodipine has been investigated as a treatment for SCI. It had previously been shown that systemic nimodipine causes severe hypotension after SCI.[12] Thus, intrathecal administration of nimodipine did not prevent the hypotension encountered with systemic administration and exerted no beneficial effect on SCBF after acute SCI.[11] Papaverine has been used to protect the spinal cord from ischemic damage while operating on the descending or thoracoabdominal aorta. It was administered

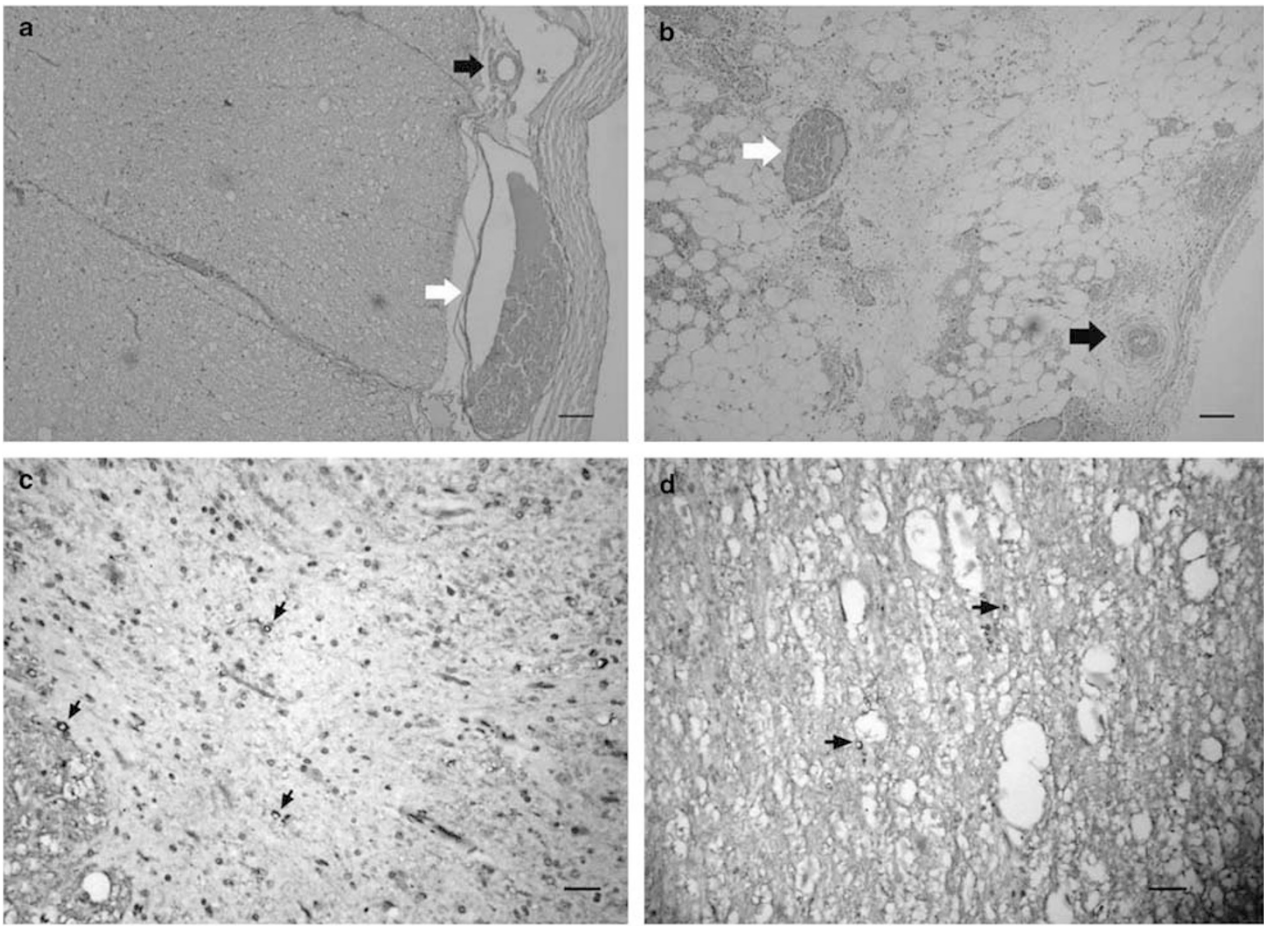

Figure 2 (**a**) The damaged was significantly mild in papaverine group, few of the arteries (black arrow) on the surface of spinal cord were occluded, but occlusion of veins (white arrow) was found (HE, bars = 100 μm); (**b**) Necrosis was significant in control group, arteries (black arrow) on the surface of spinal cord were not occluded, and occlusion of veins (white arrow) was found (HE, bars = 100 μm); (**c** and **d**) Microvessel density (brown staining endothelial cell, black arrow) was correlated well with necrosis (**c**, papaverine group; **d**, control group; bars = 50 μm).

intrathecally and appeared to provide spinal cord protection during prolonged periods of aortic cross-clamping as well.[13] The administration of intrathecal papaverine had no significant effect on mean arterial pressure, systemic vascular resistance, cerebrospinal fluid pressure or the pH of the cerebrospinal fluid.[14] Intrathecal papaverine was not associated with decrease of mean arterial pressure and may be superior to other drugs. In the present study, papaverine produced an improvement in SCBF: there was about 70% recovery of SCBF with papaverine after the injury. Intrathecal papaverine in *Macaca rhesus* with acute SCI produced beneficial effects on post-traumatic SCBF and increased spared spinal cord tissue following contusion injury, but did not cause a further decline in MABP. In our model of SCI at T10, there was no marked posttraumatic systemic hypotension due to the loss of sympathetic tone.

Papaverine in dextrose water solution was administered intrathecally 5 min after injury as SCI may have a 'super-acute phase'. *In vivo* imaging of axonal degeneration in the injured spinal cord showed that the axon ends underwent fragmentation within 30 min after injury, a process termed as 'acute axonal degeneration'.[15] It affected the distal and proximal axon ends, removed axon segments that were still connected to the soma and could have led to a secondary denervation by affecting the side branches that bear synaptic contacts. MVD measurement with immuno-histochemical methods was the gold standard for quantifying angiogenesis and, hence, the underlying blood flow.[16]

Angiogenesis is believed to be crucial for wound healing and may be an important factor in establishing a proper environment for nerve regeneration. Angiogenesis restores oxygen and nutrients to the injury site and thereby contributes to the supportive environment. After SCI, this may mean increased efficiency in wound healing and increased sprouting, which may contribute to functional recovery. Studies of angiogenesis in the injured adult rat spinal cord have demonstrated that angiogenesis correlates with regenerative responses and precedes behavioral improvement.[17]

The use of laser-Doppler flowmetry for measuring SCBF is an excellent way of providing real-time regional measurements of blood flow, characterization of microcirculatory events and record continuously, over time, in a restricted tissue volume of the spinal cord. It compares favorably with other techniques, including quantitative autoradiography, radiolabelled microspheres and hydrogen clearance.[18] The

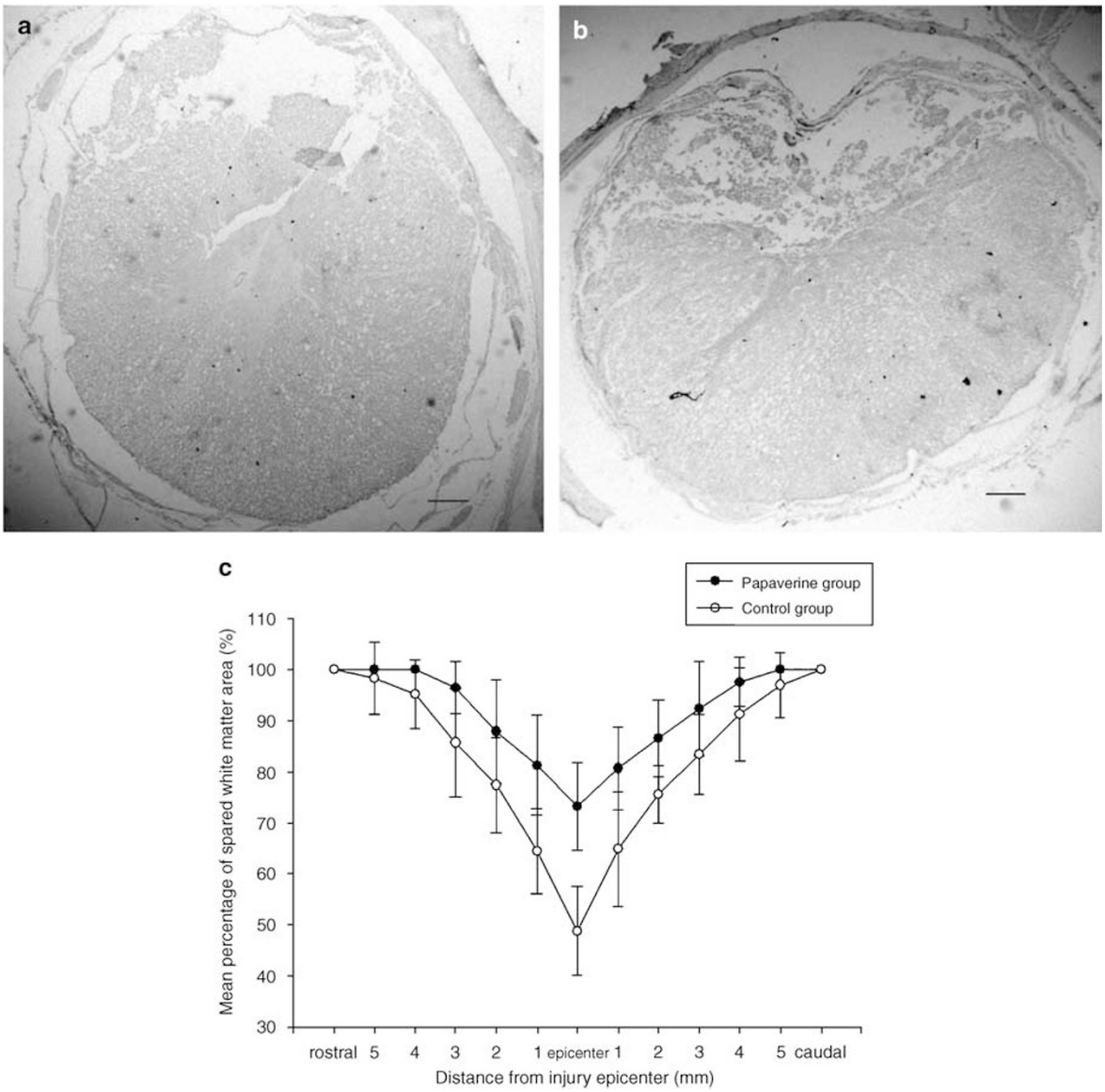

Figure 3 (**a**, **b**) Improved spinal cord preservation after spinal cord injury in papaverine group (**a**, papaverine group; **b**, control group; stained with Luxol Fast Blue; bars = 500 μm). (**c**) Significantly larger white matter area was preserved in the papaverine group than the control group 2 weeks after injury ($P<0.05$).

results of the present study showed that MVD and laser-Doppler flowmetry demonstrated a significant trend in SCBF.

We chose papaverine as the vasodilating drug because it is readily available and its usage during vascular surgery is accepted as a safe and effective method to prevent vasospasm.[13] The most characteristic effect of papaverine is relaxation of the tonus of all smooth muscles, especially when it has been spasmodically contracted. Papaverine apparently acts directly on the muscle itself. Papaverine relaxes the smooth musculature of the blood vessels, including the coronary, cerebral, peripheral and pulmonary arteries. This action is particularly evident when such vessels are in spasm, induced by reflex or drugs, and it provides the basis for the clinical use of papaverine in acute SCI. The present study focused on SCBF changes and histopathological findings in acute SCI, and the results showed that intrathecal administration of papaverine increased SCBF in non-human primates. It is likely that the effects of papaverine can reduce secondary injury in spinal cord injured *Macaca rhesus*. Functional evaluation will be performed to further clarify the beneficial effect of intrathecal papaverine on SCBF and secondary injury in our future investigation.

References

1 Carlson GD, Gorden C. Current developments in spinal cord injury research. *Spine J* 2002; **2**: 116–128.
2 Lu J, Ashwell KW, Waite P. Advances in secondary spinal cord injury: role of apoptosis. *Spine* 2000; **25**: 1859–1866.
3 Kiran S, Agrawal D. Papaverine and vasospasm. *J Neurosurg* 2005; **102**: 181.

4 Ogata M, Marshall BM, Lougheed WM. Observations on the effects of intrathecal papaverine in experimental vasospasm. *J Neurosurg* 1973; **38**: 20–25.
5 Iwanami A, Yamane J, Katoh H, Nakamura M, Momoshima S, Ishii H *et al*. Establishment of graded spinal cord injury model in a nonhuman primate: the common marmoset. *J Neurosci Res* 2005; **80**: 172–181.
6 Mautes AE, Weinzierl MR, Donovan F, Noble LJ. Vascular events after spinal cord injury: contribution to secondary pathogenesis. *Phys Ther* 2000; **80**: 673–687.
7 Daneyemez M. Silicone rubber microangiography of injured acute spinal cord after treatment with methylprednisolone and vitamin E in rats. *Spine* 1999; **24**: 2201–2205.
8 Anthes DL, Theriault E, Tator CH. Ultrastructural evidence for arteriolar vasospasm after spinal cord trauma. *Neurosurgery* 1996; **39**: 804–814.
9 Tator CH, Koyanagi I. Vascular mechanisms in the pathophysiology of human spinal cord injury. *J Neurosurg* 1997; **86**: 483–492.
10 Westmark R, Noble LJ, Fukuda K, Aihara N, McKenzie AL. Intrathecal administration of endothelin-1 in the rat: impact on spinal cord blood flow and the blood-spinal cord barrier. *Neurosci Lett* 1995; **192**: 173–176.
11 Imamura H, Tator CH. Effect of intrathecal nimodipine on spinal cord blood flow and evoked potentials in the normal or injured cord. *Spinal Cord* 1998; **36**: 497–506.
12 Guha A, Tator CH, Smith CR, Piper I. Improvement in post-traumatic spinal cord blood flow with a combination of a calcium channel blocker and a vasopressor. *J Trauma* 1989; **29**: 1440–1447.
13 Svensson LG, Stewart RW, Cosgrove III DM, Lytle BW, Antunes MD, Beven EG *et al*. Intrathecal papaverine for the prevention of paraplegia after operation on the thoracic or thoracoabdominal aorta. *J Thorac Cardiovasc Surg* 1988; **96**: 823–829.
14 Svensson LG, Grum DF, Bednarski M, Cosgrove III DM, Loop FD. Appraisal of cerebrospinal fluid alterations during aortic surgery with intrathecal papaverine administration and cerebrospinal fluid drainage. *J Vasc Surg* 1990; **11**: 423–429.
15 Kerschensteiner M, Schwab ME, Lichtman JW, Misgeld T. *In vivo* imaging of axonal degeneration and regeneration in the injured spinal cord. *Nat Med* 2005; **11**: 572–577.
16 Kvasnicka HM, Thiele J. Bone marrow angiogenesis: methods of quantification and changes evolving in chronic myeloproliferative disorders. *Histol Histopathol* 2004; **19**: 1245–1260.
17 Loy DN, Crawford CH, Darnall JB, Burke DA, Onifer SM, Whittemore SR *et al*. Temporal progression of angiogenesis and basal lamina deposition after contusive spinal cord injury in the adult rat. *J Comp Neurol* 2002; **445**: 308–324.
18 Milhorat TH, Kotzen RM, Capocelli Jr AL, Bolognese P, Bendo AA, Cottrell JE *et al*. Intraoperative improvement of somatosensory evoked potentials and local spinal cord blood flow in patients with syringomyelia. *J Neurosurg Anesthesiol* 1996; **8**: 208–215.