Paraplegia (1995) 33, 350–353

Early surgery for thoracolumbar spinal cord injury: initial experience from a developing spinal cord injury centre in India

VSSV Prasad[1], JVS Vidyasagar[4], AK Purohit[2] and I Dinakar[3]

[1]Assistant Professor, [2]Associate Professor, [3]Professor, Department of Neurosurgery; [4]Additional Professor, Department of Orthopaedics, Nizam's Institute of Medical Sciences, Panjagutta, Hyderbad, India 500482

The spinal cord injury centre of Nizam's Institute of Medical Sciences, Andhra Pradesh, India has been functioning now for 8 months and offers its services to the population of 80 million in the state. To date, 92 patients with a spinal cord injury have been treated; 51 had a thoracolumbar spinal injury. This report presents the results of the management of these 51 patients. Preoperatively both CT and MRI were performed and the radiological findings were correlated with outcome. Twenty five had a thoracic and 26 a lumber location. Twenty nine patients underwent surgical treatment (15 thoracic and 14 lumbar) and the others were treated conservatively (10 thoracic and 12 lumbar). All these operations were carried out within 2 weeks following trauma, and methylprednisolone therapy was instituted in those who reached the hospital early. Contraindications for surgery included a delay in admission of more than 3 weeks following trauma, a focus of sepsis, bedsores, a generalised bone disorder such as osteopenia, and medical illnesses. Transpedicular screw-plate fixation was performed in 27 patients, and two patients underwent decompressive laminectomy and interlaminar bone and wire fixation. Delayed spinal decompression was offered to one patient to relieve radiculopathy. Fracture-dislocation spinal injury and those with transection of the spinal cord had the worst outcome, whilst patients with a wedge compression fracture and cord oedema fared better. Operated cases had a shorter hospital stay, and complications of immobilisation were limited. Positive psychological influence of mobilisation and early acclimatisation to the altered style of living with their disability were the most significant outcomes following surgery.

Keywords: spinal cord injury; thoracolumbar injury; transpedicular screw fixation; early surgery; India

Introduction

During the past three decades surgery for internal spinal fixation has evolved rapidly since fusion rates have improved with the use of internal fixation compared to other techniques.[1–5] Technical advances and refinements in instrumentation have also provided a variety of surgical options.[6–10] Transpedicular screw-plate fixation has become an important method for internal fixation in a variety of spinal disorders and is particularly well suited for lumbar spinal fusion.[7,11,12] Compared to posterior wire-rod or hook-rod systems, transpedicular screw systems allow internal fixation of significantly fewer motion segments and provide better segmental fixation.[3,13–15] Three column spinal stabilisation, preservation of normal adjacent motion segments and preservation of mechanical pain syndromes are possible with transpedicular screw plate devices.[3] The present study analyses the initial experience that we have gained since the opening of our spinal cord injury centre, as is applicable to our working conditions and to our patient population.

Clinical material and methods

During the first 8 months of the centre, 92 spinal cord injury (SCI) patients were admitted; 51 had a thoracolumbar spinal injury (25 thoracic and 26 lumbar). There were 43 males and eight females; 80.4% were in the second and third decades of life. The majority of the patients sustained their injuries from a road traffic accident (55%) and falls (35%). Jolts in a bus (2), being hit by heavy weights (1), gunshot wound (1) and earthquake (1) were the other causes. Of the 51 patients only 11 (21.5) could reach the hospital within 24 h; 66.7% of acute injuries arrived within the first week of trauma.

The commonest location of the bony injury was L1 (31%) followed by T12 (25%), T11 (15%) and L2, L3 (12% each). Preoperative assessment of the patient included plain radiology, computed tomography (CT) and magnetic resonance imaging (MRI).

The predominant type of bony lesion was a wedge compression fracture (53%), followed by a fracture dislocation (29%). MRI scans were useful in demon-

strating the spinal cord and the soft tissue injuries. Cord transection (37%) and oedema (35%) were the commonest cord injuries encountered. Fifteen of the thoracic and 14 of the lumbar spine injuries received operative treatment.

Transpedicular screw-plate fixation (Steffe's) was performed in 26, posterior decompression and interlaminar wire fixation in two and laminectomy alone in one patient. The procedure of transpedicular screw-plate fixation was performed according to standard guidelines under the control of an image intensifier, to achieve open reduction and restore near normal alignment of the fractured spine (Figures 1 and 2). All patients were mobilised on the first postoperative day following internal fixation. Significant surgical complications included haemothorax in two patients (probably due to associated chest injury), and minor wound sepsis in one. Reasons for non-operative treatment included delay in arrival (7), focus of sepsis (8), osteoporosis (3), a medical illness such as poisoning and depressive psychosis (1 each), and a stable spinal injury (2).

Statistical analysis

Frankel grading was used for the neurological assessment of patients at the time of admission and at discharge/follow-up. Improvement in the grading was given numbers (from A to B (score 1), from C to E (score 2)). Deterioration was marked by negative scoring. The total score in both groups was compared and analysed. Fisher's exact test was used to analyse the categorical data, summarised in 2×2 tables. In addition, 95% confidence intervals (CIs) were also computed for proportions.

Figure 1 Plain radiograph, lateral view of the lumbar spine (preoperative), showing a fracture with dislocation and spinal canal encroachment

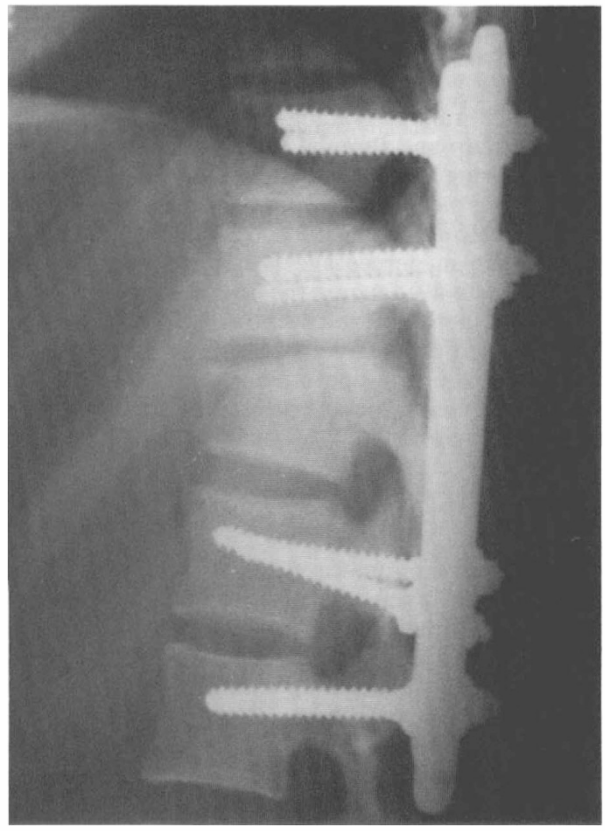

Figure 2 Postoperative plain radiograph of the lumbar spine demonstrates reduction of the dislocation and stability offered by a transpedicular screw-plate system

Results

The extent of the bony injury and of the spinal cord lesion was found to influence the outcome. Patients with a fracture-dislocation had a poorer prognosis (the majority had transection of the spinal cord), whereas those with spinal cord oedema and vertebral subluxation fared better (presenting with preserved neurological function). Those patients presenting with a fracture-dislocation of spine and total functional loss did not show any significant improvement on follow up. In both groups, the neurological deficit at the time of admission had a relevance to the outcome; the more severe the initial deficit, the poorer was the ultimate prognosis and *vice versa*. Frankel's grading at the time of admission and at the last follow-up was compared between the operative and non-operative groups. However, analysis with 95% CIs for proportions shows that the operative group has a favourable outcome. The

skeletal outcome was not analysed statistically. However, the alignment and reduction of the dislocation/subluxation was achieved by operative correction in all of the patients. The number of patients with improvement in the Frankel grading was 11 (37.9%) in the operative group and three (13.6%) in the non-operative group. Using Fisher's exact test, this result from the treatment was not significantly different between the two groups. However, the 95% confidence interval for the difference in percentage (24.3) between the two groups (−0.4 to 49) favours the operative group. Also, on interview method, the psychological perspective of the operated group of patients was found to be brighter compared to the non-operative group who had predominantly a feeling of unworthiness, depression and suicidal tendencies.

Discussion

Operative intervention for patients with spinal cord trauma is currently accepted as a preliminary step in the complex rehabilitation programme of such patients. Unless contraindicated by systemic or local problems, all patients with an unstable spinal injury appear to require surgical stabilisation. The present results of early near-anatomical open reduction and stabilisation of patients with thoracolumbar spinal injuries in symptomatic patients are consistent with the findings reported in other series,[16–19] with a benefit for operative treatment for those lesions involving the thoracolumbar junction or of the lumbar spine. The transpedicular device allows controllable distraction by acting on the leverage applied to the pedicular screws, thus achieving adequate correction of kyphosis and improvement of the reduced height of the vertebral body; consequently it achieves both adequate spinal realignment and a favourable neurological outcome.[20,21] Occasionally retropulsed bone fragments narrowing the spinal canal represent only a residual deformity (22), and do not compromise the ultimate neurological outcome.[20,23,24] Alternative approaches by the anterior route have resulted in several complications, and anterior stabilisation is now only a second choice.[19] Similarly, percutaneous interbody osteosynthesis appears to be a promising procedure, particularly in high risk patients, because of a lesser degree of operative trauma and the ability to spare the paraspinal muscles.[25] But this technique has been found to be unsuitable in the presence of lesions involving the upper thoracic or the lower lumbar spine. Spontaneous resorption of intracanal bone fragments, though occasionally observed,[26] is quite uncommon. Treatment modalities other than near-anatomical reconstruction of the spine may be suboptimal at least in symptomatic patients in the early stage.[27] It is possible that conservative management may be maintained in neurologically intact patients since there is enough evidence that it can permit a favourable neurological outcome.[28,29] The existence of associated lesions such as generalised bone disorders, a focus of sepsis, and of other life threatening conditions negates operative intervention. Although in the present series there was no statistically significant difference in the neurological outcome, between a patient treated by surgical or by non-surgical methods, the 95% confidence interval method favours surgical management. Reduction of any complications from immobilisation, reduced duration of hospital stay and reduced hospital expenses, positive psychological influences, and early integration of patients into the family in our country where compliance and the follow-up of patients is poor, appear to favour treatment by early operative stabilisation of the unstable spine wherever appropriate. The long-term results of the method in our patient population are however awaited; therefore, the case selection of thoracolumbar spinal injury patients for surgical intervention should be executed with caution.

References

1 Ferguson RL, Tencer AF, Woodard P. Biomechanical comparisons of spinal fracture models and the stabilizing effects of posterior instrumentation. *Spine* 1988; **13**: 453–460.
2 Kaufmann HH, Jones E. The principles of bony spinal fusion. *Neurosurgery* 1989; **24**: 264–270.
3 Krag MH. Biomechanics of thoracolumbar spinal fixation. A review. *Spine* 1991; **16** (suppl 3): S84–S99.
4 Lorenz M, Zindrick M, Schwaegler P. A comparison of single level fusions with and without hardware. *Spine* 1990; **16** (suppl 8): S455–S458.
5 West JL III, Bradford DS, Ogilvie JW. Results of spinal arthrodesis with pedicle screw-plate fixation. *J Bone Joint Surg Am* 1991; **73**: 1179–1184.
6 Ebelke DK, Asher MA, Neff JR. Survivorship analysis of VSP spine instrumentation in the treatment of thoracolumbar and lumbar burst fractures. *Spine* 1991; **16** (suppl 8): S428–S432.
7 Horowitch A, Peek RD, Thomas JC Jr. The Wiltse pedicle screw fixation system. Early clinical results. *Spine* 1989; **14**: 461–467.
8 Luque ER. The anatomic basis and development of segmental spine instrumentation. *Spine* 1982; **7**: 256–259.
9 Moreland DB, Egnatchik JG, Bennet GJ. Cotrel-Dubousset instrumentation for the treatment of thoracolumbar fractures. *Neurosurgery* 1990; **27**: 69–73.
10 Steffe AD, Biscup RS, Sitkowski DJ. Segmental spine plates with pedicle screw fixation. A new internal fixation device for disorders of the lumbar and thoracolumbar spine. *Clin Orthop* 1986; **203**: 45–53.
11 Roy-Camille R, Saillant G, Mazel C. Plating of thoracic, thoracolumbar and lumbar injuries with pedicle screw plates. *Orthop Clin North Am* 1986; **17**: 147–159.
12 McAfee PC, Weilard DJ, Carlow JJ. Survivorship analysis of pedicle spinal instrumentation. *Spine* 1991; **16** (Suppl): S422–S427.
13 Abumi K, Punjabi MM, Duranceau J. Biomechanical evaluation of spinal fixation devices. Part III. Stability provided by six spinal fixation devices and inter body bone graft. *Spine* 1989; **14**: 1249–1255.
14 Asham RB, Galpin RD, Corin JD. Biomechanical analysis of pedicle screw instrumentation systems in a corpectomy model. *Spine* 1989; **14**: 1398–1405.
15 Skinner R, Maybee J, Transfeldt E. Experimental pull out testing and comparison of variables in transpedicular screw fixation. A biomechanical study. *Spine* 1990; **15**: 195–201.
16 Babu ML, Wani MR. Management of thoraco-lumbar fractures. *Acta Neurochir* (Wien) 1990; **102**: 54–57.
17 Jacobs RR, Asher MA, Snider RK. Thoracolumbar spinal injuries. A comparative study of recumbent and operative treatment in 100 patients. *Spine* 1980; **5**: 463–477.
18 Lindsey RW, Dick W. The fixateur interne in the reduction and stabilization of thoracolumbar fractures in patients with neuro-

logic deficit. *Spine* 1991; **16**: 140–145.
19 Silvestro C, Francaviglia N, Bragazzi R, Viale GL. Near anatomical reduction and stabilization of burst fractures of the lower thoracic or lumbar spine. *Acta Neurochir* (Wien) 1992; **116**: 53–59.
20 Crutcher JP, Anderson PA, King HA, Monesano PX. Indirect spinal canal decompression in patients with thoraco-lumbar burst fractures treated by posterior distraction rods. *J Spinal Dis* 1991; **4**: 39–48.
21 Fredrickson B, Mann K, Yuan H, Lubicky J. Reduction of the intracanal fragment in experimental burst fractures. *Spine* 1988; **13**: 267–271.
22 Trafton PG, Boyd CA. Computed tomography of thoracic and lumbar spine injuries. *J Trauma* 1984; **24**: 506–515.
23 Herndon WA, Galloway D. Neurological return versus cross-sectional area in incomplete thoraco-lumbar spinal cord injuries. *J Trauma* 1988; **28**: 680–683.
24 Osbold WR, Weinstein SL, Sprague BL. Thoracolumbar spine fractures: Results of treatment. *Spine* 1989; **6**: 13–24.
25 Lozes G *et al*. Percutaneous interbody osteosynthesis in the treatment of thoracolumbar traumatic or tumoural lesions. A review of 51 cases. *Acta Neurochir* (Wien) 1990; **102**: 42–53.
26 Braakman R *et al*. Neurological deficit in injuries of the thoracic and lumbar spine. *Acta Neurochir* (Wien) 1991; **111**: 11–17.
27 Viale GL *et al*. Transpedicular decompression and stabilization of burst fractures of the lumbar spine. *Surg Neurol* 1993; **40**: 104–111.
28 Reid DC, Hu R, Davis LA, Saboe LA. The non-operative treatment of burst fractures of thoracolumbar junction. *J Trauma* 1988; **28**: 1188–1194.
29 Weinstein JN, Collalto P, Lehmann TR. Thoraco-lumbar 'burst' fractures treated conservatively: A long term follow-up. *Spine* 1988; **15**: 33–38.