Eye (2020) 34:650–656
https://doi.org/10.1038/s41433-019-0547-3

The ROYAL COLLEGE of OPHTHALMOLOGISTS

ARTICLE

Clinical features and visual prognostic indicators after vitrectomy for Terson syndrome

Xin Liu[1] · Longfei Yang[2] · Wenrui Cai[1] · Linlin Gao[1] · Yaping Li[1]

Received: 14 August 2018 / Revised: 29 April 2019 / Accepted: 28 May 2019 / Published online: 27 August 2019

Abstract

Purpose To determine clinical characteristics and identify factors associated with better visual outcomes in patients who had vitrectomy for vitreous haemorrhage (VH) associated with Terson syndrome (TS).

Methods The records of 48 patients (54 corresponding eyes) who underwent vitrectomy for VH associated with TS from January 2008 to December 2017 were retrospectively reviewed. The main outcome measure was the final postoperative visual acuity.

Results At the last visit, 34 eyes (63.0%) achieved a BCVA of 0.3 or better. Eyes associated with traumatic brain injury had a better visual outcome than those with primary intracerebral haemorrhage ($P = 0.042$). In the primary intracerebral haemorrhage group, patients with hypertension-induced intracranial haemorrhage (IH) showed poorer final visual acuities than the ruptured intracranial aneurysm group ($P = 0.023$). In the delayed vitrectomy group, epiretinal membrane and peripheral retina changes were more common ($P < 0.05$). However, the difference in final visual acuity between the early and delayed vitrectomy groups was not significant ($P = 0.69$).

Conclusion Most of the patients obtained visual recovery after vitrectomy for TS. VH associated with ruptured intracranial aneurysm or traumatic brain injury or eyes without retinal haemorrhage are predictive of better prognosis. Although the timing of vitrectomy was not related to the final postoperative visual outcome, early vitrectomy by three months seems to suggest less epiretinal membrane formation, retinal tears, and retinal detachments.

Introduction

Subhyaloid (preretinal), retinal, and/or vitreous haemorrhage (VH) with aneurysmal subarachnoid haemorrhage (SAH) were initially described by Moritz Litten in 1881 and were named Terson syndrome (TS) by Albert Terson in 1900 [1]. Thereafter, the definition was broadened to intraocular haemorrhage related to intracranial haemorrhage (IH) caused by a variety of reasons (e.g., brain trauma). The reported incidence of TS varies widely, ranging from 2.6 to 28% [2–5], possibly due to the high mortality of IH and the relatively low rate of detection. The exact pathophysiological mechanism of the ocular changes remains unknown. Most studies have suggested that increased intracranial pressure is transmitted via the subarachnoid space to optic nerves, resulting in venous hypertension and secondary capillary rupture [6]. Some studies have found evidence that blood could directly extravasate into the eye via the subarachnoid space between the optic nerve and its sheath, but this hypothesis remains controversial, as the connection between vitreous and subarachnoid space has not been proven [7, 8].

Factors relating to intraocular haemorrhage include high scores on the Hunt–Hess and Fisher Scales, low scores on the Glasgow Coma Scale, arterial hypertension, larger aneurysms, and older age [2, 9]. Ophthalmologic treatment is usually conservative initially, and vision in most eyes improves with spontaneous absorption of the haemorrhage within a few months; however, the VH may not clear,

Supplementary information The online version of this article (https://doi.org/10.1038/s41433-019-0547-3) contains supplementary material, which is available to authorized users.

✉ Yaping Li
li_yp2002@163.com

[1] Eye Center, The Second Hospital of Jilin University, #218 Ziqiang Street, Changchun 130000 Jilin, China

[2] Jilin Provincial Key Laboratory on Molecular and Chemical Genetics, The Second Hospital of Jilin University, #218 Ziqiang Street, Changchun 130000 Jilin, China

increasing the risk of secondary glaucoma, retinal detachment (RD), proliferative retinopathy, and cataracts, which can compromise visual recovery even further. Timely surgical treatment with pars plana vitrectomy is often employed to remove the blood, usually resulting in significant improvement of vision [10–12]. Garweg et al. [12] found that patients operated within 3 months after VH achieved a better final best corrected visual acuity (BCVA) than those who waited longer, while there was no difference in the final BCVA between early and delayed vitrectomy (more than 3 months) in another study [13]. The timing of vitrectomy for VH in TS remains under debate.

In this retrospective study, we discuss the clinical characteristics of patients who have undergone vitrectomy for VH associated with TS and attempt to identify factors associated with better visual prognosis, aiming to help physicians better manage these complicated patients.

Materials and methods

The records of patients who were admitted to our ophthalmology department with TS-related VH and who underwent vitrectomy by nine surgeons from January 2008 to December 2017 were retrospectively reviewed. Detailed information was collected from patients with a history of IH related to the onset of VH. The diagnosis of IH was confirmed by the neurology department before being referred to our department. All research was performed in accordance with the tenets of the Declaration of Helsinki and was approved by the Ethics Committee of the Second Hospital affiliated with Jilin University.

The data were collected retrospectively from patient medical records and included demographic characteristics, systemic disorders, surgical history, cause of IH, presenting visual acuity, details of the examination, timing of ophthalmic surgery, intraoperative procedures, and operative details (gauge of vitrectomy, posterior vitreous detachment (PVD), locations of haemorrhage, retina exudate, retinal tear and detachment, epiretinal membrane, tamponades, etc.). Postoperative complications, follow-up duration, and final anatomic and functional outcomes were also included. We excluded cases of VH secondary to other reasons or combined with other related diseases, such as diabetic retinopathy or ocular trauma, patients who were lost to follow-up, and those with insufficient medical records.

On admission, all eyes underwent a thorough ophthalmological examination. Visual acuity measurements were obtained using the Tumbling E or Early Treatment Diabetic Retinopathy Study charts following a standardized protocol and were recorded as decimal fractions. To facilitate calculations, light perception, hand movement, and finger counting were recorded as 0.0025, 0.005, and 0.014, respectively [14, 15]. After preoperative written informed consent was obtained, all patients underwent a standard three-port 20-gauge (20 G), 23-gauge (23 G), or 25-gauge (25 G) pars plana vitrectomy. Phacoemulsification and intraocular lens (IOL) implantation were performed in eyes with severe cataracts that affected the intraoperative visualization of the retina. Additional surgical procedures, including endolaser, membrane peeling, and silicone oil or gas tamponade, were performed when retinal tears and RD were found intraoperatively. Membrane peeling was performed to treat epiretinal membranes, and subinternal limiting membrane haemorrhage (subILM) was an indication for internal limiting membrane (ILM) peeling. The BCVA, intraocular pressure (IOP), and complete eye examination were documented after the operation.

Descriptive statistics, a t test, a χ^2 test, or Fisher's exact test, were used for comparisons between groups. The Mann–Whitney U test or Kruskal–Wallis test was applied for comparisons of data with abnormal distributions. Statistical analyses were performed with SPSS Version 19.0 (SPSS Inc., Chicago, IL), and a value of $P < 0.05$ indicated statistical significance.

Results

A total of 3942 patients were diagnosed as having VH from January 2008 to December 2017, and among these, 52 patients were confirmed as having TS. One patient was excluded because her mental state did not permit a visual acuity assessment. Two patients were excluded because they had repeat haemorrhage in the brain and died after vitrectomy, and one patient was not included due to follow-up cessation. Therefore, 54 eyes of 48 patients were included in this study. Preoperative data are shown in Table 1. Of the recruited patients, 28 were male (58.3%). The mean age was 49.44 ± 9.82 years. Twenty patients (41.7%) had a history of hypertension with durations ranging from 1 month to 30 years. Eleven eyes of eleven patients (22.9%) had VH secondary to IH resulting from traumatic brain injury, and 43 eyes of 37 patients had VH secondary to primary intracerebral haemorrhage. Among the latter group, 33 eyes of 28 patients (58.3%) had VH secondary to ruptured intracranial aneurysm and SAH, and the remaining ten eyes of nine patients (18.8%) had a history of hypertension-induced IH. The distributions of causes of IH and age are shown in Fig. 1a. Seven (14.6%) patients underwent only medical treatment, and 19 (39.6%) underwent endovascular coiling for intracranial aneurysm; neurosurgical clipping or decompressive hemicraniectomy was performed on 22 (45.8%) patients. Seventeen (35.4%) patients had VH in the right eye, and 21 (43.8%) had VH in the left eye. Bilateral VH occurred in ten (20.8%) patients.

Table 1 Clinical characteristics of Terson syndrome with vitreous haemorrhage

Age (years)	49.44 ± 9.82
Gender	
Male	28 (58.3%)
Female	20 (41.7%)
History of hypertension	20 (41.7%)
Causes of IH primary intracerebral haemorrhage	
Ruptured intracranial aneurysm	28 (58.3%)
IH induced by hypertension	9 (18.8%)
Traumatic brain injury	11 (22.9%)
Treatment for IH	
Medical treatment	7 (14.6%)
Endovascular coiling	19 (39.6%)
Neurosurgical clipping/ decompressive hemicraniectomy	22 (45.8%)
VH in right eye	17 (35.4%)
VH in left eye	21 (43.8%)
VH in bilateral	10 (20.8%)
Time between IH and vitrectomy	2.73 ± 6.11 (0.5–10) months
Mean follow-up period	11.78 ± 17.04 (4–42) months

IH intracranial haemorrhage

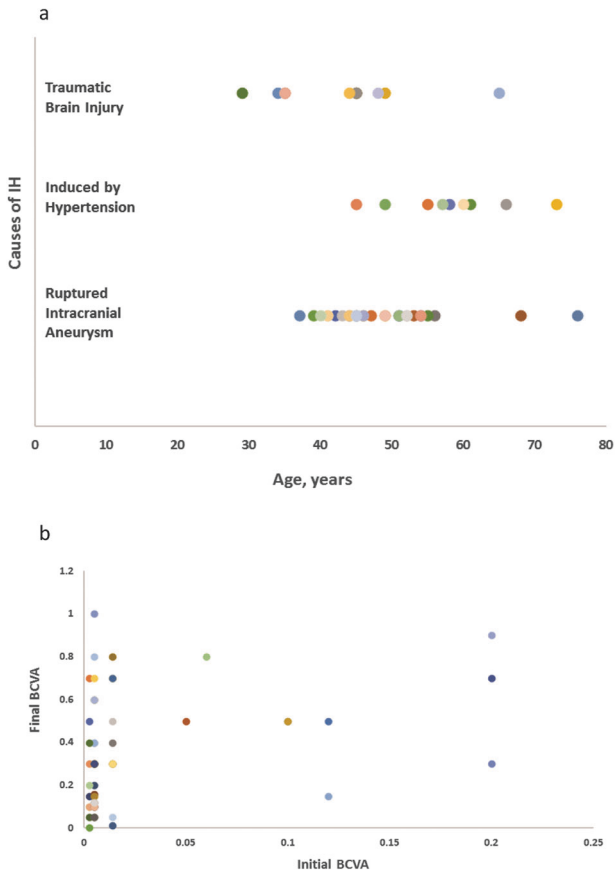

Fig. 1 a Distribution of causes of IH and age. Patients with hypertension-induced IH show an older age distribution. IH intracranial haemorrhage. **b** Distribution of the initial BCVA (*x*-axis) and the final BCVA (*y*-axis). Each eye is denoted by a dot. BCVA best corrected visual acuity

The mean follow-up period was 11.78 ± 17.04 (4–42) months (Table 1).

A 20G vitrectomy was performed on 21 eyes (38.9%), a 23G vitrectomy was performed on 16 eyes (29.6%), and a 25 G vitrectomy was performed on 17 eyes (31.5%). During surgery, in addition to VH, concurrent subILM was found in four eyes, subhyaloid haemorrhage in four eyes, subretinal haemorrhage (submacular haemorrhage not included) in five eyes, and intraretinal haemorrhage in three eyes (Supplementary Fig. 1a, b) [16, 17]. Three eyes had concurrent subILM haemorrhage and subhyaloid haemorrhage, showing a "double-ring sign" [18]. Haemorrhage beneath foveal and perifoveal areas (submacular haemorrhages) that could not be cleared with vitrectomy were found in two (3.7%) eyes. One eye had both intraretinal and subretinal haemorrhages. Seven eyes had retinal exudation near the macular area or the vascular arch (Supplementary Fig. 1c–f). One eye had neovascularization of the optic disk. PVD was found in six eyes, and partial PVD was found in 32 eyes. Cryotherapy was performed in five instances, and endolaser coagulation was performed in 11 instances for retinal tears or degeneration of the area; membrane peeling was performed intraoperatively in 19 (35.2%) eyes with epiretinal membrane, and among these 19 eyes, ILM peeling was performed in four (7.4%) eyes with epimacular membrane. Fluid tamponade was used in 34 (63.0%) eyes, air tamponade was used 12 (22.2%) eyes, C3F8 tamponade was used in four (7.4%) eyes, and silicone oil tamponade was used in four (7.4%) eyes. Four eyes were found to have tractional RD at the time of vitrectomy and were treated successfully with endolaser coagulation and silicone oil tamponade, which was removed 3 months later. No RD, uncontrollable elevated IOP, or repeat haemorrhage occurred after the surgery. No patients were pseudophakic at the time of presentation; six phacoemulsifications and IOL implantations were performed during the vitrectomy. Post-vitrectomy cataract formation was observed in two eyes, and phacoemulsification with IOL implantation was performed during the postoperative follow-up (Table 2).

Figure 1b shows the distributions of the initial BCVA and final BCVA. In all cases, the BCVA at the final follow-up was significantly improved compared with that at presentation ($P < 0.005$). The only two eyes with visual acuity improvement from light perception to finger counting had severe submacular haemorrhage at the time of vitrectomy and no sign of absorption at the final visit after 6 months.

Table 2 Clinical findings during vitrectomy

Gauge of vitrectomy	
20 G	21 (38.9%)
23G	16 (29.6%)
25G	17 (31.5%)
Concurrent haemorrhage	
SubILM haemorrhage	4 (7.4%)
Subretinal haemorrhage	5 (9.3%)
Submacular haemorrhage	2 (3.7%)
Subhyaloid haemorrhage	4 (7.4%)
Intraretinal haemorrhage	3 (5.6%)
"Double-ring sign"[a]	3 (5.6%)
Exudation within the posterior pole	7 (13.0%)
Neovascularization on optic disk	1 (1.9%)
Posterior vitreous detachment	
Complete	6 (11.1%)
Partial	32 (59.3%)
None	16 (29.6%)
Tamponade	
Fluid	34 (63.0%)
Sterilized air	12 (22.2%)
C3F8	4 (7.4%)
Silicone oil	4 (7.4%)
Phacoemulsification and IOL implantation	
During vitrectomy	6 (11.1%)
During follow-up	2 (3.7%)

Subretinal haemorrhage: haemorrhage beneath the retina, except the macular area

ILM internal limiting membrane

[a]"double-ring sign": haemorrhage both under the ILM and the subhyaloid

Table 3 Prognostic indicators of final BCVA

Variables	Teams	Final BCVA ≥ 0.3	*P* value
Gender	Male	19 (59.4%)	0.313
	Female	16 (72.2%)	
Age (years)	<45	10 (71.4%)	0.747
	≥45	25 (62.5%)	
Cause of IH	Primary intracerebral haemorrhage	25 (58.1%)	0.042
	Traumatic brain injury	10 (90.9%)	
History of hypertension	No	20 (66.7%)	0.750
	Yes	15 (62.5%)	
Presenting visual acuity	<0.1	29 (61.7%)	0.400
	≥0.1	6 (85.7%)	
Timing of vitrectomy	<3 months after IH	27 (69.2%)	0.273
	≥3 months after IH	8 (53.3%)	
Tamponade	Fluid or sterilized air	30 (65.2%)	0.882
	C3F8 or silicone oil	5 (62.5%)	
Gauge of vitrectomy	20G	13 (61.9%)	0.585
	23G	12 (75.0%)	
	25G	10 (58.8%)	
Retinal haemorrhage	No	31 (72.1%)	0.027
	Yes	4 (36.4%)	
Subretinal exudation	No	31 (66.0%)	0.649
	Yes	4 (57.1%)	
Epiretinal membrane	No	24 (68.6%)	0.433
	Yes	11 (57.9%)	
Retinal detachment	No	34 (65.4%)	0.655
	Yes	1 (50.5%)	
Laser coagulation or cryotherapy for retinal tears or degeneration	No	19 (63.3%)	0.799
	Yes	16 (66.7%)	

Retinal haemorrhage: subretinal, submacular and intraretinal haemorrhage

IH intracranial haemorrhage

Forty-five eyes (83.3%) achieved a BCVA >0.1; among these, 34 (63.0%) achieved a BCVA of 0.3 or higher, and six eyes (11.1%) achieved a BCVA >0.8. Table 3 shows the prognostic indicators of final BCVA. Eyes with traumatic brain injury had a better visual outcome than those with primary intracerebral haemorrhage. Only 25 (58.1%) eyes with VH secondary to primary intracerebral haemorrhage achieved a final BCVA better than 0.3, while ten (90.9%) eyes with traumatic brain injury had a final visual acuity ≥0.3 ($p = 0.042$). Within the primary intracerebral haemorrhage group, patients with hypertension-induced IH showed worse final visual acuities (0.19 ± 0.13) than the ruptured intracranial aneurysm group (0.41 ± 0.28) ($P = 0.023$). All patients with hypertension-induced IH had a final postoperative BCVA of <0.5. A differentiation of visual acuities according to retinal haemorrhage showed that 31 eyes (72.1%) without subretinal, submacular, or intraretinal haemorrhage had a final BCVA >0.3, while only four eyes (36.4%) with haemorrhage had the same visual outcome ($P = 0.027$). Although no statistically significant correlations of final BCVA with other variables were observed, eyes with accompanying ocular pathologies, such as RD, retinal holes, or areas of degeneration, had worse visual outcomes, although presenting with a visual acuity >0.1 suggests a final visual acuity >0.5. The delay between IH and vitrectomy together with age, gender, other ocular findings and surgical procedures (e.g., gauges of vitrectomy, cryotherapy, endolaser coagulation, membrane peeling, and tamponade) were not found to be predictive factors of poor visual outcomes (Table 3).

The mean time between IH and vitrectomy was 2.73 ± 6.11 (0.5–10) months. Thirty-two eyes (59.3%) underwent vitrectomy in less than 3 months, and 22 eyes (40.7%) underwent vitrectomy after more than 3 months. The difference in the final visual acuity between the two groups was not significant ($P = 0.69$), suggesting that early vitrectomy may not be related to visual recovery. When the results were analysed with the causes of IH as separate subgroups, the operative timing still did not influence the visual prognosis. However, in the delayed vitrectomy group, four eyes (18.2%) had developed macular membranes at the time of vitrectomy, and ten eyes (45.5%) developed epiretinal membranes on other areas except the macular; the difference was significant compared with the early vitrectomy group ($P = 0.001$). The incidences of retinal holes and degeneration areas on the peripheral retina were increased when the vitrectomy was delayed. The 46 eyes without peripheral retina changes underwent the operation at an average of 2.67 ± 1.77 months after IH, whereas the eight eyes with changes underwent the operation at 3.63 ± 3.22 months ($P = 0.029$). Within 3 months, the difference was not significant ($P = 0.564$); however, at 6 months after IH, the occurrence of peripheral retina tears and degeneration became more common ($P = 0.032$). The differences in PVD, RD, retinal exudation, tamponade, and the rate of postoperative complications between the early and late vitrectomy groups were not significant.

Discussion

In the current study, we investigated the clinical features and predictive factors of visual outcomes in TS patients with VH. In addition to VH, posterior pole subinternal limiting membrane or subhyaloid haemorrhages, subretinal haemorrhages, and submacular haemorrhages have been reported in TS [10, 13, 19]. In this study, the rates of other types of haemorrhages were similar to previously reported results. During vitrectomy, haemorrhage beneath the ILM was found in four eyes (7.4%), and haemorrhage under the ILM together with the subhyaloid showed a macular double-ring sign in three eyes (5.6%) [18]; subretinal haemorrhage was found in five eyes (9.3%), and submacular haemorrhage was found in two eyes (3.7%). Gnanaraj et al. [19] reported subretinal haemorrhage in two eyes (8%) and submacular haemorrhage in one eye (4%), apart from VH. Narayanan et al. [13] reported that three eyes (10.7%) had subhyaloid haemorrhages, and one eye (3.6%) had a subILM found during vitrectomy for TS. A 39% incidence of macular haemorrhages that accumulated beneath the ILM was reported in TS patients [10]. In children, the data were comparable to those of adults, in that subhyaloid haemorrhage and subILM were found in one eye (3.6%), subILMs were found in five eyes (17.9%), subretinal haemorrhage was found in one eye (4%), and submacular haemorrhage was found in two eyes (7%) [20]. Epiretinal membranes were reported in 15–59% of patients [7, 10, 12, 21, 22]. In this case series, 19 eyes (35.2%) had epiretinal membranes. In seven eyes (13.0%), retinal exudation was found near the macular area or the vascular arch. Retinal exudation was less frequently discussed in reported cases, perhaps because it has a lesser effect on vision and is further from the macula. The exudation showed lipid-like changes on fundus examination and a high-intensity signal on optical coherence tomography scanning. Neovascularization was present in the optic disk in one patient in our series, which seems to be a less frequent finding and might be associated with a long duration before vitrectomy and a history of hypertension. However, additional cases are needed to reach a credible conclusion.

In this case series, patients with VH secondary to IH had rapid and favourable visual acuity rehabilitation after vitrectomy. In total, 45 eyes (83.3%) achieved a BCVA >0.1; among these, 34 (63.0%) achieved a BCVA of 0.3 or higher. In this case series, the visual acuity improvements of eyes with intracranial-induced VH closely resembled the gains reported for other specific VH causes, such as traumatic brain injury and SAH, as well as for all causes of TS [11–13, 19, 23, 24]. Furthermore, we compared visual prognoses based on the IH causes and found that eyes with traumatic brain injury had a better visual outcome than those with primary intracerebral haemorrhage. In the primary intracerebral haemorrhage group, patients with hypertension-induced IH showed a worse final visual acuity than the ruptured intracranial aneurysm group. This result may be related to arteriosclerosis in not only cerebral vessels but also retinal vessels in the hypertensive patients, which could have adverse effects on the blood supply and neural function of the retina. As no study has compared vision recovery in terms of the different causes of IH, this is the first study to demonstrate that hypertension-induced IH might indicate a worse visual outcome; however, larger numbers of subjects are needed to draw a more accurate conclusion.

Subretinal, submacular, and intraretinal haemorrhages were found in 11 eyes in this study, and only four (36.4%) of these eyes achieved a visual acuity better than 0.3, while the 31 eyes (72.1%) without retinal haemorrhage achieved the same level. Retinal haemorrhage, especially submacular haemorrhage, could have severely influenced retinal function recovery, as these types of haemorrhage could not be cleared with surgery and affect the function of retinal cells. Future studies with additional cases will help confirm this finding.

The timing of vitrectomy in TS patients is a subject of debate. In our cases, when referred to our centre, the

patients were evaluated to assure that the IH was in stable condition and that the physical status was suitable for vitrectomy by the neurosurgeon and anaesthetist. There was often no delay when they were confirmed to be appropriate for the operation. We found that most cases of TS patients who had a dense VH showed no sign of self-absorption, and during surgery, even though there was no PVD, the haemorrhage of the TS could be cleared much easier than the other causes with fewer complications, such as retinal tear. More studies are needed to confirm this empirical surgical finding of relatively easier haemorrhage clearance and fewer surgical complications. Some cases of thin blood in the vitreous were observed for 1–2 months. In a recent study of patients with VH after intracranial injury, no difference was found in the final BCVA between the early vitrectomy and delayed vitrectomy (more than 3 months) groups, suggesting that a prolonged observation of VH can be performed [13]. In this analysis, we also found that the delay between IH and vitrectomy was not a predictive factor for visual outcome at either 3 or 6 months. However, a greater number of eyes in the delayed vitrectomy group exhibited epiretinal membranes, retinal holes, or degeneration areas on the peripheral retina, which may increase the difficulty of surgery and impair vision recovery. Delayed vitrectomy was also found to be associated with an increased risk of complications in the previous reports [25–27], and early vitreoretinal surgery in TS patients has been suggested to facilitate rapid vision recovery without substantial disadvantages [12, 24, 28, 29]. Meanwhile, one observational study found that in nearly half of the patients, the VH was not absorbed within 19 months, and a higher rate of epiretinal membranes was reported in the nonvitrectomy group [30, 31]. Therefore, waiting for spontaneous absorption of the VH may be infeasible and harmful, with surgical intervention appearing to be inevitable in most cases. Early vitrectomy is recommended when patients' systemic conditions permitted, because rapid visual recovery can occur in most cases, along with a reduction in complications, especially for patients with binocular involvement, to improve quality of life.

Conclusion

The findings in this case series suggested that in most TS patients, vitrectomy effectively provided rapid visual rehabilitation, and cases secondary to ruptured intracranial aneurysms and traumatic brain injuries, as well as those without retinal haemorrhage tended to have a better visual prognosis. The timing of vitrectomy was not related to the final postoperative visual outcomes or the occurrence of complications associated with VH persistence, except for epiretinal membrane formation, retinal tears, and degeneration areas. Therefore, although visual function may not be influenced by delayed vitrectomy, early operation is recommended to prevent epiretinal membrane formation and retinal tears. Close collaboration between neurosurgeons and vitreoretinal surgeons is very important for the proper diagnosis and treatment of TS.

Summary

What was known before

- Most of patients with TS had rapid visual recovery after vitrectomy for VH.

What this study adds

- VH secondary to ruptured intracranial aneurysm in primary intracerebral haemorrhage group or traumatic brain injury and eyes without retinal haemorrhage are predictive of better prognosis.
- The timing of vitrectomy was not related to final postoperative visual outcomes.
- Early vitrectomy is suggested to prevent epiretinal membrane formation and retinal tears, as well as to facilitate the rehabilitation of quality of life and self-care ability.

Acknowledgements We thank Prof. Miao Li of the China–Japan Union Hospital, Jilin University for help with the neurological diagnosis and classification and Dr Shanshan Xu for the statistical consultation. This work was supported by the International Cooperation Foundation of Jilin Provincial Science and Technology Department (grant no. 20170414048GH) and the Natural Science Foundation of Jilin Province (grant no. 20180520118JH).

Compliance with ethical standards

Conflict of interest The authors declare that they have no conflict of interest.

References

1. Terson A. De l'hemorrhagie dans le corps vitre au cours de l'hemorrhagie cerebrale. Clin Ophthalmol. 1900;6:312.
2. Fountas KN, Kapsalaki EZ, Lee GP, Machinis TG, Grigorian AA, Robinson JS, et al. Terson hemorrhage in patients suffering aneurysmal subarachnoid hemorrhage: predisposing factors and prognostic significance. J Neurosurg. 2008;109:439–44.
3. Stienen MN, Lucke S, Gautschi OP, Harders A. Terson haemorrhage in patients suffering aneurysmal subarachnoid haemorrhage:

a prospective analysis of 60 consecutive patients. Clin Neurol Neurosurg. 2012;114:535–8.
4. Garfinkle AM, Danys IR, Nicolle DA, Colohan AR, Brem S. Terson's syndrome: a reversible cause of blindness following subarachnoid hemorrhage. J Neurosurg. 1992;76:766–71.
5. Ness T, Janknecht P, Berghorn C. Frequency of ocular hemorrhages in patients with subarachnoidal hemorrhage. Graefes Arch Clin Exp Ophthalmol. 2005;243:859–62.
6. Ogawa T, Kitaoka T, Dake Y, Amemiya T. Terson syndrome: a case report suggesting the mechanism of vitreous hemorrhage. Ophthalmology. 2001;108:1654–6.
7. Sakamoto M, Nakamura K, Shibata M, Yokoyama K, Matsuki M, Ikeda T. Magnetic resonance imaging findings of Terson's syndrome suggesting a possible vitreous hemorrhage mechanism. Jpn J Ophthalmol. 2010;54:135–9.
8. Medele RJ, Stummer W, Mueller AJ, Steiger HJ, Reulen HJ. Terson's syndrome in subarachnoid hemorrhage and severe brain injury accompanied by acutely raised intracranial pressure. J Neurosurg. 1998;88:851–4.
9. Joswig H, Epprecht L, Valmaggia C, Leschka S, Hildebrandt G, Fournier JY, et al. Terson syndrome in aneurysmal subarachnoid hemorrhage-its relation to intracranial pressure, admission factors, and clinical outcome. Acta Neurochir. 2016;158:1027–36.
10. Kuhn F, Morris R, Witherspoon CD, Mester V. Terson syndrome. Results of vitrectomy and the significance of vitreous hemorrhage in patients with subarachnoid hemorrhage. Ophthalmology. 1998;105:472–7.
11. Ritland JS, Syrdalen P, Eide N, Vatne HO, Overgaard R. Outcome of vitrectomy in patients with Terson syndrome. Acta Ophthalmol Scand. 2002;80:172–5.
12. Garweg JG, Koerner F. Outcome indicators for vitrectomy in Terson syndrome. Acta Ophthalmol. 2009;87:222–6.
13. Narayanan R, Taylor SC, Nayaka A, Deshpande R, St Aubin D, Hrisomalos FN, et al. Visual outcomes after vitrectomy for Terson syndrome secondary to traumatic brain injury. Ophthalmology. 2017;124:118–22.
14. Schulze-Bonsel K, Feltgen N, Burau H, Hansen L, Bach M. Visual acuities "hand motion" and "counting fingers" can be quantified with the freiburg visual acuity test. Investig Ophthalmol Vis Sci. 2006;47:1236–40.
15. Moisseiev E, Goldstein M, Waisbourd M, Barak A, Loewenstein A. Long-term evaluation of patients treated with dexamethasone intravitreal implant for macular edema due to retinal vein occlusion. Eye. 2013;27:65–71.
16. Hoving EW, Rahmani M, Los LI, Renardel, de Lavalette VW. Bilateral retinal hemorrhage after endoscopic third ventriculostomy: iatrogenic Terson syndrome. J Neurosurg. 2009;110:858–60.
17. He T, Wu LN, Chen B, Xing YQ. Incidence and relative factors of Terson syndrome in patients with aneurysmal subarachnoid hemorrhage. Zhonghua Yan Ke Za Zhi. 2011;47:1096–101.
18. Srinivasan S, Kyle G. Subinternal limiting membrane and subhyaloid haemorrhage in Terson syndrome: the macular 'double ring' sign. Eye. 2006;20:1099–101.
19. Gnanaraj L, Tyagi AK, Cottrell DG, Fetherston TJ, Richardson J, Stannard KP, et al. Referral delay and ocular surgical outcome in Terson syndrome. Retina. 2000;20:374–7.
20. Sayman Muslubas I, Karacorlu M, Hocaoglu M, Ersoz MG, Arf S. Anatomical and functional outcomes following vitrectomy for dense vitreous hemorrhage related to Terson syndrome in children. Graefes Arch Clin Exp Ophthalmol. 2018;256:503–10.
21. Yokoi M, Kase M, Hyodo T, Horimoto M, Kitagawa F, Nagata R. Epiretinal membrane formation in Terson syndrome. Jpn J Ophthalmol. 1997;41:168–73.
22. Mao X, You Z. 25G compared with 20G vitrectomy under Resight non-contact wide-angle lenses for Terson syndrome. Exp Ther Med. 2017;14:1193–7.
23. Schultz PN, Sobol WM, Weingeist TA. Long-term visual outcome in Terson syndrome. Ophthalmology. 1991;98:1814–9.
24. Sharma T, Gopal L, Biswas J, Shanmugam MP, Bhende PS, Agrawal R, et al. Results of vitrectomy in Terson syndrome. Ophthalmic Surg Lasers. 2002;33:195–9.
25. Roux FX, Panthier JN, Tanghe YM, Gallina P, Oswald AM, Merienne L, et al. Terson's syndrome and intraocular complications in meningeal hemorrhages (26 cases). Neurochir. 1991;37:106–10.
26. Velikay M, Datlinger P, Stolba U, Wedrich A, Binder S, Hausmann N. Retinal detachment with severe proliferative vitreoretinopathy in Terson syndrome. Ophthalmology. 1994;101:35–7.
27. Nacef L, Zghal-Mokni I, Allagui I, Haba B, Daghfous F, Gaigi S, et al. Indications and results of vitrectomy in Terson syndrome. La Tunis Med. 2004;82:461–4.
28. Augsten R, Konigsdorffer E, Strobel J. Surgical approach in terson syndrome: vitreous and retinal findings. Eur J Ophthalmol. 2000;10:293–6.
29. Daus W, Kasmann B, Alexandridis E. Terson syndrome. Complicated clinical course. Der Ophthalmol. 1992;89:77–81.
30. Shaw HE Jr., Landers MB 3rd. Vitreous hemorrhage after intracranial hemorrhage. Am J Ophthalmol. 1975;80:207–13.
31. Czorlich P, Skevas C, Knospe V, Vettorazzi E, Richard G, Wagenfeld L, et al. Terson syndrome in subarachnoid hemorrhage, intracerebral hemorrhage, and traumatic brain injury. Neurosurg Rev. 2015;38:129–36.