

LI

LABORATORY INVESTIGATION

THE BASIC AND TRANSLATIONAL PATHOLOGY RESEARCH JOURNAL

VOLUME 100 | SUPPLEMENT 1 | MARCH 2020

ABSTRACTS

AUTOPSY AND FORENSICS
(1-36)



USCAP 109TH ANNUAL MEETING
2020
EYES ON YOU

FEBRUARY 29-MARCH 5, 2020

LOS ANGELES CONVENTION CENTER
LOS ANGELES, CALIFORNIA

Published by
SPRINGER NATURE
www.ModernPathology.org

 **USCAP** AN OFFICIAL JOURNAL OF THE
UNITED STATES AND CANADIAN
ACADEMY OF PATHOLOGY
Creating a Better Pathologist

EDUCATION COMMITTEE

Jason L. Hornick, Chair
Rhonda K. Yantiss, Chair, Abstract Review Board
 and Assignment Committee
Laura W. Lamps, Chair, CME Subcommittee
Steven D. Billings, Interactive Microscopy Subcommittee
Raja R. Seethala, Short Course Coordinator
Ilan Weinreb, Subcommittee for Unique Live Course Offerings
David B. Kaminsky (Ex-Officio)
Zubair Baloch
Daniel Brat
Ashley M. Cimino-Mathews
James R. Cook
Sarah Dry

William C. Faquin
Yuri Fedoriw
Karen Fritchie
Lakshmi Priya Kunju
Anna Marie Mulligan
Rish K. Pai
David Papke, Pathologist-in-Training
Vinita Parkash
Carlos Parra-Herran
Anil V. Parwani
Rajiv M. Patel
Deepa T. Patil
Lynette M. Sholl
Nicholas A. Zoumberos, Pathologist-in-Training

ABSTRACT REVIEW BOARD

Benjamin Adam
Narasimhan Agaram
Rouba Ali-Fehmi
Ghassan Allo
Isabel Alvarado-Cabrero
Catalina Amador
Roberto Barrios
Rohit Bhargava
Jennifer Boland
Alain Borczuk
Elena Brachtel
Marilyn Bui
Eric Burks
Shelley Caltharp
Barbara Centeno
Joanna Chan
Jennifer Chapman
Hui Chen
Beth Clark
James Conner
Alejandro Contreras
Claudiu Cotta
Jennifer Cotter
Sonika Dahiya
Farbod Darvishian
Jessica Davis
Heather Dawson
Elizabeth Demicco
Katie Dennis
Anand Dighe
Suzanne Dintzis
Michelle Downes
Andrew Evans
Michael Feely
Dennis Firchau
Gregory Fishbein
Andrew Folpe
Larissa Furtado

Billie Fyfe-Kirschner
Giovanna Giannico
Anthony Gill
Paula Ginter
Tamara Giorgadze
Purva Gopal
Anuradha Gopalan
Abha Goyal
Rondell Graham
Alejandro Gru
Nilesh Gupta
Mamta Gupta
Gillian Hale
Suntrea Hammer
Malini Harigopal
Douglas Hartman
John Higgins
Mai Hoang
Mojgan Hosseini
Aaron Huber
Peter Illei
Doina Ivan
Wei Jiang
Vickie Jo
Kirk Jones
Neerja Kambham
Chiah Sui Kao
Dipti Karamchandani
Darcy Kerr
Ashraf Khan
Francesca Khani
Rebecca King
Veronica Klepeis
Gregor Krings
Asangi Kumarapeli
Alvaro Laga
Steven Lagana
Keith Lai

Michael Lee
Cheng-Han Lee
Madelyn Lev
Zaibo Li
Faqian Li
Ying Li
Haiyan Liu
Xiuli Liu
Yen-Chun Liu
Lesley Lomo
Tamara Lotan
Anthony Magliocco
Kruti Maniar
Emily Mason
David McClintock
Bruce McManus
David Meredith
Anne Mills
Neda Moatamed
Sara Monaco
Atis Muehlenbachs
Bita Naini
Dianna Ng
Tony Ng
Michiya Nishino
Scott Owens
Jacqueline Parai
Yan Peng
Manju Prasad
Peter Pytel
Stephen Raab
Joseph Rabban
Stanley Radio
Emad Rakha
Preetha Ramalingam
Priya Rao
Robyn Reed
Michelle Reid

Natasha Rektman
Jordan Reynolds
Michael Rivera
Andres Roma
Avi Rosenberg
Esther Rossi
Peter Sadow
Steven Salvatore
Souzan Sanati
Anjali Saqi
Jeanne Shen
Jiaqi Shi
Gabriel Sica
Alexa Siddon
Deepika Sirohi
Kalliopi Siziopikou
Sara Szabo
Julie Teruya-Feldstein
Khin Thway
Rashmi Tondon
Jose Torrealba
Andrew Turk
Evi Vakiani
Christopher VandenBussche
Paul VanderLaan
Olga Weinberg
Sara Wobker
Shaofeng Yan
Anjana Yeldandi
Akihiko Yoshida
Gloria Young
Minghao Zhong
Yaolin Zhou
Hongfa Zhu
Debra Zynger

To cite abstracts in this publication, please use the following format: **Author A, Author B, Author C, et al. Abstract title (abs#). In "File Title." *Laboratory Investigation* 2020; 100 (suppl 1): page#**

1 Characterizing the Lymphocyte Environment in Hospital Autopsy

Brian Adkins¹, Nicholas Jaeger¹, Nadine Aguilera²

¹University of Virginia Health System, Charlottesville, VA, ²University of Virginia Health System, Fredericksburg, VA

Disclosures: Brian Adkins: None; Nicholas Jaeger: None; Nadine Aguilera: None

Background: Lymphocyte populations in the blood of healthy individuals are well-characterized with normal accepted subsets including a CD4 to CD8 T-cell ratio of 2:1. This is of great utility in flow cytometric evaluation of the peripheral blood to determine if findings are reactive, neoplastic, or physiologic. However, lymphocyte populations are less well characterized in bone marrow specimens, with few recent studies available. Likewise, the lymphocyte environment in autopsy pathology appears to have not been investigated thus far. As such, we seek to better characterize the lymphoid environment of bone marrow in autopsy specimens.

Design: The laboratory information system natural language search was queried for autopsy cases from the past 18 months. 36 cases were identified with 18 decedents who died acutely as well as 18 decedents who died of infection. Rib squeeze bone marrow specimens were obtained from formalin fixed save materials. Immunohistochemical staining for CD3, CD20, CD4, and CD8 were performed and compared. Preliminary staining was performed on 10 cases (7 acute death decedents and 3 decedents with infection). CD4:CD8 ratios were quantified by two hematopathologists (BA,NA).

Results: Staining was adequate in the 10 cases examined. Cause of death in patients who died acutely was as follows: 3 sudden cardiac death, 2 myocardial infarction, 1 cerebrovascular accident, and 1 trauma; infectious cause of death were as follows: 2 sepsis and 1 bronchopneumonia. CD3 positive T-cells were scattered interstitially and more prevalent than CD20 positive B-cells in 90% (9/10) cases. Lymphoid aggregates were present in 30% (3/10) cases and 66% (2/3) were T-cell predominant. CD4 to CD8 ratios were low or inverted mean= 0.43:1 and ranged from 0.06-1:1.

Conclusions: These results identify low to inverted CD4:CD8 ratios in marrow compared to the accepted normal peripheral blood ratio. Scattered interstitial T- cells were more prevalent than B-cells overall. Lymphocyte composition was similar in sudden death and infectious death causes. These findings are helpful in interpretation of clinical bone marrows and avoid over interpretation of low or inverted CD4:CD8.

2 Correlation Between Fetal Autopsy and Postmortem Magnetic Resonance Imaging in Fetal Anomalies Terminated in the Second Trimester: A Preliminary Report

Hulya Akgun¹, Nahit Topaloglu², Filiz Karaman², Mahmut Ozgun², Mehmet Dolanbay², Mustafa Basbug²

¹Erciyes University, Kayseri, Turkey, ²Erciyes University Medical Faculty, Kayseri, Turkey

Disclosures: Hulya Akgun: None; Nahit Topaloglu: None; Filiz Karaman: None; Mahmut Ozgun: None; Mehmet Dolanbay: None; Mustafa Basbug: None

Background: The aim of the study was to compare the consistency of major/minor fetal anomalies detected by second trimester prenatal ultrasound examination with the findings in fetal autopsies and postmortem magnetic resonance (PMMR) findings following the termination of pregnancy (TOP) in the second trimester.

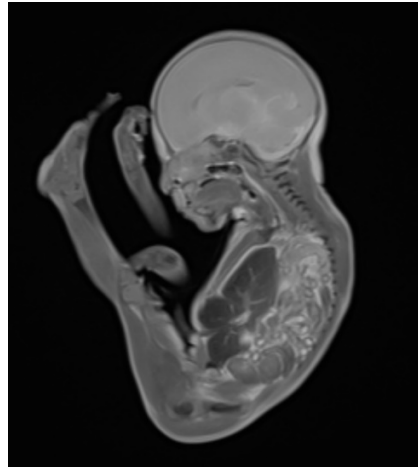
Design: In a 2-year long prospective study, 24 second-trimester TOP was performed due to fetal malformation diagnosed by second trimester-ultrasound examination at a tertiary referral center. All women accepted a postmortem MRI and an autopsy of the fetus. Prenatal ultrasound findings were compared with fetal autopsy and PMMR findings.

Results: We performed autopsy and postmortem magnetic resonance imaging in 24 fetuses. All fetuses had a postmortem whole body magnetic resonance completed before autopsy. There were central nervous system (CNS) anomalies (n=12), gastrointestinal tract anomalies (n=4) (including diaphragmatic hernia (n=2) Figure1-2), urinary tract malformations (n=3), musculoskeletal anomalies (n=2), cardiovascular anomalies (n=1), ascites (n=2). PMMR confirmed all CNS anomalies and major anomalies. Four extremity anomalies including polydactyl, (n=2), syndactyly (n=1), absence of foot (n=1), ventricular septal defect (n=1) and cleft lip and palate (n=1) were detected during autopsy but were not confirmed during the PMMR. Autopsy was not detected cerebellar hypoplasia (n=2), corpus callosum agenesis (n=2), chiari type 2 malformations (n=2), all were confirmed by PMMR. Among them, two CNS malformations were not detected by autopsy due to autolysis. When comparing the prenatal ultrasound, postmortem autopsy and PMMR, there were complete agreement in 14 cases (58%) and major agreement with additional findings in 10 cases (42%). There were no cases in total disagreement.

Figure 1 - 2

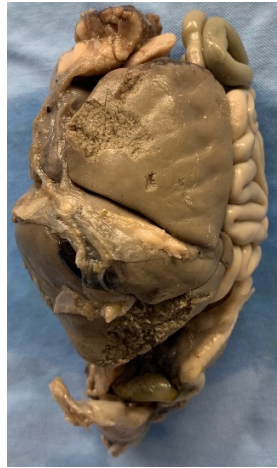

Figure 2 - 2



Conclusions: Perinatal autopsy is still gold standard for fetal anomalies, but PMMR could be helpful when autopsy is not performed or the family does not accept the autopsy. PMMR is an accurate technique for identifying CNS anomalies in fetuses, and may provide important information even in cases where autolysis present and relatively poor at detecting extremity anomalies and facial malformations.

3 Massive Cardiomegaly in a Newborn Secondary to Unsuspected Maternal Diabetes Mimicking Congenital Heart Disease: A Diagnosis Made at Autopsy

Buket Bagci¹, Cyril D'Cruz²

¹Saint Barnabas Medical Center, Springfield, NJ, ²St Barnabas Medical Center, Berkeley Heights, NJ

Disclosures: Buket Bagci: None; Cyril D'Cruz: None

Background: Fatal hypertrophic cardiomyopathy is a rare but devastating adverse outcome of gestational diabetes and prediabetes. Hypertrophic cardiomyopathy occurs in 40% of infants of diabetic mothers and is symptomatic in 5%. The heart is rich in insulin receptors and has an extensive capacity for insulin degradation. Fetal hypertrophic cardiomyopathy is believed to develop due to fetal hyperinsulinemia and increased expression of insulin receptors that causes proliferation and hypertrophy of cardiac myocytes.

Design: We report an autopsy of a macrosomic infant who presented with cyanosis at birth and a massively enlarged heart that mimicked congenital heart disease (CHD).

Results: This large for gestational age infant was born to a mother with a history of preeclampsia and obesity. Gestational diabetes was not suspected. The echocardiogram showed right atrial dilation, right ventricular hypertrophy, severe tricuspid regurgitation, suspicion for dysplastic pulmonic and tricuspid valves suggestive of CHD. The infant expired after 7 hours. The autopsy revealed a large for gestational age infant with a massively enlarged heart nearly 3 times the normal weight for age, greater than the combined weights of the lungs. There was marked hypertrophy of both ventricular walls and the septum with decreased ventricular volume. None of the valves showed any evidence of dysplasia or stenosis. The pancreas showed significant hyperplasia and hypertrophy of pancreatic islets with nuclear atypia and surrounding eosinophils, consistent with findings seen in infants of diabetic mothers. Prominent extramedullary hematopoiesis was noted in the liver. Macrosomia along with the cardiac, pancreatic and hepatic findings suggested the diagnosis of cardiomyopathy secondary to maternal diabetes.

Conclusions: Hypertrophic cardiomyopathy is a common finding in infants of diabetic mothers and most often resolves without intervention within the first 6 months of life. In general there is a direct correlation between the severity of diabetes and the cardiomyopathy but exceptions occur. The autopsy findings in the pancreas and liver, along with the hypertrophic cardiomyopathy suggested maternal diabetes. This would not have been diagnosed without an autopsy. Such pancreatic findings in stillbirth autopsies suggests possible maternal diabetes, are of value in management of future pregnancies. This case illustrates the importance of the autopsy in infants and stillborns.

4 Use of Next Generation Sequencing in the Postmortem Diagnosis of Proteus Syndrome

Tiffany Baker¹, W Bailey Glen Jr.¹, Nicholas Batalis¹, Daynna Wolff¹, Cynthia Welsh¹
¹Medical University of South Carolina, Charleston, SC

Disclosures: Tiffany Baker: None; Nicholas Batalis: None

Background: Somatic overgrowth syndromes result from spontaneous somatic mutations that arise early in development and display a mosaic pattern of expression. The temporal and anatomic heterogeneity of these syndromes result in variable phenotypes and clinical overlap. Furthermore, the variable ratio of mutated to non-mutated cells in patient tissue can result in low-level mutations that could be missed using Sanger sequencing. Recent literature points to next generation sequencing (NGS) as an adjunct to diagnosis in these rare entities. An adult male presented to our forensic autopsy service with physical features suggestive of Proteus syndrome. Due to the paucity of clinical information available, a definitive diagnosis of Proteus syndrome using accepted clinical criteria was not possible based only on gross and microscopic diagnosis.

Design: In addition to gross and microscopic examinations, whole exome NGS was performed on Deoxyribonucleic acid (DNA) extracted from formalin fixed paraffin embedded (FFPE) tissue from the affected, hemimegalencephalic portion of brain.

Results: The hyperostotic skull had right-sided bony protuberances that projected from the outer and inner surfaces resulting in a thickened appearance with associated deformation of the immediately adjacent brain tissue. The heavy brain (1,620 g) exhibited right hemimegalencephaly with an abnormal gyral pattern, cortical migration abnormalities, a 0.1 cm vascular malformation within the temporal lobe, and cystic degeneration of the caudate nucleus. Microscopically, there was increased thickness of the cortical ribbon and discrete cortical layers were indiscernible due to architectural disarray. Individual neurons displayed cytologic enlargement and abnormal distribution of Nissl substance, similar to focal cortical dysplasia type IIb. NGS demonstrated the causative variant *AKT1* (c.49G>A, p.Glu17Lys) in 14.13% of reads confirming Proteus syndrome. No *PTEN* variants were identified.

Conclusions: We report a case of a somatic overgrowth syndrome diagnosed at forensic autopsy with the aid of NGS as Proteus syndrome. To our knowledge this is the first report of the mosaic mutation detected in brain tissue and the first reported case of a post-mortem diagnosis of Proteus syndrome with the aid of NGS. We conclude that NGS may be used as an adjunctive method to support a specific diagnosis among the somatic overgrowth syndromes postmortem in the absence of sufficient clinical history.

5 A Characterization of NUT Carcinoma Presenting as an Obliterative Thoracic Tumor in a Young Adult Patient

Walter Beversdorf¹, Katherine Wang¹, Sharon Fox²

¹Louisiana State University Health Sciences Center, New Orleans, LA, ²SLVHCS/ Louisiana State University, New Orleans, LA

Disclosures: Walter Beversdorf: None; Katherine Wang: None; Sharon Fox: None

Background: NUT midline carcinoma (NMC) is a rare, aggressive, and occasionally misdiagnosed entity presenting as a poorly differentiated malignancy usually at midline sites within the head, neck, and mediastinum. Although traditionally associated with younger patients, it may affect any age group. Response to chemotherapy is characteristically poor and median survival is less than one year. Due to its rarity, poor differentiation, and a diagnostic definition requiring awareness of specific immunohistochemical or molecular methods, the potential for misdiagnosis is high.

Design: Autopsy was performed on a 29 year-old male with a large intrathoracic mass lesion originally diagnosed as non-small cell lung carcinoma (NSCLC), who rapidly deteriorated and succumbed within four months of initial diagnosis. At autopsy, the right hemithorax was diffusely infiltrated by malignant tissue. The right pleural surfaces were totally effaced with tumoral obliteration of 90% of the lung parenchyma, and there was lateral displacement of the heart (Fig. 1A). Residual lung parenchyma was disrupted by perivascular tumor spread (Fig. 1B). A 4 cm anterior mediastinal mass and regional lymphadenopathy were present.

Results: Sections showed poorly differentiated small to medium-sized cells with vaguely immunoblastic cytomorphology (Fig. 2A). Scattered foci showed squamous differentiation (Fig. 2B) within the anterior mediastinal mass determined to be likely thymus. Involvement of right lung parenchyma was predominantly solid, with pulmonary vascular cuffing (Fig. 2C). The left lung was normal. Diagnostic considerations included NSCLC, thymic carcinoma, germ cell tumor, and lymphoma. There was diffuse positivity for p63 within both solid poorly differentiated and scattered squamous components. CK7 was expressed only in non-neoplastic squamous epithelium. Malignant cells were negative for TTF-1 and c-kit. NUT immunohistochemical (IHC) staining revealed speckled nuclear positivity (Fig. 2D) consistent with NMC.

Figure 1 - 5

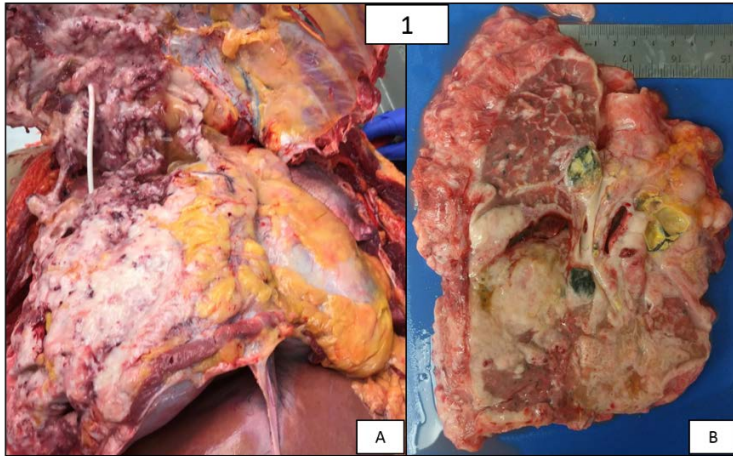
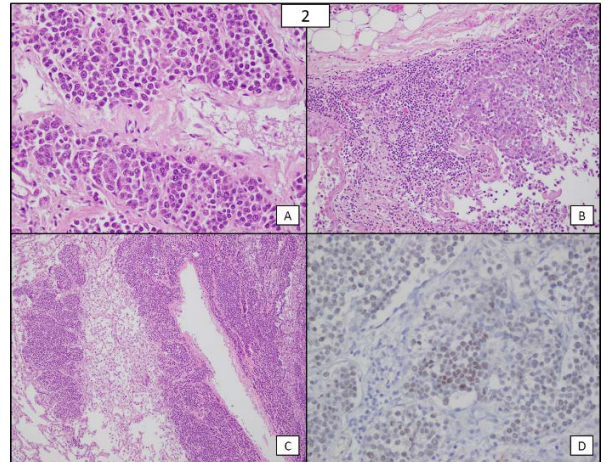


Figure 2 - 5



Conclusions: This case highlights the need for awareness of NMC as a rare and aggressive disease which may be overlooked in favor of more common thoracic malignancies. As a morphologically challenging entity characterized by poor tumor differentiation, NMC has potential to be misidentified as NSCLC on biopsy or cytologic material. Factors disfavoring the latter in this case include age and poor response to chemotherapy. Definitive diagnosis relies on evidence of NUT gene aberration by either IHC or molecular methods.

6 An Interdisciplinary, Family-Centered, Undiagnosed Disease Model for the Investigation of Sudden Unexpected Death in Pediatrics

Melissa Blessing¹, Christine Keywan¹, Sanda Alexandrescu¹, Sue Morris², Robin Haynes¹, Annapurna Poduri¹, Ingrid Holms¹, Catherine Brownstein¹, Hannah Kinney¹, Sara Vargas¹, Richard Goldstein¹

¹Boston Children's Hospital, Harvard Medical School, Boston, MA, ²Dana-Farber/Boston Children's Cancer and Blood Disorders Center, Boston, MA

Disclosures: Melissa Blessing: None; Christine Keywan: None; Sara Vargas: None

Background: Sudden infant death syndrome/sudden unexpected infant death (SIDS/SUID) and sudden unexplained death in childhood (SUDC) are poorly understood. Investigation of these deaths is under medicolegal (ML) system purview. However, several collaborative efforts with academic institutions have arisen as the need for expanded resources and a team approach to elucidate the mechanism/s of these deaths becomes clear. Our unique, family-centered model incorporates a large, interdisciplinary team to study SIDS/SUID and SUDC together as sudden unexpected death in pediatrics (SUDP).

Design: We analyzed the process of our program dedicated to the investigation of SUDP, and measured its success.

Results: The philanthropy and grant-funded program was founded in 2012 using the undiagnosed disease paradigm. It includes physicians specializing in primary care, genetics, neurology, endocrinology/metabolism, cardiology, radiology, palliative care, bereavement, neuropathology and pediatric pathology, researchers, and research laboratories. Participants are self-referred families whose previously well child died unexpectedly and without apparent cause have participated. All parent interactions explicitly incorporate bereavement support; individual and group counseling is provided. Following consent, diagnostic tissue, autopsy report and medical records are obtained from ML systems and prior healthcare providers respectively, and reviewed. Whole exome sequencing of decedent and parental DNA and secondary review of general and neuropathology is conducted, followed by exhaustive interdisciplinary review. When previously undiagnosed disease/s are established, these and other contributing factors are discussed with the family. In cases of heritable disease, referrals and anticipatory guidance is offered. In all cases, parents' worries are elicited and addressed. Publications in the program include novel findings on topics ranging from grief study to hippocampal malformation and high serum serotonin in these sudden and unexpected deaths.

Conclusions: Our institutional program offers an alternative approach to traditional SUDP evaluation, providing family-centered care via a highly interdisciplinary clinical and research effort which encourages strategies and exploration within the scientific method framework. This approach models the undiagnosed disease paradigm and addresses largely overlooked needs in bereaved parents while moving closer to uncovering the biologic substrates of sudden unexpected death in pediatrics.

7 3D Modelling as a Tool for Reproducing Macroscopic Examination of Unique Pathology Specimens: Vein of Galen Malformation

Kyriakos Chatzopoulos¹, Tyler Mann¹, Joseph Parisi¹, Reade Quinton¹
¹Mayo Clinic, Rochester, MN

Disclosures: Kyriakos Chatzopoulos: None; Tyler Mann: None; Joseph Parisi: None; Reade Quinton: None

Background: Macroscopic examination of surgical pathology and autopsy specimens is the cornerstone of anatomic pathology practice, guiding the selection of tissues for microscopic examination and application of further ancillary studies. In contrast to conventional microscopy, immunohistochemistry, and molecular methods which are all reproducible, macroscopic examination can only be performed once. Reconstruction of an already dissected specimen is sometimes awkward if not impossible, depriving pathologists and trainees from the opportunity to learn from uncommon or unique surgical or autopsy pathology specimens. Photographs before and during dissection can be of assistance, but are still limited by two dimensions. A vein of Galen malformation (VOGM) is a rare congenital form of arteriovenous shunt, occasionally diagnosed on fetal ultrasound. We attempted to reconstruct brain macroscopic findings from an infant who died of VOGM by using 3D modelling technology.

Design: A premature infant, born at 32 weeks of gestation, with an antenatal diagnosis of VGAM and resulting hydrops fetalis died on day 8 of life. A consented autopsy was performed and the brain was submitted for evaluation to neuropathology. We used the Artec3D Space Spider scanner and Artec Studio 13 Software (Santa Clara, CA, United States) to capture and print a model depicting in situ findings during brain cutting.

Results: We identified a 2.5 cm VOGM, filling the third ventricle and originating from both posterior cerebral arteries, primarily from an enlarged and duplicated left posterior cerebral artery (Figure 1). The lesion caused thinning of the third ventricular floor, left-to-right displacement of midline septi and crater-like depression of the right lateral ventricular wall. We produced a 3D model of the brain with a removable cerebellum and brainstem (Figure 2), which can be used to reproduce the findings seen in situ on the specimen when dissecting off the cerebellum and midbrain.

Figure 1 - 7

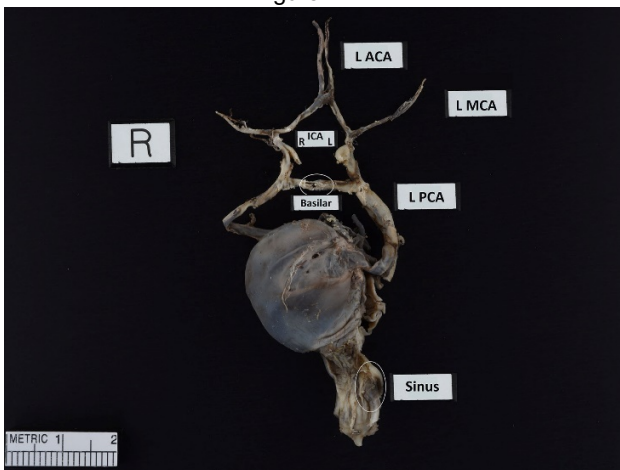
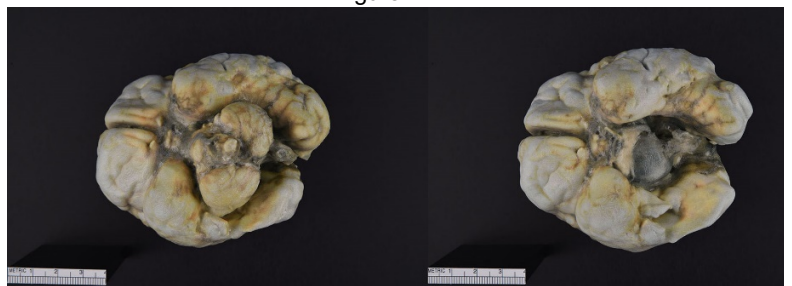

Figure 2 - 7



Conclusions: 3D modelling is an effective method for preserving and reproducing key features of macroscopic examination of unique pathology specimens, as demonstrated in the present case of a vein of Galen malformation.

8 Fluorine Detection in the Lung Tissue of a Worker with Interstitial Pulmonary Fibrosis and Long-Term Occupational Exposure to Polytetrafluoroethylene and Perfluorooctanoic Acid

Jeffrey Covington¹, Michele Von Turkovich¹, Douglas Taatjes², John DeWitt¹, Kelly Butnor¹
¹The University of Vermont Medical Center, Burlington, VT, ²Larner College of Medicine at the University of Vermont, Burlington, VT

Disclosures: Jeffrey Covington: None; Michele Von Turkovich: None; Douglas Taatjes: None; John DeWitt: None; Kelly Butnor: None

Background: Polytetrafluoroethylene (PTFE) has a wide variety of industrial and consumer applications, including use as non-stick coating on cookware. Inhalation of fumes generated from heating PTFE to high temperatures can result in acute lung injury. Aside from several reports of granulomatous pneumonitis in PTFE spray workers, it is uncertain whether long-term exposure to PTFE and compounds used in its manufacture, such as perfluorooctanoic acid (PFOA), cause chronic lung disease.

Design: Scanning electron microscopy and energy-dispersive x-ray spectroscopy (SEM-EDS) were performed to determine the nature of foreign material in the lung tissue of a 71-year-old man with a 25-year history of occupational exposure to PTFE and PFOA, who died following a brief illness clinically suspected to be adult respiratory distress syndrome (ARDS). Available clinical records were extremely limited and did not indicate whether there was a history of pre-existing pulmonary disease.

Results: The lungs demonstrated late exudative and early organizing diffuse alveolar damage (DAD) superimposed on a background of interstitial pulmonary fibrosis. The pulmonary fibrosis was mature, lacked definitive fibroblastic foci, and featured subpleural and lower lobe accentuation and focal subpleural microscopic honeycomb change. Within the fibrotic lung parenchyma were scattered giant cells containing birefringent translucent variably shaped 5-7 micron particles. Other occasional giant cells featured amorphous ferruginous material and a few giant cells contained rounded to psammomatous basophilic calcifications. Sparse extracellular anthracotic pigment was also observed. Well-formed granulomas and silicotic nodules were not appreciated. EDS analysis showed a prominent peak for fluorine in some of the foreign material. Complex spectra that included peaks for a variety of elements including magnesium and silicon were observed in some of the other probed foreign particles.

Conclusions: This is the first report of which we are aware to document the presence of fluorine, which is an elemental constituent of PTFE and PFOA, associated with giant cells in fibrotic lung tissue. Careful evaluation of other individuals with long-term exposure to PTFE and PFOA appears warranted to better elucidate the spectrum of pulmonary disease caused by these compounds.

9 A Re-Evaluation: Acute Kidney Injury (AKI) Patterns are Similar in Human Autopsy Kidneys and Rat Kidneys Despite Differences in Renal Tubule Structure

Shamaya Creagh¹, Jacqueline Macknis², Ping Zhang³

¹Beaumont Hospital, Royal Oak, MI, ²William Beaumont Hospital, Royal Oak, MI, ³William Beaumont Hospital, Birmingham, MI

Disclosures: Shamaya Creagh: None; Jacqueline Macknis: None; Ping Zhang: None

Background: Preclinical pharmaceutical studies have shown beneficial effects on rat AKI; however, based on several recent reviews, the studies have failed to show effects that benefit human AKI. While there are variations in the design of each study reviewed that may contribute to the discrepancy, differences in kidney structures and disease progression scenarios between human (short S3 renal tubule segment and AKI in aging kidneys that often occurs with diabetic/hypertensive damage) and animals (long S3 renal tubule segment and AKI models induced in rats that have non-injured kidneys) can also be two main possibilities to explain the outcome discrepancy. Using a specific injury marker of proximal tubules called kidney injury molecule-1 (KIM-1), this study compares AKI patterns between full sections of human autopsy kidneys and rat kidneys allowing for identification of kidney structural related differences in the AKI patterns. Despite the presence of renal autolysis in autopsy specimen KIM-1 has proven reliable for identifying AKI.

Design: In the animal model, 28 rats underwent induced renal ischemia (resulting in varying levels of AKI, from mild to moderate to severe acute tubular injury). Their serum creatinine levels (sCr) were measured; and the kidneys were then stained for KIM-1 to allow for AKI evaluation. In humans, 52 autopsy cases from adult patients were retrospectively reviewed for sCr and KIM-1 expression in full kidney sections.

Results: All control rat kidneys showed an absence of stains for KIM-1. In ischemic kidneys, with mild to severe ATI, there was dominant upregulation of KIM-1 expression in the S3 segment of ischemic rat models, followed by slightly less upregulation in the S2 segment and mild upregulation in the S1 segment of rat kidneys. In human autopsy kidneys, 19 normal kidneys stained negatively for KIM-1, and served as controls. Thirty-three cases stained positively for KIM-1, with dominant KIM-1 upregulation in the S3 segment, followed by less upregulation in the S2 segment, and the least upregulation in the S1 segment. KIM-1 staining scores (0, 1+, 2+ and 3+ intensity) were directly correlated with sCr in both the animal ischemic model and in the human autopsy kidney cases.

Conclusions: Despite the structural difference in the S3 segment of human and rat renal tubules, our data indicates that the AKI patterns are similar between the human and rat models. This finding implies that the difference in structure may not be the main reason for the non-reproducibility of beneficial effects o

10 Pathologic Findings in the Adrenal Gland in Adult Autopsies: A Ten-Year Community Teaching Hospital Experience

Sapna Desai¹, Gagandeep Kaur¹, Kaitlyn Williams¹, Ramapriya Vidhun², Jessica Dodge¹

¹Danbury Hospital, Danbury, CT, ²Western Connecticut Health Network, Danbury Hospital, Danbury, CT

Disclosures: Sapna Desai: None; Gagandeep Kaur: None; Kaitlyn Williams: None; Ramapriya Vidhun: None; Jessica Dodge: None

Background: Much of the published literature focuses on neoplastic adrenal gland pathology. In this study we report the prevalence and age distribution of neoplastic and non-neoplastic adrenal gland pathology seen adult hospital autopsies over a ten-year period in our institution.

Design: The laboratory information system was searched for autopsies that were performed between 1/1/2009 and 12/31/2018. Autopsies that had abdominal restrictions and patients <18 years old were excluded. The autopsy reports were reviewed and the following data were recorded: accession number, age, sex and adrenal gland pathology.

Results: Out of 383 autopsies in which the adrenal glands were examined, 61 patients (16%) had adrenal gland pathology. One patient had two pathologic findings (adrenocortical adenoma and cortical hyperplasia). Thirty-six of the 62 pathologic findings (58%) were neoplastic and 17 of the neoplasms (47%) were malignant. Seventeen patients (28%) had secondary malignancy involving the adrenal gland, 16 (26%) had adrenocortical adenomas, 8 (13%) had cortical hyperplasia, 8 (13%) had hemorrhage and/or necrosis, 4 (7%) had dystrophic calcifications, 3 (5%) had lipoma, 2 (3%) had amyloid, 2 (3%) had lymphoplasmacytic inflammation of the cortex, 1 (2%) had hyaline thickening of periarterioles and 1 (2%) had infarction (Table 1). The average cortical adenoma size was 1.2 centimeters. The most common origins of secondary malignancy were lung (5), lymphoma (4), breast (2) and colon (2). Six patients of out 12 (50%) had bilateral metastases. The average age of patients with pathologic findings was 67 years in males (range 37 to 90 years) and 55 years in females (range 39 to 94 years).

Table 1. Pathologic Findings in Adrenal Glands (n=62)

Finding	No. (%)
Metastatic Carcinoma	12 (19%)
Lymphoma/Leukemia	5 (8%)
Adrenocortical Adenoma	16 (26%)
Cortical Hyperplasia	8 (13%)
Hemorrhage and/or Necrosis	8 (13%)
Dystrophic Calcifications	4 (7%)
Others	9 (15%)

Conclusions: Adrenal gland pathology was relatively common (16% prevalence) in this ten-year study of adult hospital autopsies. The majority of pathologic findings (58%) were neoplastic and all of the malignant findings were secondary neoplasms. Prior autopsy review studies have shown that the lung is the most common primary site of adrenal metastasis which was concurrent with our findings.

11 Disseminated *Microascus gracilis* Infection in a Lung Transplant Patient

Yanna Ding¹, Lisa Steed¹, Nicholas Batalis¹

¹Medical University of South Carolina, Charleston, SC

Disclosures: Yanna Ding: None; Lisa Steed: None; Nicholas Batalis: None

Background: *Microascus gracilis* belongs to the family *Microascaceae*. Some species of this family have been involved in cutaneous and brain abscesses, invasive sinusitis, peritonitis and endocarditis and a few are recognized as opportunistic pathogens in animals and humans. While *M. gracilis* has been isolated from human bronchoalveolar lavage fluid and sputum samples, it has never been reported as a cause of significant infection in humans.

Design: We report a case of disseminated *Microascus gracilis* infection in a 67-year-old man with a history of primary idiopathic pulmonary fibrosis, status post bilateral lungs transplant. His course was complicated by donor lung cultures positive for multiple organisms and post-transplant infections. He had worsening hypoxic respiratory failure, hypotension, renal failure, and poor mental status. Imaging showed scattered hemorrhagic and hypodense lesions involving the brain. Multiple pleural fluid cultures grew *M. gracilis*. The patient eventually succumbed to his infection and an unrestricted autopsy with histologic sampling was performed.

Results: Autopsy findings included multiple skin ulcerations and hemorrhagic foci and abscesses involving the cerebral hemispheres, basal ganglia, midbrain, left ventricle and right cerebellum (Figure 1. A.); numerous punctuate tan-white circular lesions in the endomyocardium; and a tan exudate covering the pericardium and lungs. On histological examination, similar appearing fungal organisms along with hemorrhage, neutrophilic inflammation, and necrosis were identified in the brain, lungs, and heart (Figure 2.). The fungus appeared as branching septate hyphae with conidiogenous cells on hyphae and short chains of conidia. Fungal culture of brain tissue on inhibitory mold agar showed dark colonies with mostly brown mycelia (Figure 1. B.). The fungus was identified as *M. gracilis* by morphology and DNA sequencing of the D1/D2, TUB, and TEF loci.

Figure 1 - 11

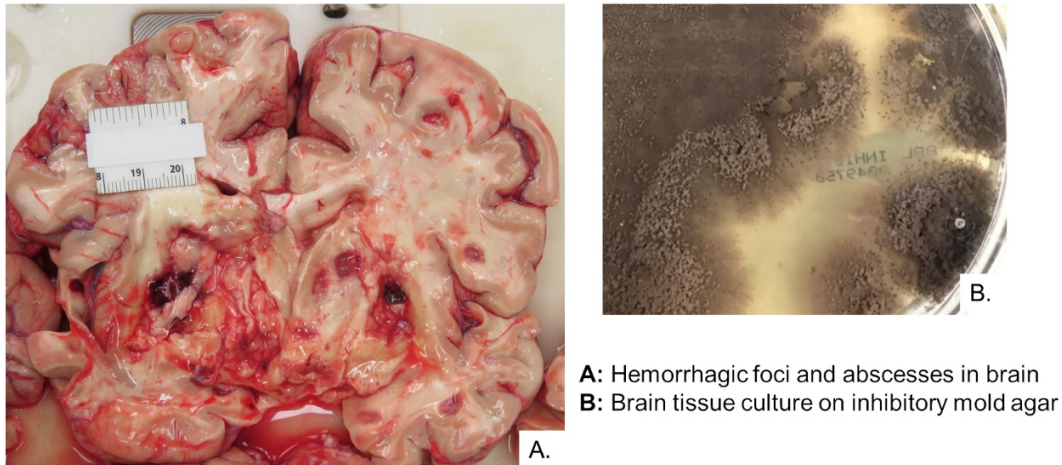
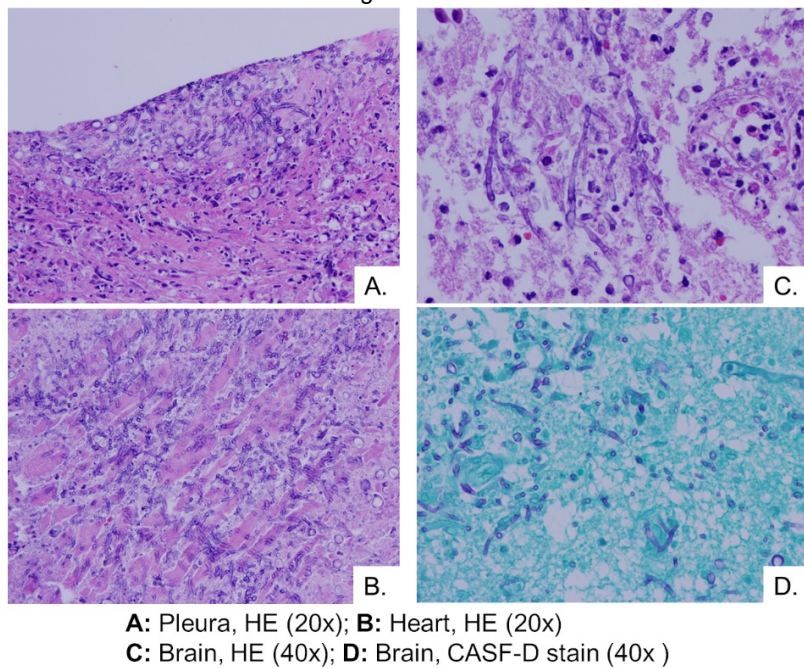


Figure 2 - 11



Conclusions: This is the first reported case of disseminated *M. gracilis* infection in an immunosuppressed human, illustrating that *M. gracilis* is another opportunistic pathogen in the family *Microascaceae*. It can cause local infections in its usual residential location in the lungs and disseminated infections in other organs including the heart and brain. Hopefully, this case increases our awareness of such opportunistic infections, particularly in lung transplant patients, and urges earlier aggressive prophylaxis, diagnosis, and treatment.

12 Meningeal Solitary Fibrous Tumor/Hemangiopericytoma in a Patient with a Remote Extensive ACA/MCA Infarction

Nibras Fakhri¹, Luis Del Valle², Sharon Fox³

¹LSUHSC- New Orleans, New Orleans, LA, ²Neurological Cancer Research, Louisiana State University Health, New Orleans, LA, ³SLVHCS/ Louisiana State University, New Orleans, LA

Disclosures: Nibras Fakhri: None; Luis Del Valle: None; Sharon Fox: None

Background: Meningeal Solitary Fibrous Tumors / Hemangiopericytomas are rare mesenchymal non-meningothelial tumors originating from the dura, accounting for 0.4% of primary intracranial neoplasms. These tumors are often supratentorial, usually toward the dorsal surface of the brain and occur in adults from the fourth to sixth decades of life. They were previously classified separately, as two different entities, however, because of molecular studies that revealed a common NAB2-STAT gene fusion, they are now considered a single entity

with a spectrum that ranges from more fibrous tumors that are considered low grade, to highly cellular neoplasms, that were previously considered hemangiopericytomas, and are now classified as high-grade tumors.

Design: Here we present a rare case of a solitary fibrous tumor found at the time of autopsy of a 62 year-old male, unusual because it grew in a large area of encephalomalacia left by a remote, reabsorbed MCA/ACA stroke.

Results: Solitary Fibrous Tumors usually presented as painless mass, often without any associated symptoms, and in our case, the large cavity left by the stroke allowed the tumor to grow to a considerable size of 7 x 4 cm without detection. Histologically, the tumor was hypocellular, fibrotic areas, mixed with thin-walled, branching vessels in a staghorn pattern. The patient presented with radiologic and immunohistochemical features that favor Hemangiopericytoma (HPC). Immunoassaying of CD34 and BCL2 demonstrated tumor positivity. Further analysis, including STAT6 immunostain, showed diffuse nuclear positivity within malignant cells, supporting our diagnosis.

Figure 1 - 12

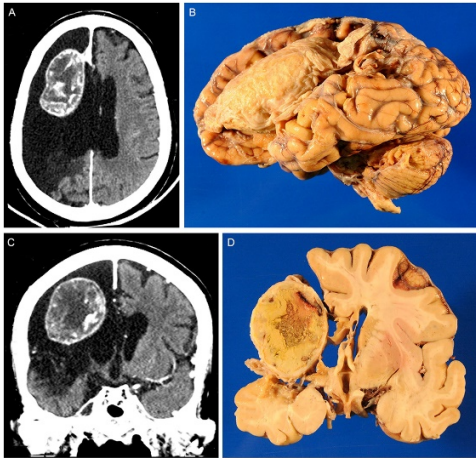
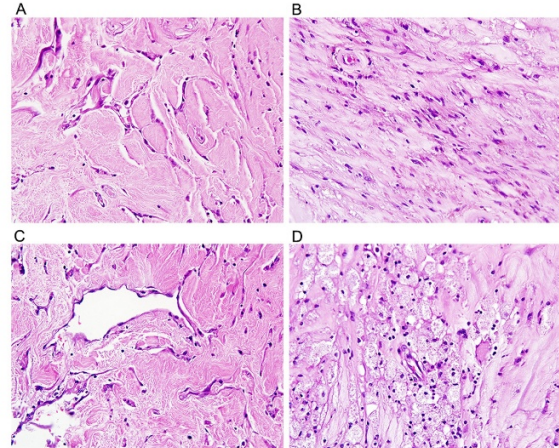


Figure 2 - 12



Conclusions: The histogenesis of hemangiopericytomas remains unclear. Most HPC are near-diploid, and breakpoints in 12q13, 12q24 and 19q13 seem to be common, with recurrent t(12;19)(q13; q13) translocations. To date, it is still considered a rare neoplasm and constitute 0.4% of CNS tumors. Hemangiopericytoma is a soft tissue tumor derived from mesenchymal cells with pericyte differentiation. The total removal of the tumor followed by postoperative- adjuvant radiotherapy is the mainstay of treatment.

13 Aorto-Digestive Fistulas: An Uncommon Cause of Acute and Fatal Gastrointestinal Bleeding. A 29-Year Retrospective Study of Autopsy Case Series

Irene Fernández¹, Tamara Zudaire¹, Luiz M Nova¹, Alba Larrea¹, Gregorio Aisa², Irene Amat¹, Angel Panizo¹
¹Complejo Hospitalario de Navarra, Pamplona, Navarra, Spain, ²Complejo Hospitalario de Navarra, Pamplona, Spain

Disclosures: Irene Fernández: None; Tamara Zudaire: None; Luiz M Nova: None; Alba Larrea: None; Gregorio Aisa: None; Irene Amat: None; Angel Panizo: None

Background: Aorto-digestive fistula (ADF) is an uncommon (incidence: 0.04-0.07% in autopsy series) but lethal life-threatening condition, due to acute gastrointestinal bleeding. Aorto-duodenal fistula is the most frequent. ADF may be primary or secondary. The former occurs in patients with aortic aneurysm, while secondary causes involve foreign body ingestion, trauma, carcinoma, aortic/digestive stents or, rarely, aortic/digestive perforated infections.

Design: The database of adult autopsy cases was consulted to identify autopsies performed on patients with ADF at our institution within the last 29 years. Clinical data was obtained through medical record review, and autopsy macroscopic and microscopic pathologic data were reviewed in detail.

Results: 2913 autopsies within the past 29 years (1990-2018) were reviewed. We report seven retrospective cases of acute digestive hemorrhage due to ADF: 2 duodenal, and 5 esophageal ADF. Six patients (85.7%) were male. The age range was 46 to 85 years, with a median age of 67 years. In 3 cases the ADF was primary (aortic aneurysm): 2 duodenal and 1 esophageal. Two esophageal ADF were secondary: one carcinoma and one invasive perforated esophageal mycosis. Two esophageal ADF were combined primary and secondary: one aortic aneurysm+squamous carcinoma, and one aortic aneurysm+esophageal amyloidosis and perforation due to foreign body ingestion. All but one patient (85.7%) presented with severe acute gastrointestinal bleeding and hypovolemic shock. The remaining patient presented acute dysphagia and chest pain. None of them reached the pre-mortem diagnosis, despite clinical suspicion in one of the

cases. The overall mortality rate was 100% as all patients died in the early period: the average survival time from the onset of symptoms was 14 hours (range: ½ -48 hours).

Figure 1 - 13

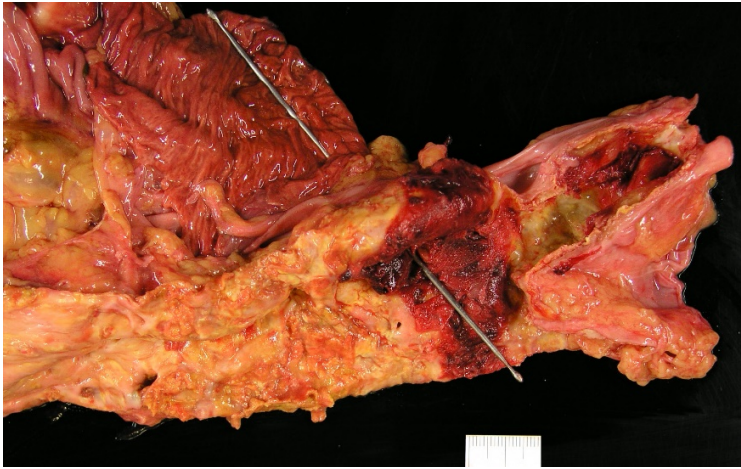
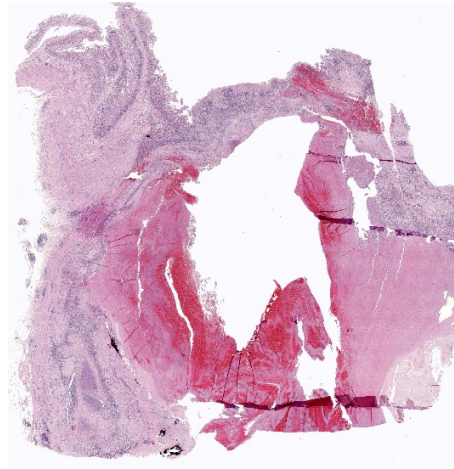


Figure 2 - 13



Conclusions: Aorto-digestive fistula is a very rare clinical entity. Thoracic or abdominal aortic aneurysms are the most common cause (primary). In our series, aorto-esophageal fistula was the most frequent ADF (71.4%). All but one cases presented with acute gastrointestinal bleeding and shock. Patients with ADF remain a challenging diagnostic and therapeutic problem: ADF should be considered in cases with acute gastrointestinal hemorrhage of obscure origin. Clinical diagnosis of ADF is often difficult because of its extreme rarity, and although it was considered in one patient, the diagnosis was not made until the time of autopsy in all of our patients.

14 Discrepancies between Clinician-Reported Cause of Death and Pathologist-Reported Cause of Death

Kara Gawelek¹, Robert Padera¹, Michelle Siciliano², Jacob Plaisted²

¹Brigham and Women's Hospital, Boston, MA, ²Brigham and Women's Hospital Pathology, Boston, MA

Disclosures: Kara Gawelek: None; Robert Padera: None; Michelle Siciliano: None; Jacob Plaisted: None

Background: Accurate reporting of mortality statistics is critical for monitoring of public health, medical research, and evaluation of antemortem medical interventions. Despite their importance, death reports may be inaccurate due to incomplete clinical information at the time of death or incorrect classification of underlying disease cause. Autopsies provide the gold-standard methodology for determination of the precise cause of death and may reveal antemortem diagnostic errors in up to 30% of cases. Thus, causes of death based on autopsy findings provide a more accurate diagnostic picture and are written by pathologists trained in death reporting. In historical reports, the extent of disagreement between clinical death reports and autopsy reports showed major disagreements in up to 29% of cases, and in an additional 26%, the death was attributed to a different specific disease.

Design: Institutional archives were searched for autopsies with completely documented clinician and pathologist reports of death completed over an 8 year period (2011-2019). Findings were categorized by organ system or injury in accordance with WHO ICD-10 code definitions. Discrepancies were flagged as major (change in disease category) or minor (disease within same category).

Results: A total of 520 cases were available for review. The cause of death was reported as "cardiac arrest", "PEA arrest", or "cardiorespiratory failure" in 71 (13.7%) of cases. Of the remaining cases (449), there was a discrepancy between clinical and autopsy principle cause of death in 203 (45.2%). The disease category was discrepant in 120 (26.7%). In 83 cases (18.5%), the autopsy cause of death reported an alternative diagnosis within the same disease category. Clinicians commonly reported mechanisms or sequelae of a disease process, rather than the underlying initial disease.

Conclusions: Conclusion: Pathologist-reported cause of death based on anatomical autopsy findings frequently differs from clinician reported cause of death. In the majority of discrepant cases, error stemmed from misclassification of underlying disease versus sequelae or mechanisms of death. A proportion of clinical reports included mechanism of death without an associated disease process. These findings highlight a need for clinical education with regards to appropriate death reporting.

15 Patterns of Mortality in Sickle Cell Disease, Has Anything Changed? An Autopsy Study

Rachel Geller¹, Mario Mosunjac², Uma Krishnamurti², Marina Mosunjac²
¹Fulton County Medical Examiner, Atlanta, GA, ²Emory University, Atlanta, GA

Disclosures: Rachel Geller: None; Mario Mosunjac: None; Uma Krishnamurti: None; Marina Mosunjac: None

Background: Few studies have examined autopsy findings in sudden death of adults with sickle cell disease (SCD). An understanding of factors contributing to sudden death in SCD can provide useful information not only for counseling the patients (PT) and their families but also for directing future research in efforts to reduce mortality and morbidity. Here we aim to determine the circumstances, causes of death, patterns of initial clinical presentation before death, and associations among pathological autopsy findings that may have contributed to the sudden unexpected death of patients with known SCD, and assess changes

Design: A retrospective comparison study of 44 autopsy cases of SCD PTs in a single institution, from two different time cohorts (1990-2003 and 2010-2019) was performed. Antemortem data, including demographics and clinical presentations, were collected from electronic medical records. Cause of death and major histopathological findings contributing to PTs' demise was extracted from the autopsy reports.

Results: 44 cases of SCD autopsies from two distinct time cohorts were identified. The average PT ages of Groups 1 and 2 are 31.3 years and 43.1 years. In each cohort, 13 PTs presented with pain crisis (61.9% Group 1 vs. 56.5% Group 2), 4 presented with sepsis or infection (19.1% Group 1 vs. 17.4% Group 2), and 2 presented with neural symptoms (9.5% Group 1 vs. 8.7% Group 2). 2 PTs in Group 1 (9.57%) and 4 PTs in Group 2 presented with acute tubular necrosis (17.4%). In each group, 7 PTs died from sepsis (33.3% Group 1 vs. 30.4% Group 2) and 4 died from sudden cardiac death (19.1% Group 1 vs. 17.4% Group 2). The cause of death was respiratory failure for 7 PTs in Group 1 (33.3%) and 6 PTs in Group 2 (26.1%). All PTs were found to have other major pathological findings contributing to death. 8 PTs in Group 1 and 3 PTs in Group 2 had thromboembolism (38.1% vs. 13%), and 7 PTs in Group 1 and 3 PTs in Group 2 had pulmonary hypertension (33.3% vs. 13%).

	GROUP 1	GROUP 2
Time cohort	1990-2003	2010-2019
Number of autopsies	N = 21	N = 23
Male	8 (38%)	12 (52.1%)
Female	13 (62%)	11 (47.9%)
Average age	31.3 years	43.1 years
Hospitalization less than 48 h	11 (52.3%)	9 (39.1%)
Clinical presentation		
Pain crisis	13 (61.9%)	13 (56.5%)
Sepsis /infection	4 (19.1%)	4 (17.4%)
Acute tubular necrosis	2 (9.5%)	4 (17.4%)
Meningitis/CNS bleed	2 (9.5%)	2 (8.7%)
Cause of death		
Respiratory failure	7 (33.3%)	6 (26.1%)
Sepsis	7 (33.3%)	7 (30.4%)
Sudden cardiac death	4 (19.1%)	4 (17.4%)
Other	3 (14.3%)	6 (26.1%)
Major pathology contributing to death		
Pulmonary edema	10 (47.6%)	12 (52.2%)
Thromboembolism	8 (38.1%)	3 (13%)
Fat emboli	7 (33.3%)	5 (21.7%)
Pulmonary hypertension	7 (33.3%)	3 (13%)
Vaso-occlusive thrombi	6 (28.5%)	4 (17.4%)
Right ventricular hypertrophy	7 (33.3%)	3 (13%)

Conclusions: To the best of our knowledge this is the largest study of autopsy cases of SCD PTs. While the clinical presentations in PTs who died are similar in the two era, we see an increase in average age of death in the later time cohort. This may reflect improved survival due to advances in supportive care, disease modifying therapy with hydroxyurea and possibly, access to care. In addition, pulmonary embolism and pulmonary hypertension were less frequent than what was noted in the previous era.

16 Does In Utero Meconium Passage in Term Stillbirth Correlate with Autopsy and Placental Findings of Hypoxia or Inflammation?

Suzanne Jacques¹, Faisal Qureshi¹
¹Harper University Hospital, Detroit, MI

Disclosures: Suzanne Jacques: None

Background: The cause of meconium passage in utero is controversial, traditionally considered evidence of fetal stress and hypoxia, and also associated with intra-amniotic inflammation/infection. It is now recognized to also occur in the absence of fetal stress. Autopsy studies have shown that many term stillborns (SB) have hypoxic/ischemic brain injury and other evidence of stress preceding the time period immediately before demise, including acute thymic involution (ATI); however, these findings, along with placental findings, have not been previously correlated with meconium stained amniotic fluid (MSAF).

Design: 35 structurally normal singleton term SB (21 early term, 14 full/late term) with complete autopsies, including brain and placental examination, were identified. MSAF was documented at delivery and confirmed on placental examination. Autopsy evaluation included brain injury and ATI. Placental evaluation included maternal and fetal vascular malperfusion and acute and chronic inflammatory lesions. Demographic and clinical features were compared.

Results: 18 (51%) SB had MSAF, and 17 (49%) had clear amniotic fluid (CAF). There was no significant difference in brain injury in the MSAF vs CAF group, including older gray matter injury (karyorrhexis) (67% vs 47%), recent gray matter injury (red neurons, but no karyorrhexis) (28% vs 35%), white matter injury (50% vs 24%), and hemorrhage (22% vs 24%). Severe ATI was more frequent in the MSAF vs CAF group (61% vs 24%, p=0.04). There was no significant difference in placental lesions between groups, including acute maternal inflammation (39% vs 18%), acute fetal inflammation (6% vs 6%), fetal vascular malperfusion (11% vs 18%), maternal vascular malperfusion (39% vs 35%), and chronic inflammatory lesions (39% vs 29%). The MSAF group was more likely to be full/late term than early term (72% vs 28%), in contrast to the CAF group (6% vs 94%) (p= 0.0001). There was no difference in other clinical factors evaluated.

Conclusions: 51% of term SB had MSAF, and, in contrast to the CAF group, these were more likely to be full/late term. Severe ATI was more frequent with MSAF, consistent with a longer interval of stress before demise. Brain injury was frequent in both MSAF and CAF groups, supporting a role for hypoxia in most term SB. No placental lesions correlated with MSAF, including inflammation. This suggests MSAF in SB is a function of older gestational age, likely superimposed on underlying pathologic processes leading to demise, including hypoxia.

17 Suicide in Children in El Paso County: A Consecutive Case Series

Heather Jones¹, Mario Rascon²

¹Texas Tech University Health Sciences Center Paul L. Foster School of Medicine, El Paso, TX, ²El Paso County Office of the Medical Examiner, El Paso, TX

Disclosures: Heather Jones: None; Mario Rascon: None

Background: There is growing concern about suicide in the US, as rates have continued to rise despite national initiatives aiming to reduce the number of deaths from suicide. It was the second leading cause of death in people aged 10-34 in 2017, posing a unique threat to young people in particular. This study aims to qualitatively examine the factors surrounding child suicides in the unique population of El Paso County over a 15 year period.

Design: Performed retrospective case review of all records with final manner of death listed as "suicide" in people aged 18 and younger in El Paso County from 2004 to 2018. Records included autopsy, investigative, and police reports, medical records, death certificates, and other documents found in official case records.

Results: A total of 61 cases were examined. Ages ranged from 11 to 18 with a median age of 16. Suicides were composed of 73.8% males and 26.2% females. The rates of child suicides loosely reflected the makeup of the population of El Paso: Hispanics (75.4% of cases, 83.0% of population), non-Hispanic whites (18.0% of cases, 11.6% of population), blacks (1.6% cases, 3.9% population), Asians (1.6% of cases, 1.3% of population), and Native Americans (3.3% of cases, 0.2% of population). Most of the cases involved children residing in El Paso County (86.9%), but some cases involved children visiting family from elsewhere in Texas (3.3%) and children residing in New Mexico who were transported to El Paso for medical care before death (9.8%). The most common method of suicide was hanging (50.8%), followed by gunshot wound to head (37.7%), overdose (6.6%), and jump from height (4.9%). Males were most likely to complete suicide via hanging (55.6%), whereas females were most likely to utilize a firearm (50.0%). The most common location by far to complete suicide was at the child's home (78.7%), specifically in the child's bedroom (39.3%).

Conclusions: Our study results align with and therefore strengthen the findings of other studies of suicide in young people, including the increased incidence of suicide with age, utilization of hanging as the most common means of suicide, high incidence of suicide completion

at home, and high male: female ratio. However, our study also brings to light information about child suicide in a unique region located on the border of Texas, New Mexico, and Mexico where the majority of the population is Hispanic.

18 Thyroid Pathology in Adult Autopsies: A Ten-Year Community Teaching Hospital Experience

Gagandeep Kaur¹, Kaitlyn Williams¹, Sapna Desai¹, Ramapriya Vidhun², Jessica Dodge¹
¹Danbury Hospital, Danbury, CT, ²Western Connecticut Health Network, Danbury Hospital, Danbury, CT

Disclosures: Gagandeep Kaur: None; Kaitlyn Williams: None; Sapna Desai: None; Ramapriya Vidhun: None; Jessica Dodge: None

Background: The prevalence of thyroid nodules detected at autopsy in the United States ranges from 8-65%. Per the literature, benign and malignant thyroid nodules occur with about the same frequency. We report our ten-year autopsy experience in a community teaching hospital. We also report the prevalence of thyroid pathology in males and females.

Design: The laboratory information system was searched for autopsies performed between 1/1/2009 and 12/31/2018. Patients <18 years old and partial autopsies such as those restricted with no examination of the neck, cases with surgically absent thyroid and cases with no microscopic examination of thyroid were excluded. Autopsy reports were reviewed, and the following data were recorded: accession number, age, sex, and thyroid pathology.

Results: Out of 366 autopsy reports reviewed, 166 patients (45.4%) had thyroid pathology. A total of 193 thyroid pathologies were found amongst the 166 patients. Twenty-four of 166 patients (14.5%) had multiple thyroid abnormalities. Non-neoplastic pathology was more common than neoplastic pathology 91.7% (177/193) vs. 8.3% (16/193), respectively. Benign nodules were more common than malignant nodules 61.6% (119/193) vs. 8.3% (16/193), respectively. Hyperplastic nodule, chronic nonspecific thyroiditis, primary malignancy, fibrosis, secondary malignancy, Hashimoto thyroiditis, atrophy and colloid cyst were the most common abnormalities (Table 1). The primary malignancies were papillary microcarcinoma (5/9) and papillary thyroid carcinoma (4/9). The most common origin of secondary malignancy (7 cases) was lymphoma (4/7), lung (2/7), and colon (1/7). Out of 246 male thyroids studied, 103 (41.9%) showed pathology. Out of 120 female thyroids studied, 63 (52.5%) showed pathology. The mean age of patients with thyroid pathology was 67.3 years for males and 68.7 years for females.

Table 1. Thyroid Pathology in Adult Hospital Autopsies (n=366)

Hyperplastic nodule, No. (%)	Chronic nonspecific thyroiditis, No. (%)	Primary malignancy, No. (%)	Fibrosis, No. (%)	Benign Neoplasms, No. (%)	Other, No. (%)
119 (32.5%)	21 (5.7%)	9 (2.5%)	9 (2.5%)	2 (0.6%)	33 (9.0%)

Conclusions: Our study showed that thyroid pathology is common in adult hospital autopsies (45.4% prevalence). Although most of the autopsy thyroid literature focuses on neoplastic thyroid pathology, we found that non-neoplastic pathology was much more common than neoplastic pathology. As expected, the prevalence of thyroid pathology was more common in females (52.5%) than males (41.9%).

19 Removal of Autopsy Artifacts from Whole Slide Images Using Unpaired Adversarial Training

Brendon Lutnick¹, Kuang-Yu Jen², John Tomaszewski³, Avi Rosenberg⁴, Pinaki Sarder⁵
¹SUNY Buffalo, Grand Island, NY, ²University of California Davis, Sacramento, CA, ³University at Buffalo, Buffalo, NY, ⁴Johns Hopkins University School of Medicine, Baltimore, MD, ⁵SUNY Buffalo, Buffalo, NY

Disclosures: Brendon Lutnick: None; Kuang-Yu Jen: None; John Tomaszewski: *Advisory Board Member*, Neurovascular Diagnostics, Inc.; Avi Rosenberg: None; Pinaki Sarder: None

Background: Histologic tissue sections from autopsies can provide a valuable source of imaging data for research applications. However, post-mortem artifacts can significantly limit their utility. The ability to correct this artifact computationally has not been previously explored. As a preliminary attempt, we used a cycle-constant generative adversarial neural network (Cycle-GAN), which does not require paired images, to attempt to remove post-mortem artifacts from sections of renal tissue.

Design: We use 598 H&E stained autopsy whole slide images (WSI) freely available from the Genotype-Tissue Expression (GTEx) project, from the NIH common fund. These were fed into a Cycle-GAN network, in parallel with 313 H&E stained transplant biopsy WSIs, which was tasked with mapping between the two image sets. This network (written using Tensorflow) was modified to efficiently operate directly on randomly selected WSI patches using the OpenSlide python library. Transfer learning was used to speed the training process, which was run for 1200 random selected 256x256 pixel tissue patches from each WSI at 10X resolution. Fig. 1 shows examples of WSI input data to the pipeline.

Results: Despite having no data labels, the Cycle-GAN network was able to successfully remove some autopsy artifact from the GTEx tissue patches; this is seen in the removal of detached tubular epithelium. We note that the H&E staining was much darker on the GTEx dataset than the biopsy images, and the network learned to map the stain differences as well. The results are detailed in Fig 2.

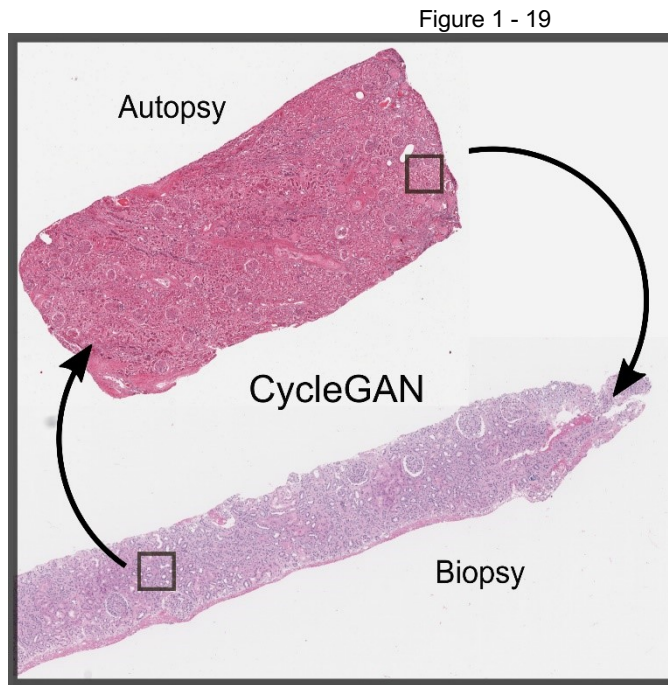


Figure 1. An overview of our method. Our datasets are H&E stained WSI images, where one set is transplant biopsies and the other is autopsy images. Randomly selected patches (10X resolution, 256x256 pixels) are selected during training and fed into a cycleGAN network, which learns to transform the patches to look like the complimentary dataset. Of interest is the mapping from autopsy to biopsy image patch, which removes artifacts associated with autopsy image data. Note the staining differences between the datasets.

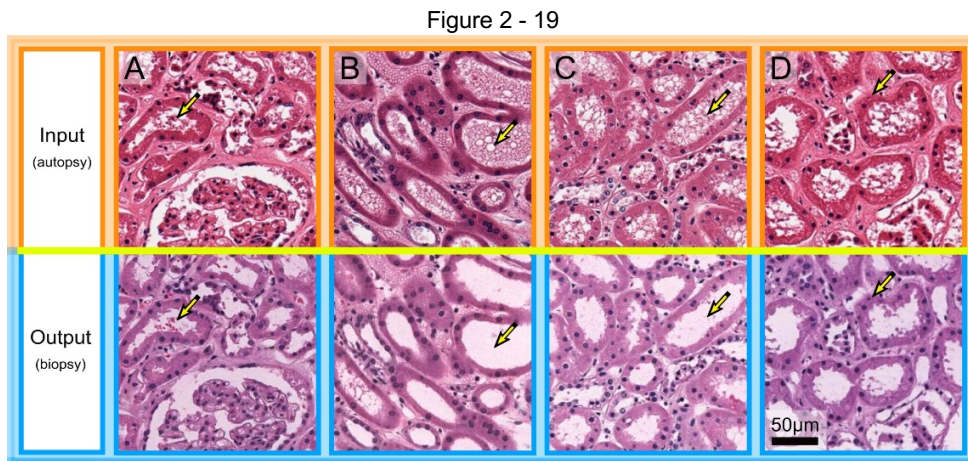


Figure 2. Results of CycleGAN transformation between GTEx autopsy and transplant biopsy datasets using H&E WSIs. The top row shows 256x256 pixel images patches from the autopsy dataset, which are mapped to biopsy data by the network (shown in the bottom row). We note that there are staining differences between the datasets, which is the cause of the color shift between input and output patches. The network learns to clean the debris in the tubules present in the autopsy images, in panel A this is mapped to red blood cell deposits which are present in the biopsy dataset. Panel B shows red blood cell remnants present in the autopsy image tubules which are removed during mapping. Panel C shows the removal of debris in the tubule, and D highlights the enhancement of a epithelial cell nuclei which has been darkened by the transformation.

Conclusions: The use of unpaired adversarial training allows for the removal of autopsy artifact from WSIs without needing to label the artifacts. However, this approach needs rigorous validation as image artifacts identified by the network are largely influenced by the patterns found in the training datasets. In the future, we plan to refine this pipeline by adding a semi-supervised conditional labeling of artifacts. We hypothesize that providing the network with relevant pathological findings will encourage the network to incorporate expert domain knowledge into the artifact removal process. Finally, we will modify this pipeline to stitch artifact corrected tissue patches back into WSIs for easy viewing.

20 Discrepancies Between Clinical and Anatomic Causes of Death in Acute Invasive Fungal Sinusitis: An Institutional Experience at a Tertiary Care Center

Lily Mahapatra¹, Hsiang-Chih (Sean) Lu², Kathleen Byrnes³

¹Barnes Jewish Hospital/Washington University, University City, MO, ²Washington University School of Medicine in St. Louis, St. Louis, MO, ³Washington University in St. Louis, St. Louis, MO

Disclosures: Lily Mahapatra: None; Hsiang-Chih (Sean) Lu: None; Kathleen Byrnes: None

Background: Acute invasive fungal sinusitis (AIFS) has a diverse clinical presentation and histological morphology, making it challenging to diagnose. AIFS is a devastating form of sinonasal fungal disease, which requires timely diagnosis and has emerged as a major cause of inpatient morbidity and mortality. Diagnosis of AIFS includes rapid recognition of clinical symptoms, histological examination of tissue for invasive fungal forms, and fungal culture.

Design: A retrospective review of institutional autopsy and medical records from 2001-2019 was completed. Only complete pediatric and adult autopsies with a hospital stay of greater than 24 hours were included. A total of 7 cases were reviewed for discrepancies between the clinical and anatomic causes of death in patients with acute invasive fungal sinusitis, determined by the presence of fungal elements on histopathological section.

Results: Of the 7 cases that met inclusion criteria, 42.9% (n=3) demonstrated clinical onset of symptoms prior to hospitalization, with fever (71.4%) and face pain (28.6%) as the most common clinical presentations. Most were women (57.1%) with a mean age of 41.6 years (range: 8-63 years). There was clinical suspicion for AIFS in three cases, with a mean time from admission to time of expiration of 21.6 days (range: 3-37 days). AIFS was associated with hematologic malignancy (42.9%), chronic steroid use (28.5%), poorly controlled diabetes (14.3%), and active Hepatitis C infection (14.3%). Antemortem cultures was positive for *Mucor* in 1 case (14.3%), *Rhizopus* in 1 case, and *Aspergillus* in 1 case. Angioinvasive fungal elements were histologically identified intracranially in all cases, with multiorgan involvement in 57.1% (n=4) of cases.

Conclusions: Antemortem diagnosis of AFIS can be challenging, especially in the pediatric population, given the lack of prototypical clinical symptoms and lack of positive fungal cultures. AFIS was commonly associated with underlying immunosuppression. Thus, a high degree of clinical suspicion should be exercised, especially in immunocompromised patients with an underlying hematological malignancy.

At autopsy, there was multiorgan involvement with preponderance for the brain, supporting the utility of extensive tissue sampling to evaluate for AFIS, even in the setting of negative fungal cultures or lack of classic symptoms. These findings highlight the importance of the pathologist's role at autopsy in definitive diagnosis of AIFS, especially in clinically equivocal cases.

21 Expanding the Role of the Autopsy Service in Public Health: The Collection of Data from Death Certification and the Obesity Epidemic

Rachel Martindale¹, Thomas Koster¹, Sharon Mount¹

¹The University of Vermont Medical Center, Burlington, VT

Disclosures: Rachel Martindale: None; Thomas Koster: None; Sharon Mount: None

Background: The United States is experiencing an obesity epidemic. The diagnostic criteria for obesity (BMI > 30 kg/m²) was met by 93.3 million Americans, resulting in a prevalence rate of 39.8% in 2015-2016. Important data on tobacco usage is obtained via death certification. We hypothesize that death certification could provide an additional means of assessing obesity and documenting its association with other co-morbidities.

Design: A retrospective review of all deaths that occurred at the University of Vermont Medical Center (UVMCC) in 2018 was performed. Cause and contributory cause of death recorded in Vermont's Electronic Death Registration System (death certification) was compared to each patient's Electronic Medical Record (EMR). Patient demographics and BMI were recorded using Excel. The cause and contributory causes of death was obtained from review of the death certificate.

Results: There were 520 deaths at UVMCC in 2018. Review of EMRs revealed that 174 (33.5%) of decedents met criteria for obesity at the time of their death. For 21 decedents (4%), BMI information was not recorded. Obese individuals ranged in age from 25 to 94 years and 97 (55.7%) were female, 77 (44.3%) were male. The obesity classes were divided as follows: 62 (35.6%) Class 1; 46 (26.4%) Class 2 and 66 (37.9%) Class 3. In 81 (46.5%) cases, the cause of death recorded on the death certificate was one of the diseases listed by the CDC as being associated with obesity. Obesity was reported on the death certificate in 22 (12.6%) of cases. In 5 decedents, obesity was listed in the major cause of death section, and in 17, obesity was listed as a contributory cause of death.

Conclusions: Our study demonstrates that obesity is highly underreported on death certificates. Accurate data will be essential to better understand the association of obesity with other diseases as well as to inform public health initiatives addressing the obesity epidemic. Our

data indicates that such information is currently not obtained via death certification. Although the cause of death in 46.5% of decedents was a CDC obesity related disease, obesity was reported in only 12.6% of death certificates. Consideration of including a check box line on the death certificate to indicate whether obesity was a contributing factor to the death, as is currently employed for tobacco use, may help provide information useful to address the crisis of obesity and to better understand the association of obesity with other co-morbidities.

22 Changes in Rate of Unexpected Findings at Autopsy: A Ten-Year Retrospective Study

Romana Mayer¹, Allen Burke²

¹University of Maryland Medical Center, Baltimore, MD, ²University of Maryland, Baltimore, MD

Disclosures: Romana Mayer: None; Allen Burke: None

Background: Discussion continues around the utility of autopsies as their numbers decline while pre-mortem clinical technology and imaging improves. Studies have shown a decrease in unexpected findings, although clinically undetected diagnoses still get missed.

Design: Autopsy data from a tertiary care institution were retrospectively reviewed over 10 years to determine the rate of unexpected findings in three categories: 1. Cause of death elicited at autopsy (not clinically known), 2. Non-incident unexpected finding that may have affected patient or hospital course, and 3. Incidental unexpected finding that was unlikely to have affected patient or hospital course. Out of 1000 autopsies, 502 met inclusion criteria. Excluded cases were non-adult autopsies, single organ or body cavity autopsies, and autopsies from patients not treated at the main hospital.

Results: The average percent of autopsies that had a clinically missed cause of death was 11.6% (range 0-18.2 per year). The average percent of autopsies that had a non-incident unexpected finding was 16.1% (range 7.3-21.8 per year). The average percent of autopsies that had an incidental unexpected finding was 15.5% (range 2.9-42.9). We found that over time (from 2011 to 2019) there was a downward trend of autopsies that had unexpected findings (from 57.1% to 17.1%, average 31% per year). This trend matched the decrease in incidental unexpected findings (from 42.9% to 2.9%). However, the number of autopsies with non-incident unexpected findings did not show a downward trend and remained relatively steady with an average of 16.1% with no time change relationship. Examples of common non-incident unexpected findings included: undiagnosed metastatic malignancy, undiagnosed infection, undiagnosed cardiac disease, and undiagnosed bleeding or hemorrhage. Examples of common incidental unexpected findings included benign neoplasms, small malignant neoplasms, autoimmune disease, vasculitis, and anatomic variants.

Example Non-Incidental Unexpected Finding	Example Incidental Unexpected Finding
Metastatic malignancy (lymphoma, leukemia, neuroendocrine)	Benign neoplasms (GIST, hemangioma, ganglioneuroma, adenoma, FNH)
Infection (fungal, CMV, VRE)	Small malignant neoplasms (adenocarcinoma, papillary carcinoma, follicular carcinoma, RCC)
Cardiac disease (HOCM, NICM, endocarditis)	Autoimmune disease (sarcoid, IgA)
Bleeding or Hemorrhage (GI, aortic, pulmonary)	Vascular (IgA, amyloid)
Vascular (calciophylaxis, emboli, Churg-Strauss)	Anatomic variants (accessory spleen, bifurcated ureter)
Trauma (spleen laceration, bowel perforation)	

Figure 1 - 22

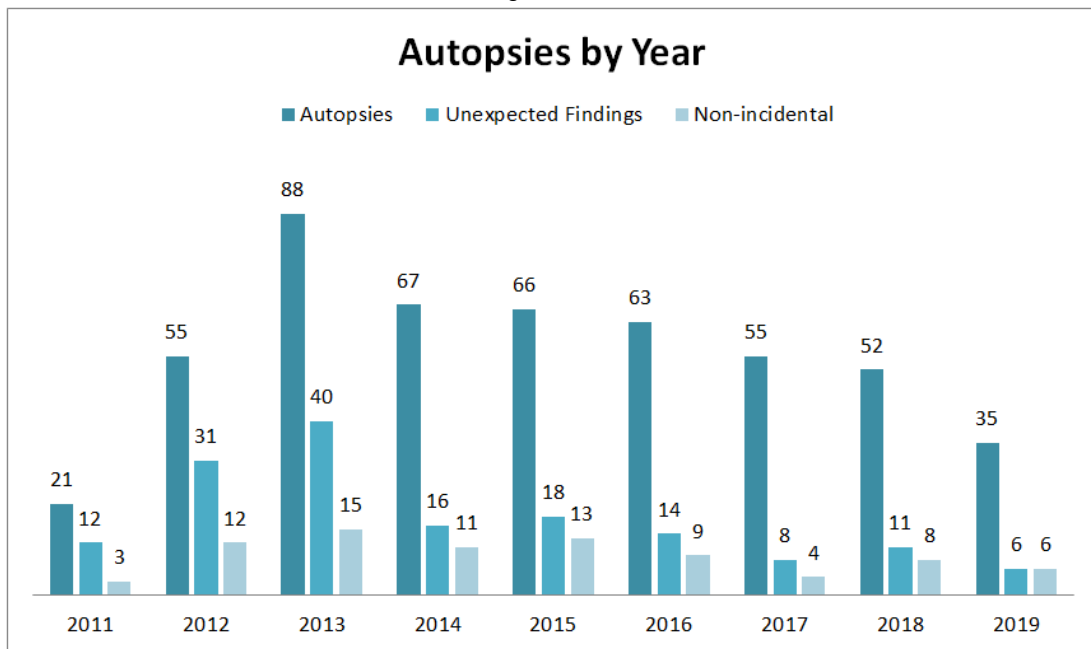
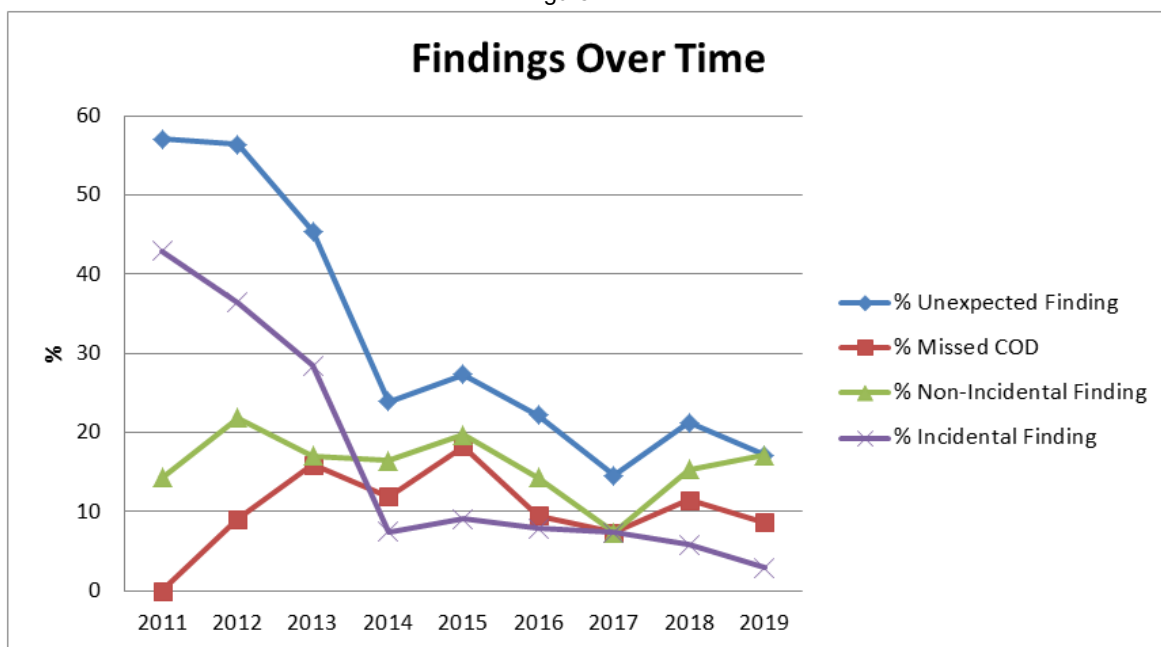


Figure 2 - 22



Conclusions: The number of all unexpected findings at autopsy has decreased over the years at our institution. However, the rates of missed cause of death and non-incidentals unexpected findings have not declined significantly. The utility of autopsy still remains strong even today in a world of advancing medicine.

23 Diffuse Infantile Myofibromatosis with a Triphasic Growth Pattern Presenting as Blueberry Muffin Baby: A Lethal Pictorial Differential Diagnosis

Odille Mejia Mejia¹, Lydia Howard², Christopher Febres-Aldana¹, Pukhraz Basra³
¹Mount Sinai Medical Center, Miami Beach, FL, ²Mt. Sinai Medical Center, Miami Beach, FL, ³H. Lee Moffitt Cancer Center & Research Institute, University of South Florida, Tampa, FL

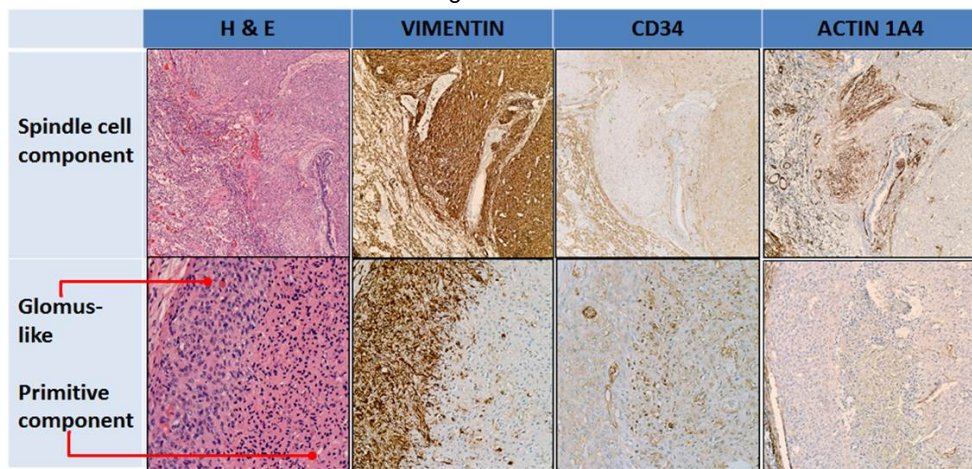
Disclosures: Odille Mejia Mejia: None; Christopher Febres-Aldana: None; Pukhraz Basra: None

Background: The term blueberry muffin baby (BMB) has been used to describe cutaneous non-blanching, blue macular lesions observed in newborns infected with rubella. Since then, congenital infections causing TORCH syndrome and hematology dyscrasias have been associated with BMB. Herein, we discuss an unusual case of lethal infantile myofibromatosis (IM) presenting as BMB.

Design: A 5-day-old baby boy was born via spontaneous delivery by a 29-year-old woman with adequate prenatal care with negative screening for TORCH infections. At birth, the APGAR scores were low, requiring advanced medical support. An abdominal and pelvic ultrasound revealed multiple hypoechoic lesions involving the GI and GU tract. Despite the medical efforts, the patient expired.

Results: An autopsy was performed revealing diffuse IM, which exhibited significant intra- and inter-tumor heterogeneity with three distinctive patterns. The predominant growth pattern in the lung was an intravascular spindle cell proliferation arranged in interlacing bundles with a whorled appearance, immunoreactive for vimentin and actins (HHF35, actin1A4), and negative for CD31, CD34, desmin and smooth muscle-myosin heavy chain, consistent with myofibroblastic differentiation. A glomus-like pattern, prevalent in intraabdominal organs, was composed of small round cells with amphophilic cytoplasm, indistinct cell borders, and small nuclei, was positive for vimentin and CD-34, while negative for CD-31, desmin, and actins. There was a proliferation of smaller irregularly shaped cells with abundant eosinophilic cytoplasm and small hyperchromatic nuclei with a primitive appearance, which were positive for CD-34 and were negative for vimentin, CD-31, and actins. Both glomus-like and primitive patterns contain branching dilated vessels as seen in hemangiopericytoma.

Figure 1 - 23



Conclusions: IM is a rare congenital tumor of infancy that can involve skin and internal organs. The diffuse involvement in newborns is a cause of BMB, and those with visceral involvement have increased mortality. In our case the extensive intravascular pulmonary component lead to death. Although IM can display divergent growth with biphasic morphology, we describe the coexistence of three growth patterns with distinctive morphologic and immunohistochemical features. The broad morphologic spectrum seen in IM suggests that this tumor arises from pluripotent perivascular cells capable of differentiating along myofibroblasts, pericytes, and glomus cell lines.

24 Interstitial Lung Disease as a Distractor in the Diagnosis of Lung Adenocarcinoma

Nicole Mendelson¹, Kirsten Threlkeld²

¹The University of Vermont Medical Center, Richmond, VT, ²The University of Vermont Medical Center, Burlington, VT

Disclosures: Nicole Mendelson: None; Kirsten Threlkeld: None

Background: Lung adenocarcinoma can present with variable clinical presentations. Cases in which there are diffuse inflammatory changes and honeycombing represent a subset of cases in which interstitial lung disease (ILD) is the favored diagnosis. These radiologic findings represent a pitfall in the diagnosis of malignancy and highlight the importance of biopsy confirmation.

Design: We present the autopsy findings of a 61 year old female with a past medical history of chronic respiratory failure secondary to pulmonary fibrosis on oxygen at rest with a 50 pack-year smoking history. She began experiencing respiratory exacerbations in the months preceding her death and was repeatedly treated for community acquired pneumonia and acute respiratory failure. On her final admission, imaging showed mediastinal lymphadenopathy, ground glass opacities and honeycombing. Due to worsening hypoxia she was intubated and transferred to UVMHC. Upon admission, ILD was favored with need for biopsy diagnosis. She continued to decline, transitioned to comfort care measures, and was pronounced dead at the bedside. The patient expressed interest in having an autopsy performed and her family consented after her passing.

Results: Autopsy examination revealed gross and microscopic evidence of metastatic, poorly differentiated adenocarcinoma bilaterally involving 85% of the lung parenchyma. Gross examination revealed dense, heterogeneous lungs and microscopic examination showed a poorly differentiated adenocarcinoma with areas of mucinous and focal enteric differentiation. The uninvolved background lungs exhibited patchy pulmonary interstitial fibrosis not further classifiable. IHC showed positive CK7, focal CK20 and negative TTF-1, a pattern commonly found in mucinous adenocarcinomas of lung origin. Other sites of origin were excluded based upon gross exam.

Figure 1 - 24

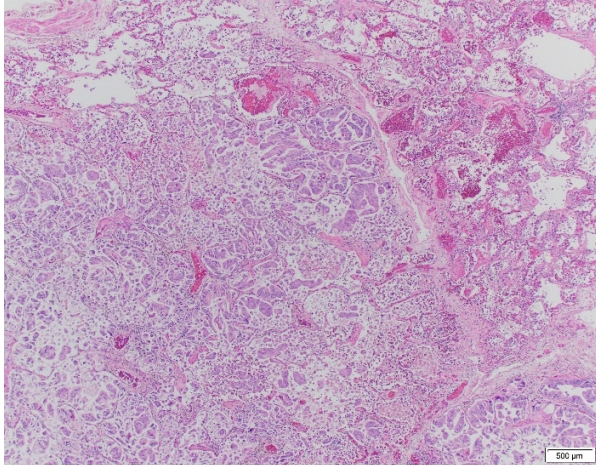
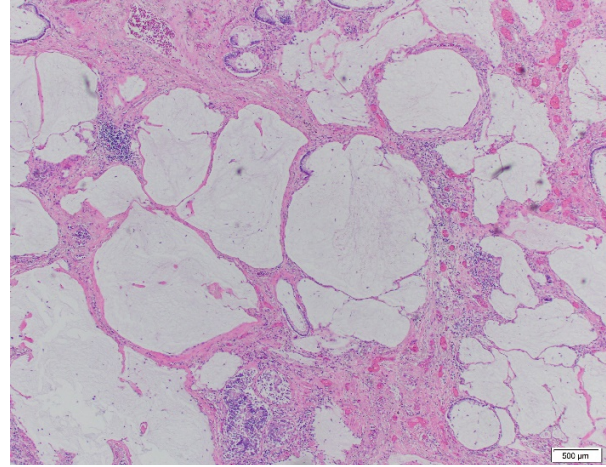


Figure 2 - 24



Conclusions: We report a case of lung adenocarcinoma mimicking pulmonary fibrosis radiographically. This case represents a major discrepancy in clinical impression vs autopsy findings and demonstrates the uniquely challenging diagnosis of diffuse lung adenocarcinoma mimicking or arising in the setting of ILD. This particular patient had imaging demonstrating progression to diffuse disease over the course of many years. Considering this progression, early radiographic findings consistent with ILD and severe fibrosis of the background lung, it is most likely that her ILD progressed over many years and provided a diagnostic challenge in the diagnosis of lung adenocarcinoma.

25 Autopsy Findings in Adult Onset Hemophagocytic Lymphohistiocytosis: A 5 Case Series and Literature Review

Caroline Mullins Underwood¹, Hayley Premo², Barbara Anderson¹, Sarah Rapisardo³, Avani Pendse⁴, Carolyn Glass⁴, Jadee Neff⁴
¹Duke University Health System, Durham, NC, ²Durham, NC, ³Duke University, Durham, NC, ⁴Duke University Medical Center, Durham, NC

Disclosures: Caroline Mullins Underwood: None; Hayley Premo: None; Barbara Anderson: None; Sarah Rapisardo: None; Avani Pendse: None; Carolyn Glass: None; Jadee Neff: None

Background: Hemophagocytic lymphohistiocytosis (HLH) is a rare but often fatal leukocyte disorder characterized by uncontrolled histiocyte activation with phagocytosis of blood cells. In adults, HLH is rare and usually secondary to malignancy or infection. To date, 18 cases of adult onset HLH with post-mortem tissue diagnosis have been reported in the literature. We present here a series of 5 cases with molecular analysis of this unique phenomenon.

Design: Post mortem findings from 5 adult autopsies with HLH as the primary cause of death were reviewed along with 18 previously reported cases from 14 published articles. The diagnosis of HLH was either made or confirmed by autopsy. A next generation sequencing (NGS) panel targeting 75 genes associated with myeloid neoplasms was performed on all 5 cases.

Results: In our cohort (80% female, median age 64, range 26-85 years), the pre-mortem ferritin level was >15,000 ng/mL in 4/4 patients, and the soluble IL-2 receptor (sIL2R) was elevated in 2/4 cases. Only 2 patients were treated for HLH prior to death, and treatment was significantly delayed for 1 of them due to a negative bone marrow biopsy. In 2 patients HLH was not diagnosed or treated prior to death. Post mortem gross examination revealed splenomegaly (3/5), vertebral osteoporosis (3/5), and hepatic congestion (2/5). Multifocal hemophagocytosis with histiocytes acting as the phagocytic cell was seen in all cases. Hemophagocytosis involved the spleen and bone marrow (5/5), lymph nodes (2/2) and liver (4/5). Other splenic findings included red pulp expansion (5/5) and extramedullary hematopoiesis (3/5). The bone marrow was hypercellular (5/5) with an increased myeloid to erythroid ratio (4/5) and mild erythroid atypia (3/5). The liver showed mild lymphohistiocytic infiltrates in the portal tracts (3/5) and sinusoidal dilation (3/5). The lymph node architecture was preserved with slight sinus dilatation. No pathogenic mutations or recurrent variants of uncertain significance were identified by NGS. After diagnosis or confirmation of HLH at autopsy, a potential precipitating etiology was identified in 4 cases (EBV, sepsis, HHV6, and autoimmune flare).

Case	Age (years)	Sex	phagocytic Cell Type	Location of hemophagocytosis			
				Spleen	BM	LN	Liver
current Study							
case 1	64	F	Histiocytes	(+)	(+)	n.a	(+)
case 2	61	F	Histiocytes	(+)	(+)	(+)	(+)
case 3	65	F	Histiocytes	(+)	(+)	n.a	(+)
case 4	85	F	Histiocytes	(+)	(+)	n.a	-
case 5	26	M	Histiocytes	(+)	(+)	(+)	(+)
Yamashita, et al (2019)	45	M	Histiocytes	(+)	(+)	(+)	(+)
Koizumi, et al (2018)	53	M	n.a	n.a	(+)	n.a	n.a
Bangaru, et al (2017)	mid 40's	M	Histiocytes, plasma cells	(+)	(+)	(+)	(+)
Nakano, et al (2017)	86	F	Histiocytes	(+)	(+)	-	(+)
Magaki, et al (2016)	41	M	Histiocytes, lymphocytes	(+)	-	-	(+)
Yu & Chua (2016)	21	M	lymphocytes, Histiocytes	(+)	(+)	(+)	n.a
Sharmeen & Hussain (2016)	52	M	Histiocytes	(+)	(+)	(+)	(+)
Pastula, et al (2015)	55	M	Histiocytes, lymphocytes	-	-	-	-
Oto, et al. (2015)							
Patient A	69	F	Histiocytes, lymphocytes	(+)	(+)	(+)	-
Patient B	73	F	Histiocytes, lymphocytes	-	(+)	(+)	(+)
Patient C	79	M	Histiocytes, lymphocytes	(+)	-	(+)	(+)
Patient D	71	F	Histiocytes, lymphocytes	(+)	-	(+)	(+)
Feuillet, et al (2009)	18	M	Histiocytes	n.a	(+)	n.a	n.a
Aryal, et al (2013)	56	M	Histiocytes	(+)	(+)	n.a	n.a
Chute, et al (2013)							
Patient A	52	M	Histiocytes	(+)	(+)	(+)	(+)
Patient B	28	F	lymphohistocytic infiltrate	(+)	(+)	(+)	(+)
Alomari (2012)	68	F	lymphocytes, Histiocytes	(+)	(+)	(+)	(+)
Tiong, et al (2012)	68	M	Histiocytes	(+)	(+)	n.a	(+)
total N=23	Median 56 years	F 43% M 57%	Histiocytes 100% Lymphocytes 41% Plasma cells 4.5%	91%	83%	77%	89%

Conclusions: HLH is a rare but fatal condition that is likely underdiagnosed. We show that hemophagocytosis can be identified at autopsy and suggest that the spleen, bone marrow, lymph nodes, and liver should be examined to diagnose or confirm the clinical suspicion of HLH.

26 Cardiac Metastases: A 35 Year Single Center Retrospective Autopsy Study

Luiz M Nova¹, Irene Fernández¹, Tamara Zudaire¹, Monica Bronte¹, Alicia Córdoba¹, Rosa Guarch¹, Angel Panizo¹
¹Complejo Hospitalario de Navarra, Pamplona, Navarra, Spain

Disclosures: Luiz M Nova: None; Irene Fernández: None; Tamara Zudaire: None; Monica Bronte: None; Alicia Córdoba: None; Rosa Guarch: None; Angel Panizo: None

Background: Cardiac Metastases (CM) are more prevalent than primary cardiac tumors, although they are rare (average incidence of 7.1% among autopsies of cancer patients). This incidence is anticipated to increase with extended survival of oncologic patients.

Design: Adult (18 years or older) autopsy cases from 1984 to 2019 diagnosed of any type of solid cancer were retrieved. Leukemia and lymphoma cases were excluded. The medical charts of these patients were reviewed for clinical information. Autopsy pathologic data were reviewed in detail: origin of the tumors, histological type, extent of cardiac involvement, and CM localization.

Results: A total of 1294 adult autopsies diagnosed of any type of cancer within the past 35 years were reviewed, and 124 cases of CM were found. 39 cases of leukemia or lymphoma CM were excluded from the study. 85 cases of solid tumor CM (incidence: 6.8%) were studied: age range was 32-85 yrs. (mean age: 60.6 yrs.), being 64 males and 21 women. Lung was primary site for 43 cases (50.6%) of all CM, and next in frequency was gastrointestinal & pancreas-biliary (14 cases). Other primaries were: pleura-peritoneum (n=6), genitourinary (n=5), soft-tissues (n=4), skin (n=4), endocrine (n=4), breast (n=3), and head & neck (n=2). The most frequent CM by histological cell type were carcinoma (73 cases; 85.9%): adenocarcinoma (31 cases), neuroendocrine (16 cases), squamous (14 cases), urothelial (4 cases), and other (8 cases). Other CM cell types were: mesothelioma (n=6), sarcoma (n=4), 1 blastoma, and 1 melanoma. In 21 cases, more than one layer of the heart was involved. The predominant layer of the heart involved by the CM was the pericardium (58 cases: 39 alone and 19 associated with other layers). Myocardium was involved in 36 cases (42.3%), epicardium in 7 cases, and endocardium in 3 cases. Intracavitary (auricular or ventricular) tumor thrombi were seen in 6 cases (7% of all CM). All but one case (98.8%) had multiple extracardiac metastases. The frequency of cardiac metastases increased with the number of distant metastases: 53 cases (62.3%) had CM and distant metastases in 4 or more different organs. Clinical presentations of CM were commonly asymptomatic.

Conclusions: CM is a rare occurrence, with an incidence of 6.8% in our series. Lung cancer accounted for most of the CM seen, and carcinomas were the most frequent histotype. CM increased with rising number of distant metastases. Pericardial metastases are the most common type of CM, followed by myocardium.

27 Why Cancer Patients Die: Autopsy Should Inform End of Life Care

David Priemer¹, Jody Hooper¹
¹Johns Hopkins University, Baltimore, MD

Disclosures: David Priemer: None; Jody Hooper: None

Background: Part I of the 'Cause of Death' (COD) statement on death certificates and in autopsy reports characterizes not only underlying CODs, but also immediate CODs. Immediate CODs are the most proximate events that begin the cascade that ends in death. Part II shows ancillary risks or conditions. Immediate CODs may be difficult to determine in complex disease states such as cancer, and may be omitted. Immediate CODs are also often not reported in the literature. This creates a knowledge gap in the treatment of terminal cancer patients, missing opportunities for extending survival and supplying a better quality of life.

Design: We searched the electronic database of a large academic center over three years to identify autopsy reports of patients with metastatic and/or locally aggressive cancer. Demographics of patients were recorded. We then reviewed each autopsy report to either confirm the COD statement as written, or to construct a new COD statement which included a more immediate cause where appropriate.

Results: The search identified 121 decedents (67 men, 54 women). Average age was 60.5 years (3-92 years). The most common cancer types were pancreaticobiliary (17 cases), prostate (12), and lung (12). In 115/121 (95%) patients, cancer was the underlying COD. Of those 115, 108 had cancer listed in part I of the COD, leaving 7 with it listed in part II. 55 reports (55%) stated an immediate COD proximate to cancer in part I, while the remaining listed only the cancer in part I. Upon review, 41 of these 55 cases (75%) had an identifiable immediate COD; the rest had insufficient clinical information or ultimately did not have another immediate COD. The most common immediate CODs were tumor burden in the lung (27 cases, 22% of total), pneumonia (21, 18%), sepsis (12, 10%), hepatic tumor burden (9, 7%), and pulmonary embolus (6, 5%). More unusual immediate causes included peritonitis, complications of surgery, and hemorrhage.

Conclusions: In this cohort, in most cases cancer was appropriately listed in part I of the COD. However, a substantial proportion of autopsy reports did not identify a more immediate COD, though there was usually sufficient clinical and autopsy data to assign one. Though areas of greatest tumor burden might not be able to be addressed, immediate causes of death such as pneumonia, sepsis, or pulmonary emboli might be prevented or alleviated, even in a hospice setting. These immediate causes of death should be cited in autopsy reports and death certificates.

28 Novel Extramedullary Hematopoiesis Liver Score Correlates with Gestational Age and Chronic Hypoxic Cause of Death at Perinatal Autopsy

Heidi Reinhard¹, Julie Fanburg-Smith², Ben Murie³

¹Nationwide Children's Hospital, Columbus, OH, ²Penn State Health Milton S. Hershey Medical Center, McLean, VA, ³Penn State Health Milton S. Hershey Medical Center, Palmyra, PA

Disclosures: Heidi Reinhard: None; Julie Fanburg-Smith: None; Ben Murie: None

Background: Extramedullary hematopoiesis (EMH) occurs in the yolk sac, liver, and spleen during fetal embryogenesis and is usually considered physiologic. By six months gestation EMH decreases, while bone marrow produces progenitor cells. After an index case of chronic hypoxia with several maternal risk factors in a term, stillborn with extensive EMH, we wanted to understand the significance of EMH and develop a liver scoring system to evaluate EMH at perinatal autopsy.

Design: Pediatric autopsies (19 weeks to 24 months gestation), were reviewed from 2011-2019 for details, maternal medical/recreational risk factors, and cause of death recorded. Liver weight and morphology for EMH as well as spleen, bone marrow, thymic involution, and adrenal cortical fat were evaluated. EMH liver score was independently scored by three reviewers as follows: 0= no EMH, 1= few rare clusters, 3-10%, 2= 10-25% parenchyma, 3= 25-50%, and 4 equals >50%. Liver was used rather than spleen due to less autolytic/hemorrhagic artifact. Median liver scores for each group determined "acceptable" for that age range.

Results: Perinatal deaths of 44 M and 34 F were scored and put into five age groups: 1) Extremely premature, GA 19-24 weeks, n=9, EMH-liver score median (LSM)= 4; 2) Premature, GA 25-35 weeks, n=24, EMH-LSM 2.5; 3) Term, GA 36-41 weeks, n=20, EMH-LSM= 1.0; 4) Infant, 42 weeks-6 months, n=15, EMH-LSM=1; and 5) Child, 6 months-24 months, n=10, EMH-LSM=1. Aberrant thymic involution and increased adrenal cortical fat and erythroid hyperplasia with dyserythropoiesis in the bone marrow, were considered measurements of stress and chronic hypoxia, and correlated to when EMH liver score was out of the median range for that age group, especially in extremely premature, premature, and term groups. More data is required for other age groups. Age-adjusted normal-median EMH liver score correlates with acute cause of death, such as trauma or hemorrhage, whereas abnormal (too high or too low for median EMH liver score for that age group) corresponded to chronic hypoxic cause of death.

Conclusions: EMH liver score is a reproducible and valuable method to understand physiologic versus pathologic EMH in all age groups. EMH liver score correlates with thymic and adrenal and bone marrow stress changes and acute versus chronic causes of death. EMH liver score <4 in extreme prematurity, ≥ 2.5 in premature, ≥1 in term or after birth should be considered pathologic and prompt a search for an underlying chronic hypoxic cause of death.

29 A Rare Case of Mitochondrial Encephalopathy, Lactic Acidosis, and Stroke-Like Episodes (MELAS): Unique Findings at Autopsy

Natali Ronen¹, Karen Arispe Angulo², Michael Lawlor¹, Ann Esselman³, Robert Goodwin³, Tamar Giorgadze¹

¹Medical College of Wisconsin, Milwaukee, WI, ²Medical College of Wisconsin Affiliated Hospitals, Milwaukee, WI, ³MCW, Milwaukee, WI

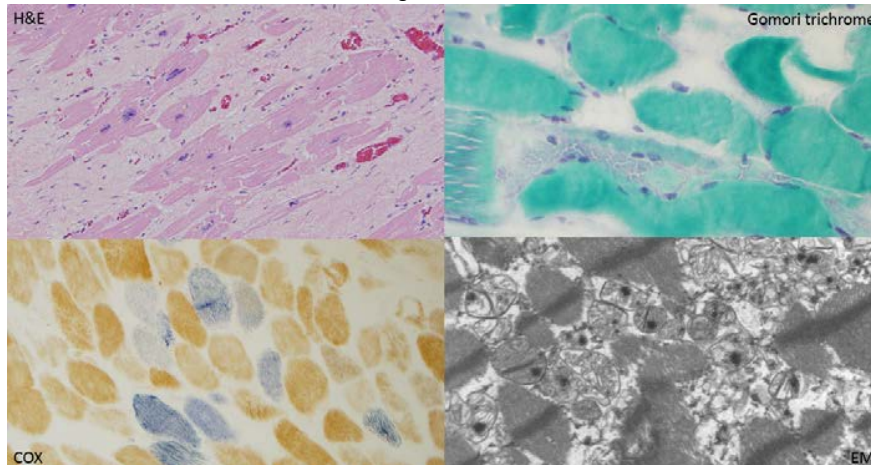
Disclosures: Natali Ronen: None; Karen Arispe Angulo: None; Michael Lawlor: *Grant or Research Support*, Audentes Therapeutics; *Advisory Board Member*, Audentes Therapeutics; *Grant or Research Support*, Solid Biosciences; *Advisory Board Member*, Solid Biosciences; *Consultant*, Dynacure; Robert Goodwin: None; Tamar Giorgadze: None

Background: Mitochondrial encephalopathy, lactic acidosis, and stroke-like episodes (MELAS) is a rare mitochondrial genetic disorder caused by impaired energy production and vasoconstriction due to nitric oxide depletion. Management of MELAS is mostly symptomatic.

Design: We report a case of a 31-year-old female who underwent genetic testing in 12/2010 and was found to have a heteroplasmic tRNA Leu, m.3243A>G mutation which is present in approximately 80% of individuals with MELAS. Our patient had muscle fatigue, cerebellar atrophy and rapidly progressive cardiomyopathy over a 2-year period with a rapid decrease in ejection fraction. She initially refused treatment of her heart failure due to unwanted side effects. A few days prior to her death, she presented to the emergency department with pleuritic chest pain, increasing shortness of breath and hypotension. Work up was consistent with stage D heart failure due to non-ischemic cardiomyopathy with severe left ventricular dysfunction. Despite escalation in therapies the patient continued to decompensate and expired.

Results: The main autopsy finding was significant cardiomegaly (heart weight: 489.9 g.) Histologically there was extensive collagen deposition between the cardiomyocytes, which showed remarkable hypertrophy. Examination of frozen skeletal muscle tissue revealed slightly increased myofiber size variation due to the presence of mild atrophy in some fibers. The number of internally nucleated fibers was slightly increased, suggestive of a low level of chronic regenerative changes. Rare ragged red fibers were seen, suggestive of mitochondrial disease further confirmed by a large number of COX-negative, SDH positive fibers on a COX/SDH stain. An NADH stain highlighted increased mitochondrial staining in some fibers. Overall, the findings were most consistent with mild to moderate mitochondrial disease. Electron microscopy of skeletal muscle showed myofibers with markedly increased numbers and abnormal aggregation of mitochondria, suggestive of intramitochondrial inclusions (Fig 1).

Figure 1 - 29



Conclusions: In our case, the patient had lost a substantial function of her heart over a short period of time at a very young age. The clinical symptoms, together with the histologic evaluation, electron microscopy findings, and the molecular finding support the diagnosis of MELAS.

30 An Eleven-Year Retrospective Study of Autopsy Cases with Potential and Definitive Clinical Impact

Justin Rueckert¹, Kirsten Threlkeld¹, William Humphrey¹

¹The University of Vermont Medical Center, Burlington, VT

Disclosures: Justin Rueckert: None; Kirsten Threlkeld: None; William Humphrey: None

Background: Every autopsy case at the University of Vermont Medical Center (UVMCC) is reviewed at a monthly Q/A meeting to assess for discrepancies between clinical and autopsy diagnoses. When discrepancies are identified, the clinical impact is assessed and ranked: Level 1 no impact; Level 2 potential impact and Level 3 definitive impact. The clinical team who cared for the patient is notified for Level 2 and 3 discrepancies. We hypothesize trends exist in discrepancies revealed through postmortem examination. Better understanding of these trends will provide opportunities for targeted education for our clinical colleagues.

Design: Records of discrepancies were reviewed from January 1, 2008 to December 31, 2018 at UVMCC and recorded in an EXCEL spreadsheet. Information documented included: level of clinical impact, date of death, clinical diagnoses, autopsy diagnoses, and clinical service notified. Only level 2 and 3 cases were further analyzed. The autopsy diagnoses resulting in discrepancy from ante mortem impression were grouped according to diagnostic similarities when possible. The month of death and clinical service notified were also analyzed to uncover trends.

Results: A total of 175 discrepant cases were identified. Of these, 113 were level 1, 38 were level 2, and 23 were level 3. Of the level 2 cases, the top three categories of discrepant diagnoses in descending order were neoplasia (13), infection (9), and cardiovascular system (5). Of the cases where the clinical service notified was documented, the 3 most contacted were medicine (7), oncology (6), and radiology (5). Of the level 3 cases, the top categories of discrepant diagnoses in descending order were infection (4), cardiovascular system (4), gastrointestinal system bleed/ulcer (3), pulmonary embolus (3), and exsanguination secondary to surgical hardware (3). Of the cases where the clinical service notified was documented, the four most contacted were outside hospitals (4), emergency medicine (3), cardiothoracic surgery (2), and orthopedic surgery (2). There was no significant trend in month of death for level 2 or 3 cases.

Level 2 Discordance	
Diagnostic Category	Number of Cases
Neoplasia (13)	
• Carcinoma (8)	
○ Metastatic esophageal adenocarcinoma	1
○ Metastatic pancreatic adenocarcinoma	1
○ Well differentiated pancreatic neuroendocrine tumor	1
○ Lung Primary	
• Metastatic small cell carcinoma	1
• Metastatic adenocarcinoma	1
• Lung adenocarcinoma	1
• Large cell neuroendocrine	1
○ Squamous cell carcinoma of the larynx	1
• Lymphoma (4)	
○ Low-grade B-cell lymphoma involving multiple organs	1
○ Lymphomatous infiltrate of heart	1
○ CNS involvement by marginal zone lymphoma	1
○ Leptomeningeal involvement by chronic lymphocytic leukemia	1
• Myelolipoma, hemorrhagic	1
Infectious (9)	
• Pneumonia	4
• Pyelonephritis	1
• Viral encephalitis	1
• Endocarditis/pericarditis	1
• Pelvic abscess secondary to diverticulitis	1
• CNS Toxoplasmosis	1
Cardiovascular (5)	
• Myocardial infarction	1
• Atherosclerotic cardiovascular disease	1
• Thoracic aortic dissection	1
• Cardiac amyloid	1
• Cardiac rupture (unknown) secondary to mural abscess (known)	1
False positive (4)	
• Aortic stenosis (no aortic stenosis)	1
• Hemorrhagic conversion of stroke (no hemorrhagic conversion)	1
• Pneumonia (no pneumonia, but large effusions)	1
• Cholangiocarcinoma (bile sludge)	1
Lung (2)	
• Diffuse alveolar damage and pulmonary alveolar proteinosis	1
• Foreign body embolization secondary to IV drug use	1
Fetal (2)	
• False positive: Absent corpus callosum on MRI (corpus callosum present at autopsy)	1
• Discrepant gestational versus anatomic age suggestive of unrecognized gestational diabetes	1
Non-neoplastic Hematology (1)	
• Hemophagocytic Lymphohistiocytosis	1
Gastrointestinal System (1)	
• Cirrhosis	1
Dermatology (1)	
• Hypersensitivity dermatitis	1
Level 3 Discordance	
Diagnostic Category	Number of Cases
Cardiovascular (4)	
• Myocardial infarction	3
• Aortic Dissection	1
Infectious (4)	
• Pseudomembranous colitis	1
• Cardiac tamponade due to rupture of aorta from abscess	1
• Mycotic pseudoaneurysm	1
• Lyme carditis	1

Gastrointestinal System (4)	
• Bleeding duodenal ulcer	2
• Acute gastric ulceration	1
• Colonic pseudo-obstruction	1
Lung (3)	
• Pulmonary Embolism	3
Hardware (3)	
• Right coronary artery dissection immediately distal to anastomosis and mesh placement	1
• Defect to thoracic aorta related to surgical hardware	1
• Exsanguination due to dehiscence of surgical repair site of pseudoaneurysm	1
Neoplasia (2)	
• Carcinoma (1)	
○ Lung adenocarcinoma	1
• Lymphoma (1)	
○ Intravascular lymphoma	1
Central Nervous System (1)	
• Intracerebral hemorrhage	1
False Positive (1)	
• Acute myocardial infarction (no acute myocardial infarction)	1
Fetal (1)	
• Severe acute chorioamnionitis	1

Conclusions: Discrepancies with potential and definitive clinical impact are often encountered at the time of autopsy. Identifying trends in these discrepancies allows pathologists to provide targeted education for our clinical colleagues and improve the quality of care for our patients.

31 Alcohol-Related Deaths in Medical Autopsies at an Academic Institution: An Underreported Finding

Tuyet Hong Tran¹, Melissa Guzzetta²

¹New York University Langone Medical Center, New York, NY, ²NYU Langone Health, Westfield, NJ

Disclosures: Tuyet Hong Tran: None; Melissa Guzzetta: None

Background: The “opioid epidemic” is overshadowing the fact that alcohol use disorder is more prevalent than opioid use disorders. According to WHO, alcohol directly contributes annually to over three million deaths worldwide and is a causal factor in over 200 diseases. In comparison, 118,000 people died from opioid use in 2015 worldwide. Despite more reportable deaths from harmful alcohol use, the number is underestimated because alcohol-related deaths are underreported.

Design: We performed a retrospective review of autopsy cases in our pathology database using the key terms “chronic alcoholism”, “chronic alcoholic”, “chronic alcohol”, “chronic ethanol”, “alcoholic”, “alcohol”, “ethanol”, and “etoh” from 2004 to 2019. Cases positive for one or more key terms had autopsy report and medical record reviewed to see if alcohol-related death was reported on the Final Autopsy Diagnosis (FAD).

Results: 247 cases were positive for one or more key terms. In 91 cases the patient explicitly denied alcohol use, and FAD did not report alcohol-related death. 62 cases did not have documentation of the patient’s alcohol usage. 19/62 cases had autopsy findings that raised the possibility of alcohol-related death. These cases had complications from end stage liver disease associated with splenomegaly, esophageal varices, ulcers, jaundice, and ascites. Alcohol use disorder was not clinically confirmed, so the associated autopsy report could not causally attribute alcohol use to death. 66 cases had a clinical diagnosis of alcohol use disorder. 34/66 cases reported alcohol-related death on the FAD; 97% were from chronic use, and 2.9% from acute intoxication. 32/66 cases reported the disease and not alcohol-related death.

Conclusions: At our institution, alcohol-related deaths are underreported on the FAD. Although alcohol is a known causal factor in acute and chronic pancreatitis, liver disease, several cancers, cardiac dysrhythmia and other diseases, 48.5% autopsy cases reported the disease itself and not alcohol-related death. Alcohol-related death may be further underreported by issues that surfaced during our study. Patients who die from alcohol use may not get an autopsy. Also, patients may not disclose their true alcohol use. Another issue is clinicians may fail to document alcohol use in the medical chart. It is important to report alcohol-related deaths on the FAD because underreporting may have implications on public health awareness and affect funding for future research and disease prevention.

32 Disseminated Kaposi Sarcoma without Cutaneous Involvement in a Heart Transplant Patient with Well-Controlled HIV

Cindy Wang¹, Imran Uraizee¹, Rebeca Rocha¹, Girish Venkataraman², Lindsay Alpert¹
¹The University of Chicago, Chicago, IL, ²University of Chicago Medical Center, Chicago, IL

Disclosures: Cindy Wang: None; Imran Uraizee: None; Rebeca Rocha: None; Girish Venkataraman: *Consultant, Sylvant*; Lindsay Alpert: None

Background: A 40-year-old male with a history of Burkitt lymphoma status post chemoradiation therapy, HIV on highly active antiretroviral therapy (HAART) with a negative viral load, and non-ischemic cardiomyopathy status post heart transplant in March 2017 was transferred from an outside hospital with norovirus and parainfluenza infections. He was pancytopenic and had acute kidney injury. Diffuse lymphadenopathy was seen on CT scan, which was concerning for post-transplant lymphoproliferative disorder (PTLD). The patient experienced rapid clinical decline with respiratory failure and electrolyte derangements.

Design: Clinical records were reviewed and a complete unrestricted autopsy including external and internal gross examination was performed. Histologic evaluation included special stains and immunohistochemical studies.

Results: The autopsy revealed disseminated Kaposi sarcoma, confirmed by KHSV immunostain, involving the lungs, heart, stomach, small intestine, colon, pancreas and the cervical, mediastinal, mesenteric, para-aortic, and peripancreatic lymph nodes (Figure 1, Figure 2). Additionally, the bone marrow demonstrated hemophagocytic lymphohistiocytosis (HLH) without evidence of KS or PTLD (Figure 2). The cardiac allograft exhibited prominent concentric left ventricular hypertrophy, which is a known side effect of post-transplant immunosuppressive therapy. There was no clinical or autopsy evidence of cutaneous involvement by Kaposi sarcoma.

Figure 1 - 32

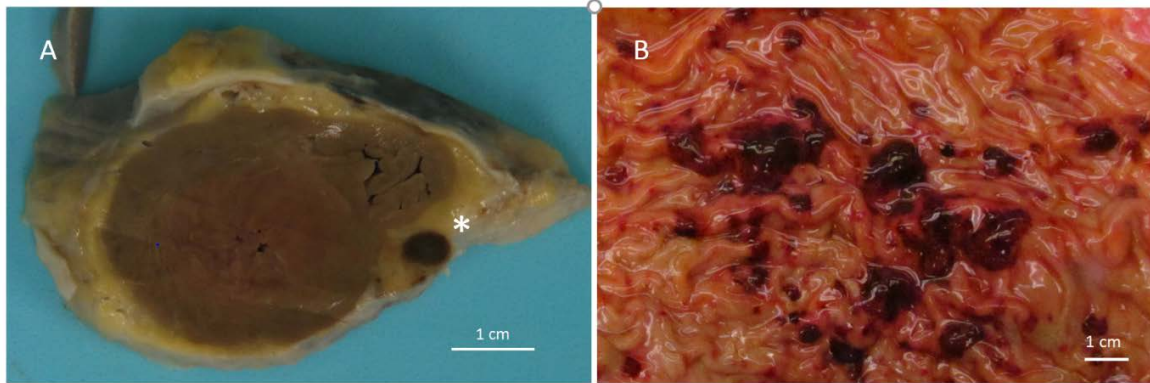


Figure 1: Gross images of organs involved by Kaposi sarcoma. A: Left ventricle with concentric hypertrophy and Kaposi sarcoma involving pericardial fat (*). B: Kaposi sarcoma involving stomach mucosa.

Figure 2 - 32

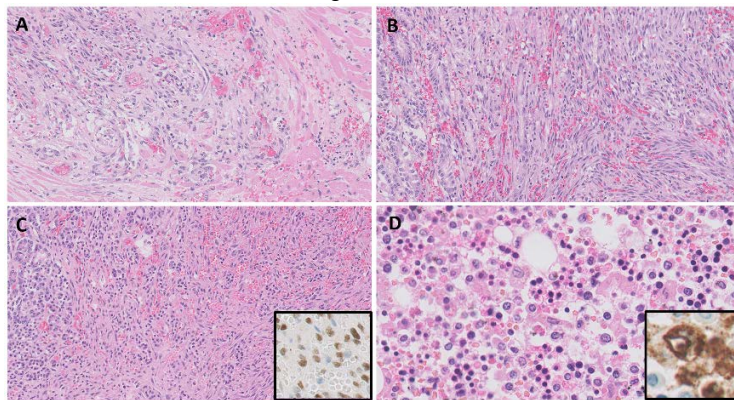


Figure 2: Disseminated Kaposi sarcoma involving myocardium (A), stomach (B), and pancreas with inset showing KHSV immunostain (C) (H&E at 10x, inset at 20x). The bone marrow demonstrates hemophagocytosis with inset showing macrophages highlighted by a CD68 immunostain (D) (H&E at 20x, inset at 40x).

Conclusions: Our case demonstrated hemophagocytic lymphohistiocytosis in the setting of disseminated Kaposi sarcoma without cutaneous involvement in a transplant patient with well-controlled HIV. Interestingly, human herpes virus 8 (HHV8) infection/Kaposi

sarcoma has been reported as a rare trigger for the development of HLH in transplant and HIV-infected patients. In the absence of cutaneous involvement, KS may prove to be a cryptic diagnosis due to systemic manifestations that are difficult to discriminate from other disease processes, particularly in the setting of an immunocompromised host.

33 Postmortem Microbiology Cultures, Usefulness and Cost: A Study of 652 Cases from the University of Vermont Medical Center Autopsy Service

Jonathan Wilcock¹, Elisha Johnson¹, Sharon Mount¹, Christina Wojewoda¹, Angela Theiss¹
¹The University of Vermont Medical Center, Burlington, VT

Disclosures: Jonathan Wilcock: None; Elisha Johnson: None; Sharon Mount: None; Christina Wojewoda: None

Background: The usefulness of postmortem cultures remains unclear in medical literature. Increasing healthcare costs and decreasing reimbursements put pressure on pathology departments to reduce spending. This is especially true for non-incoming generating services such as autopsy. Therefore, an increased understanding the costs as well as the characteristics of useful postmortem cultures has significant implications.

Design: A computer search identified all autopsy cases in which postmortem cultures were performed between 2013 and 2018. Culture results were compared to final autopsy reports to assess their usefulness. “Useful” was defined as helping to rule out a clinically suspected pathogen or revealing an unexpected clinically significant pathogen. “Not useful” included cases in which the culture results were non-contributory to the cause of death or were known prior to death. Costs were determined based on billing charges for each associated test. Cases were reviewed by the director of microbiology, an ABP board certified medical microbiologist.

Results: 652 autopsies were performed, with 179 cases performing microbiologic testing (27.45%). 43 cases (24.16 %) were considered useful, while 135 (75.84%) were not useful. Culture proved useful in 6.6% of all autopsies. The postmortem interval averaged 29.7 hours (range: 3 to 79 hours) for useful cultures and 41.0 hours (range: 3 to 288 hours) for those cultures that were not useful (p=0.07; 95% CI - 23.93 to 1.24). The estimated cost for postmortem cultures during the 5 year time span was \$37,330. The estimated average cost per useful culture was \$870.00. Elimination of non-useful cultures would result in a saving of approximately \$5660.00 per year. The usefulness of culture per case by sites examined is as follows: blood only 9/56 (16%); lung only 11/54 (20%); lung and blood 7/23 (30%), other 5/19 (26%); blood and other 5/14 (36%); lung and other 4/6 (67%); lung, blood and other 4/4 (100%).

Figure 1 - 33

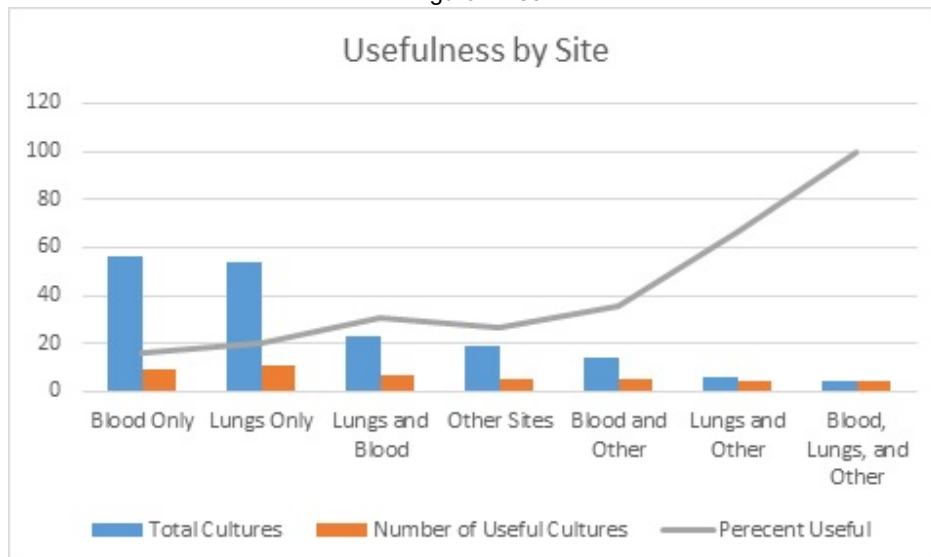
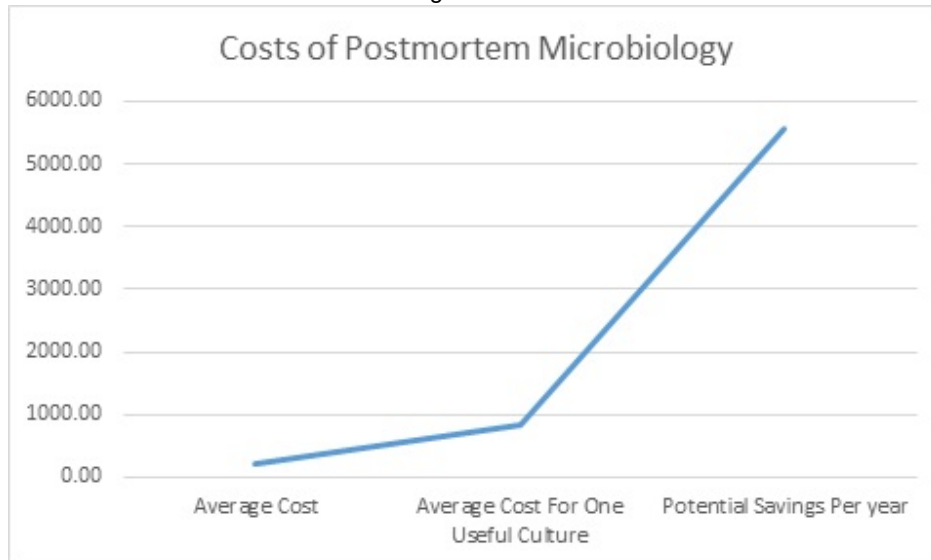


Figure 2 - 33



Conclusions: Postmortem culture results were useful in a small, but not insignificant number of cases (6.6%). The usefulness of culture increased when more sites were evaluated. The approximate average cost per useful culture was \$870.00. Useful cultures were obtained even in descendants with prolonged postmortem intervals. There would be a significant cost savings if selection of cases were based on appropriate clinical settings and culture locations. This study sheds light on the need to develop criteria for efficient postmortem microbiology.

34 Quantification of Liver Fibrosis in Autopsy Specimens of Young versus Elderly Patients

Jared Woods¹, Robert Padera¹, Lei Zhao²

¹Brigham and Women's Hospital, Boston, MA, ²Brigham and Women's Hospital, Harvard Medical School, Boston, MA

Disclosures: Jared Woods: None; Robert Padera: None; Lei Zhao: None

Background: Pathologic changes in human livers associated with aging are not well studied. For instance, fibrosis in the liver increases significantly with age in animal studies. However, the amount of fibrosis associated with natural aging in human livers has not been studied and whether that would affect clinical diagnosis of liver diseases is unclear. In this study we compared pathologic findings in young and old livers using archived autopsy specimens with an emphasis on degree of fibrosis. Metabolic syndrome was also taken into consideration when analyzing the data given its prevalence in the general population.

Design: Autopsy cases of young and elderly individuals from 2018 and 2019 were collected, and patients with known liver diseases including viral hepatitis, autoimmune hepatitis, hemochromatosis, biliary diseases, drug induced liver injury, hepatic venous outflow obstruction due to congenital heart diseases, and known cirrhosis were excluded. A detailed chart review was performed, and conditions related to metabolic syndrome (diabetes, dyslipidemia, hypertension, history of coronary artery disease, and myocardial infarction) were documented. 5 µm formalin-fixed, paraffin-embedded sections were stained with H&E and trichrome to quantify liver fibrosis and steatosis. Portal fibrosis was quantified with trichrome using the following grading scheme: 0=weak portal staining, 1=strong portal staining, 2=periportal, 3=bridging, 4=cirrhosis. The presence of steatosis, steatohepatitis, portal inflammation, and centrilobular fibrosis were also scored.

Results: Forty-nine liver sections from elderly patients (age 80-100) were analyzed. Twelve liver sections from young patients (ages 27-49) were used as controls. 4/12 young patients (33.3%) and 28/49 elderly patients (57.1%) had evidence of increased fibrosis. 4/12 young patients (33.3%) and 14/49 elderly patients (28.6%) had evidence of steatosis. After removing patients with features of metabolic syndrome from the analysis, 3/8 young patients (37.5%) and 5/9 elderly patients (55.6%) had evidence of increased fibrosis (p=0.5).

	N=12	N=49
Age (range, median)	27-49, 35	80-100, 85
Chart review		
History of coronary artery disease or myocardial infarction	0 (0)	25 (51.0%)
Diabetes	0 (0)	15 (30.6%)
Dyslipidemia	1 (8.3%)	19 (38.7%)
Hypertension	0 (0)	36 (73.5%)
Pathology review		
Steatosis	4 (33.3%)	14 (28.6%)
Steatohepatitis	1 (8.3%)	4 (8.2%)
Presence of increased fibrosis	4 (33.3%)	28 (57.1%)
Presence of centrilobular fibrosis	2 (16.7%)	14 (28.6%)
Portal inflammation	2 (16.7%)	7 (14.3%)
Excluding patients with clinical or histological evidence of metabolic syndrome		
	N=8	N=9
Age (range, median)	27-49, 33.5	80-92, 85
Evaluation of fibrosis (stage 0/stage1/stage2/stage3)	5/1/2/0	4/4/1/0

Conclusions: Liver fibrosis is common in elderly patients. Some percentage of fibrosis can be attributed to the increased prevalence of metabolic syndrome in aged individuals. For elderly patients with no evidence of metabolic syndrome, the liver may remain fibrosis free (by trichrome analysis) and does not differ significantly from the degree of fibrosis in younger patients.

35 Correlation between Coronary Angiography and Autopsy Findings in Patients with Coronary Artery Disease

Yan Zhou¹, Emilian Racila²

¹University of Minnesota, Minneapolis, MN, ²University of Minnesota Medical Center, Minneapolis, MN

Disclosures: Yan Zhou: None; Emilian Racila: None

Background: Autopsy is the gold standard and an important quality control in the clinical and imaging assessment of the extent of internal organ disease. Previous studies have shown that there are significant discrepancies between coronary cineangiography (CCA) and postmortem findings in patients with coronary artery disease (CAD). However, the extent to which these discrepancies impact the overall assessment of CAD severity and the degree of stenosis present in each of the main coronary arteries is not known. The aim of this study is to evaluate the correlation between CCA and autopsy findings in patients with CAD and to determine the degree to which discrepancies affect each of the main coronary arteries.

Design: Autopsy cases performed at our institution over the last four years have been investigated. A total of 212 cases with evidence of CAD were found. Cases were divided in three groups based on percentage of coronary artery stenosis: ≤50% mild, 51-75% moderate and ≥75% severe. The discrepancy between CCA and autopsy findings was considered significant if the difference was more than 20% between the two evaluation methods in each of the following coronary arteries: left anterior descending (LAD), left circumflex (LCX) and right coronary (RCA). 138 cases showed evidence of moderate or severe CAD in at least one coronary artery, population comprised of 86 men and 52 women.

Results: 39 of all CAD cases had available concurrent CCA data for analysis. In LAD, 9 of 16 mild CAD, 4 of 8 moderate CAD, and 5 of 15 severe CAD cases were discrepant. In LCX, 7 of 19 cases of mild CAD, 4 of 5 cases of moderate CAD, and 9 of 14 cases of severe CAD were discrepant. In RCA, 6 of 17 cases of mild CAD, 4 of 7 cases of moderate CAD, and 7 of 12 cases of severe CAD were discrepant. The CAD degree of stenosis was underestimated by CCA in 17 of 18 discrepant LAD cases, 18 of 20 discrepant LCX cases, and 12 of 17 discrepant RCA cases. In 6 of 18 LAD (33%), 7 of 20 LCX (35%), and 7 of 17 RCA (41%) the discrepancy resulted in upgrading from mild/moderate to severe CAD.

Conclusions: There is a significant rate of discrepancy between the severity of CAD as determined by CCA and postmortem examination. There are several potential explanations for discrepancy, such as the reference diameter used by each method to estimate stenosis. Nevertheless, autopsy remains the most accurate method to determine severity of disease and clinicians should be aware that CAD stenosis may be significantly underestimated in some patients.

36 Autopsy Climate Change: Autopsy Trends from 2000 to 2018, a Single Institution Analysis

Patricija Zot¹, Kaitlyn Wieditz¹, Austin Wiles¹

¹Virginia Commonwealth University Health System, Richmond, VA

Disclosures: Patricija Zot: None; Kaitlyn Wieditz: None; Austin Wiles: None

Background: Autopsy is a fundamental pathology procedure grounding clinical medicine and autopsy residency training. A minimum of 50 autopsies is required to sit for the Anatomic Pathology boards. Cases can be shared by two residents. Only 10 limited and 5 single organ autopsies are allowed to count towards a single resident’s quota. According to the law in the Commonwealth of Virginia, autopsy restrictions are placed by legal next of kin, limiting the agency of trainees to obtain case numbers. The purpose of this study is to quantify the types of internal autopsies performed at our institution, which averages about 1000 deaths per year, over 18 years (2000-2018) and identify trends in internal autopsy requests that may necessitate changes in institutional and autopsy service practice.

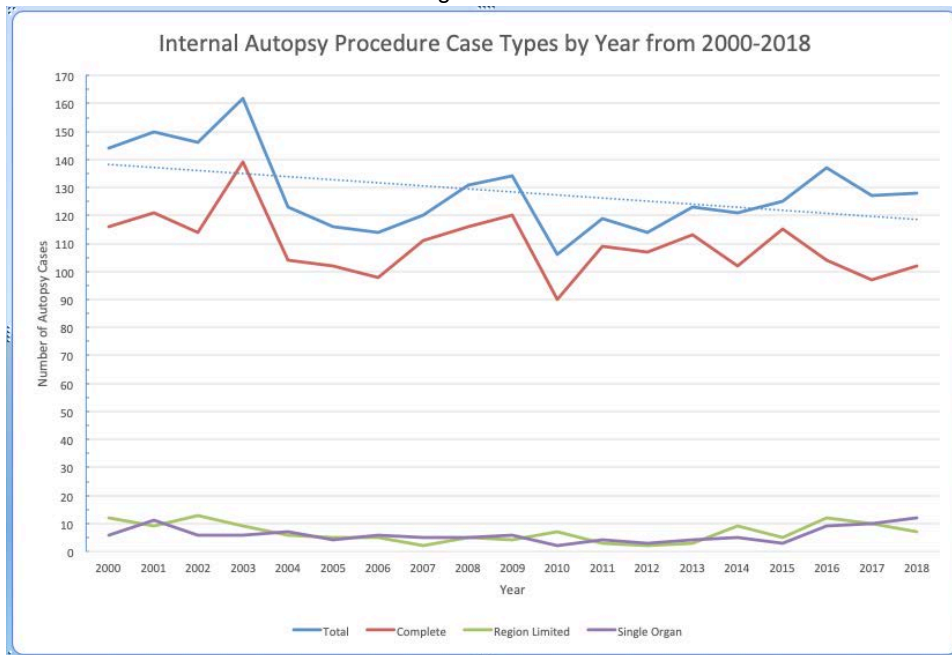
Design: The hard copy of the autopsy service logbook was reviewed for an 18-year period (2000-2018). The types of internal autopsies were counted per annum. These data were plotted over time to identify trends using linear regressions.

Results: Over 18 years, the average total number of internal autopsies per year has decreased by -0.95 cases/year, but there is a low correlation rate of $R^2 = 0.18$. The most common type of autopsy performed is a complete autopsy with CNS examination, but with a decreasing trend (-0.88 cases/year, $R^2 = 0.20$). Region limited autopsies (e.g. chest or abdomen only cases) are also declining (-0.12 cases/year) but with weak correlation ($R^2 = 0.04$). Autopsies limited to the chest are more common than those limited to the abdomen. Single organ autopsies are weakly increasing (+0.04 cases/year) also with a weak correlation ($R^2 = 0.01$). In summary, annual rates for all types of autopsy cases are declining with low correlation coefficients.

Table 1: Internal Autopsy Case Numbers and Types, Linear Regression Trends for our institution by year for 2000-2018.

Year		Autopsy Case Numbers						
		Total	Complete	Region Limited	Chest Only	Abdomen Only	Single Organ	Brain Only
2000		144	116	12	8	2	6	5
2001		150	121	9	5	4	11	7
2002		146	114	13	11	2	6	4
2003		162	139	9	5	3	6	6
2004		123	104	6	5	1	7	6
2005		116	102	5	3	2	4	2
2006		114	98	5	5	0	6	3
2007		120	111	2	1	1	5	4
2008		131	116	5	4	1	5	2
2009		134	120	4	3	1	6	4
2010		106	90	7	6	1	2	2
2011		119	109	3	2	1	4	3
2012		114	107	2	1	1	3	3
2013		123	113	3	3	0	4	2
2014		121	102	9	4	1	5	5
2015		125	115	5	1	1	3	2
2016		137	104	12	12	0	9	8
2017		127	97	10	8	2	10	8
2018		128	102	7	7	0	12	8
Linear Regression	Slope	-0.95	-0.88	-0.12	-0.03	-0.11	0.04	0.06
	R ²	0.18	0.20	0.04	0.00	0.38	0.01	0.02

Figure 1 - 36



Conclusions: While weakly correlated, there is an overall downward trend in internal autopsy procedures for our institution, which matches observed global phenomena. Since the numbers are small and there are no reference rates comparing institution size with autopsy rates, statistical significance is difficult to explore. Given the educational clinical quality importance of autopsy, immediate action seems indicated to defend these few cases. Motivational consent techniques, education of clinical colleagues, and outreach service expansion is likely needed to balance autopsy rate trends with training requirements and decisional autonomy of legal next of kin.