0031-3998/90/2806-0657$03.00/0
PEDIATRIC RESEARCH

Vol. 28, No. 6, 1990
Printed in U.S.A.

Deficiency of Long-Chain 3-Hydroxyacyl-CoA Dehydrogenase: A Cause of Lethal Myopathy and Cardiomyopathy in Early Childhood

FRANCIS ROCCHICCIOLI, RONALD J. A. WANDERS, PATRICK AUBOURG, CHRISTINE VIANEY-LIAUD, LODADWYK IJLST, MONIQUE FABRE, NATHALIE CARTIER, AND PIERRE-FRANCOIS BOUGNERES

Unité 188 INSERM and Pediatric Endocrinology, Saint Vincent de Paul Hospital, Paris, France [F.R., P.A., N.C., P.-F.B.]; Department of Pediatrics, University Hospital Amsterdam, Amsterdam, The Netherlands [R.J.A.W., L.I.]; Biochemistry Department, Debrousse Hospital, Lyon, France [C.V.-L.]; and Pathology Department, Kremlin-Bicêtre Hospital, France [M.F.]

ABSTRACT. A child presented in early childhood with episodes of coma and hypoglycemia and a rapidly evolutive myopathy and cardiomyopathy leading to death at 9 mo of age. Ketosis was decreased (blood β-hydroxybutyrate: 0.07 mmol/L) despite normal plasma levels of fatty acids (0.81 mmol/L). The patient's urine contained excessive amounts of the C_6 to C_{10} dicarboxylic acids present in almost all defects of fatty acid mitochondrial oxidation. More specifically, gas chromatography-mass spectrometry identified an accumulation of medium- and long-chain (C_8 to C_{14}) 3-hydroxy-dicarboxylic acids, suggesting a defect of the mitochondrial enzyme that normally dehydrogenates these 3-hydroxyacyl-CoA esters. Biochemical studies in the patient's cultured fibroblasts confirmed the impairment of medium- and long-chain fatty acid oxidation, and allowed the recognition of the deficiency of long-chain 3-hydroxyacyl-CoA dehydrogenase. The activities of long-, medium-, and short-chain acyl-CoA dehydrogenases and 3-ketoacyl-CoA thiolase were normal. These results describe a disorder of fatty acid metabolism that affects the liver, skeletal muscles, and myocardium. It is important to point out that long-chain 3-hydroxyacyl-CoA deficiency shares many clinical similarities with systemic carnitine deficiency, as well as with carnitine-palmityl-CoA transferase and long-chain acyl-CoA dehydrogenase deficiencies. The differential diagnosis of this disease relies on the demonstration of long-chain urinary dicarboxylic acids with a hydroxyl group in 3-position and the study of the enzyme activity in cultured fibroblasts. (*Pediatr Res* 28: 657–662, 1990)

Abbreviations

CoA, coenzyme A
LCAD, long-chain acyl-CoA dehydrogenase
MCAD, medium-chain acyl-CoA dehydrogenase
SCAD, short-chain acyl-CoA dehydrogenase

Defects of the mitochondrial oxidation of fatty acids represent a newly recognized area of inborn errors of metabolism (1, 2). After their carnitine-dependent transfer through the mitochondrial membranes, acyl-CoA esters are oxidized through four initial steps mediated by acyl-CoA dehydrogenase, enoyl-CoA hydratase, 3-hydroxyacyl-CoA dehydrogenase, and 3-ketoacyl-CoA thiolase (Fig. 1). There are three acyl-CoA dehydrogenases with different chain-length specificities: LCAD acts on acyl-CoA of more than 12 carbon atoms, MCAD acts on those that are six to 12 carbon atoms long, and SCAD on those with four to six carbon atoms. Defects of each of these enzymes, inherited in an autosomal manner, have been described since 1982, MCAD deficiency being by far the most common (2–7). However, in recent years, unidentified deficiencies of other enzymes of the β-oxidative pathway were known to exist in patients presenting obvious manifestations of a fatty acid oxidation defect, but normal acyl-CoA dehydrogenase activities (8–13).

Our report describes one of these patients, who developed recurrent hypoglycemia in early childhood and died at 9 mo of age from a rapidly progressive myopathy and cardiomyopathy, in whom biochemical studies demonstrated a specific defect of long-chain 3-hydroxyacyl-CoA dehydrogenase.

CASE REPORT

This female patient was first admitted to the Hôpital Saint Vincent de Paul of Paris at 9 mo of age because of major muscular weakness. Her parents were French caucasians and were considered in good health. The family medical history was entirely negative. The patient was the 3040-g product of a normal first pregnancy and, except for frequent upper respiratory tract infections, had been well, with normal growth and early development. At 5 mo of age, she developed fever (40°C) and started vomiting 2 h after the evening meal and with irritability and excitation before going to bed. At 0600 h, she was found unarousable in bed, with major hypotonia. She was admitted to a country hospital, where blood glucose was found at 20 mg/dL (1.12 mmol/L), was ressuscitated with i.v. glucose, and discharged without further investigation. One mo later, she was readmitted in the Children's Hospital of Montpellier with early morning coma and generalized seizures. Temperature was 37°C. At admission, blood glucose was 30 mg/dL (1.7 mmol/L). After correction of the hypoglycemia, the findings of the examination were unremarkable except for hypotonia and muscular weakness. Plasma insulin, growth hormone, and cortisol were normal. The girl was otherwise alert with normal cognitive development.

The child was referred 3 mo later to Saint Vincent de Paul Hospital because of a major deterioration of her status associated with aggravation of her muscular weakness and failure to thrive. On arrival she looked exhausted, but was normally conscious. Weight was 5.5 kg (10th percentile) and height 69.5 cm (50th percentile). The liver was soft and enlarged to 3 cm below the costal margin. The child was pale and had severe signs of my-

Received April 30, 1990; accepted July 23, 1990.
Correspondence: Patrick Aubourg, Unité 188 INSERM, Hôpital Saint Vincent de Paul, 82 avenue Denfert Rochereau, 75014 Paris, France.

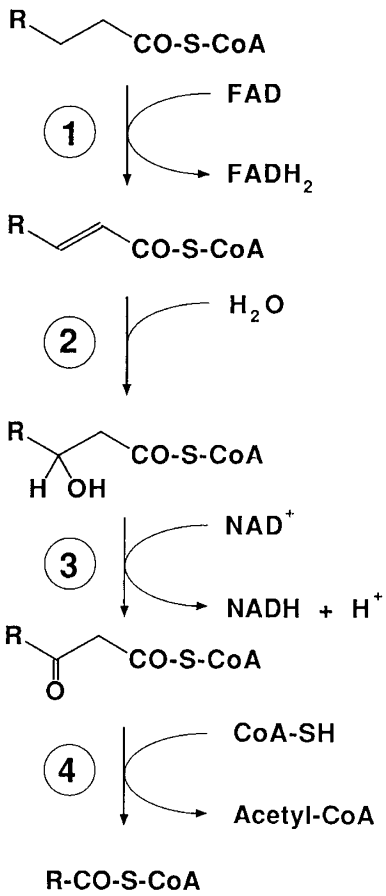

Fig. 1. Pathway of fatty acyl-CoA β-oxidation in mitochondria. An acyl-CoA enters the spiral and acyl-CoA dehydrogenase (*1*) inserts a double bond, forming an enoyl-CoA fatty acid. Enoyl-CoA hydratase (*2*) adds water across the double bond to form a 3-hydroxyacyl-CoA, which is oxidized by an NAD-linked 3-hydroxyacyl-CoA dehydrogenase (*3*) to form a 3-ketoacyl-CoA. In the presence of free coenzyme A (*CoASH*), 3-ketoacyl-CoA thiolase (*4*) yields acetyl-CoA and a two-carbons shorter acyl-CoA fatty acid.

Table 1. *Urine ketone bodies and dicarboxylic concentrations in patient**

	Patient	Controls (n = 48)
Ketone bodies		
Acetoacetate	3	0–10
β-hydroxybutyrate	14	8–40
Saturated dicarboxylic acids		
C_6	1710	5–20
C_8	414	2–8
C_{10}	557	0.5–3
C_{12}	23	ND
C_{14}	2	ND
Monounsaturated dicarboxylic acids		
C_6	20	0
C_8	34	0–0.01
C_{10}	224	0–0.05
C_{12}	ND	ND
C_{14}	ND	ND
3-Hydroxysaturated dicarboxylic acids		
C_6	29	ND
C_8	38	ND
C_{10}	187	ND
C_{12}	168	ND
C_{14}	55	ND
3-Hydroxy monounsaturated dicarboxylic acids		
C_6	5	ND
C_8	54	ND
C_{10}	33	ND
C_{12}	24	ND
C_{14}	190	ND
3-Hydroxy diunsaturated dicarboxylic acids		
C_6	ND	ND
C_8	ND	ND
C_{10}	ND	ND
C_{12}	4	ND
C_{14}	42	ND

* All results are expressed as mmol/mol creatinine. ND, not detectable.

opathy. She had a profound weakness and no active movement of the limbs against gravity. She remained in a frog leg position and had a poor cry. The face was inexpressive but without involvement of the extraocular muscles. The chest was flat with limited thoracic ampliation and unadapted respiratory efforts. Upper and lower limb muscles were severely atrophic and tendon reflexes could not be elicited. A gallop rhythm was noted, with a grade 2 systolic murmur and a rate of 150–180 beats per min. Systolic blood pressure was 70 mm Hg. Chest radiograph showed cardiomegaly with prominent left ventricle and a cardiothoracic index of 0.60. The ECG demonstrated peaked T waves in midprecordium and left ventricular hypertrophy.

Laboratory results included a plasma glucose of 72 mg/dL (4 mmol/L) and normal potassium, sodium, and chloride. Bicarbonate was 27 mmol/L, urea nitrogen 6.1 mmol/L, blood ammonia 143 μmol/L, hematocrit 37%, and white-cell count 8900/mm^3. No ketones were detectable in the urine. Aspartate transaminase was 31 IU/L ($n < 25$), alanine transaminase 77 IU/L ($n < 45$), and bilirubin 3.5 mmol/L. Creatine phosphokinase was 606 IU/L ($n < 120$) and lactate dehydrogenase 650 IU/L ($n < 240$). Plasma insulin was 6 μU/mL, cortisol 23 μg/dL.

A two-dimensional echocardiogram demonstrated a dilated, poorly contracting left ventricle, with minor aortic and mitral regurgitation. A urine specimen at the time of admission showed elevated concentrations of dicarboxylic acids (see Results). After a short fast, a blood specimen was obtained for measurement of glucose, lactate, FFA, β-hydroxybutyrate, and carnitine levels (see Results). The day after arrival, the child required mechanical ventilation. She was given i.v. glucose and L-carnitine at a dose of 200 mg/kg per d. Her condition thereafter rapidly deteriorated, and despite aggressive ressuscitation, the child died 24 h later with acute cardiac decompensation.

MATERIALS AND METHODS

Because of the severity of the child's status at arrival, metabolic studies were limited to a 6-h fast to get fasting values of the major circulating substrates, during which blood glucose levels were monitored frequently to avoid hypoglycemia.

Blood glucose, lactate, pyruvate, β-hydroxybutyrate, and plasma FFA concentrations were determined as previously described (14). Plasma carnitine levels were measured with a photometric method (15). Urine organic acids were measured as the trimethylsilyl derivatives by gas liquid chromatography-mass spectrometry (16).

Liver and skeletal muscle tissues were immediately collected after death, fixed in paraffin for light microscopy or fixed in glutaraldehyde for electron microscopy (17).

Oxidation of [1-^{14}C]palmitic, octanoic, and succinic acids to CO_2 by fibroblasts was measured as described previously (18). Acyl-CoA dehydrogenase activity for palmitic, octanoic, and succinic CoA esters was carried out essentially as described by

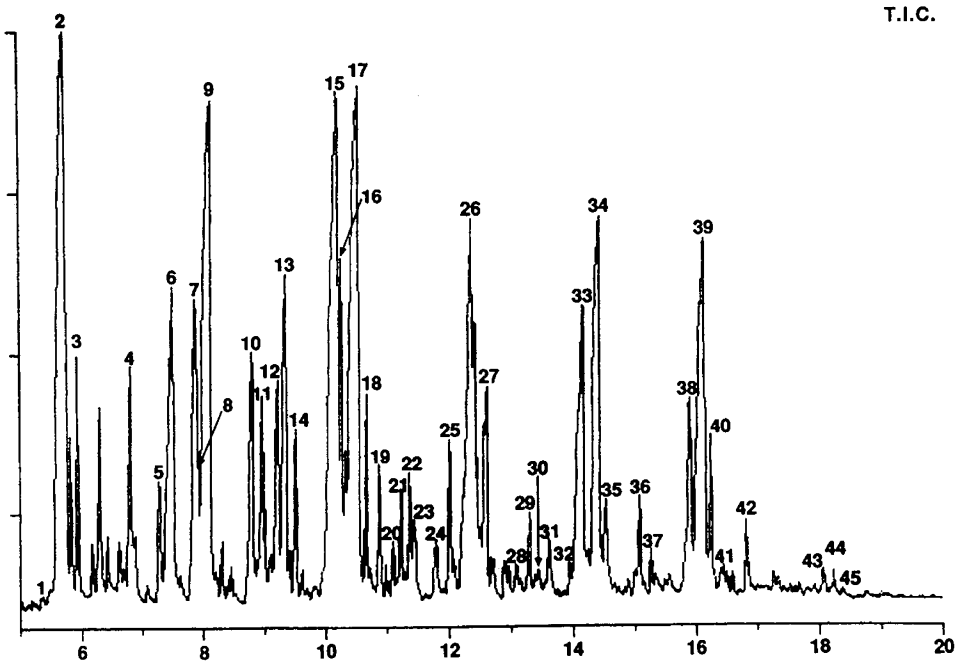

Fig. 2. urine organic acid profile from the patient. The peaks are identified as the trimethylsilyl derivatives of the following acids: *1*, unsaturated adipic acid; *2*, adipic acid; *3*, 3-methyladipic acid; *4*, pimelic acid; *5*, 2-ketoglutaric acid; *6*, *p*-hydroxyphenylacetic acid; *7*, unsaturated suberic acid; *8*, 3-hydroxyadipic acid; *9*, suberic acid; *10*, aconitic acid; *11*, unsaturated azelaic acid; *12*, azelaic acid and homovanillic acid; *13*, citric acid; *14*, isocitric acid; *15*, unsaturated sebacic acid; *16*, 3-hydroxysuberic acid; *17*, sebacic acid; *18*, vanylmandelic acid; *19*, *p*-hydroxyphenyllactic acid; *20*, unsaturated 3-hydroxyazelaic acid; *21*, 3-hydroxyazelaic acid; *22*, undecanedioic acid; *23*, palmitic acid; *24*, hippuric acid; *25*, unsaturated 3-hydroxysebacic acid; *26*, 3-hydroxysebacic acid; *27*, dodecanedioic acid; *28*, unsaturated 3-hydroxyundecanedioic acid; *29*, 3-hydroxyundecanedioic acid; *30*, tridecanedioic acid; *31*, stearic acid; *32*, diunsaturated 3-hydroxydodecanedioic acid; *33*, unsaturated 3-hydroxydodecanedioic acid; *34*, 3-hydroxydodecanedioic acid; *35*, tetradecanedioic acid; *36*, unsaturated 3-hydroxytridecanedioic acid; *37*, 3-hydroxytridecanedioic acid; *38*, diunsaturated 3-hydroxytetradecanedioic acid; *39*, unsaturated 3-hydroxytetradecanedioic acid; *40*, 3-hydroxytetradecanedioic acid; *41*, hexadecanedioic acid; *42*, diunsaturated 3-hydroxypentadecanedioic acid; *43*, diunsaturated 3-hydroxyhexadecanedioic acid; *44*, unsaturated 3-hydroxyhexadecanedioic acid; *45*, 3-hydroxyhexadecanedioic acid. The column used was a 25 m × 0.25 mm silica fused capillary column with CPSil 19 CB and temperature programmed at 8°C/min from 120 to 300°C. *T.I.C.*, total ion current *vs* time.

Coates *et al.* (5). The activity of 3-hydroxyacyl-CoA dehydrogenase for acetoacetyl-CoA, 3-keto-octanoyl-CoA and 3-keto-hexadecanoyl-CoA and the activity of 3-ketoacyl-CoA thiolase were measured in homogenates of cultured fibroblasts as recently described (19).

RESULTS

After not being fed for 6 h, the child had normal blood glucose (65 mg/dL, 3.6 mmol/L), low β-hydroxybutyrate concentration (0.07 mmol/L) with regard to rather elevated FFA (0.81 mmol/L), and lactate slightly above the upper limit of normality (3.75 mmol/L). Plasma total carnitine concentration was decreased (22 μmol/L, $n > 40$) with elevated urinary excretion (9.8 mol/mol creatinine, $n < 0.05$). Table 1 shows the urinary concentrations of acetoacetate, β-hydroxybutyrate, medium-chain dicarboxylic acids, and other metabolites derived from the abnormal catabolism of FFA in the patient. Although acetoacetate and β-hydroxybutyrate concentrations were low, suggesting an impairment of hepatic ketogenesis, the urinary dicarboxylic acids were markedly elevated in the patient. In addition, C_8 to C_{14} dicarboxylic acids hydroxylated in 3-position were identified by mass spectrometry analysis in the patient's urine (Fig. 2).

Light microscopy of the liver showed moderate portal fibrosis with micro- and macrovesicular steatosis. In addition to the presence of numerous neutral fat droplets, electron microscopy showed enlarged mitochondria with abnormal cristae in the hepatocytes (Fig. 3). The other organelles including peroxisomes showed no qualitative alterations. Light microscopy of skeletal muscle showed abnormal variation of type I and type II fibers with moderate evidence of lipid storage. Electron microscopy showed an increased number of mitochondria with abnormal cristae between the myofibrills (Fig. 4).

The data shown in Table 2 indicate that the oxidation of [1-^{14}C]palmitic acid by the patient's cultured fibroblasts is reduced to 45% of normal and that of [1-^{14}C] octanoate is reduced to 53% of normal. These values are similar to those reported in LCAD deficiency (2). However, with the electron transfer flavoprotein-based assay, we found that LCAD as well as MCAD and SCAD activities were within the normal range. Activity measurement of 3-ketoacyl-CoA thiolase using acetoacetyl-CoA as substrate was also normal. Although 3-hydroxyacyl-CoA dehydrogenase showed normal activity for acetoacetyl-CoA, its activity was reduced to 42% of the normal mean with 3-ketooctanoyl-CoA, a value close to −2 SD of the control group, and to 27% with 3-ketohexadecanoyl-CoA substrates, a value well below the normal range.

DISCUSSION

Our study describes a metabolic disorder of mitochondrial fatty acid oxidation associated with deficient activity of long-chain 3-hydroxyacyl-CoA-dehydrogenase. The clinical manifestations in our patient resemble the severe forms of LCAD deficiency in the following: multiple episodes of coma and hypoglycemia, striking involvement of cardiac and skeletal muscles, early onset within the first months of age, and poor prognosis (2, 6). However, patients with 3-hydroxyacyl-CoA dehydrogenase defi-

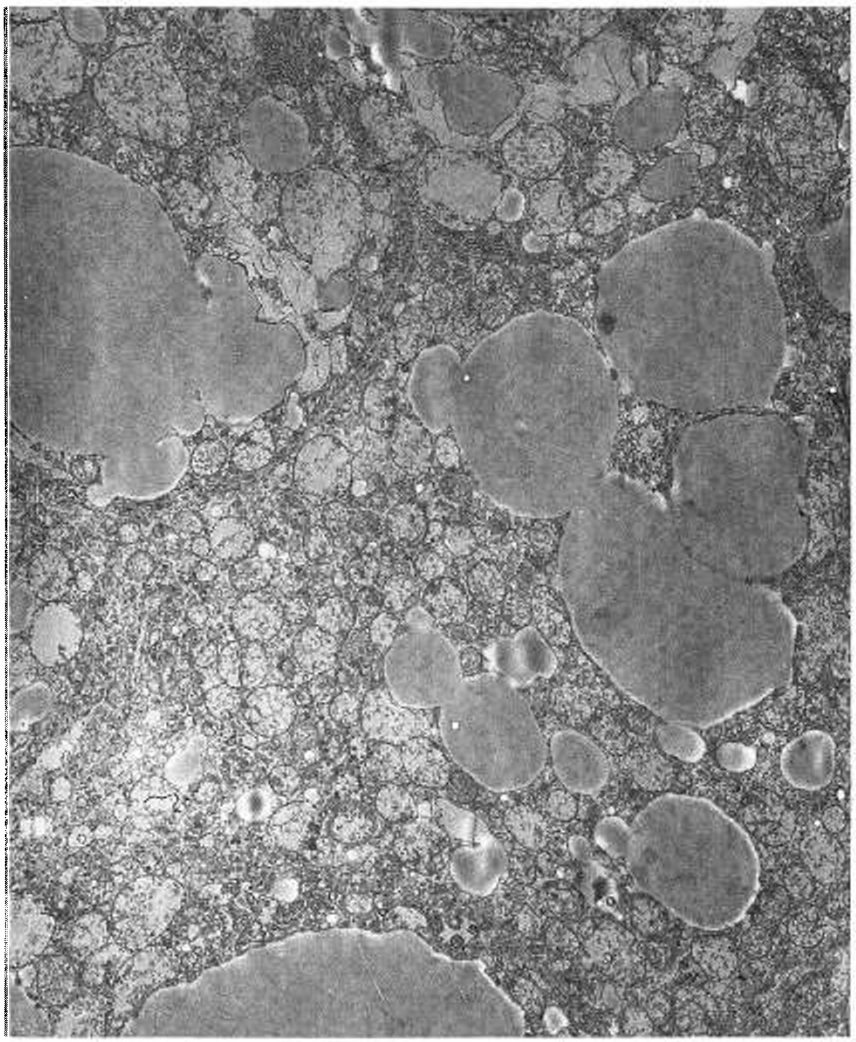

Fig. 3. Electron micrograph of hepatocyte from the patient. The cell is packed with numerous lipid droplets and enlarged rounded mitochondria with abnormal cristae. ×6600.

ciency may have less severe clinical manifestations (20): the limited number of cases does not presently allow a clinical overview of the disease.

The urinary organic profile reveals reduced ketogenesis and dicarboxylic aciduria, characteristic of a defect of hepatic fatty acid oxidation. As reported in patients with LCAD and MCAD, the low circulating plasma level of carnitine observed in our patient is likely to be a consequence of the defect of hepatic fatty acid oxidation (1, 2). The administration of carnitine because of our initial suspicion of carnitine deficiency did not reverse the rapidly fatal course of the cardiac decompensation. We even questioned whether it could have aggravated the situation, through an increase in the generation of possibly toxic long-chain dicarboxylic compounds. We were not able to confirm nor eliminate this hypothesis, which should therefore be kept in mind for the management of other patients with similar clinical syndromes.

In addition to the C_6 to C_{10} dicarboxylic aciduria observed in most, if not all (8, 20), reported cases of deficient β-oxidation, our patient excreted longer-chain C_{12} and C_{14} dicarboxylic acids with a hydroxyl group in 3-position. These compounds, not found in patients with LCAD deficiency, were reported in the urine of one patient with similar clinical presentation (8), who was proven subsequently to have a defect in fatty acid oxidation at the level of long-chain 3-hydroxyacyl-CoA dehydrogenation (20). This deficiency has been demonstrated in the cultured fibroblasts of our patient. There are two mitochondrial enzymes called 3-hydroxyacyl-CoA dehydrogenases, which catalyze the oxidation of the hydroxy group to a keto group in a NAD^+ dependent reaction. There is evidence to support the existence of two chain-length-specific 3-hydroxyacyl-CoA dehydrogenase enzymes in mammalian tissues, one being specific for short-chain substrates, the other for medium- and long-chain substrates (21, 22). Our patient had a combined defect of both palmitic (C_{16}) and octanoic (C_8) acid oxidation, demonstrable in her cultured fibroblasts. Whereas palmitic acid oxidation takes place in both mitochondria and peroxisome, the oxidation of octanoate is almost uniquely mitochondrial (23). We first established that the patient's defect in fatty acid oxidation was not due to a deficiency of any of the acyl-CoA dehydrogenases nor to a defect of 3-ketoacyl-CoA thiolase. With the use of a specific substrate, 3-ketohexadecanoyl-CoA, we found that the deficient step was at the level of long-chain 3-hydroxyacyl-CoA dehydrogenase. Because of the overlapping chain-length specificity of this enzyme with the short-chain 3-hydroxyacyl-CoA dehydrogenase, substrates such as 3-ketooctanoyl- and 3-ketodecanoyl-CoA can be partially oxidized.

Therefore, the oxidation of the long-chain acyl-CoA derived from the predominant C_{16} to C_{18} plasma fatty acids cannot continue beyond their hydroxylation in 3-position (Fig. 1). The

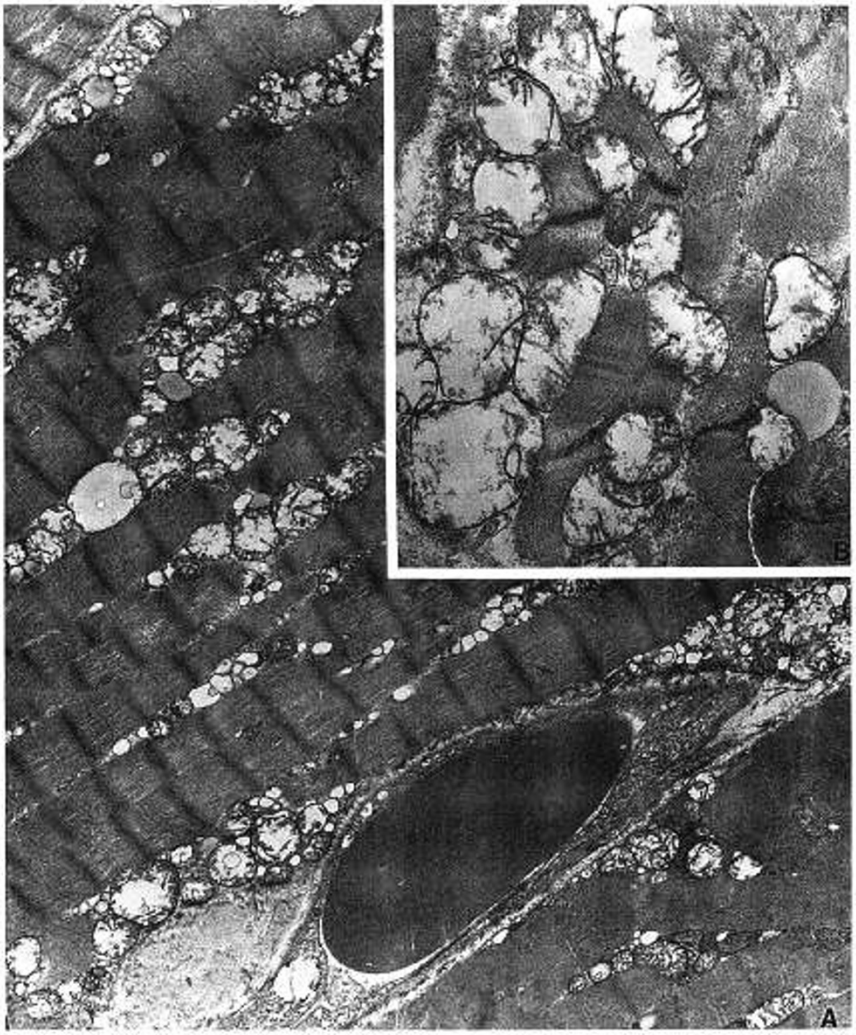

Fig. 4. Electron micrograph of longitudinally oriented muscle fibers from the patient showing (*A*) rows of mitochondria between the myofibrills (×6600) and (*B*, insert) increased cristae within the mitochondria (×10 800).

Table 2. *Fatty acid oxidation, acyl-CoA dehydrogenase, 3-ketoacyl-CoA thiolase, and 3-hydroxyacyl-CoA dehydrogenase activity measurements in cultured skin fibroblasts of patient and control subjects*

Activity measured	Substrate	Patient	Controls (n = 5)*
Fatty acid oxidation†	[1-^{14}C]-succinic	2.59	2.89 ± 0.80
	[1-^{14}C]-octanoic	0.66	1.25 ± 0.46
	[1-^{14}C]-palmitic	1.09	2.39 ± 0.36
Acyl-CoA dehydrogenase‡			
SCAD	Butyryl-CoA	1.16	1.23 ± 0.16
MCAD	Octanoyl-CoA	2.40	2.02 ± 0.41
LCAD	Palmityl-CoA	3.42	2.85 ± 0.62
3-Ketoacyl-CoA thiolase§	Acetoacetyl-CoA (+50 mmol/L K^+)	15.1	14.8 ± 3.20
3-Hydroxyacyl-CoA dehydrogenase§	Acetoacetyl-CoA	112.0	77.8 ± 12.1
	3-Keto-octanoyl-CoA	21.3	50.7 ± 17.0
	3-Keto-hexadecanoyl-CoA	19.3	71.2 ± 6.50
	C8/C4 activity ratio	0.19	0.51 ± 0.09
	C16/C4 activity ratio	0.17	0.91 ± 0.22

* Mean ± SD.
† nmol $^{14}CO_2/10^6$ cells/h.
‡ nmol electron transfer flavoprotein reduced/min/mg protein.
§ nmol/min/mg protein.

resulting C_8 to C_{14} 3-hydroxyacyl-CoA esters can leave the mitochondria, then undergo ω-oxidation in the microsomes and form the 3-hydroxy-dicarboxylic acids observed in the patient's urine. Alternatively, the C_{16} and C_{18} 3-hydroxylated compounds can be shortened by four to eight carbon atoms through the peroxisomal β-oxidation. The residual activity observed with 3-keto-hexadecanoyl-CoA (27%) is likely the reflection of the activity of the peroxisomal bifunctional protein toward this substrate (24).

In conclusion, it is important to point out the clinical and biochemical similarities between our observation and other defects in fatty acid oxidation, such as LCAD deficiency (2, 6), systemic carnitine deficiency (25), and carnitine-palmityltransferase deficiency (26). The muscular and cardiac involvement observed in our patient is consistent with the hypothesis that the accumulation of long-chain dicarboxylic acids, which occurs in all of these disorders, is directly toxic to these tissues (6). Another contributory mechanism to the predominant expression of the mitochondrial defect in muscle and heart can be the limited capacity of the alternative pathway of fatty acid peroxisomal β-oxidation in these tissues *versus* the liver (27), resulting in a more complete defect of the lipid-derived energy production.

REFERENCES

1. Vianey-Liaud C, Divry P, Gregersen N, Mathieu M 1987 The inborn errors of mitochondrial fatty acid oxidation. J Inher Metab Dis 10(suppl 1):159–198
2. Roe CR, Coates PM 1989 Acyl-CoA dehydrogenases deficiencies. In: Scriver CR, Beaudet AL, Sly WS, Valle D (eds) The Metabolic Basis of Inherited Disease. McGraw-Hill, New York, pp 889–914
3. Coates PM, Hale DE, Finocchiaro G, Tanaka K, Winter SC 1988 Genetic deficiency of short chain acyl-coenzyme A dehydrogenase in cultured fibroblasts from a patient with muscle carnitine deficiency and severe skeletal muscle weakness. J Clin Invest 81:171–175
4. Bougnères PF, Rocchiccioli F, Kølvraa S, Hadchouel M, Lalau Keraly J, Chaussain JL, Wadman SK, Gregersen N 1985 Medium-chain acyl-CoA dehydrogenase deficiency in two siblings with Reye-like syndrome. J Pediatr 106:918–921
5. Coates PM, Hale DE, Stanley CA, Corkey BE, Cortner JA 1985 Genetic deficiency of medium-chain acyl CoA dehydrogenase: studies in cultured skin fibroblasts and peripheral mononuclear leukocytes. Pediatr Res 19:671–676
6. Treem WR, Witzleben CA, Piccoli DA, Stanley CA, Hale DE, Coates PM, Watkins JB 1986 Medium-chain and long-chain acyl CoA dehydrogenase deficiency: clinical, pathologic and ultrastructural differentiation from Reye's syndrome. Hepatology 6:1270–1278
7. Hale DE, Batshaw ML, Coates PM, Frerman FE, Goodman SI, Singh I, Stanley CA 1985 Long-chain acyl coenzyme A dehydrogenase deficiency: an inherited cause of nonketonic hypoglycemia. Pediatr Res 19:666–671
8. Glasgow AM, Engel AG, Bier DM, Perry LW, Dickie M, Todaro J, Brown BI, Utter MF 1983 Hypoglycemia, hepatic dysfunction, muscle weakness, cardiomyopathy, free carnitine deficiency and long-chain acylcarnitine excess responsive to medium chain triglyceride diet. Pediatr Res 17:319–326
9. Bennett MJ, Gray RGF, Isherwood DM, Murphy N, Pollitt RJ 1985 The diagnosis and biochemical investigation of a patient with a short chain fatty oxidation defect. J Inherited Metab Dis 8(suppl 2):135–136
10. Pollitt RJ, Losty H, Westwood A 1987 3-Hydroxydicarboxylic aciduria: a distinctive type of intermittent dicarboxylic aciduria of possible diagnostic significance. J Inherited Metab Dis 10(suppl 2):266–269
11. Riudor E, Ribes A, Boronat M, Sabado C, Dominguez C, Ballabriga A 1986 A new case of C_6-C_{14} dicarboxylic aciduria with favourable evolution. J Inherited Metab Dis 9(suppl 2):297–299
12. Kelley RI, Morton DH 1988 3-Hydroxyoctanoic aciduria: identification of a new organic acid in the urine of a patient with non-ketotic hypoglycemia. Clin Chim Acta 175:19–26
13. Poll-The BT, Bonnefont JP, Ogier H, Charpentier C, Pelet A, Le Fur JM, Jakobs C, Kok RM, Duran M, Divry P, Scotto J, Saudubray JM 1988 Familial hypoketotic hypoglycaemia associated with peripheral neuropathy, pigmentary retinopathy and C_6-C_{14} hydroxydicarboxylic aciduria. A new defect in fatty acid oxidation? J Inherited Metab Dis 11(suppl 2):183–185
14. Bougnères PF, Lemmel C, Ferré P, Bier DM 1986 Ketone body transport in the human neonate and infants. J Clin Invest 77:42–48
15. Cederblat G, Harper P, Lindgren K 1986 Spectrophotometry of carnitine in biological fluids and tissues with a Cobas biocentrifugal analyzer. Clin Chem 32:342–346
16. Rocchiccioli F, Aubourg P, Bougnères PF 1986 Medium- and long-chain dicarboxylic aciduria in patients with Zellweger syndrome and neonatal adrenoleukodystrophy. Pediatr Res 20:62–66
17. Aubourg P, Robain O, Rocchiccioli F, Dancea S, Scotto J 1985 The cerebro-hepato-renal (Zellweger) syndrome: lamellar lipid profiles in adrenocortical, hepatic mesenchymal, astrocyte cells and increased levels of very long chain fatty acids and phytanic acid in plasma. J Neurol Sci 69:9–25
18. Kølvraa S, Gregersen N, Christensen E, Hobolth N 1982 *In vitro* fibroblast studies in a patient with C_6-C_{10} dicarboxylic aciduria: evidence for a defect in general acyl CoA dehydrogenase. Clin Chim Acta 126:53–67
19. Wanders RJA, Ijlst L, Van Gennip AH, Jakobs C, De Jager JP, Dorland L, Van Sprang FJ, Duran M 1990 Long-chain 3-hydroxyacyl-CoA dehydrogenase deficiency: identification of a new inborn error of mitochondrial fatty acid β-oxidation. J Inherited Metab Dis 13:311–314
20. Hale DE, Thorpe C, Braat K, Wright JH, Roe CR, Coates PM, Hashimoto T, Glasgow AM 1990 The L-3-hydroxyacyl-CoA dehydrogenase deficiency. In: Tanaka K, Coates PM (eds) Fatty Acid Oxidation, Clinical, Biochemical and Molecular Aspects. Alan R Liss, New York, pp 503–510
21. El-Fakhri M, Middleton B 1979 The existence of two different L-3-hydroxyacyl-coenzyme A dehydrogenases in rat tissues. Biochem Soc Trans 7:392–393
22. Osumi T, Hashimoto T 1979 Occurrence of two 3-hydroxyacyl-CoA dehydrogenases in rat liver. Biochim Biophys Acta 574:258–267
23. Hryb DJ, Hogg JF 1979 Chain length specificities of peroxisomal and mitochondrial β-oxidation in rat liver. Biochem Biophys Res Commun 87:1200–1206
24. Osumi T, Hashimoto T 1980 Purification and properties of mitochondrial and peroxisomal 3-hydroxyacyl-CoA dehydrogenase from rat liver. Arch Biochem Biophys 203:372–383
25. Waber LJ, Valle D, Neill C, Di Mauro S, Shug A 1982 Carnitine deficiency presenting as familial cardiomyopathy: a treatable defect in carnitine transport. J Pediatr 101:700–705
26. Bougnères PF, Saudubray JM, Marsac C, Bernard O, Odièvre M, Girard J 1981 Fasting hypoglycemia resulting from hepatic carnitine palmitoyl transferase deficiency. J Pediatr 98:742–746
27. Veerkamp JH, Moerkerk HTB 1986 Peroxisomal fatty acid oxydation in rat and human tissues. Effect of nutritional state, clofibrate treatment and postnatal development in the rat. Biochim Biophys Acta 875:301–310