

## 2016, the year of Zika virus

Diederik van de Beek and Matthijs C. Brouwer

In 2016, the literature on neurological infections was, understandably, dominated by Zika virus. However, we should not overlook important publications on the treatment of cryptococcal and bacterial meningitis.

Zika virus (ZIKV) sparked global attention in early 2016 after the first cases of brain developmental disorders in newborns were linked to ZIKV infection of their mothers during pregnancy<sup>1,2</sup> (FIG. 1). Initial reports of the *Aedes aegypti* mosquito-transmitted flavivirus epidemic described ZIKV as an exanthemic disease, similar to dengue and chikungunya virus infections<sup>2</sup>. As the epidemic unfolded, however, increasing numbers of newborns with microcephaly were diagnosed, raising suspicions of a causal relationship with ZIKV<sup>2,3</sup>.

An autopsy study of a fetus from a ZIKV-infected mother revealed microcephaly with lack of gyration, hydrocephalus, and multifocal calcifications in the cerebral cortex and subcortical white matter, together with mild focal inflammation<sup>1</sup>. Using reverse transcription PCR (RT-PCR) and electron microscopy, Mlakar and colleagues identified ZIKV in the fetal brain tissue in this particular case. A Brazilian study showed a 100-fold increase in microcephaly incidence from November 2015 to February 2016, mirroring the peak incidence of ZIKV infection<sup>3</sup>. After a review of the 1,501 suspected cases, 76 were classified as definite ZIKV-related brain developmental disorders, 54 as highly probable, 181 as moderately probable, and 291 as somewhat

probable. Of the affected live-born children, 80% had microcephaly, and the remainder had other congenital structural abnormalities of the brain.

Experimental studies provided further support for a causal link between ZIKV and microcephaly. In neural stem cell, neurosphere and brain organoid models, Garcez and colleagues showed that ZIKV could infect human brain cells and reduce their viability, which might lead to abrogation of neurogenesis during human brain development<sup>4</sup>. The offspring of mice and nonhuman primates infected with ZIKV show similar congenital brain disorders to those found in humans.

ZIKV was also found to be associated with a sharp rise in the incidence of Guillain-Barré syndrome (GBS), an inflammatory demyelinating polyneuropathy (FIG. 1). At the height of the ZIKV epidemic in early 2016, a cluster of GBS cases was observed in Colombia<sup>5</sup>. A total of 401 patients were identified with a neurological syndrome and a history of ZIKV infection, of whom 270 (67%) were diagnosed with GBS. Clinical features were reported for 68 patients, reporting to six university hospitals. The ZIKV infection presented with fever, rash, myalgia, headache, conjunctivitis and arthralgia, after which limb weakness, paraesthesia and

facial palsy developed. The mean duration between onset of ZIKV symptoms and GBS was 7 days, and 42% of patients did not have an asymptomatic period between ZIKV and GBS. The latter patients were classified as having a para-infectious onset, whereas those with a symptom-free interval were deemed to have post-infectious GBS<sup>5</sup>. The authors showed that RT-PCR in urine had the highest sensitivity (67%) for demonstrating ZIKV infection in this patient population. Positive serology (IgG or IgM) for ZIKV was identified in 86% of the patients.

The rate of encephalitis among ZIKV infected individuals is low, particularly when compared with other flavivirus infections, such as West Nile and dengue virus. A fatal case of ZIKV encephalitis was reported in Brazil in an otherwise healthy non-pregnant woman<sup>6</sup>. She presented with a rash and arthralgia, after which she rapidly developed leg weakness, dysarthria and confusion. After a gradual deterioration over a period of 10 days, severe brain oedema was observed, which eventually resulted in her death.

2016 was undoubtedly the year of ZIKV, but other important studies on the topic of neurological infections were published. Two large randomized clinical trials evaluated treatment options in HIV-associated cryptococcal meningitis<sup>7,8</sup>. Cryptococcosis is a defining opportunistic infection for AIDS, and is the second most common AIDS-defining illness in Africa. Therapies for cryptococcal meningitis are currently limited to three antifungal drugs (amphotericin B, 5-fluorocytosine and fluconazole) and treatment for complications (in particular, raised cerebrospinal fluid (CSF) pressure), and case fatality rates are high (30%). Oral therapies are desirable for resource-poor settings, which have the highest cryptococcal disease burden.

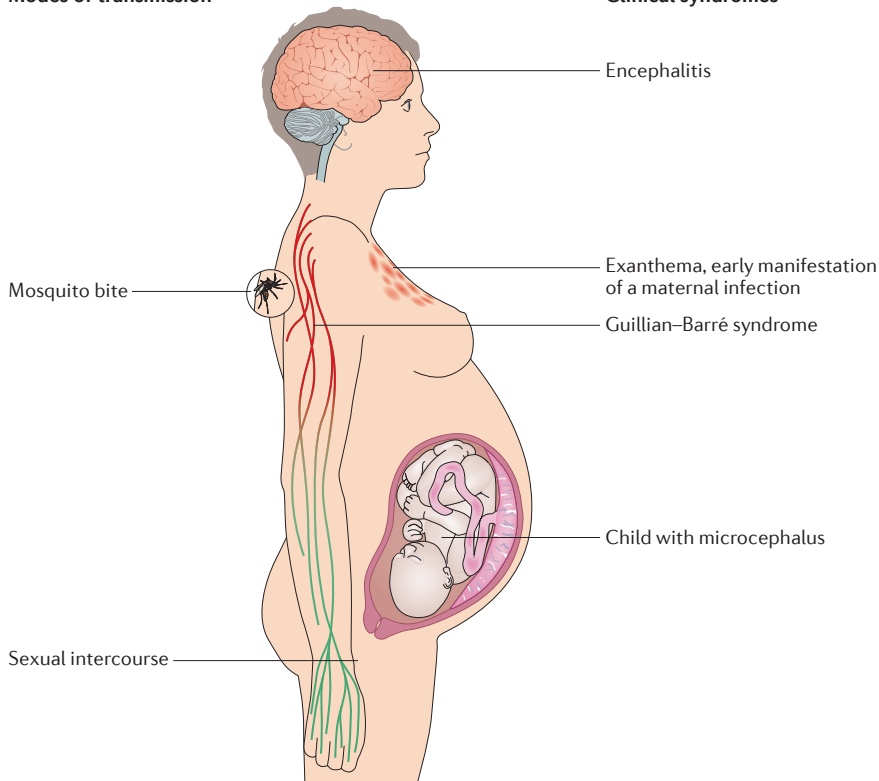
During brain infections, immune responses can exacerbate cerebral oedema and neurological damage, leading to coma and death. Therefore, adjunctive anti-inflammatory therapies might be of interest in cryptococcal meningitis. A double-blind, randomized, placebo-controlled trial published in 2016 attempted to answer a burning clinical question: what is the role of adjunctive dexamethasone therapy in HIV-associated cryptococcal meningitis? This

### Key advances

- Zika virus (ZIKV) infection disrupts neurogenesis in the fetal brain, resulting in neurodevelopmental disorders, most notably microcephaly<sup>3</sup>
- ZIKV infection has also been linked to Guillain-Barré syndrome<sup>5</sup>
- Dexamethasone does not reduce mortality, and increases disability, among patients with HIV-associated cryptococcal meningitis<sup>7</sup>
- Further investigation of adjunctive sertraline in cryptococcal meningitis is warranted<sup>8</sup>
- According to new guidelines, in suspected bacterial meningitis, antibiotic therapy should be started as soon as possible, and no more than 1 h after hospitalization<sup>10</sup>

## Modes of transmission

## Clinical syndromes



**Figure 1 | Zika virus transmission and clinical syndromes.** Zika virus (ZIKV) is commonly transmitted by the *Aedes aegypti* mosquito, but sexual transmission has also been reported. ZIKV infection presents with exanthema, and might lead to abrogation of neurogenesis during fetal brain development, resulting in microcephaly. During or after ZIKV infection, acute demyelinating inflammatory polyneuropathy can develop. In rare cases, ZIKV causes encephalitis.

important trial used a clinical end point, 10-week survival, but was stopped for safety reasons after inclusion of 451 adult patients with HIV-associated cryptococcal meningitis from Vietnam, Thailand, Indonesia, Laos, Uganda, and Malawi<sup>7</sup>. At 10 weeks, mortality rates were similar between groups, but the percentage of patients with disability was higher in the dexamethasone group than in the placebo group (OR 0.42, 95% CI 0.25–0.69,  $P < 0.003$ ). Patients in the dexamethasone group had impaired CSF fungal clearance compared with the placebo group. These findings show that adjunctive dexamethasone has no role in HIV-associated cryptococcal meningitis.

The second trial was an open-label, dose-finding trial on adjunctive sertraline for the treatment of HIV-associated cryptococcal meningitis<sup>8</sup>. Sertraline is a selective serotonin reuptake inhibitor with *in vitro* and *in vivo* fungicidal activity against *Cryptococcus* species. 112 participants from Uganda were randomly assigned to three different dose of sertraline for the first 2 weeks, followed by a consolidation dose for 8 weeks. The primary

outcome was the 2-week CSF clearance rate for *Cryptococcus*. At 12 weeks, 40% of the study participants had died, indicating the severity of disease. Participants receiving sertraline had faster cryptococcal CSF clearance and a lower incidence of immune reconstitution inflammatory syndrome and relapse than was reported in the past. No clear dose-response relationship between the sertraline dose and early fungicidal activity was found. Nevertheless, further investigation of adjunctive sertraline for cryptococcal meningitis in randomized clinical trials using clinical end points is warranted.

“ ZIKV was ... found to be associated with a sharp rise in the incidence of Guillain-Barré syndrome ”

The incidence of community-acquired bacterial meningitis decreased following the introduction of conjugate vaccines, but

the case fatality rate remains high (17%)<sup>9</sup>. In 2016, European guidelines for the diagnosis and treatment of acute bacterial meningitis were published by the European Society of Clinical Microbiology and Infectious Diseases (ESCMID)<sup>10</sup>. The guidelines state that empirical treatment with dexamethasone should be routine for all adults and children with acute bacterial meningitis in the setting of high-income countries. The guideline strongly recommends starting antibiotic therapy as soon as possible, and no more than 1 h after arrival at hospital<sup>10</sup>.

To summarize, 2016 was an exciting year for the CNS infections field. ZIKV infection during pregnancy was found to cause microcephaly and other severe fetal brain defects, and an increased incidence of GBS was reported in areas affected by ZIKV. Randomized clinical trials showed no role for adjunctive dexamethasone and promising effects of adjunctive sertraline in HIV-associated cryptococcal meningitis. Progress has been made in the treatment of bacterial meningitis over the past decade, but we are not there yet, and there is still an urgent need for new adjunctive treatments for cryptococcal and bacterial meningitis.

*Diederik van de Beek and Matthijs C. Brouwer are at the Department of Neurology, Amsterdam Neuroscience, Academic Medical Centre, University of Amsterdam, PO Box 22660, 1100DD Amsterdam, Netherlands.*

Correspondence to D.v.d.B. [d.vandebek@amc.uva.nl](mailto:d.vandebek@amc.uva.nl)

doi:10.1038/nrneuro.2016.202

Published online 13 Jan 2017

1. Mlakar, J. *et al.* Zika virus associated with microcephaly. *N. Engl. J. Med.* **374**, 951–958 (2016).
2. Brasil, P. *et al.* Zika virus infection in pregnant women in Rio de Janeiro. *N. Engl. J. Med.* **375**, 2321–2334 (2016).
3. Franca, G. V. *et al.* Congenital Zika virus syndrome in Brazil: a case series of the first 1501 livebirths with complete investigation. *Lancet* **388**, 891–897 (2016).
4. Garcez, P. P. *et al.* Zika virus impairs growth in human neurospheres and brain organoids. *Science* **352**, 816–818 (2016).
5. Parra, B. *et al.* Guillain-Barré syndrome associated with Zika virus infection in Colombia. *N. Engl. J. Med.* **375**, 1513–1523 (2016).
6. Soares, C. N. *et al.* Fatal encephalitis associated with Zika virus infection in an adult. *J. Clin. Virol.* **83**, 63–65 (2016).
7. Beardley, J. *et al.* Adjunctive dexamethasone in HIV-associated cryptococcal meningitis. *N. Engl. J. Med.* **374**, 542–554 (2016).
8. Rhein, J. *et al.* Efficacy of adjunctive sertraline for the treatment of HIV-associated cryptococcal meningitis: an open-label dose-ranging study. *Lancet Infect. Dis.* **16**, 809–818 (2016).
9. Bijlsma, M. W. *et al.* Community-acquired bacterial meningitis in adults in the Netherlands, 2006–2014: a prospective cohort study. *Lancet Infect. Dis.* **16**, 339–347 (2016).
10. van de Beek, D. *et al.* ESCMID guideline: diagnosis and treatment of acute bacterial meningitis. *Clin. Microbiol. Infect.* **22** (Suppl. 3), S37–S62 (2016).

### Competing interests statement

The authors declare no competing interests.