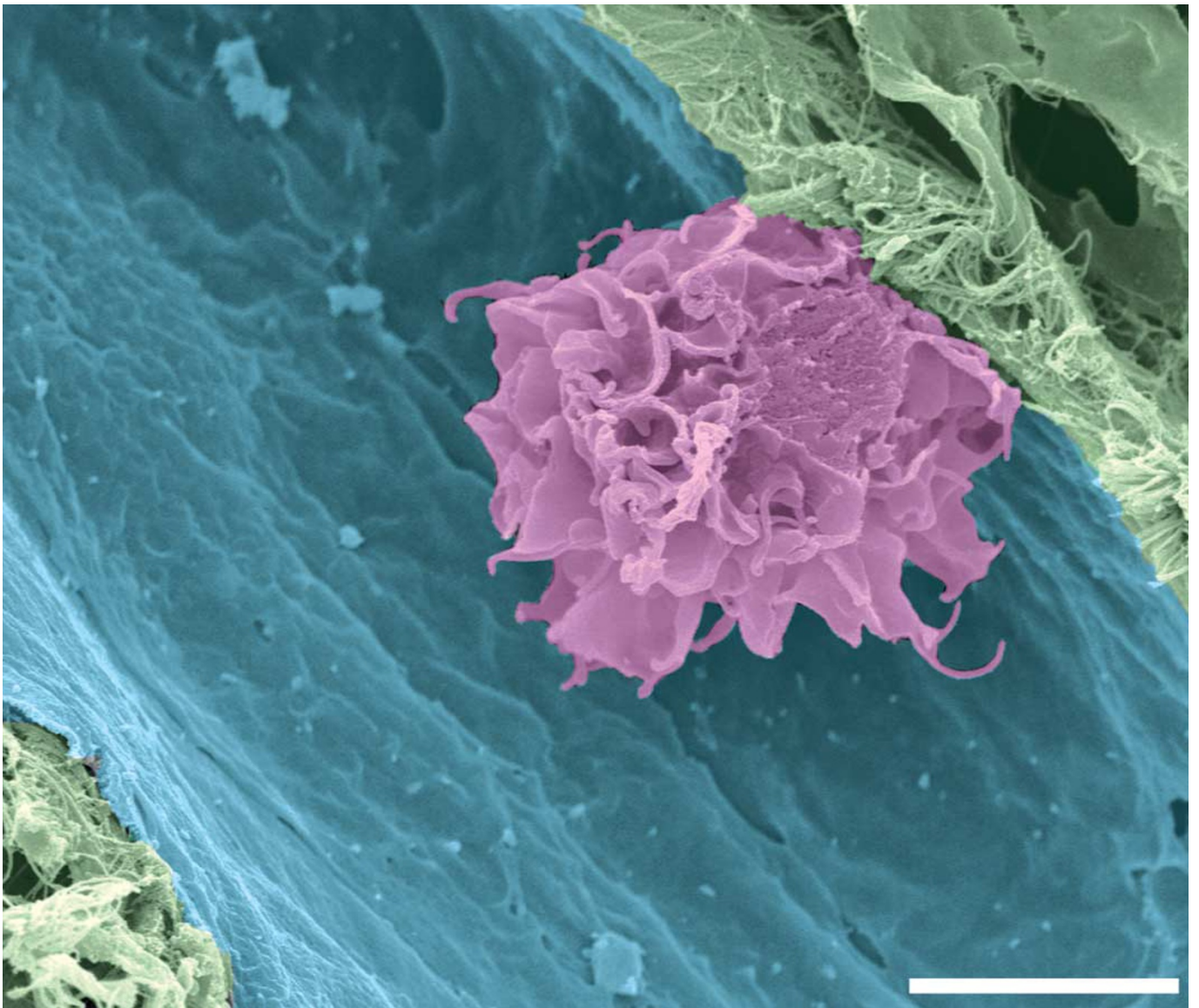


CELL OF THE MONTH



This month's winning image was submitted by Kristian Pfaller (University of Innsbruck, Austria (Kristian.Pfaller@uibk.ac.at)). It shows a human Langerhans cell in a dermal lymphatic vessel.

Purple and blue pseudo-colouring represent the dendritic cell and the lymphatic vessel, respectively. The specimen was examined in a field emission scanning electron microscope (DSM 982 Gemini, Zeiss). Bar, 5 μm .

The winner would like to acknowledge the help of Lukas A. Huber (Lukas.A.Huber@uibk.ac.at) and Patrizia Stoitzner (patrizia.stoitzner@uibk.ac.at) (both at the University of Innsbruck, Austria), who were also involved in this work.

We are pleased to acknowledge the help of our two external advisors, Ariel Ruiz i Altaba (Developmental Genetics Program, New York Medical Center) and Lelio Orci (Department of Morphology, University Medical Center, Geneva).