
Endoscopy

By
P.Perumal
Scientist
IVRI, Izatnagar

Definition

► Endoscopy means looking inside and typically refers to looking inside the body for medical reasons using an instrument called an endoscope.

► Endoscopy can also refer to using a borescope in technical situations where direct line-of-sight observation is not feasible

Introduction

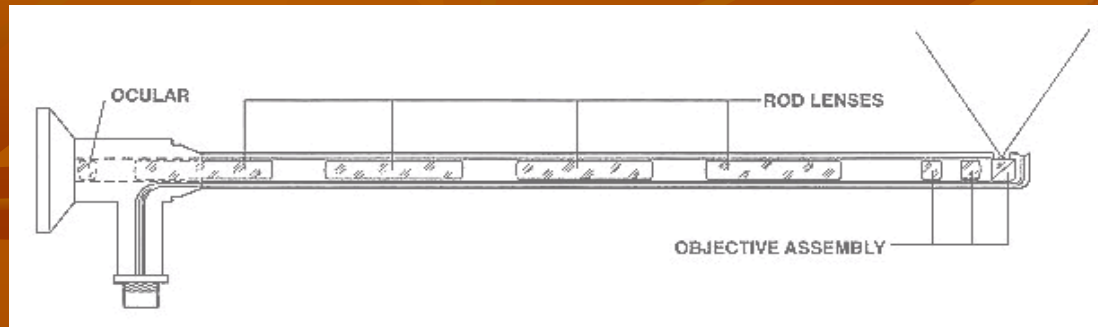
- Endoscopy is a minimally invasive diagnostic medical procedure that is used to assess the interior surfaces of an organ by inserting a tube into the body.
- The instrument may have a rigid or flexible tube and not only provide an image for visual inspection and photography, but also enable taking biopsies and retrieval of foreign objects.
- Endoscopy is the vehicle for minimally invasive surgery and patients may receive conscious sedation so they do not have to be consciously aware of the discomfort.
- Many endoscopic procedures are considered to be relatively painless and, at worst, associated with moderate discomfort.

History

Nature Precedings : doi:10.1038/npre.2012.7064.1 : Posted 31 Mar 2012

- The first endoscope - 1806 by **Philip Bozzini** with his introduction of a "Lichtleiter" (light conductor)
- An endoscope was first introduced into a human in 1822 by **William Beaumont**
- **Hans Christian Jacobaeus** - early endoscopic explorations of the abdomen and the thorax with **laparoscopy** (1912) and **thoracoscopy** (1910).
- Laparoscopy was used in the diagnosis of **liver** and **gallbladder** disease by **Heinz Kalk** in the 1930s.
- **Hope** reported in 1937 on the use of laparoscopy to diagnose **ectopic pregnancy**.
- In 1944, **Raoul Palmer** placed his patients in the **Trendelenburg position** after gaseous distention of the abdomen and thus was able to reliably perform **gynecologic** laparoscopy.
- The gastroscope was first developed in 1952 by a Japanese team of a doctor and optical engineers.
- In 1950s **Harold Hopkins** designed a "fibroscope" (a coherent bundle of flexible glass fibres able to transmit an image), which proved useful both medically and industrially.
- **Fernando Alves Martins**, from Portugal, invents the first fibre optics endoscope (1963/64)

Components



An endoscope can consist of

A rigid or flexible tube

A light delivery system to illuminate the organ or object under inspection. The light source is normally outside the body and the light is typically directed via an optical fiber system

- S lens system transmitting the image to the viewer from the fiberscope
- An additional channel to allow entry of medical instruments or manipulators

Types

The gastrointestinal tract (GI tract):

esophagus, stomach and duodenum
(esophagogastroduodenoscopy)

small intestine (enteroscopy)

large intestine\colon (colonoscopy, sigmoidoscopy)

bile duct

□ endoscopic retrograde cholangiopancreatography (ERCP),
duodenoscope-assisted cholangiopancreatography,
intraoperative cholangioscopy

rectum (rectoscopy) and anus (anoscopy), both also referred to
as (proctoscopy)

The respiratory tract

□ The nose (rhinoscopy)

□ The lower respiratory tract (bronchoscopy)

Normally closed body cavities (through a small incision):

- ❑ **The abdominal or pelvic cavity (laparoscopy)**
- ❑ **The interior of a joint (arthroscopy)**
- ❑ **Organs of the chest (thoracoscopy and mediastinoscopy)**

The ear (otoscope)

The urinary tract (cystoscopy)

The female reproductive system (gynoscopy)

- ❑ **The cervix (colposcopy)**
- ❑ **The uterus (hysteroscopy)**
- ❑ **The fallopian tubes (falloscopy)**

During pregnancy

- ❑ The amnion (amnioscopy)
- ❑ The fetus (fetoscopy)

■ Plastic Surgery

■ Panendoscopy (or triple endoscopy)

- ❑ Combines laryngoscopy, esophagoscopy, and bronchoscopy

■ Hand Surgery, such as endoscopic carpal tunnel release surgery

Non-medical uses for endoscopy

- ❑ The planning and architectural community have found the endoscope useful for pre-visualization of scale models of proposed buildings and cities (architectural endoscopy)
- ❑ Internal inspection of complex technical systems (borescope)
- ❑ Endoscopes are also a tool helpful in the examination of improvised explosive devices by bomb disposal personnel.
- ❑ The FBI uses endoscopes for conducting surveillance via tight spaces.

Uses of Endoscopy

Fibre optic endoscopes now have widespread use in medicine and guide a myriad of diagnostic and therapeutic procedures including:

- **Arthroscopy**: examination of joints for diagnosis and treatment (arthroscopic surgery)
- **Bronchoscopy**: examination of the trachea and lung's bronchial trees to reveal abscesses, bronchitis, carcinoma, tumors, tuberculosis, alveolitis, infection, inflammation
- **Colonoscopy**: examination of the inside of the colon and large intestine to detect polyps, tumors, ulceration, inflammation, colitis diverticula, Crohn's disease, and discovery and removal of foreign bodies.
- **Colposcopy**: direct visualization of the vagina and cervix to detect cancer, inflammation, and other conditions.
- **Cystoscopy**: examination of the bladder, urethra, urinary tract, uterine orifices, and prostate (men) with insertion of the endoscope through the urethra.

- **ERCP** (endoscopic retrograde cholangio-pancreatography) uses endoscopic guidance to place a catheter for x-ray fluoroscopy with contrast enhancement.
- This technique is used to examine the liver's biliary tree, the gallbladder, the pancreatic duct and other anatomy to check for stones, other obstructions and disease. X-ray contrast is introduced into these ducts via catheter and fluoroscopic x-ray images are taken to show any abnormality or blockage.
- ERCP can detect biliary cirrhosis, cancer of the bile ducts, pancreatic cysts, pseudocysts, pancreatic tumors, chronic pancreatitis and other conditions such as gallbladder stones.
- **Esophogegastroduodensoscopy** (EGD): visual examination of the upper gastro-intestinal (GI) tract. (also referred to as gastroscopy) to reveal hemorrhage, hiatal hernia, inflammation of the esophagus, gastric ulcers.
- Endoscopic biopsy is the removal of tissue specimens for pathologic examination and analysis.

- **Gastroscopy**: examination of the lining of the esophagus, stomach, and duodenum. Gastroscopy is often used to diagnose ulcers and other sources of bleeding and to guide biopsy of suspect GI cancers.
- **Laparoscopy**: visualization of the stomach, liver and other abdominal organs including the female reproductive organs, for example, the fallopian tubes.
- **Laryngoscopy**: examination of the larynx (voice box).
- **Proctoscopy**, sigmoidoscopy, proctosigmoidoscopy: examination of the rectum and sigmoid colon.
- **Thoracoscopy**: examination of the pleura (sac that covers the lungs), pleural spaces, mediastinum, and pericardium.

Endoscopy has little value for people with the following conditions

- **Severe coronary artery disease and acute or recent heart attack**
- **Uncontrolled high or low blood pressure**
- **Shock**
- **Massive upper GI bleeding**
- **Acute peritonitis (inflammation of certain tissues in your abdomen)**
- **Injuries of the cervical spine**
- **Perforation of organs of the upper GI tract and A history of respiratory distress**
- **Severe coagulopathy, a disease in which you continue bleeding because of inadequate clotting in your blood**
- **Recent upper GI tract surgery**
- **Long-standing and stable inflammatory bowel diseases (except for watching cancers)**

- **Chronic irritable bowel syndrome and Acute and self-limiting diarrhea**
- **Bloody or tarry stools with a clear source of the bleeding**
- **Pregnancy in second or third trimester**
- **History of severe chronic obstructive pulmonary disease**
- **Recent colon surgery or past surgery of your abdomen or pelvis resulting in internal adhesions**
- **Acute diverticulitis**
- **Tear in a blood vessel in your abdomen**
- **Sudden colon inflammation and Acute inflammation of the sac that lines your abdomen**
- **Non- correctable coagulopathy, a disease in which you continue bleeding due to inadequate clotting factors in your blood**
- **Massive gastrointestinal bleeding**

Mechanism of function of endoscope

- Endoscopy allows physicians to peer through the body's passageways. Endoscopy is the examination and inspection of the interior of body organs, joints or cavities through an endoscope. An endoscope is a device that uses fiber optics and powerful lens systems to provide lighting and visualization of the interior of a joint. The portion of the endoscope inserted into the body may be rigid or flexible, depending upon the medical procedure.
- An endoscope uses two fiber optic lines. A "light fiber" carries light into the body cavity and an "image fiber" carries the image of the body cavity back to the physician's viewing lens. There is also a separate port to allow for administration of drugs, suction, and irrigation. This port may also be used to introduce small folding instruments such as forceps, scissors, brushes, snares and baskets for tissue excision (removal), sampling, or other diagnostic and therapeutic work. Endoscopes may be used in conjunction with a camera or video recorder to document images of the inside of the joint or chronicle an endoscopic procedure. New endoscopes have digital capabilities for manipulating and enhancing the video images.

Upper GI Endoscopy

- **Upper GI endoscopy is a procedure that uses a lighted, flexible endoscope to see inside the upper GI tract. The upper GI tract includes the esophagus, stomach, and duodenum—the first part of the small intestine.**
- **Upper GI endoscopy can detect:** ulcers, abnormal growths, precancerous conditions, bowel obstruction, inflammation, hiatal hernia
- **Upper GI endoscopy can be used to determine the cause of:** abdominal pain, nausea, vomiting, swallowing difficulties, gastric reflux, unexplained weight loss, anemia, bleeding in the upper GI tract
- **Upper GI endoscopy can be used to** remove stuck objects, including food, and to treat conditions such as bleeding ulcers. It can also be used to biopsy tissue in the upper GI tract. During a biopsy, a small piece of tissue is removed for later examination with a microscope.

Points to Remember

- **Upper gastrointestinal (GI) endoscopy is a procedure that uses a lighted, flexible endoscope to see inside the upper GI tract.**
- **To prepare for upper GI endoscopy, no eating or drinking is allowed for 4 to 8 hours before the procedure. Smoking and chewing gum are also prohibited.**
- **Patients should tell their doctor about all health conditions they have and all medications they are taking.**
- **Driving is not permitted for 12 to 24 hours after upper GI endoscopy to allow the sedative time to wear off. Before the appointment, patients should make plans for a ride home.**
- **Before upper GI endoscopy, the patient will receive a local anesthetic to numb the throat.**

- **An intravenous (IV) needle is placed in a vein in the arm if a sedative will be given.**
- **During upper GI endoscopy, an endoscope is carefully fed into the upper GI tract and images are transmitted to a video monitor.**
-
- **Special tools that slide through the endoscope allow the doctor to perform biopsies, stop bleeding, and remove abnormal growths.**
- **After upper GI endoscopy, patients may feel bloated or nauseated and may also have a sore throat.**
- **Unless otherwise directed, patients may immediately resume their normal diet and medications.**
- **Possible risks of an upper GI endoscopy include abnormal reaction to sedatives, bleeding from biopsy, and accidental puncture of the upper GI tract.**

Esophagogastroduodenoscopy

- **Esophagogastroduodenoscopy is a diagnostic endoscopic procedure that visualizes the upper part of the gastrointestinal tract up to the duodenum.**
- **It is considered a minimally invasive procedure since it does not require an incision into one of the major body cavities and does not require any significant recovery after the procedure.**

Indications

**Diagnostic
Surveillance
Therapeutic**

Diagnostic

- **Upper gastrointestinal bleeding as evidenced by hematemesis or melena**
- **Unexplained anemia (usually along with a colonoscopy)**
- **Persistent dyspepsia in patients over the age of 40-45 years**
- **Heartburn and chronic acid reflux - this can lead to a precancerous lesion called Barrett's esophagus**
- **Persistent vomiting**
- **Dysphagia - difficulty in swallowing**
- **Odynophagia - painful swallowing**

● **Surveillance**



- **Surveillance of Barrett's esophagus**
- **Surveillance of gastric ulcer or duodenal ulcer**
- **Occasionally after gastric surgery**
- **Confirmation of diagnosis/biopsy**
- **Abnormal barium swallow or barium meal**
- **Confirmation of celiac disease (via biopsy)**

Therapeutic

Treatment (banding/sclerotherapy) of esophageal varices

- Injection therapy (e.g. epinephrine in bleeding lesions)
- Cutting off of larger pieces of tissue with a snare device (e.g. polyps, endoscopic mucosal resection)
-
- Application of cautery to tissues
- Removal of foreign bodies (e.g. food) that have been ingested
- Tamponade of bleeding esophageal varices with a balloon

- Application of photodynamic therapy for treatment of esophageal malignancies
- Endoscopic drainage of pancreatic pseudocyst
- Tightening the lower esophageal sphincter
- Dilating or stenting of stenosis or achalasia
- Percutaneous endoscopic gastrostomy (feeding tube placement)
- Endoscopic retrograde cholangiopancreatography (ERCP) combines EGD with fluoroscopy
- Endoscopic ultrasound (EUS) combines EGD with 5-12 MHz ultrasound imaging

Complications

The complication rate is about 1 in 1000.

They include:

- **Aspiration, causing aspiration pneumonia**
- **Bleeding**
- **Perforation**
- **Cardiopulmonary problems**

Enteroscopy

Enteroscopy is medical equipment for the direct visualization of small bowel.

Types

- fiber optic endoscope
 - Double-balloon enteroscopy
 - Single-balloon enteroscopy
- wireless endoscopy system
 - Capsule endoscopy

Double-balloon enteroscopy

- Double-balloon enteroscopy, also known as push-and-pull enteroscopy is an endoscopic technique for visualization of the small bowel. It was developed by Hironori Yamamoto in 2001.
- It is novel in the field of diagnostic gastroenterology as it is the first endoscopic technique that allows for the entire gastrointestinal tract to be visualized in real time.

Indications

Double-balloon enteroscopy has found a niche application in the following settings:

- **bleeding from the gastrointestinal tract of obscure cause**
- **iron deficiency anemia with normal colonoscopy and gastroscopy**
- **visualization and therapeutic intervention on abnormalities seen on traditional small bowel imaging**
- **ERCP in post-surgical patients with long afferent limbs**

Advantages

- Endoscopic image of polyp in small bowel detected on double-balloon enteroscopy.
 - Double-balloon enteroscopy offers a number of advantages to other small bowel image techniques, including barium imaging, wireless capsule endoscopy and push enteroscopy:
 - It allows for visualization of the entire small bowel to the terminal ileum
 - It allows for the application of therapeutics
 - It allows for the sampling or biopsying of small bowel mucosa, for the resection of polyps of the small bowel, and in the placement of stents or dilatation of strictures of the small bowel.
 - It allows for access to the papilla in patients with long afferent limbs after Billroth II antrectomy.
-

Disadvantages

- **The key disadvantage of double-balloon enteroscopy is the time required to visualize the small bowel; this can exceed three hours, and may require that patients be admitted to hospital for the procedure.**
- **There has also been case reports of acute pancreatitis and intestinal necrosis associated with the technique.**

Sigmoidoscopy

Sigmoidoscopy is the **minimally invasive medical** examination of the large **intestine** from the **rectum** through the last part of the **colon**.

- There are two types of sigmoidoscopy, flexible sigmoidoscopy, which uses a flexible **endoscope**, and rigid sigmoidoscopy, which uses a rigid device.
- Flexible sigmoidoscopy is generally the preferred procedure.
- A sigmoidoscopy is an effective screening tool.
- A sigmoidoscopy is similar but not the same as a **colonoscopy**.
- A Sigmoidoscopy only examines up to the **sigmoid**, the most distal part of the colon, while colonoscopy examines the whole large bowel.

Risks

- **Quite safe, sigmoidoscopy does carry the very rare possibility of **tearing of the intestinal wall** by the instrument, which would require immediate major surgery to repair the tear;**
- **In addition, removal of a polyp may sometimes lead to localized bleeding which is resistant to cauterization by the instrument and must be stopped by surgical intervention.**

Colonoscopy

- Colonoscopy is the **endoscopic** examination of the **colon** and the distal part of the **small bowel** with a **CCD camera** or a **fiber optic** camera on a flexible tube passed through the **anus**.
- **Virtual colonoscopy**, which uses 2D and 3D imagery reconstructed from **computed tomography** (CT) scans or from **nuclear magnetic resonance** (MR) scans, is also possible, as a totally **non-invasive** medical test, although it is not standard and still under investigation regarding its diagnostic abilities.

Indications

- Indications for colonoscopy include gastrointestinal hemorrhage, unexplained changes in bowel habit or suspicion of malignancy.
 - Colonoscopies are often used to diagnose colon cancer, but are also frequently used to diagnose inflammatory bowel disease.
 - In older patients (some times even younger ones) an unexplained drop in hematocrit (one sign of anemia) is an indication to do a colonoscopy, usually along with an EGD, even if no obvious blood has been seen in the stool (feces).
 - Fecal occult blood is a quick test which can be done to test for microscopic traces of blood in the stool. A positive test is almost always an indication to do a colonoscopy. In most cases the positive result is just due to hemorrhoids; it can also be due to diverticulosis, inflammatory bowel disease (Crohn's disease, ulcerative colitis), colon cancer, or polyps.
-

Anoscopy

An anoscopy is an examination using a small, rigid speculum (anoscope) inserted a few inches into to the anus in order to evaluate problems of the anal canal.

Conditions visible to anoscopy

- Haemorrhoids
- Anal fissures
- Fistulas
- Abscesses
- Inflammation
- Perianal/rectal tumors
- Anoscopy will permit biopsies to be taken, and is used when ligating prolapsed haemorrhoids. It is used in the treatment of warts produced by HPV.

Proctoscopy

- **Proctoscopy is a common medical procedure in which an instrument called a proctoscope (also known as a rectoscope) is used to examine the anal cavity, rectum or sigmoid colon.**
- **A proctoscope is a short (10in or 25 cm long), straight, rigid, hollow metal tube, and usually has a small light bulb mounted at the end.**

Otoscope

- An Otoscope or auriscope is a medical device which is used to look into the ears.
- Health care providers use otoscopes to screen for illness during regular check-ups and also to investigate when a symptom involves the ears.
- With an otoscope, it is possible to see the outer ear and middle ear.

Indications

Diseases which may be diagnosed by an otoscope include otitis media and otitis externa, infection of the middle and outer parts of the ear, respectively.

Cystoscopy

- **Endoscopy of the urinary bladder via the urethra is called cystoscopy.**
- **Diagnostic cystoscopy is usually carried out with local anaesthesia.**
- **General anaesthesia is sometimes used for operative cystoscopic procedures.**

Recommend conditions

- Frequent urinary tract infections and Blood in the urine (hematuria)
 - Loss of bladder control (incontinence) or overactive bladder
 - Unusual cells found in urine sample
 -
 - Need for a bladder catheter
 - Painful urination, chronic pelvic pain, or interstitial cystitis
 - Urinary blockage such as from prostate enlargement, stricture, or narrowing of the urinary tract
 - Stone in the urinary tract
 - Unusual growth, polyp, tumor, or cancer
-

Hysteroscopy

- Hysteroscopy is the inspection of the uterine cavity by endoscopy.
 - It allows for the diagnosis of intrauterine pathology and serves as a method for surgical intervention (operative hysteroscopy).
 - A hysteroscope is in fact a modification of the traditional resectoscope, which is used for transurethral resection of the prostate.
 - It has a double-channeled sheath allowing for continuous flow of fluid or gas media into the uterus through the larger channel, while allowing for fewer outflows through the smaller channel.
 - This results in the distention of the uterine cavity.
-

Indications

- **Hysteroscopic adhesiolysis is the technique of lysing adhesions in the uterus using either microscissors (recommended) or thermal energy modalities.**
 - **Hysteroscopy can be used in conjunction with laparoscopy or other methods to reduce the risk of perforation during the procedure.**
 - **Endometrial polyp. Polypectomy.**
 - **Gynecologic bleeding**
 - **Uterine fibroids. Myomectomy.**
 - **Congenital Uterine malformations (also known as Mullerian malformations). Eg. septum.**
 - **Evacuation of retained products of conception in selected cases.**
-

Complications

- **A common problem is the uterine perforation when the instrument breaches the wall of the uterus.**
- **This can lead to bleeding and damage to other organs.**
- **A life-threatening condition is the bowel perforation by the instruments after the uterine perforation, resulting in acute peritonitis which can be fatal.**
- **Furthermore, cervical laceration, intrauterine infection (especially in prolonged procedures), electrical and laser injuries, and complications caused by the distention media described above are also not uncommon.**

Colposcopy

- Colposcopy is a medical diagnostic procedure to examine an illuminated, magnified view of the cervix and the tissues of the vagina and vulva.
- The main goal of colposcopy is to prevent cervical cancer by detecting precancerous lesions early and treating them.

Laparoscopic surgery

- Laparoscopic surgery, also called minimally invasive surgery (MIS), bandaid surgery, keyhole surgery.
 - It is a modern surgical technique in which operations in the abdomen are performed through small incisions (usually 0.5-1.5cm) as compared to larger incisions needed in traditional surgical procedures.
 - Laparoscopic surgery includes operations within the abdominal or pelvic cavities, whereas keyhole surgery performed on the thoracic or chest cavity is called thoracoscopic surgery.
 - Laparoscopic and thoracoscopic surgery belong to the broader field of endoscopy.
-

Advantages

There are a number of advantages to the patient with laparoscopic surgery versus an open procedure.

- Reduced haemorrhaging, which reduces the chance of needing a blood transfusion.
- Smaller incision, which reduces pain and shortens recovery time, as well as resulting in less post-operative scarring.
- Less pain, leading to less pain medication needed.
- Although procedure times are usually slightly longer, hospital stay is less, and often with a same day discharge which leads to a faster return to everyday living.
- Reduced exposure of internal organs to possible external contaminants thereby reduced risk of acquiring infections.

Risks

- The most significant risks are from trocar injuries to either blood vessels or small or large bowel. The risk of such injuries is increased in patients who have below average body mass index or have a history of prior abdominal surgery.
- Vascular injuries can result in hemorrhage that may be life threatening. Injuries to the bowel can cause a delayed peritonitis.
- Some patients have sustained electrical burns unseen by surgeons who are working with electrodes that leak current into surrounding tissue.
- The resulting injuries can result in perforated organs and can also lead to peritonitis. This risk is reduced through the use of bipolar, instead of monopolar (patient-current-return) electro-surgical tools.

- **Hypothermia** and peritoneal trauma due to increased exposure to cold, dry gases during **insufflation**. The use of heated and humidified CO2 may reduce this risk.
- **Pneumoperitoneum**
- Gas tends to rise, and when a pocket of CO2 rises in the abdomen, it pushes against the diaphragm and can exert pressure on the **phrenic nerve**.
- For an appendectomy, the right shoulder can be particularly painful. In some cases this can also cause considerable pain when breathing.
- **Coagulation** disorders and dense **adhesions** (**scar tissue**) from previous abdominal surgery may pose added risk for laparoscopic surgery

Robotics and Technology

The process of minimally invasive surgery has been augmented by specialized tools for decades. In recent years, electronic tools have been developed to aid surgeons.

Some of the features include:

- Visual magnification - use of a large viewing screen improves visibility
 - Stabilization - Electromechanical damping of vibrations, due to machinery or shaky human hands
 - Simulators - use of specialized virtual reality training tools to improve physicians' proficiency in surgery
 - Reduced number of incisions
-

Non-robotic hand guided assistance systems

There are also user-friendly non robotic assistance systems that are single hand guided devices with a high potential to save time and money.

- **The stabilisation of the camera picture because the whole static workload is conveyed by the assistance system.**
- **Some systems enable a fast repositioning and very short time for fixation of less than 0.02 seconds at the desired position. Some systems are lightweight constructions (18kg) and can withstand a force of 20 N in any position and direction.**
- **The benefit – a physically relaxed intervention team can work concentrated on the main goals during the intervention.**
- **The potentials of these systems enhance the possibilities of the mobile medical care with those lightweight assistance systems. These assistance systems meet the demands of true solo surgery assistance systems and are robust, versatile, and easy to use.**

Arthroscopy

- Arthroscopy (also called arthroscopic surgery) is a minimally invasive surgical procedure.
- It is used in examination and sometimes treatment of damage of the interior of a joint is performed using an arthroscope.
- It is a type of endoscope that is inserted into the joint through a small incision.

Indications

- Torn floating cartilage,
- Torn surface cartilage,
- ACL reconstruction,
- Trimming damaged cartilage.
- Spinal disc herniation and degenerative discs
- Spinal deformity and Tumors
- General spine trauma

Types of arthroscopy

Shoulder arthroscopy

- Subacromial impingement, acromioclavicular osteoarthritis,
- Rotator cuff tears, frozen shoulder (adhesive capsulitis),
- Chronic tendonitis and partial tears of the long biceps tendon,
- SLAP lesions and shoulder instability.

Spinal arthroscopy

- Many invasive spine procedures involve the removal of bone, muscle, and ligaments to access and treat problematic areas.
 - In some cases, thoracic (mid-spine) conditions requires a surgeon to access the problem area through the rib cage, dramatically lengthening recovery time.
-

Mediastinoscopy

- Mediastinoscopy is a surgical procedure that enables visualization of the contents of the mediastinum, usually for the purpose of obtaining a biopsy.
- Mediastinoscopy is often used for staging of lymph nodes of lung cancer and
- Diagnosing other conditions effecting structures in the mediastinum such as sarcoidosis or lymphoma.

Thoracoscopy

- Thoracoscopy is a medical procedure involving internal inspection of the pleural cavity.
- It was developed by Hans Christian Jacobaeus, a Swedish internist in 1910 for the treatment of tuberculous intra-thoracic adhesions.
- He used a cystoscope to examine the thoracic cavity, developing his technique over the next twenty years.

Video-assisted thoracoscopic surgery

- **Video-assisted thoracoscopic surgery (VATS) is a surgical operation involving thoracoscopy, usually performed by a thoracic surgeon.**
- **It has historically also been referred to as pleuroscopy.**
- **Prior to 1990, limited diagnostic procedures were done using variations on the cystoscope since 1910.**
- **Advances in direct optical visualization were quickly surpassed when video cameras were attached to the endoscopes.**
- **The advent of endoscopic stapling was also a major advance so that complicated procedures such as pulmonary lobectomy could be performed safely.**

Fetoscopy

- Fetoscopy is an endoscopic procedure during pregnancy to allow access to the fetus, the amniotic cavity, the umbilical cord, and the fetal side of the placenta.
- A small (3-4 mm) incision is made in the abdomen, and an endoscope is inserted through the abdominal wall and uterus into the amniotic cavity.
- Fetoscopy allows medical interventions such as a biopsy or a laser occlusion of abnormal blood vessels.

Laryngoscope

- **Rigid laryngoscope:**

A rigid laryngoscope utilized by anesthesia, pulmonary or critical care personnel for intubation typically consists of a handle (incorporating two batteries) and an interchangeable blade with a bulb light source.

- **Direct laryngoscopy**

- **indirect laryngoscopy**

- **Transnasal Flexible Laryngoscope**

Uses of Laryngoscopes

- **Helps in intubation during the administration of general anaesthesia or for mechanical ventilation.**
- **Detects causes of voice problems, such as breathing voice, hoarse voice, weak voice, or no voice.**
- **Detects causes of throat and ear pain.**
- **Evaluates difficulty in swallowing: a persistent sensation of lump in the throat, or mucous with blood.**
- **Detects strictures or injury to the throat, or obstruction masses in the airway.**

Bronchoscopy

- Bronchoscopy is a technique of visualizing the inside of the airways for diagnostic and therapeutic purposes.
- An instrument (bronchoscope) is inserted into the airways, usually through the nose or mouth, or occasionally through a tracheostomy.

Types

- **Rigid:**A rigid bronchoscope is a straight, metal tube with an inner diameter of up to one centimetre.
- **Flexible (fiberoptic):**A flexible bronchoscope is longer and thinner than a rigid bronchoscope. It contains a fiberoptic system that transmits an image from the tip of the instrument to an eyepiece or video camera at the opposite end.
- Using Bowden cables connected to a lever at the handpiece, the tip of the instrument can be oriented, allowing the practitioner to navigate the instrument into individual lobe or segment bronchi.
- Most flexible bronchoscopes also include a channel for suctioning or instrumentation, but these are significantly smaller than those in a rigid bronchoscope.

Purposes

Diagnostic

- To view abnormalities of the airway
 - To obtain tissue specimens of the lung in a variety of disorders
 - To evaluate a person who has bleeding in the lungs, possible lung cancer, a chronic cough, or a collapsed lung
-

Therapeutic

- To remove secretions, blood, or foreign objects lodged in the airway
 - Laser resection of tumors or benign tracheal and bronchial strictures
 - Stent insertion to palliate extrinsic compression of the tracheobronchial lumen from either malignant or benign disease processes
 - Bronchoscopy is also employed in percutaneous tracheostomy
 - Surgical procedures on the airways, such as tracheal reconstruction, often require the use of bronchoscopy
 - Intubation of patients with difficult airways is often performed using a flexible bronchoscope
-

Complications and Risks

- Risks associated with the drug used

- A rigid bronchoscope can scratch or tear airways or damage the vocal cords

- Complications from fiberoptic bronchoscopy remain extremely low. Common complications include excessive bleeding following biopsy.

- A lung biopsy also may cause leakage of air, called pneumothorax.

- Pneumothorax occurs in less than 1% of lung biopsy cases .

- Laryngospasm is a rare complication but may sometimes require intubation.

- Patients with tumors or significant bleeding may experience increased difficulty breathing after a bronchoscopic procedure, sometimes due to swelling of the mucous membranes of the airways.

Recent developments

- **Capsule endoscopy**
- **Recent development and usefulness of infrared endoscopic system for diagnosis of gastric cancer**
- **Development and Application of a Falloposcope for Transvaginal Endoscopy of the Fallopian Tube**
- **Therapeutic endoscopy**
- **3-D Ultrasound Guidance of Surgical Robotics: A Feasibility Study**
- **Use of Endoscopic Techniques for Pituitary Adenoma Resection**

Capsule endoscopy

- **Capsule Endoscopy is a term used to describe a miniature capsule used to record images through the digestive tract for use in medicine.**
- **This was invented by a group in Baltimore, Md. USA in 1989**

Uses

- Capsule endoscopy is used as a less-invasive procedure in placement of a traditional endoscope
- The technology is used by gastroenterologists to detect diseases such as Crohn's disease, gastric ulcers, and colon cancer.
- The capsule camera is primarily used to visualize the small intestine. Whereas the upper gastrointestinal tract and the colon can be very adequately visualized with scopes (cameras placed at the ends of thin flexible tubes).
- No available scope is able to traverse the entire length of the small intestine. Because the capsule is swallowed and travels through the digestive system, capsule endoscopy takes a longer amount of time than traditional endoscopy.
- The images are of good quality, comparable to those from scopes. The test carries a high sensitivity and specificity for detecting lesions.
- Early research has shown that capsule endoscopy can detect evidence of disease in some cases that traditional endoscopy cannot.

Infrared endoscopy

- **Endoscopic mucosal resection (EMR) is a useful treatment for early gastric cancer**
- **Hemoglobin in vessels absorbs infrared rays with wavelengths ranging from 700 to 900 nm, allowing observation of blood vessels below the mucosal layer.**
- **Using infrared film, we developed a method of infrared photography of the human gastric mucosa and visualization of the pattern of deep vessels.**
- **However, this system has been surpassed by the more recently developed near-infrared electronic endoscopic system.**
- **This system uses a charge-coupled device (CCD) that is sensitive to infrared rays as well as visible light.**
- **The CCD made it possible to obtain clearer images on a television monitor. To more clearly visualize vessels in the mucosa and submucosa, indocyanine green (ICG) was used as a contrast medium. It absorbs light maximally at a wavelength of approximately 805 nm in human serum.**
- **After intravenous injection of ICG, deep submucosal vessels can be observed under near-infrared illumination.**

Development of new infrared videoendoscope

- **Conventional system, one range of infrared rays was emitted by the light source and the strength of reflected light from an object is displayed in a monotonous monitor.**
- **Lesion locates in a dark area, endoscopic findings would be obscure and were difficult to assess. To improve this problem, a new infrared videoendoscopic system was developed and usefulness of the system is assessed.**
- **Endoscope (Q-240IR, Olympus), has a higher performance CCD (300 000 pixels vs 100 000 pixels in conventional systems).**
- **Red and green channels of the endoscope pass the light at 790–820 nm, and blue channel passes the light at 920–960 nm.**
- **After intravenous administration of ICG, ICG in blood absorbs near-IR maximally at a wavelength of about 805 nm.**
- **Therefore, submucosal vessels absorb IR light around 805 nm, which corresponds to red and green channels of the endoscope, whereas submucosal vessels reflect IR light at 920–960 nm, which corresponds to blue channel of the endoscope, and vessels are displayed blue in a monitor.**
- **With these improvements, the new infrared videoendoscopic system can recognize submucosal vessels of gastric cancers in a greater detail with higher resolution under IR light.**

Diagnostic accuracy of depth of gastric cancer

- **A videoendoscope was inserted and used to inspect the surface of the stomach.**
- **Under near-infrared electronic endoscopy, the patients received ICG intravenously at a dosage of 2 mg/kg bodyweight, and the gastric cancers were observed.**
- **During endoscopic observation, an investigator assessed the infrared endoscopic findings.**

Therapeutic endoscopy

- Therapeutic endoscopy is the medical term for an endoscopic procedure during which treatment is carried out via the endoscope.
- This contrasts with diagnostic endoscopy, where the aim of the procedure is purely to visualise a part of the gastrointestinal, respiratory or urinary tract in order to aid diagnosis.
- In practice, a procedure which starts as a diagnostic endoscopy may become a therapeutic endoscopy depending on the findings, such as in cases of upper gastrointestinal bleeding, or the finding of polyps during colonoscopy.

Types of endoscopic therapy

- **Endoscopic haemostasis**
- **Injection sclerotherapy**
- **Argon plasma coagulation**
- **Dilatation and Polypectomy**
- **Variceal banding and Stenting**
- **Percutaneous endoscopic gastrostomy**
- **Foreign body removal**

Areas under development

- **Anti-reflux procedures**
- **Treatment of Barrett's oesophagus**
- **Transoralgastroplasty(TOGA procedure)**

3-D Ultrasound Guidance of Surgical Robotics: A Feasibility Study

■ laparoscopic procedures - increase information available to the surgeon and serve as an additional intraoperative guidance tool.

■ The integration of RT3D with recent advances in robotic surgery also can increase automation and ease of use.


■ The probe, operates at 5 MHz, to image the spleen, liver, and gall bladder and to guide surgical instruments.

■ the three-dimensional (3-D) measurement system of the volumetric scanner used with this probe was tested as a guidance mechanism for a robotic linear motion system in order to simulate the feasibility of RT3D/robotic surgery integration.

■ Using images acquired with this ultrasound device, coordinates were acquired by the scanner and used to direct a robotically controlled needle toward desired *in vitro* targets as well as targets in a post-mortem canine.

Use of Endoscopic Techniques for Pituitary Adenoma Resection

- **The progressive refinement of transsphenoidal pituitary surgery has continued under a minimally invasive endoscopic strategy.**
- **The physical advantages of the endoscope allow a transsphenoidal approach through a natural nasal air pathway without the need for a transsphenoidal retractor.**
- **The unique optical characteristics of an endoscope provide great advantages in pituitary tumor surgery, particularly for macroadenomas.**
- **Wide-angled panoramic views at the posterior wall of the sphenoidal sinus allow clear anatomic orientation in comparison to the limited sellar exposure in conventional microscopic techniques.**
- **Angled-lens views allow direct visualization at the suprasellar region or various anatomic corners.**
- **Close-up internal views at the tumor resection cavity render minute details at the tumor removal site, allowing further cleansing of any residual crumbs of tumor tissue.**



Thank You