Modern Pathology (2017) 30, 486–498

Bone marrow morphology and disease progression in congenital thrombocytopenia: a detailed clinicopathologic and genetic study of eight cases

Hamilton C Tsang[1], James B Bussel[2], Susan Mathew[1], Yen-Chun Liu[1], Allison A Imahiyerobo[2], Attilio Orazi[1] and Julia T Geyer[1]

[1]Department of Pathology and Laboratory Medicine, New York-Presbyterian Hospital Weill Cornell Medicine, New York, NY, USA and [2]Department of Pediatrics and Medicine, New York-Presbyterian Hospital Weill Cornell Medicine, New York, NY, USA

Patients with congenital thrombocytopenia have an increased risk of developing myeloid neoplasms. In these cases, the morphologic distinction between disease at baseline and at progression is challenging. This report analyzes clinicopathologic features of congenital thrombocytopenia with long-term follow-up at one referral center. Records from the last 20 years were searched for cases of congenital thrombocytopenia with bone marrow biopsies and peripheral blood smears. The clinical, morphologic, immunophenotypic, and molecular features were analyzed. Six adult and two pediatric patients were identified (six male, two female). Age range at first biopsy was 1–47 (median, 31) years. Underlying diseases included thrombocytopenia-absent radius syndrome, congenital thrombocytopenia with radial–ulnar synostosis, *MYH9*-related disorder, shortened telomere syndrome, congenital thrombocytopenia with *ANKRD26* mutation, and familial platelet disorder with predisposition to acute myeloid leukemia. Four patients had myelodysplastic/myeloproliferative neoplasm-like marrow changes such as hypercellularity, increased myeloid to erythroid ratio, numerous micromegakaryocytes (highlighted by CD42b), and marrow fibrosis. Two patients had marrow hypoplasia and two had unremarkable marrow morphology. Three patients—all in the myelodysplastic/myeloproliferative neoplasm-like group—developed disease progression characterized by erythroid and myeloid dysplasia, elevated bone marrow blasts, and new cytogenetic abnormalities. Unlike non-familial myeloid neoplasms, congenital thrombocytopenia patients in the myelodysplastic/myeloproliferative neoplasm-like group had a long and indolent clinical course (average age at disease progression, 47 years). In summary, three distinct morphologic types of congenital thrombocytopenia were identified: a hyperplastic myelodysplastic/myeloproliferative neoplasm-like group, a hypoplastic bone marrow failure-like group, and a group with relatively normal marrow morphology. Emergence of cytogenetic abnormalities and dysplasia in non-megakaryocyte lineages correlated with disease progression.
Modern Pathology (2017) **30,** 486–498; doi:10.1038/modpathol.2016.218; published online 6 January 2017

Congenital thrombocytopenias are rare conditions that show a spectrum of clinical findings and varying degrees of heritability with the unifying feature of thrombocytopenia. Recent developments, especially in identification of molecular defects, have improved the ability to identify and distinguish cases of congenital thrombocytopenia.[1–3] Notwithstanding considerable progress, approximately half of patients with congenital thrombocytopenia do not have a specific diagnosis because the underlying causes have not (yet) been identified.[4,5]

A subset of congenital thrombocytopenias have an increased risk of developing myeloid neoplasms. Leukemias have been reported with varying frequency in association with inherited thrombocytopenias, including Wiskott–Aldrich syndrome,[6–9] ankyrin repeat domain 26 (*ANKRD26*)-related thrombocytopenia,[6,10] shortened telomere syndrome,[11–14] familial platelet disorder with predisposition to acute myeloid leukemia caused by

Correspondence: Dr JT Geyer, MD, Department of Pathology and Laboratory Medicine, New York-Presbyterian Hospital Weill Cornell Medicine, 525 East 68th Street, New York 10021, NY, USA.
E-mail: jut9021@med.cornell.edu
Received 25 June 2016; revised 9 November 2016; accepted 10 November 2016; published online 6 January 2017

germline heterozygous mutations in *RUNX1*,[15–17] *ETV6*-related thrombocytopenia,[1–3] and myosin heavy chain 9 (*MYH9*)-related disorder[18,19] (Table 1). Although these diseases have known molecular defects and expected clinical course, the distinction between the baseline condition and disease progression may be difficult, even with relevant clinical history. Data are limited on bone marrow biopsy findings for congenital thrombocytopenias. Most studies report the common finding of varying degrees of immature or dysplastic megakaryocytes,[8–10,20–24] but there is little information comparing the histopathologic findings between the entities, and there are no studies following bone marrow biopsies over time.

This study analyzes bone marrow alterations in cases of congenital thrombocytopenia with long-term follow-up. This is the first comprehensive integrated evaluation of these rare cases.

Materials and methods

Samples

A computer-assisted search of the pathology files of the Weill Cornell Medicine New York-Presbyterian Hospital from the last 20 years was performed for congenital thrombocytopenia patients with bone marrow biopsy and follow up at our institution. Both bone marrow biopsies and aspirates were performed from posterior superior iliac crest. The clinical information, complete blood counts, and relevant radiographic images were also obtained following institutional review board approval. Complete blood count data (hemoglobin, mean corpuscular volume, white blood cell count, absolute neutrophil count, absolute lymphocyte count, and platelet count) of all the patients from the time of diagnosis was concurrently reviewed and recorded for statistical analysis. The degree of anemia was determined based on the World Health Organization toxicity grading system, as follows: grade 1 (mild) 9.5–10.9 g/dl, grade 2 (moderate) 8–9.4 g/dl, grade 3 (severe) 6.5–7.9 g/dl, and grade 4 (life-threatening) < 6.5 g/dl. Thrombocytopenia was graded according to the National Cancer Institute criteria into grade 1 ($75–150 \times 10^9$/L), grade 2 ($50–75 \times 10^9$/L), grade 3 ($10–50 \times 10^9$/L), and grade 4 ($< 10 \times 10^9$/L).

Morphology

A detailed bone marrow biopsy and aspirate analysis included quantification of the marrow cellularity, the myeloid to erythroid ratio, evidence of reticulin and collagen fibrosis, presence of dysplasia, aspirate and core biopsy blast count, megakaryocyte morphology and overall number, aberrant megakaryocyte antigen expression, and presence of megakaryoblasts. Dysplasia was defined according to the World Health Organization criteria.

Special Stains, Immunohistochemistry, and Flow Cytometry

Reticulin stain was performed on every case and was graded according to a modified Bauermeister/Manoharan scale. Trichrome staining was performed. The blast count was evaluated by manual count of the bone marrow aspirate and with immunohistochemical staining for CD34 (BioGenex MU236-UC, Fremont, Ca with dilution of 1:50) on the bone marrow biopsy. Immunohistochemical stain for CD42b (Leica NCL-CD42b, Newcastle-upon-Tyne, UK with dilution of 1:50) was performed to simplify the quantification of the megakaryocytes and to identify the presence of megakaryoblasts. Four-color flow cytometric analysis was performed on eight bone marrow aspirates to assess for B-cell and T-cell clonality, increased myeloid blasts, and evidence of immunophenotypic abnormalities in myeloid lineage cells.

Cytogenetic Analysis

Cytogenetic studies were performed on overnight unstimulated bone marrow cultures. The findings were described according to the 2009 and 2013 International System for Human Cytogenetic Nomenclature. Fluorescence *in situ* hybridization was carried out on five cases using the LSI D5S23/D5S721/EGR1 probes (Abbott Molecular, Des Plaines, IL, USA). Diepoxybutane clastogen assay for Fanconi anemia (Quest Diagnostics, Madison, NJ, USA) was performed in one case.

Molecular Analysis

Molecular studies were performed in six cases. Myelodysplastic syndrome molecular profile, including *ASXL1*, *RUNX1*, *EZH2*, *ETV6*, *and TP53,* testing was performed via polymerase chain reaction (Genoptix Medical Laboratory, Carlsbad, CA, USA) on bone marrow aspirates in two cases. *ANKRD26* polymerase chain reaction (University of Pavia, Pavia, Italy) was performed in two cases. *MPL* mutation, *WAS*, *ADAMTS13*, *MYH9*, and *RUNX1* polymerase chain reaction (Blood Center of Wisconsin, Milwaukee, WI, USA) was performed in one case. *MYH9* polymerase chain reaction (Children's Hospital of Philadelphia, Philadelphia, PA, USA) was performed in one case. *TERT* mutation testing was performed in one case. Telomere length by quantitative polymerase chain reaction was performed in one case. Human leukogen antigen testing (LabCorp, Burlington, NC, USA) was performed in one case. *JAK2*^{V617F} polymerase chain reaction (Weill Cornell, New York, NY, USA) was performed in one case on peripheral blood. *RUNX1-RUNX1T1* (*AML1-ETO*) t(8;21) by real-time polymerase chain reaction was performed in one case. Osteopetrosis testing, including *TCIRG1*, *TCIRG1* deletion, *CLCN7*

Table 1 Summary of congenital thrombocytopenias

Disease	*Frequency*	*Mode of inheritance*	*Genetic abnormality*	*Associated clinical features*	*Salient histologic features*	*Risk of hematologic malignancy*
Thrombocytopenia-absent radius syndrome	53 families	Autosomal recessive	*RBM8A* (1q21.1)	Platelet count often normalizes in adults, bilateral radial aplasia ± other malformations	Decreased or absent megakaryocytes, small immature megakaryocytes	Not determined
ANKRD26-related thrombocytopenia	45 families	Autosomal dominant	*ANKRD26* (10p2)	Risk of leukemia	Increased megakaryocytes, dysmegakaryopoiesis	5% of patients developed acute leukemias, 2% had myelodysplastic syndrome, and 1% chronic myeloid leukemia
Amegakaryocytic thrombocytopenia with radial–ulnar synostosis	8 families	Autosomal dominant	*HOXA11* (7p15-14)	Aplastic anemia, radioulnar synostosis ± other defects	Reduced or absent megakaryocytes; some cases have bone marrow aplasia	Not determined; up to 50% of patients progressed to aplastic anemia within the first five years of life
Shortened telomere syndrome	425 individuals	X-linked, autosomal dominant, autosomal recessive	*DKC1* (Xq28), *TERC* (3q26), *TERT* (5p15.53), *NOP10* (15q14-q15)	Pulmonary fibrosis, oral leukoplakia, dysplastic nails, reticulated skin pigmentation	Bone marrow aplasia	1% incidence of leukemia (acute myeloid leukemia and acute lymphoblastic leukemia)
MYH9-related disorder	220 families	Autosomal dominant	*MYH9* (22q12-13)	Cataracts, nephropathy ± deafness	Giant hypogranular platelets; large leukocyte inclusions (Döhle-like bodies)	Isolated reports of acute myeloid leukemia and myelodysplastic syndrome
Mediterranean macrothrombocytopenia		Autosomal dominant	Not determined	Moderate bleeding tendency	Giant platelets; immature megakaryocytes	Not determined
Wiskott–Aldrich syndrome	4 per million	X-linked	*WAS* (Xp11)	Severe immunodeficiency	Microthrombocytes; poorly lobulated small megakaryocytes	10% cumulative incidence of lymphoma
Familial platelet disorder with predisposition to acute myeloid leukemia	30 families	Autosomal dominant	*RUNX1* (21q22)	Mild to moderate bleeding tendency, aspirin-like functional platelet defect	Normal-sized platelets	Development of leukemia or myelodysplastic syndrome in 40% of patients
GATA1-related disease	10 families	X-linked	*GATA1* (Xp11)	Hemolytic anemia, unbalanced globin chain synthesis	Dyserythropoiesis; dysmegakaryopoiesis; macrothrombocytopenia	Not determined
ETV6-related thrombocytopenia	7 families	Autosomal dominant	*ETV6* (12p13.2)	Risk of leukemia	Normal-sized platelets	20% incidence of acute lymphoblastic leukemia

Table 2 Summary of patient and bone marrow biopsy characteristics

Case	*Entity*	*Gender*	*Age at first biopsy (years)*	*Years of follow-up*	*Number of biopsies*	*Genetic abnormalities at diagnosis*	*Bone marrow disease pattern*
1	Thrombocytopenia-absent radius syndrome	M	27	21	14	–	Myelodysplastic/myeloproliferative neoplasm-like
2	*ANKRD26*-related thrombocytopenia	M	47	7	10	*ANKRD26*	Myelodysplastic/myeloproliferative neoplasm-like
3	Shortened telomere syndrome	M	40	1	3	*TERT*	Myelodysplastic/myeloproliferative neoplasm-like
4	*MYH9*-related disorder	F	38	<1	1	*MYH9*, inv(9)(p12q13)	Myelodysplastic/myeloproliferative neoplasm-like
5	Familial platelet disorder with predisposition to acute myeloid leukemia	F	34	<1	1	–	Bone marrow failure-like
6	Congenital thrombocytopenia with radial–ulnar synostosis	M	1	16	6	–	Bone marrow failure-like
7	Unspecified congenital thrombocytopenia with giant platelets	M	1	2	2	–	Normal
8	Wiskott–Aldrich syndrome	M	27	25	1	*WAS*	Normal

deletion, *OSTM1*, *OSTM1* deletion, and *PLEKHM1* (Connective Tissue Gene Tests, Allentown, PA, USA), was performed on one case. *GATA1* mutation (Prevention Genetics, Marshfield, WI, USA) was performed in one case. *SBDS* gene mutation, and dyskeratosis congenita gene testing *DKC1*, *TINF2* Exon 6, *TERC*, *NHP2* exon 4, *NOP10* exon 2, and *TERT* (Ambry genetics, Aliso Viejo, CA, USA) was performed in one case.

Results

Clinical Presentation

A total of eight cases of inherited thrombocytopenia were identified. Six were male and two female patients with age range at first bone marrow biopsy from 1.3 to 47 years (Table 2). Underlying diseases included thrombocytopenia-absent radius syndrome, *ANKRD26*-related thrombocytopenia, congenital thrombocytopenia with radial–ulnar synostosis, shortened telomere syndrome, *MYH9*-related disorder, Wiskott–Aldrich syndrome, and familial platelet disorder with predisposition to acute myeloid leukemia. One disorder was not further characterized.

Thrombocytopenia-absent radius syndrome. This male patient initially presented at 1 month of age with a characteristic congenital absence of both radii and both ulnas with further deformities of both humerii (Figure 1) and both tibias requiring knee replacement twice for his right knee. Up until the age of 20, his platelet counts were usually $25–45 \times 10^3/\mu l$ and would fall with intercurrent infections. By the age of 27 years, his platelet counts were between $5–15 \times 10^3/\mu l$. He was found to have hepatomegaly and massive splenomegaly. Significant extramedullary hematopoiesis was seen on magnetic resonance imaging and in his spleen post-splenectomy at age 34.

During subsequent follow-up, the patient's white blood cell count was initially over $100 \times 10^3/\mu l$ but gradually decreased and was found to be persistently elevated ($22–38 \times 10^3/\mu l$) with neutrophilia and myeloid left-shift. He has been treated with steroids, intravenous immunoglobulin, aminocaproic acid, and required frequent platelet transfusions. A course of eltrombopag was given with initial substantial platelet increase followed by transient appearance of blasts resulting in cessation of this treatment. The patient was diagnosed with acute myeloid leukemia at age 47 and was treated with chemotherapy followed by allogeneic stem cell transplant. The patient currently has stable disease with moderate thrombocytopenia and neutrophilia, but no increase in blasts.

ANKRD26-related thrombocytopenia. This male patient with a long-standing history of

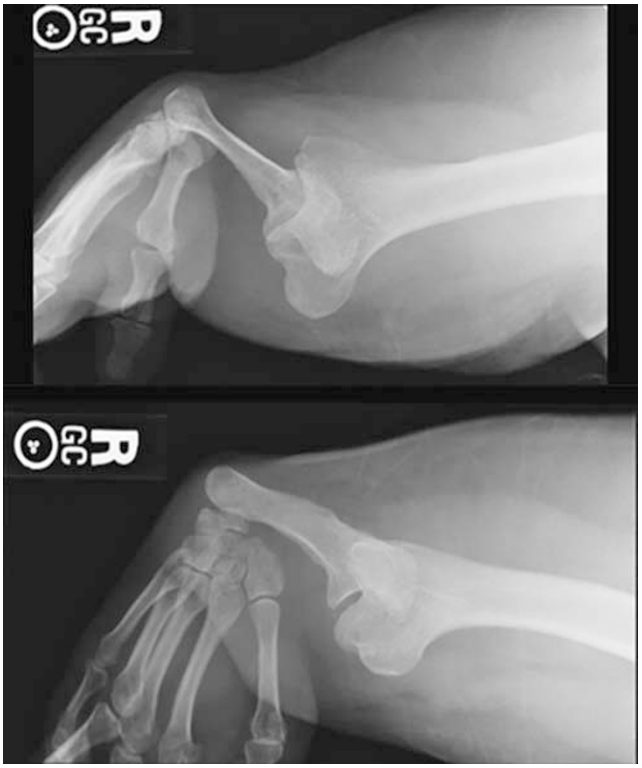

Figure 1 Lateral (top) and posterior–anterior (bottom) radiograph of right forearm of Case 1 (thrombocytopenia-absent radius syndrome) showing absent radius and associated ulnar, carpal, and clavicular deformities.

thrombocytopenia (on average $< 10 \times 10^3/\mu l$, lowest $2 \times 10^3/\mu l$) was virtually asymptomatic until the age of 47 years, then presented with bruising, frequent epistaxis, and months of swelling and petechiae in the lower extremities. Multiple family members (grandfather, father, aunt, uncle, four cousins, and son) were reported to have thrombocytopenia. Notably, his father's sister also developed chronic myelogenous leukemia and his father expired due to acute myeloid leukemia. Treatments included steroids, romiplostim, rituxumab, cyclophosphamide, and thalidomide. Despite therapy, the patient developed progressive anemia with a decrease in hemoglobin from 13 g/dl in 2011 to 4–6 g/dl in 2014. At that time, he was started on azacitidine, followed by matched unrelated stem cell transplant. Nine months following transplant, the patient has stable grade 3 thrombocytopenia and no evidence of anemia.

Shortened telomere syndrome. This male patient initially presented at the age of 41 years. He had frequent nose bleeds and was pancytopenic with platelet count of $10 \times 10^3/\mu l$, hemoglobin between 7.5 and 9.0 g/dl, and white blood cell count of $2.5 \times 10^3/\mu l$. The patient had a strong history of multiple family members with idiopathic pulmonary fibrosis and thrombocytopenia. He was treated with danazol. Because of the concern for disease progression, he received a matched unrelated stem cell transplant with a relatively uneventful post-transplant course and normal complete blood counts 2.5 years post-transplant.

MYH9-related disorder. This female patient presented at the age of 38 years old with a platelet count of $78 \times 10^3/\mu l$ and occasional petechiae. She sought workup because her son was born with a low platelet count and tested positive for *MYH9* mutation. The patient has not required treatment except at delivery of her next child.

Familial platelet disorder with predisposition to acute myeloid leukemia. This female patient presented at the age of 36 years old with a history of hepatitis C and asymptomatic thrombocytopenia ($60–120 \times 10^3/\mu l$). Five other immediate family members had thrombocytopenia and abnormal platelet function studies. One brother with thrombocytopenia subsequently developed acute myeloid leukemia. Patient's son was studied for delayed development and mild thrombocytopenia. Platelet function assay of the patient and her brother showed decreased platelet aggregation with arachidonic acid, collagen, adenosine diphosphate 20 μM, and epinephrine, and normal aggregation with ristocetin. The patient was treated with trials of intravenous immunoglobulin, romiplostim, and etrombopag with partial response to the latter two agents. She is clinically stable.

Congenital thrombocytopenia with radial–ulnar synostosis. This male patient presented at several months of age with platelet counts between $30–40 \times 10^3/\mu l$ with easy bruising and petechiae. Several months later he was discovered to have inability to supinate his arms bilaterally, and pulmonary hypertension. He was followed up to 16 years of age, maintaining stable platelet counts fluctuating between $30–50 \times 10^3/\mu l$. During this time, he developed one episode of a severe left knee hemarthrosis. The most recent platelet counts on no treatment were $60–70 \times 10^3/\mu l$.

Unspecified congenital thrombocytopenia with giant platelets. This male patient presented at birth with decreased platelets, abnormal bruising, and a perinatal intracranial bleed. The patient's cousin had osteopetrosis. The patient was treated with prednisone, intravenous immunoglobulin, and romiplostim. After clinical follow-up of 2 years, he requires platelet transfusions regularly with baseline platelets fluctuating between $3–60 \times 10^3/\mu l$, but is otherwise clinically stable.

Wiskott–Aldrich syndrome. This male patient was initially diagnosed around 12 months of age at our institution and presented again at 25 years old with severe eczema, psoriasis, bleeding diathesis, and thrombocytopenia ($30–40 \times 10^3/\mu l$). He had multiple other male family members affected with similar

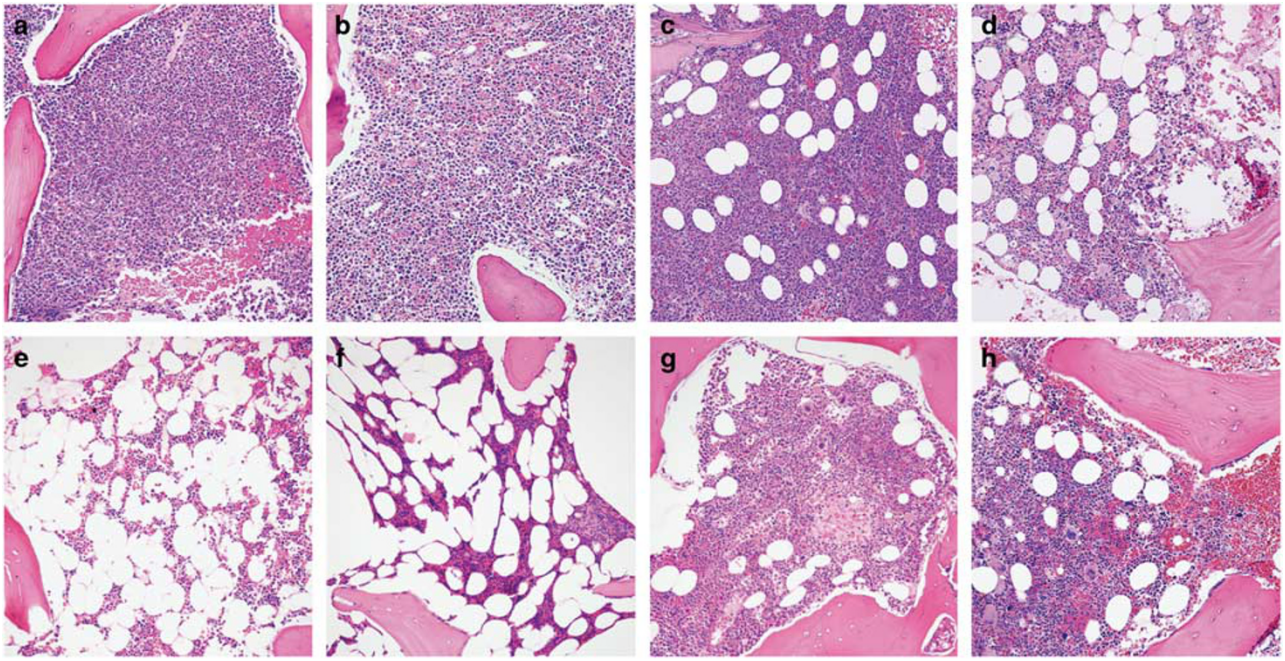

Figure 2 Bone marrow cellularity. Hematoxylin and eosin of bone marrow biopsies demonstrating hypercellularity in (**a**) Case 1: thrombocytopenia-absent radius syndrome, (**b**) Case 2: *ANKRD26*-related thrombocytopenia, (**c**) Case 3: shortened telomere syndrome, (**d**) Case 4: *MYH9*-related disorder. Hypocellular marrow was observed in (**e**) Case 5: familial platelet disorder with predisposition to acute myeloid leukemia and (**f**) Case 6: congenital thrombocytopenia with radial–ulnar synostosis. Normocellular marrow was observed in (**g**) Case 7: unspecified congenital thrombocytopenia with giant platelets and (**h**) Case 8: Wiskott–Aldrich syndrome.

symptoms. He was managed with daily ethrombopag and had been clinically stable. He chose to undergo stem cell transplant primarily to address severely symptomatic psoriasis and eczema, and unfortunately passed away from peri-transplant complications.

Morphologic and Immunophenotypic Features

Thrombocytopenia-absent radius syndrome. Multiple bone marrow biopsies were obtained during follow-up of 28 years starting after the age of 20. All biopsies showed markedly hypercellular (virtually 100%) bone marrows (Figure 2a) with markedly elevated myeloid to erythroid ratio (>10:1) and a decreased megakaryopoesis with a predominance of micromegakaryocytes (Figure 3), best highlighted by CD42b immunostain (Figure 4a). Bone marrow eosinophilia and basophilia were also noted. This was consistent with several magnetic resonance imaging studies which all revealed the absence of fat in the medullary space. When the patient was 34 years old, a splenectomy was performed which confirmed extramedullary hematopoesis. Subsequent bone marrow biopsies showed similar findings until, at the age of 39 years, the number of myeloid blasts slowly began to increase up to 23% 8 years later. The increase in blasts correlated with development of myeloid and erythroid dysplasia and marrow fibrosis. He developed acute myeloid leukemia and underwent successful stem cell transplant complicated by chronic graft-versus-host disease.

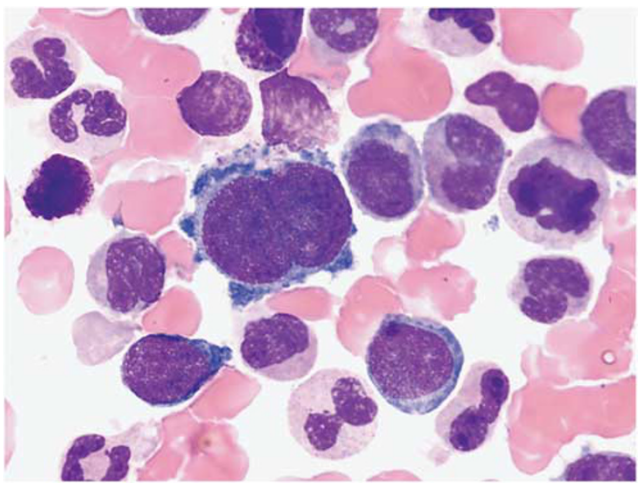

Figure 3 Micromegakaryocyte morphology as seen in bone marrow aspirate from Case 1: thrombocytopenia-absent radius syndrome.

ANKRD26-related thrombocytopenia. The initial bone marrow biopsy showed markedly increased cellularity (90%) (Figure 2b) with an increased myeloid to erythroid ratio (3.6:1) and increased number of micromegakaryocytes highlighted by CD42b staining (Figure 4b). There was increased

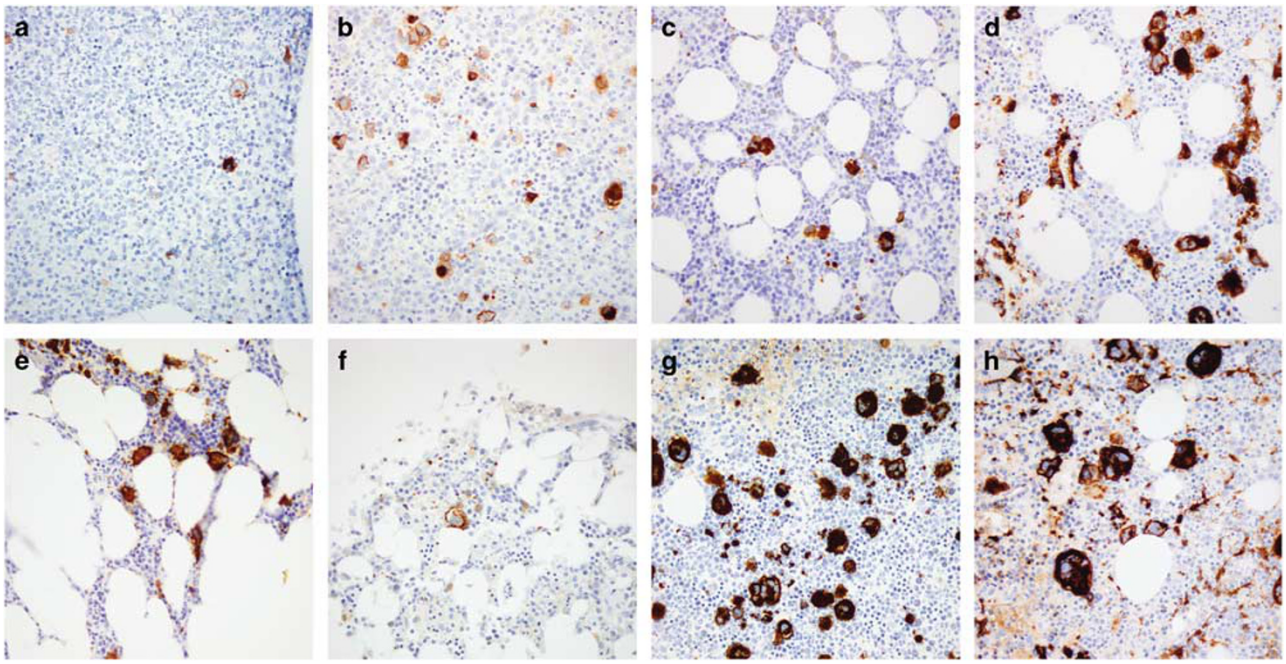

Figure 4 Presence of micromegakaryocytes was a notable feature in six patients. CD42b immunohistochemical stain highlights megakaryocytes (**a**) Case 1: thrombocytopenia-absent radius syndrome, (**b**) Case 2: *ANKRD26*-related thrombocytopenia, (**c**) Case 3: shortened telomere syndrome, (**d**) Case 4: *MYH9*-related disorder, (**e**) Case 5: familial platelet disorder with predisposition to acute myeloid leukemia, (**f**) Case 6: congenital thrombocytopenia with radial–ulnar synostosis, (**g**) Case 7: unspecified congenital thrombocytopenia with giant platelets, and (**h**) Case 8: Wiskott–Aldrich syndrome.

fibrosis (MF-2) (Figure 5a) and no increase in blasts. Subsequent biopsies correlating with worsening anemia showed increase in cellularity (95–100%) over time, increasing myeloid to erythroid ratio (up to 5:1), new evidence of erythroid and myeloid dysplasia and up to 7% blasts. Splenectomy showed evidence of extramedullary hematopoiesis with no increase in blasts.

Shortened telomere syndrome. Several bone marrow biopsies were evaluated. The initial biopsy showed increased cellularity (80%) (Figure 2c) for the patient's age, increased myeloid to erythroid ratio (3.4:1), 5% myeloblasts by immunohistology, megaloblastoid features in the erythroid lineage, increased fibrosis (MF-2) (Figure 5b) and overt dysplasia in the myeloid and megakaryocyte lineages. Megakaryocytes were composed predominantly of small, hypolobated dysplastic-appearing forms (Figure 4c). Post-transplant bone marrow biopsy showed normal cellularity (50%) for age, normal myeloid to erythroid ratio, and adequate megakaryocytes.

MYH9-related disorder. A bone marrow biopsy showed increased cellularity (85%) (Figure 2d), increased myeloid to erythroid ratio, myeloid left-shift, and a markedly increased number of megakaryocytes varying from atypically small to normal in size (Figure 4d). There was increased (MF-2) marrow fibrosis. Rare enlarged platelets were observed on review of the peripheral blood smear (Figure 5c).

Familial platelet disorder with predisposition to acute myeloid leukemia. A bone marrow biopsy showed a mildly hypocellular bone marrow for age (~40%) (Figure 2e), a normal myeloid to erythroid ratio, an increased number of micromegakaryocytes and scattered bare megakaryocyte nuclei (Figure 4e).

Congenital thrombocytopenia with radial–ulnar synostosis. The patient was followed with bone marrow biopsy from 15 months to 12 years of age. The earliest biopsy showed bone marrow with normal cellularity (Figure 2f) and myeloid to erythroid ratio, but with decreased number of megakaryocytes. The megakaryocytes present tended to be immature small forms (Figure 4f). Over time, there was progressive bone marrow failure with 25% cellularity at 12 years old and virtually absent megakaryocytes. There was no evidence of myeloid/erythroid dysplasia or marrow fibrosis.

Unspecified congenital thrombocytopenia with giant platelets. The patient had two bone marrow biopsies at the age of 1 and 2 years old. The biopsies showed appropriate cellularity (>90%) for age (Figure 2g), normal myeloid to erythroid ratio, and increased number of megakaryocytes showing increased pleomorphism (Figure 4g). Peripheral

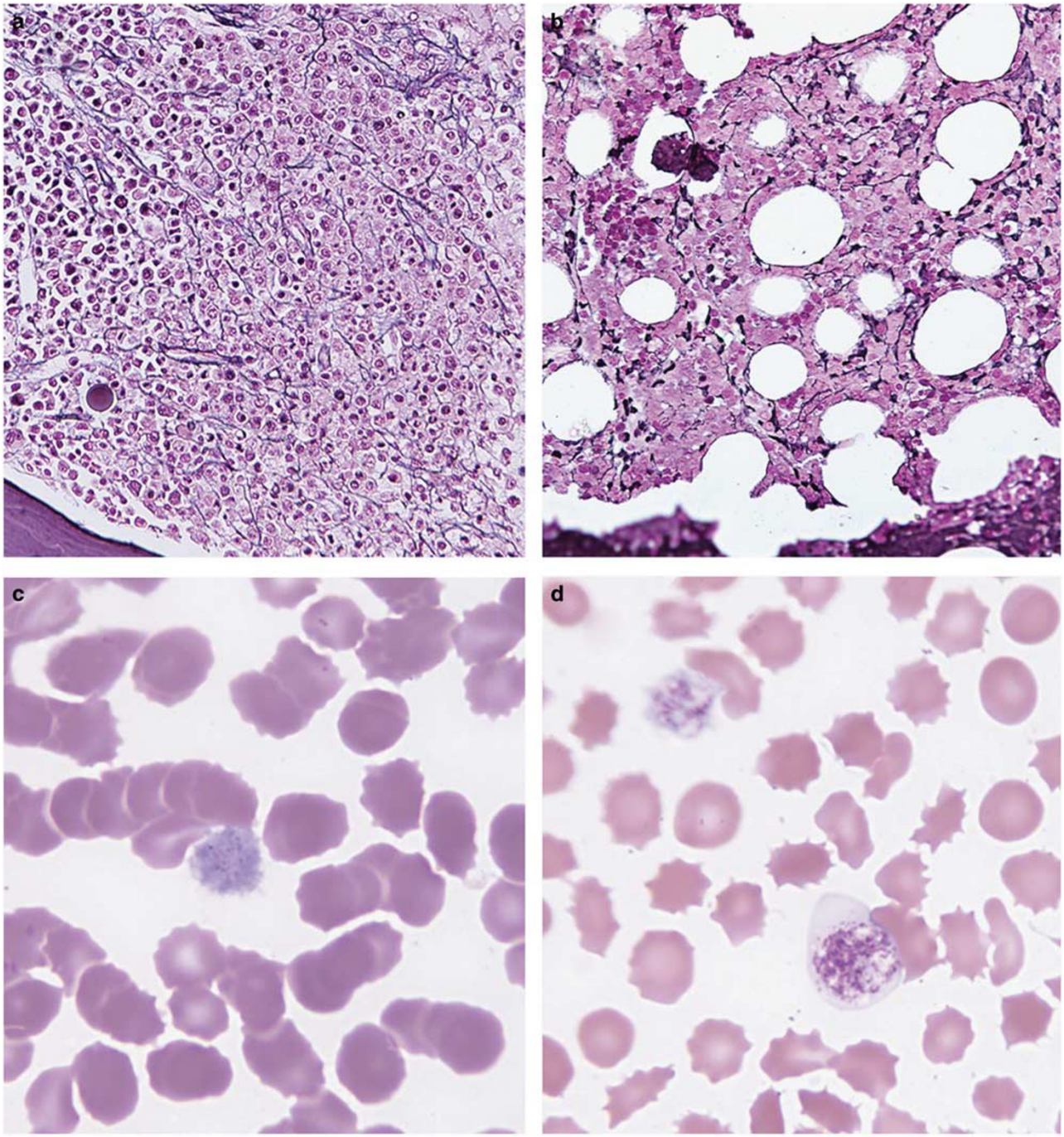

Figure 5 Additional characteristics of each case included: (**a**) Moderate reticulin fibrosis (MF-2) with reticulin staining in Case 2: *ANKRD26*-related thrombocytopenia and (**b**) Case 3: shortened telomere syndrome. Abnormally large and giant platelets were observed in the peripheral blood smears of (**c**) Case 4: *MYH9*-related disorder and (**d**) Case 7: unspecified congenital thrombocytopenia with giant platelets.

blood smears showed abundant giant platelets (Figure 5d).

Wiskott–Aldrich syndrome. A bone marrow biopsy showed normal cellularity (70%) for age (Figure 2h), normal myeloid to erythroid ratio, and a markedly increased number of megakaryocytes varying from small to normal in size (Figure 4h).

Molecular Studies and Cytogenetics

Thrombocytopenia-absent radius syndrome. The patient had multiple bone marrow biopsies with normal male karyotype until 20 years later when a bone marrow biopsy 1 year before the diagnosis of acute myeloid leukemia was found to have new cytogenetic abnormalities with partial loss of 3p and 12q. At the same time, molecular analysis

demonstrated evidence of two missense frameshift mutations in the *CALR* gene (c.1153_1154insCTTGT and c.1154A>C; K385T). Neither mutation has been previously described.

ANKRD26-related thrombocytopenia. There was a heterozygous single nucleotide substitution (c.-134G>A) in 5′-untranslated region of *ANKRD26* detected with targeted polymerase chain reaction. Extensive additional molecular genetic workup was performed including *ASXL1*, *RUNX1*, *EZH2*, *ETV6*, *TP53*, and *JAK2*^{V617F} polymerase chain reaction which were all negative. Subsequently, a 21-gene myeloid molecular sequencing panel was performed when disease progression was suspected which demonstrated mutation in *CBL* gene (c.111T>G; pY371D).

Shortened telomere syndrome. Molecular testing showed *TERT* mutation with telomere length by quantitative polymerase chain reaction reported to be in the first percentile. Cytogenetics showed an extra chromosome 1, which had isochromosome 1q, suggesting four copies of 1q. A myelodysplastic syndrome molecular profile showed *RUNX1* and *ETV6* mutations.

MYH9-related disorder. Cytogenetic analysis showed a constitutive pericentric inversion of one of the homologs of chromosome 9; 46,XX,inv^{9} (p12q13)c[20]. Molecular testing showed heterozygosity in the *MYH9* gene for a missense variant mutation defined as c.4198 C>T and predicted to result in the amino acid substitution p.Arg1400Trp.

Familial platelet disorder with predisposition to acute myeloid leukemia. Cytogenetics showed a normal female karyotype. *RUNX1-RUNX1T1* t(8;21) by real-time polymerase chain reaction was not detected. The patient and her brother had normal results with conventional polymerase chain reaction testing for *RUNX1*, *ANKRD26*, *MPL*, *WAS*, *ADAMTS13*, and *MYH9* gene mutations. Next-generation sequencing performed on the sample from the patient's son showed a large *RUNX1* deletion.

Congenital thrombocytopenia with radial–ulnar synostosis. *Hox11a*, *c-mpl*, Wiskott–Aldrich syndrome protein, and Fanconi anemia molecular testing were normal. Cytogenetics showed a normal male karyotype.

Unspecified congenital thrombocytopenia with giant platelets. An extensive genetic workup was normal (*ANKRD26*, *MPL*, *ADAMTS13*, *WAS*, *MYH9*, *RUNX1*, *TCIRG1*, *TCIRG1* deletion, *CLCN7* deletion, *OSTM1*, *OSTM1* deletion, *PLEKHM1*, diepoxybutane clastogen assay for Fanconi anemia, *GATA1* mutation, *SBDS* gene mutation, *DKC1*, *TINF2* Exon 6, *TERC*, *NHP2* exon 4, *NOP10* exon 2, and *TERT*). Cytogenetics showed a normal male karyotype.

Wiskott–Aldrich syndrome. Cytogenetics showed a normal male karyotype. Genetic testing showed a point mutation in exon 2 of the *WAS* gene.

Discussion

More than 20 individual inherited thrombocytopenia entities—all with a very low incidence in the general population—have been identified thus far. They remain under-diagnosed by hematologists and oncologists and are often classified as idiopathic thrombocytopenic purpura, or even myelodysplastic syndrome or myeloproliferative neoplasm. Information in the literature regarding their histopathologic findings is very limited. Patients with congenital thrombocytopenia can present with bone marrow features mimicking myelodysplastic syndrome and myeloproliferative neoplasm. A high incidence of hematologic malignancy has been previously established in certain categories of familial thrombocytopenia.[5–14,18,19] The distinction between the baseline condition and disease progression to malignancy can be challenging, especially in the absence of relevant clinical history.

The distinctive histologic findings, clinical features, and familial inheritance patterns of common types of congenital thrombocytopenia are summarized in Table 1.[5–14,18,19,25–29] As congenital thrombocytopenia cases are heterogeneous in etiology and clinical features, it was expected that there could be distinctive microscopic findings differentiating each disease (Figure 4). Persistent eosinophilia in thrombocytopenia with absent radii, giant platelets in *MYH9*-related disease, and progressive bone marrow aplasia in congenital thrombocytopenia with radial–ulnar synostosis have been previously described.[21,28] Genetic mutations in *ANKRD26*, *MYH9*, *TERT*, and *RUNX1* genes were discovered in patients and their family members and were crucial in unequivocal assignation of *ANKRD26*-related thrombocytopenia, *MYH9*-related disorder, shortened telomere syndrome, and familial platelet disorder with predisposition to acute myeloid leukemia, respectively.[5]

Bone marrow core biopsy is an important tool to provide baseline characteristics of the congenital thrombocytopenia and to evaluate for disease progression. In the current era of molecular diagnosis based on peripheral blood samples, bone marrow examination is often bypassed. In this series of eight cases, three distinct morphologic patterns were observed. Four out of the eight patients (thrombocytopenia-absent radius syndrome, *ANKRD26*-related thrombocytopenia, shortened telomere syndrome, and *MYH9*-related disorder) had an initial bone marrow morphology that was reminiscent of myelodysplastic/myeloproliferative neoplasm, including marked bone marrow hypercellularity (4/4),

Table 3 Bone marrow changes in patients with disease progression

Case	*Entity*	*Cellularity*	*Myeloid to erythroid ratio*	*Number of blasts*	*Developed myeloid dysplasia*	*Developed erythroid dysplasia*	*Developed bone marrow fibrosis*	*Cytogenetic progression*	*Molecular progression*
1	Thrombocytopenia-absent radius syndrome	~100% all biopsies	>10:1 all biopsies	1%, steady increase to 23%	Yes	Yes	Yes	+(3)(p13), +(12)(q13)	*CALR* mutation
2	*ANKRD26*-related thrombocytopenia	>90% all biopsies	4:1–5:1 all biopsies	1%, steady increase to 7%	Yes	Yes	Yes	No	*CBL* mutation
3	Shortened telomere syndrome	80%	3.4:1	3%, then 5%	Yes	Yes	No	47,XY,+i(1)(q10) [20]	*RUNX1* and *ETV6* mutation

increased myeloid to erythroid ratio (4/4), mild increase in blasts (1/4), fibrosis (2/4), and numerous micromegakaryocytes (4/4). Two out of eight patients (congenital thrombocytopenia with radial–ulnar synostosis and familial platelet disorder with predisposition to acute myeloid leukemia) had morphologic features of bone marrow failure, including hypocellularity and decreased number of megakaryocytes. Megakaryocytes in these two cases had atypically small morphology. Finally, the remaining two cases (Wiskott–Aldrich syndrome and unspecified congenital thrombocytopenia with giant platelets) had normal bone marrow morphology with an appropriate increase in unremarkable-appearing megakaryocytes.

Presence of micromegakaryocytes was a notable feature in six out of eight patients. Micromegakaryocytes were morphologically undistinguishable from small hypolobated megakaryocytes observed in myelodysplastic syndrome. They were best appreciated with CD42b immunohistochemical staining that highlights cells with the glycoprotein Ib receptor for von Willebrand factor. Micromegakaryocytes were not readily apparent on hematoxylin- and eosin-stained slides, therefore, immunohistochemical staining was found to be an important ancillary test for optimal characterization of suspected congenital thrombocytopenia.

Moderate reticulin fibrosis (MF-2) was present in the initial bone marrow biopsies of patients with *ANKRD26*-related thrombocytopenia and shortened telomere syndrome. The patient with thrombocytopenia-absent radius syndrome developed marrow fibrosis in the course of disease progression. Bone marrow fibrosis may be seen in a variety of benign conditions and malignant disorders, and is well known to be associated with myeloid neoplasm.[30–32] Although idiopathic pulmonary fibrosis and cirrhosis are well recognized in shortened telomere syndrome,[11–13,33] bone marrow fibrosis has not been specifically reported as a feature in congenital thrombocytopenia patients. Thus, reticulin fibrosis may be more likely associated with disease progression.

In this study, three out of eight (38%) patients had evidence of morphologic disease progression as noted on multiple consecutive bone marrow biopsies (Table 3). All patients were in the myelodysplastic/myeloproliferative neoplasm-like morphologic group. The patient with thrombocytopenia-absent radius syndrome developed evidence of erythroid and myeloid dysplasia, slowly progressive elevated bone marrow blasts, bone marrow fibrosis, evidence of new cytogenetic abnormalities, and presence of *CALR* gene mutations. The patient with *ANKRD26*-related thrombocytopenia had a worsening anemia and multiple bone marrow biopsies, which showed progressive increase in cellularity and the myeloid to erythroid ratio, new erythroid and myeloid dysplasia and an increase in blasts, as well as mutation in *CBL* gene. The patient with shortened telomere syndrome

diagnosis presented at the age of 41 with pancytopenia, overt trilineage dysplasia, a borderline increase in blasts and presence of *RUNX1* and *ETV6* mutations.

Molecular abnormalities are a salient feature in both congenital thrombocytopenia and in myeloid neoplasms. In this study, additional acquired genetic and cytogenetic defects over the course of disease in congenital thrombocytopenia were strongly associated with disease progression. At baseline, four of eight congenital thrombocytopenia patients were identified to have characteristic disease-specific mutations (*TERT* gene mutation defining shortened telomere syndrome, *ANKRD26, MYH9,* and *WAS* genes). Over time, all three patients with clinical disease progression concerning for myeloid neoplasm developed new cytogenetic and/or molecular abnormalities. The patient with thrombocytopenia-absent radius syndrome had partial loss of 3p and 12q, correlated to an increase in blasts and clinical deterioration. The molecular analysis demonstrated evidence of two missense frameshift mutations in the *CALR* gene. Neither mutation has been previously described. Mutations in exon 9 of the *CALR* gene has been described in a large subset of patients with patients with *JAK2* wild-type essential thrombocythemia and primary myelofibrosis.[34,35] Calreticulin is a highly conserved protein with pleiotropic roles related to distribution in the endosplasmic reticulum, cytosol, and the cell surface. *In vitro* transfection of mutant calreticulin leads to hyperactivation of the pathway.[35] Calreticulin immunostaining highlights the megakaryocytes in bone marrows specimens from patients with myeloid neoplasms.[36] Thus, *CALR*-mutated myeloproliferative neoplasms appear to correspond to stem cell-derived neoplasms with aberrant and preferential expansion of the megakaryocyte lineage.[34] A study of 154 patients with familial myeloproliferative neoplasm demonstrated that all *CALR* mutations were somatically acquired.[37] In this study, it is unclear when the patient acquired this mutation and whether there was a possibility of germline *CALR* mutation associated with thrombocytopenia-absent radius syndrome pathogenesis. To the best of our knowledge, *CALR* mutation has not been previously described in patients with congenital thrombocytopenia or in patients with *de novo* acute myeloid leukemia.

Familial thrombocytopenia with *ANKRD26* mutation is a recently described entity that is one of the more common forms of congenital thrombocytopenia.[10,38] Approximately 45 families have been identified with an autosomal dominant transmission. It is characterized by normal platelet size, moderate thrombocytopenia, and absent or mild bleeding tendency. Predisposition to myeloid neoplasms, especially acute myeloid leukemia and myelodysplastic syndrome has been reported in the affected family members. Results of bone marrow examination have been previously described in four patients. Similar to the patient in this study, all showed an increased number of very small hypolobated megakaryocytes ('dysmegakaryopoiesis').[10,38] In this study, the patient with *ANKRD26*-related thrombocytopenia demonstrated a mutation in the *CBL* gene at the time of morphologic disease progression. *CBL* is a tumor-suppressor gene that encodes a multivalent adaptor protein with E3 ubiquitin ligase activity.[39] Somatically acquired, mostly homozygous *CBL* mutations have been found to occur with variable prevalence in myeloproliferative disorders, including juvenile myelomonocytic leukemia and acute myeloid leukemia.[40,41] Heterozygous germline mutations in *CBL* gene have been found in patients with Noonan syndrome.[42] The significance of *CBL* mutation is the setting of disease progression in *ANKRD26*-related thrombocytopenia is uncertain. Finally, the patient with shortened telomere syndrome had evidence of morphologic disease progression and concurrent detection of *RUNX1* and *ETV6* gene mutations. Both mutations have been described in germline setting of familial thrombocytopenia[15,43] and in somatic setting of myeloid neoplasms including acute myeloid leukemia.[44,45]

The patient with familial platelet disorder with predisposition to acute myeloid leukemia is presumed to have *RUNX1* abnormality due to strong family history of thrombocytopenia with autosomal dominant transmission and presence of large *RUNX1* gene deletion in her son, identified by sequencing but not with conventional polymerase chain reaction techniques. Familial platelet disorder with predisposition to acute myeloid leukemia is an autosomal dominant disorder characterized by mild to moderate thrombocytopenia and abnormalities of platelet function. More than a third of these patients develop myelodysplastic syndrome and/or acute myeloid leukemia.[16] Bone marrow morphology has not been systematically evaluated in familial platelet disorder with predisposition to acute myeloid leukemia, but when reported, dysmegakaryopoiesis has been documented.[46] Dysmegakaryopoiesis may reflect the abnormal megakaryopoiesis secondary to the germline *RUNX1* mutation, since *RUNX1* is a transcription factor that plays a key role in megakaryocyte maturation, differentiation, ploidization, and proplatelet formation.[47] *RUNX1* mutations are distributed throughout the gene and comprise complete deletions of *RUNX1*, splice-site mutations, missense, nonsense, and frameshift mutations. Germline testing on individuals with suspected *RUNX1* mutations should include tests sensitive to deletions, duplications, and rearrangements, which may go undetected by standard sequencing techniques, as was the case in the family described in this study.[48]

The only effective treatment to increase the platelet count in patients with congenital thrombocytopenia—other than short-term effects of platelet transfusion and infrequent responses to intravenous

immunoglobulin and steroids—are thrombopoietin receptor agonists. Their use has been specifically described in Wiskott–Aldrich syndrome[49] and *MYH9*-related disorder.[50] These agents have been well-described by our group and others to result in bone marrow findings reminiscent of myeloproliferative neoplasm.[51] Therefore, use of these agents may further complicate morphologic evaluation of bone marrow biopsies in these cases and could even result in induction of true myeloproliferative neoplasm or even leukemia as had been seen in cases of myelodysplastic syndrome and of severe aplastic anemia.[52]

In summary, congenital thrombocytopenias are a heterogeneous group of diseases with variable clinical characteristics and morphologic features. We identified three distinct types based on bone marrow morphology: a hyperplastic myelodysplastic/myeloproliferative neoplasm-like group, a hypoplastic bone marrow failure-like group, and a group with normal marrow morphology. Three of four patients in the myelodysplastic/myeloproliferative neoplasm-like group had evidence of disease progression, compared with none in the other groups. Features of disease progression included development of non-megakaryocytic dysplasia, increase in blasts, and new cytogenetic/molecular abnormalities. Analysis is complicated by the fact that patients in the myelodysplastic/myeloproliferative neoplasm-like group had evidence of persistently elevated bone marrow cellularity (3/3), high myeloid to erythroid ratio (3/3), megakaryocyte atypia (3/3), and marrow fibrosis (2/3) for years before definitive diagnosis of disease progression. In addition, although the cytogenetic abnormalities in patient with thrombocytopenia-absent radius syndrome were definitely a new finding, the significance of *CALR, CBL, RUNX1*, and *ETV6* gene mutations is less clear since these mutations have not been evaluated at the disease onset. Myeloid neoplasm was diagnosed at ages 40, 47, and 52 in these patients with lifelong congenital thrombocytopenia. Thus, myelodysplastic/myeloproliferative neoplasm-like congenital thrombocytopenias appear to have a long and indolent clinical course with very slow progression to leukemia in a subset of cases.

On the basis of these findings, we suggest that bone marrow biopsy is an important part in the diagnostic workup and subsequent monitoring of patients with congenital thrombocytopenia. Adequate and complete clinical history is paramount, since there is a significant morphologic overlap with myeloid neoplasms. Conservative approach is warranted in congenital thrombocytopenia patients with myelodysplastic/myeloproliferative neoplasm-like morphologic findings. Further studies on the evaluation of both bone marrow morphology and molecular genetic characteristics and their contribution to thrombocytopenia and disease progression are warranted to further elucidate the pathogenesis of not only these rare hematologic disorders but their progression to malignancy.

Disclosure/conflict of interest

The authors declare no conflict of interest.

References

1 Balduini CL, Iolascon A, Savoia A. Inherited thrombocytopenias: from genes to therapy. Haematologica 2002;87:860–880.
2 Balduini CL, Savoia A. Inherited thrombocytopenias: molecular mechanisms. Semin Thromb Hemost 2004;30:513–523.
3 Balduini CL, Savoia A. Genetics of familial forms of thrombocytopenia. Hum Genet 2012;131:1821–1832.
4 Noris P, Pecci A, Di Bari F, *et al.* Application of a diagnostic algorithm for inherited thrombocytopenias to 46 consecutive patients. Haematologica 2004;89:1219–1225.
5 Cines DB, Bussel JB, McMillan RB *et al.* Congenital and acquired thrombocytopenia. Hematol Am Soc Hematol Educ Program 2004;1:390–406.
6 Noris P, Favier R, Alessi MC, *et al.* ANKRD26-related thrombocytopenia and myeloid malignancies. Blood 2013;122:1987–1989.
7 Mullen CA, Anderson KD, Blaese RM. Splenectomy and or Bone-marrow transplantation in the management of the Wiskott-Aldrich syndrome - long-term follow-up of 62 cases. Blood 1993;82:2961–2966.
8 Sano H, Kobayashi R, Suzuki D, *et al.* Wiskott-Aldrich syndrome with unusual clinical features similar to juvenile myelomonocytic leukemia. Int J Hematol 2012;96:279–283.
9 Yoshimi A, Kamachi Y, Imai K, *et al.* Wiskott-Aldrich syndrome presenting with a clinical picture mimicking juvenile myelomonocytic leukaemia. Pediatr Blood Cancer 2013;60:836–841.
10 Noris P, Perrotta S, Seri M, *et al.* Mutations in ANKRD26 are responsible for a frequent form of inherited thrombocytopenia: analysis of 78 patients from 21 families. Blood 2011;117:6673–6680.
11 Gramatges MM, Bertuch AA. Short telomeres: from dyskeratosis congenita to sporadic aplastic anemia and malignancy. Transl Res 2013;162:353–363.
12 Yamaguchi H, Calado RT, Ly H, *et al.* Mutations in TERT, the gene for telomerase reverse transcriptase, in aplastic anemia. N Engl J Med 2005;352:1413–1424.
13 Alter BP. Diagnosis, genetics, and management of inherited bone marrow failure syndromes. Hematol Am Soc Hematol Educ Program 2007;29–39.
14 Liew E, Owen C. Familial myelodysplastic syndromes: a review of the literature. Haematologica 2011;96: 1536–1542.
15 Kirito K, Sakoe K, Shinoda D, *et al.* A novel RUNX1 mutation in familial platelet disorder with propensity to develop myeloid malignancies. Haematologica 2008;93:155–156.
16 Owen CJ, Toze CL, Koochin A, *et al.* Five new pedigrees with inherited RUNX1 mutations causing familial platelet disorder with propensity to myeloid malignancy. Blood 2008;112:4639–4645.
17 Jongmans MC, Kuiper RP, Carmichael CL, *et al.* Novel RUNX1 mutations in familial platelet disorder with

enhanced risk for acute myeloid leukemia: clues for improved identification of the FPD/AML syndrome. Leukemia 2010;24:242–246.
18 Fujishima N, Hirokawa M, Ishikawa H, *et al.* May–Hegglin anomaly developing myelodysplasia and acute myeloid leukemia. Int J Hematol 2004;79: 505–506.
19 Rheingold SR. Acute myeloid leukemia in a child with hereditary thrombocytopenia. Pediatr Blood Cancer 2007;48:105–107.
20 Seri M, Pecci A, Di Bari F, *et al.* MYH9-related disease: May-Hegglin anomaly, Sebastian syndrome, Fechtner syndrome, and Epstein syndrome are not distinct entities but represent a variable expression. Medicine 2003;82:203–215.
21 Hedberg VA, Lipton JM. Thrombocytopenia with absent radii. A review of 100 cases. Am J Pediatr Hematol Oncol 1988;10:51–64.
22 Bonsi L, Marchionni C, Alviano F, *et al.* Thrombocytopenia with absent radii (TAR) syndrome: from hemopoietic progenitor to mesenchymal stromal cell disease? Exp Hematol 2009;37:1–7.
23 Bosticardo M, Marangoni F, Aiuti A, *et al.* Recent advances in understanding the pathophysiology of Wiskott-Aldrich syndrome. Blood 2009;113:6288–6295.
24 Melazzini F, Palombo F, Balduini A, *et al.* Clinical and pathogenetic features of ETV6 related thrombocytopenia with predisposition to acute lymphoblastic leukemia. Haematologica 2016;101:1333–1342.
25 Bader-Meunier B, Proulle V, Trichet C, *et al.* Misdiagnosis of chronic thrombocytopenia in childhood. J Pediatr Hematol Oncol 2003;25:548–552.
26 Heath KE, Campos-Barros A, Toren A, *et al.* Nonmuscle myosin heavy chain IIA mutations define a spectrum of autosomal dominant macrothrombocytopenias: May-Hegglin anomaly and Fechtner, Sebastian, Epstein, and Alport-like syndromes. Am J Hum Genet 2001;69: 1033–1045.
27 Kunishima S, Matsushita T, Kojima T, *et al.* Identification of six novel MYH9 mutations and genotype-phenotype relationships in autosomal dominant macrothrombocytopenia with leukocyte inclusions. J Hum Genet 2001;46:722–729.
28 Thompson AA, Woodruff K, Feig SA, *et al.* Congenital thrombocytopenia and radio-ulnar synostosis: a new familial syndrome. Br J Haematol 2001;113:866–870.
29 Yoshida H, Hashii Y, Okuda T, *et al.* A case of congenital bone marrow failure with radio-ulnar synostosis. Int J Hematol 2010;91:331–332.
30 Vardiman JW, Thiele J, Arber DA, *et al.* The 2008 revision of the World Health Organization (WHO) classification of myeloid neoplasms and acute leukemia: rationale and important changes. Blood 2009;114:937–951.
31 Kuter DJ, Bain B, Mufti G, *et al.* Bone marrow fibrosis: pathophysiology and clinical significance of increased bone marrow stromal fibres. Br J Haematol 2007;139: 351–362.
32 Della Porta MG, Malcovati L. Myelodysplastic syndromes with bone marrow fibrosis. Haematologica 2011;96:180–183.
33 Yamaguchi H, Baerlocher GM, Lansdorp PM, *et al.* Mutations of the human telomerase RNA gene (TERC) in aplastic anemia and myelodysplastic syndrome. Blood 2003;102:916–918.
34 Nangalia J, Massie CE, Baxter EJ, *et al.* Somatic CALR mutations in myeloproliferative neoplasms with nonmutated JAK2. N Engl J Med 2013;369:2391–2405.
35 Klampfl T, Gisslinger H, Harutyunyan AS, *et al.* Somatic mutations of calreticulin in myeloproliferative neoplasms. N Engl J Med 2013;369:2379–2390.
36 Vannucchi AM, Rotunno G, Bartalucci N, *et al.* Calreticulin mutation-specific immunostaining in myeloproliferative neoplasms: pathogenetic insight and diagnostic value. Leukemia 2014;28:1811–1818.
37 Rumi E, Harutyunyan AS, Pietra D, *et al.* CALR exon 9 mutations are somatically acquired events in familial cases of essential thrombocythemia or primary myelofibrosis. Blood 2014;123:2416–2419.
38 Marquez R, Hantel A, Lorenz R, *et al.* A new family with a germline ANKRD26 mutation and predisposition to myeloid malignancies. Leuk Lymphoma 2014;55:2945–2946.
39 Schmidt MH, Dikic I. The Cbl interactome and its functions. Nat Rev Mol Cell Biol 2005;6:907–918.
40 Caligiuri MA, Briesewitz R, Yu J, *et al.* Novel c-CBL and CBL-b ubiquitin ligase mutations in human acute myeloid leukemia. Blood 2007;110:1022–1024.
41 Loh ML, Sakai DS, Flotho C, *et al.* Mutations in CBL occur frequently in juvenile myelomonocytic leukemia. Blood 2009;114:1859–1863.
42 Martinelli S, De Luca A, Stellacci E, *et al.* Heterozygous germline mutations in the CBL tumor-suppressor gene cause a Noonan syndrome-like phenotype. Am J Hum Genet 2010;87:250–257.
43 Zhang MY, Churpek JE, Keel SB, *et al.* Germline ETV6 mutations in familial thrombocytopenia and hematologic malignancy. Nat Genet 2015;47:180–185.
44 Gaidzik VI, Bullinger L, Schlenk RF, *et al.* RUNX1 mutations in acute myeloid leukemia: results from a comprehensive genetic and clinical analysis from the AML study group. J Clin Oncol 2011;29:1364–1372.
45 Schnittger S, Dicker F, Kern W, *et al.* RUNX1 mutations are frequent in de novo AML with noncomplex karyotype and confer an unfavorable prognosis. Blood 2011;117:2348–2357.
46 Latger-Cannard V, Philippe C, Bouquet A, *et al.* Haematological spectrum and genotype-phenotype correlations in nine unrelated families with RUNX1 mutations from the French network on inherited platelet disorders. Orphanet J Rare Dis 2016;11:49.
47 Bluteau D, Glembotsky AC, Raimbault A, *et al.* Dysmegakaryopoiesis of FPD/AML pedigrees with constitutional RUNX1 mutations is linked to myosin II deregulated expression. Blood 2012;120:2708–2718.
48 Nickels EM, Soodalter J, Churpek JE, *et al.* Recognizing familial myeloid leukemia in adults. Ther Adv Hematol 2013;4:254–269.
49 Gerrits AJ, Leven EA, Frelinger AL 3rd, *et al.* Effects of eltrombopag on platelet count and platelet activation in Wiskott-Aldrich syndrome/X-linked thrombocytopenia. Blood 2015;126:1367–1378.
50 Pecci A, Gresele P, Klersy C, *et al.* Eltrombopag for the treatment of the inherited thrombocytopenia deriving from MYH9 mutations. Blood 2010;116:5832–5837.
51 Boiocchi L, Orazi A, Ghanima W, *et al.* Thrombopoietin receptor agonist therapy in primary immune thrombocytopenia is associated with bone marrow hypercellularity and mild reticulin fibrosis but not other stromal abnormalities. Mod Pathol 2012;25:65–74.
52 Townsley DM, Desmond R, Dunbar CE, *et al.* Pathophysiology and management of thrombocytopenia in bone marrow failure: possible clinical applications of TPO receptor agonists in aplastic anemia and myelodysplastic syndromes. Int J Hematol 2013;98:48–55.