

Review

International Society of Urological Pathology (ISUP) Consensus Conference on Handling and Staging of Radical Prostatectomy Specimens. Working group 3: extraprostatic extension, lymphovascular invasion and locally advanced disease

Cristina Magi-Galluzzi¹, Andrew J Evans², Brett Delahunt³, Jonathan I Epstein⁴, David F Griffiths⁵, Theo H van der Kwast⁶, Rodolfo Montironi⁷, Thomas M Wheeler⁸, John R Srigley⁹, Lars L Egevad¹⁰, Peter A Humphrey¹¹ and The ISUP Prostate Cancer Group¹²

¹Department of Anatomic Pathology, Cleveland Clinic & Lerner College of Medicine of Case Western Reserve University, Cleveland, OH, USA; ²Department of Pathology and Laboratory Medicine, University Health Network, Toronto General Hospital Toronto, Ontario, Canada; ³Department of Pathology and Molecular Medicine, Wellington School of Medicine and Health Sciences, University of Otago, Wellington, New Zealand; ⁴Department of Pathology, Johns Hopkins Hospital, Baltimore, MD, USA; ⁵Department of Pathology, Cardiff University School of Medicine, University Hospital of Wales, Cardiff, UK; ⁶Department of Pathology, University Health Network and University of Toronto, Toronto, Ontario, Canada; ⁷Section of Pathological Anatomy, Polytechnic University of the Marche Region, School of Medicine, United Hospitals, Ancona, Italy; ⁸Department of Pathology, Baylor College of Medicine, Houston, TX, USA; ⁹Department of Pathology and Molecular Medicine, McMaster University, Hamilton, Ontario, Canada; ¹⁰Department of Oncology-Pathology, Karolinska Institute, Stockholm, Sweden and ¹¹Department of Pathology and Immunology, Washington University School of Medicine, St Louis, MO, USA

The International Society of Urological Pathology Consensus Conference on Handling and Staging of Radical Prostatectomy Specimens in Boston made recommendations regarding the standardization of pathology reporting of radical prostatectomy specimens. Issues relating to extraprostatic extension (pT3a disease), bladder neck invasion, lymphovascular invasion and the definition of pT4 were coordinated by working group 3. It was agreed that prostate cancer can be categorized as pT3a in the absence of adipose tissue involvement when cancer bulges beyond the contour of the gland or beyond the condensed smooth muscle of the prostate at posterior and posterolateral sites. Extraprostatic extension can also be identified anteriorly. It was agreed that the location of extraprostatic extension should be reported. Although there was consensus that the amount of extraprostatic extension should be quantitated, there was no agreement as to which method of quantitation should be employed. There was overwhelming consensus that microscopic urinary bladder neck invasion by carcinoma should be reported as stage pT3a and that lymphovascular invasion by carcinoma should be reported. It is recommended that these elements are considered in the development of practice guidelines and in the daily practice of urological surgical pathology. *Modern Pathology* (2011) 24, 26–38; doi:10.1038/modpathol.2010.158; published online 27 August 2010

Keywords: classification; prostatectomy; prostatic adenocarcinoma; tumor stage

Correspondence: Dr C Magi-Galluzzi, MD, PhD, Department of Anatomic Pathology, Glickman Urological & Kidney Institute and Lerner College of Medicine, Cleveland Clinic, 9500 Euclid Avenue, L25, Cleveland, OH 44195 USA. E-mail: MAGIC@ccf.org
¹²See appendix.

Received 25 October 2009; revised 15 July 2010; accepted 20 July 2010; published online 27 August 2010

Extraprostatic extension is a well-established adverse prognostic factor for prostate carcinoma,^{1–5} and accurate identification of this feature is required for optimal patient management after radical prostatectomy.^{1–4} Despite this, disagreement exists as to what features define extraprostatic

extension, especially at the prostatic apex and bladder neck.^{5,6}

Although infiltration of the urinary bladder and rectum by prostatic adenocarcinoma is associated with a poor outcome, there is debate as to the appropriate staging category that should be applied and specifically whether tumor involvement of the urinary bladder should be categorized as pT4 or M1 disease. Similarly, the independent prognostic significance of microscopic invasion of the bladder neck by prostate cancer has recently been questioned.⁷

Lymphatic and vascular invasion are among the histological variables in radical prostatectomy specimens that the Association of Directors of Anatomic and Surgical Pathology and the College of American Pathologists recommend to be reported following microscopic examination of routinely stained sections.^{8–10} Few studies have assessed the incidence and the prognostic impact of lymphovascular invasion and to date there are conflicting findings.^{11–20}

The prognostic importance of these several features was addressed by consensus conference participants.

Materials and methods

In order to identify the methods and practices most commonly employed by urological pathologists worldwide, a web-based survey on handling and reporting of radical prostatectomy specimens was distributed to 255 members of the International Society of Urological Pathology (ISUP).

ISUP Consensus Conference

The ISUP survey was followed up with a consensus conference held in conjunction with the 2009 Annual Scientific Meeting of the United States and Canadian Academy of Pathology held in Boston, Massachusetts. The aim was to obtain consensus relating to the handling, staging and reporting of radical prostatectomy specimens. Those who completed the electronic survey were invited to attend the consensus conference, which was held on March 8, 2009. The detailed process related to the survey and consensus meeting are reported in an introductory paper.²¹

Representatives from five working groups appointed to coordinate the consensus process presented background information and results from detailed literature reviews to the meeting. The survey results were then discussed with the objective of achieving agreement on controversial issues. Following this, a ballot was taken on a series of questions that were designed to address these controversial issues and an achievement of 65% agreement on voting was considered to be consensus. With a few exceptions, there was agreement between the survey results and the consensus

conference results. The results of the individual working group reports related to specimen handling, T2 substaging, seminal vesicle and lymph node involvement, and margin status are reported separately.^{22–25}

Many recommendations of this consensus conference have already been incorporated into international guidelines, including the recent College of American Pathologists protocol and checklist for reporting adenocarcinoma of the prostate, and the structured reporting protocol for prostatic carcinoma from the Royal College of Pathologists of Australia.^{26,27}

Results and discussion

Extraprostatic Extension (pT3a)

The tumor, lymph node and metastasis (TNM) staging system for prostate cancer defines pT3a as extension of tumor into periprostatic soft tissue. Extraprostatic extension is the preferred terminology and should be used in favor of ambiguous terms such as capsular penetration, capsular invasion or capsular perforation.^{8,28} Extraprostatic extension is most simply defined as the presence of tumor beyond the confines of the prostate and criteria exist to guide pathologists in its recognition.^{28,29} This definition is, however, somewhat oversimplified as the prostate does not possess a true histological capsule³⁰ and it can be challenging for pathologists to identify the boundary of the gland. This is particularly true when tumor at the periphery is associated with a desmoplastic reaction.^{29,31} It, therefore, follows that the diagnosis of extraprostatic extension can be made in several different situations²⁹ and varying diagnostic criteria for extraprostatic extension will apply in different regions of the prostate. In the posterior, posterolateral and lateral aspects of the gland, tumor admixed with periprostatic fat is the most easily recognized manifestation of extraprostatic extension (Figures 1a–c). Tumor in fat is almost always a feature of extraprostatic extension by prostate cancer; however, pathologists should be aware that intraprostatic fat has been identified, although only rarely (1% of radical prostatectomy specimens) by some investigators and not at all by others.^{32,33} Although more likely to be problematic in prostate biopsies, intraprostatic fat could potentially give rise to a false-positive diagnosis of extraprostatic extension in radical prostatectomy specimens as well. Extraprostatic extension in the posterolateral area can be diagnosed when tumor is identified within loose connective tissue or perineural spaces of the neurovascular bundles, even in the absence of direct contact between tumor cells and adipocytes. It may also be recognized as a distinct tumor nodule within desmoplastic stroma that bulges beyond the normal contour of the gland. Pathologists who had faced this situation will typically track along the edge of

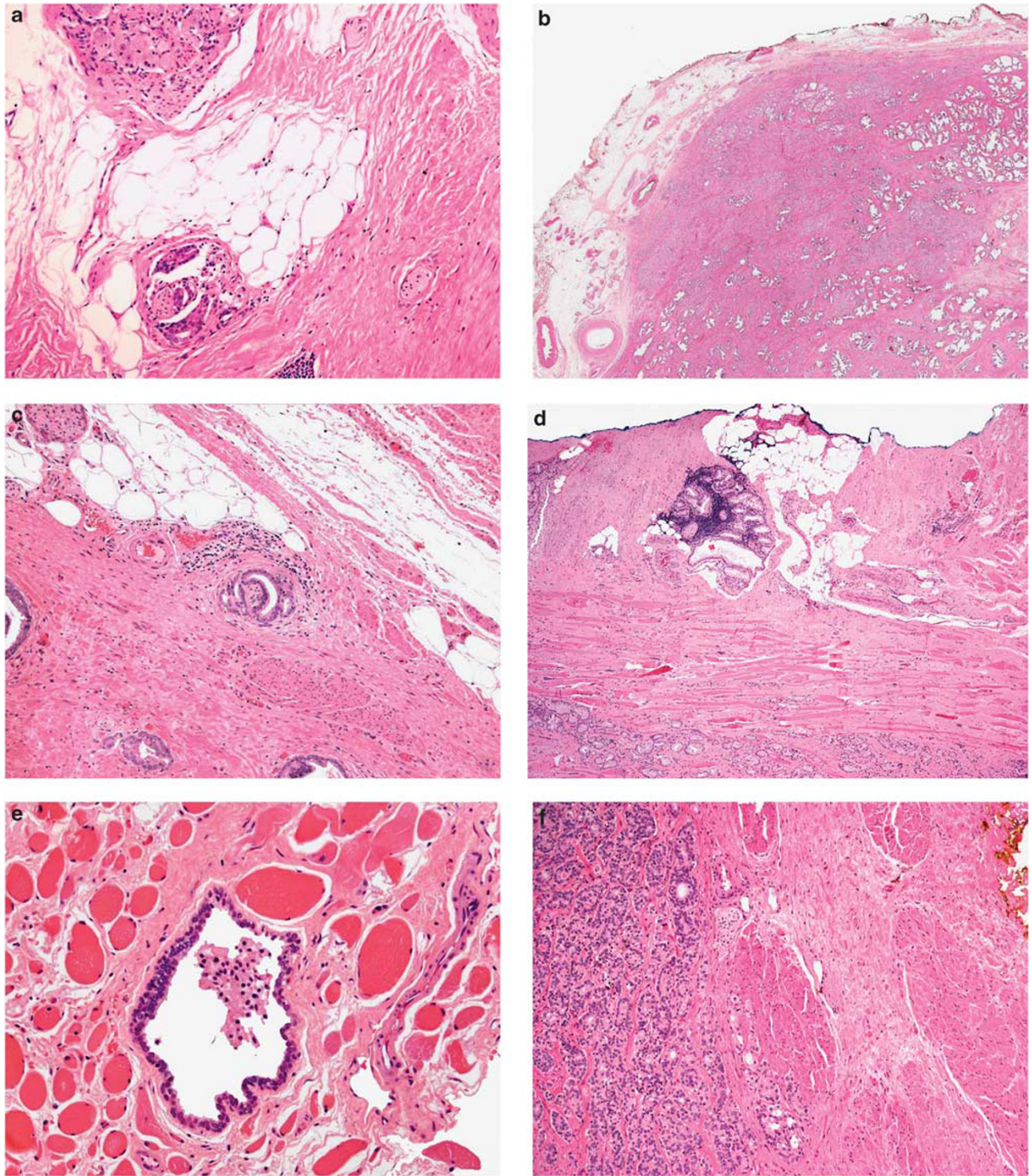


Figure 1 (a) Focal extraprostatic extension in the posterolateral aspect of the gland characterized by malignant glands in periprostatic fat. Also note that the extraprostatic extension has occurred via perineural invasion. (b) Established extraprostatic extension in the posterolateral aspect of the gland characterized by direct extension of malignant glands into periprostatic fat. This focus of extraprostatic extension is accompanied by pronounced stromal desmoplasia, creating a bulge of tumor beyond the normal contour of the prostate. (c) Malignant glands with perineural invasion and associated stromal desmoplasia. This tiny cluster of glands is located at the very edge of the prostate, in its lateral aspect, in close association with periprostatic fat. Situations such as this have been associated with appreciable interobserver variability between pathologists with respect to making a diagnosis of extraprostatic extension. (d) Section from the anterior aspect of a radical prostatectomy specimen with a large volume anterior tumor. Malignant glands are seen beyond the contour of the prostate with extensive infiltration of the tissue of the anterior fibromuscular zone and of the anterior periprostatic fat. This finding constitutes extraprostatic extension in the anterior aspect. (e) Benign prostatic gland within striated muscle in a section from the prostatic apex. (f) Microscopic invasion by prostatic adenocarcinoma among thick smooth muscle bundles of the coned bladder neck. The muscular wall of the bladder neck is infiltrated by prostate cancer in the absence of benign prostatic glandular tissue.

the gland at low magnification, starting in a region without tumor, to confirm disruption of its normal rounded contour, before making a diagnosis of extraprostatic extension.²⁹ In the apex, anterior and bladder neck regions, there is a paucity of fat and the histological boundary of the prostate is poorly defined. Some pathologists feel that extraprostatic extension cannot be diagnosed in sections from the distal apical margin, whereas others diagnose extraprostatic extension at the apex when tumor touches an inked surgical margin, where benign glands have not been similarly cut across,^{6,30} or when malignant glands extend beyond the contour of the normal glandular prostate⁶ (Figure 1d). Benign glands are frequently admixed with striated muscle in the apex (Figure 1e), and it follows that finding malignant glands within striated muscle does not, itself, constitute extraprostatic extension in this location.^{6,29}

The prostatic stroma in the anterior aspect blends in with extraprostatic smooth muscle, creating yet another challenge for the pathologist attempting to mark the boundary of the gland. Identifying prostate cancer beyond the contour of the normal glandular prostate has been suggested as the method for diagnosing extraprostatic extension at this location.²⁹

Data on interobserver variability among pathologists concerning the diagnosis of extraprostatic extension are limited. There are two separate reports based on comparing the results obtained by a single reviewer with those of a group of pathologists.^{34,35} Both these studies indicated that there is substantial variability between experienced reviewers and non-experts. Ekici *et al*³⁴ conducted an intradepartmental study of 114 radical prostatectomy specimens and reported high interobserver variation for the diagnosis of extraprostatic extension between general pathologists and the experienced reviewer. Van der Kwast *et al*³⁵ reported similar findings from a single pathologist central review of 552 radical prostatectomy specimens in an EORTC trial. Evans *et al*⁶ assessed interobserver variability for extraprostatic extension assessment among a group of 12 urological pathologists. In this study, a panel of three urological pathologists selected 30 slides that represented a spectrum of difficulty with respect to diagnosing extraprostatic extension. The panel selected sections that were thought to be clearly positive or negative for extraprostatic extension—as well as equivocal sections that the panel thought could possibly be interpreted either way. The participating pathologists were blinded as to the panel's designation of the slides, being either straightforward or equivocal for extraprostatic extension. There was excellent agreement for the unequivocal sections, with the overall level of agreement in the range reported for Gleason scoring by urological pathologists,^{36–39} whereas for the problematic sections only fair agreement was achieved. Problems with extraprostatic extension

interpretation were noted to be related to the lack of a true prostatic histological capsule and the definition applied to the boundary of the prostate on a given section.³⁰ A major conclusion of this study was that robust interpretation of extraprostatic extension is not possible in certain situations.

Recognizing that more than 50% of patients with extraprostatic extension at radical prostatectomy do not show tumor progression over a 10-year follow-up period,³⁹ different methodologies have been suggested in order to quantify extraprostatic extension in a manner that will provide accurate prognostic information in terms of prostate-specific antigen (PSA) failure and cancer progression. It is important to recognize that no single method for quantitation of extraprostatic extension has emerged that is objective, practical and accurate in terms of its ability to predict PSA failure and disease progression. The 1992 TNM system divided extraprostatic extension into T3a and T3b subcategories based on a unilateral or bilateral involvement; however, subsequent studies found no difference in outcome between the two groups.^{40–42} In 1993 Epstein *et al*⁴³ suggested that the extent of extraprostatic extension could be categorized as focal or established, where focal refers to the finding of a few neoplastic glands outside the prostate, and established extraprostatic extension to anything more than a few glands. Applying these criteria to 196 cases, this group found 8-year progression-free rates of 82 and 65% for the focal and established extraprostatic extension groups, respectively. In 1998 Wheeler *et al*⁴⁴ provided a more objective version of the focal *versus* established approach of Epstein. Tumor invading the periprostatic fat or bladder neck smooth muscle was subdivided into focal or established subgroups, where focal was defined as extraprostatic tumor occupying <1 high-power field on ≤2 separate sections and established as any extraprostatic extension that was more extensive than focal. Using this approach, Wheeler *et al* reported actuarial 5-year progression-free probabilities from 688 T1-2 NX M0 cases of 73 and 42% for the focal and established groups, respectively. Other methods of reporting the extent of extraprostatic extension include the greatest linear dimension, the radial dimension and even volumetric measurements of extraprostatic extension.^{2,45–48} Most recently, Sung *et al*⁴⁹ investigated the relationship between radial extent of extraprostatic extension and PSA failure after radical prostatectomy. They used an ocular micrometer to measure the maximum distance that tumor protruded beyond the outer margin of the prostatic stroma in 83 radical prostatectomy specimens with extraprostatic extension. Their findings on the prognostic utility of radial distance were also systematically compared with seven other methods of quantifying extraprostatic extension. These approaches included the methods of Epstein *et al*⁴³ and Wheeler *et al*,⁴⁴ as well as counting the number of extraprostatic malignant glands,

unilateral *versus* bilateral extraprostatic extension, unifocal *versus* multifocal extraprostatic extension, circumferential length of extraprostatic extension and total volume of extraprostatic extension as estimated by a grid method. Of all methods assessed, it was found that radial distance of extraprostatic extension was the only independent predictor of PSA recurrence in multivariate analysis. These authors concluded that the independent information provided by measuring radial distance of extraprostatic extension could potentially be incorporated into future TNM staging systems for substaging pT3a prostate cancer. They further noted that not all patients with extraprostatic extension will be accurately identified and that not all cases of extraprostatic extension can be subclassified in a straightforward manner, the main reasons being (1) the presence of a desmoplastic reaction, which can obscure the boundary between the prostate and its adjacent soft tissue, and (2) the lack of a prostatic capsule. As shown in the study by Evans *et al*,⁶ both these factors will create appreciable interobserver variability with respect to the diagnosis of extraprostatic extension. It would seem intuitive that measuring the radial distance of extraprostatic extension⁴⁹ is a more objective method of quantitation than the focal *versus* established approach;⁴³ however, it must be recognized that the accuracy of any method is limited by the difficulty pathologists can encounter in identifying the boundary of the gland.

Extraprostatic extension from peripheral zone cancers is most commonly identified in the posterolateral aspect of the gland, in which tracking of tumor along perineural spaces has long been thought to represent the most common mechanism of spread.⁵⁰ Extraprostatic extension from transition zone cancers typically occurs by direct extension anteriorly without perineural invasion.²⁹ Although pathologists tend to report the location(s) of extraprostatic extension, there is no evidence that the location of this has prognostic significance or critical relevance with respect to additional therapy after radical prostatectomy.

Results of ISUP survey on extraprostatic extension

With respect to the recognition of extraprostatic extension, 90% of the respondents agreed that carcinoma adjacent to, or invading, adipose tissue is diagnostic of extraprostatic extension (Table 1). The survey respondents reported that they generally avoided diagnosing extraprostatic extension when carcinoma was present within a fibrous band bulging beyond the prostate parenchyma. Further, the survey indicated only moderate support for the idea that there is no reliable method to diagnose extraprostatic extension in sections from the apical margin. A clear majority of the respondents noted that they stratify the extent of extraprostatic extension as being focal/minimal or established/extensive. There was, however, no clear consensus as to

the method of stratification, with 38% of respondents using the subjective criteria of Epstein⁴³ to identify focal or established extraprostatic extension. Another 29% indicated that their definitions of focal or established extraprostatic extension were purely subjective. Only 11% used the single high-power field method of Wheeler *et al*⁴⁴ and 24% of respondents measured the depth or radial distance of extraprostatic extension as suggested by Sung *et al*.⁴⁹ In cases in which extraprostatic extension is present, 97% respondents indicated that they reported the location and 78% reported the number of sites of extraprostatic extension, despite an apparent lack of clinical significance for the data.

Results of consensus meeting on extraprostatic extension

During the consensus meeting, 93 and 82% of the voting delegates agreed that in the absence of fat involvement, extraprostatic extension can be identified (posterolaterally) when cancer bulges beyond the contour of the gland or beyond the condensed smooth muscle of the prostate, respectively (Table 1). Scanning magnification should be used to look for a protuberance of tumor from the normal smooth contour of the prostate, followed by higher magnification to confirm the absence of condensed smooth muscle in the desmoplastic stroma. The apex and anterior aspects of the prostate remain problematic areas. In all, 62% of the pathologists who took the survey thought that there is not a reliable landmark at the apical margin of the prostate that can be used to definitively establish the presence of EPE at this site. However, 87% of the voting delegates agreed that extraprostatic extension can be identified anteriorly. Consensus was not achieved as to whether the diagnostic option of indeterminate for extraprostatic extension should be available in staging schemes. An overwhelming majority of the delegates supported the suggestion that extraprostatic extension should be quantitated. However, the delegates could not agree on what specific method should be used to classify extraprostatic extension as focal. The methods described by Wheeler and Epstein were supported by 13 and 20%, respectively. Subjective assessment, including these two methods, was used by 61% of delegates, whereas 41% used a quantitative assessment, such as the radial extent of extraprostatic extension in millimeters. Two delegates used both subjective and quantitative methods.

Pathologists faced with heavy workloads need to identify a method for quantifying extraprostatic extension that is practical and has at least some element of objectivity. On the basis of the survey, pathologists appear to prefer the subjective approach suggested by either Epstein *et al*⁴³ or Wheeler *et al*⁴⁴ over quantitative methods, and a slightly higher number of delegates seem to prefer Epstein's method over Wheeler's. It was agreed that any approach should have clinical relevance and would require validation by at least one large multicenter study, perhaps involving the

Table 1 Comparison of survey results with consensus conference results

	Survey results		Consensus conference results		
	Survey number responding	Survey %	CC number responding	CC %	
Stratify EPE in focal vs established	155	91	NA	NA	Consensus
Definition of focal EPE	143	55	NA	NA	No consensus
Tumor adjacent or invading adipose tissue is diagnostic of EPE	154	90	NA	NA	Consensus
EPE when tumor is within a fibrous band beyond the prostate parenchyma	151	62	108	93	Consensus
EPE when tumor is beyond condensed smooth muscle	NA	NA	107	82	Consensus
EPE cannot be definitively diagnosed at the apical margin (no reliable landmark)	153	62	NA	NA	No consensus
EPE can be identified anteriorly	NA	NA	105	87	Consensus
Report EPE location	155	97	108	97	Consensus
EPE should be quantitated	NA	NA	110	94	Consensus
Subjective assessment of EPE	NA	NA	103	61	No consensus
Quantitative assessment of EPE	NA	NA	103	41	No consensus
Report depth of maximum EPE	156	76	NA	NA	Consensus
Report number of sites involved by EPE	156	78	NA	NA	Consensus
Indeterminate for EPE option	NA	NA	107	63	No consensus
Record BNI in report	157	87	NA	NA	Consensus
Distinction of BNI in detrusor muscle vs tumor intermixed with benign glands	155	57	NA	NA	No consensus
<i>Method used to distinguish BNI in detrusor muscle vs tumor intermixed with benign glands</i>	94	—	NA	NA	No consensus
Microscopic involvement of detrusor muscle is equivalent to pT3	—	37	—	—	—
Microscopic involvement of detrusor muscle is equivalent to pT4	—	23	—	—	—
Cancer intermixed with benign glands is equivalent to capsular incision (no impact on stage)	—	32	—	—	—
Others	—	7	—	—	—
<i>BNI as pT3</i>	90	—	NA	NA	No consensus
pT3	—	30	—	—	—
pT3a	—	42	—	—	—
pT3b	—	7	—	—	—
Other	—	21	—	—	—
BNI (within thick muscle bundle) as pT3a	NA	NA	106	92	Consensus
Report extent of BNI	154	50	NA	NA	No consensus
<i>Method used to report extent of BNI</i>	80	—	—	—	—
Measure in mm	—	16	—	—	—
Subjective (focal vs extensive)	—	81	NA	NA	Consensus
Mention if tumor is at ink at BN	155	77	107	83	Consensus
Tumor in lymphatic space adjacent to node = negative lymph node	157	59	NA	NA	No consensus
Tumor present only within endothelial lined spaces in the muscular wall of seminal vesicles = pT3b	151	55	106	56	No consensus
LVI reported on H&E	NA	NA	106	93	Consensus
Rectal involvement by prostate cancer as pT4	156	89	NA	NA	Consensus

Abbreviations: BN, bladder neck; BNI, microscopic bladder neck invasion; CC, consensus conference; EPE, extraprostatic extension; LVI, lymphovascular invasion; NA, not asked, so does not apply. The entries in bold represent issues for which a consensus was reached.

simultaneous evaluation of a number of methods, although this was not specifically voted upon.

Microscopic Bladder Neck Invasion

In the 2002 AJCC TNM staging system, bladder neck invasion was designated as pT4 disease, whereas in the 2009 TNM scheme, microscopic bladder neck invasion was categorized as pT3a cancer.^{7,51,52} In the past, prostate cancer with bladder neck invasion was considered as advanced disease, similar to external sphincter and/or rectal involvement,^{53–55}

based on the concept that tumors that invade surrounding structures are more aggressive and warrant higher staging than tumors that do not invade surrounding structures.⁷ Considering that bladder neck-sparing techniques have been implemented in radical prostatectomy to improve postoperative urinary continence and that clinical stage pT4 prostate cancer is rarely treated surgically, this outdated staging system was based upon the finding of gross invasion of the bladder neck or external sphincter.

Currently most instances of bladder neck invasion are detected through the incidental finding of tumor

cells among smooth muscle bundles of the bladder neck,¹⁰ and the prognosis of this subset of patients seems to be different from that of men with rectal or striated sphincter muscle invasion. The latest College of American Pathologists practice protocol specifically states that 'microscopic involvement of bladder neck muscle fibers indicates pT3a disease.'²⁶ For categorization as pT4, gross invasion of the bladder neck is required.

Despite this dramatic stage migration, bladder neck invasion remains a significant finding, with a prevalence that ranges from 3 to 9% of reported series.⁵³⁻⁶⁰

Most studies^{53,54,58-61} have shown that bladder neck invasion carries a risk of progression similar to extraprostatic extension and lower than that of seminal vesicle invasion. This supports the concept that bladder neck invasion should be considered as pT3a disease, as these studies have shown that the prognosis of patients with bladder neck invasion is no worse than that for those with pT3 disease.^{53-55,57,61-63}

There is controversy as to whether microscopic bladder neck invasion remains an independent histological prognostic factor and predicts disease progression after radical prostatectomy. Some investigators have found that bladder neck invasion is associated with other well-established poor prognostic features such as higher Gleason score and serum PSA, extraprostatic extension, seminal vesicle invasion, positive surgical margins, positive lymph nodes and extensive tumor volume.^{54-57,60} However, in multivariate models, bladder neck invasion was found not to be an independent predictor of PSA recurrence after radical prostatectomy, and prognosis was dependent on other pathological features.

In contrast, Poulos *et al* concluded that bladder neck invasion is an independent predictor of early PSA recurrence in patients undergoing radical prostatectomy,⁵⁹ although it should be noted that this series was hampered by a small number of cases, as well as a short follow-up interval (median 12 months).

The lack of a consistent sampling method for the bladder neck and of a pathological definition of bladder neck invasion in different studies complicates the accurate determination of prognostic significance of microscopic bladder neck invasion.^{57,58,64-66} In most reported studies, the bladder neck was 'coned' from the radical prostatectomy specimen and cut in a perpendicular manner.^{53,59,60} In a few studies, the base margin was taken *en face*, and margin positivity at this site was defined as bladder neck invasion.^{57,62}

Microscopic bladder neck invasion has been defined as the presence of neoplastic cells within the smooth muscle bundles of the coned bladder neck^{59,60} or as the microscopic invasion of the muscular wall of the bladder neck by prostate cancer cells in the absence of benign prostatic glandular tissue in the section⁵³⁻⁵⁵ (Figure 1f).

Yossepowitch *et al*⁵³ compared the prognosis of patients treated by radical prostatectomy, who had bladder neck invasion by tumor, with those with

seminal vesicle invasion. They identified bladder neck invasion in 9% of their 286 cases and concluded that this carries a lower risk of progression than seminal vesicle invasion, although the study was limited by a small number of patients. Subsequently, the same group studied a larger cohort of patients (2571 radical prostatectomies) and detected bladder neck invasion in 3% of the cases. The authors also found that bladder neck invasion constituted a heterogeneous group of tumors with different pathological features and inconsistent outcome, and showed that, in a multivariate model, the finding of bladder neck invasion did not independently predict PSA recurrence.⁵⁴

Dash *et al* found bladder neck invasion, defined as margin positivity at the basal margin of the prostate taken *en face*, in 5% of 1123 men with clinically localized prostate cancer, treated by radical prostatectomy. The authors found a marked difference, on univariate analysis, in the PSA-recurrence rates for focal *versus* extensive invasion of the bladder neck margin, although they admitted that the distinction between focal and extensive was subjected to interpretation. However, in a multivariate model, the PSA recurrence risk with bladder neck invasion was not a significant independent prognostic factor.⁵⁷

In a recent multicenter study of 1722 men treated with radical prostatectomy, Buschemeyer *et al*⁵⁶ found a positive bladder neck margin in 5% of patients and this was associated with other poor prognostic features. When associated with other positive margins, a positive bladder neck margin had a risk of progression similar to that of seminal vesicle invasion (pT3b). Although men with an isolated bladder neck margin were reported to have a more favorable pathological profile, there were too few cases in the series to reliably assess outcome.

Microscopic bladder neck invasion was detected in 90 (5%) specimens included in a study by Zhou *et al*,⁶⁰ and in approximately half of the cases there was a positive surgical margin at the bladder neck. In 53% of the cases with bladder neck invasion, the prostate cancer predominantly involved the anterior zone. The radical prostatectomy specimens of patients with bladder neck invasion, defined as the presence of neoplastic cells within the coned bladder neck, were subcategorized into those with true bladder neck (70%) and false bladder neck (30%) invasion. The presence of malignant glands within thick smooth muscle bundles characteristic of the bladder neck, in the absence of intermixed benign prostatic glandular tissue, was considered true bladder neck invasion. In contrast, cases with malignant glands intermixed with benign prostatic glands were interpreted as surgical incision into the prostate gland close to the bladder neck and therefore regarded as false-positive bladder neck invasion. Univariate analysis indicated that both true bladder neck invasion and false-positive bladder neck invasion was significantly associated with an increased PSA-recurrence risk. However, in

a multivariate model, controlling for initial PSA, extraprostatic extension, seminal vesicle invasion, lymph node involvement, Gleason score, tumor volume, and positive surgical margin, bladder neck invasion was found not to be a significant independent prognostic factor.

Results of ISUP survey on microscopic bladder neck invasion

The respondents reached consensus on reporting microscopic prostate cancer invasion of the bladder neck in radical prostatectomy specimens (Table 1). However, only 57% distinguished between microscopic invasion of the detrusor muscle by prostate cancer and prostate cancer intermixed with benign prostatic glands at the bladder neck, and 37% and 23% considered microscopic invasion of the detrusor muscle by prostate cancer to be equivalent to pT3 or to pT4 stage, respectively. One-third (32%) of respondents considered prostate cancer intermixed with benign prostatic glands at the bladder neck to be equivalent to prostatic incision, with no impact on stage. When asked how they reported microscopic invasion of bladder neck by prostate cancer, 42% of the participants responded as pT3a, 30% as pT3, and 7% as pT3b. Only half of the pathologists reported the extent of microscopic invasion of the bladder neck; 81% distinguished between focal and extensive invasion and 16% measured the extent in millimeters. Two respondents (2%) used other methods. Of the survey respondents, 77% stated that they would record the presence of prostate cancer at the inked margin in sections from the bladder neck, and considered this to be a positive margin.

Results of ISUP consensus meeting on microscopic bladder neck invasion

During the meeting, there was consensus that tumor involving the bladder neck, specifically

defined as neoplastic cells within thick smooth muscle bundles, should be reported as pT3a (Table 1). The presence of prostate cancer glands intermixed with benign prostatic glands at the bladder neck was considered equivalent to capsular incision. It was recommended that, in accordance with the 2009 TNM system,³⁹ if tumor is present at the inked resection margin at the bladder neck, this should be stated in the report. There was consensus that the locations of positive margins should be noted as occurring on the left or right and posterior, posterolateral, lateral, anterior at either the apex, mid or base (or bladder neck).²⁵

Lymphovascular Invasion

Lymphovascular invasion has been defined as the unequivocal presence of tumor cells within endothelial-lined spaces with no underlying muscular walls^{12,15,18,19} or as the presence of tumor emboli in small intraprostatic vessels¹⁴ (Figure 2a), as most reports have suggested a predilection of tumor emboli for small vessels defined by their endothelial lining but with little or no underlying muscular wall.¹⁶

In many studies, except two,^{17,67} no attempt has been made to distinguish between lymphatic and vascular channels because of the difficulties of differentiating between them on routine light microscopic examination^{12,14,17–19} and as, for practical purposes, either lymphatic or venous involvement implies ultimate reach of tumor to the circulatory system.¹⁰

If lymphovascular invasion is equivocal or tumor cells merely encroach on a vascular space, the finding is considered negative for lymphovascular invasion by most authors.^{13,15,16,18} Particular care should be taken to exclude artifacts due to retraction or mechanical displacement of tumor cells into a

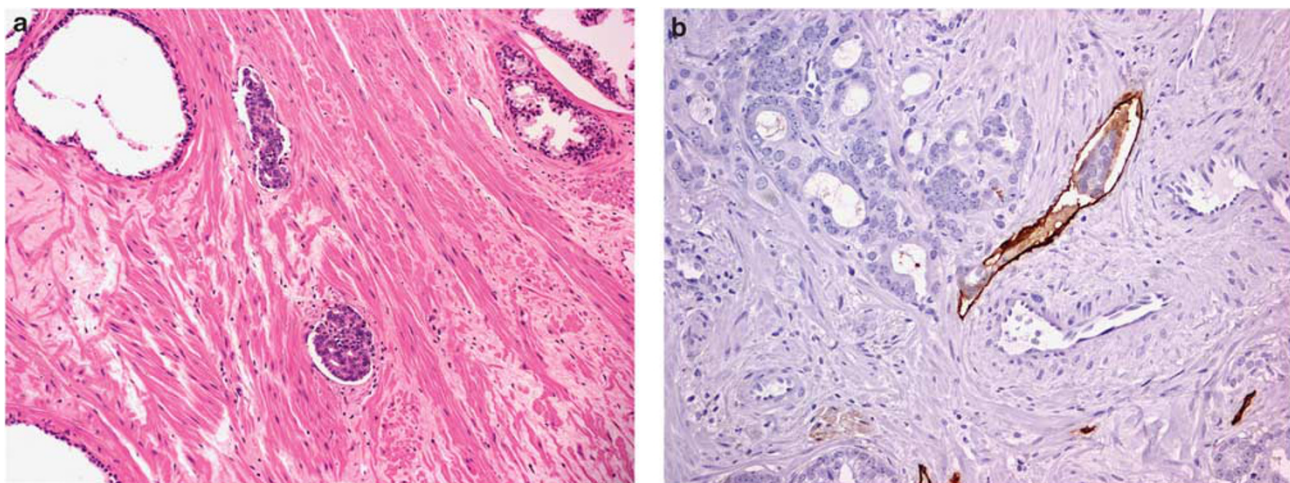


Figure 2 (a) Unequivocal presence of tumor cells within small endothelial-lined intraprostatic vessels with no underlying muscular walls. (b) Cluster of malignant prostatic glands with associated lymphovascular invasion highlighted with D2-40 (podoplanin) immunostaining.

lumen by the scalpel blade (pseudoemboli), tumor within prostatic ducts and tumor within perineural spaces.^{11,13,15}

Although lymphovascular invasion is commonly reported on routine examination (H&E), immunoperoxidase staining using antibody to CD31 (pan-endothelial marker) or CD34 (blood vessel endothelial marker) has been used by some authors to identify the presence of endothelium, either in equivocal cases of lymphovascular invasion¹¹ or in cases with foci of lymphovascular invasion identified on routine stains.^{15,16} D2-40 (podoplanin) immunostaining (Figure 2b) has been utilized to evaluate the distribution of lymphatic vessels in the prostate, and the presence of peritumoral lymphatic vessels invasion was found significantly associated with regional lymph node metastases.^{68,69} To determine how angiogenesis correlated with metastasis in prostate carcinoma, Weidner *et al* counted microvessels, highlighted by immunostaining of endothelial cells by factor VIII antigen, and reported that the mean microvessel count in tumors from patients with metastases was significantly higher than that for patients without metastasis.⁷⁰

The location and the number of tumor emboli have been recorded by some authors. Herman *et al* evaluated the presence of lymphovascular invasion within the prostatic parenchyma, the ejaculatory duct complex, the prostatic capsule, periprostatic fat or seminal vesicles, and found that in approximately half (53%) of the cases lymphovascular invasion occurred outside the prostatic stroma.¹³ Baydar *et al* classified lymphovascular invasion as intratumoral (55%), at the periphery of the tumor (18%), both intra- and peritumoral (9%) and at a distant site from the tumor (18%).¹¹ The number of foci of lymphovascular invasion in each case has been shown to range from 1 to 40, with the majority of patients having 1 or 2 foci.^{11,13,71}

Lymphovascular invasion has been reported to be associated with adverse pathological features in radical prostatectomy specimens,⁶ such as higher Gleason score, positive surgical margins, extraprostatic extension and seminal vesicle invasion,^{12,16,18,72–75} and with decreased time to biochemical progression,^{13,16,18,19,72} distant metastases^{8,19} and overall survival after radical prostatectomy.^{18,19,67} Univariate analyses showed lymphovascular invasion to be a significant predictor of disease recurrence and/or progression following radical prostatectomy,^{12,15,17,72–75} and multivariate analyses have confirmed that lymphovascular invasion is an independent predictor of disease recurrence, when controlling for other pathological variables known to influence clinical outcome.^{13,15,16,72–74}

However, most studies on lymphovascular invasion included a substantial number of patients with lymph node metastasis and/or seminal vesicle invasion^{12,13,16–19,71} and failed to stratify patients into clinicopathologically meaningful categories.⁷⁶ The strong negative impact of lymph node metastasis

and seminal vesicle invasion on PSA recurrence, and the different risk of PSA failure between patients with organ confined disease (pT2N0) and those with pT3aN0 disease might have obscured the true impact of lymphovascular invasion on the outcome of patients with pT3aN0 tumors.

Recently, the incidence of lymphovascular invasion in prostate cancer patients with pT3aN0 disease was found to range between 28% and 35%.^{13,20} On univariate analysis, lymphovascular invasion was associated with a higher preoperative PSA and Gleason score in the prostatectomy specimen, but not with surgical margin status, biopsy Gleason score or clinical stage. In a multivariate analysis, preoperative PSA and lymphovascular invasion were identified as the only significant and independent predictors of PSA failure. When pT3aN0 prostate cancer patients were followed up without any treatment after radical prostatectomy, lymphovascular invasion was a significant and independent predictor of PSA failure and cancer progression. The 5-year PSA failure-free survival rate in patients with no lymphovascular invasion and PSA ≤ 10 ng/ml could be as high as 93.5%, suggesting that adjuvant therapy would not be indicated for this subset of patients. On the other hand, pT3aN0 patients with lymphovascular invasion had a poor prognosis, even when preoperative PSA was < 10 ng/ml. In the study by May *et al*¹⁵ on node-negative prostate cancer patients treated by radical prostatectomy, lymphovascular invasion and Gleason score were independent predictors of biochemical failure, by multivariate analysis. The 5-year biochemical-free survival was 87.3% and 38.3% for patients without and with evidence of lymphovascular invasion in the radical prostatectomy specimen, respectively ($P < 0.001$).

Results of ISUP survey and consensus meeting on lymphovascular invasion

Half of the survey respondents considered tumor present only within endothelial-lined spaces in the muscular wall of the seminal vesicles as pT3b. However, 59% of the participants at the consensus conference reported the presence of tumor in a lymphatic space adjacent to a lymph node as a negative lymph node with a specific comment. There was consensus that lymphovascular invasion should be reported in the routine examination of radical prostatectomy specimens.

Invasion of Rectum, Urinary Bladder, External Sphincter, Levator Muscles and/or Pelvic Wall: pT4

pT4 prostate cancer is defined as direct invasion of rectum or gross invasion of urinary bladder, external sphincter, levator muscles and/or pelvic wall, with or without fixation. Although patients with large bulky masses involving these structures are not typically candidates for radical prostatectomy, it is

possible to assign a pT4 category to a radical prostatectomy specimen in the uncommon case in which there is an accompanying biopsy with prostatic carcinoma in one of these sites. As noted above, microscopic invasion of the urinary bladder neck by prostatic carcinoma is considered to be pT3a disease.

The posteriorly located Denonvilliers' fascia constitutes an effective barrier for the spread of tumor into the rectum.⁷⁷ Rectal involvement is now a clinically rare, late event for prostate cancer and is usually associated with widespread metastatic disease. Involvement of the rectum by prostate cancer can produce symptoms and signs similar to those of colon cancer, such as constipation, rectal stenosis, abdominal pain, rectal bleeding and intermittent diarrhea.^{78–81} A possible prostatic origin for a colonic mass should be entertained when histological features such as the lack of an *in situ* component, an extrinsic pattern of involvement, microacinar or solid architecture and/or prominent nucleoli are noted, especially in the absence of nuclear pleomorphism and mitotic activity.⁸²

Large, bulky pT4 prostate cancers can directly invade the urinary bladder, and produce bladder neck obstruction and ureteral obstruction. Ureteral obstruction is present in 2–10% of patients with extensive local spread, and can cause symptoms related to renal failure and uremia.⁷⁸ Urinary bladder invasion by prostatic carcinoma can also occur via lymphovascular invasion, without contiguous spread.⁸³

Results of ISUP survey and consensus meeting on pT4 disease

A consensus in the survey considered direct rectal involvement by prostatic carcinoma to be pT4; 4% of the respondents to the survey would not stage the tumor and 1% would classify rectal involvement as M1 (Table 1).

At the consensus conference there was universal agreement, although this was not specifically voted upon, that a pT4 category be assigned to a radical prostatectomy specimen if an associated biopsy of urinary bladder (that is not microscopic invasion of bladder neck), rectum or pelvic side wall is positive. It was further stipulated that the prostate carcinoma should directly invade these structures, as assessed by clinical and/or radiological means.

Disclosure/conflict of interest

The authors declare no conflict of interest.

References

1 Epstein JI, Pound CR, Partin AW, *et al*. Disease progression following radical prostatectomy in men with Gleason score 7 tumor. *J Urol* 1998;160:97–100.

- 2 Hull GW, Rabbani F, Abbas F, *et al*. Cancer control with radical prostatectomy alone in 1,000 consecutive patients. *J Urol* 2002;167:528–534.
- 3 Kattan MW, Wheeler TM, Scardino PT. Postoperative nomogram for disease recurrence after radical prostatectomy for prostate cancer. *J Clin Oncol* 1999;17:1499–1507.
- 4 Kausik SJ, Blute ML, Sebo TJ, *et al*. Prognostic significance of positive surgical margins in patients with extraprostatic carcinoma after radical prostatectomy. *Cancer* 2002;95:1215–1219.
- 5 Swindle P, Eastham JA, Ohori M, *et al*. Do margins matter? The prognostic significance of positive surgical margins in radical prostatectomy specimens. *J Urol* 2005;174:903–907.
- 6 Evans AJ, Henry PC, Van der Kwast TH, *et al*. Interobserver variability between expert urologic pathologists for extraprostatic extension and surgical margin status in radical prostatectomy specimens. *Am J Surg Pathol* 2008;32:1503–1512.
- 7 Greene FL. The American Joint Committee on Cancer: updating the strategies in cancer staging. *Bull Am Coll Surg* 2002;87:13–15.
- 8 Srigley JR, Amin MB, Epstein JI, *et al*. Updated protocol for the examination of specimens from patients with carcinomas of the prostate gland. *Arch Pathol Lab Med* 2006;130:936–946.
- 9 Amin MB, Grignon D, Bostwick D, *et al*. Recommendations for the reporting of resected prostate carcinomas. Association of Directors of Anatomic and Surgical Pathology. *Am J Clin Pathol* 1996;105:667–670.
- 10 Epstein JI, Srigley J, Grignon D, *et al*. Recommendations for the reporting of prostate carcinoma: Association of Directors of Anatomic and Surgical Pathology. *Am J Clin Pathol* 2008;129:24–30.
- 11 Baydar DE, Baseskioglu B, Ozen H, *et al*. Prognostic significance of lymphovascular invasion in clinically localized prostate cancer after radical prostatectomy. *ScientificWorld Journal* 2008;8:303–312.
- 12 Cheng L, Jones TD, Lin H, *et al*. Lymphovascular invasion is an independent prognostic factor in prostatic adenocarcinoma. *J Urol* 2005;174:2181–2185.
- 13 Herman CM, Wilcox GE, Kattan MW, *et al*. Lymphovascular invasion as a predictor of disease progression in prostate cancer. *Am J Surg Pathol* 2000;24:859–863.
- 14 Loeb S, Roehl KA, Yu X, *et al*. Lymphovascular invasion in radical prostatectomy specimens: prediction of adverse pathologic features and biochemical progression. *Urology* 2006;68:99–103.
- 15 May M, Kaufmann O, Hammermann F, *et al*. Prognostic impact of lymphovascular invasion in radical prostatectomy specimens. *BJU Int* 2007;99:539–544.
- 16 McNeal JE, Yemoto CE. Significance of demonstrable vascular space invasion for the progression of prostatic adenocarcinoma. *Am J Surg Pathol* 1996;20:1351–1360.
- 17 Salomao DR, Graham SD, Bostwick DG. Microvascular invasion in prostate cancer correlates with pathologic stage. *Arch Pathol Lab Med* 1995;119:1050–1054.
- 18 Shariat SF, Khoddami SM, Saboorian H, *et al*. Lymphovascular invasion is a pathological feature of biologically aggressive disease in patients treated with radical prostatectomy. *J Urol* 2004;171:1122–1127.
- 19 van den Ouden D, Kranse R, Hop WC, *et al*. Microvascular invasion in prostate cancer: prognostic significance in patients treated by radical prostatectomy for clinically localized carcinoma. *Urol Int* 1998;60:17–24.

- 20 Yamamoto S, Kawakami S, Yonese J, *et al*. Lymphovascular invasion is an independent predictor of prostate-specific antigen failure after radical prostatectomy in patients with pT3aN0 prostate cancer. *Int J Urol* 2008;15:895–899.
- 21 Egevad L, Srigley JR, Delahunt B. International Society of Urological Pathology (ISUP) Consensus Conference on Handling and Staging of Radical Prostatectomy Specimens: rationale and organization. *Mod Pathol* 2011;24:1–5 (this issue).
- 22 Samaratunga H, Montironi R, True LD, *et al*. International Society of Urological Pathologists (ISUP) Consensus Conference on Handling and Staging of Radical Prostatectomy Specimens. Working group 1: specimen handling. *Mod Pathol* 2011;24:6–15 (this issue).
- 23 van der Kwast TH, Amin MB, Billis A, *et al*. International Society of Urological Pathology (ISUP) Consensus Conference on Handling and Staging of Radical Prostatectomy specimens. Working group 2: T2 substaging and prostate cancer volume. *Mod Pathol* 2011;24:16–25 (this issue).
- 24 Berney D, Wheeler TM, Grignon DJ, *et al*. International Society of Urological Pathology (ISUP) Consensus Conference on Handling and Staging of Radical Prostatectomy Specimens. Working group 4: seminal vesicles and lymph nodes. *Mod Pathol* 2011;24:39–47 (this issue).
- 25 Tan PH, Cheng L, Srigley JR, *et al*. International Society of Urological Pathology (ISUP): Consensus Conference on Handling and Staging of Radical Prostatectomy Specimens. Working group 5: surgical margins. *Mod Pathol* 2011;24:48–57 (this issue).
- 26 Srigley JR, Humphrey PA, Amin MB, *et al*. Protocol for the examination of specimens from patients with carcinoma of the prostate gland. *Arch Pathol Lab Med* 2009;133:1568–1576.
- 27 Kench J, Clouston D, Delahunt B, *et al*. Royal College of Pathologists of Australasia ProstateCancer (Radical Prostatectomy) Structured Reporting Protocol. 2010, pp 54; <http://www.rcpa.edu.au/Publications/StructuredReporting/CancerProtocols.htm>.
- 28 Srigley JR. Key issues in handling and reporting radical prostatectomy specimens. *Arch Pathol Lab Med* 2006;130:303–317.
- 29 Epstein JI, Amin M, Boccon-Gibod L, *et al*. Prognostic factors and reporting of prostate carcinoma in radical prostatectomy and pelvic lymphadenectomy specimens. *Scand J Urol Nephrol Suppl* 2005;216:34–63.
- 30 Ayala AG, Ro JY, Babaian R, *et al*. The prostatic capsule: does it exist? Its importance in the staging and treatment of prostatic carcinoma. *Am J Surg Pathol* 1989;13:21–27.
- 31 Chuang AY, Epstein JI. Positive surgical margins in areas of capsular incision in otherwise organ-confined disease at radical prostatectomy: histologic features and pitfalls. *Am J Surg Pathol* 2008;32:1201–1206.
- 32 Cohen RG, Stables S. Intraprostatic fat. *Hum Pathol* 1998;29:424–425.
- 33 Sung MT, Eble JN, Cheng L. Invasion of fat justifies assignment of stage pT3a in prostatic adenocarcinoma. *Pathology* 2006;38:309–311.
- 34 Ekici S, Ayhan A, Erkan I, *et al*. The role of the pathologist in the evaluation of radical prostatectomy specimens. *Scand J Urol Nephrol* 2003;37:387–391.
- 35 van der Kwast TH, Collette L, Van Poppel H, *et al*. Impact of pathology review of stage and margin status of radical prostatectomy specimens (EORTC trial 22911). *Virchows Arch* 2006;449:428–434.
- 36 Allsbrook Jr WC, Mangold KA, Johnson MH, *et al*. Interobserver reproducibility of Gleason grading of prostatic carcinoma: urologic pathologists. *Hum Pathol* 2001;32:74–80.
- 37 Allsbrook Jr WC, Mangold KA, Johnson MH, *et al*. Interobserver reproducibility of Gleason grading of prostatic carcinoma: general pathologist. *Hum Pathol* 2001;32:81–88.
- 38 Glaessgen A, Hamberg H, Pihl CG, *et al*. Interobserver reproducibility of modified Gleason score in radical prostatectomy specimens. *Virchows Arch* 2004;445:17–21.
- 39 Ohori M, Wheeler TM, Kattan MW, *et al*. Prognostic significance of positive surgical margins in radical prostatectomy specimens. *J Urol* 1995;154:1818–1824.
- 40 May F, Hartung R, Breul J. The ability of the American Joint Committee on Cancer Staging system to predict progression-free survival after radical prostatectomy. *BJU Int* 2001;88:702–707.
- 41 Sakr WA, Wheeler TM, Blute M, *et al*. Staging and reporting of prostate cancer—sampling of the radical prostatectomy specimen. *Cancer* 1996;78:366–368.
- 42 Zagars GK, Geara FB, Pollack A, *et al*. The T classification of clinically localized prostate cancer. An appraisal based on disease outcome after radiation therapy. *Cancer* 1994;73:1904–1912.
- 43 Epstein JI, Carmichael MJ, Pizov G, *et al*. Influence of capsular penetration on progression following radical prostatectomy: a study of 196 cases with long-term follow-up. *J Urol* 1993;150:135–141.
- 44 Wheeler TM, Dillioglulig O, Kattan MW, *et al*. Clinical and pathological significance of the level and extent of capsular invasion in clinical stage T1-2 prostate cancer. *Hum Pathol* 1998;29:856–862.
- 45 Davis BJ, Pisansky TM, Wilson TM, *et al*. The radial distance of extraprostatic extension of prostate carcinoma: implications for prostate brachytherapy. *Cancer* 1999;85:2630–2637.
- 46 McNeal JE, Villers AA, Redwine EA, *et al*. Capsular penetration in prostate cancer. Significance for natural history and treatment. *Am J Surg Pathol* 1990;14:240–247.
- 47 Sohayda C, Kupelian PA, Levin HS, *et al*. Extent of extracapsular extension in localized prostate cancer. *Urology* 2000;55:382–386.
- 48 Stamey TA, McNeal JE, Freiha FS, *et al*. Morphometric and clinical studies on 68 consecutive radical prostatectomies. *J Urol* 1988;139:1235–1241.
- 49 Sung MT, Lin H, Koch MO, *et al*. Radial distance of extraprostatic extension measured by ocular micrometer is an independent predictor of prostate-specific antigen recurrence: a new proposal for the substaging of pT3a prostate cancer. *Am J Surg Pathol* 2007;31:311–318.
- 50 Villers A, McNeal JE, Redwine EA, *et al*. The role of perineural space invasion in the local spread of prostatic adenocarcinoma. *J Urol* 1989;142:763–768.
- 51 Ohori M, Wheeler TM, Scardino PT. The New American Joint Committee on Cancer and International Union Against Cancer TNM classification of prostate cancer. Clinicopathologic correlations. *Cancer* 1994;74:104–114.
- 52 Edge SB, Byrd DR, Carducci M, *et al*. (eds). *AJCC Cancer Staging Manual* 7th edn. Springer: New York, NY, 2009.
- 53 Yossepowitch O, Engelstein D, Konichezky M, *et al*. Bladder neck involvement at radical prostatectomy:

- positive margins or advanced T4 disease? *Urology* 2000;56:448–452.
- 54 Yossepowitch O, Sircar K, Scardino PT, *et al*. Bladder neck involvement in pathological stage pT4 radical prostatectomy specimens is not an independent prognostic factor. *J Urol* 2002;168:2011–2015.
- 55 Rodriguez-Covarrubias F, Larre S, Dahan M, *et al*. Invasion of bladder neck after radical prostatectomy: one definition for different outcomes. *Prostate Cancer Prostatic Dis* 2008;11:294–297.
- 56 Buschemeyer 3rd WC, Hamilton RJ, Aronson WJ, *et al*. Is a positive bladder neck margin truly a T4 lesion in the prostate specific antigen era? Results from the SEARCH Database. *J Urol* 2008;179:124–129.
- 57 Dash A, Sanda MG, Yu M, *et al*. Prostate cancer involving the bladder neck: recurrence-free survival and implications for AJCC staging modification. American Joint Committee on Cancer. *Urology* 2002;60:276–280.
- 58 Obek C, Sadek S, Lai S, *et al*. Positive surgical margins with radical retropubic prostatectomy: anatomic site-specific pathologic analysis and impact on prognosis. *Urology* 1999;54:682–688.
- 59 Poulos CK, Koch MO, Eble JN, *et al*. Bladder neck invasion is an independent predictor of prostate-specific antigen recurrence. *Cancer* 2004;101:1563–1568.
- 60 Zhou M, Reuther AM, Levin HS, *et al*. Microscopic bladder neck involvement by prostate carcinoma in radical prostatectomy specimens is not a significant independent prognostic factor. *Mod Pathol* 2009;22:385–392.
- 61 Billis A, Freitas LL, Magna LA, *et al*. Prostate cancer with bladder neck involvement: pathologic findings with application of a new practical method for tumor extent evaluation and recurrence-free survival after radical prostatectomy. *Int Urol Nephrol* 2004;36:363–368.
- 62 Aydin H, Tsuzuki T, Hernandez D, *et al*. Positive proximal (bladder neck) margin at radical prostatectomy confers greater risk of biochemical progression. *Urology* 2004;64:551–555.
- 63 Ruano T, Meirelles L, Freitas LL, *et al*. The significance of microscopic bladder neck invasion in radical prostatectomies: pT4 disease? *Int Urol Nephrol* 2009;41:71–76.
- 64 Blute ML, Bostwick DG, Bergstralh EJ, *et al*. Anatomic site-specific positive margins in organ-confined prostate cancer and its impact on outcome after radical prostatectomy. *Urology* 1997;50:733–739.
- 65 Grossfeld GD, Chang JJ, Broering JM, *et al*. Impact of positive surgical margins on prostate cancer recurrence and the use of secondary cancer treatment: data from the CaPSURE database. *J Urol* 2000;163:1171–1177.
- 66 Shekarriz B, Tiguert R, Upadhyay J, *et al*. Impact of location and multifocality of positive surgical margins on disease-free survival following radical prostatectomy: a comparison between African-American and white men. *Urology* 2000;55:899–903.
- 67 Bahnson RR, Dresner SM, Gooding W, *et al*. Incidence and prognostic significance of lymphatic and vascular invasion in radical prostatectomy specimens. *Prostate* 1989;15:149–155.
- 68 Roma AA, Magi-Galluzzi C, Kral MA, *et al*. Peritumoral lymphatic invasion is associated with regional lymph node metastases in prostate adenocarcinoma. *Mod Pathol* 2006;19:392–398.
- 69 Zeng Y, Opeskin K, Horvath LG, *et al*. Lymphatic vessel density and lymph node metastasis in prostate cancer. *Prostate* 2005;65:222–230.
- 70 Weidner N, Carroll PR, Flax J, *et al*. Tumor angiogenesis correlates with metastasis in invasive prostate carcinoma. *Am J Pathol* 1993;143:401–409.
- 71 Ferrari MK, McNeal JE, Malhotra SM, *et al*. Vascular invasion predicts recurrence after radical prostatectomy: stratification of risk based on pathologic variables. *Urology* 2004;64:749–753.
- 72 de la Taille A, Rubin MA, Buttyan R, *et al*. Is microvascular invasion on radical prostatectomy specimens a useful predictor of PSA recurrence for prostate cancer patients? *Eur Urol* 2000;38:79–84.
- 73 Ito K, Nakashima J, Mukai M, *et al*. Prognostic implication of microvascular invasion in biochemical failure in patients treated with radical prostatectomy. *Urol Int* 2003;70:297–302.
- 74 Babaian RJ, Troncoso P, Bhadkamkar VA, *et al*. Analysis of clinicopathologic factors predicting outcome after radical prostatectomy. *Cancer* 2001;91:1414–1422.
- 75 Epstein JI, Partin AW, Potter SR, *et al*. Adenocarcinoma of the prostate invading the seminal vesicle: prognostic stratification based on pathologic parameters. *Urology* 2000;56:283–288.
- 76 Fine SW, Reuter VE. What is the prognostic significance of lymphovascular invasion in radical prostatectomy specimens? *Nat Clin Pract Urol* 2007;4:128–129.
- 77 Villers A, McNeal JE, Freiha FS, *et al*. Invasion of Denonvilliers' fascia in radical prostatectomy specimens. *J Urol* 1993;149:793–798.
- 78 Kim ED, Grayhack JT. Clinical symptoms and signs of prostate cancer. *Comprehensive Textbook of Genitourinary Oncology*. Vogelzang NJ, Scardino PT, Shipley WU (eds). Williams & Wilkins: Baltimore, 1996.
- 79 Hoffman JR, Firoozmand E, Luthringer DJ, *et al*. Carcinoma of the prostate with aggressive rectal invasion. *Am Surg* 2009;75:434–436.
- 80 Foster MC, O'Reilly PH. Carcinoma of the prostate masquerading as rectal carcinoma. Report of 3 cases and review of the literature. *Br J Urol* 1990;66:193–195.
- 81 Bowrey DJ, Otter MI, Billings PJ. Rectal infiltration by prostatic adenocarcinoma: report on six patients and review of the literature. *Ann R Coll Surg Engl* 2003;85:382–385.
- 82 Lane Z, Epstein JI, Ayub S, *et al*. Prostatic adenocarcinoma in colorectal biopsy: clinical and pathologic features. *Hum Pathol* 2008;39:543–549.
- 83 Bates AW, Baithun SI. Secondary neoplasms of the bladder are histological mimics of nontransitional cell primary tumours: clinicopathological and histological features of 282 cases. *Histopathology* 2000;36:32–40.

Appendix

The members of The ISUP Prostate Cancer Group are the following:

Adebowale Adeniran, Hikmat Al-Ahmadie, Ferran Algaba, Robert Allan, Mahul Amin, Marc Barry,

Sheldon Bastacky, Dilek Baydar, Louis Bégin, Dan Berney, Athanase Billis, Liliane Boccon-Gibod, David Bostwick, Maria Brito, Tucker Burks, Christer Busch, Philippe Camparo, Liang Cheng, Cynthia Cohen, Milton Datta, Laurence de Leval, Brett Delahunt, Warick Delprado, Lars Egevad, Jonathan

Epstein, Andrew Evans, Sara Falzarano, Samson Fine, Eddie Fridman, Bungo Furusato, Masoud Ganji, Lisa Glantz, Anuradha Gopalan, David Grignon, Rainer Grobholz, Charles Guo, Rekha Gupta, Bora Gurel, Seife Hailemariam, Ardeshir Hakam, Omar Hameed, Donna Hansel, R-Peter Henke, Mehsati Herawi, Michelle Hirsch, Jiaoti Huang, Wei Huang, Christina Hulsbergen van de Kaa, Peter Humphrey, Kenneth Iczkowski, Edward Jones, Michael Jones, Laura Jufe, James Kench, Hyun-Jung Kim, Peter Kragel, Glen Kristiansen, Katia Ramos Moreira Leite, Claudio Daniel Lewin, Josep Lloreta, Antonio Lopez-Beltran, Scott Lucia, Dani el Luthringer, Cristina Magi-Galluzzi, Peter McCue, Teresa McHale, Jesse McKenney, Maria Merino, Rodolfo Montironi,

Gabriella Nesi, George Netto, Esther Oliva, Pedro Oliveira, Adeboye Osunkoya, Gladell Paner, Anil Parwani, Maria Picken, Galina Pizov, Andrew Renshaw, Jae Ro, Stephen Rohan, Ruben Ronchetti, Mark Rubin, Hemamali Samaratunga, Anna Sankila, Alan Schned, Isabell Sesterhenn, Ahmed Shabaik, Rajal Shah, Jonathan Shanks, Steven Shen, Jungweon Shim, Taizo Shiraishi, VO Speights Jr, John Srigley, Ming-Tse Sung, Sueli Suzigan, Hiroyuki Takahashi, Puay Hoon Tan, Bernard Tetu, Satish Tickoo, John Tomaszewski, Patricia Troncoso, Kiril Trpkov, Lawrence True, Toyonori Tsuzuki, Jennifer Turner, Theo van der Kwast, Mark Weiss, Thomas Wheeler, Kirk Wojno, Keith Volmar, Chin-Lee Wu, Jorge Yao, Asli Yilmaz and Jim Zhai.