

Design: Tissue microarrays (TMAs) were constructed from genetically profiled tumors (3 TMAs, n = 149), of which 34 have *TP53* mutations and 20 have *RB1* mutations or deletion. We performed immunohistochemistry for p53 and RB on all TMA slides as well as on full sections from another set of tumors with *TP53* (n = 10) and *RB* (n = 14) mutations. These full sections contained both invasive and non-invasive UC to compare the expression patterns between these 2 components.

Results: From the TMAs, in 34 tumors with known *TP53* mutation, p53 expression was strong and diffuse in 19 (19/34), was completely negative in 10 cases (10/34), and focally/weakly positive in 5. In 20 tumors with known *RB1* mutation, RB expression was completely lost in 17 cases (17/20), and focally/weakly positive in 3 cases. Cases that were *TP53/RB1* wild type exhibited a spectrum of expression but generally none were diffusely and strongly positive for p53 or completely negative for RB. RB expression was lost in both the invasive and non-invasive components in all *RB1* mutated tumors (adjacent normal urothelium and stromal cells retained RB expression). Similarly, in *TP53* mutated tumors, the patterns of expression were similar between the invasive and non-invasive components.

Conclusions: Although *TP53* mutations are well-known to be early events in UC, we demonstrate that *RB1* loss is an early event in the development of urothelial carcinoma. *RB1* mutations result in complete loss of RB expression in overwhelming majority of the cases. *TP53* mutations may result in either diffuse and strong p53 expression or, less frequently, complete loss of expression. Awareness of these patterns of expression may be helpful in assessing the potential role of these markers in patient risk stratification.

1081 Mutational Analysis of Gleason Score 7 Prostate Cancer Using Next Generation Sequencing and Fluorescent In Situ Hybridization

Ming Zhou, Zach Liu, Roberto Zoino, Chrysostomos Chrysostomou, Gaurav Rajoria, Szczepan Klimek, Herber Lepor. New York University, New York, NY; Histopathology Services, Ramsey, NJ.

Background: Prostate cancer (PCa) is a clinically and genetically heterogeneous disease. Understanding the genetic abnormalities is necessary to better determine the risk of disease progression and to identify potential targets for precision therapy. We analyzed the mutational landscape in a cohort of intermediate grade (Gleason score 7) PCa with well characterized clinical follow-up.

Design: 42 cases of GS7 PCa were studied. H&E sections were reviewed to confirm the diagnosis. Representative tumor areas were microdissected. DNA was extracted from the paraffin sections. DNA library was prepared with PCR amplification. Each patient sample was barcoded and loaded for emulsion PCR for clonal amplification. The amplified DNA copies were then sequenced on the Ion torrent PGM. The sequences were analyzed with variant caller software. 19 genes that have been repeatedly shown to be mutated in PCa ("prostate genes" including APC, AR, FAT3, FOXA1, KLK2, KLK3, KLK4, MED12, MUC16, MUC2, MUC4, SCN11A, SPOP, THSD7B, TNXB, TP53, TTN, ZAN and ZNF595) and Ion Torrent HotSpot Cancer panel that contained genes frequently altered in other cancers were sequenced. FISH on paraffin-embedded tumor tissue was performed using commercially available DNA probes for PTEN, ERG, and PIK3CA.

Results: Using FISH to detect ERG/TMPRSS2 translocation and PTEN deletion, 12 (30%), 29 (71%), 7 (18%) and 7 (18%) tumors had alteration involving ERG, PTEN, both genes and none of the genes. One of 37 tumors had PIK3CA amplification while none had AR amplification. None of these changes correlated with PSA recurrence. Using NGS to sequence the "prostate genes", 16 mutations were detected in 15 of 42 tumors, averaging 0.4 mutation per tumor. These mutations involved SPOP gene in 6 tumors, TP53 in 4, MED1 in 2, FoxA1 in 2, AR in 1 and ZAN in 1. One tumor had two mutations, 14 had 1 mutation and remaining 27 had no mutations. Mutations in SPOP correlated marginally with PSA recurrence with PSA recurrence in 0 of 6 tumors with SPOP mutation and in 12 of 31 (39%) tumors with wild type SPOP (p=0.064). Mutation in KIT was detected in 8/43 (19%) tumors. KIT mutation occurred only in PTEN deleted tumors (7/22, 32%), but not in PTEN wild type tumor (0/12, p=0.062).

Conclusions: Gene mutations are rare in GS 7 PCa. SPOP is mutated in 6/42 (15%) of tumors and marginally correlates with PSA recurrence. Chromosomal alterations involving PTEN and ERG are much more frequent. Relationship between PTEN deletion and KIT mutation warrants further investigation.

1082 PD-L1 Protein Expression and PD-L1 Gene Amplification in Urothelial Carcinoma of the Urinary Bladder

Chunlai Zuo, Bhaskar VS Kallakury, Bryan Firestone, Olga Voronel, Christine E Sheehan, Tipu Nazeer, Jeffrey S Ross. Albany Medical College, Albany, NY; Georgetown University Hospital, Washington, DC.

Background: Urothelial carcinoma (UCB) is the most common primary neoplasm of the urinary bladder. PD-L1 (programmed death-ligand 1), a 40kDa type I transmembrane protein, expression has been linked to enhanced response to the checkpoint inhibitor atezolizumab in UCB, but has not been evaluated as a prognostic factor for the disease.

Design: Formalin-fixed paraffin-embedded tissue sections from 63 UCB were immunostained by an automated method utilizing rabbit monoclonal PD-L1/CD274 (Spring Bioscience, clone SP142) and ultraView DAB detection (Roche/Ventana, Tucson AZ). Membranous PD-L1 immunoreactivity was scored as negative, low positive (1 - 24%) and high positive (= or > 25%) in both the tumor cells and tumor infiltrating lymphocytes (TILs). Results were correlated with clinicopathologic variables. *PD-L1* gene amplification was assessed by hybrid capture-based comprehensive genomic profiling (CGP) on a separate set of 806 UCB.

Results: PD-L1 immunoreactivity was noted as positive in 8/63 (13%) UCB [6 low positive and 2 high positive] and correlated with high tumor grade [8/21 (38%) grade 3 vs 0/21 grade 2 vs 0/21 (0%) grade 1, p<0.0001] and advanced tumor stage [6/23 (26%) advanced (pT2 and pT3) versus 2/40 (5%) low (pT1 and pT1) stage, p=0.016]. PD-L1 immunoreactivity was noted in the TIL component of 4/63 (6%) UCB and correlated

with high tumor grade [4/21 (19%) grade 3 vs 0/21 (0%) grade 2 vs 0/21 (0%) grade 1, p=0.014], while showing a trend for advanced tumor stage [3/23 (13%) advanced vs 1/40 (3%) low stage, p=0.098]. On CGP, 6 (0.7%) of 806 UCB demonstrated *PD-L1* gene amplification. On multivariate analysis, advanced tumor stage (p=0.007) independently predicted overall survival.

Conclusions: High tumor expression of PD-L1 was associated with high grade and advanced stage in UCB. *PD-L1* amplification is extremely uncommon in UCB indicating that PD-L1 expression can occur independently of *PD-L1* gene copy number. This study confirms that PD-L1 expression is an adverse prognostic factor in UCB and supports the further development of checkpoint inhibitor therapy for this disease.

Gynecologic and Obstetric Pathology

1083 Expression of Alcohol Dehydrogenase 5 in Ovarian Carcinoma: Effect on Prognosis and Therapeutic Potential

Eman Abdulfatah, Giri Shailendra, Rattan Ramandeep, Mohammed F Daaboul, Sharif Sakr, Baraa Aloseh, Muhammad K Alsafadi, Fatimah Alruwai, Vishakha Pardeshi, Sudeshna Bandyopadhyay, Adnan R Munkarah, Rouba Ali-Fehmi. WSU, Detroit, MI.

Background: S-nitrosoglutathione (GSNO), a physiological nitrosylating agent significantly inhibits ovarian cancer (Oca) growth by promoting nitrosylation of various genes and inhibiting inflammation. GSNO is catabolized by alcohol dehydrogenase 5 (ALDH5) leading to reduction in the process of nitrosylation. Our aim was to evaluate ALDH5 expression in Oca and its relation with inflammatory markers expression and survival and to explore the role of ALDH5 inhibition in treating Oca.

Design: IHC of ALDH5 was performed on tumor tissue microarray for 360 Oca (292 serous, 12 endometrioid, 43 mucinous and 13 clear cell carcinoma). IHC for COX-2, iNOS, eNOS and NFkB was performed on a subset of cases (n=120). Each marker was evaluated to establish H-score. Expression of ALDH5 in various Oca cell lines was determined using quantitative PCR. Oca cell lines were treated with ALDH5 inhibitor (N6022) in the presence or absence of GSNO and cell survival was assayed by MTT. We investigated the effect of GSNO in an immunocompetent isogenic mouse model of Oca which expressed lower level of ALDH5. Data was analyzed by Fisher exact test and Kaplan-Meier analysis.

Results: High ALDH5 expression was significantly associated with Type II Oca (HG serous and endometrioid carcinoma) vs. Type I (LG serous, LG endometrioid, mucinous and clear cell carcinoma) (P= 0.003). High ALDH5 expression was significantly associated with increased COX-2 (P= 0.001) and NFkB(P= 0.001) expression (table 1). The overall survival was shorter in patients with high ALDH5 expression (median; 32 vs. 49 months) without significant difference. Expression of ALDH5 in Oca cell lines showed inverse correlation with cytotoxic effect of GSNO. Inhibition of ALDH5 potentiated the cytotoxicity of sub-optimal doses of GSNO in Oca cell lines (P<0.05). In preclinical mouse model, oral administration of GSNO significantly attenuated tumor growth and ascites accumulation (p<0.01).

	Low ALDH5 expression(n=88)	High ALDH5 expression(n=32)	P value
Cox-2 expression			
Low	28 (31.8%)	0 (0.0%)	0.001
High	60 (68.2%)	32 (100.0%)	
NFkB expression			
Low	82 (93.2%)	0 (0.0%)	0.001
High	6 (6.8%)	32 (100.0%)	
iNOS expression			
Low	30 (34.1%)	7 (21.9%)	0.264
High	58 (65.9%)	25 (78.1%)	
eNOS expression			
Low	79 (90.0%)	31 (96.9%)	0.443
High	9 (10.0%)	1 (3.1%)	

Conclusions: High ALDH5 expression was significantly associated with Type II Oca and inflammatory mediators. Inhibition of ALDH5 could be a potential therapeutic target in Oca.

1084 Discoidin Domain Receptor 1 in Advanced Stage Ovarian Carcinoma: Prognostic Implications and Epithelial-to-Mesenchymal Transition Associations

Eman Abdulfatah, Marta Marco, Rafael Fridman, Vishakha Pardeshi, Sharif Sakr, Robert T Morris, Sudeshna Bandyopadhyay, Rouba Ali-Fehmi. WSU, Detroit, MI.

Background: Ovarian carcinoma (Oca) presents at advanced stages with metastatic disease within the peritoneal cavity; one of the theories being acquisition of an epithelial-to-mesenchymal transition (EMT). Discoidin Domain Receptors (DDRs); DDR1 and DDR2, are receptor tyrosine kinases that play a role in tumorigenesis, primarily stimulated by collagens I-IV and are associated with increased invasiveness via promoting EMT. In this study, we evaluate DDR1 expression in advanced stage Oca to determine correlations with clinicopathologic features and potential associations with EMT.

Design: Retrospective review of 95 stages (III-IV) Oca was conducted. Clinicopathologic parameters were analyzed. IHC of DDR1, collagen type 1 alpha (COL1A1) & EMT markers (vimentin, SNAIL, SLUG, ZEB1 & loss of E-cadherin) was performed on TMA of 95 Oca; HG serous(75), LG serous(8), HG endometrioid(5),

undifferentiated(5) and mucinous Ca(2). Each marker was evaluated to establish H-score. Data was analyzed using Fisher exact test, Spearman's rho test and Kaplan-Meier analysis.

Results: Patient's age ranged (16 to 87) years. High DDR1 was identified in 69.5% (66/95) of advanced stage OCa and was significantly associated with Type II (HG serous, HG endometrioid and undifferentiated) vs. Type I (LG serous and mucinous) (P= 0.001). Significantly increased expression of COL1A1 was associated with high DDR1 (P= 0.001) (Table 1). High DDR1 significantly correlated with expression of EMT markers including SNAIL and SLUG (P=0.001 and P=0.001, respectively) and loss of E-cadherin (P=0.001). High ZEB1 showed a significant correlation with E-cadherin loss ($r=0.718$; $p<0.001$). The 5 year overall survival was shorter in pts with high DDR1 (median; 27 versus 35 months) without statistical significance.

	Low DDR1 expression(n=29)	High DDR1 expression(n=66)	P-value
COL1A1 expression			
Low	23 (79.3%)	6 (9.1%)	0.001
High	6 (20.7%)	60 (90.9%)	
Vimentin expression			
Negative	13 (44.8%)	38 (57.6%)	0.178
Positive	16 (55.2%)	28 (42.4%)	
SNAIL expression			
Low	10 (34.5%)	1 (1.5%)	0.001
High	19 (65.5%)	65 (98.5%)	
SLUG expression			
Low	22 (75.9%)	9 (13.6%)	0.001
High	7 (24.1%)	57 (86.4%)	
E-cadherin expression			
Normal	23 (79.3%)	10 (15.4%)	0.001
Aberrant (loss)	6 (20.7%)	55 (84.6%)	
ZEB1 expression			
Low	15 (51.7%)	29 (43.9%)	0.511
High	14 (48.3%)	37 (56.1%)	

Conclusions: High DDR1 was significantly associated with high grade, Type II OCa and EMT markers. Inhibition of DDR1 could be a potential therapeutic target for advanced OCa.

1085 Management of Insufficient Endometrial Biopsy for Women with Abnormal Uterine Bleeding: To Further Investigate Or Reassure?

Wamidh Advar, Ramya Gadde, Dhyanjay A Chitale, Ghassan Allo, Daniel Schultz, Arthur R Gaba, Ziyang Zhang. Henry Ford Hospital, Detroit, MI.

Background: Endometrial biopsy (EB) is an essential part of investigation performed in women having AUB and is recommended for all women over the age of 45 years with abnormal uterine bleeding (AUB). Frequently, EB contains only scant strips of endometrial surface epithelium, creating a dilemma for pathologists and clinicians judging adequacy for management. There are no published guidelines for endometrial biopsy adequacy. There is considerable disagreement among clinicians regarding further management. The current recommendation is that endometrial thickness of <4 mm is considered as reassuring. To investigate this recommendation, we correlated EB with ultrasound (US) findings and available follow up data.

Design: Electronic medical records were used to retrieve EB performed on women older than 50 years presenting with AUB and for whom US and follow up data were available. Patients who didn't have endometrial pathology or gynecologic complaints within 12 months of follow up were considered as having no evidence of endometrial disease. We categorized EB results into 3 groups: group I: had only strips of endometrial surface epithelium; group II: had intact benign endometrium (proliferative/secretory); and group III: had endometrial pathology (polyp/hyperplasia/cancer).

Results: 183 patients were retrieved, age ranging 50-85 years. The follow up period is from 1 month to 9 years. There were 79 (43%) patients in group I: 42/79 with ET \geq 4 mm, 4 (9.5%) of them had endometrial carcinoma (EMC) upon follow up, while 25/79 patients with ET < 4 mm, 1 (4%) patient had EMC upon follow up. In 12/79 patients, EM could not be visualized by US and all had no evidence of disease (EOD) upon follow up. In group II, there were 83 (45%) patients: 58/83 with ET \geq 4 mm, 1 (1.7%) patient had serous carcinoma upon follow up and 11/83 with ET < 4 mm, all had no EOD upon follow up. In 14/83 patients, EM could not be visualized by US and all had no EOD upon follow up. In group III, there were 21 (12%) patients, 5 had polyps, 6 had hyperplasia and 10 had EMC, all with ET \geq 4 mm except 1 polyp with ET < 4 mm.

Conclusions: Based on this preliminary data from our cohort, for clinical management, it is essential to correlate with US findings if the EB only contains strips of surface epithelium (group I) because 9.5% of such patients with thickened EM were found to have cancer upon follow up. Noteworthy, in this group, ET < 4mm did not guarantee no cancer. In addition, the presence of intact benign endometrium (group II) can't entirely exclude cancer especially when ET \geq 4 mm.

1086 Fumarate Hydratase (FH)-Deficient Uterine Smooth Muscle Neoplasms Can Be Identified by Characteristic Histological Features and Confirmed by FH IHC

Abbas Agaimy, David L Wachter, Nafisa Wilkinson, James Bolton, Matthias W Beckmann, Florian Haller, Arndt Hartmann. University Hospital of Erlangen, Erlangen, Germany; St James's Hospital Beckett Street Leeds LS9 7TF, Leeds, United Kingdom; Central Manchester University Hospitals NHS Foundation Trust, Manchester, United Kingdom.

Background: HLRCC is a rare autosomal dominant disease caused by inactivating germline mutations in the FH gene. Affected individuals are prone to develop cutaneous (up to 80%) and uterine (up to 77%) leiomyomas and aggressive papillary RCC (up to 1/3). FH-deficient Uterine leiomyomas can be easily overlooked if one is not aware of their distinctive morphological features.

Design: We reviewed H&E-stained slides from 9 presumed FH-deficient uterine leiomyomas collected prospectively over 2 years from our routine and consultation files. FH immunohistochemistry (IHC) was performed using a monoclonal antibody (clone J-13, 1:50, Santa Cruz). In addition, tissue microarray (TMA) slides containing 23 extra-uterine and 8 uterine leiomyosarcomas, 6 atypical uterine smooth muscle neoplasms and 8 conventional uterine leiomyomas were screened for FH loss by IHC.

Results: All 9 cases with initial suspicion of FH deficiency were confirmed by IHC as FH-deficient. Patient's age ranged from 25 to 70 years (median: 35). Eight patients had multiple nodules (2 to 14) measuring up to 9 cm. Histologically, all tumors showed consistent and reproducible features: moderate cellularity, remarkable cytoplasmic eosinophilia with fibrillary quality, focal neurofilament-like cytoplasmic material surrounded by nuclear palisades reminiscent of neuroblastic or schwannian neoplasms, scattered enlarged bizarre nuclei with pseudo-inclusions, variable perinuclear halos, hyaline globular bodies and prominent hemangiopericytoma-like vasculature. All tumors expressed smooth muscle actin, desmin and caldesmon and showed complete loss of FH by IHC. Screening of the TMA cohorts showed only one case with FH loss (previous enucleation from 1 of the above 9 patients).

Conclusions: FH-deficient uterine leiomyomas are probably much more frequent than expected. They can be easily recognized by their distinctive histological features. FH IHC represents an excellent confirmatory marker and it is not complicated by interpretive difficulties known for 2SC immunostaining. The relationship of FH-deficient uterine smooth muscle tumors to the HLRCC syndrome needs further clarification. Genetic counselling and molecular FH analysis are warranted to confirm or rule out a HLRCC syndrome.

1087 BRCA Status Can Be Determined Using FFPE Blocks, a Feasibility Pilot Study

Mohammad R Akbari, Robert Royer, Dina Bassiouny, Nadia Ismiil, Matthew Cesari, Valerie Dube, Guangming Han, Fang-I Lu, Elzbieta Slodkowska, Magda Naeim, Mahmoud Khalifa, Sharon Nofech-Mozes. Women's College Research Institute, Women's College Hospital, University of Toronto, Toronto, ON, Canada; Dalla Lana School of Public Health, University of Toronto, Toronto, ON, Canada; Sunnybrook Health Sciences Centre, University of Toronto, Toronto, ON, Canada.

Background: Mutations in BRCA genes are predisposing carriers to cancer, mainly in breast and ovary through alteration in DNA repair mechanism. Molecular diagnosis of germ line mutation via Sanger sequencing or next generation sequencing (NGS) using peripheral blood are the main methods for testing. Recent data suggest that homologous recombination-deficient tumors are highly sensitive to platinum based chemotherapy and may benefit from drugs targeting DNA damage repair pathway like PARP inhibitors. We designed a pilot feasibility study to determine BRCA mutation status on formalin fixed paraffin embedded tissue (FFPE).

Design: Wet leftover material from ovarian high grade serous carcinoma patients was accessed before being discarded to produce anonymized study FFPE tissue blocks of paired tumor and benign tissue from 28 women. Blocks were processed according to routine surgical pathology protocols. Macrodissection was performed when required and DNA was extracted and sequenced for coding regions of BRCA1, BRCA2, PALB2 and RAD51C. Both tumor DNA and normal tissue DNA for each patient were paired-end sequenced for 300 cycles (2x150) using Nimblegen SeqCap for target enrichment and illumina MiSeq for sequencing.

Results: DNA was successfully extracted from 27 pairs. The 27 matched tumor-normal DNA samples were sequenced for the coding regions of the four genes at 3931x on average. The mean percentage of the target region covered at 100x or more was 99.8. The results are summarized in Table 1.

Table 1:	BRCA1	BRCA2	PALB2	RAD51C
Germline	3	1	1	0
Somatic*	1	2	0	1

*One patient had somatic mutation in both BRCA2 and RAD51C.

Conclusions: BRCA and related mutations can be assessed in FFPE tissue from tumors and benign samples using NGS. BRCA and PALB2 germline mutations were identified in 15% and 4% of unselected ovarian cancer patients. In addition, somatic mutations were identified in 11% of the samples. Emerging data suggest that both germline and somatic DNA mutation carrier patients (one fourth of the tested patients) may benefit from PARP inhibitors, the latter are not currently tested in clinical practice.

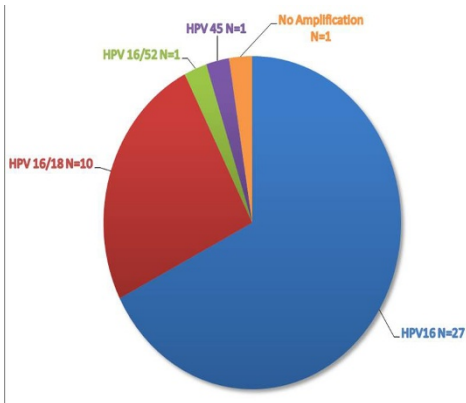
1088 Rare Subtype(s) and Frequency of Multi-Viral Subtype High-Risk HPV infection in High-Grade SIL and Squamous Cell Carcinoma in a Cervical Carcinoma Prevalent Developing Country - A Multiplex Real-Time PCR-Based Study

Shabnam Akhter, Pradip Manna, Mohammed Kamal, C James Sung, W Dwayne Lawrence, M Ruhul Quddus. Women & Infants Hospital/Alpert Medical School of Brown University, Providence, RI; BSM Medical University, Dhaka, Bangladesh; Physicians Reference Laboratory, Overland Park, KS.

Background: Bangladesh, with a population of 160 million and nearly half being women, has the 4th highest rate of cervical carcinoma deaths in the world. With mortality rate of 17.9/100,000, it is projected that ~500,000 of these women would die of this entirely preventable cancer by 2030. HPV vaccination is not widely offered in Bangladesh. This pilot study is designed to find out the prevalence of rare and multi-viral high-risk HPV (HR-HPV) subtype(s) infection in the country. As the prevalence of HR-HPV may vary according to the geographic region, this piece of information will help strategize a large scale vaccination program in tackling cervical carcinoma in the country.

Design: Forty cases of cervical High-Grade SIL (HSIL) and Squamous cell carcinoma (SqCa) were collected from BSM Medical University, Dhaka, Bangladesh. DNA was extracted from tissue representing high-grade SIL (HSIL) and squamous cell carcinoma (SqCa) and multiplex PCR was run to identify all 15 HR-HPV subtypes along with known positive controls.

Results: Of the total, 27 cases were biopsies/cones and 13 cases were hysterectomies including 5 HSIL and 35 SqCa. Viral subtype distribution is shown in Figure 1.



Infection caused by rare subtypes is virtually non-existent. Only two rare subtypes, HR-HPV 45 and 52, were found in two cases. Multi-subtype infection, detected in 28% cases, was limited to HR-HPV16/18 in all cases but one; one case showed HR-HPV16/45 combination.

Conclusions: A remarkable homogeneity of HR-HPV 16 infection is noted in women with HSIL & SqCa in this cervical carcinoma prevalent country. This finding is in sharp contrast to the reports from western countries of frequent multi-viral and rare subtype HR-HPV infection. This pilot study suggests that a vaccination program covering HR-HPV 16/18 may prove to be highly effective in saving the lives of innumerable women and serve as a platform for a larger population based study.

1089 Glucocorticoid Receptor Expression in Ovarian Tumors

Ghassan Allo, Dhnanjay A Chitale, Sharon H Alford, Adnan R Munkarah, Ira Winer, Manohar Ratnam. Henry Ford Hospital, Detroit, MI; Karmanos Cancer Institute, Detroit, MI.

Background: Dexamethasone (Dex) is a synthetic glucocorticoid that is frequently co-administered with chemotherapy in ovarian and other cancers to alleviate side effects of chemotherapy on non-target tissues. However, in vitro and preclinical data show that Dex can induce stress response mechanisms in lung, breast and ovarian cancer cells, causing it to attenuate cytotoxicity of, and response to chemotherapeutic drugs when Dex is co-administered. This response has been suggested to be predicted by the expression status of glucocorticoid receptor (GR) in lung and breast cancers. Therefore, establishing GR as a predictive biomarker of tumor response to Dex-combined chemotherapy would potentially enable clinical decision making with respect to the use of Dex during chemotherapy, particularly as alternative Dex-free treatments such as nab-paclitaxel are now available. We therefore undertook to examine the distribution of GR expression within various subtypes of ovarian tumors as a first step toward exploring GR as a predictor of chemotherapy response in ovarian neoplasms.

Design: Tissue microarrays of 286 ovarian tumors, each case represented in triplicate, were semi-quantitatively assessed for GR immunohistochemical expression using H-score (negative staining defined as weak to no staining H-score<50 while strong diffuse staining as that with H-score≥200). Descriptive statistics and Fischer's exact tests were used for statistical analysis.

Results: Of the 286 cases examined, 244 tumors (85%) showed GR expression (Table 1), 193 (79%) of which with strong diffuse positivity. Among ovarian epithelial carcinomas, type 2 cancers were more likely to be GR positive (190 of 205, 93% vs. 47 of 74, 64%; p<0.0001), with more cases exhibiting strong diffuse positivity (149 of 205, 73% vs. 37 of 74, 50%; p=0.0005).

Conclusions: This is the first report of a comprehensive study of GR status in ovarian tumors, demonstrating highly variable GR expression profile both among subtypes of ovarian cancer and within each, subtype suggesting that tumor GR status may be a major

determinant of the variability in response of ovarian cancer patients to chemotherapy. Pathologic subgroups of patients identified as expressing high GR may also be candidates for novel treatments that use GR antagonists.

Diagnosis	Total n	n positive	% positive	n strong diffuse	% strong diffuse
Carcinomas					
Serous	166	155	93	124	80
Mucinous	23	17	73	14	82
Endometrioid	34	17	50	15	88
Clear cell	17	13	76	8	61
MMMT	9	9	100	8	88
Mixed	7	6	85	4	66
Poorly Differentiated	22	19	86	13	68
Small cell	1	1	100	0	0
Others					
Mucinous cystadenoma	1	1	100	1	100
Brenner tumor	2	2	100	2	100
Carcinoid tumor	2	2	100	2	100
Granulosa cell tumor	2	2	100	2	100

1090 Prognostic Indicators of Uterine Carcinosarcoma in Comparison to Uterine Serous Carcinoma

Baraa Alesh, Nagla Salem, MHD Fayed Daaboul, Rafic Beydoun, Dongping Shi, Paul Tranchida, Sudeshna Bandyopadhyay, Rouba Ali-Fehmi. WSU, Detroit, MI.

Background: Uterine carcinosarcoma (CS) is a highly aggressive neoplasm that harbours either homologous or heterologous mesenchymal elements. This is an attempt to first evaluate the prognostic significance of heterologous elements in CS and to compare its clinicopathologic characteristics and outcome to uterine serous carcinoma (USC).

Design: A retrospective review of 72 CS and 132 USC was conducted. Clinicopathologic parameters including tumor size($\leq 2\text{cm}$), lymphovascular invasion (LVI), adnexal involvement and outcome in both early(FIGO I+II) and late stage(FIGO III+IV) CS and USC were analyzed. The presence and prognostic impact of heterologous elements in CS was also analyzed. All H&E slides were reviewed by 2 pathologists to validate the histologic parameters. Data were analyzed using the Fisher exact test and Kaplan-Meier survival analysis.

Results: In CS, 18 cases had heterologous elements, all of which presented at late stage. 10(55.6%) and 8(44.4%) heterologous type CS had ovarian and tubal involvement, respectively, compared to 4(22.2%) ovarian involvement and 2(11.1%) tubal involvement in homologous type(Table1). A tumor size of $\geq 2\text{cm}$ was more frequently seen in early and late stage CS than USC (Table2). Patients with late stage CS had more LVI, ovarian and tubal involvement when compared to those with late stage USC (Table2). The median survival time for early stage USC and CS was 88 months and 43 months, respectively($p=0.03$). The median survival time for late stage USC and CS was 29 months and 12 months, respectively ($p=0.05$)

Conclusions: Presence of heterologous elements showed a negative impact on prognosis in patients with CS. When comparing uterine CS and USC, CS showed worse clinicopathological features and outcome.

Table 1		Homologous type n(%)	Heterologous type n(%)	p
Ovarian inv.	No	14(77.8)	8(44.4)	.04
	Yes	4(22.2)	10(55.6)	
FT inv.	No	16(88.9)	10(55.6)	.02
	Yes	2(11.1)	8(44.4)	

Table 2		Early stage n(%)			Late Stage n(%)		
		USC	CS	p	USC	CS	p
Tumor size	<math>< 2\text{cm}</math>	21(33.9)	2(6.5)	.03	12(20.3)	0(0)	.002
	$\geq 2\text{cm}$	41(66.1)	29(93.5)		47(79.7)	38(100)	
LVI	No	28(40.6)	15(45.5)	.39	18(29)	9(23.7)	.36
	yes	41(59.4)	18(54.5)		44(60)	29(76.3)	
Ovarian inv.	No	-	-		24(38.7)	23(60.5)	.02
	Yes	-	-		38(61.3)	15(39.5)	
FT inv.	No	-	-		43(69.4)	28(73.7)	.4
	Yes	-	-		19(30.6)	10(26.3)	
Median survival in months		88	43	.03	29	12	.05

1091 Heterotopic Steroid (Hilus) Cells in the Fallopian Tube

John Aranake-Chrisinger, Horacio M Maluf. Washington University School of Medicine, St. Louis, MO.

Background: The incidence of hilus cells in the fallopian tube is reported to be approximately 0.5%. However as complete submission of the fallopian tubes, either in prophylactic salpingo-oophorectomy or in cases of ovarian/pelvic serous carcinoma

becomes standard practice, their presence appears to be more common than previously thought. We reviewed 70 cases of salpingo-oophorectomy to determine the incidence and pattern of presentation of this peculiar histologic finding.

Design: The files were searched from 2005-2014 using the terms “fallopian” and “prophylactic.” The cases were reviewed for the presence of hilus cells in the fallopian tubes to determine the incidence of this finding. Also, the archives were searched over the same period for “hilus,” to identify additional cases for histologic examination. Patient age, indication for salpingectomy, growth pattern, and location were noted. Four randomly selected cases were stained for inhibin to confirm the diagnosis.

Results: Fifty prophylactic cases were identified, of which seven were found to have hilus cells in the fallopian tube, yielding an incidence of 14%. The patients ranged in age from 29 to 58 years old. Indications for prophylactic salpingectomy were BRCA mutations in four patients, breast carcinoma in three patients, and Lynch syndrome in one patient. The search for “hilus” yielded 20 relevant results, among which three cases of fallopian tube hilus cells were found. These patients ranged in age from 52 to 80 years old. Indications for surgery were uterine and ovarian neoplasia. Taking all cases together, clusters were observed in three cases, cords in two cases, a loose collection of single cells in one case, and a combination of growth patterns in four cases. The hilus cell rests also varied in location. Five cases were subepithelial, two cases were within the muscle, one case was subserosal, one case was subepithelial and intramuscular, and one case was within the paratubal soft tissue. Three cases were multifocal. Bilateral involvement and Reinke crystalloids were not observed. Inhibin stain was positive in all stained cases.

Conclusions: Steroid cells are present in 14% of fallopian tubes, which significantly more common than previously thought. Although they have been considered to be heterotopic in nature, the possibility that they represent a metaplastic change in the subepithelial tubal stroma or implantation of follicular cells during follicular rupture cannot be entirely excluded. In occasional cases the need to distinguish these rests from metastatic carcinoma, particularly lobular carcinoma, may arise.

1092 A MicroRNA Whole Transcriptome Assay to Distinguish between Histological Subtypes of Ovarian Carcinomas

Le Aye, Jonas Pettersson, Craig Stephens, Miriana Moran, Tiffany I Long, Stephanie H Astrow, Robert Makowsky, Chris Roberts, Louis Dubeau, Pamela M Ward. USC, Los Angeles, CA; Response Genetics, Los Angeles, CA; HTG Molecular Diagnostics, Tucson, AZ.

Background: Distinction between ovarian high grade serous, endometrioid, and clear cell carcinomas is important because of the differences in prognosis and therapeutic approaches associated with each subtype. Such distinction is often challenging based on traditional histopathological examination, resulting in diagnostic errors that have a significant impact on clinical care and clinical trials. Our hypothesis is that the expression profile of microRNAs (miRNAs) could complement histopathology to improve diagnostic accuracy.

Design: Hematoxylin-eosin stained 5µm thick sections of 24 high and low grade serous, 15 endometrioid, and 11 clear cell ovarian carcinomas were independently reviewed by 2 pathologists and used as an evaluation set for miRNA expression profiling studies based on a panel of 2255 miRNAs. Tissue sections were microdissected to ensure that tumor cells accounted for ≥80% of all cells in each sample. MicroRNA was isolated using the HTG *Edge processor*. Uniquely barcoded miRNA libraries were prepared from each sample. Pooled libraries were sequenced using the Illumina *MiSeq* platform. All data analyses were performed using the R programming language (www.r-project.org) and the Bioconductor package (www.bioconductor.org). Test statistics for differential expression across the three sample types were calculated using empirical Bayes estimators. An unsupervised principle component analysis (PCA) was performed on only the statistically significant genes as a quality control metric to establish classifier performance, and internally validated using 5-fold cross validation.

Results: Forty miRNAs were differentially expressed among 2255 examined. The PCA showed separate clustering of the 50 cases, which segregated into 3 groups corresponding to their respective histological subtypes. The distribution of *area under the curve* values across the 5-fold cross validation were all above 0.8. Although there was some degree of overlap between the different clusters, some cases clearly fell outside the clusters associated with their respective histological diagnoses.

Conclusions: Ovarian high-grade serous, endometrioid and clear cell carcinomas are associated with distinct miRNA expression profiles. If cases with profiles different than those associated with their respective histopathological diagnosis are also associated with atypical clinical behaviors, then molecular classification based on miRNA profiling might complement histopathological diagnoses to more accurately predict clinical outcome.

1093 Serous Psammocarcinoma Revisited: A Single Institution Experience

Keegan Barry-Holson, Ann K Folkins, Teri A Longacre. Stanford University Medical Center, Stanford, CA.

Background: Serous psammocarcinoma is a rare form of serous carcinoma arising from either the ovary or the peritoneum, characterized by extensive (>75%) psammoma body formation, stromal invasion, and low-grade cytology. Since first described by Gilks *et al* in 1990, when it was purported to have a clinical course similar to serous borderline tumors, additional studies of psammocarcinoma, save for case reports, have been lacking.

Design: The pathology electronic database was searched for all cases of possible serous psammocarcinoma. Pathology reports and medical records were reviewed to document demographic data, histologic findings, treatment regimens, and clinical outcomes.

Results: Twenty-nine cases of ovarian and peritoneal serous psammocarcinoma as defined by the Gilks *et al* study were identified. Patient ages ranged from 32 to 82

years (median 59). 21 (72%) were FIGO stage III and 24 (82%) were treated first with debulking surgery. 9 patients have significant clinical follow-up, and the follow-up ranged from 4 months (given recent diagnosis) to 11 years. 4 patients (44%) were treated with adjuvant chemotherapy (carboplatin-taxol); 2 had no evidence of disease at 1 and 5 years post therapy. One patient is doing well 4 months into chemotherapy with no imaging studies performed to date. One patient succumbed to her disease at 7 years after chemotherapy and multiple recurrences. Chemotherapy was recommended to another patient, and she is undergoing treatment at an outside institution. 3 patients are alive with disease, one with extended follow-up at 11 years; however, their chemotherapy status is unknown.

Conclusions: Serous psammocarcinoma is a rare form of low-grade serous carcinoma that appears to exhibit a variable clinical course intermediate to that of usual serous borderline tumor and low-grade serous carcinoma. Recurrences are common and up to 45% of patients have persistent or progressive disease. Debulking with or without chemotherapy is the most common treatment regimen. Strict histologic criteria need to be followed when making this rare diagnosis.

1094 Histopathologic Features of Post-Ablation Tubal Sterilization Syndrome

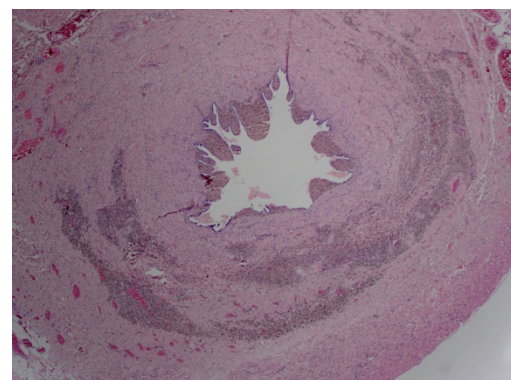
Jamen Bartlett, Kelly J Butnor. University of Vermont Medical Center, Burlington, VT.

Background: Post-ablation tubal sterilization syndrome (PATSS) is an uncommon complication of endometrial ablation in patients with antecedent tubal ligation. PATSS is characterized by cyclic abdominal pain sometimes accompanied by vaginal spotting. Recurrent tubal distention resulting from retrograde menstruation by residual/regenerated cornual endometrial tissue is the postulated cause of PATSS. Reports of PATSS have largely focused on the clinical, imaging and operative findings. Detailed descriptions of the gross pathologic findings are sparse. Rarer still are examples in which the histologic manifestations are discussed. To our knowledge, this is the first study to depict the histologic features of PATSS.

Design: The pathologic findings of two patients whose clinical presentations were compatible with PATSS and had undergone hysterectomy at our institution were reviewed.

Results: The clinical findings are presented below. A clinical suspicion of PATSS was conveyed to the pathologist at the time of initial pathologic examination in only 1 case. Both cases showed similar pathologic findings. Gross examination disclosed bilateral hemosalpinx of the proximal fallopian tubes and attenuated endometria. Histologic sections of the dilated portions of the fallopian tubes showed intraluminal hemosiderotic material and plial and mural hemosiderin-laden macrophages. The endometria contained sparse inactive glands with submucosal scarring, consistent with ablation changes. The pathologic features, in conjunction with the clinical findings, were interpreted as consistent with PATSS.

	Patient 1	Patient 2
Age (y)	47	38
Time since tubal ligation (mo)	158	191
Time since ablation (mo)	26	66
Indication for ablation	Menorrhagia	Menorrhagia
Obstetrical History	G5P4	G3P3
Presenting symptoms	Cyclic abdominal pain and vaginal bleeding	Pelvic pain
Ultrasonographic findings	Hematometra	Hematometrioma



Conclusions: While PATSS is estimated to complicate 5-10% of endometrial ablations, it is likely underreported due to a lack of awareness. Pathologists should consider PATSS in hysterectomy specimens that show post-ablative endometrial changes accompanied by dilatation and hemosiderosis of previously ligated fallopian tubes.

1095 Molecular Mechanism of Ovarian Tumor Induced Immunosuppression and Its Prevention by Metformin

Animesh Barua, Sa'Rah McNeal McNeal, Lindsey Franklin, Paolo Gattuso, Sameer Sharma, Pincas Bitterman. RUsh University Medical Center, Chicago, IL.

Background: Tumor induced immunosuppression contributes to the aggressive progression of malignant ovarian epithelial cancer (OVCA). Information on the immunopathology of OVCA development and progression is not well known. Longstanding unresolved inflammation and associated oxidative stress in the ovary and fimbria of the fallopian tube has been suggested as a putative factor for OVCA. Glucose regulated

protein 78 (GRP78), an endoplasmic reticular (ER) chaperon protein, increases with chronic stress and may lead to malignant transformation after translocating to the nucleus from the ER. GRP78 is immunosuppressive although its mechanism is not known. GRP78 may enhance expression of immune response gene 1 (IRG1) to suppress antitumor immunity. Metformin, an anti-diabetic drug, has been suggested to have anti-tumor effect. The goal of this study was to examine whether GRP78 is associated with enhanced expression of immunosuppressive IRG1 and whether metformin treatment suppresses IRG1 expression in OVCA patients.

Design: *Experiment-1:* GRP78 expression and its association with ovarian epithelial malignant transformation was examined in archived ovarian specimen from subjects with (n=10) or without (n=10) OVCA risk including BRCA mutations. *Experiment-2:* Specimens from OVCA patients treated with (n=20, serous) or without metformin (early stage, n=5 for each of the serous, endometrioid, mucinous and clear cell; and late stage, n=10, serous) were used. Effects of metformin treatment on GRP78 and IRG1 expression were determined and compared by paired T-tests and oneway ANOVA.

Results: Ovarian and fimbrial surface epithelial cells in subjects with OVCA risk showed strong GRP78 expression. Compared with OVCA without metformin treatment, the intensity of GRP78 expression decreased remarkably in metformin-treated OVCA patients ($P < 0.01$). Similarly, malignant cells in OVCA without metformin showed strong IRG1 expression while it was weak or absent in metformin treated patients ($P < 0.001$). GRP78 was positively correlated with IRG1 expression.

Conclusions: The results of this study suggest that expression of GRP78, a molecular marker of cellular stress, is associated with OVCA development and suppression of anti-tumor immunity. Metformin treatment reduces immunosuppression by decreasing GRP78 possibly by reducing cellular stress. This study will lead to a larger study to develop anti-tumor immunotherapies. Support: Swim Across America.

1096 Intervillous Thrombi Are Increased in Placentas from Pregnancies Complicated by Diabetes

Kristen M Basnet, Rhonda Bentley-Lewis, Deborah Wexler, Fusun Kilic, Drucilla Roberts. Massachusetts General Hospital, Boston, MA; University of Arkansas for Medical Sciences, Little Rock, AR.

Background: Intervillous thrombi (IVT) are common placental pathologies of unclear etiology. Intervillous thrombi may form as a protective reaction against fetomaternal hemorrhage in the setting of villous trophoblastic membrane disruption. One possible cause for trophoblastic disruption is apoptosis, and a role for hyperglycemia in trophoblast apoptosis and placental dysfunction has been suggested. We sought to determine if placentas from pregnancies complicated with diabetes had an increased incidence of IVT.

Design: Medical records of 206 obstetric patients at the Massachusetts General Hospital with well characterized diabetes: Type I diabetes (n=39), Type II diabetes (n=37), and gestational diabetes (GDM, n=130), from 1994 to 2011, were identified. Placental pathology reports were reviewed to determine numbers of IVT in each group. For patients with placental IVT, gestational and maternal age-matched controls were selected from the pathology archives comprising placentas examined only for the indication of Group B Streptococcus positivity. Control patient medical records and placental pathology reports were then reviewed to confirm euglycemia and identify the presence of IVT, respectively. Fisher exact test was used for statistical analysis.

Results: An increased incidence of IVT was present in patients with diabetes as a group (Type I, Type II, and GDM; 32/206, 15.5%; $p = 0.04$) and in GDM exclusively (22/130, 16.9%; $p = 0.03$) versus controls (7/99, 7.1%). IVT were also increased in patients with Type I diabetes (4/39, 10.3%) and Type II diabetes (6/37, 16.2%) compared to controls (7/99, 7.1%), but the results did not attain statistical significance ($p = 0.73$ and 0.19, respectively).

Conclusions: The incidence of IVT is increased in the placentas of patients with diabetes as a group (Type I, Type II, and GDM), and in patients with GDM in particular, versus those of euglycemic patients. This is the first report of an association between diabetes and an increased incidence of placental IVT. Our findings give support to the hypothesis that trophoblastic apoptosis associated with diabetes may be the etiology of the increased incidence of IVT.

1097 HNF1- β Is Strongly Expressed in Ovarian Mucinous Carcinoma

Dina Bassiouny, Nadia Ismiil, Matthew Cesari, Valerie Dube, Guangming Han, Fang-I Lu, Elzbieta Slodkowska, Hak Fai Chiu, Nim Li, Magda Naeim, Mahmoud Khalifa, Sharon Nofech-Mozes. Sunnybrook Health Sciences Centre, University of Toronto, Toronto, ON, Canada.

Background: Histopathologic evaluation of HE slides is usually sufficient for cell typing in most cases of ovarian carcinomas and immunohistochemistry (IHC) is used as an adjunct diagnostic tool in difficult cases. Recent reports highlighted Hepatocyte Nuclear Factor β (HNF-1 β) as a sensitive marker in ovarian clear cell carcinoma (OCC). Its expression in ovarian serous and endometrioid adenocarcinoma is significantly lower. Current data is limited with regards to HNF-1 β expression in ovarian mucinous carcinoma (OMC).

Design: HNF-1 β expression was studied by IHC (Sigma, Aldrich CA, 1:200) on 41 OMC arrayed in 1mm duplicate cores. Cases were identified through the Biomatix institutional research database. IHC was scored semiquantitatively; % positive nuclei: 0 (< 1%), 1-25% (1+), 25-50% (2+), 50-75% (3+), >75% (4+); intensity: weak (1+), moderate (2+), strong (3+). Each core was scored individually and the highest score was considered for interpretation.

Results: Tissue was available in 40/41 cases. There was a high level of concordance among paired cores. HNF-1 β was positive in 37/40 (92.5%) cases, 34 cases showed strong and diffuse nuclear positivity (score ≥ 6 ; Figure 1), whereas 3 cases showed moderate staining (score 4-5).

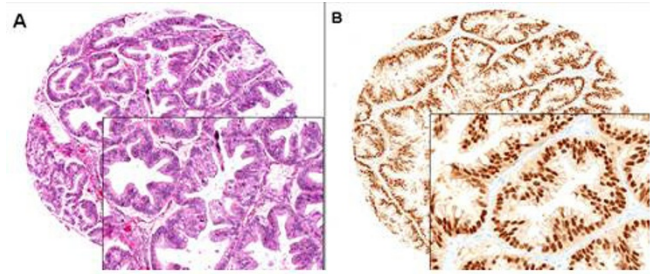


Figure 1: Diffuse, strong nuclear positivity of HNF-1 β in mucinous ovarian tumor.

Conclusions: HNF-1 β is diffusely expressed in the majority of OMC and is not specific for OCC. Since clear cell changes may be encountered in other cell types, in challenging cases, HNF-1 β should be used in a panel and the interpretation should be made with caution in the context of tumor morphology.

1098 MMR Protein Expression in Ovarian Carcinoma: A Clinicopathologic Study

Dina Bassiouny, Sharon Nofech-Mozes, Nadia Ismiil, Matthew Cesari, Valerie Dube, Guangming Han, Elzbieta Slodkowska, Hak Fai Chiu, Eugene Hsieh, Nim Li, Magda Naeim, Mahmoud Khalifa, Fang-I Lu. Sunnybrook Health Sciences Centre, University of Toronto, Toronto, ON, Canada.

Background: Lynch syndrome (LS) accounts for 10 to 15% of all inherited ovarian cancer cases. Deficient MMR expression can be used for its screening. The aim of this study is to evaluate MMR protein expression in ovarian carcinomas (OC).

Design: All H/E slides were reviewed with a gynecologic pathologist to confirm diagnosis. MMR protein expression was evaluated in 608 OC accessioned between 2000-2013, arrayed in 1 millimeter cores in duplicates and characterized by immunohistochemistry (IHC). MLH1, MSH2, MSH6 and PMS2 were assessed as intact or deficient. The latter required a positive internal control. Equivocal cases were confirmed on full slides. The clinicopathologic characteristics were compared between the groups using χ^2 test and t-test.

Results: Nine/608 patients (1.5%) demonstrated deficient MMR expression. One/9 patients (11.1%) had concurrent loss of both MSH2/MSH6, 4 (44.4%) had combined loss of MLH1/PMS2, 3 (33.3%) had only MLH1 loss and 1 patient (11.1%) had only loss of PMS2. Two patients with combined loss of MLH1/PMS2 had personal or family history of other malignancies which raises the possibility of LS. Deficient MMR tumors were high grade, 5 endometrioid and 4 serous ($p = 0.001$). They were more likely to be unilateral ($p = 0.05$) and presented at early stage (66.7% at I/II) ($p = 0.003$) and frequently associated with ovarian or extra-ovarian endometriosis ($p = 0.05$). Age, surface involvement, tumor lymphocytic infiltrate, lymphovascular invasion or disease free survival between groups were not significantly different.

Conclusions: High grade OC of serous and endometrioid subtypes that are unilateral and are associated with endometriosis are more likely to be MMR deficient. Tools to efficiently select and screen patients with OC at risk for LS are needed.

1099 TLR4 and MAD2: Drivers of Chemoresistance in Ovarian Cancer

Mark Bates, Luke Gubbins, Dorinda Mullen, Eimear Lee, Jacqui Barry-O'Crowley, Danielle Costigan, Ciaran O'Riain, Cathy D Spillane, Michael F Gallagher, Cara Martin, Amanda McCann, Sharon O'Toole, John J O'Leary. Trinity College Dublin, Dublin 2, Ireland; University College Dublin, Belfield, Dublin 4, Ireland; Coombe Women & Infants University Hospital, Dublin 8, Ireland; St James's Hospital, Dublin 8, Ireland.

Background: MAD2 is a key protein involved in the spindle assembly checkpoint and knockdown of this protein has been shown to facilitate paclitaxel resistance through the induction of senescence. Additionally low MAD2 immunohistochemical (IHC) staining has been associated with reduced progression free survival (PFS). Conversely the TLR4-MYD88 pathway is known to mediate paclitaxel resistance through the upregulation of pro-tumorigenic cytokines and pro-survival genes and blockage of this pathway has been shown to restore chemosensitivity to paclitaxel. Furthermore high TLR4 IHC staining is associated with reduced PFS.

Design: A2780 and SKOV-3 cells were transfected with siRNA targeting MAD2. MAD2 and TLR4 expression was then analysed by RT-PCR. SKOV-3 cells were subsequently transfected with siRNA targeting MAD2 and then treated with 1 μ M paclitaxel. Cell viability was then assessed using the CCK-8 assay. β -galactosidase activity was also measured in SKOV-3 cells following transfection using the Senescence β -Galactosidase Staining kit.

Results: In this study a novel link between TLR4 and MAD2 was observed. Specifically when MAD2 was knocked down in both A2780 and SKOV-3 cells, a 3 fold upregulation of TLR4 mRNA expression was observed. MAD2 knockdown in SKOV-3 cells was also shown to render SKOV-3 cells highly resistant to paclitaxel. These cells displayed enlarged cell and nuclear size and an increase in β -galactosidase activity. Additionally TLR4 and MAD2 expression was analysed by IHC in a tissue microarray cohort of high grade serous, stage 2-4 ovarian cancer patients (n=36). Patients with a TLR4 high and MAD2 low phenotype had significantly reduced DFI ($p = 0.002$) and PFS ($p = 0.002$), compared to those possessing any other phenotype, a reduction in patient overall survival was also observed but this was just below significance ($p = 0.081$).

Conclusions: The results demonstrate the development of a lethal phenotype which is highly resistant to paclitaxel chemotherapy and a synergy between the MAD2 senescence

associated paclitaxel resistance mechanism and the cytokine and pro-survival gene driven TLR4 paclitaxel resistance mechanism. This lethal phenotype likely drives chemoresistant and recurrent disease.

1100 Usefulness of Napsin A Immunohistochemistry in the Diagnosis of Clear Cell Carcinoma of the Ovary

Sarah Bell, Darren Ennis, Aoisha Hoyle, Iain McNeish, David Millan. Queen Elizabeth University Hospital, Glasgow, Scotland, United Kingdom; Institute of Cancer Sciences, University of Glasgow, Glasgow, Scotland, United Kingdom.

Background: Clear cell carcinoma (CCC) of the ovary is a poor responder to chemotherapy and therefore has an unfavourable prognosis. Histological diagnosis can be challenging due to clear cell change in other ovarian malignancies. Napsin A has previously been reported as a sensitive and specific marker of CCC. We aimed to assess the diagnostic utility of Napsin A staining in a cohort of ovarian CCC, endometrioid (EC) and high grade serous (HGSC) carcinomas.

Design: Following case review, a TMA was constructed using three separate tumour cores from each patient sample and then stained with Napsin A using standard IHC techniques. Each core was scored independently by two pathologists and by Slidepath Tissue Image Analysis using a histoscore method, multiplying intensity of cellular staining (range 0-3) by percentage of positive cells (range 0-100, maximum 300). Cores were also assessed using a 10% cut off for cytoplasmic staining.

Results: A total of 22 CCCs, 21 ECs and 24 HGSCs were included in the study. Median histoscore in the CCC cohort was 110/300. 6 out of 22 (27%) CCCs showed a low histoscore (<30/300) and 5 of these showed <10% staining. Furthermore, 4 cases of CCC showed no Napsin expression. All of the ECs and HGSCs were negative for Napsin.

Conclusions: In this study, a third of CCC showed only focal or negative Napsin staining and overall, the median histoscore was low (110/300). This is in contrast to previous studies and we believe this marker has considerable limitations. Reassuringly, all ECs and HGSCs showed no Napsin expression confirming its use in the differential diagnosis with these tumours. Negative staining for Napsin A does not exclude the diagnosis of CCC and therefore may be of most diagnostic use in a panel of markers.

1101 Clear Cell Carcinomas of the Ovary: A Mono-Institutional Study of 73 Cases in China with Analysis of the Prognostic Significance of Clinicopathologic Parameters and IMP3 Expression

Rui Bi, Xuxia Shen, Weiwei Zhang, Yufan Cheng, Zheng Feng, Xu Cai, Wentao Yang. Fudan University Shanghai Cancer Center, Shanghai, China; School of Public Health, Hong Kong, Hong Kong.

Background: Ovarian clear cell carcinoma (CCC) is an uncommon subtype of ovarian epithelial tumor. The prognostic significance of its clinicopathological parameters is discordant, with the exception of stage as the adverse prognostic factor. Insulin-like growth factor-II mRNA-binding protein 3 (IMP3 or IGF2BP3) has been reported to be an independent negative prognostic marker for ovarian CCC, but it is no further verification research, especially in Chinese.

Design: The present study aimed to evaluate the prognostic significance of its clinicopathological characteristics and the expression of IMP3 in Chinese patients with primary pure CCC. We collected clinicopathological data from 73 cases with a minimum of 5 years of follow-up and evaluated the expression of IGF2BP3 by immunohistochemistry.

Results: In total, 49.3% of the patients were in stage I. Advanced stages were closely related to poor prognosis of disease-free survival (DFS) and of overall survival (OS) ($P < 0.005$). Patients with CCC coexisting with endometriosis tended to be younger and to have unilateral involvement but did not exhibit differences in prognosis compared with patients with CCC without endometriosis. Other histological features such as the growth pattern, cell atypia, mitosis, and necrosis did not have prognostic significance. IGF2BP3 was positive in 63% of patients (46 of 73 cases); Thus, positive expression of IGF2BP3 is an adverse prognostic marker in terms of OS ($P = 0.012$), even in stage I patients ($P = 0.038$).

Conclusions: The present study demonstrates that IGF2BP3 expression has prognostic significance, with the exception of stage. IGF2BP3 represents a biomarker of unfavorable prognosis even in stage I patients.

1102 The Role of T Regulatory Cell Apoptosis in the Progression of Endometrial Hyperplasia to Endometrial Carcinoma

Julie Anne Bishop, Mirna B Podoll, Zhenglong Wang. University of Louisville, Louisville, KY.

Background: Endometrial carcinoma (EC) is the most common malignancy in the female genital tract, and is the second most common cause of gynecologic cancer mortality. EC arises from complex endometrial hyperplasia (EH), a well-known consequence of hyperestrogenism. Recent studies indicate that EC tumorigenesis is related to inflammation, where T regulatory cells (Tregs) act as key factors in the pathogenesis of inflammation and tumor cell tolerance. Currently, there are no studies analyzing differences in Treg concentration and apoptosis between EC and EH.

Design: In this study, we retrospectively analyzed 6 surgical cases of EC and 6 cases of EH comparing the stromal concentration of total Tregs and apoptotic Tregs for each group. A representative formalin-fixed, paraffin-embedded tissue block containing the lesion was selected for immunohistochemistry to assess Treg and apoptotic Treg concentration using FOXP3 (AbCam, 236A/E7, 1:100 dilution), a protein involved in Treg development, and BCL2 (Dako, 124, 1:100 dilution), an anti-apoptotic protein. Immunoreactivity was evaluated based on five high-power fields (hpf) in each case ($n=30$). The presence of Tregs (cells with nuclear FOXP3 reactivity) and apoptotic Tregs (cells displaying cytoplasmic BCL2 reactivity and nuclear FOXP3 reactivity)

were quantified for each hpf. The average concentrations of total Tregs and apoptotic Tregs were compared between EC and EH using an unpaired Two-Tailed T-test, with a p -value < 0.05 considered significant.

Results: The EC group showed an average of 130.1 Tregs/hpf, while the EH group displayed an average of 36.6 Tregs/hpf. When apoptosis was evaluated, the EC group showed greater concentrations of Tregs with overexpression of BCL2 ($p=0.02$) suggesting that the higher number of Tregs is most likely due to decreased apoptosis.

Conclusions: This preliminary data shows the potential regulatory roles of Tregs in the progression from EH to EC. The difference in Treg apoptosis between EH and EC groups indicates that the survival of Tregs was differentially regulated in the microenvironment during the early transition from EH to EC. We plan to expand our current studies to evaluate other cytokine-mediated interactions with Tregs in order to better understand the microenvironment in which disease progression occurs. This concept is of particular importance for identifying targets of therapeutic intervention and to potentially predict the likelihood of EH progressing to EC.

1103 Expression of PD-L1 and PD-1 Positive Tumor Infiltrating Lymphocytes in Ovarian Tumors

Peter N Bonneau, Luis F Carrillo, Alexander C Mackinnon. Medical College of Wisconsin, Milwaukee, WI.

Background: The expression of PD-L1 and PD-1 positive tumor infiltrating lymphocytes (TILs) are associated with various solid tumors, and therapies developed against PD-L1 have shown strong anti-tumor responses. Together, these findings suggest potential clinical utility for these biomarkers in selecting therapy. Few and limited studies have examined the expression of PD-L1 and PD-1 positive TILs within ovarian tumors, and none have examined specific ovarian tumor subtypes in regard to these markers. The objective of this study was twofold: 1) to evaluate PD-L1 expression in a variety of ovarian tumors and 2) characterize PD-1 positive TILs using a panel of antibody clones and manufacturers for PD-L1 and PD-1.

Design: A retrospective search of ovarian tumors yielded 60 ovarian tumors that were built into tissue microarrays. Immunohistochemical stains for PD-L1 (Cell Signaling, E1L3N; Spring BioScience, SP142) and PD-1 (Abcam, NAT105; Biocare, NAT105) were performed on all ovarian tumors. PD-L1 expression was defined by any detectable cytoplasmic or membranous staining, and cases with PD-1 positive TILs were scored as positive. Positive TILs were counted within a single 400x high-power field (HPF) using a hot-spot approach.

Results: PD-L1 expression and PD-1 positive TILs were present in several ovarian tumors with variable numbers of TILs/HPF. No significant difference was detected between PD-L1 clones or between PD-1 manufacturers, based on tumor positivity. Staining for PD-L1 was typically weak and focal.

	PD-L1 E1L3N Positive (%)	PD-L1 SP142 Positive (%)	PD-1 NAT105 Abcam Positive (%) (TIL/HPF)	PD-1 NAT105 Biocar Positive (%) (TIL/HPF)
All cases	38/59 (64)	36/60 (60)	34/57 (60) (1-88)	35/59 (59) (1-116)
High grade serous carcinoma	23/25 (92)	21/25 (84)	19/24 (79) (1-88)	19/25 (76) (1-116)
Serous borderline	3/8 (38)	4/9 (44)	7/9 (78) (1-52)	7/9 (78) (1-49)
Mucinous carcinoma	0/2 (0)	0/2 (0)	0/2 (0)	0/2 (0)
Mucinous borderline	0/3 (0)	0/3 (0)	1/3 (33) (1-1)	1/3 (33) (1-1)
Clear cell carcinoma	3/4 (75)	4/4 (100)	2/4 (50) (5-78)	2/4 (50) (22-107)
Adult granulosa cell tumor	1/6 (17)	1/6 (17)	0/4 (0)	1/5 (20) (2-2)
Mixed epithelial carcinoma	4/4 (100)	3/4 (75)	1/4 (25) (32-37)	1/4 (25) (33-57)
Others	4/7 (57)	3/7 (43)	4/7 (57) (1-64)	4/7 (57) (1-68)

Conclusions: Our findings support previous studies of PD-L1 staining and PD-1 positive TILs in ovarian tumors. We further demonstrate staining characteristics of several ovarian tumor subtypes, with positivity appearing most associated with high-grade serous and clear cell carcinomas.

1104 Are the Genomics in the Cancer Genome Atlas Representative of Patients with Recurrent Ovarian High Grade Serous Carcinoma That Is Refractory to Standard Therapy?

Emily Broadus, Scott Kopetz, J Jack Lee, Jiexin Zhang, Kenna Shaw, Russell Broadus. University of Texas, Austin, TX; M.D. Anderson Cancer Center, Houston, TX.

Background: The Cancer Genomics Atlas (TCGA) provides a genomic fingerprint of different primary, untreated cancer types. Primary cancers from patients with recurrent disease refractory to standard therapy may have a distinct molecular biology compared to most primary cancers. A year ago, our institution initiated a protocol for the systematic identification of potential therapeutic targets in patients with advanced solid tumor malignancies, providing us with the opportunity to compare genomic data from these patients to those represented in TCGA. Ovarian high grade serous carcinoma is not typically considered a mutation-rich malignancy, but according to TCGA, 12-20% of these tumors have mutations in actionable genes, such as *CCNE1*, *NF1*, and *PIK3CA*.

Design: Patients eligible for the protocol had no remaining standard of care therapy anticipated to extend life by more than 3 months, ECOG performance status of ≤ 1 , and a willingness to consider clinical trial enrollment. The patients' tumors and germline DNA were sequenced with a 409-fragment-length (Ion Proton) gene panel. Ninety-nine genes on the panel are considered actionable, defined as genes for which a matched genotype selected trial exists at our institution. Three hundred patients have been tested on this protocol to date; 20 of these have ovarian high grade serous carcinoma (termed MDA patients). TCGA sequencing data for the same 409 genes from 316 ovarian high grade serous carcinomas were extracted using cBioPortal.org.

Results: There were fewer mutations in actionable genes in the MDA group (0.2 mutations per patient) compared to TCGA (3.0 mutations per patient). Only 4 patients in the MDA cohort had mutations in an actionable gene (1 each for *AR*, *BRAF*, *MTOR*, and *ROSI*). Mutations in actionable genes in the TCGA group were not common, with most having mutation frequencies of 1-6%. Exceptions include *CCNE1* (20%), *PIK3CA* (18%), *NFI* (12%), and *PTEN* (8%). None of the MDA patients had mutations in these 4 actionable genes. *TP53* mutation, while not targetable therapeutically, has recently been associated with better survival compared to patients with wildtype *TP53*. The MDA cohort had significantly fewer patients with *TP53* mutation (80%) compared to TCGA (95%).

Conclusions: Patients in the MDA group had tumors with significantly fewer mutations in actionable genes, particularly *PIK3CA*, *NFI*, and *CCNE1*. These results have profound implications for the design of targeted therapy clinical trials that will include ovarian cancer patients.

1105 The Role of Pathologic Evaluation of Endometrial Ablation Resections in Predicting Ablation Failure and Adenomyosis in Hysterectomy

Aurelia Busca, Carlos Parra-Herran. University of Ottawa, Ottawa, ON, Canada.

Background: Endometrial ablation is commonly performed to manage dysfunctional uterine bleeding. However, failure in symptom control eventually requiring hysterectomy is seen in up to 30% of patients. Deep adenomyosis is more common in such failure cases. Ablations using a resectoscope will produce an endomyometrial resection (EMR) specimen. The value of histopathologic examination of these specimens in predicting treatment failure and the presence of deep adenomyosis has not been fully addressed.

Design: We retrieved histologic material from subjects with history of failed ablation (persistent symptoms after ablation requiring hysterectomy), and subjects who had endometrial ablation, clinical improvement at follow-up and no hysterectomy (control group). Aggregate tissue measurement and total number of EMR fragments were recorded. H&E stained slides were evaluated for features of an abnormal endometrial distribution suggestive of adenomyosis: Number of fragments with endometrium on opposite edges (separated by myometrium), number of fragments with endometrium in 3 edges or more, and number of fragments containing areas of endometrium completely surrounded by myometrium (endometrial islands). Hysterectomy specimens of the study group were evaluated for the presence of adenomyosis and its distribution (superficial vs deep). Unpaired t test was used for analysis.

Results: The study and control groups consisted of 18 patients each. The number of fragments with endometrium on opposite sides was significantly higher in the study group (mean 2.11) compared to the control group (mean 0.94, $p=0.005$). In contrast, maximum aggregate dimension (2.3 cm vs 2.79 cm), number of fragments with endometrium on three sides (4.5 vs 2.78) and number of fragments with endometrial islands (4.5 vs 4.11) did not significantly differ between study and control groups. Adenomyosis was seen in 13/18 hysterectomies of the study group (72.2%); 5 of these (27.8%) involved deep myometrium. None of the EMR features assessed were statistically associated with deep adenomyosis.

Conclusions: An abnormal distribution of endometrium in EMR specimens, particularly endometrium lining opposite sides of a myometrial fragment, appears to be indicative of future ablation failure and need for definitive surgery. Thus, examination and reporting of such distribution may have clinical value. Adenomyosis is frequent in patients with ablation failure. While our findings suggest a relationship between an abnormal endometrial distribution in EMR and adenomyosis, a significant association with deep adenomyosis was not observed.

1106 A Standardized Endometrial Carcinoma Lymph Node Processing Protocol Increases Lymph Node Counts but Does Not Increase Detection of Metastases

Joseph Carlson, Denis Nastic, Babylonia Tibert, Sahar Salehi, Henrik Falconer. Karolinska University Hospital, Stockholm, Sweden.

Background: Lymphadenectomy in endometrial carcinoma allows improved staging, but can lead to increased morbidity. Identification of metastases can affect choice of subsequent treatment. Proper processing of lymphadenectomy specimens is critical in patient management, however, there are currently no standardized guidelines for handling these specimens. Lymph node counts are also used as indicators of surgical quality. The current study evaluates a proposed standardized method for lymphadenectomy processing.

Design: In May, 2014, a standardized protocol for processing lymphadenectomy specimens was introduced in the Department of Pathology. This is a retrospective study evaluating the impact of this protocol, by comparing results pre- and post-protocol implementation.

Results: A total of 163 lymphadenectomy specimens were evaluated in this study, including 106 pre- and 57 post-protocol. The mean patient age was 63.3 years. Tumor subtypes included 107 endometrioid, 32 serous, 5 clear cell, 15 carcinosarcomas and 4 undifferentiated. A total of 216 lymph node metastases were detected out of 4547 resected lymph nodes (4.8%). A total of 51 patients were diagnosed with one or more metastases (31.3%).

Comparing pre- and post-protocol, total lymph node counts increased, from 23.3 (SD=14.4) to 36.5 (SD=20.6) ($p<0.0001$). The mean number of lymph nodes affected per patient increased slightly, but this was not statistically significant (PRE: 3.8; POST: 5.00). The percentage of patients with one or more lymph node metastasis was unchanged (PRE: 33/106=31.1%; POST: 18/57=31.6%).

Conclusions: Introduction of a standardized protocol led to a statistically significant increase in the number of identified lymph nodes. Increased lymph node counts did not result in a detectable improvement in the detection of patients with metastatic disease. The protocol had the advantage of standardizing expectations between surgeons and pathologists, thereby reducing uncertainty. Lymph node counts are currently being evaluated as a possible quality parameter within surgical treatment of endometrial carcinoma, and thus a standardized method of processing lymph nodes is essential. The proposed protocol may serve as a model for processing of lymphadenectomy specimens.

1107 Do Antibody Clones of PD-L1 and PD-1 Expressing Tumor Infiltrating Lymphocytes in Cervical Tumors Matter?

Luis F Carrillo, Peter N Bonneau, Alexander C Mackinnon, Irene Aguilera-Barrantes. Medical College of Wisconsin, Milwaukee, WI.

Background: PD-L1 expression and PD-1 positive tumor infiltrating lymphocytes (TILs) have been associated with various solid tumors. Therapies developed against PD-L1 have been suggested to show strong anti-tumor response, suggesting potential clinical utility for these markers. To date, few studies have examined the expression of PD-L1 and PD-1 positive TILs within cervical tumors, and none comparing available antibody clones. The objective of this study was to evaluate cervical tumor for expression of PD-L1 and PD-1 positive TILs using different antibody clones for each marker.

Design: A tissue microarray was constructed with 27 cervical tumors. IHC for PDL-1 (Cell Signaling, E1L3N; Spring BioScience, SP142) and PD-1 (Abcam, NAT105; Biocare, NAT105) were performed on all cervical tumors. Any cytoplasmic or membranous staining was recorded as positive for both PD-L1 and PD-1, with a case considered positive for PD-1 with the finding of any positive TILs. Positive TILs were counted within a single 400x high-power field (HPF), using a hot-spot approach.

Results: PD-L1 tumor positivity and PD-1 positive TILs were observed frequently in both squamous cell carcinomas and cervical adenocarcinomas. There was no significant difference observed between staining for either PD-L1 clone or PD-1 manufacturers. Staining for PD-L1 was often only weak and focal.

	PD-L1 E1L3N Positive (%)	PD-1 SP142 Positive (%)	PD-1 NAT 105 Abcam Positive (%) (TIL/HPF)	PD-1 NAT105 Biocare Positive (%) (TIL/HPF)
All cervix	18/27 (67%)	16/27 (59%)	27/27 (100%) (0-41)	27/27 (100%) (1-42)
SCC	11/11 (100%)	10/11 (91%)	11/11 (100%) (3-18)	11/11 (100%) (3-35)
All AdenoCa	7/14 (50%)	6/14 (43%)	14/14 (100%) (2-38)	14/14 (100%) (1-42)
AdenoCa, Intestinal	2/2 (100%)	1/2 (50%)	2/2 (100%) (15-38)	2/2 (100%) (33-42)
AdenoCa, Endometrioid	1/2 (50%)	1/2 (50%)	2/2 (100%) (8-11)	2/2 (100%) (12-18)
Others	0/2 (0%)	2/2 (100%)	2/2 (100%) (8-18)	2/2 (100%) (10-17)

Conclusions: PD-L1 and PD-1 positive TILs are often associated with cervical tumors, with positivity found in nearly all squamous cell carcinomas tested. The antibody clone or manufacturer used does not significantly affect positivity.

1108 PAX-8 Expression in Women with Reactive Mesothelial Proliferations of the Peritoneal Cavity

Cody Carter, Andrew Sciallis. University of Michigan Health System, Ann Arbor, MI.

Background: PAX-8 is a transcription factor essential for development of the kidney, thyroid, and Müllerian organs. Immunohistochemistry for the PAX-8 protein is seen as a sensitive and specific marker for most tumors from these organs. It is often used in the differential diagnostic work-up of papillary lesions of the peritoneal cavity, specifically as to whether a papillary proliferation is mesothelial ("PAX-8 negative") or Müllerian ("PAX-8 positive"). However, the immunoprofile of non-neoplastic mesothelial proliferations in women with respect to PAX-8 is not well known.

Recently, we have seen institutional and consultation cases of reactive mesothelial proliferations in women which have morphologically resembled epithelial tumors and were diffusely positive for PAX-8. We present our experience with PAX-8 immunostaining in a series of female patients with incidentally-found reactive mesothelial proliferations.

Design: We searched our institutional and consultative archives for cases of mesothelial hyperplasia. All available H&E-stained slides from these cases were re-reviewed retrospectively and relevant clinical history was recorded. Immunohistochemistry for PAX-8 and two sensitive mesothelial makers (D2-40 and calretinin) were performed on selected representative blocks. Immunoreactivity for PAX-8 was arbitrarily designated as diffusely positive (> 75% of cells), positive (50-74%), patchy positive (6-49%), focally positive (1-5%), or negative (< 1%), and staining intensity was designated as strong or weak.

Results: Our final study group consisted of 17 women (average age at diagnosis 34 years, range 9-73) with reactive mesothelial proliferations. Medical history/indications for surgery were variable and included non-neoplastic (n=7) and neoplastic (n=10) conditions.

PAX-8 immunorexpression was seen in 4 patients (24%; 3 patients with diffuse and strong staining, 1 patient patchy and strong staining). All 4 patients underwent surgery for non-neoplastic conditions (2 patients with endometriosis, 1 with appendicitis, 1 with ruptured ectopic pregnancy). In 1 case, the morphology of the mesothelial proliferation was distinctly papillary. D2-40 and calretinin immunostains were strongly positive in all cases.

Conclusions: Although PAX-8 expression was seen in a minority of cases, when positive it can be diffuse and strong. While PAX-8 immunohistochemistry can be a diagnostic aid in morphologically challenging cases, a panel of immunostains should be employed as PAX-8 staining can occur in reactive mesothelial proliferations.

1109 Objective, Domain-Specific HER2 Measurement in Uterine and Ovarian Serous Carcinomas and Its Clinical Significance

Daniel Carvajal-Hausdorf, Kurt Schalper, Yalai Bai, Jonathan Black, Alessandro D Santin, David L Rimm. Yale University School of Medicine, New Haven, CT.

Background: HER2 overexpression/amplification is identified in up to 40% of uterine serous (USC) and 10% of ovarian serous carcinomas (OSC). However, clinical trials using various HER2-targeted agents have failed to show significant responses. FDA-approved HER2 assays target only the protein's intracellular domain (ICD) and not the extracellular domain (ECD). Previous quantitative studies in breast cancer by our group have shown that the ICD of HER2 is expressed in some cases that do not express the HER2 ECD. We measured HER2 ICD and ECD in USC and OSC samples, and determined their relationship with clinico-pathologic characteristics and survival.

Design: We measured HER2 ICD and ECD levels in 2 cohorts of USC and OSC comprising 102 and 175 patients, respectively. HER2 antibodies targeting ICD (CB11) and ECD (SP3) were validated and standardized using the AQUA® method of quantitative immunofluorescence (QIF) and a previously reported HER2 standardization tissue microarray (TMA). Median cut-point was used to stratify patients according to HER2 ICD/ECD status.

Results: In USC, 32% of patients with high HER2 ICD had low ECD levels (16/50 patients). HER2 ECD was associated with younger age ($P=0.007$). HER2 ICD and ECD levels were not associated with survival. In OSC, 39% of patients with high HER2 ICD had low ECD levels (34/87 patients). There was no association of HER2 ICD/ECD status with age and staging. HER2 ICD-high status was significantly associated with longer disease-specific survival (DSS) (log-rank $P=0.019$, HR=0.53, 95% CI: 0.32-0.90). HER2 ECD was not associated with survival. HER2 ICD-high status was independent predictor of better outcome in a Cox proportional hazards model including age and stage.

Conclusions: Using objective, domain-specific HER2 measurement, approximately one third of USC and OSC patients with high HER2 ICD levels do not show uniform overexpression of the ECD. This may be related to the presence of p95 HER2, an oncogenic fragment generated by full protein cleavage or alternative initiation of translation. These observations raise the possibility that USC/OSCs that express low ECD despite gene amplification (and HER2 positivity by ICD-targeted antibodies) may benefit less from therapies that target the extracellular domain (e.g. trastuzumab) and more from kinase inhibitors (e.g. lapatinib or afatinib) that target the intracellular domain.

1110 Cytological Recognition of Serous Tubal Intraepithelial Carcinoma from Tubal Cytology and and Pelvic Washing Samples

Hao Chen, Robert R Klein, Stacy J Arnold, Li Li, Setsuko K Chambers, F Zahra Aly, Wenxin Zheng. University of Arizona, Tucson, AZ.

Background: High-grade serous carcinoma (HGSC) is a significant cause of mortality in women mainly due to advanced stage of presentation. The secretory cells within the epithelium lining the fallopian tube have been proposed as the cell of origin for the majority of ovarian HGSC. The earliest recognized histologic precursor lesion of HGSC is serous tubal intraepithelial carcinoma (STIC). In our previous study, we characterized the distinct cytological features of malignant fallopian tube epithelium. In the current study, we attempt to test the sensitivity of detecting HGSC and STIC using the same established cytological criteria of fallopian tube sampling. Finally, we explore the usage of the biomarkers IMP3 and P53 in detection of STIC and HGSC in pelvic washings specimen.

Design: A total of 56 tubal specimens collected from 38 patients who underwent bilateral salpingo-oophorectomy (BSO) due to various indications including pelvic mass suspicious for malignancy, benign disorders, and prophylactic BSO. A standard procedure using cytobrush to collect epithelial cells from tubal fimbria is performed as previously described. The fallopian tube was then entirely submitted for histological examination. Correlation between tubal cytology and histological findings of the tube or pelvic washings was performed. IHC staining for IMP3 and p53 was performed when cytological atypia was seen.

Results: Diagnoses from tubal brushings divided into 3 categories and the number of each category are recorded as follows: benign (n=36), atypical (n=7) and a combined suspicious and confirmed malignancy (n=11). The cytological diagnosis of malignant or suspicious for malignancy is highly correlated with the histological finding of HGSC (100%). Interestingly, two malignant cytology specimens showed no invasive cancers within the fallopian tube. However, STIC was found. Cytological evaluation of pelvic washing is positive in 7 of 9 patients with histological diagnosis of HGSC. IMP3 and p53 immunostaining of pelvic staining highlight malignant cell clusters and intraepithelial neoplasm. Both IMP3 and p53 staining are negative in atypical cell clusters.

Conclusions: The cytological approach by obtaining tubal epithelial cells has potential to be a useful method for ovarian cancer screening and early detection. Fallopian tube cytology is more sensitive in detecting HGSC and STIC than pelvic washing cytology. IMP3 and p53 immunostaining is helpful in detecting intraepithelial neoplasm in pelvic washing specimen.

1111 Immunohistochemical Profiling of Endometrial Serous Carcinoma
Wenqian Chen, Arjumand Husain, Gregg Nelson, Peter Rambau, Sandra Lee, Maire Duggan, Cheng-Han Lee, Martin Kobel. University of Calgary, Calgary, AB, Canada; Tom Baker Cancer Center, Calgary, AB, Canada; University of Alberta, Edmonton, AB, Canada; Chinook Regional Hospital, Lethbridge, AB, Canada.

Background: Endometrial serous carcinoma (ESC) is an aggressive neoplasm occurring in older women. The objective of this study is to i) to refine immunohistochemical (IHC) panels to encompass differential diagnoses endometrioid grade 3 (EC3) and clear cell carcinomas (CCC); ii) to explore, which biomarker differentiates it from ovarian high-grade serous carcinomas (HGSC); and iii) to explore whether IHC expression as a surrogate for molecular alterations is a prognostic factor.

Design: 52 ESC from a single institution were assessed for 16 IHC markers, including ARID1A, CCNE1, ER, HNF1B, FBXW7, IGF2BP3, NAPS, CDKN2A, TP53, PAX8, PGR, PTEN, TFF3, VIM and WT1. ERBB2 chromogenic *in situ* hybridization (CISH) was evaluated on tissue microarrays. Statistics analysis was performed.

Results: All ESC showed aberrant TP53, normal mismatch repair protein, retained ARID1A and PTEN expression. A panel of TP53, PTEN and CDKN2A had a sensitivity of 93.6% (95% CI, 84-98%) and specificity of 87.8% (95% CI, 75-95%) for ESC versus EC3, a panel of NAPS and ER had a sensitivity of 97.9% (95% CI, 89-99%) and specificity of 72.2% (95% CI, 46-90%) for ESC versus CCC, and WT1 alone had a sensitivity of 66.0% (95% CI, 51-79%) and specificity of 98.0% (95% CI, 94-99%) for ESC versus HGSC. Among all 52 ESCs, ERBB2 amplification was present in 23%, FBXW7 expression was absent in 10%, and CCNE1 was overexpressed in 59%. However, none of those was associated with prognosis.

Conclusions: This study demonstrated ubiquitous aberrant TP53 expression, absence of PTEN, preserved mismatch repair protein expression, ARID1A abnormalities, and high expression levels of ER in ESC. This will support the value of IHC marker panels for histotyping of high grade endometrial carcinomas.

1112 ES/PNET, A Potential for Misdiagnosis: Clinicopathologic and Molecular Cytogenetic Analysis of 5 Cases with Literature Review

Yufan Cheng, Rui Bi, Bin Chang, Wentao Yang, Xiaoyu Tu, Jian Wang. Fudan University Shanghai Cancer Center, Shanghai, China.

Background: Ewing sarcoma/primitive neuroectodermal tumors (ES/PNET) constitute a family of neoplasms characterized by a continuum of neuroectodermal differentiation. The most common primary site of involvement is along the central axis, particularly the chest (Askin tumor). ES/PNET of the genital tract is very rare, especially of uterine corpus and cervix, always presenting a diagnostic challenge. We describe 5 cases here, with the emphasis on the clinicopathologic and molecular cytogenetic features.

Design: We describe 5 cases here, with the emphasis on their clinicopathologic and molecular cytogenetic features.

Results: The patients ranged in age from 13 to 42 years (average 28 years). Lower abdominal pain and abnormal uterine bleeding were the most common symptoms. 3 cases located in cervix. 2 cases arised in uterine corpus, with one of them involving pelvic organs. 4 patients underwent total abdominal hysterectomy and bilateral salpingo-oophorectomy and, in one patient, pelvic lymphadenectomy. 1 patient accepted a submucosal tumor resection. Histologically the tumor was composed of uniform, rounded, oval and sometimes spindle shaped cells with a narrow rim of eosinophilic cytoplasm. Slim fibrous septa were occasionally seen between the tumor cell nests. In one case, neoplastic cells focally formed neuroectodermal rosettes. Mitoses and coagulative necrosis were easily found. By immunohistochemical studies, the tumor cells of all of the 5 cases were positive for CD99, Vimentin, negative for P63, Desmin, HMB45 and CD10. 4 of them were positive for cytokeratin (AE1/AE3) and synaptophysin. It was noted that most of the cases presented definitely AE1/AE3 immunostain and in one of them, P16 positive stain was also identified, resulting in a diagnostic confusion with small cell carcinoma. In all of the 5 cases, molecular testing demonstrated the rearrangement of EWSR1 gene, which confirmed the diagnosis of ES/PNET.

Conclusions: As small cell carcinoma (SCC) is more frequently seen in uterine cervix and corpus, the overlapping features between ES/PNET and SCC may lead to a misdiagnosis. Therefore, a timely confirmation with molecular analysis is essential for the diagnosis.

1113 Overdiagnosis of HSIL (CIN 2): Four Nonspecific p16 Immunohistochemistry Patterns

Jennifer L Clark, Yuxin Liu. University of Massachusetts Medical School, Worcester, MA.

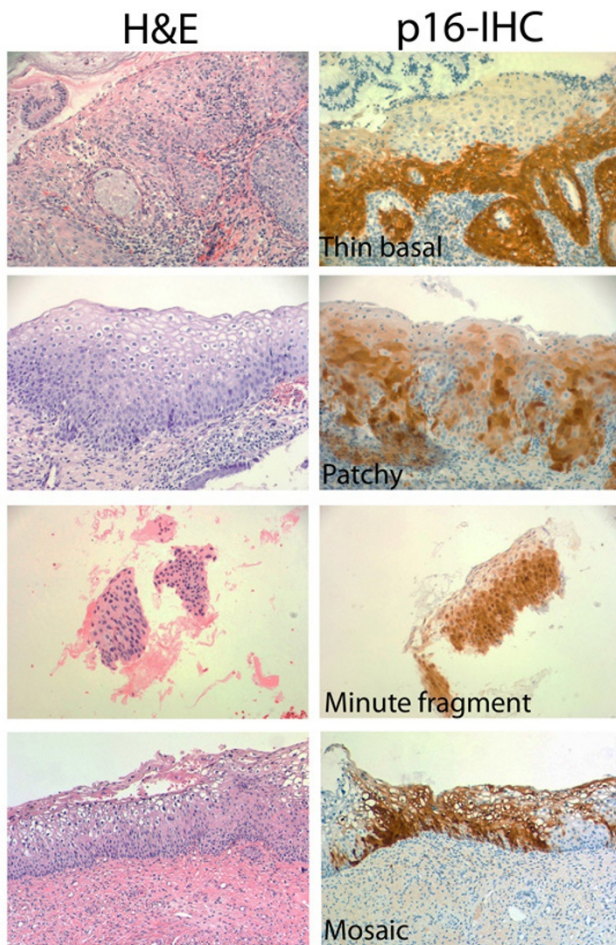
Background: The LAST project recommends p16-IHC to classify putative CIN2 into LSIL or HSIL. HSIL is supported by strong, diffuse, "block-like" p16 staining pattern. Our aim was to assess the impact of implementing p16-IHC and various clinical outcomes of this emerging group, "p16-classified HSIL."

Design: We searched the UMass database for patients fulfilling the criteria: HSIL diagnosis on biopsy, p16-IHC performed, and two-year surveillance. Medical charts were reviewed.

Results: Among 210 eligible patients, HSIL was present in 136 (65%) subsequent LEEPs and absent in 74 (35%). These 74 patients underwent surveillance for two years, revealing no high-grade lesions. On review of these 74 cases, 42 (57%) showed concurrence, while 32 (43%) were downgraded to LSIL based on morphology and nonspecific p16 staining. Table 1 shows the clinicopathological characteristics of these 32 patients whose p16-IHC revealed 4 nonspecific patterns (Table 2, Figure 1): thin basal (n=13;41%), patchy (n=12;37%), minute fragment (n=5;16%), and mosaic (n=2;6%).

	N (%)
Age	
<40 years	25(78%)
≥40 years	7 (22%)
Pap smear	
High-grade	8 (25%)
Low-grade or less	24 (75%)
HPV status	
Positive	14 (44%)
Negative	2 (6%)
Unknown	16 (50%)
Two-year follow-up	
Negative LEEP	11 (34%)
Low-grade or less on biopsy or cytology	21 (69%)

p16 staining pattern	Description	N (%)
<i>Thin basal</i>	continuous, strong, but limited to lower 1/3	13 (40%)
<i>Patchy</i>	discontinuous and weak	12 (38%)
<i>Minute fragment</i>	small free-floating tissue	5 (16%)
<i>Mosaic</i>	strong nuclear/membrane staining, clear cytoplasm	2 (6%)



Conclusions: 35% of patients with “p16-classified HSIL” reveal no high-grade lesions in subsequent excision and surveillance for two years. 43% were overdiagnosed as HSIL due to overuse p16-IHC on unequivocal CIN1 or mistaking p16 nonspecific staining patterns as positive. Pathologists should follow LAST recommendations with special attention to nonspecific p16 staining.

1114 Clinical Outcomes of hrHPV-Positive/Cytology-Negative Patients
Lani K Clinton, Jordan K Kondo, Pamela Tauchi-Nishi, David Shimizu. University of Hawaii Pathology Residency Program, Honolulu, HI; Queen’s Medical Center, Honolulu, HI.

Background: Women with high-risk (hr) human papillomavirus (HPV)+/cytology- Pap tests are a diagnostic dilemma. Although higher rates of HSIL are found with hrHPV despite negative cytology, colposcopy for all may be unnecessary. The presence of HPV 16/18/45 may identify patients at increased risk for HSIL. We assessed clinical outcomes of hrHPV+/cytology- patients to aid the management of this challenging population.

Design: This is a case series study consisting of a retrospective review of hrHPV+/cytology- Pap tests and HPV subtyping from September 1, 2011 to July 14, 2015.

Results: During the 46.5-month study, we found 996 HPV+/cytology- cases with 280 (28%) follow-up. 152 (54%) and 128 (46%) had histologic and only cytologic follow-up, respectively. Histologic HSIL was highest in the 30-39 years group at 20%; HSIL was reported in 21 (14%) overall. HPV 16/18/45 genotyping was performed on 237 (24%); 32 (14%) were positive for HPV 16 (7%), HPV 18/45 (6%), or HPV 16 and 18 (<1%). HSIL was found in 4 (44%) of HPV 16/18/45+ specimens and ≤LSIL in 5 (56%). Among 5 HPV16+ cases, 2 (40%) had HSIL and 3 (60%) had ≤LSIL. Among 3 HPV18/45+ cases, 1 (33%) had HSIL and 2 (67%) had ≤LSIL. The single HPV16+18+ case had HSIL. Among 11 HPV16/18/45- cases, 1 (9%) had HSIL and 10 (91%) had ≤LSIL.

Table 1. Age-stratified follow-up for HPV+/cytology- patients

Age, y	Histopathologic follow-up				Cytologic follow-up		
		≥HSIL(%)	≤LSIL(%)		≥HSIL(%)	≤LSIL(%)	
≤29	26	15 (1(7))	14(93)	11	0	11(100)	
30-39	126	65 (13(20))	52(80)	61	1(2)	60(98)	
40-49	66	42 (4(10))	38(90)	24	0	24(100)	
50-59	43	20 (3(15))	17(85)	23	0	23(100)	
≥60	19	10 (0)	10(100)	9	0	9(100)	
Total	280	152 (21(14))	131(86)	128	1(1)	127(99)	

Table 2. Histologic follow-up for HPV subtyping

	No.(%)	Histologic follow-up(%)	≥HSIL	≤LSIL
HPV 16/18/45-	205(86)	11(5)	1(9)	10(91)
HPV 16/18/45+				
HPV 16+	17(7)	5(29)	2(40)	3(60)
HPV 18/45+	14(6)	3(21)	1(33)	2(67)
HPV 16/18+	1(<1)	1(100)	1(100)	0
HPV 16/18/45+ Total	32(14)	9(28)	4(44)	5(56)

Conclusions: Overall, we found 14% of HPV+/cytology- patients harbored HSIL on histologic follow-up. Previous reports of HSIL range from 2-11%. Moreover, HPV subtyping shows a higher rate of HSIL for those that are HPV16/18/45+ at 44%, making these patients better candidates for colposcopy, and supporting the practice of HPV subtyping in this group.

1115 A Reassessment of the Incidence of Hydatidiform Molar Disease as Defined by Histopathologic and Molecular Analysis

Terence Colgan, Martin C Chang, Shabin Nanji, Elena Kolomietz. Mount Sinai Hospital, Toronto, ON, Canada.

Background: Hydatidiform molar disease (HMD), consisting of complete mole (CM) and partial mole (PM), is a non-neoplastic proliferative disorder of the placental villi and may develop into gestational trophoblastic neoplasia (GTN). Most studies of the incidence of HMD have relied upon morphologic diagnosis and were conducted before both the routine use of obstetrical ultrasound (ObU/S) to detect abnormalities and the medical management of spontaneous and missed abortions. Our retrospective institution-based study aimed to re-assess the incidence of HMD and the CM: PM ratio when the diagnosis of HMD is made by histopathology with the selective use of p57 immunohistochemistry (IHC) and molecular genotyping (MG).

Design: Consecutive hospital cases of HMD and number of deliveries were identified over a 27 month period. A diagnosis of CM required the typical histopathologic appearance for CM alone, or atypical villous morphology (AVM) with absent IHC villous staining. A diagnosis of PM required the typical appearance for PM, or AVM suspicious for PM and MG findings of diandric triploidy or triploidy. MG analysis determining parental contribution was performed on microdissected formalin fixed paraffin embedded sections of maternal and conceptus tissues using QF-PCR analysis of 19 polymorphic short tandem repeat markers.

Results: Forty-nine HMD cases were identified: 18 CMs and 31 PMs. IHC confirmed the diagnosis in 17/18 CM’s. No MG was performed in the CMs. MG was performed in 24/31 PMs since histopathology was equivocal; diandric triploidy was identified in 21 cases and triploidy in 3 cases. The average number of monthly deliveries was 558. If the expected incidence of HMD in North America is between 1.0 and 2.0 per 1000 deliveries is assumed to represent a normally distributed 1-sigma confidence interval, our observed HMD incidence (3.1 /1000) is significantly greater than this expected incidence ($p < 0.001$).

Conclusions: The true incidence of HMD may be higher than has been appreciated previously. This finding is likely attributable to increased detection of placental abnormalities by ObU/S and the ability of MG to definitively identify PM in cases which are equivocal by histopathology alone. The CM: PM ratio of 18/31 approaches 1:2, and could provide a useful laboratory benchmark. Some GTN cases with an apparent history of abortion only could be attributable to undetected HMD.

1116 The Detection of Aneuploidy in Non-Molar Abortuses through Selective DNA Genotyping in Cases of Suspected Hydatidiform Mole

Terence Colgan, Martin C Chang, Shabin Nanji, Elena Kolomietz. Mount Sinai Hospital, Toronto, ON, Canada.

Background: In our institution the pathologic diagnosis and classification of hydatidiform molar disease (HMD), consisting of complete mole (CM) and partial mole (PM), are made using histopathology and in select cases, p57 immunohistochemistry and molecular genotyping (MG). Non-molar abortuses (NMA) mimicking PM can be

distinguished from true PM by MG with high accuracy. In this retrospective institution-based study we aimed to assess whether this method yields a second benefit – the detection of clinically relevant aneuploidy in NMAs.

Design: Cases of atypical villous morphology (AVM) suspicious for, but non-diagnostic, of HMD were submitted for MG. The MG analysis was performed on microdissected formalin fixed paraffin embedded sections of conceptus and maternal tissues using QF-PCR analysis of 19 polymorphic short tandem repeat markers (STRs) on chromosomes 13, 18, 21, X, and Y. Informative MG results, final diagnosis, and number and type of aneuploid AVM cases were tabulated over a 42 month period.

Results: The final diagnosis of the 114 informative MG tests of AVM was 47 PM, 62 NMA, and 5 CM. Of the NMA cases, our MG panel identified aneuploidy in 9/62 (14.5%) cases. These consisted of 4 cases of trisomy 18, 2 of trisomy 13, and 3 of monosomy X. Non-molar aneuploidy composed 9/114 (8%) of all informative MG tests of AVM.

Conclusions: MG using a panel of STRs to analyze cases of AVM suspicious for HMD can detect cases of aneuploidy in addition to its diagnostic utility. Further counselling may be warranted if future pregnancies are being considered. For example, following detection of a trisomy 13, parental chromosomal studies should be undertaken to detect a Robertsonian translocation in a parent with its associated increased recurrent risk of aneuploidy. MG analysis of AVM suspicious for HMD not only improves diagnostic accuracy, but can detect clinically relevant aneuploidy in NMA.

1117 The Prevalence of Vulvar Lichen Sclerosus in Patients with Vulvar Squamous Cell Carcinoma

Jonathan Davick, Colleen Stockdale, James T Krone, Megan I Samuelson. University of Virginia, Charlottesville, VA; University of Iowa, Iowa City, IA.

Background: Women with vulvar lichen sclerosus (LS) have an increased risk of developing differentiated vulvar intraepithelial neoplasia (VIN) and vulvar squamous cell carcinoma (SCC). Previous studies have indicated that 4 to 7% of women with LS will go on to develop vulvar SCC. Because of its strong association with differentiated VIN, LS is an important disorder for both clinicians and pathologists to recognize. Our primary aim was to determine the prevalence of LS among women with vulvar SCC. Additionally, we were interested in any relationship between the grade of the excised SCC and the presence or absence of LS.

Design: Following IRB approval, all patients who underwent excision for invasive SCC of the vulva from 1/1/2009 through 12/31/2014 were identified by searching the University of Iowa Hospitals and Clinics' laboratory information system (n=111). The hematoxylin and eosin (H&E) stained sections from cases that identified SCC on excision but made no mention of LS in the original pathology report were reviewed by an expert gynecologic pathologist (MS). These cases were reviewed for evidence of LS that was not originally reported. Patients who had LS identified in the original pathology report were recorded as such, and the slides for these cases were not reviewed. The grade of the excised SCC was also recorded for all patients in our study population.

Results: The proportion of our study population patients with synchronous LS and vulvar SCC upon excision was 0.29 with 95% confidence interval limits of 0.21 – 0.38. There were 9 patients in our study population who did not have LS identified adjacent to the vulvar SCC on excision, but who did have a previous histopathologic diagnosis of vulvar LS. Using this information, the proportion of patients in our study population who have ever had a histopathologic diagnosis of LS is 0.36 with a 95% confidence interval of 0.28 – 0.45. Thus, 36% of patients who underwent excision for invasive SCC during our study period had a histopathologic diagnosis of LS at one point in their lives. The presence of LS on the excision specimens was not associated with the grade of the adjacent SCC.

Conclusions: Our study is the largest to date to report the prevalence of LS in vulvar SCC excision specimens. Based on the 36% association of LS with vulvar SCC found in our study, we recommend that pathologists and clinicians carefully evaluate and report the presence of LS given its association with differentiated VIN and invasive SCC.

1118 Assessment of the Chemotherapy Response Score (CRS) System in High Grade Serous Carcinoma (HGSC)

Helena M Ditzel, Kyle Stickland, Emily Meserve, Mamta Gupta, Jonathan H Hecht, Doug I Lin, Kirsten M Jochumsen, William R Welch, Michelle Hirsch, Bradley J Quade, Kenneth R Lee, George L Mutter, Christopher P Crum, Marisa R Nucci, Brooke E Howitt. Brigham and Women's Hospital, Harvard Medical School, Boston, MA; Beth Israel Deaconess Medical Center, Harvard Medical School, Boston, MA; Odense University Hospital, University of Southern Denmark, Odense, Denmark.

Background: A Chemotherapy Response Score (CRS) system was recently described to assess the histopathologic response and prognosis of patients with HGSC receiving neoadjuvant chemotherapy (NACT). The current study was performed as an independent assessment of the CRS system.

Design: Cases included 72 patients with stage III-IV HGSC who underwent interval debulking procedures after NACT. One H&E slide of omental (n=68) and/or adnexal (n=61) tumor showing the least treatment effect (selected by one pathologist) were included (n=57 with both omentum and adnexal slides available). All slides were independently scored by 11 pathologists (2 trainees, 2 junior gynecologic pathologists, and 7 senior gynecologic pathologists) from 2 institutions using only the published description of the three-tiered CRS system (Table 1). Interobserver variability was assessed utilizing Fleiss' kappa (κ). Patients were stratified according to consensus CRS. Overall survival (OS) and progression-free survival (PFS) were estimated using the Kaplan-Meier method and were compared using the log-rank test.

Results: The overall interobserver reproducibility was good for omentum (κ 0.64) and moderate for adnexa (κ 0.52). There was no difference between CRS1 and CRS2 for OS and PFS ($p > 0.05$) however, for omental disease, CRS1/2 were associated with a median PFS of 11 months (95%CI 9-14) vs. 22 months (95%CI 18-27) for CRS3

($p=0.006$). An omental score of CRS3 demonstrated a trend toward prolonged median OS, but this was not statistically significant (54 months (95%CI 31-76) for CRS3 vs. 37 months for CRS1/2 (95%CI 25-48) ($p=0.083$)).

Conclusions: The CRS system reported by Böhm et al. appears to offer a relatively reproducible method for predicting PFS, with the favorable prognostic factor being CRS3. Additional web-based training on specific CRS criteria may improve interobserver reproducibility and prognostic value.

Criteria for the Chemotherapy Response Score	
CRS1	No or minimal tumor response.
CRS2	Appreciable tumor response amid viable tumor that is readily identifiable.
CRS3	Complete or near-complete response with minimal irregularly scattered tumor foci seen as individual cells, cell groups, or nodules up to 2mm maximum size.
Reference: Böhm S. et al. J Clin Oncol 33:2457-2463, 2015.	

1119 Mucinous Tumors Involving the Ovary: GREB1 and Pax8 Immunopanel Identifies Ovarian Primaries with High Sensitivity

Bojana Djordjevic, Sarah Strickland, Kendra Hodgkinson, Barbara Vanderhyden, Carlos Parra-Herran. The Ottawa Hospital, University of Ottawa, Ottawa, ON, Canada; Ottawa Hospital Research Institute, University of Ottawa, Ottawa, ON, Canada.

Background: The utility of immunohistochemistry to identify mucinous neoplasms involving the ovary as primary or metastatic is limited. We have recently found that a novel marker, GREB1 (Growth Regulation by Estrogen in Breast cancer 1), an estrogen receptor alpha upregulated protein, is expressed in up to 80% of ovarian mucinous carcinomas. The aim of this project was to assess the performance of GREB1 in distinguishing primary ovarian mucinous neoplasms (POMNs) from gastrointestinal (GI) tumors, both alone and in combination with PAX8, a helpful marker in this differential diagnosis, which we studied previously.

Design: GREB1 immunohistochemistry was applied to tissue arrays consisting of 49 primary GI mucinous adenocarcinomas (19 colorectal, 15 gastric, 15 pancreatobiliary), 58 POMNs (19 cystadenomas, 21 borderline tumors, 18 adenocarcinomas) and 19 metastatic carcinomas to the ovary (14 lower and 5 upper gastrointestinal primaries). GREB1 nuclear staining was scored in terms of intensity (scale 0-3) and percentage of positive cells. Staining was considered positive if 2+ or 3+ intensity was seen in >1% of cells, or if 1+ intensity was seen in $\geq 20\%$ of cells. PAX8 staining was assessed by the same criteria.

Results: GREB1 was expressed in 69% of POMNs and 21% of GI tumors ($p < 0.0001$). GREB1 staining did not differ significantly among different POMN types (72% cystadenomas, 67% borderline tumors, 65% adenocarcinomas). Among GI tumors, GREB1 expression was seen in 0% colorectal, 13% gastric and 33% of pancreatic carcinomas and in 14% of GI metastases to the ovary. PAX8 was expressed in 74% of POMNs and 1% of GI tumors ($p < 0.0001$). Addition of PAX8 enhanced the sensitivity and negative predictive value of GREB1: 93% of POMNs and only 16% of GI tumors were positive for one or both of these markers ($p < 0.0001$).

	GREB 1	Pax 8	GREB 1 and/or Pax
Sensitivity (%)	69	74	93
Specificity (%)	83	99	84
PPV (%)	79	98	83
NPV (%)	74	82	93

Conclusions: For the first time, we document the expression of GREB1 in the spectrum of POMNs and tumors of upper and lower GI origin. The combination of positive GREB1 and/or PAX8 is highly sensitive for tumors of ovarian origin. Thus, GREB1 can be a useful tool in the diagnostic work-up of mucinous tumors involving the ovary.

1120 Architectural Overlap between Benign Endocervix and Pattern A Invasive Endocervical Adenocarcinoma: Are All Pattern A Adenocarcinomas Really Invasive?

Greg Douglas, Brooke E Howitt, John Schoolmeester, Lauren Schwartz, Zuzana Kos, Shahidul Islam, Bojana Djordjevic, Carlos Parra-Herran. University of Ottawa, Ottawa, ON, Canada; Brigham and Women's Hospital, Boston, MA; Mayo Clinic, Rochester, MN; University of Pennsylvania, Philadelphia, PA.

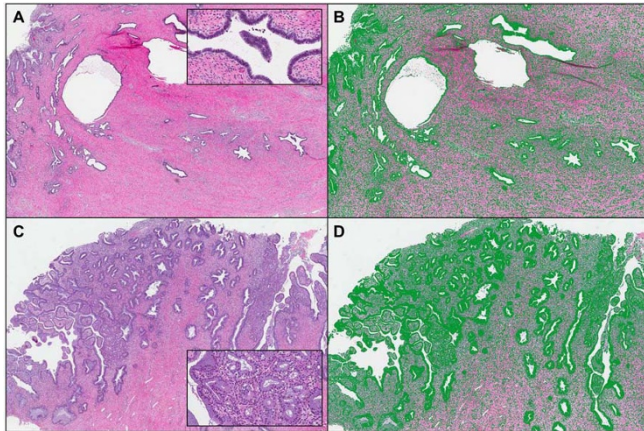
Background: Studies on the proposed pattern based classification (PBC) for invasive endocervical adenocarcinoma (IEA) have shown that tumors with nondestructive invasion (pattern A, IEA-A) have a 0% rate of nodal metastases. Based on the frequent difficulty in distinguishing adenocarcinoma in situ (AIS) from IEA, we hypothesize that some of the so-called IEA-A represent AIS involving areas of benign glandular proliferation.

Design: 13 sections diagnosed independently as IEA-A by three gynecologic pathologists, and 14 sections of benign endocervix (BE) with tunnel clusters, diffuse lamina hyperplasia or normal architecture were selected. Three additional pathologists evaluated a digital image from each section and classified it as IEA-A or BE based on the architecture only. To blind the interpretation to cytologic features, nuclei and cytoplasm were obscured using morphometric software (Zen 2011, Carl Zeiss Microscopy, Germany).

Results: 13/27 cases (48%, 8 IEA-A and 5 BE) were correctly classified by all three reviewers; 19/27 (70%, 10 IEA-A and 9 BE) were correctly classified by at least two reviewers. 3/13 IEA-A cases (23%) were interpreted as BE by at least two reviewers. Conversely, 5/14 BE cases (36%) were interpreted as IEA-A by at least two reviewers.

Conclusions: An abnormal architecture, distinct from BE patterns, is seen in many IEA-As supporting their designation as invasive lesions. However, some cases interpreted as IEA-A have architecture that overlaps with that of BE, thus may represent AIS. In

addition, BE can be architecturally complex and mirror patterns that pathologists would classify as IEA-A if malignant cytologic features were present. Given this overlap and the nil risk of nodal spread of IEA-A, the term “endocervical adenocarcinoma with nondestructive proliferation” can be considered when applying the PBC.



Adenocarcinoma, diagnosed as IEA-A by 3 pathologists (A). Once cytologic details were obscured (B), 3 separate reviewers classified it as BE. In contrast, a case of BE (C) was misdiagnosed as IEA-A by 2/3 reviewers when blinded to cytologic features (D).

1121 Prospective Evaluation of Lymph Node Processing at Staging Surgery for High-Grade Endometrial Cancer

Jessie A Ehrisman, Sara Abbott, Zach Harmon, Angeles Alvarez Secord, Andrew Berchuck, Paula S Lee, Fidel A Valea, Gloria Broadwater, Xuechan Li, Laura J Havrilesky, Allison Hall. Duke University Medical Center, Durham, NC.

Background: Our objective was to determine, in the setting of surgical staging for endometrial cancer (EC): 1) whether processing the additional adipose tissue that remains after gross identification of lymph node (LN) candidates results in the identification of additional LNs; and 2) whether division of LN tissue into nodal basin-specific specimens has any effect on the number of LNs identified.

Design: Following IRB approval and informed consent, a prospectively accrued randomized controlled trial was performed of women with high-grade EC who were scheduled for surgical staging. At surgery, subjects were randomized to collection of LNs into nodal basin-specific containers (e.g., left external iliac, left common iliac) on the randomized side versus simple labeling (right pelvic and right aortic) on the non-randomized side. The total number of LNs and total number of LNs with metastases on the randomized versus the non-randomized side were compared using a one-sided paired t-test. The remaining adipose tissue from each LN specimen was submitted for histologic examination in addition to all grossly identified LN candidates. We analyzed the number of LNs and the number of LNs with metastatic carcinoma identified from the additional adipose tissue.

Results: Of the 120 patients that gave consent, 62 had sufficient tissue and data to be included in this analysis. The additional adipose tissue contained 7.2 additional LNs per patient on average (range, 0-26). In 3/62 total cases (5%) and 3/17 cases with LN metastases (18%), the additional adipose tissue contained LNs with metastatic carcinoma. In all three cases, metastatic disease was also detected in ≥ 1 grossly identified LN candidate. The mean number of LNs identified was not significantly different based on method of specimen collection/submission: 11.1 (randomized side) versus 10.5 (non-randomized side) ($p=24$, $n=52$). Likewise, the mean number of LNs containing metastatic disease per side was not significantly different: 0.31 (randomized) versus 0.37 (non-randomized) ($p=.58$).

Conclusions: LN totals are higher when all of the tissue in LN specimens is examined microscopically. The presence of LNs with metastases in the additional adipose tissue is important because the number of positive LNs has prognostic significance. These findings suggest that submitting all adipose tissue from LN specimens for EC should be considered.

1122 SOX17 Is Highly Expressed in Endometrial Adenocarcinoma

Mohamed El Hag, Tracy A Stein, Bo Ye, Prachi Raut, Haodong Xu, Mahmoud Khalifa, Faqian Li. University of Minnesota Medical Center, Minneapolis, MN; UCLA Medical Center, Los Angeles, CA.

Background: SOX17 is a member of the Sry-related HMG box transcription factor family which play key roles in embryogenesis and development. Expression of SOX17 is regulated through the Wnt/ β -catenin signaling pathway. RT-PCR has shown SOX17 expression in tissues including testis and ovary. However, the utility of SOX17 as a diagnostic/prognostic marker has not been investigated in endometrial adenocarcinoma (EAC). The purpose of this study is to evaluate SOX17 expression patterns in EAC and to determine its prognostic significance, in addition to investigating its relationship with β -catenin.

Design: TMA of 41 endometrial cases (36 EAC and 5 benign endometria) was stained for initial evaluation of SOX17 expression. Subsequently, whole slides from 20 cases representing 12 patients (11 primary EACs and 9 metastatic EACs) were reviewed and stained for SOX17 and β -catenin. The presence and intensity of SOX17 nuclear expression was graded from 0 to 3 and percentage of tumor cells in each grade was

estimated. A total SOX17 intensity score was calculated and used to compare primary versus metastatic disease. Additionally, β -catenin intensity and localization was documented.

Results: SOX17 was positive in 76% of TMA cases (31/41). All benign endometrium TMA specimens stained intensely (3+). 72% of EAC TMA specimens were positive (26/36). Interestingly, all whole slide EAC cases (20/20) stained positively for SOX17, but showed inter- and intra-specimen variation in intensity and percentage of tumor cell positivity, reflecting tumor heterogeneity. Cases of primary EAC had an average SOX17 intensity score of 155.46 and median of 160, compared to metastatic EAC (average 210/median 230). β -catenin showed nuclear positivity in 47% of EAC cases, predominantly in areas of squamous differentiation which were negative for SOX17, in contrast to surrounding SOX17-positive adenocarcinoma.

Conclusions: SOX17 is variably but consistently expressed in EAC. An opposite staining pattern of SOX17 and β -catenin is observed in EAC: β -catenin predominantly highlights squamous differentiation while SOX17 decorates glandular components. Additionally, an increased number of positive tumor cells and increased SOX17 intensity was observed in metastatic disease. However, only 11 primary EAC cases were analyzed, precluding correlation of SOX17 expression with FIGO grade and tumor stage. Further investigation is underway to confirm SOX17 expression in primary versus metastatic disease, as well as the value of SOX17 expression in tumor grading and prognostication.

1123 Evaluation of Microsatellite Instability (MSI) Status in Endometrial Adenocarcinoma by Comprehensive Genomic Profiling (CGP) Identifies Subset That May Benefit from Immunotherapy

Julia A Elvin, Eric M Sanford, Zachary Chalmers, Garrett Frampton, Alessandro D Santini, Jo-Anne Vergilio, James Suh, Laurie Gay, Michael Hall, Evgeny Yakirevich, Alexander Brodsky, Straj M Ali, Vincent A Miller, Philip J Stephens, Jeffrey S Ross, James Sun. Foundation Medicine, Inc., Cambridge, MA; Yale University School of Medicine, New Haven, CT; Albany Medical College, Albany, NY; Fox Chase Cancer Center, Philadelphia, PA; Brown University, Providence, RI.

Background: The PD-1 inhibitor pembrolizumab shows promising activity in advanced endometrial adenocarcinoma (EA) with mismatch repair (MMR) deficiency. We developed and validated a novel computational method to assess microsatellite instability (MSI) using next generation sequencing (NGS) data and applied it to a series of EA previously assayed with CGP.

Design: DNA was extracted from 257 FFPE EA clinical specimens. CGP was performed on hybridization-captured libraries of 315 cancer-related genes plus 47 introns from 19 genes frequently rearranged in cancer. 114 intronic homopolymer repeat loci (10-20bp long in the human reference genome) were analyzed for length variability and compiled into an overall MSI score via principal components analysis. Predictions of MSI-H (High) or MSS (MSI-Stable) were validated against colorectal and EA in which MSI status was previously determined by PCR or IHC, showing an overall concordance of 97% (65/67).

Results: MSI status was determined for 257 consecutive, predominantly advanced-stage EAs from women with a median age of 65 yrs (range: 24-88 yrs). 45 (17.5%) cases were identified as MSI-H and showed a correlation with non-serous/clear cell histology: 33 of 115 (29%) endometrioid; 10 of 32 (24%) mixed/non-serous; 2 of 82 (2.4%; Fisher's $p < .0001$) serous, and 0 of 16 clear cell ($p < .0001$). Known or likely MMR GA were identified in 18 of 45 MSI-H cases (40%) compared to 4 of the 215 (1.8%; $p < .0001$) MSS cases. Of the MSI-H cases with MMR GA, 8 *MSH-6*, 7 *MSH-2*, 3 *MLH1*, and 1 *PMS2* GA were observed. 3 of 4 MSS-MMR mutated cases had a co-occurring *POLE* GA and a hypermutated non-in/del signature; the fourth case had a low mutation burden. Rates of co-occurring GA were similar ($p > .019$) between MSI-H and MSS EA in *PIK3CA* (61%; 46%), *CTNNB1* (24%; 39%), *TP53* (24%; 34%), *PIK3R1* (30%; 23%), *KRAS* (30%; 20%), but *GA PTEN*, *ARID1A*, and *MLL2* were significantly more frequent ($p < 0.0001$) in MSI-H EA cases.

Conclusions: Assessing EA MSI status by CGP detects 150% more patients who may benefit from immunotherapy compared to detecting GA in MMR pathway genes alone, while simultaneously detecting other clinically relevant GA which may be matched to targeted therapies.

1124 Lymph Node Metastases in Low Grade Endometrial Carcinoma (LGEC): What Matters?

Elizabeth D Euscher, Genevieve R Lyons, Roland L Bassett, Elvio Silva, Anais Malpica. MD Anderson Cancer Center, Houston, TX.

Background: Characteristics of lymph node (LN) metastases (mets) in patients (pts) with LGEC and how they relate to pt outcome have not been defined. We undertook this study to address this issue.

Design: 59 LGEC with mets only to LNs treated from 1993-2015 were evaluated for tumor (tu) size, myometrial invasion (MI), cervical stromal invasion (CI), lymphovascular invasion (LVI), microcystic/elongated/fragmented (MELF) or single cell (SCI) patterns of invasion, LN met size, extranodal extension (ECE), glandular (GP) or single cell pattern (SCP) w/in the LN met and tissue reaction w/in the LN met. Therapy (tx) and follow up (f/u) were recorded.

Results: Tu size ranged from 2-12 cm (median 4.5). Cases had the following adverse features: $>50\%$ MI, 35 (59.3%); CI, 10 (16.9%); LVI, 54 (91%); MELF &/or SCI, 45 (76.3%). LN met size ranged from 0.05-38 mm (median 1.8) with 20 <0.2 mm and 42 from 0.2-2.0 mm. LN mets had the following features: ECE, 7 (11.9%); GP, 33 (55.9%); SCP, 26 (44.1%); tissue reaction, 20 (33.9%). 55 pts had adjuvant tx: pelvic radiation (XRT), 23 (39%); chemotx+XRT, 27 (45.8%); chemotx alone, 3 (5.1%); hormone tx, 1 (1.7%); cuff XRT 1 (1.7%). Tx was not given/unknown in 4 pts. 58 pts had f/u data: 6 pts recurred of whom 3 died of disease (DOD). 1 pt DOD after

incomplete lymphadenectomy. 12 pts died of other cause (DOC). 42 pts are alive, no evidence of disease (NED). Table 1 summarizes features of LN mets in pts with adverse events.

Pt	#LN mets	Location largest met	Size largest met (mm)	ECE	Histologic pattern	Tissue reaction	Follow up
1	1	pelvic	1.9	no	SCP	no	DOC
2	2	pelvic	11	no	SCP	yes	NED
3	1	pelvic	25	yes	GP	no	DOD
4	3	paraaortic	20	yes	GP	yes	DOD
5	>3	paraaortic	9	yes	GP	yes	DOD
6	1	paraaortic	4.5	no	GP	yes	NED
7	1	pelvic	18	no	GP	yes	DOD

Uterine factors (tu size, MI, CI, LVI, MELF/SCI) were not significantly associated with progression free (PFS) or overall survival (OS) ($p > 0.05$). Met size was associated with decreased PFS ($p = 0.0411$). Met size, ECE and GP were associated with decreased OS ($p < 0.05$).

Conclusions: Most pts in this study had small LN mets and are NED. No pts with mets < 1.8 mm DOD or recurred. ECE is uncommon (11.9% pts) but associated with decreased OS. Based on a threshold of 1.8 mm, serial sectioning of LNs at 2.0 mm intervals would increase odds of detecting potentially clinically relevant mets. Reporting met size and ECE may help guide adjuvant tx in pts with LN mets.

1125 Patient Outcome Is Not Related to Chemotherapeutic Response Score (CRS)

Elizabeth D Euscher, Roland L Bassett, Anna Yemelyanova, Preetha Ramalingam, Anais Malpica. MD Anderson Cancer Center, Houston, TX.

Background: CRS is an emerging prognostic factor in high grade serous carcinoma (HGSC). Although several CRS methods have been proposed, only one has been validated and none are systematically used in USA. We assessed the role of CRS on patient(pt) outcome.

Design: We evaluated 48 neoadjuvantly treated(tx) (tx initiated 2008-2009) HGSC for presence of features identified in 5 CRS methods: size of viable tumor(tu) foci, fibroinflammatory changes, foamy histiocytes, tu necrosis, tx related cytologic changes. CRS was assigned using features applicable to each method. Because no pt had either complete or absent response, 3 methods had only 2 response categories. Pt age, pretx CA125, FIGO stage, #neoadjuvant chemo cycles, #adjuvant chemo cycles, BRCA status and follow up(f/u) were recorded.

Results: All pts(27-85yo; median 65) had f/u(12-81 mo) with 27 FIGO stage III and 21 FIGO stage IV cases. 3-17 neoadjuvant chemo(median 4) and 0-10 adjuvant chemo(median 3) cycles were given. At last f/u 36 (75%) pts died of disease and of 45 evaluable pts, all but 3 had progression. Median progression free survival(PFS) was 1.3 yrs; overall survival(OS) was 3 yr. Table 1 summarizes Cox models for CRS.

	Score	#Pts	#Deaths	Hazard Ratio	95% CI	p-Value
Method 1	1=mainly viable tu; min regression changes	11	7	--	--	--
	2=multifoc or diffuse regression; resid tu easily id'd	18	15	1.94	0.79, 4.79	0.15
	3=mainly regression; no or all resid tu < 2 mm	19	14	1.21	0.49, 3.00	0.69
Method 2	1=viable tu foci ≤ 3 mm	23	17	--	--	--
	2=viable tu foci > 3 mm	25	19	1.18	0.61, 2.29	0.62
Method 3	1=mild response	11	8	--	--	--
	2=marked response	37	28	1.11	0.51, 2.44	0.79
Method 4	1=persist tu; marked histol changes	36	27	--	--	--
	2=persist tu; no histol changes at least 1 site	12	9	1.01	0.47, 2.15	0.98
Method 5	1=aggregate score > 4 , optimal tx response	9	6	--	--	--
	2=aggregate score < 4	39	30	1.49	0.62, 3.58	0.38

There was no significant association between method, age, FIGO stage, pretx CA125, #neoadjuvant or adjuvant chemo cycles or BRCA status with PFS or OS.

Conclusions: CRS did not correlate with pt outcome in this study possibly related to the mixed response to neoadjuvant tx in most pts or to other factors at the molecular level. Larger studies should be undertaken to evaluate the role of CRS in HGSC before it is universally adopted for pt management.

1126 HNF1 β Expression and Loss of ARID1A Correlate with Histological Component in Uterine Carcinosarcomas

Joana Ferreira, Rita Luz, Fernanda Silva, Ana Felix. IPOLFG, Lisboa, Portugal; Centro Hospitalar de Setubal, Setubal, Portugal; CEDOC-FCMUNL, Lisboa, Portugal.

Background: Uterine carcinosarcomas(UCS) are rare and aggressive neoplasms. Previous studies have shown mutations of the ARID1A gene either by Next Generation Sequencing analysis or loss of expression by immunohistochemistry. It has been suggested that loss of immunohistochemical expression correlates with ARID1A mutation status but this remains to be determined. HNF1 β clusters with ARID1A in

endometriosis associated neoplasia but lacks specificity for any tumor subtype and has not been evaluated in UCS. We aim to characterize ARID1A and HNF1 β immunoprofiles in the different components of UCS and their metastases.

Design: Archival cases of UCS(2000-2014) were retrieved. Tissue microarrays(TMAs) were created with representative epithelial and mesenchymal components for each case and its corresponding metastases when available. TMAs were stained with ARID1A and HNF1 β antibodies. Loss of expression of ARID1A was considered if less than 5% of the cells showed positivity. HNF1 β positivity was considered if more than 5% of the cells showed positivity.

Results: We included 462 tissue samples from 55 patients (median age: 76 years old) of whom 59% presented with stage III/IV disease. Median overall survival was 14 months. Loss of ARID1A expression was observed in 21 subjects(38%). Loss of expression was not seen in all the histological components, being more frequent in the sarcomatous component(25% vs. 21% in the carcinomatous component, $p = 0.05$). In the sarcomatous elements, loss of ARID1A expression was observed more frequently in the heterologous subtypes($p < 0.01$). In 26%(5/19 cases) of metastases there was loss of ARID1A expression. Furthermore, 3 cases showed a discordant ARID1A immunoreactivity between the primary tumor and the metastasis. Ten cases(18%) expressed HNF1 β . This expression was restricted to the carcinomatous component (either endometrial or serous subtypes). In 37% of the metastases(7/19 cases), there was expression of HNF1 β ($p < 0.05$). Among these, four gained HNF1 β expression in the metastasis($p < 0.01$). There was no difference in median survival between the ARID1A+/ARID1A- groups or the HNF1 β +/HNF1 β - groups.

Conclusions: Loss of ARID1A expression is a frequent event in UCS, especially in the sarcomatous heterologous components. Lower rates of mutated ARID1A have been described in UCS and the observed loss of expression may be explained by a non-mutational loss. HNF1 β is exclusively expressed in the carcinomatous component of UCS and is frequently gained in the metastases.

1127 Morphological Diversity in Lichen Sclerosus with Emphasis on Features of Differentiated Vulvar Intraepithelial Neoplasia

William Frampton, Jordan M Newell, Rebecca Phaeton, Joshua P Kesterson, Joshua I Warrick. Penn State Hershey Medical Center, Hershey, PA.

Background: Human papilloma virus (HPV)-independent vulvar squamous cell carcinoma (SCC) typically arises in the setting of lichen sclerosus (LS). Differentiated vulvar intraepithelial neoplasia (dVIN) is the cancer precursor, manifest as atypia with epithelial maturation. LS may have features of dVIN. Distinction between these two is thus often challenging. We therefore set out to document the frequency of morphologic features of dVIN in a consecutive series of vulvar biopsies for LS.

Design: A retrospective series of 73 vulvar biopsies diagnosed as LS was reviewed (2001-2010), all of which had follow up data and no documented anogenital SCC. Histological features of dVIN were documented for each case. Level of development of basal cytologic atypia, cytoplasmic eosinophilia, and architectural complexity were graded by a semi-quantitative score (four-tiered; none, mild, moderate, prominent). Acanthosis, atrophy, orthokeratosis, and parakeratosis were documented as present/absent. Level of intraepithelial inflammation was graded semiquantitatively (four-tiered; none, mild, moderate, prominent).

Results: Cytoplasmic eosinophilia was relatively common, with 25% having moderate or prominent levels of development (16 cases moderate, 2 prominent). Orthokeratosis and parakeratosis were seen in 40% and 15% of cases, respectively. The remaining dVIN features were less common: 12% had architectural complexity (8 cases moderate, 1 case prominent), 12% had acanthosis (9 cases), and 7% had basal cytologic atypia (5 cases, all moderate). 55% were atrophic (40 cases). Correlation analysis (Spearman) showed positive correlations among basal atypia, architectural complexity, acanthosis, and cytoplasmic eosinophilia (r-values range 0.25-0.49; all p-values < 0.05). Level of inflammation did not correlate with any of these features.

Conclusions: Features of dVIN may be seen in a minority of LS lesions without anogenital SCC at follow up. Cytoplasmic eosinophilia is more common than other dVIN features. Although features of dVIN are not infrequent in LS, prominent architectural complexity and basal atypia are rare. Features of dVIN seen in LS tend to occur together, as shown by correlation analysis. The findings indicate a high threshold should be maintained for the diagnosis of dVIN, because an inappropriately low threshold will likely include cases of benign LS.

1128 Twin Placenta with Complete Hydatidiform Mole and Its Mimics in the First Trimester: Histologic Diagnosis and Immunohistochemical Study

Masaharu Fukunaga. Jikei University Daisan Hospital, Tokyo, Japan.

Background: Twin pregnancies

with a normal placenta and complete mole (CM) have a higher risk of persistent trophoblastic disease than conventional CM, and should be differentiated from its mimics, such as partial mole (PM) and CM with mosaicism, for patient management.

Design: Nine cases of morphologically twin pregnancy with CM in the first trimester and three cases of clinically putative twin pregnancy with CM were investigated by immunostaining of p57 (Kip2) (p57) and TSSC3, which are products of paternally-imprinted, maternally-expressed genes. DNA ploidy was also analyzed by flow cytometry in three cases, all of which were diploid. One case was chromosomally analyzed.

Results: Patient ages ranged from 20- 38 years (mean, 32 years), and gestation ranged from 8 to 12 weeks (mean, 8.5 weeks). Clinically, hydatidiform mole was suspected in nine cases, and abortion or blighted ovum was suspected in three cases. The initial pathologic diagnosis was PM in nine cases and CM in three cases. On review, six cases were histologically diagnosed as CM with twins (twin pregnancy with a coexisting normal placenta and CM). The admixture of large hydropic villi with circumscribed trophoblastic hyperplasia and smaller, normal-appearing villi without trophoblastic

hyperplasia was observed in all cases. The cytotrophoblasts and stromal cells in the larger villi were negative for p57 (androgenic) and TSSC3, whereas these cells were positive in the smaller villi (biparental) in six cases. Three cases were conventional CM and two cases were CM with foci of placental mesenchymal dysplasia. In the remaining case, in which larger villi showed 46XX and normal-appearing villi showed 46 XY, cytotrophoblasts in the larger villi diffusely expressed TSSC3. Normal-appearing villi exhibited p57 and PSSC3 expression in a mosaic pattern. No patients developed persistent trophoblastic diseases.

Conclusions: Immunohistochemical analysis is a useful tool for the differential diagnosis of twin placenta with CM and morphologically mimicking cases. Two cases were not twins with CM, but rather CM with androgenic/biparental chimera or mosaic molar gestation and PMD. The single case of twins with CM was suspected to be due to androgenic/biparental chimera or mosaic molar and normal-appearing villi, although molecular cytogenetic analysis was not performed. Immunohistochemistry for the imprint gene products p57 and TSSC3 may be a useful screening tool for cytogenetic analyses.

1129 Malignant Mesonephric Tumors of the Female Genital Tract: A Clinicopathologic Study of 16 Cases Including 4 Cases of Biphasic Tumor with a Sarcomatous Component

Masaharu Fukunaga. Jikei University Daisan Hospital, Tokyo, Japan.

Background: Malignant mesonephric tumors (MMTs) are rare neoplasms of the female genital tract, arising primarily in the cervix, and are defined as adenocarcinomas arising from mesonephric remnants by the WHO classification. Because of their rarity, the biologic behavior of MMTs is not well known. Extrauterine tumors have been rarely reported.

Design: Sixteen cases of MMT were clinicopathologically studied to further understand the histologic diversity, histogenesis, and biologic behavior.

Results: The patients ranged in age from 46 to 76 years (mean, 57 years). There were 12 adenocarcinomas (ACs) and 4 malignant mixed mesonephric tumors (biphasic tumors with a sarcomatoid component) (MMMTs). The ACs were found in the cervix (6), meso-ovary or ovary (3), and uterine body (3). The MMMTs involved the meso-ovary or ovary (2), uterine cervix (1), and uterine body (1). ACs showed variable proliferative patterns, including glandular (ductal), tubular, papillary, retiform, and solid. Of the MMMTs, 3 were homologous and 1 was heterologous (cartilage). One AC and MMMT each had mixed epithelial elements, including serous and endometrioid adenocarcinomas. Mesonephric remnants or hyperplasia was observed in 2 cervical and 2 endometrioid ACs and 1 meso-ovarian MMMT. One ovarian AC was associated with endometriosis. Immunohistochemically, all tumors were positive for CAM5.2, CD10, and calretinin, and negative for ER, PgR, and CEA. Of the 11 patients with follow-up information available (mean, 60 months), 3 patients with MMMT (2 in the meso-ovary or ovary, 1 in the uterine body) died of the disease at 25, 51, and 100 months, respectively, after surgery. No patients with AC and follow-up information died of disease. One patient was alive with lung metastases and the remaining 9 patients had no evidence of disease 6 to 76 months postoperatively.

Conclusions: A diversity of histologic patterns was observed, with 9 cases arising from outside the uterine cervix, and mesonephric remnants or hyperplasia were found in only 5 cases. Because two cases exhibited mixed epithelial elements and one was associated with endometriosis, some MMTs without mesonephric remnants may be identified as adenocarcinomas with mesonephric differentiation. The possibility of a mesonephric tumor should be considered when encountering an unusual-appearing carcinoma, malignant mixed tumor, or even an endometrioid adenocarcinoma. All of the patients with AC and follow-up information survived. In contrast, 3 of the 4 patients with MMMT died of disease. MMMTs may be more aggressive than ACs.

1130 Gene Expression Profiling of Endometrial Carcinoma Type 1 in Mexican Women

Gabriela Sofia Gomez Macias, Oralia Barboza, Raquel Garza, Barbara Saenz. Hospital Universitario de la UANL, Monterrey, Nuevo Leon, Mexico.

Background: Describe the expression profile of 5 genes (*KI67*, *MMP11*, *ESR1*, *PTEN*, *PIK3A*) related to hormonal dependency, rate of cell proliferation, invasion and progression, looking correlate with pathological stage and degree of differentiation in type I endometrial carcinoma.

Design: We designed an observational, descriptive, cross-sectional study. The sample included 107 patients with primary type I endometrial cancer. In each tissue sample, immunohistochemical markers of Ki-67, estrogen receptors and progesterone receptors were performed and the gene expression was determined by PCR-RT. Endometrial carcinoma was staged according to the FIGO. Clinical information was retrieved from the medical records.

Results: A total of 107 patients with primary type I endometrial carcinoma were included in the analysis. The mean age of presentation was 56 years. In respect to grade of differentiation, 2.8% were classified as well differentiated, 76.6% as moderately differentiated, and 20% as poorly differentiated. Overexpression of *MMP11*, high levels of expression of *ESR1* correlated with low grade differentiation carcinomas and early stages. High levels of expression of *Ki67* and *PIK3A* correlated with poor differentiated carcinomas and advanced stages, as well the low levels of *PTEN*.

Conclusions: The expression isolation of the genes previously described for endometrial carcinoma type 1 correlated with expression found in this study with the degrees of differentiation and pathological stages.

1131 Endometrial Carcinomas with POLE Exonuclease Domain Mutations Have a Favorable Prognosis

Blake Gilks, Melissa McConechy, Aline Talhouk, Samuel Leung, Cheng-Han Lee, David G Huntsman, Jessica N McAlpine. University of British Columbia, Vancouver, Canada; University of Alberta, Edmonton, Canada.

Background: The aim of this study was to confirm the prognostic significance of the *POLE* exonuclease domain mutations (EDM) in endometrial carcinoma (EC) patients. In addition, the effect of treatment on *POLE* mutated tumours was assessed.

Design: A retrospective patient cohort of 496 EC patients was identified for targeted sequencing of the *POLE* exonuclease domain ultimately yielding 406 evaluable tumours. Univariable and multivariable analyses were performed to determine the effect of *POLE* mutation status on progression-free survival (PFS), disease-specific survival (DSS) and overall survival (OS). Combining results from eight studies in a meta-analysis, we computed pooled hazard ratios (HR) for PFS, DSS, and OS.

Results: *POLE* EDMs were identified in 39 of 406 (9.6%) ECs. Women with *POLE* mutated ECs were younger, with Stage 1 (92%) tumors, grade 3 (62%), endometrioid histology (82%) and frequent (49%) lymphovascular invasion. In univariable analysis, *POLE* mutated ECs had significantly improved outcomes compared to patients with no EDMs for PFS, DSS and OS. In multivariable analysis, *POLE* EDMs were only significantly associated with improved PFS. The effect of adjuvant treatment on *POLE* mutated cases could not be determined conclusively, however both treated and untreated patients with *POLE* EDM ECs had good outcomes. *POLE* EDMs were associated by meta-analysis with improved PFS and DSS with pooled HRs 0.34 (95% CI 0.15-0.73) and 0.35 (95% CI 0.13-0.92) respectively.

Conclusions: *POLE* EDMs are prognostic markers that predict excellent outcomes for EC patients. Further investigation is needed to determine if treatment is necessary for this group of women.

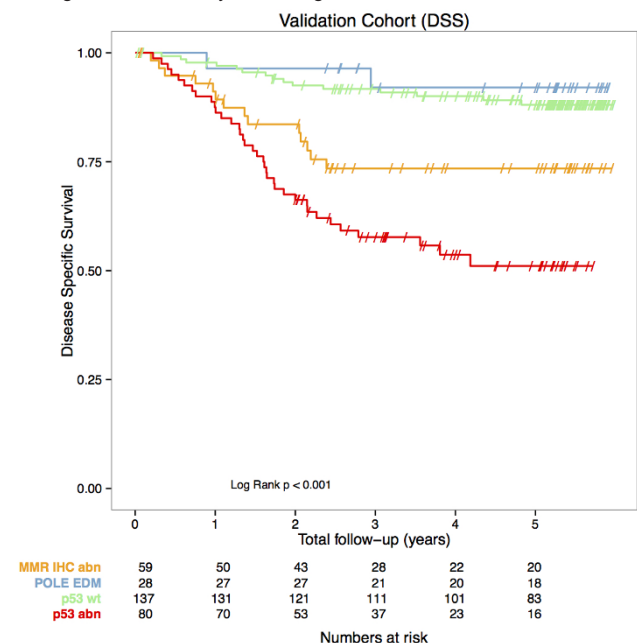
1132 Proactive Molecular Risk Classifier for Endometrial Cancer (ProMisE) for Improved Endometrial Cancer Management

Blake Gilks, Aline Talhouk, Melissa McConechy, David G Huntsman, Cheng-Han Lee, Jessica N McAlpine. University of British Columbia, Vancouver, Canada; University of Alberta, Edmonton, Canada.

Background: Classification of endometrial carcinoma (EC) by morphologic features is irreproducible, and yields limited prognostic and predictive information. Genomic data from the Cancer Genome Atlas (TCGA) supports classification of endometrial carcinomas into 4 prognostically significant subgroups. We developed a molecular classifier based on surrogate assays available in diagnostic laboratories, and based on data from the TCGA endometrial carcinoma cohort (Br J Cancer 2015;113:299-310); in this study we validated our surrogate molecular classifier (ProMisE) in a series of 315 cases of EC.

Design: Immunohistochemistry for mismatch repair (MMR) proteins, *POLE* mutational analysis, and p53 immunohistochemistry as a surrogate for 'copy number' status was used to classify 315 endometrial carcinomas into one of four categories: MMR abn, *POLE* exonuclease domain mutations (EDM), p53 abn, and p53 wt, corresponding to the TCGA molecular categories MSI, *POLE*, CN-H and CN-L, respectively.

Results: The proposed molecular classifier was associated with clinical outcomes, as was stage, grade, lymph-vascular space invasion, nodal involvement and adjuvant treatment. In multivariable analysis both molecular classification and clinical risk groups were associated with outcomes, but differed greatly in composition of cases within each clinical risk group, with half of *POLE* and mismatch repair loss subgroups residing within the clinically defined 'high-risk'.



Conclusions: Molecular classification of ECs can be achieved using clinically applicable methods on formalin-fixed paraffin-embedded samples, and provides independent

prognostic information beyond established risk factors. This pragmatic molecular classification tool has potential to be used routinely in guiding treatment for individuals with endometrial carcinoma and in stratifying cases in future clinical trials.

1133 Myxoid Smooth Muscle Tumors of the Uterus: Clinicopathologic Study of 40 Cases

Ronald Goh, Paola Dal Cin, Sarah Chiang, Robert H Young, Esther Oliva. Singapore General Hospital, Singapore, Singapore; Brigham and Women's Hospital, Boston, MA; Memorial Sloan Kettering Cancer Center, New York, NY; Massachusetts General Hospital, Boston, MA.

Background: Myxoid uterine smooth muscle tumors (M-SMT) are rare, lacking well-defined criteria to separate benign from malignant as they can behave aggressively despite bland cytology, low mitotic index and no tumor cell necrosis (TCN). We aim to better delineate the clinicopathologic characteristics of these tumors.

Design: 40 patients with M-SMTs of at least 30% myxoid component were evaluated for the following: age, size, border (invasive vs circumscribed), myxoid and non-myxoid components, cellularity, atypia, mitotic index, TCN, vascular invasion, stage and follow-up. FISH analysis for ALK gene rearrangement was performed in 13.

Results: There were 10 benign (b) and 30 malignant (m) M-SMT. On average, patients with bM-SMT were younger (42 vs 53) and tumors were smaller (6 vs 11cm). Half were entirely myxoid, the rest had a coexistent spindle component. No invasive border, TCN, high cellularity and at most mild atypia was noted. Mitotic index ranged from 0-2, being 0 in 7. Six patients with follow-up (43-170; mean 92 months) were alive and well. Half of mM-SMT were entirely myxoid, 14 had admixed spindle (including leiomyoma-like areas in 9), 3 epithelioid, and 1 chondroid components. An invasive border was seen in 20/26. TCN, high cellularity and at least moderate atypia was seen in 11, 5, and 19 tumors respectively. Mitotic index ranged from 0-73 (mean 9.6) and was ≤ 2 in 9, of which 4/5 with follow-up recurred. 15 patients had stage 1, 4 stage 2, and 5 stage 3 tumors. Stage could not be determined in 6. Among 20 patients with follow-up (3-127, mean 39 months) 9 died of disease and 14 had recurrences. TCN, cellularity and atypia did not correlate with worse outcome, in contrast to invasion, mitotic index >5 and extrauterine spread (adverse in 82%, 90% and 100% respectively). 80% had a combination of invasive border, TCN, high cellularity, moderate-marked atypia and/or mitotic index >2 (81% adverse outcome). 3 out of 4 with single atypical feature and available follow-up recurred. ALK gene rearrangement was absent.

Conclusions: Invasive border, TCN, high cellularity, moderate-marked atypia and >2 mitoses/10HPFs are associated with malignancy in M-SMT, either singly or in combination. Hence, pathological evaluation should be carried out on well-sampled, completely excised tumor. As expected, invasive border, mitoses $>5/10HPFs$ and extrauterine spread were more often associated with worse prognosis.

1134 Microcystic, Elongated, and Fragmented (MELF) Pattern Invasion in Ovarian Endometrioid Carcinoma: Immunohistochemical Profile and Prognostic Implications

Allison Goldberg, Lauren Cooper, Daniel De Cotiis, Norman Rosenblum, Joanna Chan. Thomas Jefferson University, Philadelphia, PA; Hospital of University of Pennsylvania, Philadelphia, PA.

Background: Microcystic, elongated, and fragmented (MELF) pattern invasion in uterine endometrioid carcinoma (UEC) is a poor prognostic indicator. It has a different immunohistochemical profile (IHCP) than non-MELF UEC, supporting it as a potential sign of epithelial mesenchymal transition (EMT) and Lynch Syndrome (LS). MELF in ovarian endometrioid carcinoma (OEC) has been recently recognized and its significance has not been determined. Here we evaluate MELF OEC for its IHCP and prognostic implications.

Design: All cases of OEC without synchronous UEC resected at our institution from 1996 to 2014 were reviewed by two pathologists for MELF, histologic subtype, grade, bilateral disease, lymphovascular space invasion (LVSI), extranodal metastasis, and lymph node metastasis (LNM). IHCP included: MLH1, PMS2, MSH6, MSH2, β -catenin, e-cadherin, CK19 and BCL1. A retrospective chart review evaluated clinical and demographic features and overall survival (OS). Data were analyzed using Fisher exact test analysis. OS was analyzed using Kaplan-Meier method.

Results: Forty patients met inclusion criteria. MELF was found in 28%. OS was 63% with MELF and 66% without MELF ($p = 0.1$). Mean OS time was 67 months with MELF and 50.7 months without MELF ($p = 0.2$). There was no difference in recurrence rate (RR). MELF had no evidence of concurrent endometriosis or LVSI. Non-MELF showed 24% with endometriosis ($p = 0.002$) and 17% with LVSI ($p = 0.014$). In patients with complete pelvic staging, pelvic LNM was in 36% of patients with MELF, and 12% of patients without MELF ($p = 0.079$). No association between MELF and bilaterality of disease, extranodal metastasis, or high grade features, such as clear cell, mucinous, or serous was found. There was no IHCP difference between MELF and non-MELF OEC.

Conclusions: MELF occurs at similar rates in OEC and UEC. While MELF is a poor prognostic indicator in UEC, we find MELF to have no effect on RR or OS in OEC. Further, we find the IHCP in MELF OEC similar to non-MELF OEC, suggesting MELF in OEC is not a sign of EMT or LS. Although histologically similar, MELF OEC and MELF UEC are likely not entirely analogous and MELF may only be a histologic mimic in OEC. MELF in OEC is associated with positive LNM in patients with full pelvic staging, suggesting that MELF tumors may be under-sampled, and should prompt further evaluation. Further research with a larger cohort could further our knowledge of the prognostic implications of MELF in OEC.

1135 The MELF Pattern of Myometrial Invasion in Endometrial Endometrioid Carcinoma Displays a Mesenchymal Gene Expression Signature: A Case Series

Beth Harrison, Athena Chen, Gemma Toledo, Kshitij Arora, Vikram Deshpande, Esther Oliva. Massachusetts General Hospital, Boston, MA.

Background: The microcystic, elongated and fragmented (MELF) pattern of myometrial invasion in endometrial endometrioid carcinoma (EEC) is associated with an increased risk of lymphovascular invasion (LVI) and lymph node metastases. Immunohistochemical studies have shown that MELF displays characteristics of the epithelial-to-mesenchymal transition (EMT). We aimed to investigate this phenomenon by simultaneously quantifying epithelial (E) and mesenchymal (M) markers by in situ hybridization (ISH).

Design: Ten EECs with MELF were retrieved and clinicopathologic data obtained. A dual colorimetric ISH was performed on FFPE sections using custom QuantiGene View RNA (Affymetrix, CA) probes for E markers (CDH1, EpCAM, KRT5, KRT7, KRT8, KRT19; red) and M markers (FN1, CDH2, SERPINE1; blue). MELF and LVI foci were defined as positive for M signature if at least one tumor cell per focus showed a predominance of blue signals over red signals.

Results: The ten EECs were grades 1-2 and stages IA to IVB. All but one showed distinct microanatomical variation in E and M signatures, with strong M signature largely limited to scattered tumor cells in MELF glands at the invasive front and surrounding reactive stromal cells. Non-MELF EEC areas showed a predominantly E signature with scattered foci of weak M signature. A majority of MELF foci displayed an M signature (57%), whereas most foci of LVI displayed an E signature (92%). Nine patients were alive without disease at follow-up and one with striking MELF was lost to follow-up.

GRADE AND STAGE	FOLLOW UP (YRS)	FOLLOW UP	M SIG MELF FOCI	M SIG LVI FOCI
2; IA	2.3	NED	0/2 (0%)	0/0 (0%)
2; IA	5.8	NED	5/185 (2.7%)	0/0 (0%)
1; IA	3.2	NED	6/16 (3.8%)	0/6 (0%)
1; IB	15.3	NED	43/58 (74.1%)	0/0 (0%)
2; IB	0.0	LTFU	135/136 (99.2%)	1/5 (20%)
2; II	19.8	NED	37/57 (64.9%)	0/3 (0%)
2; II	19.9	NED	28/43 (65.1%)	1/4 (25%)
2; IIIA	12.3	NED	113/130 (86.9%)	0/9 (0%)
2; IIIC2	16.9	NED	25/35 (71.4%)	16/46 (34.8%)
2; IVB	18.3	NED	30/44 (68.2%)	0/2 (0%)

Conclusions: This study provides further evidence that MELF has a predominant EMT-like mesenchymal phenotype. Although an M phenotype is associated with worse prognosis in other cancers (pancreatic and colonic) when not present at the invasive front but expressed in the main tumor, limited data from our pilot study shows that a conspicuous M signature in MELF does not negatively impact prognosis of EEC.

1136 CyclinE1 Expression in High Grade Serous Carcinomas and Malignant Mixed Mullerian Tumors

Joseph Hatem, Carolina Reyes. Hospital of the University of Pennsylvania, Philadelphia, PA.

Background: Amplification of Cyclin E1 gene (*CCNE1*) has been found in a subset of ovarian high grade serous carcinomas, which in association with cyclin-dependent kinase 2 (CDK2), activates the cell cycle. Amplification of *CCNE1* is associated with resistance to platinum-based therapy and overall worse disease-free and overall survival. Pharmacologic agents that target CDK2 are in development and may be effective in the treatment of *CCNE1* amplified HGSC.

CCNE1 amplification has also been found in other neoplasms. Malignant mixed Mullerian tumors (MMMT) of the uterus are rare and little is known about the molecular pathogenesis of this tumor. Preliminary work on few cases has suggested that Cyclin E1 may be overexpressed in a subset of MMMTs.

We evaluated the expression of Cyclin E1 by immunohistochemistry (IHC) on cases of HGSC and MMMT. In doing so, we aimed to support the existing literature regarding overexpression of Cyclin E1 in HGSC. In addition, we sought to evaluate for overexpression in MMMTs.

Design: Paraffin blocks from 28 cases of HGSC and 25 cases of MMMTs were retrieved. Unstained sections were stained with an antibody to Cyclin E1. Positive and negative controls were reviewed and found to be adequate. Cyclin E1 expression was scored on a 4-point scale (0 to 3+).

Results: All cases of HGSC showed at least weak expression of Cyclin E1. Strong (3+) expression was seen in 57% of HGSC. 25% showed moderate (2+) expression and 18% showed weak (1+) staining.

Both the carcinoma and sarcoma components of the MMMT cases were assessed for Cyclin E1 expression. Regarding the carcinoma component, strong expression was seen in 24% of cases. 38% showed moderate expression, 24% showed weak expression, and 14% were negative. Regarding the sarcoma component, strong expression was seen in 17% of cases, 13% showed moderate expression, 45% showed weak expression and 25% were negative.

Conclusions: Our findings support existing literature of Cyclin E1 overexpression in a large subset of HGSC. We also expand upon the existing evidence by demonstrating the expression pattern of Cyclin E1 in a large subset of MMMTs. The findings are important in light of recent efforts to develop cyclin-dependent kinase 2 (CDK2) inhibitors.

1137 Rethinking Decidual Vasculopathy of Preeclampsia

Jonathan H Hecht, Zsuzsanna K Zsengeller, Ananth Karumanchi, Seymour Rosen. Beth-Israel Deaconess Medical Center, Boston, MA.

Background: Preeclampsia is associated with a failure of arteriolar transformation by trophoblastic colonization resulting in decidual vasculopathy (DV). While this vascular transformation has been extensively studied in the placental bed, there is limited data on the morphologically similar vascular injury in decidual vessels of the free membranes.

Design: We describe DV in the membranes using stains for CD31, CD34, Cd42b, CD68, desmin, fibrin and Masson's trichrome in patients with preeclampsia. Membrane-roll sections from the placentas of 6 patients with preeclampsia were examined.

Results: DV was detected in 34-80% of small arteries per case with 302 vessels examined. Changes ranged from so called hypertrophic DV with medial hypertrophy, to more dilated vessels with fibrinoid necrosis / atherosclerosis. Affected vessels showed endothelial proliferation with detachment. Remodeling of the media was characterized by smooth muscle loss and fragmentation with variable degrees of fibrin deposition. CD31 and CD34 highlighted the prominent endothelium and showed striking particulate staining throughout the media (Fig. 1). CD42b (platelet marker) staining in these vessels was minimal. Detection of nitrotyrosine in the intima and media was noted and suggested reactive nitrogen species generation / oxidant injury.

Conclusions: All of these findings infer a sequence of endothelial injury, fragmentation and repair with incorporation of endothelial components into the vascular wall. This kind of rampant endothelial injury seems to be a characteristic finding in the placenta of preeclampsia and may be responsible for the elevated circulating endothelial microparticles that some have found in patients with preeclampsia.

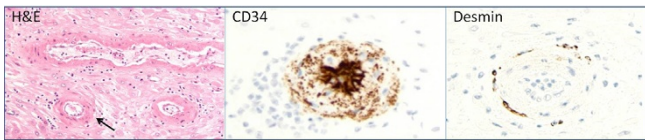


Figure 1. These 3 vessels (left) are characterized by endothelial proliferation and detachment. The walls have a limited cellular component and are composed largely of a homogeneous eosinophilic material without an overt fibrinoid component. The artery (lower left, arrow) in a CD34 preparation shows intense endothelial staining associated with a striking particulate component in the media. The same artery has only an occasional cell positive for desmin.

1138 Utility of Immunolabeling with Stathmin-1 in the Accurate Classification of Anal Squamous Intraepithelial Lesions

Erika Hissong, Adela Cimic, Edyta C Pirog. Weill Cornell Medical College, New York, NY.

Background: The classification of anal intraepithelial neoplasia (AIN) in mucosal biopsies is subject to considerable inter-observer variability, yet the distinction between low and high grade lesions is clinically important in determining potential therapeutic options and the need for continued surveillance. Because of this diagnostic dilemma, a search for objective immunohistochemical markers that may aid in the diagnosis of equivocal cases has been undertaken. Stathmin-1 is a microtubule-destabilizing protein shown to be important during mitosis. In normal squamous mucosa it is expressed exclusively in the basal cells. The aim of this study is to determine whether immunohistochemistry for Stathmin-1 enhances diagnostic accuracy in the assessment of anal mucosa biopsies.

Design: This is a retrospective pilot study of 39 anal biopsies and includes the normal anal transitional zone (NL, n=10), low-grade AIN (AIN1, n=10), and high-grade AIN (AIN2, n=9, AIN3, n=10). The histologic features of all cases were re-reviewed and agreed upon by two independent pathologists. The mean age at the time of diagnosis was 47. Twenty-seven (27) patients were male and twelve (12) patients were female. Immunohistochemistry for Stathmin-1 was performed and staining patterns (lower third of the epithelium, lower two thirds and full thickness) together with intensity of staining (1-3+) were evaluated. The staining was considered positive if at least two thirds of the epithelial thickness was immunoreactive (1-3+).

Results: There was no positivity for Stathmin-1 in NL and AIN-1. Interestingly, 62% of AIN 2 lesions fulfilled the criteria for the positive staining by strong (2-3+) positivity in lower two thirds but no full thickness staining was detected. 88% of AIN3 lesions were positive, of which 66% showed full thickness staining.

Conclusions: In the subset of high grade intraepithelial lesions, Stathmin-1 showed greater sensitivity for AIN3 than AIN2 (sensitivity = 55% for AIN2, 80% for AIN3). AIN2 lesions are commonly the most difficult to classify. In the difficult cases when morphology is not sufficient and immunohistochemistry is warranted for the diagnosis, Stathmin-1 alone may not be sufficiently sensitive for a reliable diagnosis of high grade intraepithelial neoplasia.

However, in our study, immunohistochemistry for Stathmin-1 shows excellent negative predictive value in normal epithelium or AIN1 lesions (NPV=76%), in contrast to known data.

1139 Inter-Observer Agreement in Endometrial Carcinoma (EC) Diagnosis Varies Depending on TCGA Subgroup Assignment

Lien Hoang, Mary A Kinloch, Katherine Grondin, Cheng-Han Lee, Carol Ewanowich, Martin Kobel, David G Huntsman, Jessica N McAlpine, Robert Soslow, Blake Gilks. Memorial Sloan Kettering Cancer Center, New York, NY; Saskatoon City Hospital, Saskatoon, SK, Canada; Laval University, Quebec City, QC, Canada; University of Edmonton, Edmonton, AB, Canada; University of Calgary, Calgary, AB, Canada; BC Cancer Agency, Vancouver, BC, Canada; Vancouver General Hospital, Vancouver, BC, Canada.

Background: We performed molecular analysis on a series of endometrial carcinomas and stratified them into the same molecular groups as modeled by the Cancer Genome Atlas (TCGA) (Br J Cancer 2015;113:299-310). Using this series, we examined inter-observer histologic agreement within each of the 4 molecularly defined groups. The goal was to determine which group is most challenging to diagnose using standard histologic assessment.

Design: Seven gynecologic subspecialty pathologists based in different tertiary care centers assigned histologically-based diagnosis given 151 endometrial carcinomas using 1-2 representative slides from hysterectomy specimens. Inter-observer agreement in histotype diagnosis was then compared between each of the 4 TCGA groups.

Results: Inter-observer agreement in each of the 4 TCGA groups is summarized in Table 1. Consensus agreement in histotype diagnosis was excellent in the CN-L group, intermediate in the MSI and POLE, and lowest in the CN-H group.

Table 1. Inter-observer agreement of histologic diagnosis in the 4 molecularly classified TCGA groups.

	POLE	MSI	CN-L	CN-H
N	34	40	41	36
Consensus Diagnosis *	22 (65%)	23 (58%)	37 (90%)	14 (39%)
Histotype Distribution†	EC1-2: 19 EC3: 12 SC: 1 CCC: 0 DDEC: 1 Other: 1	EC1-2: 29 EC3: 7 SC: 0 CCC: 0 DDEC: 2 Other: 2	EC1-2: 37 EC3: 3 SC: 0 CCC: 0 DDEC: 0 Other: 1	EC1-2: 4 EC3: 4 SC: 23 CCC: 1 DDEC: 1 Other: 3

* All 7 pathologists in agreement

† Kappa values are calculated based on 5 major diagnostic categories: endometrioid, serous, clear cell, mucinous and other

Conclusions: The degree of diagnostic agreement made by gynecologic subspecialty pathologists varies depending on TCGA subgroup assignment. In the groups where inter-observer variability is less optimal (MSI, POLE, CN-H), there may be a role for ancillary immunohistochemical or molecular studies.

1140 Endometrial Biopsies Can Be Used Reliably to Predict Final Endometrial Carcinoma Classification Using Both Histopathologic and Molecular Based Strategies

Lien Hoang, Melissa McConechy, Quentin Nakonechny, Joyce M Leo, Angela Cheng, Sam Leung, Aline Talhouk, Cheng-Han Lee, Martin Kobel, David G Huntsman, Jessica N McAlpine, Robert Soslow, Blake Gilks. Memorial Sloan Kettering Cancer Center, New York, NY; BC Cancer Agency, Vancouver, BC, Canada; Vancouver General Hospital, Vancouver, BC, Canada; Genetic Pathology Evaluation Center, Vancouver, BC, Canada; University of Edmonton, Edmonton, AB, Canada; University of Calgary, Calgary, AB, Canada.

Background: Endometrial carcinomas can be classified by histopathologic diagnosis or by a molecular based scheme as recently reported by the Cancer Genome Atlas (TCGA). In this study, we compare the ability of endometrial biopsies (EMB) to predict the final classification made on hysterectomies (Hyst), using both techniques, histopathologic assignment and molecular analysis.

Design: 51 EMB and corresponding Hyst were selected from institutional archives. Sequencing for POLE, TP53 and immunohistochemical evaluation of DNA mismatch repair proteins were performed independently in both the EMB and Hyst, and used to stratify each into 1 of the 4 TCGA molecular categories (MSI, POLE, CN-L, CN-H), as described previously (Br J Cancer 2015;113:299-310). 3 gynecologic subspecialty pathologists also assigned histotype diagnoses. Diagnoses made on the original pathology report (by mostly non-specialized pathologists) were also analyzed.

Results: TCGA group assignment using EMB reliably predicted group assignment in Hyst (kappa = 0.85; excellent agreement) (Table 1). Gynecologic subspecialty pathologists frequently predicted Hyst final diagnosis (average kappa = 0.69; substantial agreement), but original EMB pathology reports were less successful (kappa = 0.35; fair agreement).

Table 1: Concordance between molecular classification performed on endometrial biopsies and corresponding hysterectomies (N =51, kappa = 0.85).

Prediction (biopsy)	Reference (hysterectomy)				
	MMR	POLE	CN-L	CN-H	Total
MMR	14	2	0	0	16 (31%)
POLE	0	9	1	0	10 (20%)
CN-L	2	0	10	0	12 (24%)
CN-H	0	1	0	12	13 (25%)
Total	16 (31%)	12 (24%)	11 (22%)	12 (24%)	

Conclusions: Molecular classification of endometrial carcinomas made on EMB and Hyst have excellent concordance and can serve as an alternative or adjunctive classification strategy for endometrial carcinomas. Classification using histologic diagnosis was overall moderate; gynecologic subspecialty pathologists more frequently predicted final diagnosis compared to non-specialized pathologists.

1141 Novel Marker GREB1 Is Frequently Expressed in -Major Ovarian Carcinoma Histotypes

Kendra Hodgkinson, Carlos Parra-Herran, Barbara Vanderhyden, Bojana Djordjevic. Ottawa Health Research Institute, University of Ottawa, Ottawa, ON, Canada; The Ottawa Hospital, University of Ottawa, Ottawa, ON, Canada.

Background: Growth regulation by estrogen in breast cancer 1 (GREB1) is an estrogen receptor alpha (ESR1) upregulated protein required for hormone-stimulated proliferation of breast and prostate cancer cell lines. In breast cancer, GREB1 is a marker for estrogenic activity, and is expressed more frequently in ESR1+ tumours. Animal studies suggest that GREB1 also plays a role in ovarian cancer. Our aims were to 1) examine GREB1 expression in ovarian cancer and 2) determine whether GREB1 expression correlates with ESR1.

Design: Tissue microarray slides containing 80 ovarian carcinomas (20 cases each of serous, mucinous, endometrioid, and clear cell carcinoma; 4 x 0.5mm cores per case) were obtained from the Cooperative Human Tissue Network. Immunohistochemistry was performed for GREB1 and ESR1. Staining was scored in terms of intensity (scale 0-3) and percentage of positive cells. GREB1 was considered positive if 2+ or 3+ intensity was seen in >1% of cells, or if 1+ intensity was seen in ≥20% of cells. ESR1 was considered positive if staining of any intensity was seen in >1% of cells.

Results: GREB1 expression, ranging from 75-85% of cases, was similar across the four ovarian histological subtypes examined. ESR1 expression was frequent in serous and endometrioid but less common in clear cell and mucinous carcinomas. Interestingly, GREB1 and ESR1 expression did not correlate: 78% ESR1+ vs. 56% ESR1- tumours were GREB1+. Furthermore, nearly all (94%) of serous, mucinous and endometrioid tumours that were ESR1- were GREB1+.

Subtype	# ESR1+ (%)	#GREB1+ (%)	# GREB1 or ESR1+ (%)
Serous n=20	80	85	100
Endometrioid n=20	85	75	100
Clear Cell n=20	30	75	75
Mucinous n=20	50	80	95

Conclusions: For the first time, we demonstrate expression of GREB1 across the most common ovarian carcinoma histotypes. Unlike in breast cancer, GREB1 expression does not correlate with ESR1 expression in ovarian cancer. The frequent GREB1 expression may represent activation of estrogenic pathways that are independent of ESR1, and suggests that GREB1 may be a more sensitive marker of estrogen-related activity than ESR1. As such, GREB1 may be a useful and a more robust alternative biomarker to ESR1, both in the diagnostic setting and for assessment of eligibility for adjuvant hormonal therapies.

1142 Proteomic Profiles of Vulvar Squamous Cell Carcinoma

Emily Holthoff, Stephanie Byrum, Thomas J Kelly, Alan Tackett, Steven Post, Charles Quirk. UAMS, Little Rock, AR.

Background: Vulvar squamous cell carcinoma (vSCC) is a gynecologic malignancy diagnosed in nearly 4500 women in the US each year. High risk of recurrence and nodal metastasis lead to increased morbidity and mortality in these patients. In previous studies, we identified 2 major variants of vSCC. Some tumors exhibit a pushing invasive pattern and lymphoplasmacytic (LPC) stromal response; others display an infiltrative invasive pattern and a fibromyxoid (FMX) stromal response. We also showed that infiltrative tumors with FMX stroma are more likely to recur and metastasize to the lymph nodes, exhibit perineural invasion, and undergo an epithelial mesenchymal transition (EMT). Molecular tumor features that contribute to these outcomes have not been well defined in vSCC and may be due to differential expression of key proteins involved in biological processes that aid in tumor growth and invasion.

Design: In this study, label-free high resolution LC-MS/MS was used to determine the proteomic profiles of FFPE tissue sections from 10 infiltrative vSCC with FMX stroma and 10 pushing vSCC with LPC stroma. Of these 20 tumors, 11 were associated with recurrence and 8 contained lymph node metastases. Proteomic profiles were associated with morphologic tumor features, tumor recurrence, and nodal metastases to identify proteins linked to increased risk of adverse outcomes.

Results: When comparing infiltrative and pushing tumors, 205 proteins exhibited significant expression changes between the two groups. Importantly, 42 proteins were uniquely identified in infiltrative tumors. Included in these was thrombospondin-4, a glycoprotein that mediates cell-matrix interactions and may play a role in macrophage recruitment. In addition, 96 proteins were identified only in the pushing tumors, including STAT1, which may play a significant role in mediating effects of the inflammatory stromal response through IFN γ signaling. Expression of 105 proteins was either significantly different or uniquely identified in recurrent tumors, and the expression of 115 proteins was either uniquely identified or significantly varied in tumors with nodal metastases. Included in these 115 significant proteins was SRPX2, an important regulator of FAK signaling and cell motility, which could contribute to increased metastatic potential in these tumors.

Conclusions: Overall, our results identify a proteomic profile in vSCC that implicates a role for specific pathways in differentiating aggressive vulvar squamous cell carcinoma as defined by morphologic tumor features, recurrence, and nodal metastases.

1143 Multicystic, Elongated, Fragmented Pattern of Myometrial Invasion Does Not Impact Outcomes of Patients with Low-Grade Endometrial Carcinomas - A Retrospective Study at North Shore - LIJ Health System

Maheen Hossain, Shu Liang, Peter Farmer, Cathy Fan, Sharon Liang. North Shore - LIJ Health System, Lake Success, NY; DOC of Oregon, Salem, OR.

Background: Multicystic, elongated and fragmented (MELF) pattern of myometrial invasion has been associated with high incidence of lymphovascular invasion (LVSI) and lymph node (LN) metastasis in low-grade endometrial carcinomas (FIGO grade 1 or 2). However, its clinical implication is unknown and that's the purpose of this study.

Design: LGECs were retrieved from pathology files at NSUH and LIJMC (1/2010 to 9/2015). Available slides were reviewed and related clinicopathological features (age, tumor size, FIGO stage, grade, myometrial invasion, LUS involvement, adnexal involvement, LN status, cervical stroma involvement and LVSI) were recorded. Recurrence and survival information were obtained from tumor registry. A chi-square test was used to calculate *P* value. Cox proportional hazard ratio analysis was used to identify risk factors for recurrence and survival.

Results: Twenty-two (19.6%) of 112 LGECs demonstrated MELF pattern. The clinicopathological characteristics with and without MELF were listed in Table 1. Univariate risk analysis for recurrence and survival was listed in Table 2. Multivariate risk analysis was not significant.

Conclusions: MELF pattern of myometrial invasion is significantly associated with lymphovascular invasion, lymph node metastasis and higher FIGO stage, but does not adversely impact recurrence or survival. LUS and cervical stromal involvement seem to have higher recurrence and mortality in univariate risk analysis. A larger sample size and longer follow up is warranted to further characterize the clinical implication of MELF.

	MELF Positive (n=22)	MELF Negative (n=90)	<i>P</i> value
Age yo (range)	63.9 (42-88)	63.4 (36-85)	
Tumor size cm (range)	3.7 (0-9)	3.1 (0-10)	
FIGO stage 3 or 4	12	23	0.003
FIGO grade 2	7	32	0.742
Myometrial invasion >50%	11	32	0.212
LUS involvement	6	17	0.383
Adnexal involvement	1	4	0.984
Cervical stroma involvement	1	6	0.713
LVSI	19	22	<0.001
LN positive	12	22	0.006
Recurrence	1	8	0.502
Death	0	5	0.258

	Hazard Ratio for Recurrence	Hazard Ratio for Survival
FIGO stage	3.127	n.s
FIGO grade	1.464	1.719
Tumor size	1.284	1.292
LUS involvement	7.8	3.239
Cervical stroma involvement	7.432	4.22
LVSI	5.254	n.s

1144 Recurrent Gains of CD274 and PDCD1LG2 in Squamous Cell Carcinomas of Cervix and Vulva

Brooke E Howitt, Heather Sun, Margaretha GM Roemer, Alyssa Kelly, Bjoern Chapuy, Emeline M Aviki, Christine Pak, Evisa Gjini, Youling Yang, Larissa Lee, Akila Viswanathan, Neil Horowitz, Donna Neuberg, Christopher P Crum, Neal Lindeman, Frank Kuo, Azra H Ligon, Gordon J Freeman, F Stephen Hodi, Margaret A Shipp, Scott Rodig. Brigham and Women's Hospital, Boston, MA; Dana Farber Cancer Institute, Boston, MA.

Background: A subset of tumors expresses the PD-1 ligands to engage PD-1 on T-cells and inhibit anti-tumor immunity. Clinical responses to PD-1 blockade are associated with PD-L1 expression by tumor cells and provide a rationale for screening tumors to identify patients most likely to benefit. However, the biological basis for expression of PD-L1 is poorly understood. In this study we investigate expression of PD-L1 using immunohistochemistry (IHC) and correlate with genetic alterations using fluorescence *in situ* hybridization (FISH).

Design: In a series of cervical (n=48) and vulvar (n=23) SCCs, we performed FISH on formalin-fixed, paraffin-embedded tissue (FFPE) with probes targeting *CD274* (PD-L1), *PDCD1LG2* (PD-L2), and the centromeric region of chromosome 9 (control). A minimum of 50 malignant cells were scored to determine the target:control ratio. A target:control ratio of >3:1 were scored as amplified, <3:1 but >1:1 as co-gain, and 1:1 as polysomy (if >2 copies), disomy (if =2 copies), or monosomy (if <2 copies). IHC using mouse anti-human PD-L1 monoclonal antibody (clone 9A11) was performed and evaluated for percentage of tumor with positive staining (0-100%) and average intensity of staining (0=negative, 1=weak, 2=moderate, 3=strong) without knowledge of the genetic status of the tumors. A modified H-score was generated by multiplying percentage and the average intensity of positive staining (0-300).

Results: In cervical SCC, co-amplification or co-gain of *CD274* and *PDCD1LG2* was present in the majority of cases (32/48; 67%). PD-L1 expression across tumors demonstrated a range of H-scores (0-270) that was highest among co-amplified cases and lowest among disomic cases (p=0.0013). In vulvar SCCs, 6/23 (26%) had co-

amplification and 4/23 (17%) had co-gain of *CD274* and *PDCD1GL2*. PD-L1 IHC revealed a correlation of higher PD-L1 expression with increasing copy number gains ($p=0.0021$).

Conclusions: Our data reveal that selective copy number gain of *CD274* and *PDCD1GL2* at 9p24.1 occurs frequently in SCCs of the cervix and vulva and provides a genetic basis for increased PD-L1 protein expression, potentially aiding in immune evasion. Patients whose tumors have a genetic basis for PD-1 ligand expression may be uniquely sensitive to PD-1 blockade.

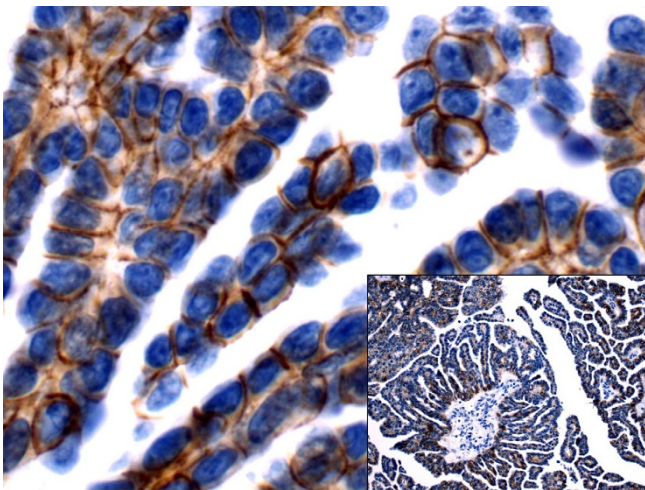
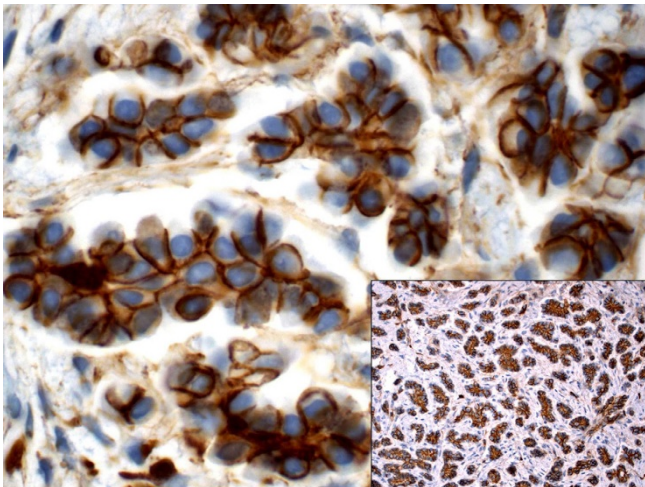
1145 Cell Polarity Reversal in Ovarian Low-Grade Serous Carcinomas and Micropapillary Serous Borderline Tumors - Are They Biologically Similar? An Immunohistochemical Study

Yiang Hui, Joyce J Ou, Shahrzad Slater, C James Sung, W Dwayne Lawrence, M Ruhul Quddus. Women & Infants Hospital/Alpert Medical School, Providence, RI.

Background: When proposed that micropapillary serous borderline tumors (M-SBT) may fall under carcinoma category, it created tremendous controversy among gynecologic pathologists. M-SBT can progress to low grade serous carcinomas (LGSC) and both show micropapillary growth patterns. Reversal of cell polarity has been demonstrated in micropapillary tumors of the breast. This study aimed to qualitatively assess the presence of cell polarity reversal in LGSCs and M-SBTs using immunohistochemical markers to provide possible clues to the similar biologic behavior of M-SBT and LGSC.

Design: Forty-nine tissue samples including 9 M-SBTs, 21 LGSCs, 16 epithelial implants and 3 proliferative endosalpingiosis from 34 patients were retrieved. H&E slides were reviewed to confirm the diagnosis and presence of lesional areas. Immunohistochemistry for membranous markers E-cadherin and p120 was performed and read by two pathologists to see alteration of staining patterns to identify reversal of cell polarity.

Results: Membranous staining was robust for both markers in all cases. E-cadherin and p120 staining showed unique staining patterns similar to what has been described in invasive micropapillary breast tumors as indicating cell polarity reversal: absent immunostaining on the peripheral border of papillary clusters and staining of the basal and lateral aspects of the cells. Staining patterns in LGSC (figure 1) and M-SBT (figure 2) differed from benign lesions, e.g., proliferative endosalpingiosis and Implants which did not show alteration of staining patterns.



Conclusions: Patterns of immunostaining of E-cadherin and p120 are similar in LGSCs and M-SBTs indicating reversal of cell polarity. In contrast, loss of cell polarity was not observed in benign lesions. This finding supports the view that LGSC and M-SBT may have similar biologic potential and may be related lesions.

1146 Demise of the Pap Smear? Not So Fast! Report of HPV DNA Negative Cervicovaginal Dysplasias

Yiang Hui, Katrine Hansen, Jayasimha N Murthy, Danielle B Chau, C James Sung, M Ruhul Quddus. Women & Infants Hospital/Alpert Medical School of Brown University, Providence, RI; Memorial Hospital/Alpert Medical School of Brown University, Pawtucket, RI.

Background: With recent FDA approval of an HPV DNA test for primary screening for cervical squamous intraepithelial lesion, there has been a trend in ordering HPV DNA testing without Pap smears for primary screening. The HPV DNA screening assay detects 14 high-risk HPV (hrHPV) types and genotype HPV 16/18, when present. However, studies have reported cases of cervical cancer where the testing was negative for hrHPV. We sought to identify cases of cervical dysplasia where the screening was negative for HPV DNA and assess them using PCR and microarray techniques capable of detecting all 14 hrHPVs.

Design: We retrieved 18,200 HPV DNA test reports over a 15-month period from archival records after IRB approval. Corresponding Pap smears and surgical biopsies were reviewed. Representative tissue biopsies of hrHPV test negative cases and abnormal cytology was collected and DNA extracted using a QIAmp DNA FFPE kit. hrHPV genotyping by PCR amplification was performed using labeled allele-specific primers. PCR products were transferred to microarray chips for signature Tag/Capture probe hybridization. Signal detection for each type was performed against a beta-globin gene control.

Results: Seventeen cases were negative for hrHPV DNA but had positive Pap smears. On Pap smear, 13 (76.5%) patients had low-grade SIL (LSIL) while 4 (24.5%) had high-grade SIL (HSIL). Twenty-seven corresponding cervical/vaginal biopsies were identified with 20 (74 %) showing LSIL and 7 (26%) with HSIL.

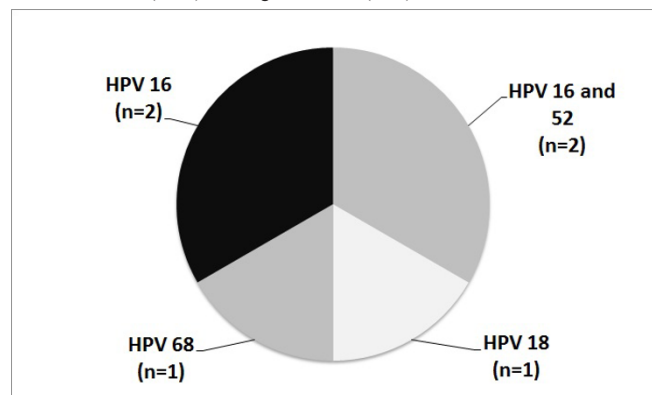


Figure 1 shows the distribution of hrHPV types in 6 biopsies with HSIL. One case of LSIL was positive for hrHPV 56 and 59. Nineteen biopsies of LSIL and one HSIL remained HPV-negative by PCR and microarray technique.

Conclusions: Our study shows that cases of biopsy proven HSIL may be associated with non-16/18 hrHPVs or negative for HPV DNA and may be missed if HPV DNA testing alone is performed as a primary means of screening. HPV DNA testing alone should, therefore, be used with caution for primary screening. These findings support the continued use of co-testing with Pap smear and HPV DNA as a screening method for cervical squamous intraepithelial lesions.

1147 Utility of Phosphohistone H3 in Uterine Smooth Muscle Tumors: An Outcome-Based Assessment

Philip Ip, Kin Long Chow, Ka Wing Wong, Ka Yu Tse, Richard WC Wong, Alice NH Chan, Nancy WF Yuen, Annie N Cheung. The University of Hong Kong, Hong Kong, SAR, Hong Kong.

Background: In the absence of tumor cell necrosis, the distinction between uterine leiomyoma with bizarre nuclei (LBN) and leiomyosarcoma (LMS) is dependent on the mitotic count. Most LBNs have <2 mitotic figures (MF)/10 high power fields (HPF) while LMS have >10 MFs/10 HPFs. Mitosis-counting is not always accurate because of potential confusion between true MFs and karyorrhectic nuclei. Also, behavior of tumors with ambiguous morphologies (significant nuclear atypia, >2 to <10 MFs, indeterminate necrosis, or combinations thereof) is variable and uncertain. Phosphohistone H3 (PHH3), a mitosis-specific immunomarker, has been shown to be useful in the diagnosis of uterine smooth muscle tumors (USMT) but assessment methods have not been standardized.

Design: PHH3 immunohistochemistry was done on 48 LMS, 23 smooth muscle tumors of uncertain malignant potential (STUMP) and 23 leiomyomas (LM) (including 11 LBN). Result was expressed as highest count/10 HPFs and listed according to histologic types. In order to test the discriminating power of PHH3 in distinguishing benign USMT with ambiguous morphologies from malignant tumors, 2 biologic patient groups were further delineated. Those in Group 1 all had a benign outcome (11 LBN, 9 STUMP with no recurrence) while in Group 2, patients had either a recurrence or death (2 STUMP with recurrence, and 29 LMS).

Results: Median follow-up of LMS, STUMP and LM patients were respectively 28, 71 and 62 months. 52.1% (25/48) with LMS died while 8.7% (2/23) with STUMP had a recurrence, both at 14 months. All with LM/LBN were alive and with no tumors. The respective median PHH3 scores for LMS, STUMP and LM were 17, 3 and 2/10HPF ($p<0.05$). The corresponding H&E mitotic counts were 12, 3 and 1/10 HPF. Median ages for Group 1 and 2 patients were 44 and 53 years, respectively, and median follow-up were 69 (range 5-156) and 7 (range 1-96) months. PHH3 scores for Groups 1 and

2 were 3 and 24/10 HPF, respectively. Using ROC analysis, a PHH3 score of $\geq 6/10$ HPF was highly compatible with malignancy with sensitivity of 80.6%, specificity of 93.7%, and positive and negative predictive values of 92.5% and 83.3%, respectively. For malignant USMT, multivariate analysis showed that a PHH3 score of $\geq 9/10$ HPFs was independently associated with a poor outcome.

Conclusions: In USMT with ambiguous morphologies, a PHH3 score of $\geq 6/10$ HPF is highly predictive of malignancy. PHH3 score may also be a useful prognostic indicator for malignant USMT.

1148 The Microcystic, Elongated, and Fragmented (MELF) Pattern of Invasion Is Associated with Non-Vaginal Recurrences and Increased Lymph Node Metastases, Even When Compared to Myoinvasive Infiltrative Cases without MELF

Amy S Joehlin-Price, Kelsey McHugh, Julie A Stephens, David E Cohn, David Cohen, Adrian A Suarez. The Ohio State University, Columbus, OH.

Background: MELF has been associated with non-vaginal recurrences and lymph node metastases in multi-institutional case control studies, but has not been well examined in large single institution cohorts lacking case control selection bias.

Design: Hysterectomy specimens with FIGO 1 endometrioid endometrial carcinoma (EC) and lymphadenectomies between the dates of July 2007 and April 2012 were identified. Electronic medical records and histologic slides were reviewed.

Results: Out of 464 identified cases, 163 (35.1%) were non-myoinvasive, 60 had MELF (12.9%), 222 (47.8%) had infiltrative invasion pattern without MELF, 13 (2.8%) had pure pushing borders of invasion, 5 (1.1%) had pure adenomyosis-like invasion, and 1 (0.2%) had pure adenoma malignum-like invasion. 16 cases had lymph node metastases (+LN). A significantly higher proportion of MELF cases had +LN than non-MELF cases overall (18.3% vs 1.2%, $p < 0.001$, Fisher's exact test) and infiltrative, invasive cases without MELF (18.3% vs 1.8%, $p < 0.001$, Fisher's exact test). The maximum number of MELF glands per slide did not differ between +LN and cases without +LN, $p = 0.137$ (Wilcoxon Rank Sum test).

A significant difference in non-vaginal recurrence was found between MELF and overall non-MELF infiltrative cases, $p = 0.024$ (Log-rank test). The median time to recurrence could not be estimated due to the low absolute number of recurrences ($n = 4$ MELF, $n = 9$ non-MELF).

+LN metastases showed different histologic features including histiocyte-like, solid glandular, and cystic glandular patterns. All three patterns were noted in both MELF and non-MELF cases.

Conclusions: MELF is significantly related to +LN, even when comparing with other EC infiltrative patterns. MELF cases also showed decreased time to non-vaginal recurrences. +LN in MELF cases display various histologic patterns.

1149 DNA Genotyping of Non-Molar Donor Egg Pregnancies with Abnormal Villous Morphology: Recommendations to Prevent Misinterpretation as Dispermic Complete Hydatidiform Mole

Nancy Joseph, Caryll Pineda, Nam Tran, Joseph T Rabban. University of California San Francisco, San Francisco, CA.

Background: Short tandem repeat (STR) genotyping can be used to diagnose a complete hydatidiform mole (CHM) since the chorionic villous tissue, which contains only paternal DNA (uniparental genome), carries unique alleles that do not match the maternal decidua tested for comparison. However, a non-molar pregnancy established using a donor egg will also show a genotype that does not match the recipient maternal decidua, potentially causing misinterpretation as a dispermic CHM. Since a donor egg pregnancy has a biparental genome, most STR loci should show heterozygous alleles but in a dispermic CHM, which is uniparental, most loci should be homozygous. In a monospermic CHM, all of the STR loci should be homozygous, so misinterpretation is unlikely. We propose that evaluating the pattern of STR allele zygosity can distinguish the genotype of donor egg products of conception (POC) from dispermic CHM.

Design: STR genotype (AmpFISTR Identifier PCR Amplification system targeting 15 STR loci) and p57 immunostaining of 10 donor egg POC (6 with abnormal morphology suspicious for CHM) was compared to 22 CHM (2 dispermic). The ratio of allele zygosity (homozygous versus heterozygous) at the STR loci was compared. Data was interpreted blinded to whether a donor egg was used.

Results: All 10 donor egg POC resembled the genotype of CHM in that all showed genotypes that did not match the maternal decidua. However, most STR loci had heterozygous alleles in donor egg POC whereas most were homozygous in dispermic CHM ($p < 0.0001$). Positive p57 staining in villous cytotrophoblast and mesenchyme confirmed biparental genome in all 10 donor egg POC while all CHM lacked p57 staining as expected.

Allele Zygosity	Donor Egg POC	Dispermic CHM
Homozygous loci	26%	76%
Heterozygous loci	74%	23%
Ratio of Heterozygous to Homozygous loci	3:1	1:3

Conclusions: Evaluation of the ratio of heterozygous to homozygous loci is essential before interpreting a DNA genotype as a CHM. If the ratio is high (3:1 or more), the possibility of a donor egg pregnancy should be considered and p57 immunohistochemistry should be performed. In this setting, positive p57 staining confirms a donor egg was used and excludes a CHM. From a practical standpoint, it may be prudent to use p57 staining to confirm any diagnosis of dispermic CHM based on DNA genotyping alone.

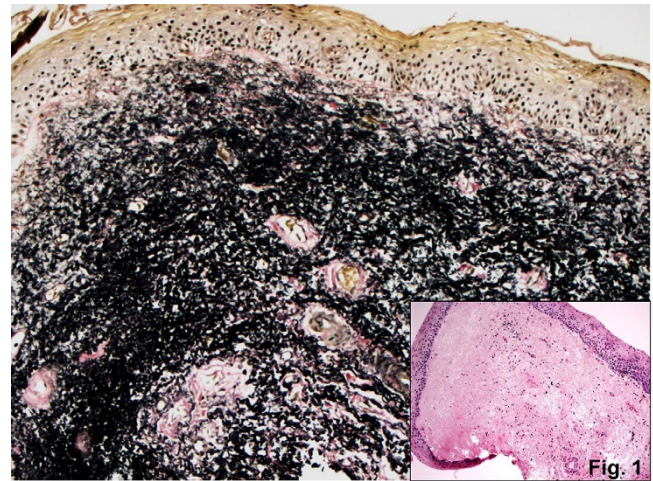
1150 Vulvar Elastosis: An Under-Recognized Entity Often Confused with Lichen Sclerosus. Report of a Series

Elizabeth Kalife, M Ruhul Quddus, Katrine Hansen, Kamaljeet Singh, W Dwayne Lawrence. Women and Infants Hospital, Providence, RI.

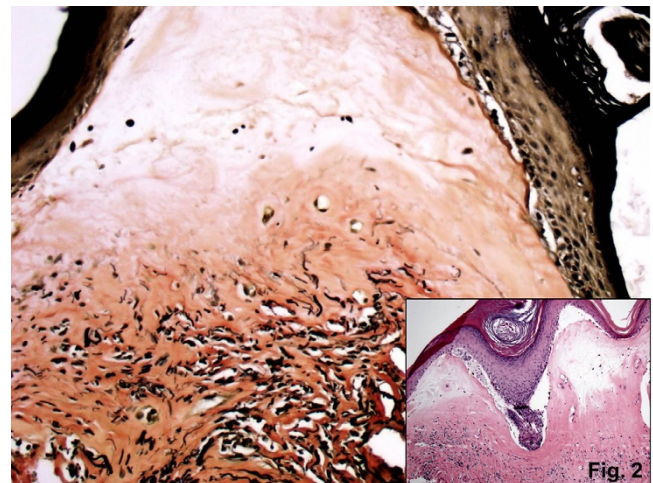
Background: In clinical practice, vulvar biopsy of patients ≥ 50 years of age is often performed for suspicion of lichen sclerosus (LS). The histologic findings of established LS include flattened rete pegs and dermal homogenization; lichenoid inflammation, vacuolar interface change and hyperkeratosis are variably present depending upon the stage of the lesion. Some of these features are also seen in elastotic dermatoses: In our experience, a subset of cases diagnosed with LS actually represent vulvar elastosis on further examination. A review of the literature reveals limited description of vulvar elastosis; our case series would provide the first description of vulvar elastosis as a histologic mimic of LS.

Design: 16 cases of vulvar elastosis were identified through retrospective review of consult files and pathology archives; 11 cases of LS and 11 age-matched normal vulvar biopsies served as controls. For each case, H&E and elastic tissue-stained slides were examined. Histologic parameters (flattening of the rete pegs, vacuolar interface change, hyper/parakeratosis and dermal homogenization) were recorded in a database with elastic tissue staining pattern, density and distribution. The data was scored according to features favoring either LS or elastosis as a unique diagnosis.

Results: The most common histologic findings in cases of elastosis were flattened rete pegs and dermal homogenization; elastic stain shows both increased density and abnormal distribution of elastic fibers in the papillary and reticular dermis.



Cases of LS were characterized by dermal homogenization, flattened rete pegs and hyperkeratosis. On elastic stain, these cases uniformly showed abnormal loss of elastic fibers in the papillary dermis.



None of these features were present in the normal controls.

Conclusions: These findings confirm that elastosis is a histologic mimic of LS and should be considered in the differential diagnosis.

1151 Cornual/Interstitial Pregnancy: Distinction from Conventional Tubal Pregnancy, Emphasizing Microscopic Features to Avoid a Potential Diagnostic Pitfall When Accompanied by a Normal Fallopian Tube Specimen

Yuna Kang, Joseph T Rabban. University of California San Francisco, San Francisco, CA.

Background: Pregnancies that implant in the uterine cornua (cornual pregnancy) or intra-myometrial (interstitial) portion of the fallopian tube (interstitial pregnancy) carry a higher risk of morbidity than conventional ectopic tubal pregnancy due to extra risk of rupture of uterine wall blood vessels. Management may include salpingectomy along

with cornual resection, even though the extra-uterine fallopian tube is not abnormal. This may cause diagnostic confusion in evaluating these specimens, particularly since clinicians may refer to these as "ectopic pregnancies" and since the pathology of cornual/interstitial pregnancy is not well described in the literature.

Design: 15 patients in our archives were suspected to have cornual pregnancy and underwent management resulting in a pathologic specimen. Slides were reviewed to map the anatomic location of chorionic villi and placental implantation and to define the incidence of salpingitis isthmica nodosum (SIN), tubal endometriosis, and chronic salpingitis.

Results: Most patients were multigravid (3 prior pregnancies, median); prior GYN surgery included C-section (3/15), abortion (5/15), ectopic pregnancy (1/15). Average gestational age was 7.75 weeks. Specimens consisted of cornual resection with (8/15) or without (3/15) salpingectomy; salpingectomy with cornual evacuation but not cornual resection (2/15); or cornual evacuation alone (2/15). Placental implant site was present overlying myometrium in all cornual resections, though in some cases it was not possible to distinguish implantation within a dilated interstitial tube from implant in cornua. Villi were in 5/15 cases. No implantation site, villi, or rupture was present in any salpingectomy; all were grossly normal. In 2 patients, a normal fallopian tube was accompanied by separate tissue fragments of villi and blood clot evacuated from the cornua. SIN was seen in 2 cornua specimens; the cornual implant site partially involved SIN in 1 case. No cases had endometriosis or chronic salpingitis. 4 patients subsequently had a normal pregnancy; 1 had another cornual pregnancy.

Conclusions: For cornual/interstitial pregnancy specimens accompanied by a salpingectomy specimen, pathologists should be aware that a.) the fallopian tube will be normal; b.) the key diagnostic finding of placental implantation site is in the separate tissue fragments (with or without myometrium); c.) there is overlap in the histologic appearance of cornual versus interstitial pregnancy.

1152 HPV-Independent Vulvar Squamous Cell Carcinoma Has a Significantly Worse Prognosis Than HPV-Associated Carcinoma

Anthony Karnezis, Angela Cheng, Samuel Leung, Suzanne Jordan, Naveena Singh, Dianne M Miller, Jessica N McAlpine, C Blake Gilks. University of British Columbia, Vancouver, BC, Canada; Barts Health NHS Trust, London, United Kingdom.

Background: Vulvar squamous cell carcinoma (VSCC) is two molecularly distinct diseases subdivided based on HPV status, with some studies demonstrating that patients with HPV-positive tumors have a better prognosis. The aims of this study were to 1) assess p16 immunohistochemistry (IHC) in the determination of HPV status in VSCC and 2) perform a retrospective analysis of survival of in VSCC patients stratified by HPV status.

Design: 201 invasive VSCC cases were classified as "HPV-associated" when warty/basaloid VSCC or HSIL (VIN2/3) was observed, or "HPV-independent" in the presence of well-differentiated keratinizing invasive SCC or dVIN. For p16 IHC, strong nuclear and cytoplasmic staining of all cells in at least the lowermost third of the epithelium was scored as positive. All cases with discrepant HPV predictions by H&E morphology versus p16 IHC were further analyzed by PCR for HPV DNA.

Results: The sensitivity and specificity of p16 IHC in classification of VSCC as HPV-independent or HPV-associated was 100% and 98.4%, respectively. HPV-associated VSCC patients were younger (median 58 yrs vs. 75 yrs for HPV-independent tumors). HPV-associated and HPV-independent tumors showed a similar stage distribution. In univariable analysis, patients with HPV-independent tumors had worse progression free survival (HR 0.56, 95% CI 0.33-0.95), disease specific survival (HR 0.19, 95% CI 0.09-0.40) and overall survival (HR 0.52, 95% CI 0.36-0.75). After adjusting for age, tumor size, lymph node status, tumour stage, lymphovascular invasion and adjuvant treatment in multivariable analysis, patients with HPV-independent tumors showed worse progression free survival (HR 0.11, 95% CI 0.02-0.66) and disease specific survival (HR 0.05, 95% CI 0.01-0.51).

Conclusions: p16 IHC is validated as an accurate surrogate marker for HPV status in VSCC. VSCC can be stratified into two prognostically different diseases based on HPV status; this highlights a potential role for such subtyping in planning treatment.

1153 Loss of SWI/SNF Complex Protein Expression Is Associated with Dedifferentiation in Endometrial Carcinomas

Anthony Karnezis, Lien Hoang, Noorah Almadani, Basile Tessier-Cloutier, Julie A Irving, Bojana Djordjevic, Robert Soslow, David G Huntsman, C Blake Gilks, Martin Kobel, Cheng-Han Lee. University of British Columbia, Vancouver, BC, Canada; Royal Jubilee Hospital, Victoria, BC, Canada; The Ottawa Hospital, Ottawa, ON, Canada; Memorial Sloan Kettering Cancer Center, New York, NY; Calgary Laboratory Services and University of Calgary, Calgary, AB, Canada; Royal Alexandra Hospital and University of Alberta, Edmonton, AB, Canada.

Background: Dedifferentiated endometrial carcinoma (DDEC) is an aggressive endometrial cancer that contains a mix of low grade endometrioid and undifferentiated carcinoma components. The molecular basis of the histologic dedifferentiation is unknown, and no specific diagnostic immunohistochemistry (IHC) marker has been identified.

Design: We performed targeted DNA sequencing and IHC on an index series of 8 DDEC. IHC was then done on a validation series of 22 DDEC and 31 grade 3 endometrioid carcinomas (EC).

Results: We identified somatic inactivating mutations in *SMARCA4*, a core ATPase of the SWI/SNF complex, in the undifferentiated components of 4 of 8 tumours in the index series. IHC confirmed the loss of SMARCA4 specifically in the undifferentiated component, while the corresponding low-grade endometrioid component retained SMARCA4. An expanded survey of other members of the SWI/SNF complex showed SMARCB1 loss in the undifferentiated component of 2 of 4 SMARCA4-intact tumours. All SMARCA4/SMARCB1-deficient tumours also showed loss of SMARCA2, the

other SWI/SNF ATPase. We then examined the expression of SMARCA2, SMARCA4 and SMARCB1 in an additional 22 DDEC and 31 grade 3 EC. Combining the results from the index and the validation sets, 15 of 30 (50%) of the DDECs examined showed either SMARCA4/SMARCA2 loss (11 tumours, 37%) or SMARCB1/SMARCA2 loss (4 tumours, 13%). The loss of SMARCA4 or SMARCB1 was mutually exclusive and occurred only in the undifferentiated component. All 31 grade 3 EC showed intact SWI/SNF protein expression. The majority (73%) of the SMARCA4/SMARCA2-deficient and half of SMARCB1/SMARCA2-deficient undifferentiated components showed defective mismatch repair protein expression.

Conclusions: The loss of SWI/SNF proteins specifically in the undifferentiated component of DDEC may contribute to the pathogenesis of the dedifferentiated phenotype and can distinguish DDEC from grade 3 endometrioid carcinoma.

1154 The Assessment of Potential Biomarkers of Disease Progression in High Grade Squamous Cervical Lesions – Promoter Methylation Analysis of Selected Tumour-Suppressor Genes and Viral/Microbial Co-Infection

Jana Kaspirkova, Barbora Gomolcakova, Ondrej Ondic, Michal Michal. Biopsticka Laborator, Pilsen, Czech Republic.

Background: Implementation of HPV detection by means of molecular genetics has improved efficiency of cervical cancer screening in terms of increased sensitivity. The inadequate specificity of an HPV test for identifying only severe precancerous lesions is solved by colposcopy and/or histological examination of tissue-biopsies. Additional biomarkers analysed from liquid-based cytological (LBC) samples could better define the real risk of HPV positive patients of having a high-grade lesion and decrease the number of patients who have to undergo an invasive diagnostic procedure. In our study, we focused on molecular genetic analyses of two aspects potentially reflecting higher risk of disease progression: (1) HPV-driven methylation silencing of selected tumour-suppressor genes and (2) the presence of selected infectious agents discussed as possible transforming cofactors.

Design: 51 paired samples of LBC and consecutive punch or cone biopsy of the cervix rendering the diagnosis of HSIL within 6 weeks interval had been prospectively identified. Analysis of methylation silencing of tumour-suppressor genes *CADMI*, *MAL*, and *has-miR-124*, related to cervical carcinogenesis, was performed in LBC samples using methylation-specific qPCR. Furthermore, these samples were investigated for the presence of selected human herpesviruses - *HSV1*, *HSV2*, *VZV*, *EBV*, *CMV*, *HHV6*, *HHV8*; polyomaviruses - *BK*, *JC*, *Merkel cell polyomavirus (MCPyV)*; and *Chlamydia trachomatis*, using PCR methodology, and compared to LBC cervical smears of 51 women without HPV infection.

Results: Methylation silencing of selected tumour-suppressor genes was detected in 26 patients (58%), 19 patients were negative for methylation, and 6 samples were not suitable for analysis due to their low cellularity. The most commonly detected infectious agent in the study group was *MCPyV* (6 cases), followed by *EBV*, *JCV*, and *Chlamydia trachomatis* (4 cases each). *CMV*, *HSV1*, and *HHV6* were detected in one case each.

Conclusions: The positive methylation status of tumour-suppressor genes *CADMI*, *MAL*, and *has-miR-124* detected in LBC smear holds promise in identifying HPV-positive patients at higher risk for disease progression. Several infectious agents were detected in the study samples, but this finding was not statistically significant though we have to consider the bias of small study group.

1155 Loss of BAF250a (ARID1A) Expression Is Associated with Progression of Endometriosis-Related Stage I Ovarian Clear Cell Carcinoma

Ayako Kawabata, Takako Kiyokawa, Nozomu Yanaiharu, Aikou Okamoto. Department of Obstetrics and Gynecology, Jikei University School of Medicine, Tokyo, Japan; Department of Pathology, Jikei University School of Medicine, Tokyo, Japan.

Background: Mutations in *ARID1A* and upregulation of IL-6 signal are frequent molecular events in ovarian clear cell carcinoma (OCC). Recent studies have shown approximately 50% of OCC to harbor somatic mutation in *ARID1A* resulting in loss of the corresponding protein BAF250a in immunohistochemistry. The significance of IL-6 expression in OCC remains unknown. We conducted a retrospective study to examine the association of loss of BAF250a expression with respect of IL-6 overexpression, potential prognostic factors, and patients' survival in stage I OCC.

Design: One hundred and ninety-three cases of FIGO stage I OCC (46 FIGO stage IA, 89 stage IC1, 10 stage IC2, 48 stage IC3) surgically treated between 2000 and 2012 at a single institution were included in this study. The median follow-up was 90.5 months (6-170 mo). All H-E slides were reviewed for the presence of endometriosis (EMosis) associated with carcinoma. Immunohistochemical staining for BAF250a (193 cases) and IL-6 (138 cases) were performed. Complete lack of nuclear immunoreactivity of the cells was considered loss of BAF250a expression. IL-6 expression was scored using: 0 = negative, 1-50% = focal, and > 50% = diffuse. Progression-free survival (PFS) and overall survival (OS) were calculated, and comparisons were made using the log-rank test.

Results: Of 193 cases 140 (73%) were associated with EMosis. Loss of BAF250a expression was found in 109/193 (57%) cases: 77/140 (55%) with EMosis, and 32/53 (60%) without EMosis. Although loss of BAF250a expression had no impact on patients' survival (PFS or OS), it was correlated with FIGO stage (67/135 cases [50%] in IA/IC1 vs. 42/58 [72%] cases IC2/IC3; $p < 0.01$). This association was still significant in those with EMosis ($p = 0.01$) while it was not observed in those without EMosis. Diffuse IL-6 expression was found in 43/138 cases (31%) and was associated with adverse prognosis (OS, $p = 0.034$; PFS, $p = 0.043$). There was no correlation between loss of BAF250a expression and diffuse IL-6 expression.

Conclusions: These results suggest that *ARID1A* loss may play an important role in the tumor progression as well as tumor initiation in OCC associated with endometriosis.

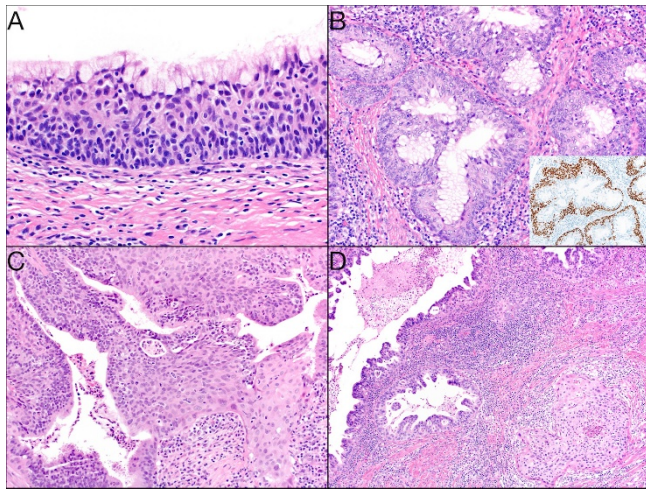
1156 Adenosquamous Carcinoma and Adenosquamous Intraepithelial Lesion of the Cervix: Analysis of a Rigorously Classified Case Series

Michael Keeney, Gary L Keeney, John Schoolmeester. Mayo Clinic, Rochester, MN.

Background: Adenosquamous carcinoma (ASC) of the uterine cervix is an ill defined neoplasm subject to misclassification. We thoroughly evaluated cases coded as ASC from our institutional archive to better describe its clinical and pathologic features.

Design: Case inclusion criteria were threefold: 1. The specimen was processed at our institution 2. The specimen was a hysterectomy or trachelectomy 3. A singular invasive neoplasm demonstrate morphologic and immunophenotypic evidence of squamous (keratinization, intercellular bridges or other such features) and glandular (cuboidal to columnar epithelium in circinate or tubular structures) differentiation. Cases were identified using keywords "ASC" and "cervix." Immunohistochemical stains (p63, p40, p16, ER, PR) and in-situ hybridization for human papillomavirus E6/E7 RNA (HPV ISH) were performed. Clinical data were retrieved from the medical record.

Results: Thirty-two cases met criterion #1. Fifteen cases were excluded due to failure of criterion #2 or slides were not available. Seventeen cases were then histologically evaluated and eleven (73%) were reclassified as an assortment of entities. Four cases (27%) met all 3 inclusion criteria and were striking in their morphologic heterogeneity. More, these cases featured a distinctive intraepithelial lesion with both squamous (p63+) and glandular (p63-) differentiation (Fig1A). The invasive component showed nests with a circuitous pattern of central goblet cells surrounded by squamous epithelium (Fig1B, p63 inset) or cuboidal glands intermixed with keratinizing squamous epithelium (Fig1C) or a collision tumor pattern of adenocarcinoma and squamous cell carcinoma (Fig1D). HPV ISH was positive in all cases. Patient stage at presentation varied: IIIB(2), IVB(1) and IB1(1). One IIIB was lost to follow-up. All remaining patients had no evidence of disease at last follow-up (29-76 months, mean 52).



Conclusions: ASC is an uncommon, heterogenous neoplasm with a distinctive intraepithelial lesion we term "adenosquamous intraepithelial lesion." Although historically considered a neoplasm with a poorer outcome by some studies, from our limited, but rigorously classified series, patients may present at advanced stage yet may have similar outcomes to other HPV-associated cervical carcinomas.

1157 Clinical Outcomes in a Subset of Endometrial Surface Epithelial Lesions with Marked Nuclear Atypia

Elizabeth Kehr, Marisa R Nucci, Christopher P Crum. Brigham and Women's Hospital, Boston, MA.

Background: Uterine serous carcinoma has been associated with a precursor termed serous endometrial intraepithelial carcinoma (SEIC). SEIC has been shown to have metastatic potential with a recurrence risk approaching 5%. Thus, its proper recognition in curettings is vital to ensuring early and effective treatment. Diagnostic features of SEIC include an abnormal surface or superficial glandular epithelial proliferation with elevated N/C ratio, loss of polarity and both strong p53 (or complete loss) staining and elevated MIB1 index. Nevertheless, there is a subset of surface endometrial epithelial lesions with marked nuclear atypia (EMATYP) that may be difficult to distinguish from SEIC. This study addressed a series of EMATYPs seen in a consultation practice.

Design: The consultation files were scanned for cases classified as p53 positive EMATYP. Histologic features, p53 and MIB1 immunohistochemistry were recorded. Followup information from subsequent histologic samples were obtained.

Results: A total of 18 EMATYPs were retrieved between 2006-2015. In 8 a SEIC was diagnosed. In 10, a diagnosis of EMATYP was made. In the latter, the most consistent histologic features were conspicuous nuclear enlargement and variable N/C ratio accompanied by strong p53 (or null) immunostaining. MIB1 proliferation indices varied, ranging from 10-40%. One case was strongly positive for p16. All 8 cases classified as SEICs had followup hysterectomy procedures with the following results: one invasive serous carcinoma, 6 SEIC, and one had atypia of unclear significance. Conversely, the 10 cases of EMATYP had followup hysterectomy procedures with the following results: three had diagnoses of SEIC (including the p16+ case); two had diagnoses of endometrioid intraepithelial neoplasia, two had diagnoses of atypia of unclear significance; and three had negative hysterectomies.

Conclusions: EMATYP appears to be a distinct subset of p53-positive atypias seen in postmenopausal women with a significant risk of neoplasia and an estimated risk of SEIC to be 30%. The finding of marked surface endometrial intraepithelial atypia is a

significant finding. It underscores the importance of follow up in cases when some, but not all, features of SEIC are encountered. Moreover, nuclear enlargement, a feature often associated with reactive atypias, does not exclude the possibility of a serous neoplasm, particularly in the setting of strong p53 staining. The use of additional markers (such as p16), should also be considered when triaging these p53 positive atypias.

1158 Combination of Ki-67, MCM2, p16, and p53 Expression Can Distinguish High Grade Serous Carcinoma From Low Grade Serous Tumors

Sarah M Kelting, Cherie Paquette, Mark E Smolkin, Amir A Jazaeri, Megan R Barrett, Mark H Stoler. University of Virginia, Charlottesville, VA; Women and Infants Hospital, Providence, RI; MD Anderson, Houston, TX.

Background: Low grade (LGSC) and high grade (HGSC) serous carcinomas of the ovary /fallopian tube may overlap morphologically yet arise from molecularly distinct precursor lesions and have vastly different prognoses. In current practice, diagnosis is requested on increasingly smaller radiologically-guided needle biopsies, and the literature offers little guidance on combining morphology with ancillary studies in this critical differential diagnosis. The aim of this study is to assess an immunohistochemical panel to help distinguish between these entities in small specimens.

Design: Included for analysis are tissue microarrays (TMA) of 10 serous cystadenomas, 33 serous borderline tumors (SBT), 10 micropapillary SBT, 14 LGSC, and 35 HGSC. TMAs were used as a proxy for small biopsy samples. Based on literature review of candidate biomarkers, a panel of immunohistochemical stains was performed: p16, p53, BRAF, ER, E-cadherin, Ki-67, MCM2, MAPK, PR, and p120. Most stains were scored semiquantitatively by percentage (1, <25%; 2, 25-75%; and 3, >75%) and intensity (0, 1+, 2+ and 3+) and multiplied, with a score of ≥ 4 positive. Otherwise, positivity was as follows: MAPK if >5%, p53 if non-wildtype, and BRAF if intensity $\geq 2+$. Stepwise logistic regression analysis was performed to generate a model discriminating between HGSC versus all others, with $p=0.05$ marking significance.

Results: E-cadherin was excluded as it was universally positive. Logistic regression analysis identified a panel of 4 stains (Ki-67, MCM2, p16, and p53) that aided in distinguishing HGSC from all others: positivity for all 4 markers strongly supported HGSC. Model based predictions were made for each sample, and agreement with true class was (28/34=82%) for HGSC and (64/67=96%) for all others. In HGSC, Ki-67 was positive in 43%, MCM2 44%, p16 71%, and p53 86%, which compares to the other serous tumors which as a group were Ki-67 positive in 3%, MCM2 1%, p16 25%, and p53 12%. This study lacked statistical power to separate LGSC from all others.

Conclusions: These results suggest that a panel of 4 stains (Ki-67, MCM2, p16, and p53) can reliably distinguish HGSC from other serous tumors in small biopsy specimens. As pathologists are asked to assess very small specimens obtained by advanced radiologically-guided techniques, this marker panel may be useful in avoiding overdiagnosis of HGSC. Further studies are needed to identify markers to aid in separating LGSC from benign/borderline tumors.

1159 Malignant Brenner Tumors Show an Absence of TERT Promoter Mutations Which Are Commonly Present in Urothelial Carcinoma

Francesca Khani, Mairo L Diolombi, Pallavi Khattar, Weihua Huang, John T Fallon, Jonathan I Epstein, Minghao Zhong. The Johns Hopkins Hospital, Baltimore, MD; New York Medical College, Westchester, NY.

Background: Recently, TERT promoter mutations have been identified in urothelial carcinoma (UC) with high frequency, and some studies suggest that they may serve as a biomarker for aggressive disease. As benign Brenner tumors of the ovary show urothelial differentiation, both histologically and immunophenotypically, we had previously investigated TERT promoter mutations in a series of these tumors and found none of them to have these mutations. Since TERT promoter mutations are found to be present in UC and are absent in benign urothelium, we investigated a series of malignant Brenner tumors of the ovary in order to determine their TERT promoter mutation status.

Design: One of our databases was searched for malignant Brenner tumors and 5 cases were identified, all of which were consultation cases. These cases were re-reviewed, and unstained slides from selected tissue blocks were obtainable from 4 of these cases for genomic DNA extraction. Macrodissection was used in some cases to ensure that 20% of the cells were neoplastic. TERT promoter mutations were detected by standard PCR-sequencing.

Results: In the 4 cases of malignant Brenner tumors with available material, the mean age of the women at diagnosis was 66 (range 53-76). All cases showed the characteristic features of malignant Brenner tumors, showing either thick, blunt, elongated papillae lined by malignant transitional-type epithelium exhibiting cystic and/or solid growth patterns and areas of stromal invasion, or a disorderly, angulated growth pattern of epithelial nests with an invasive appearance in a tumor with solid growth. High grade cytologic atypia resembling that seen in high grade UC was present in all cases. Importantly, all cases showed an associated benign or atypical proliferative Brenner component, distinguishing these tumors from solid serous carcinomas with a transitional cell component or metastatic UC from the urinary tract. TERT promoter mutations were detected in none of the 4 cases (0/4).

Conclusions: In conjunction with our prior study on a series of benign Brenner tumors which also showed an absence of TERT promoter mutations, the current study further suggests that despite the morphologic resemblance to high grade UC of the urinary tract, malignant Brenner tumors may exhibit a molecularly distinct pathogenesis. Although malignant Brenner tumors are exceedingly rare, these findings may have therapeutic implications since the molecular pathogenesis of these tumors appears to be different from typical high grade UC.

1160 Whole Exon Sequencing of Malignant Brenner Tumor: Differences from Conventional Urothelial Carcinoma

Pallavi Khattar, Francesca Khani, Mairo L Diolombi, Weihua Huang, John T Fallon, Jonathan I Epstein, Minghao Zhong. Westchester Medical Center at New York Medical College, Valhalla, NY; John Hopkins University, Baltimore, MD.

Background: Malignant Brenner tumor (MBT) is a rare form of invasive epithelial ovarian cancer and has overlapping morphology and IHC profile with urothelial carcinoma (UC). However, it is not clear if MBT is different from UC at a molecular level. In addition, the specific genetic alterations associated with MBT have not been identified. Therefore, we performed whole exon sequencing (WES) to comprehensively evaluate MBT for molecular change.

Design: One of our Surgical Pathology's Database was searched for malignant Brenner tumors and 4 consultation cases were available for this study. Macrodissection was used in some cases to ensure that at least 20% of the cells were neoplastic. Genomic DNA was extracted from formalin-fixed paraffin-embedded (FFPE) tissues by Qiagen AllPrep DNA/RNA Kit. The isolated genomic DNA was subject to targeted sequencing by using Illumina Exome Enrichment & Sequencing Kits. We used Illumina MiSeq system for paired-end (151 bp × 2) sequencing and Illumina on-instrument MiSeq Reporter to generate the variant call format (VCF) files through BWA alignment/mapping and somatic variant caller. By using Illumina VariantStudio, we performed variant filtering, annotation and interpretation with various sources of variant databases. And finally, we focused on variants in 13 most frequently mutated genes associated with UC (Nature 507, 315–322).

Results: The WES generated data with mean coverage > 60× and 24,000–33,000 single nucleotide variants (SNV) for each specimen. The 13 gene mutations found most frequently in urothelial carcinoma ---- (*FBXW7, ERBB3, STAG2, FGFR3, ERCC2, RBL, CDKN1A, EP300, PIK3CA, KDM6A, ARID1A, MLL2, TP53*), were not identified in MBT. Interestingly, *FLT3* and *NOTCH1* mutations were found in all 4 MBT specimens

Conclusions: Even though there is a high similarity between MBT and UC at the morphologic and IHC profile level, MBT carried distinct genetic mutations from those of UC. *FLT3* and *NOTCH1* mutations were highly associated with MBT and might be possible candidates for targeted therapy.

1161 Concordance between Beta-Catenin Immunohistochemistry and Next-Generation Sequencing of the CTNNB1 Gene

Grace Kim, Charanjeet Singh, Bojana Djordjevic, Russell Broaddus. MD Anderson Cancer Center, Houston, TX; University of Ottawa, Ottawa, ON, Canada.

Background: *CTNNB1* (encodes β-catenin) mutations in exon 3 are associated with worse survival and increased risk of recurrence in low-grade, low-stage endometrial endometrioid adenocarcinomas (LGLS-EEC). Exon 3 mutations prevent phosphorylation of β-catenin, promoting nuclear translocation and subsequent activation of the Wnt/β-catenin signaling pathway. Cyclin D1 is characteristically upregulated by this pathway. The goal of this study was to determine if β-catenin and/or cyclin D1 immunohistochemistry (IHC) could be used as a surrogate to *CTNNB1* gene sequencing and hence as a screening tool in the management of women with LGLS-EEC.

Design: Tumors from 51 patients with advanced/recurrent endometrial carcinomas were subjected to a next generation sequencing panel of 46/50 genes to identify potential therapeutic targets. Forty-four tumors were of pure endometrioid histotype, while 7 others had undifferentiated, non-endometrioid, or unclassifiable components. β-catenin (Biosciences) and cyclin D1 (Lab Vision) antibodies were utilized for IHC. For β-catenin IHC, presence /absence of distinct nuclear staining was noted. Cyclin-D1 IHC was categorized as either high or low nuclear expression. A third pathologist (BD), blinded to the sequencing results, also analyzed the β-catenin IHC slides.

Results: 21/51 tumors had exon 3 *CTNNB1* mutations, including 4 of the tumors that were not purely endometrioid. 2/21 cases with *CTNNB1* mutation failed to demonstrate nuclear staining. 1/30 wildtype cases had nuclear β-catenin staining in approximately 40% of the tumor cells. All cases, including those with *CTNNB1* mutations, exhibited strong membranous β-catenin staining in at least some foci of the tumor. Nuclear expression of β-catenin tended to be scattered and multi-focal. Based on β-catenin IHC, the third blinded pathologist correctly ascertained *CTNNB1* mutation status in 48/51 cases, with the exception of the 3 cases noted above. β-catenin IHC had a sensitivity of 90.5% and a specificity of 96.7% in predicting *CTNNB1* mutation status, with a false positive rate of 3.3% and a false negative rate of 9.5%. There was no correlation between cyclin-D1 IHC and *CTNNB1* mutational status.

Conclusions: β-catenin IHC proved to be a reliable screening tool in identifying endometrial carcinomas with *CTNNB1* mutation, with discordance between sequencing and IHC identified in only 6% of cases. However, due to the scattered and multi-focal nuclear β-catenin expression, tissue microarrays and small biopsies would be more likely to exhibit false negative results.

1162 Transitional Cell Metaplasia of the Uterine Cervix: A Histopathological and Immunohistochemical Analysis Suggesting an Increased Androgenic Stimulation during Cellular Differentiation

Kyu-Rae Kim, Ji Young Park, Su Hyun Yoo. Asan Medical Center, University of Ulsan College of Medicine, Seoul, Korea; Daegu Catholic University Medical Center, Daegu, Korea.

Background: Transitional cell metaplasia (TCM) occurs in various sites of female genital organs including the uterine cervix. The pathogenetic mechanism has not been clarified, however, TCM of the uterine cervix occurs predominantly in peri-/postmenopausal women. Previously, TCMs have been described in patients with adrenogenital syndrome or after androgen treatment, all of whom have increased serum androgen levels, which suggests a possible pathogenetic role of androgenic hormone.

Design: To investigate the pathogenetic role of androgenic hormone in the TCM, we compared the distribution patterns and Histocores of androgen receptor (AR), GATA-3 (a transcription factor involved in androgen regulation), and AKR1C3 (an enzyme involved in androgen biosynthesis) expressions in normal exocervical mucosa in women before age 40 (n=25), senile atrophy (n=23) and TCM (n=29) in the uterine cervix of postmenopausal women.

Results: In normal exocervical mucosa of young women, AR and GATA 3 were predominantly confined to the basal and parabasal layers with strong intensity, whereas both expressions were significantly extended up to the intermediate and superficial layers in the TCM (P<0.0001). AKR1C3 expression in normal mucosa was mostly confined to basal and parabasal layers with some extension to the intermediate layer, but in the TCM the expression was diffusely extended through the entire layers with weaker intensity. In the senile atrophy, AR and GATA3 expressions were identified throughout the entire layers, but AKR1C3 expression was nearly absent. TCM showed stronger and extended expressions of AR and GATA 3 up to the intermediate and superficial layer compared to senile atrophy, but AKR1C3 expression was significantly increased in the TCM compared to the senile atrophy.

Conclusions: Upward extension of AR and GATA 3 expressions in the TCM compared to normal mucosa and senile atrophy may suggest that androgen pathway might be related to the pathogenetic mechanism of TCM. Considering the conversion capacity of AKR1C3 from androstenedione to testosterone followed by aromatization to synthesize 17β-estradiol in the tissue, thicker epithelial layers of the TCM compared to the senile atrophy might be due to increased estrogen synthesis by AKR1C3 expression.

1163 Diagnostic Significance of Simple Nonatrophic Glands in the Interpretation of Endometrium after Progestin Treatment in Patients with Endometrial Intraepithelial Neoplasia and Endometrioid Adenocarcinoma in Young Women

Kyu-Rae Kim, Su Hyun Yoo, Stanley J Robboy. Asan Medical Center, Seoul, Korea; Duke University Medical Center, Durham, NC.

Background: Progestin therapy is useful to help preserve fertility in young patients who have developed endometrial intraepithelial neoplasia (EIN) or well differentiated endometrioid adenocarcinoma (WDEC). Intercurrent endometrial biopsy is commonly used to monitor the effects of treatment. Diagnostically, it is difficult to determine the significance of sparsely scattered, architecturally simple (single separated) glands lined by nonatrophic epithelium having round nuclei and abundant cytoplasm embedded in a decidualized stroma.

Design: To examine the biological properties of those simple nonatrophic glands after progestin treatment, loss of PTEN and PAX2 expression was measured in nonatrophic glands (132 foci) and atrophic glands (132 foci) within a decidualized stroma in 3 consecutive sections of 84 follow-up curettage specimens from 43 patients with EIN or WDEC. Separately, incidences of atrophic and nonatrophic glands were searched among 59 patients with either successful delivery after treatment (n=23) or recurrent/persistent disease (n=36).

Results: Complete loss of PTEN or PAX2 expression was identified in 66% and 69% of nonatrophic glands, respectively, while the losses were identified in 3.8% and 0.8% of atrophic glands, respectively (p<.0001). The incidences of decreased expressions for PTEN and PAX2 were not significantly different between nonatrophic and atrophic glands. Among 23 patients who had a successful delivery after progestin treatment, 43% of the patients had only atrophic glands at the last follow-up before pregnancy, while among 36 patients with recurrent or persistent disease, 25% of the patients had only atrophic glands without residual disease at the last follow-up before recurrence.

Conclusions: Sparse, simple, nonatrophic endometrial glands have significantly higher incidence of PTEN or PAX2 loss compared to the atrophic glands. The glands with loss of PTEN or PAX2 expression *per se* do not necessarily mean precancerous or cancerous glands in the pretreatment specimens, however, persistent simple nonatrophic glands showing loss of PTEN or PAX2 after progestin treatment may represent residual neoplastic glands.

1164 CTNNB1 (Beta Catenin) Mutation Identifies Patients with Grades 1 or 2 Endometrioid-Type Endometrial Carcinoma at Risk of Recurrence

Katherine Kurnit, Bryan Fellman, Diana Urbauer, Gordon Mills, Russell Broaddus. MDACC, Houston, TX.

Background: *CTNNB1* (encodes β-catenin) mutation is one of the more common mutations in endometrial cancer (EC). The purpose of this study was to determine pathologic and demographic characteristics of *CTNNB1* mutant ECs with an emphasis on survival outcomes.

Design: We performed a retrospective chart review of all patients with histologically-confirmed EC who sought care at University of Texas MD Anderson Cancer Center and underwent either clinical (46/50 gene panel) or research-based (200 gene panel) next generation sequencing of their tumors since 2000. Clinical information including demographic information, pathology information, and clinical outcomes was extracted using a chart review. Statistical analyses included Fisher's exact, chi-squared, and Kruskal-Wallis tests, and Kaplan-Meier product-limit estimator was then used to calculate recurrence-free survival (RFS).

Results: 343 patients were included in this analysis, 17% of which had tumors with an exon 3 *CTNNB1* mutation. Patients with tumors that had *CTNNB1* mutations were significantly younger and had a higher body mass index compared to women with *CTNNB1* wildtype tumors. *CTNNB1* mutated tumors were more frequently endometrioid (EEC) histology, more often grade 1, and less often had lymphovascular space invasion. FIGO stage at time of hysterectomy was not significantly different between the *CTNNB1* mutant and wildtype groups. Among low grade (grade 1 or 2) EEC, *CTNNB1* mutants had higher rates of recurrence (44 vs 25%, p = 0.017). Within this same low grade EEC group, *CTNNB1* mutants had worse RFS than *CTNNB1* wild type tumors (median

6.14 vs 11.31 years, $p=0.039$). There were no differences in rates of adjuvant therapy, advanced stage, or *TP53* mutations between the *CTNNB1* groups within the low grade EEC group. *KRAS* mutations were more common among *CTNNB1* wildtype tumors. **Conclusions:** *CTNNB1* mutations are more common in younger, obese EC patients, women we tend to think of as having good prognosis, hormone-driven malignancies. However, *CTNNB1* mutation is associated with increased risk of recurrence and with significantly decreased RFS in this patient group. Assessment of these mutations may be useful in the up-front identification of women with low grade EC at risk of recurrence.

1165 Molecular Characterization of High Grade Endometrial Stromal Sarcoma

Nicholas Ladwig, Joseph T Rabban, Charles Zaloudek, Nancy M Joseph, Gregor Krings, Karuna Garg, University of California San Francisco, San Francisco, CA.

Background: The classification of endometrial stromal sarcomas (ESS) was recently modified in the 2014 WHO, with reintroduction of the high-grade (HG-ESS) category in addition to low-grade ESS (LG-ESS) and undifferentiated uterine sarcoma (UUS). HG-ESS is currently poorly defined and the WHO description pertains primarily to tumors with the YWHAE-NUTM2 translocation that are a distinct and relatively well described entity. However, many uterine sarcomas that show features of HG-ESS lack this translocation and are not well characterized. The aim of this study was to assess the morphologic, molecular and clinical features of HG-ESS.

Design: We identified 6 cases of HG-ESS. We included for comparison 1 UUS and 4 LG-ESS. DNA was extracted from formalin-fixed paraffin embedded tissue. Capture-based next generation sequencing was performed using an assay that targets the coding regions of over 500 cancer genes as well as select introns, covering a total of 2.8 megabases.

Results: One of 6 HG-ESS showed the YWHAE-NUTM2 translocation which was also seen in 1 fibroblastic LG-ESS. Of the 5 remaining HG-ESS, 1 showed somatic mutations in *POLE* and *PTEN* and one HG-ESS with heterologous rhabdomyoblastic differentiation showed mutations in *PTEN* and *PIK3CA*. One case showed amplification of *MDM2/CDK4*.

Age	Diagnosis	Stage	Metastasis	Status	Fusion	Somatic Mutations	CNV	Loss		Gain	
32	HG-ESS	IIIB	Disseminated	Dead of disease (DOD)	YWHAE-NUTM2	-	-	-	-	-	-
78	HG-ESS	IC	-	No evidence of disease (NED)	-	<i>POLE</i> (p.P286R); <i>PTEN</i> (p.E299)	-	-	-	7p	-
44	HG-ESS	IIA	Unknown (U)	Lost to follow up (LTF)	-	-	X	-	-	1q; 10q	-
54	HG-ESS	IIIB	U	LTF	-	-	-	-	-	12q-15q (<i>MDM2</i> , <i>CDK4</i>)	-
60	HG-ESS	IC	U	LTF	-	-	4	-	-	1p34, 6p11-21.3, 19q13, 18q21.2; 12	-
60	HG-ESS (with rhabdomyoblastic differentiation)	IIA	Lungs	Hospice	-	<i>PTEN</i> (p.R130Q); <i>PIK3CA</i> (p.H1047R)	16q	-	-	1q; 8	-
61	UUS	IA	-	LTF	-	<i>TP53</i> (p.E298); <i>MED12</i> (p.G44D)	Many	-	-	Many	-
44	LG-ESS	IB	Kidney, IVC	NED	<i>JAZF1-PHF1</i>	-	-	-	-	-	-
52	LG-ESS	IB	-	NED	<i>JAZF1-PHF1</i>	-	-	-	-	1p; 5q; 7p	-
67	LG-ESS	U	U	U	-	-	-	-	-	6q; 11p	3p; 11q
33	LG-ESS (fibroblastic variant)	IA	-	LTF	YWHAE-NUTM2	-	-	-	-	-	-

Conclusions: Although small, our study shows that HG-ESS is a molecularly heterogeneous entity and only a small proportion of tumors show the YWHAE-NUTM2 translocation. We found other interesting somatic mutations and amplifications in these tumors. Further studies are needed to assess the frequency of these abnormalities and to better define the category of HG-ESS.

1166 Invasive Stratified Mucin-Producing Carcinoma and Stratified Mucin-Producing Intraepithelial Lesion (SMILE): 15 Cases Presenting a Spectrum of Cervical Neoplasia with Description of a Distinctive Variant of Invasive Adenocarcinoma

Ricardo R Lastra, Kay J Park, John Schoolmeester, University of Chicago, Chicago, IL; Memorial Sloan Kettering Cancer Center, New York, NY; Mayo Clinic, Rochester, MN.

Background: Stratified mucin-producing intraepithelial lesion (SMILE) is a cervical intraepithelial lesion, distinct from conventional squamous or glandular counterparts, believed to arise from embryonic cells at the transformation zone via transdifferentiation during high risk HPV-associated carcinogenesis. We identified a distinct form of invasive cervical carcinoma with morphologic features identical to those in SMILE we term invasive stratified mucin-producing carcinoma.

Design: Fifteen cases from 15 patients (mean 36 years; range 22 to 64 years) were retrieved from the pathology archives of multiple institutions with either a diagnosis of SMILE or invasive cervical carcinoma with a description or comment about the invasive tumor's resemblance to SMILE. Clinical follow up was included when available.

Results: Seven cases had solely intraepithelial disease with a component of SMILE (mean 29 years; range 22 to 40 years). The 8 other cases had invasive stratified-mucin producing carcinoma (mean 44; range 34 to 64 years) in which SMILE was identified in 7. All cases of invasive stratified-mucin producing carcinoma demonstrated stratified, immature nuclei with intracytoplasmic mucin which morphologically varied between cases from "mucin-rich" to "mucin-poor" in a similar manner to SMILE. All cases had mitotic figures, apoptotic debris and an intralesional neutrophilic infiltrate was seen in the majority of cases. In cases of invasive carcinoma, the depth of invasion ranged from less than 1 mm to 19 mm. Follow-up was available in 8 cases and ranged from 1 to 36 months (mean 11). Three cases of invasive stratified-mucin producing carcinoma had biopsy or resection proven metastatic carcinoma on follow-up.

Conclusions: Given that SMILE is well rooted as a distinct intraepithelial lesion, we propose the term invasive stratified mucin-producing carcinoma to describe its corresponding invasive carcinoma to maintain consistency in nomenclature and to create a spectrum of cervical neoplasia. Treatment of invasive stratified mucin-producing should not differ from other forms of invasive cervical carcinoma. However, awareness of this entity and its capacity for invasion and distant metastasis is important to ensure adequate patient management.

1167 Intraoperative Consultation in Low Grade Endometrial Endometrioid Adenocarcinoma: Is Frozen Section Superior to Gross Examination?

Barrett C Lawson, Esther Soundar, Shilpa Jain, Matthew L Anderson, Ramya P Masand, Baylor College of Medicine, Houston, TX.

Background: Criteria used to triage women undergoing hysterectomy for low grade endometrioid endometrial carcinoma (LGEEAC) for surgical staging remain controversial. Some use preoperative biopsy grade along with intraoperative gross assessment of myoinvasion (MI) and tumor size (TS); others perform frozen sections (FS) to assess grade, MI and lymphovascular invasion (LVI). Increased OR time due to FS increases complications and morbidity. We sought to determine whether performing intraoperative frozen sections (IOFS) provides superior risk stratification in LGEEAC as compared to gross assessment alone.

Design: Retrospective analysis of 153 patients (pts) with LGEEAC on endometrial biopsy whose uteri were sent for intraoperative consultation was performed. IOFS findings were recorded including microscopic grade, gross and microscopic depth of MI and gross TS. Same parameters on final diagnosis were noted. Decision to stage based on IOFS and lymph node (LN) status in cases with staging was recorded.

Results:

Biopsy Histology	Frozen Histology	Final histology
Hyperplasia (n=24)	Hyperplasia (11), Ungraded (6), Grade 1(3), Grade 2(2), No ca (2)	Hyperplasia (1), Grade 1(11), Grade 2(12)
Grade 1 (n=68)	Hyperplasia (5), Ungraded (12), Grade 1(31), Grade 2(12), High grade ca (2), No ca (6)	Grade 1(28), Grade 2(33), High grade ca(7)
Grade 2 (n=48)	Hyperplasia (3), Ungraded (11), Grade 1(8), Grade 2(23), No ca (3)	Grade 1(4), Grade 2(41), High grade ca(3)
Ungraded (n=6)	Ungraded (1), Grade 1 (4), High grade ca(1)	Grade 1(3), Grade 2 (3)

High concordance was observed between preoperative biopsy grade and FS. Depth of MI was concordant in 129 of 133 cases. In 4 cases, where gross MI differed from FS, final was concordant with gross in 2 and FS in 2. Of 48 cases (TS>2cm) with staging, 3 had + LNs (6%), and of 20 cases (TS<=2cm) with staging, 4 had +LNs (20%). 84 pts met gross criteria for staging; 51 were staged: 5 (9.8%) had + LNs. Of those not meeting criteria, 17 were staged: 2 (11.8%) with + LNs. 23 pts met frozen criteria and were staged; 2 (8.7%) had + LNs. Of 124 pts not meeting criteria; 41 were staged: 4 (9.8%) had+ LNs.

Conclusions: Addition of FS analysis to preoperative biopsy and intraoperative gross assessment has little impact on intraoperative decisions, making IOFS redundant. Neither gross nor frozen criteria currently used are accurate in identifying pts with risk of nodal disease. Future efforts should focus on developing tools to improve accuracy and decrease unnecessary morbidity.

1168 Genomewide Copy Number Analysis of Müllerian Adenosarcoma Identified Increased Chromosomal Instability and Chromothripsis-Like Profiles in the Aggressive Subgroup

Jen-Chieh Lee, Tzu-Pin Lu, Chun A Changou, Cher-Wei Liang, Hsien-Neng Huang, Alexandra Lauria, Hsuan-Ying Huang, Ben Davidson, Ming-Chieh Lin, Kuan-Ting Kuo. National Taiwan University Hospital, National Taiwan University College of Medicine, Taipei, Taiwan; National Taiwan University, Taipei, Taiwan; Taipei Medical University, Taipei, Taiwan; Brigham and Women's Hospital and Harvard Medical School, Boston, MA; Kaohsiung Chang Gung Memorial Hospital and Chang Gung University College of Medicine, Kaohsiung, Taiwan; The Norwegian Radium Hospital, Oslo University Hospital, Oslo, Norway.

Background: Müllerian adenosarcomas (MAs) are malignant gynecologic tumors. Sarcomatous overgrowth (SO) predicts poor prognosis. The genomic landscape remains poorly understood. We conducted this study to characterize the genomewide copy number (CN) variations in MA.

Design: 16 MAs, including 8 with and 8 without SO, were subjected to CN analysis using a SNP array kit designed for formalin-fixed paraffin-embedded tissue. FISH and IHC were performed for validation.

Results: CN variations, particularly losses, were significantly higher in cases with SO. Frequent amplifications of chromosomal 12q were noted, involving *CDK4*, *MDM2*, *CPM*, *YEATS4*, *DDIT3* and *HMG A2*, without obvious association with SO status. Losses of chromosomes 13q, 9p, 16q and 17q were among the most prevalent and almost limited to cases with SO. *MDM2* and *CDK4* amplification, as well as losses of *RB1* and *CDKN2A/B*, were verified by FISH. By IHC, expression of *MDM2* and *CDK4* highly correlated with *MDM2/CDK4* coamplification. *HMG A2* expression was observed in, but not limited to, all cases with *HMG A2* amplification. Both cases with *RB1* loss were negative for RB immunostaining. Chromothripsis-like CN profiles involving chromosome 12 or 14 were observed in 3 fatal cases with SO. With whole chromosome painting, dividing tumor cells in all 3 cases were shown to have scattered extrachromosomal materials derived from chromosomes involved by chromothripsis, suggesting this phenomenon may serve as visual evidence for chromothripsis in paraffin tissue.

Conclusions: We identified frequent chromosome 12q amplifications in MA with potential therapeutic implications. Global chromosomal instability and chromothripsis were more frequent in cases with SO. To our knowledge, this is the first time that evidence of chromothripsis has been demonstrated in paraffin-embedded clinical tissues and in MAs.

1169 P16 Expression and Biologic Behavior of Flat Vulvar Low-Grade Squamous Intraepithelial Lesions (LSIL)

Natasha Lewis, Kruti Maniar. Northwestern University-Feinberg School of Medicine, Chicago, IL.

Background: Flat vulvar LSIL (VIN 1, "flat condyloma") is uncommon and poorly understood. Current recommendations endorse treating all vulvar LSIL conservatively, with some controversy as to whether VIN 1 represents a true biologic entity. However, a significant proportion of VIN 1 has been shown to harbor high-risk HPV, with an as yet unclear rate of progression to higher grade lesions. We aimed to better characterize the biology of flat vulvar LSIL and assess a potential prognostic role for the biomarker p16 (overexpressed in high-risk HPV-related lesions) for subsequent development of HSIL.

Design: All available cases of flat vulvar LSIL from 2003-2010 were reviewed by two pathologists for confirmation of diagnosis, with p16 immunostaining (Biocare, clone G175-405) performed in cases with sufficient material. Clinical data and pathology results were obtained from medical records. The frequency of subsequent development of vulvar HSIL/invasive carcinoma was compared between p16(+) (diffuse block reactivity) and p16(-) (all other expression patterns) cases using the Fisher exact test.

Results: 51 cases of flat vulvar LSIL were identified from 50 patients (age range 22-73 years, median 39.5 years). 2 of 51 cases (4%) showed p16 positivity. Follow-up data was available in 34 cases (follow-up range 0.4-132.9 months, mean 58.0 months). 1 of 2 p16(+) cases and 1 of 48 p16(-) cases with follow-up developed subsequent vulvar HSIL (VIN 2-3) (p=0.079). Mean time from biopsy to development of vulvar HSIL was 8.6 months. For the 18 patients with treatment information available, 10 (56%) received treatment after biopsy (CO2 laser vaporization, imiquimod, cryotherapy, trichloroacetic acid or excision). 1 of 2 p16(+) cases (50%) and 11 of 48 p16(-) cases (23%) had high-grade HPV-related lesions in additional lower anogenital tract sites (cervical HSIL, invasive cervical squamous cell carcinoma or adenocarcinoma) (p=0.426).

Conclusions: Vulvar LSIL is infrequently p16(+) (4%), suggesting cell cycle disruption by high-risk HPV is uncommon in these lesions. Few patients with vulvar LSIL developed subsequent higher grade vulvar lesions (5.9% of all cases with follow-up), which may be partly due to the frequent use of destructive treatment; however, this rate was higher among p16(+) cases (50%) than p16(-) cases (2.1%). While this difference was not statistically significant, the findings suggest that p16 positivity in vulvar LSIL may help predict subsequent development of HSIL. Further studies are warranted to better define the significance of this marker in flat vulvar LSIL.

1170 The Utility of Next Generation Sequencing-Based Gene Fusion Detection Assay in the Diagnosis of Endometrial Stromal Sarcoma

Xiaodong Li, Mona Anand, Josh Haines, Namitha Manoj, Brian Kudlow, Marisa R Nucci, Colin JR Stewart, Cheng-Han Lee. University of Alberta, Edmonton, AB, Canada; ArcherDX, Inc, Boulder, CO; Brigham and Women's Hospital, Boston, MA; King Edward Memorial Hospital, Perth, Australia.

Background: Endometrial stromal sarcomas (ESS) are classified into a low-grade type (LGESS) that harbors genetic fusion involving *JAZF1* and a high-grade type (HGESS) that harbors *YWHAE-NUTM2A/B* fusions. Because of the multiple potential fusion combinations in ESS, simultaneous interrogation for the different fusion possibilities can reduce turnaround time when molecular confirmation is sought.

Design: We examined here the utility of a next generation sequencing-based fusion assay in 11 LGESS and 5 HGESS that were previously confirmed to harbor ESS genetic rearrangements by fluorescence in situ hybridization (FISH) analysis.

Results: The fusion assay identified junctional fusion transcript sequences that corresponded to the known FISH results in all cases (Table 1). Case 6 harbored a *JAZF1-PHF1* fusion that contained an in-frame 72bp intergenic sequence upstream of *PHF1* at the junctional region and this was correctly identified because of the open-ended nature of the assay design. We also included two FISH-negative non-ESS uterine sarcomas as negative controls and there were no fusion candidates identified in these non-ESS uterine sarcomas.

No.	Diagnosis	Age	Site	FISH	NGS assay
1	HGESS	45	Uterus	<i>YWHAE/NUTM2A</i>	<i>YWHAE-NUTM2A</i>
2	HGESS	67	Uterus	<i>YWHAE/NUTM2A</i>	<i>YWHAE-NUTM2A</i>
3	HGESS	47	Uterus	<i>YWHAE/NUTM2B</i>	<i>YWHAE-NUTM2B</i>
4	HGESS	26	Uterus	<i>YWHAE</i>	<i>YWHAE-NUTM2B</i>
5	HGESS	57	Uterus	<i>YWHAE/NUTM2B</i>	<i>YWHAE-NUTM2B</i>
6	LGESS	21	Uterus	<i>JAZF1/PHF1</i>	<i>JAZF1-PHF1</i>
7	LGESS	33	Uterus	<i>JAZF1/PHF1</i>	<i>JAZF1-PHF1</i>
8	LGESS	69	Uterus	<i>JAZF1/SUZ12</i>	<i>JAZF1-SUZ12</i>
9	LGESS	69	Uterus	<i>JAZF1/SUZ12</i>	<i>JAZF1-SUZ12</i>
10	LGESS	40	Uterus	<i>JAZF1/SUZ12</i>	<i>JAZF1-SUZ12</i>
11	LGESS	51	Ovary	<i>JAZF1</i>	<i>JAZF1-SUZ12</i>
12	LGESS	26	Uterus	<i>JAZF1</i>	<i>JAZF1-PHF1</i>
13	LGESS	49	Uterus	<i>JAZF1</i>	<i>JAZF1-PHF1</i>
14	LGESS	61	Uterus	<i>JAZF1</i>	<i>JAZF1-SUZ12</i>
15	LGESS	37	Uterus	<i>JAZF1</i>	<i>JAZF1-SUZ12</i>
16	LGESS	56	Peritoneum	No rearrangement	No fusions
17	Adenosarcoma	55	Uterus	No rearrangement	No fusions
18	Leiomyosarcoma	61	Uterus		

Conclusions: Our findings demonstrate the utility of next generation sequencing-based fusion assay in the diagnosis of ESS.

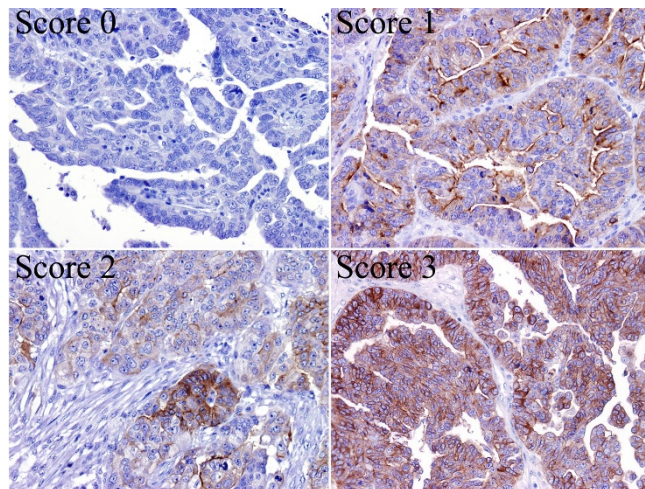
1171 B7-H4 Expression in Ovarian Serous Carcinoma: A Study of 306 Tissue Samples

Li Liang, Yi Jiang, Jun-song Chen, Na Niu, Jinsong Liu. The University of Texas MD Anderson Cancer Center, Houston, TX; The First Affiliated Hospital of Nanjing Medical University, Nanjing, China.

Background: Immune therapy against certain immune checkpoint inhibitors, such as PD-L1, a member of the B7 family, has been quite effective in suppressing the growth of a subset of incurable cancers. However, it is unclear why anti-PD-L1 therapy only works in a subset of cancers, and it is possible that other members of the B7 family may be involved in suppressing the immune response. B7-H4, a novel member of the B7 family, has been demonstrated to inhibit T-cell responses by inhibiting T-cell proliferation and cytokine production. We therefore examined B7-H4 expression patterns in ovarian cancer.

Design: We investigated B7-H4 expression patterns in 306 tissue samples of ovarian serous carcinoma using tissue microarrays and anti-B7-H4 antibody (D1M81, 1:200; Cell Signaling Technology). The immunohistochemistry results were scored as follows: 0, no staining; 1, apical membranous and cytoplasmic staining; 2, mixed pattern with circumferential membranous staining in less than 10% of tumor cells; 3, circumferential membranous staining in at least 10% of tumor cells.

Results: B7-H4 protein was expressed in 267 (91%) of 293 high-grade serous carcinomas, of which 63 samples were scored as 1, 70 samples were scored as 2, and 134 samples were scored as 3. B7-H4 protein was expressed in 9 (69%) of 13 low-grade serous carcinomas, of which 6 samples were scored as 1, 2 samples were scored as 2, and 1 sample was scored as 3. B7-H4 protein expression was not associated with disease stages. However, there was significant difference in B7-H4 protein expression between high-grade and low-grade serous carcinoma (Fisher's exact test, $P < 0.05$).



Conclusions: Our large-cohort study demonstrated that B7-H4 protein was highly expressed in the majority of high-grade ovarian serous carcinomas, suggesting that this immune-modulatory molecule may play an important role in these tumors. Future studies are warranted to determine whether B7-H4 represents a novel target for immune therapy and whether B7-H4 expression can serve as a predictive marker.

1172 Primary Glial and Neuronal Tumors of the Ovary or Peritoneum: A Clinicopathological Study of 11 Cases

Li Liang, Adriana Olar, Yi Jiang, Na Niu, Anna Yemelyanova, Gregory Fuller, Jinsong Liu. The University of Texas MD Anderson Cancer Center, Houston, TX; The First Affiliated Hospital of Nanjing Medical University, Nanjing, China.

Background: Primary glial and neuronal tumors of the ovary and peritoneum are rare neuroectodermal-type tumors, morphologically and immunophenotypically, but not necessarily molecularly, identical to their counterparts in the central nervous system.

Design: We retrospectively reviewed 11 cases, including 4 ependymomas, 6 astrocytic tumors and 1 neurocytoma.

Results: Patient age ranged from 9 to 50 years (median, 24 years). In contrast to astrocytic and neuronal tumors, all ependymomas with detailed history (n=3) were not associated with any other ovarian neoplasm. The neurocytoma arose in association with mature teratomatous components in a patient with a history of treated mixed germ cell tumor. Immunohistochemical staining showed that 7 ependymal and astrocytic tumors were positive for GFAP, and 2 ependymomas were positive for estrogen and progesterone receptors. The neurocytoma was positive for synaptophysin, and negative for GFAP, S100 protein and SALL4. No *IDH1-R132H* mutation was detected in 2 of 2 (0%) astrocytomas by immunohistochemistry. Next-generation sequencing was performed on additional 2 ependymomas and 2 astrocytomas, but detected no mutations in a panel of 50 genes that included *IDH1*, *IDH2*, *TP53*, *PIK3CA*, *EGFR*, *BRAF* and *PTEN*. Follow-up was available in 8 patients (median, 8 months).

Patient	Age	Diagnosis	Other ovarian neoplasms	IDH1 mutation	Follow-up (months)
1	35	Ependymoma	Unknown	NA	NA
2	50	Ependymoma	None	Negative	AWD, 59
3	36	Anaplastic ependymoma	None	NA	AWD, 9
4	29	Anaplastic ependymoma	None	Negative	AWD, 3
5	38	Astrocytoma	Mixed germ cell tumor	Negative	NA
6	24	Anaplastic astrocytoma	Mature teratoma	NA	NED, 5
7	17	High-grade glioma/glioblastoma	Immature teratoma	Negative	NED, 8
8	19	High-grade glioma/glioblastoma	Immature teratoma	NA	NED, 18
9	9	High-grade glioma/glioblastoma	Immature teratoma	Negative	NA
10	10	High-grade glioma/glioblastoma	Immature teratoma	Negative	AWD, 4
11	22	Neurocytoma	Mixed germ cell tumor	Negative	AWD, 8

Conclusions: Primary glial and neuronal tumors of the ovary can arise independently or in association with other ovarian germ cell tumor components. Pathologists should be aware of these probably underdiagnosed tumors.

1173 High NRF2 with p62 Co-Expression in PTEN Null Endometrial Endometrioid Carcinomas Is Associated with Different Survival Impact in Early vs Late Stage Disease

Diana Lim, Ying Ni, Meusia Neo, Hoe Meng Chen, Charis Eng, Joanne Ngeow. National University Health System, Singapore, Singapore; Singapore Polytechnic, Singapore, Singapore; Cleveland Clinic, Cleveland, OH; National Cancer Centre, Singapore, Singapore.

Background: Nuclear factor erythroid 2-related factor 2 (NRF2) has traditionally been considered as a cancer-preventive transcription factor as it regulates several cytoprotective genes in response to oxidative and inflammatory insults. However, constitutive activation of NRF2 promotes carcinogenesis and imparts chemoresistance. Recent studies show that PTEN represses NRF2 activity and PTEN loss inhibits NRF2 degradation, enhancing cellular accumulation of NRF2. As PTEN inactivation frequently occurs in endometrial endometrioid carcinomas (EEC), we hypothesized that NRF2 immunorepression would be up-regulated in these tumors. We further investigated if the cellular autophagy pathway may also account for NRF2 activation in EEC as in-vitro studies show that the autophagy adaptor protein p62 competes with Keap1 (negative regulator of NRF2) for binding with NRF2.

Design: Immunohistochemical staining for NRF2, p62 and PTEN was performed on a tissue microarray constructed from 200 cases of EEC. NRF2 and p62 expression was assessed using the H-score method, with positive staining defined as H score ≥ 2 . PTEN loss was defined as absent staining in tumor cells with positive internal control. Immunorepression profiles were correlated with clinicopathological data.

Results: Median age of diagnosis was 56 years (range 25-89). 178 tumors were FIGO stages I/II and 22 were stages III/IV (120 G1, 54 G2, 26 G3). 144 tumors demonstrated PTEN loss. Of these, 102 (70%) exhibited concurrent NRF2 overexpression ($p=0.009$). 75% of tumors with PTEN-/NRF2+ also showed p62 positivity ($p=0.01$). A PTEN-/NRF2+/p62+ immunophenotype did not show any association with age of diagnosis, FIGO stage, grade, lymphovascular or depth of myometrial invasion. Interestingly, while tumors with PTEN-/NRF2+/p62+ appears to be associated with better overall survival as a group (mean 147 versus 121 months), Stage 4 tumors (n=7) with PTEN-/NRF2+/p62+ were associated with poorer survival (mean 4.8 versus 15 months) suggesting that these tumors may be more resistant to systemic therapy.

Conclusions: PTEN loss is associated with NRF2/p62 overexpression in EEC. NRF2 may represent a novel therapeutic target in endometrial cancers. More studies are needed to validate our observation of poorer survival amongst Stage 4 patients with activated NRF2/p62 phenotype.

1174 Distinct SMARCA4/ARID1A and Genomic Profiles in Classic Versus Large Cell Variant of Ovarian Small Cell Carcinoma, Hypercalcemic-type

Douglas Lin, Joel Greenbowe, Jeffrey S Ross, Siraj M Ali, Julia A Elvin. Beth Israel Deaconess Medical Center, Boston, MA; Foundation Medicine, Cambridge, MA; Albany Medical College, Albany, NY.

Background: Ovarian small cell carcinoma, hypercalcemic-type (OSCCHT) is an extremely aggressive neoplasm that usually occurs in young women and is associated with hypercalcemia and poor prognosis. Although the classic tumor morphology is composed diffuse sheets of small cells with scant cytoplasm and follicle-like spaces, a large cell variant with eosinophilic cytoplasm has been described. We performed comprehensive genomic profiling to uncover clinically and pathophysiologically relevant genomic alterations in OSCCHT.

Design: DNA was extracted from formalin-fixed, paraffin-embedded tissue from 12 cases of OSCCHT (including 10 cases of classic morphology and 2 cases exhibiting a large cell variant morphology). Comprehensive genomic profiling (CGP) based on targeted next generation sequencing (NGS) was performed on hybridization-captured, adaptor ligation-based libraries in a CLIA-certified lab, by surveying 315 genes for all classes of genomic alterations (base substitutions, insertions/deletions, copy number alterations, and rearrangements).

Results: CGP revealed inactivating SMARCA4 alterations and a low mutation rate profile (average 3.9 genomic alterations per case) in 100% (10 of 10) OSCCHT with classic morphology. In contrast, 2 of 2 cases of OSCCHT with large cell variant morphology exhibited a high mutation rate (hypermutated) profile (average 69.5 genomic events per case) with alterations in ARID1A, which co-exists and forms part of the same SWI/SNF chromatin remodeling complex as SMARCA4.

Conclusions: Our results support a role for alterations of the SMARCA4/ARID1A SWI/SNF chromatin remodeling complex in the pathogenesis of OSCCHT. However, different mutation rate and genomic profiles seen in classic versus the large cell variant of such strongly suggest that they may be biologically distinct entities. Our results also support the notion that targeted therapies against SMARCA2 ATPase or EZH2 inhibitors, which may be effective in SMARCA4-deficient tumors, should be considered in OSCCHT and that immunotherapies may be considered in the large cell variant.

1175 Genomic Analysis of Ovarian PNETs by Next Generation Sequencing Reveals Recurrent Copy Number and TP53 Alterations

Christopher Liverman, Nancy M Joseph, Charles Zaloudek. University of California San Francisco, San Francisco, CA.

Background: Primitive neuroectodermal tumors (PNETs) of the ovary are rare germ cell tumors thought to arise from the immature neuroepithelium of teratomas. Due to their rarity, the molecular underpinnings of ovarian PNETs are largely unknown. Peripheral PNET/Ewing Sarcoma shows translocation of the EWSR1 gene. A subset of central nervous system PNETs show MYCN or MYC amplification. The molecular drivers of ovarian PNET remain unknown. The purpose of this study was to determine the genomic alterations in ovarian PNETs using FISH analysis and next generation sequencing.

Design: We identified six cases of previously well-characterized ovarian PNET from our consult files.

DNA was extracted from formalin-fixed paraffin embedded tissue. Capture-based next generation sequencing was performed using an assay that targets the coding regions of over 500 cancer genes as well as select introns, covering a total of 2.8 Megabases (MB). Additionally, fluorescent in situ hybridization (FISH) for EWS rearrangement, MYCN and MYC copy number was performed on all cases. Immunohistochemistry for p53 was also performed on all cases.

Results: Average sequencing depth was 500x. Recurrent copy number alterations (CNAs) were identified as detailed in Table 1.

Three of the six tumors demonstrated mutation in TP53 (p.R337L, p.R282W and p.R110fs).

Gains		Losses	
Chromosome	# of Tumors	Chromosome	# of Tumors
2	5/6	14	5/6
8	4/6	9	4/6
17	3/6	13q	4/6
20q	3/6	10q	3/6
1q	3/6	15	3/6
5p	2/6	4	3/6
3q	2/6		

These three tumors demonstrated corresponding aberrant p53 staining by immunohistochemistry, with two tumors showing p53 overexpression and one showing complete p53 loss. PTEN mutation was identified in one case without a p53 mutation. All cases were negative for EWS re-arrangement, MYC and MYCN amplification by FISH. NGS analysis confirmed the absence of EWS rearrangement, MYC and MYCN amplification.

Conclusions: Ovarian PNETs demonstrate recurrent copy number alterations and TP53 mutations suggesting a distinct molecular phenotype for this rare tumor type. These findings have important diagnostic relevance for the classification of ovarian germ cell tumors. Future studies comparing the genomics of ovarian PNET with immature teratomas could shed light on the pathogenesis of this tumor.

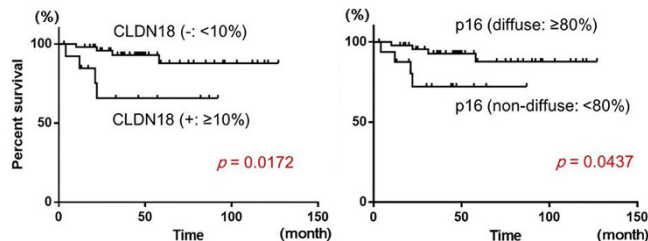
1176 Expression of Claudin-18, a Novel Gastric Marker, Is Associated with Poor Prognosis in Cervical Adenocarcinoma

Daichi Maeda. Akita University, Graduate School of Medicine, Akita, Japan.

Background: Gastric-type mucinous adenocarcinoma (GA) is now recognized as a distinct subtype of uterine cervical adenocarcinoma, and its prognosis has been reported to be poor. However, morphological distinction between GAs and non-GAs are often difficult. We have previously shown that a novel gastric marker claudin-18 (CLDN18) is almost specifically expressed in GAs. We believe that positivity for CLDN18 along with non-diffuse pattern of p16 staining are hallmark immunohistochemical features of GAs. In this study, we investigated clinical significance of these immunohistochemical markers along with a conventional gastric marker, HIK1083, in cervical adenocarcinomas.

Design: This retrospective study was based on 65 cases of cervical adenocarcinoma. Morphologically, 9 cases revealed typical GA features. In 4 cases, the possibility of GA was raised. Most other cases were classified as usual-type adenocarcinoma. Immunohistochemistry for CLDN18, HIK1083 and p16 was performed. The association between expression of these markers and clinicopathological factors including parametrial invasion, vaginal invasion, lymph node metastasis, T-stage and overall survival was then evaluated.

Results: CLDN18-positivity ($\geq 10\%$) and HIK1083-positivity ($\geq 10\%$) was observed in 14 cases (21.5%) and 7 cases (10.7%), respectively. Vaginal invasion was more frequent in CLDN18-positive cases. ($p=0.004$) Further, CLDN18 expression was associated with poor overall survival. ($p=0.0172$) On the other hand, HIK1083 expression did not correlate with any of the clinicopathological factors assessed. Non-diffuse pattern of p16 staining ($<80\%$) was observed in 17 cases (26.2%), and it was associated with lymph node metastasis ($p=0.0352$) and poor overall survival ($p=0.0437$).



Conclusions: Expression of CLDN18, a novel gastric marker, is a poor prognostic indicator in uterine cervical adenocarcinoma. Immunohistochemistry for CLDN18 and p16 is useful not only for the diagnosis of GAs, but also for the prediction of patient outcome in cervical adenocarcinoma in general.

1177 Would Fallopian Tube Tissue Be Left Behind? Quantitation of Tubal-Type Epithelium within Ovary at Time of Risk Reducing Salpingo-Oophorectomy – Implications for Ovary Conserving Strategies

Sarah Mahon, Julie McFadden, Noreen Gleeson, Ciaran O'Riain. St. James's Hospital, Dublin, Ireland.

Background: Evidence regarding tubal origin of extrauterine high grade serous carcinoma (HGSC) has led to suggestions that salpingectomy only or salpingectomy with delayed oophorectomy could be an alternative to risk reducing bilateral salpingo-oophorectomy (RRBSO) surgery in high risk individuals. Among the considerations before adopting this strategy is that HGSC may potentially arise in tubal tissue present as inclusion cysts in ovaries. Ovarian cortical inclusion cysts are of two types; tubal type lined by ciliated epithelium (PAX8+, Calretinin-) and mesothelial type lined by flat cuboidal cells (PAX8-, Calretinin+). We quantified tubal cysts present within the ovaries of women undergoing RRBSO to assess whether ovary-conserving surgery would lead to a significant amount of tubal tissue being left in situ and potentially acting as a source for subsequent development of HGSC.

Design: All ovarian tissue from consecutive RRBSO specimens (n=65; age range 33-72 years; median 48; average 49) were reviewed by two pathologists. The number and size of tubal and mesothelial cysts was quantified from H&E slides. Distinction of cyst types was based on published criteria. Where interpretations of cyst type differed, consensus opinion was established. Immunohistochemistry (PAX-8, Ber-EP4, Calretinin) was performed on slides from 19 cases with an emphasis on examining cysts of indefinite type on H&E.

Results: The majority of women had at least one inclusion cyst within ovarian tissue (80%, n=52). Tubal cysts were present in 78% of women (range 0-51 cysts per woman; median=3; average =5.4). Mesothelial cysts were present in 49% of women (range 0-10; median=0; average =1.1). Over 96% of both cyst types measured ≤ 1 mm. There was a weak positive correlation between numbers of tubal cysts and age ($r=0.30$), which was stronger than that for mesothelial cysts ($r=0.10$). Immunohistochemistry confirmed all H&E designated tubal type cysts as showing tubal immunophenotype. A single mesothelial cyst and all indefinite or potentially mixed cysts were designated as of tubal origin following immunohistochemistry.

Conclusions: The majority of inclusion cysts are of tubal type and are present at time of RRBSO in 78% of women in this series. Individual women considering ovary conserving strategies should be aware that there is a high probability of tubal tissue being present in conserved ovaries but that the volume is low compared to that removed by salpingectomy.

1178 Vaginal Melanoma: A Molecular Analysis of 32 Cases

Anais Malpica, Elizabeth D Euscher. MD Anderson Cancer Center, Houston, TX.

Background: Mucosal melanomas have site specific heterogeneity with respect to commonly described molecular alterations. Within the gynecologic tract, molecular alterations of vulvar melanoma are best described. Vaginal melanoma (VaM) is less well characterized, but differences in the molecular alterations between vulvar and vaginal sites have been reported particularly with respect to cKIT alterations. This study presents a series of 32 cases of VaM.

Design: PCR based methods were used to evaluate cases for BRAF, cKIT and NRAS mutations. Data regarding age, clinical presentation, tumor location and follow up was obtained from review of the medical record.

Results: Patients ranged from 32-85 years (median 60.5) with the following presentations: abnormal vaginal bleeding, 21; vaginal discharge, 6; palpable vaginal mass, 2; pelvic pressure/pain, 2; unknown, 1. The tumor epicenter was identified in 22 cases: upper 1/3, 6; middle 1/3, 1; distal vagina to include introitus, 15. In 7 cases, the vaginal location was not specified, and in 3 cases multiple tumor nodules were noted within the vagina. 32 cases were analyzed for cKIT mutations, 30 for BRAF mutations and 21 cases were analyzed for NRAS mutations with mutations detected as follows: BRAF, 2 (6.25%) cases; cKIT, 4 (12.5%) cases; NRAS, 2 (6.25%) cases. Findings for the 8 cases with molecular alteration are summarized in Table 1.

	Age	Location	BRAF	cKIT exon 11	cKIT exon 13	cKIT exon 17	NRAS	F/U
1	66	Multiple Vaginal (Vag) Nodules	V600E	neg	neg	neg	Not Done	No Evidence of Disease (NED)
2	56	Upper Vag	469 exon 11	neg	neg	neg	neg	NED
3	84	Distal Vag	neg	Val to Asp	neg	neg	Not Done	Dead of Disease (DOD)
4	61	Distal Vag	neg	neg	neg	Asp to Val	Not Done	DOD
5	61	Distal Vag	Not Done	Val to Ala	neg	neg	Not Done	DOD
6	75	Distal Vag	neg	Trp to Arg	neg	neg	neg	DOD
7	55	Upper Vag	neg	neg	neg	neg	Exon 2	Alive with Disease (AWD)
8	55	Upper Vag	neg	neg	neg	neg	Exon 2	AWD

Conclusions: VaM tends to be a disease of elderly women with genetic alterations detected in only a quarter of cases with cKIT mutations most frequently detected. In this series, most tumors had an epicenter in the distal vagina. NRAS and cKIT mutations

were geographically restricted. Cases with cKIT mutation were restricted to the distal vagina suggesting that distal VaM may be more similar to vulvar melanoma. Tumor location within the vagina may predict the likelihood of a specific molecular alteration.

1179 Evaluating Mixed Endometrial Carcinomas with a Panel of Immunohistochemical Markers

Cathleen Matrai, Edyta C Pirog, Lora H Ellenson. NYPH-Weill Cornell, NYC, NY.

Background: Historically, endometrial carcinomas have been classified primarily according to their histology. However, the use of immunohistochemistry (IHC) has become commonplace in diagnosing uterine carcinomas, particularly those cases in which there is morphologic ambiguity or tumor heterogeneity. In this study, our objective was to explore the association of tumors with mixed histology with a well-established panel of biomarkers to evaluate the consistency and utility of these stains, with particular focus on diagnostically challenging cases.

Design: 18 cases of mixed endometrial carcinoma were identified from our surgical pathology files. Slides were reviewed and histological features confirmed. Included cases were comprised of various combinations of classical serous (SC), endometrioid (EC), and clear cell (CC) morphologies. Each case was then subjected to a panel of IHC markers including p53, p16, ki67, ER, and PR. Intensity and extent of staining were evaluated on a 4-tiered scale (0, 1+, 2+, 3+) and a 5-tiered scale (0 = null, 1 = <1-24%, 2 = 25-49%, 3 = 50-74%, 4 = 75-100%) respectively.

Results: Staining did not follow a predictable pattern. In 5/14 cases with an EC component, strong p16 positivity was seen associated with endometrioid morphology. All 5 strongly positive cases contained a SC component that was also positive. In 2 of these cases, the endometrioid component showed strongly positive p53 staining and 3 showed a wild-type staining pattern. One SC component demonstrated wild-type staining while the remaining SC components demonstrated either strong p53 positivity (3+) or a null staining pattern (0, 1 case), consistent with p53 mutation. 5/9 CC cases were strongly p53 positive, all 5 of which were associated with a SC component. However, cases with only CC and EC components showed wild-type p53 staining. In 6/9 cases with CC morphology, there was weak to no staining with p16. However, 4 of these showed p53 staining patterns similar to their serous counterpart. 4/10 mixed SC/EC cases showed ER staining in the serous component, 3 of which showed strong, diffuse staining, with 2 showing stronger staining than that seen in the EC component.

Conclusions: Despite displaying diagnostic morphology, components of many mixed endometrial carcinomas may not exhibit expected IHC features. This may reflect an origin from a single clone with subsequent divergence, resulting in a tumor with both mixed histologic and genetic features. It is important to note that these tumors may not demonstrate the IHC prototype of their constituents with inherent diagnostic implications for limited endometrial samples.

1180 Detection of Serous Tubal Intraepithelial Carcinoma (STIC) in Incidentally Removed Fallopian Tubes from Low-Risk Women

Emily Meserve, Jelena Mirkovic, James Conner, Eric Yang, Brooke E Howitt, Christopher P Crum. Brigham & Women's Hospital, Boston, MA.

Background: Successful risk-reduction of pelvic high grade serous carcinoma (HGSC) by opportunistic salpingectomy is predicated on the hypothesis that an intraepithelial precursor to HGSC will be prevented. While the prevalence of STIC is 5.4% in asymptomatic women with germline *BRCA1/2* mutations (BRCA+) and ~50% in women with HGSC (Conner 2014), in low-risk women (LRW) without either HGSC or germline *BRCA1/2* mutations this prevalence is unclear. Our institution has been examining fallopian tubes by the SEE-FIM protocol for 10 years. This study ascertained an estimate of the STIC frequency in LRW.

Design: All salpingectomy reports at our institution from January 2006-December 2011 were carefully examined to identify women >50 years old with grossly identifiable distal fallopian tube that was entirely submitted for microscopic examination. Based on primary diagnosis, cases were assigned as 1) benign, 2) endometrioid neoplasia (of endometrium or ovary) including EIN, 3) HGSC of endometrium or pelvis, 4) other non-serous malignancies, and 5) prophylactic procedures in BRCA+ women. 10% of low-risk cases without a diagnosis of STIC and all sub-diagnostic tubal atypias were re-reviewed.

Results: Of 4051 cases identified, 2268 met inclusion criteria with 336 (14.8%) in group 1, 943 (41.7%) in group 2, 356 (15.7%) in group 3, 468 (20.6%) in group 4 and 165 (7.2%) in group 5. 81 STICs were identified, 76 (93.9%) associated with HGSC and 2 (2.5%) in prophylactic procedures. The remaining 3 STICs were associated with a grade 2 endometrioid endometrioid adenocarcinoma, an invasive low grade ovarian serous carcinoma, and an ovarian carcinosarcoma lacking serous morphology and associated with a clear cell adenofibroma. The proportion of LRW (groups 1, 2, 4) with STIC was 0.17% (3/1747); no STICs were identified in group 1.

Conclusions: Incidentally detected STIC in LRW who are >50 years old (0.17%) is 55- and 20-fold less common than in BRCA1+ (9.4%) and BRCA2+ (3.4%) women respectively, with an incidental STIC expected approximately once in 590 fully examined specimens. This risk ratio is similar to that seen for HGSC, where the risk is approximately 30 and 10-13 fold higher for BRCA1+ and BRCA2+ women relative to LRW. Although opportunistic salpingectomy with ovarian conservation may decrease risk, the low frequency of STIC underscores the need for widespread application of this surgical approach to reduce the HGSC death rate. The potential that differential risk of HGSC exists between LRW with endometrioid neoplasia and other LRW women bears further study.

1181 Clinicopathologic Comparison of Lynch Syndrome-Associated and "Lynch-Like" Endometrial Carcinomas Identified on Universal Screening Using Mismatch Repair Protein Immunohistochemistry

Anne M Mills, Emily A Sloan, Martha Thomas, Susan C Modesitt, Mark H Stoler, Kristen A Atkins, Christopher A Moskaluk. University of Virginia, Charlottesville, VA.

Background: Expanded testing for Lynch Syndrome (LS) is increasingly recommended for patients with endometrial carcinomas, and immunohistochemistry (IHC) for tumor loss of mismatch repair (MMR) protein expression is the most common primary screen. This has led to the recognition of MMR-IHC deficient cases without identifiable mutations on directed germline sequencing. The clinical implications of such "Lynch-like" (LL) cancers are unclear.

Design: The files of the UVA Pathology Department were retrospectively searched for all MMR-deficient endometrial carcinomas identified on universal screening. Cases were categorized as likely sporadic (MLH1/PMS2 loss, evidence of *MLH1* promoter hypermethylation) or putative LS (loss of MSH2/MSH6, MSH6, or PMS2). Putative LS cases were further subdivided into LS and LL groups based on the presence or absence of a confirmatory mutation by germline testing, and the clinicopathologic features of these groups were compared.

Results: 31% (66/210) of endometrial carcinomas had deficiencies in ≥ 1 MMR protein, including 26 putative LS cases, 15 of which had germline testing. Directed germline sequencing confirmed LS in 47% (7/15); the 8 remaining cases were classified as LL. High-grade and/or biphasic morphology was seen in 43% (3/7) of LS and 63% (5/8) of LL cases; the remaining cases from both groups showed low-grade, conventional endometrioid morphology. The majority (71%, 5/7) of LL cases were MSI-High. The majority of cases from both groups [LS: 86% (6/7); LL: 88% (7/8)] were low-stage (T1a/T1b). Endometrial carcinoma was the presenting malignancy in 86% (6/7) of LS patients and 88% (7/8) of LL patients. Family history was suggestive of LS in 29% (2/7) of LS patients and 13% (1/8) of LL patients. Screening algorithms based on age and cancer history would have failed to identify LS patients in 57% (4/7) of cases.

Conclusions: Although universal MMR-IHC identifies endometrial carcinoma patients with LS who would have been missed using targeted screening algorithms, it also identifies cancers with discordant IHC and germline results for which the somatic vs. germline origin of the MMR defect is unclear. Further study of this Lynch-Like group is required before drawing definitive conclusions about their familial cancer risk.

1182 Validation of a Novel RNA ISH Assay for HR-HPV E6/7 mRNA

Anne M Mills, Mark H Stoler. UVA, Charlottesville, VA.

Background: High-risk human papillomaviruses (HR-HPVs) are associated with a variety of in situ and invasive carcinomas, and it is well established that dysregulated expression of the HPV oncogenes E6&E7 is necessary for neoplastic transformation. In situ hybridization (ISH) for HPV DNA was historically used as a biomarker, but suffered from limited sensitivity and is no longer commercially available. PCR can be highly sensitive, but is unable to localize HR-HPV to cells of interest. Overexpression of p16 by immunohistochemistry can serve as a surrogate marker, but has imperfect specificity and presents interpretative challenges. Given these shortcomings, there has long been interest in the development of an ISH assay for HR-HPV mRNA to assess for transcriptionally active HR-HPV. We herein validate "HR-HPV RISH" (RNAScope, Advanced Cell Diagnostics), a novel assay which targets E6/E7 mRNA from the 18 most common HR-HPV types, on a variety of tissues using automated technology available in the clinical setting.

Design: 94 FFPE samples of in situ and invasive lesions expected to contain HR-HPV were collected from the archives of UVA Pathology, including 13 CIN I, 25 CIN III, 8 VIN III, 14 AIN III, 14 cervical squamous cell carcinomas (SCC), 18 p16-positive H&N SCC, and 2 anal SCC. Also included were 18 reactive and 10 normal cervix samples. HR-HPV RISH and LR-HPV RISH, a similar assay for E6/7 mRNA from the 6 most common low-risk HPV types, were performed on all samples. Two pathologists independently reviewed recut H&E slides and ISH slides. The pathologists were masked to H&E diagnosis at the time of ISH review and vice versa. All cases of disagreement were reviewed in tandem to obtain a consensus diagnosis.

Results: HR-HPV RISH was positive in 0% (0/10) negative cervix, 5.6% (1/18) reactive cervix, 92.3% (12/13) CIN I, 100% (25/25) CIN III, 100% (8/8) VIN III, and 100% (14/14) cervical SCC. The single positive reactive cervix case showed a "cut-in" lesion on the ISH slide. 1 anal SCC and 1 AIN were negative for HR-HPV RISH; both cases were strongly positive for LR-HPV RISH and these were the only LR-positive cases in the data set. 87.5% (14/16) of p16+ H&N SCC were HR-HPV RISH positive; the 2 negatives were laryngeal. Using blinded consensus H&E diagnosis as gold standard, HR-HPV RISH had a sensitivity of 94.6% (95% CI: 87.1-97.9%) and a specificity of 96.4% (95% CI: 79.1-99.8%) for the presence of a HR-HPV-related lesion. Interobserver agreement for HR-HPV RISH was "very good" at 95.1% (kappa: 0.880, 95% CI: 0.786-0.973).

Conclusions: HR-HPV RISH is a highly sensitive, specific, and easily interpretable assay for the presence of HR-HPV.

1183 Extra-Uterine Smooth Muscle Tumors of the Female Genital Tract: Clinicopathologic Study of 24 Cases

Laura Moench, Sucheta Srivastava, Teri A Longacre. Stanford Medicine, Stanford, CA.

Background: The concept of benign metastasizing leiomyoma is well recognized, but the presentation of extrauterine female genital tract smooth muscle tumors in other unusual sites is not as well documented and often poses significant diagnostic problems.

Design: The surgical pathology archives at a single institution were reviewed from 2005 to 2015 for diagnoses of extrauterine female genital tract smooth muscle tumors involving the pelvis, abdomen, lymph nodes or lung. Cases with a prior diagnosis of STUMP or leiomyosarcoma were excluded. Histologic features, including cytologic

atypia, cellularity, mitotic index, type of necrosis (coagulative, hyalinizing/ischemic, or uncertain), cell morphology (epithelioid vs. spindled vs. myxoid) and status of tumor margins or adhesion to adjacent organs were recorded. Medical records were reviewed for age, hormone use, tumor size, number and location, surgical procedure, therapy, and follow-up.

Results: 24 patients with extrauterine smooth muscle tumors were identified. Patient age ranged from 31 to 77 years (mean 51). Extrauterine sites of involvement included pelvic peritoneum (n=19), pelvic lymph node (n=1) and lung (n=2). Two had widespread pelvic and abdominal involvement (disseminated peritoneal leiomyomatosis). Ten were isolated tumor masses. All but 4 were associated with synchronous or metachronous (n=9) uterine leiomyomas. Of the 24 extrauterine smooth muscle tumors, 3 were epithelioid, 2 were atypical with bizarre nuclei, and 2 were diagnosed as smooth muscle tumors of uncertain malignant potential (STUMP) on the basis of epithelioid histology and increased mitotic index. Two were lipoleiomyomas and the remainder had leiomyoma histology. Two patients (8%) developed recurrent pelvic disease at 2 and 11 years, respectively. One of the recurrences was usual leiomyoma while the other was a STUMP based on increased mitotic index and increased cellularity. No patient succumbed to disease in the follow up period.

Conclusions: Female genital tract smooth muscle tumors that present in unusual sites are problematic with respect to diagnosis and clinical management. Our data suggest that while most of these tumors are associated with banal (leiomyoma) histology and a benign clinical course, a subset may exhibit atypical histology. In addition, the concept of benign metastasizing leiomyoma should not be limited to those cases with pulmonary involvement as 7 cases in this series developed pelvic and/or lymph node recurrences in absence of pulmonary disease.

1184 Perineural Invasion Is a Valuable Prognostic Factor in Advanced Stage and/or Lymph Node Positive Cervical Cancer

Bahar Muezzinoglu, Cigdem Vural, Busra Yaprak Bayrak, Izzet Yucesoy. Kocaeli University Medical School, Kocaeli, Turkey.

Background: Perineural invasion (PNI) is correlated with adverse survival in several malignancies, but its significance cervical cancer remains to be clearly defined.

Design: The objective of this study was to determine the association between PNI status and clinical outcomes in clinically localized surgically treated cervical cancers. We reviewed clinical records and pathology slides of 117 patients with cervical cancer treated with surgery at a single academic center. PNI was evaluated for presence, number of foci per slide, involved largest nerve size, and topographically (intratumoral vs extratumoral). Association with these parameters, clinicopathologic characteristics and survival were analyzed.

Results: The analysis demonstrated that PNI in cervical cancer was significantly correlated with parametrial invasion, tumor size, resection margin involvement, lymphovascular invasion, lymph node metastasis, and higher stage disease (p<0.005). Similarly PNI density, mean size of the nerve involved were also associated with advanced stage (p<0.005). In the multivariate analysis, PNI was not an independent prognostic factor for cervical cancer. However, in advanced stage cases and lymph node positive cases PNI is significantly associated with lower overall survival (42 vs 57 months and 35 vs 60 months, respectively, p<0.005).

Conclusions: Presence and extend of PNI and the size of the nerve involved are accompanied by high risk factors for recurrence. PNI has a significant prognostic impact on overall survival in patients with advanced stage and/or lymph node positive cervical cancer.

1185 Genomic Characterization of Gastric-Type Endocervical Adenocarcinomas

Rajmohan Murali, Maria De Filippo, Britta Weigelt, Kay J Park. Memorial Sloan Kettering Cancer Center, New York, NY.

Background: Gastric-type cervical adenocarcinomas (GCAs) are under-recognized, aggressive, chemorefractory neoplasms that are not associated with HPV. The pathogenesis of GCA is poorly understood, due to their rarity. We sought to characterize the mutational landscape of GCAs using a targeted capture next-generation sequencing assay.

Design: DNA extracted from tumor and matched normal formalin-fixed paraffin-embedded tissue from 10 GCAs was subjected to next-generation sequencing targeting all exons and selected introns of 341 actionable cancer genes (MSK-IMPACT). Somatic single nucleotide variants (SNVs) were identified using MuTect, and small insertions and deletions (indels) were detected using Strelka and VarScan 2. Copy number alterations (CNAs) were identified using VarScan 2. The repertoire of mutations and gene copy number alterations of GCAs was compared to that of common-type HPV-associated cervical carcinomas as reported by Ojesina *et al* (Nature 2014; 506:371-5).

Results: We obtained high-quality sequencing data for 6 matched tumor-normal GCA pairs, and for 2 tumors without matched normal tissues. The targeted sequencing analysis yielded a median depth of coverage of 347x (range 57-741x).

We identified a median of 1.5 somatic mutations (range 0-9) in the 6 cases where matched normal tissue was available. Three genes were recurrently targeted by mutations in these 6 GCAs, namely *TP53* (hotspot R282W, Q192*), *GNAS* (two R201H hotspot mutations) encoding a G protein frequently found to be somatically mutated in tumors of the biliary tract, pancreas, small intestine and pituitary, and in *SMAD4* (Q534*, R361S), a tumor suppressor gene frequently mutated in gastrointestinal cancers and a mediator of the TGF-beta signaling pathway.

Mutation analysis of the two GCAs without matched normal tissue revealed the presence of mutations in *TP53*, but also DNA repair-related genes, as well as a *CDKN2A* frameshift mutation.

In comparison with HPV-associated cervical carcinomas, we found GCAs to more frequently harbor *GNAS* and *SMAD4* mutations and *CDKN1B* (12p13.1) amplifications.

Conclusions: The results of our exploratory pilot study provide evidence to suggest that the repertoire of somatic mutations and gene copy number alterations in GCAs is distinct from that of HPV-associated cervical carcinomas, and identifies novel pathogenetic bases for this rare, aggressive disease.

1186 Genomic Analysis of Low-Grade Serous Ovarian Tumors Associated with High-Grade Serous Carcinoma or Undifferentiated Carcinoma

Rajmohan Murali, Raghu Chandramohan, Robert Soslow, Donavan Cheng, W Glenn McCluggage. Memorial Sloan Kettering Cancer Center, New York, NY; Illumina, San Francisco, CA; Belfast Health and Social Care Trust, Belfast, United Kingdom.

Background: Serous tumors form two distinct groups based on their morphology and major genetic alterations: serous borderline tumors (SBT) and low-grade serous carcinomas (LGSC), associated with RAS alterations; and high-grade serous carcinomas (HGSC)/undifferentiated carcinoma (UC), associated with *TP53* mutations. Generally, there is fidelity with respect to the 2 subtypes (SBT/LGSC vs HGSC/UC) during their course. Rarely, SBT/LGSC may progress to HGSC/UC. Using a next-generation sequencing approach, we sought to determine the genomic alterations underlying this rare transformation.

Design: We identified 5 patients who had low-grade serous tumors (SBT, LGSC) with synchronous or metachronous high-grade tumors (HGSC/UC).

DNA extracted from tumors and matched normal tissue was subjected to next-generation sequencing targeting all exons and selected introns of 341 actionable cancer genes. Sequencing reads were subjected to paired-sample variant-calling algorithms to identify different classes of somatic mutations: point mutations (MuTect), indels (SomaticIndelDetector), and copy number variants (custom pipeline).

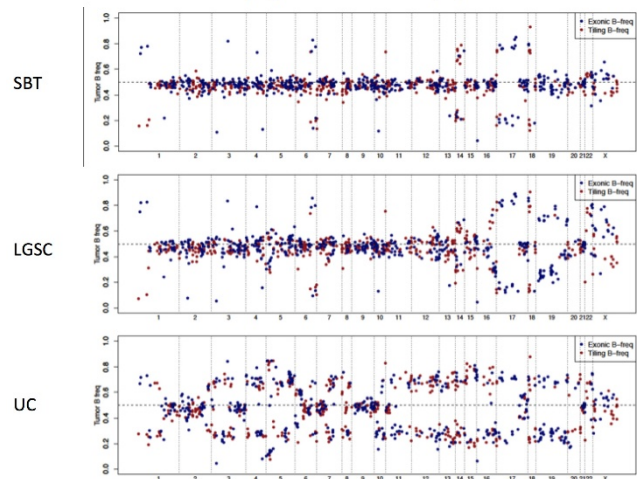
Results: Two or more tumor samples were obtained from 5 patients: 1 LGSC+HGSC, 2 SBT+LGSC+UC, 1 LGSC+HGSC and 1 SBT+HGSC.

The mutant allele frequencies (%) in the table show acquisition of new mutations and/or outgrowth of clones harboring specific mutations with progression to HGSC/UC.

Patient	Gene	SBT	LGSC	HGSC	UC
1	PIK3C2G		5	30	
2	MYCL1	<1	11	21	
	NRAS	36	4	38	
	SETD2	32	22	37	
	EGFR	28	39	39	
	CDKN2A	11	<1	0	
	CREBBP	0	1	31	
	EIF1AX	48	4	46	
EP300	0	<1	41		
3	TP53	0	12		43
	ATR	31	36		28
	MLL2	0	0		8
	NF1	56	68		46
	NOTCH2	10	<1		2
4	NRAS	32	19		9
	TGFBR2	0	9		<1
	RFWD2	0	5		<1
5	KRAS	31		37	
	TP53	2		53	
	MYCN	11		0	

The figure shows increasing loss-of-heterozygosity with progression from SBT to LGSC to UC in one patient.

DNA copy number, patient 3



Conclusions: The results show genotypic alterations underlying tumor progression. *RAS* mutations predominate in low-grade tumors, with emergence of *P53* (and other) mutations and increasing LOH as the tumors progress.

1187 Utility of Uroplakin-II Immunohistochemical Studies in Differentiating Primary Cutaneous Vulvar Paget Disease from Pagetoid Urothelial Intraepithelial Neoplasia

Kent J Newsom, Layla Alizadeh, Samer Z Al-Quran, Edward J Wilkinson. University of Florida, Gainesville, FL.

Background: Urothelial carcinoma of the bladder secondarily involving vulvar skin, known as pagetoid urothelial intraepithelial neoplasia (PUIN) is a rare vulvar tumor and can be challenging to distinguish from primary cutaneous vulvar Paget disease (PCVPD) on the basis of histology alone. Often, the use of immunohistochemistry can help differentiate the two lesions which have significantly different treatment, morbidity, and outcomes. Prior studies utilized Uroplakin-III (UP-III) and Cytokeratin 20 (CK20) to differentiate these lesions. A recent immunohistochemical stain (IHC) for urothelial carcinoma, Uroplakin-II (UP-II), has been introduced with a reported better sensitivity and specificity for urothelial carcinoma compared to UP-III, CK20 and GATA-3. This study examines whether UP-II is useful in differentiating PCVPD from PUIN when compared to UP-III, CK20 and GATA-3 in an initial battery of immunohistochemical studies.

Design: UP-II IHC was performed on archived, formalin-fixed, paraffin-embedded tissue blocks from 3 PUIN and 15 PCVPD cases using commercially available probes. Three pathologists blinded to the original diagnosis independently reviewed and interpreted the lesional cell staining using a scoring method (0-3+): 0 (negative), 1+ (faint staining), 2+ (moderate staining), 3+ (strong staining). Previously performed UP-III, CK20 and GATA-3 IHC were also reviewed when available.

Results: All PUIN cases (3/3) were immunoreactive for UP-II and showed intense (3+) or focal moderate (2+) tumor cell positivity. All PCVPD cases were UP-II IHC negative (0/15). Review of UP-III IHC on 3 PUIN cases demonstrated no immunoreactivity in 1 case, and focal, faint to moderate positivity within lesional cells in 2 cases. CK20 demonstrated strong positive immunoreactivity in 1 PUIN case, focal moderate positivity in a second case, and no immunoreactivity in the third case. Additionally, 1 of 15 PCVPD cases demonstrated strong lesional immunoreactivity for CK20 in the setting of no colorectal carcinoma. GATA-3 demonstrated nonspecific, strong positive reactivity in both tumor cells, normal epidermis, and adnexal structures in all cases.

Conclusions: Positive immunoreactivity for UP-II IHC within the lesional vulvar Paget disease cells is a more reliable marker for PUIN diagnosis than CK20, GATA-3, and UP-III. UP-II demonstrates utility as an initial screening antibody, as part of an IHC panel in the work-up of vulvar Paget disease, and in differentiating between PCVPD and PUIN.

1188 PELP1 Expression in Endometrial Carcinomas Is Associated with FIGO Grade and Histological Subtype

Shuang Niu, Yan Peng. University of Texas Southwestern Medical Center, Dallas, TX.

Background: PELP1 is a novel co-regulator of nuclear hormone receptors. Previous studies revealed that PELP1 plays an essential role in the proliferation of cancerous endometrial cells. However, the association of the PELP1 protein expression with FIGO grade and histological subtype in endometrial carcinomas has not been well characterized.

Design: We investigated PELP1 immunoreactivity in 24 endometrial cancer cases (9 FIGO grade 1 endometrioid carcinoma, 8 FIGO grade 3, and 7 high grade serous carcinoma). Whole tissue sections of the 24 cases were immunolabeled for PELP1 (Bethyl Laboratories, 1:100 dilution, Montgomery, TX). The slides were scored based on both extent and intensity of nuclear staining. Score of extent: 0 (negative), 1 (1-30%), 2 (31-60%), 3 (61-90%) or 4 (91-100%); score of intensity: 0 (negative), 1 (weak), 2 (intermediate) or 3 (strong). Final PELP1 score=extent score+intensity score. The slides were reviewed and scored by two pathologists.

Results: PELP1 expressed in both epithelial cells and stroma. Paried/adjacent normal endometrial glands were used as internal positive controls for each case. PELP1 expression in adjacent normal glands was higher than that in tumors in the FIGO grade 3 endometrioid carcinoma group (6.56 ± 0.68 vs. 4.38 ± 0.69 , $p < 0.01$, paired t test). There was no significant difference in PELP1 expression between tumors and normal glands in serous carcinomas and FIGO grade 1 tumors. Tumor cells in all of the 24 cases were positive for PELP1 (100%). However, degree of the intratumoral PELP1 expression was different among the 3 groups. PELP1 in serous carcinomas and FIGO grade 1 tumors was significantly higher than that in FIGO grade 3 tumors (6.9 ± 0.01 vs. 4.38 ± 0.65 , $p < 0.01$ and 6.67 ± 0.17 vs. 4.38 ± 0.65 , $p < 0.01$, respectively; unpaired t test, two tailed). There was no significant difference in PELP1 expression between serous carcinomas and FIGO grade 1 tumors (6.9 ± 0.01 vs. 6.67 ± 0.17 , $p > 0.05$).

Conclusions: Our study demonstrated significantly decreased PELP1 protein expression in FIGO grade 3 endometrioid carcinoma compared to FIGO grade 1 endometrioid carcinoma and serous carcinoma. The results indicate that expression of PELP1 in endometrial carcinomas is associated with FIGO grade and histological subtype. These findings suggest PELP1 may have potential prognostic value for endometrial endometrioid carcinoma and provide further support for the distinct molecular pathways of poorly differentiated endometrioid carcinoma and high grade serous carcinoma.

1189 FOXL2 Mutation Status in Ovarian Granulosa-Theca Cell Tumors

Amber Nolan, Charles Zaloudek, Joseph Rabban, Nancy M Joseph, Ankur R Sangoi, Karuna Garg. University of California San Francisco, San Francisco, CA; El Camino Hospital, Mountain View, CA.

Background: Adult granulosa cell tumor (AGCT) of the ovary is considered a tumor of low malignant potential capable of recurrence and metastasis while fibroma is benign; therefore distinction between the two entities is clinically important. Some fibromas can have minor sex cord elements (SCE), arbitrarily defined as less than 10% of tumor volume. Fibromas with SCE >10% are considered "granulosa cell tumors in a prominent fibrothecomatous background", also referred to as "granulosa-theca cell tumor" (GTCT).

GTCT is a poorly defined entity that can be challenging to distinguish both from spindled AGCT and cellular fibroma. In limited studies, these tumors appear to have excellent prognosis. AGCTs are known to almost universally harbor a FOXL2 mutation, while fibromas do not. The FOXL2 mutation status has not been evaluated in GTCT.

Design: Twelve granulosa theca cell tumors were identified. DNA was extracted and the 5' portion of exon 1 of the FOXL2 gene was amplified using specific PCR primers.

Results: Patient age ranged from 32 to 70 years. Most patients presented at FIGO stage IA (1 at stage IC) and all had no evidence of disease at last follow up (1-54 months). Six of the 12 (50%) cases demonstrated mutations in FOXL2 (p.C134W). All cases that showed $\leq 20\%$ of granulosa cells were negative for FOXL2 mutation while FOXL2 mutation was identified in most cases that showed $\geq 40\%$ granulosa cells.

Case	Cellularity (% granulosa cells)	FOXL2 mutation status
1	20%	Wild-type
2	20%	Wild-type
3	20%	Wild-type
4	30%	Wild-type
5	30%	p.C134W
6	40%	Wild-type
7	40%	p.C134W
8	40%	p.C134W
9	40%	p.C134W
10	40%	p.C134W
11	40%	p.C134W
12	50%	Wild-type

Conclusions: In our study, half of the GTCTs demonstrated FOXL2 mutations, while the other half were wild-type. None of the tumors with low volume of granulosa cells ($\leq 20\%$) showed FOXL2 mutations. Future studies of larger size and longer follow up should test whether the 10% cutoff for SCE in fibrothecoma should be moved to $< 30\%$. Cases with 40% or more SCE are most likely to harbor FOXL2 mutations, raising the question of whether these are more appropriately classified and treated as AGCT. From a practical standpoint, these results raise the question as whether all morphologic diagnoses of granulosa theca cell tumor should be evaluated by FOXL2 mutation testing since a positive finding may result in a more definitive classification as AGCT.

1190 Biomarker Selection in Early Ovarian Cancer

John J O'Leary, Sara O'Kane, Sharon O'Toole, John K O'Brien, Stephen R Pennington, Dolores J Cahill. Trinity College Dublin, Dublin, Ireland; University College Dublin, Dublin, Ireland.

Background: Due to a lack of specific disease symptoms, only 20% of patients with ovarian cancer (OC) are diagnosed at Stage 1, when therapeutic intervention would be most effective. This highlights the need to identify biomarkers for the diagnosis of early stage OC. Autoantibodies to cancer antigens can be detected up to 5 years before a tumour can be identified by other means and are therefore extremely attractive analytes for inclusion as an early stage OC test. However, selection of autoantibodies to include as disease specific markers is hindered by inadequate understanding of the natural autoantibody (NAA) repertoire of healthy individuals and inappropriate choice of control cohorts in autoantibody biomarker discovery studies. Profiling the NAA repertoire of healthy people will identify antigens that can be "subtracted" from a biomarker panel for detection of early OC.

Design: Study approval was obtained from SJH/AMNCH research ethics committee. Using protein arrays from the Human Expression Library (hEx1) brain library (ImaGenes, Germany), 22 early and 20 late OC serum samples, and 15 benign ovarian disease samples were profiled. These profiles were compared to 436 other samples (132 healthy, 95 cancer, 69 autoimmune, 140 other disease).

Results: Autoantibodies detected in $\geq 30\%$ of cohort samples were considered to be part of the autoantibody repertoire. Approximately 250 proteins have been identified as being associated with initiating an autoantibody response in early OC (detected in early OC samples and not associated with late OC samples, healthy/control samples or with benign ovarian disease). The frequency of autoantibodies to these proteins have been compared with all samples screened to enable identify antigens that can be "subtracted" from a biomarker panel for detection of early OC.

Conclusions: Autoantibody profiling of serum samples from OC patients and controls has supported the identification of a large number of autoantibodies which may be involved in disease formation and/or progression. The selection of autoantibodies for further biomarker validation has been supported by identification of the NAA profile and ensuring the NAA proteins are subtracted from any disease associated biomarker panel.

1191 HE4 Has a Role in Treatment Planning in Endometrial Cancer

Sharon O'Toole, Ritzee Shireen, Seamus McDonald, Lucy Norris, Anthony Cooney, Feras AbuSaadeh, Waseem Kamran, Cliona Murphy, Nadine Farah, Tom D'Arcy, Noreen Gleeson, John J O'Leary. Trinity College Dublin, Dublin, Ireland; St. James's Hospital, Dublin, Ireland; Coombe Women's and Infants University Hospital, Dublin, Ireland.

Background: Human epididymis protein 4 (HE4) is a secreted protein that is overexpressed in some cancers. HE4 is emerging as a useful biomarker in diagnosis and management of endometrial cancers. The aim of this study was to evaluate the role of serum HE4 in the treatment planning for women diagnosed with endometrial cancer.

Design: Patients undergoing surgery for endometrial disease were recruited into this study and had pre-operative serum samples taken, n=210. Demographic, clinical, radiological and laboratory data were reviewed. HE4 and CA125 serum levels were analysed using the Fujirebio Diagnostic ELISA Kits and results correlated with clinicopathological details. Standard cut-off points of 70 pmol/L for HE4 and 35 U/ml for CA125 were used.

Results: HE4 showed a sensitivity of 62% and specificity of 98% for detection of endometrial cancer. CA125 had a very low sensitivity of 15% for endometrial cancer diagnosis. HE4 was significantly higher in more advanced poorly differentiated disease. HE4 displayed a sensitivity of 76% and 78%, respectively for predicting outer half myometrial invasion and lymphovascular space invasion.

Conclusions: HE4 has a role in endometrial cancer diagnosis and prognosis and may have a role in determining patients that require lymphadenectomy. For women diagnosed with endometrial cancer, HE4 has the potential to stratify them into treatment regimens where the most appropriate treatment can be delivered resulting in improved quality of life and outcome for endometrial cancer patients.

1192 HPV Vaccination Status in Patients with High Grade Cervical Precancerous Lesions

Fredrick D Oakley, Manideepthi Pemmaraju, Marie R Griffin, Mohamed M Desouki. Vanderbilt University, Nashville, TN.

Background: Two HPV vaccines, Gardasil and Cervarix, targeting common high risk types were approved in the United States in 2006 and 2009, respectively. High grade cervical intraepithelial neoplasia (CIN2 & CIN3) and adenocarcinoma *in situ* (AIS) are reportable diseases to Tennessee (TN) Cancer Registry. The purpose of this study is to provide baseline data on rates of CIN2, CIN3 and AIS and vaccination status of patients diagnosed with these lesions.

Design: Women with CIN2+ (CIN2, CIN3 and AIS) living in Davidson County, TN were identified in this multicenter collaborative study. From 2008 through 2013 data including diagnosis, race/ethnicity, age and HPV vaccination status were collected on patients aged 18-39 years. Women with invasive cervical carcinoma were excluded. Vaccine eligible women are those ≤ 26 years on 6/2006 (date Gardasil was licensed).

Results: A total of 1,893 women with CIN2+ were identified, of whom 1403 (74%) were HPV vaccine eligible. A total of 253/1403 (18%) received at least one dose of an HPV vaccine and 150/1893 (7.9%) received at least one dose prior to their CIN2+ diagnosis. The overall CIN2+ rate decreased from 1062 to 854 per 100,000 women annually between 2008 and 2013. For women aged 25-29 and 30-39, there were no clear trends in the rate of CIN2+ lesions and averaged 230 and 378 per 100,000, respectively. In women aged 18-20 and 21-24 years, the incidence of CIN2+ lesions trended downward from 153 to 51 and from 336 to 188 per 100,000 women, respectively. In all age groups, the rates of CIN2 were higher than CIN3. AIS was identified in 2 patients age <25 years (0.63/100,000) and 26 patients ≥ 25 years (5.37/100,000). Vaccine types were Gardasil (230) Cervarix (2), and unknown type (27). Three, two, and one vaccine doses were documented in 63.8%, 19.7%, and 16.6%, respectively. First vaccination was at age 16-20 years in 45 (20.5%), 21-24 years in 114 (21%), and 25-29 years in 58 (15.2%). Vaccination rates in Whites, African American and Hispanic population were 20.2%, 19.3% and 9.5% for those who were vaccine eligible, respectively.

Conclusions: The frequency of CIN2+ in Davidson County among women 18-39 years is approximately 1 per 1000 per year and AIS lesions are uncommon. The frequency of CIN2+ is trending down in woman 18-24 years, likely related to changes in screening. Gardasil was almost exclusively used, but vaccination rates are low, and provided too late for some women. Vaccination rates were lower in Hispanics than in White and African American populations.

1193 Distribution of Cervical Lesions Associated with HPV in the Democratic Republic of São Tomé and Príncipe

Rita SS Oliveira, Ana C Braga, Lucilia Goncalves, Gabriela Gasparinho, Marco Ferreira, Luis V Pinto, Ana Matos, Elizabeth Carvalho, Manuel Cardoso, Paula Guerra, Sara B Turpin, Ruben R Roque, Gilberto Matias, Armandina Silva, Raquel Almeida, Henrique Nabais, Rui Nobre, Hugo Prazeres. Hospital Prof. Doutor Fernando Fonseca, E.P.E., Amadora, Portugal; Pathology Laboratory Roriz, Lisboa, Portugal; Group for Cancer Intervention in Low Resource Settings: STP Cervical Cancer Mission, Lisboa, Portugal; Marques Valle Flor Institute ONG, Lisboa, Portugal; Champalimaud Foundation, Lisboa, Portugal; Armed Forces Hospital, Porto, Portugal; Ministry of Health, São Tomé, Sao Tome and Principe; Coimbra University, Coimbra, Portugal; Portuguese Oncology Institute, Coimbra, Portugal.

Background: Cervical cancer is the most common cancer in women of Eastern/Middle Africa, causing almost nine of ten (87%) cervical cancer deaths in underdeveloped regions. WHO Global Action Plan for the Prevention and Control of Noncommunicable Diseases 2013-2030 (resolution WHA66.10) aims to reduce premature mortality from noncommunicable diseases with a 25% relative reduction in overall cancer mortality. In the Democratic Republic of São Tomé and Príncipe there is no database available for the prevalence of HPV associated cervical lesions.

Design: Cross-sectional descriptive study was carried out (December 2011 to March 2014) using liquid based (Turbitec®) cytology. The cytological findings were classified according to the 2001 Bethesda System. Colposcopy with or without biopsy was performed whenever atypical cells (ASC-US or ASC-H) or a lesion were identified. Genotyping of the HPV profile was performed.

Results: The cytological survey included 5038 women (25-54 years old), which represents 17,53% of the target population (5038/28651) according to the Census 2012. The results of the cervical cytology were: NILM (4469; 89%) and SIL/carcinoma (569; 11%) - LSIL (194; 34,1%), ASC-H (39; 6,8%), HSIL (83; 14,6%), AGC (4; 0,7%) and carcinoma (1; 0,2%). From the 124 cervical biopsies performed, the results were correlated as follow:

Cytological diagnosis	Histological diagnosis				
	No result	No dysplasia	LSIL	HSIL	Carcinoma
LSIL (27)	-	9 (33%)	14 (52%)	3 (11%)	1 (4%)
ASC-H (29)	3 (10%)	1 (4%)	14 (48%)	10 (34%)	1 (4%)
HSIL (68)	3 (4%)	5 (7%)	9 (13%)	47 (69%)	4 (7%)

10% of the collected samples were sequenced for HPV DNA, revealing 34 distinct types of HPV with 12 HPV-HR (HPV 16, 18, 31, 33, 35, 39, 45, 51, 52, 56, 58 and 59).

Conclusions: This is the first attempt to document the epidemiological profile of cervical lesions in São Tomé and Príncipe. Our results confirms a public health problem that need further investigation, particularly regarding HPV genotyping profile, in order to define future actions.

1194 Histological Characteristics of HPV-Associated and -Independent Squamous Cell Carcinomas of the Vulva: A Study of 791 Cases

Jaume Ordi, Natalia Rakislova, Omar OC Clavero, Maria Alejo, Belen Lloveras, Laia Alemay, Xavier Bosch, Silvia de Sanjose. Hospital Clinic - Barcelona University, Barcelona, Spain; ISGlobal, Barcelona, Spain; Catalan Institute of Oncology, IDIBELL, L'Hospitalet del Llobregat, Barcelona, Spain.

Background: There is clear evidence indicating that there are two different etiopathogenic pathways for the development of vulvar squamous cell carcinomas (VSCC): one associated with infection by human papillomavirus (HPV), and another independent of HPV. We aimed to determine whether there are any differential characteristics between the two types of VSCCs in a large series of tumors.

Design: We included 791 VSCCs from 39 countries during the period 1980-2011. A single paraffin block was available for review of each case. The analysis in all the tumors included histological review, HPV analysis HPV/DNA detection using SPF10PCR/DEIA/LiPA25 system and p16 immunohistochemistry. The histological evaluation was done blindly to the HPV results and included characteristics of the tumor as well as changes in the adjacent skin.

Results: 184 tumors (23.3%) were positive for HPV. There was a strong association between histological type and the presence of HPV (p<0.001). HPV-positive tumors were more frequently basaloid (33.2%), warty (9.2%) or non-keratinizing (19.0%). However, 38.0 were of the keratinizing type. HPV-negative tumors were more frequently keratinizing (78.1%), but were occasionally basaloid, warty or non-keratinizing (6.1, 2.8 and 10.7%, respectively). HPV positive VIN (vulvar intraepithelial neoplasia) were frequently of basaloid/warty type (88.0%). However, 12.0 of them showed differentiated features. Contrarily, VIN lesions in HPV-negative tumors were frequently of the differentiated type (78.9%), but 21.1 of the VIN lesions showed basaloid/warty features. Although several histological characteristics were more frequently associated with HPV-negative VSCC (individual keratinization, highly differentiated cells, invasive front with small nests, presence of lichen sclerosis or lichen simple chronicus in the adjacent skin; p<0.001), all of them were also present in a number of HPV-positive tumors and none of them allowed differentiation between HPV-positive and -negative VSCC. p16 was positive in 85.9% of the HPV-positive and in 4.3% of the HPV-negative tumors (p<0.0001).

Conclusions: Histological criteria do not allow differentiation between HPV-positive and -negative VSCC. p16 is a good surrogate marker of HPV etiology in the absence of HPV DNA detection.

1195 Intravenous Leiomyomatosis (IVL), from Molecular Genetics to Clinical Biomarkers: A Study of 26 Cases

Zehra Ordu, Anna G McDonald, Michele De Nictolis, Eugenia Garcia-Fernandez, David Hardison, Jaime Prat, Esther Oliva. Massachusetts General Hospital, Boston, MA; San Salvatore Hospital, Pesaro, Italy; Hospital Universitario La Paz, Madrid, Spain; Wake Forest Baptist Medical Center, Winston-Salem, NC; Hospital de la Sta Creu i Sant Pau, Barcelona, Spain.

Background: IVL is a benign smooth muscle proliferation characterized by intravascular growth. Despite the well delineated molecular genetic alterations of uterine leiomyomas and leiomyosarcomas, there is only a single comprehensive molecular genetic study of IVL showing several recurrent copy number aberrations including 22q12-q13 (66%) and 10q22 (33%) alterations (%11 with both abnormalities). Studying IVL expression patterns in correlation with their genetic background may potentially provide insight into their biology.

Design: 26 IVL were evaluated for 5 immunohistochemical markers: p16, Carbonic Anhydrase IX, and INI1 for the "potential" 22q deletion group and CyclinD1 (due to close proximity to *FAM22A* locus also altered in endometrial stromal sarcoma which correlates with CyclinD1 expression) for the "potential" 10q22 duplication group. In addition, FH was also analyzed as one of the reported cases had a 1q42-q44 deletion. Staining was evaluated in tumor and myometrium with a semiquantitative method: 0 (no staining), 1 (minimal, <5%), 2 (focal, 5-24%), 3 (multifocal, 25-50%) and 4 (diffuse, >50%). Data was analyzed by student t-test.

Results: All 26 IVL showed differential expression of either CyclinD1 or p16 (mean scores 1.46 and 2.73) in comparison to myometrium (mean scores 0.08 and 0.15) ($p < 0.001$). Multifocal/diffuse p16 and CyclinD1 positivity was detected in 16 (61%) and 6 (23%) IVL, 5 (19%) coexpressed both. Overall, 13 out of 15 usual, 4 with hydropic change, 3 out of 4 cellular, and 1 with fat IVLs had more extensive p16 than CyclinD1 positivity. Two epithelioid IVL had multifocal/diffuse CyclinD1 positivity but only absent/focal p16 positivity. IN1 showed nuclear staining in all IVL and nuclear and cytoplasmic staining in myometrium. FH was retained and Carbonic Anhydrase IX was negative in all cases.

Conclusions: Our immunohistochemical findings are in parallel to previously reported molecular profile of IVL suggesting pathways that may be relevant to 22q deletion and 10q duplication with p16 and Cyclin D1 as their respective biomarkers. Of interest, IVL with epithelioid morphology appears to show a phenotype vastly driven by cyclinD1 expression with potential biological implications.

1196 Genome-Wide Copy Number Analysis of Uterine Tumors Resembling Ovarian Sex Cord Tumors (UTROSCT)

Joyce J Ou, Umadevi Tantravahi, John R Pepperell, Danielle B Chau, Michele M Lomme, C James Sung, W Dwayne Lawrence. Women & Infants Hospital, Providence, RI; Alpert Medical School of Brown University, Providence, RI.

Background: Uterine tumors resembling ovarian sex cord tumors (UTROSCT) are rare uterine mesenchymal neoplasms characterized by a predominance of sex cord-like elements. In addition to diverse architectural patterns, UTROSCT can also variably express epithelial, smooth muscle, and sex cord markers. To date, these tumors lack the t(7;17) translocation seen in several types of endometrial stromal tumors (EST). The molecular cytogenetics of this polyphenotypic entity have not been well-characterized. In this study, we utilized a molecular inversion probe (MIP) array to examine genome-wide copy number changes in a series of UTROSCT.

Design: Five cases of UTROSCT were identified from hospital archives. Genomic DNA was extracted from formalin-fixed, paraffin-embedded sections. OncoScan FFPE Assay (Affymetrix) was used to assess genome-wide copy number variations (CNVs) and 74 actionable mutations in 9 genes. Data analysis and visualization was performed in Nexus Express for OncoScan (BioDiscovery) and Chromosome Analysis Suite (ChAS; Affymetrix).

Results: The most prominent CNV in UTROSCT was a recurrent gain of chromosome 1q, seen in 3 of 5 cases. In all three cases, the gain (~104 Mb) involved most of the q arm extending from q21.1-q44. In one case, the duplication resulted in 4 copies of the q arm. The clinicopathologic features of these three cases included age range from 55 to 68 years, tumor size from 6 to 17 cm, and disease-free interval from 2 months to 4 years. Morphologically, these three tumors exhibited focally increased mitotic activity and cytologic atypia compared to the other two cases without 1q gains. The second most frequent CNV involved chromosome 11q. Two of the three cases with 1q gains also showed a 35 Mb homozygous deletion in 11q and an 83.7 Mb heterozygous deletion in 11q, respectively. Additional CNVs found in UTROSCT included gains in 7q and 8q and losses in 6q and 17p. Somatic mutation analysis was negative in all cases.

Conclusions: CNVs have been identified in a series of UTROSCT, a rare uterine neoplasm that is considered distinct from other endometrial stromal tumors. The majority of UTROSCT cases displayed a recurrent gain in chromosome 1q, with no cases exhibiting the EST-associated t(7;17). This study demonstrates the feasibility of genomic profiling of rare archived mesenchymal uterine lesions by MIP array.

1197 Mismatch Repair (MMR) Protein Deficiency in Early Stage Ovarian Carcinomas. A Study by Spanish Ovarian Cancer Research Group (GEICO)

Jose Palacios, Ana Gutierrez-Pecharroman, Eva Cristobal, Jose Antonio Lopez-Guerrero, Ignacio Romero, David Hardisson, Francisco Vera, Begona Vieites, Angel Garcia, Javier Ibarra, Sofía Hakin, Rosa Guarach, Encarna Andrada, Santiago Montes, Francisco Pastor, Maria C Gomez, Maria C Gomez, Andres Poveda. Hospital Universitario Ramon y Cajal, Madrid, Spain; Instituto Valenciano de Oncología, Valencia, Spain; Spanish Ovarian Cancer Research Group, Barcelona, Spain.

Background: While there has been extensive investigation of MMR deficiency in colorectal and endometrial cancer, MMR deficiency in ovarian cancer is relatively under-investigated. In this study, we analyse the frequency of MMR protein deficiency in early stage ovarian cancer and its relationship with morphological and immunohistochemical features.

Design: A total of 287 stage I and II of ovarian carcinomas were collected retrospectively by the Spanish Group for Ovarian Cancer Research (GEICO) from the archives of 24 Spanish hospitals. Tumours were classified into 6 different histological types according to morphological and immunohistochemical features (WT1, p53, p16, oestrogen receptor, progesterone receptor, ARID1A, Napsin-A and HIN1B). In addition, the expression of MLH-1, PMS-2, MSH-2, MSH-6, β -catenin and HER2 protein were analysed on tissue microarrays for all the samples.

Results: After centralized histological and immunohistochemical evaluation, the tumours were classified as high grade serous carcinoma (98 cases), low grade serous carcinoma (23 cases), high grade endometrial carcinoma (25 cases), low-intermediate grade endometrial carcinoma (66 cases), mucinous carcinoma (26 cases) and clear cell carcinoma (49 cases).

MMR protein deficiency (MMR-pd) was detected in a total of 17 cases (6%), MLH1/PMS2 loss was observed in 7 cases (2.4%), MSH2/MSH6 loss in 7 cases (2.4%), PMS2 loss in 7 cases (2.4%) and MSH6 loss in 10 cases (3.5%). MMR-pd was statistically associated with the histological type, since it was detected in 15.2%, 12%, 4.1%, 3.8%, 1% and 0% of low/intermediate grade endometrial carcinoma, high grade endometrial carcinoma, clear cell carcinoma, mucinous carcinoma, high grade serous carcinoma and

low grade serous carcinoma respectively ($P=0.003$). MMR-pd was also more frequently observed in tumours with a "wild type" p53 expression pattern ($p=0.012$) and reduced or absent ARID1A expression ($P < 0.001$).

Conclusions: MMR deficiency is infrequent among early stage ovarian carcinomas. Most MMR deficient tumours are endometrioid carcinomas and the pattern of MMR protein loss suggests a higher frequency of hereditary (associated to Lynch syndrome) than sporadic cases.

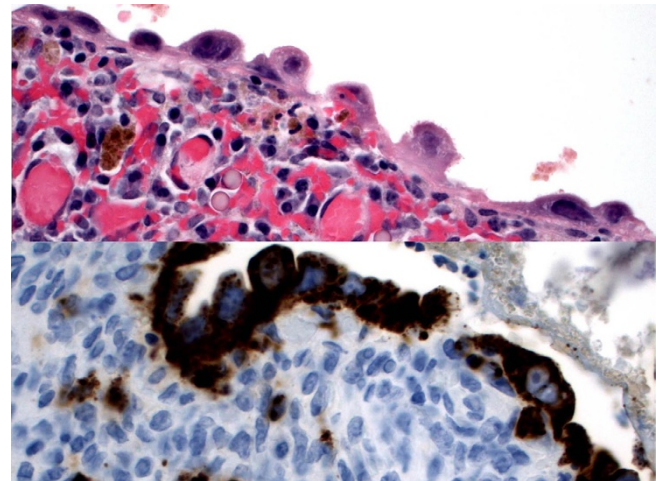
1198 Investigation of Napsin-A in Atypical Versus Usual Endometriosis

Cherie Paquette, M Ruhul Qudus, C James Sung, Joyce J Ou, W Dwayne Lawrence. Women and Infants Hospital, Providence, RI; Brown University School of Medicine, Providence, RI.

Background: Atypical endometriosis (with cytologic atypia including crowding, hyperchromasia, and nuclear enlargement) is associated with risk of clear cell (CCC) or endometrioid carcinoma. Studies have demonstrated ARID1A and PIK3CA mutations, loss of heterozygosity, and other molecular alterations in endometriosis supporting a pre-neoplastic categorization, with few studies focusing on atypical endometriosis. With the recent demonstration of Napsin-A immunohistochemical (IHC) stain positivity in the majority of CCC, this raises the question of whether atypical or usual endometriosis may also be positive for Napsin-A. Endometriosis, to our knowledge, has so far not yet been studied using Napsin-A. Napsin-A positivity in usual or atypical endometriosis would strengthen the etiologic link with CCC.

Design: The records of one institution were searched from 2007-2015 for all atypical endometriosis and cases of endometriosis adjacent to CCC. Additionally, 10 cases of usual endometriosis were selected. Napsin-A IHC was performed on a representative slide from each case and scored positive if the endometriotic glands had cytoplasmic stain of at least moderate intensity.

Results: 21 cases of atypical endometriosis (range 25-61, mean 41.3 years), 8 of endometriosis adjacent to CCC (range 52-78, mean 62.3 years), and 10 of usual endometriosis (range 24-62, mean 41.2 years) were included. The majority (87.5%) of CCC were positive for Napsin-A. The positivity for Napsin-A in endometriosis is as follows: 52.3% for atypical endometriosis, 37.5% for endometriosis adjacent to CCC, and 10% for usual endometriosis. Figure 1 below shows atypical endometriosis on H&E and Napsin-A stain.



Conclusions: Here we demonstrate that Napsin-A is positive in 52.3% of atypical endometriosis cases, while usual endometriosis is rarely Napsin-A positive. This supports the hypothesis that atypical endometriosis is a precursor lesion of CCC. Further, these results suggest caution in using Napsin-A to confirm a diagnosis of CCC in small biopsies without overt evidence of invasion: a focus of atypical endometriosis may have cytologic atypia and Napsin-A positivity. Further studies are needed to elucidate molecular changes leading to Napsin-A expression in atypical endometriosis.

1199 Current Practices in the Processing, Diagnosis and Reporting of Endometrial Carcinoma. Results of a Web Based Survey by the International Society of Gynecological Pathologists (ISGyP)

Vinita Parkash, Anais Malpica, Xavier Matias-Guiu, Esther Oliva, W Glenn McCluggage. Yale University School of Medicine, Bridgeport Hospital, New Haven, CT; The University of Texas MD Anderson Cancer Center, Houston, TX; Hospital Universitari Arnau de Vilanova, University of Lleida, IRBLleida, Lleida, Spain; Massachusetts General Hospital, Boston, MA; Belfast Health and Social Care Trust, Belfast, Ireland.

Background: This survey based study was undertaken to inform on variability in processing, diagnosis and reporting of endometrial carcinoma among the membership of the ISGyP.

Design: A 112 question survey was circulated among the membership of the ISGyP using a web-based online tool (www.surveymonkey.com) during July 2015, with three reminders sent.

Results: 47% (242/514) of members responded to the survey. 87% were from North America, Europe, or Australia. Depth of myoinvasion (93%), assessment of tumor type (88%), and tumor grading (75%) were consistently evaluated at frozen section; other parameters were not (cervical, adnexal and vascular invasion). At grossing, tumor size and site were recorded consistently; sectioning protocols were variable with respect to

sectioning of tumor, normal endometrium, uninvolved adnexa and omentum. Lymph nodes were entirely submitted by 93%. Immunohistochemistry use was inconsistent for tumor subtyping (22-45% depending on subtype). FIGO was the most commonly used grading system (97%); 17% indicated reporting a mixture of grades for mixed patterns. 86% reported recording inner/outer half myoinvasion but percentage myoinvasion was reported by 52% and distance to serosa by 59%. Patterns of myoinvasion (51%) and depth of cervical tumor invasion (60%) were variably reported. Tumor involvement of deep adenomyosis (10%), isolated tumor cells in lymph nodes (65%), tumor cells in tubal lumen (5%) and keratin granulomas (2%) were sometimes used to upstage tumors. Use of hormone receptor staining, mismatch repair protein analysis, ploidy and molecular studies were extremely variable. 9% of respondents did not report stage on the pathology report; the remainder used FIGO and/or AJCC or UICC staging systems. WHO 2003 (16%), WHO 2014 (71%) and EIN (13%) were used for reporting precursor lesions of endometrioid adenocarcinoma.

Conclusions: This survey demonstrates areas of significant variability in the processing, diagnosis and reporting of endometrial carcinoma. A consensus conference is planned to attempt to standardize these parameters.

1200 Pattern Based Classification of Invasive Endocervical Adenocarcinoma, Depth of Invasion Measurement and Distinction from Adenocarcinoma In Situ: Interobserver Variation among Academic Gynecologic Pathologists

Carlos Parra-Herran, Monica Taljaard, Bojana Djordjevic, Carolina Reyes, Lauren Schwartz, John Schoolmeester, Ricardo R Lastra, Charles Quick, Anna Laury, Golnar Rasty, Marisa R Nucci, Brooke E Howitt. University of Ottawa, Ottawa, ON, Canada; University of Pennsylvania, Philadelphia, PA; Mayo Clinic, Rochester, MN; University of Chicago, Chicago, IL; University of Arkansas for Medical Sciences, Little Rock, AR; Cedars-Sinai Medical Center, Los Angeles, CA; Toronto East General Hospital, Toronto, ON, Canada; Brigham and Women's Hospital, Boston, MA.

Background: A pattern based classification (PBC) for invasive endocervical adenocarcinoma (IEA) has been proposed as predictive of the risk of nodal metastases. Importantly, pattern A tumors (IEA-A) have 0% rates of nodal involvement. We aim to determine the reproducibility of the PBC in the context of common diagnostic challenges: distinction between adenocarcinoma in situ (AIS) and IEA (particularly IEA-A), and depth of invasion (DOI) measurement.

Design: Nine gynecologic pathologists from 7 academic institutions independently reviewed 96 cases of endocervical adenocarcinoma (2 slides per case). They determined the presence or absence of AIS and/or IEA in each case, classifying the latter according to the PBC (IEA-A, B or C). Tumor DOI was also recorded. Intraclass correlation coefficients (ICC) were calculated.

Results: Overall, diagnostic reproducibility of AIS and IEA as per the PBC was acceptable (ICC 0.65, CI 0.58-0.72). Perfect agreement (9/9 reviewers) was seen in only 11 cases (11.4%), all destructively invasive (10 IEA-C and 1 IEA-B). Agreement by $\geq 8/9$, $7/9$ and $6/9$ reviewers was seen in 26%, 42.7% and 64.6% cases, respectively. Among the 62/96 cases with $\geq 6/9$ concordance, 45 (72.5%) were IEA-B or C; 17 (27.5%) had an agreement diagnosis of AIS or IEA-A. Agreement in the diagnosis of AIS vs IEA-A was poor (ICC 0.23). Distinction between nondestructive (AIS/IEA-A) and destructive (IEA-B/C) carcinoma showed higher agreement (ICC 0.62). Estimation of DOI showed superior reproducibility compared to the PBC (ICC 0.84, CI 0.8-0.88).

Conclusions: Based on interobserver agreement, the PBC is best at diagnosing destructive patterns or IEA (B and C), which carry a risk for nodal metastases. Agreement in the diagnosis of AIS and IEA-A was less consistent; given their nil risk of nodal spread, the term "endocervical adenocarcinoma with nondestructive proliferation" can be considered when the distinction between the two is difficult, after excluding destructive IEA. Estimation of DOI was highly reproducible among pathologists; thus, the PBC can complement, but should not replace, the DOI metric.

1201 Endocervical Adenocarcinoma (EEC): A Retrospective Study of 75 Cases

Anna Pesci, Angela R Shih, Esther Oliva. Ospedale Sacro Cuore-Don Calabria, Negrar, Verona, Italy; Massachusetts General Hospital, Boston, MA.

Background: Among EEC, usual type is most common. However, true incidence of other types is not well known with gastric adenocarcinoma often classified as usual type in the past. Moreover, a new classification based on pattern of invasion has been proposed for usual EEC which appears to correlate with risk of lymph node (LN) metastases. We aim to determine the incidence of different types of EEC with special interest in gastric type and prognosis based on subtypes and pattern of invasion.

Design: EEC diagnosed at our institution between 2000-2010 were retrieved excluding biopsy specimens. Histotype, pattern-of invasion as described by Silva (A, B and C), stage and follow-up were recorded.

Results: The 75 patients had a mean age of 44 (range 26-79) yrs. 55 were usual (73%), 9 gastric (12%), 6 endometrioid (8%), 3 adenocarcinoma (4%), 1 clear cell and 1 mixed usual/neuroendocrine carcinomas. Median age of patients with usual EEC was younger (43 yrs) compared to gastric (50 yrs) and endometrioid (51 yrs) EEC. One gastric EEC occurred in a setting of lobular endocervical gland hyperplasia and one in Peutz-Jegher Syndrome. 13 EEC (17.3%) had a pattern A of invasion (all usual), 10 pattern B (9 usual, 1 endometrioid) and 52 (69.3%) pattern C (33 usual, 9 gastric, 5 endometrioid, 3 adenocarcinoma, 1 clear cell and 1 usual/neuroendocrine). Within pattern A, 12 and 1 out of 13 patients had stage I and II tumors respectively and all were alive and well (AW) (4-13; average 7.5 years). All 10 patients with pattern B had stage I tumors and were AW (1-11; average 7.6 yrs). Among patients with pattern C, 41 had stage I (78%)(27 usual, 5 endometrioid, 5 gastric, 2 adenocarcinoma, 1 clear cell, 1 mixed usual/neuroendocrine), 6 stage II (4 usual, 2 gastric) and 5 stage III (2 usual, 2 gastric, 1 adenocarcinoma) tumors. 7 patients had LN metastasis (3 usual, 3 gastric, 1

adenosquamous type). Of 49/52 patients with follow-up (6, range 1-15 yrs), 4 died of disease (1, 3, and 11 yrs)(1 usual, 3 gastric), 2 were alive with disease (usual)(3 and 4 yrs) and 1 died of unrelated causes at 9 yrs. 5/9 patients with gastric EEC were AW (1, 6 and 7 yrs, 3 stage I, 1 stage II and 1 stage III).

Conclusions: EEC with pattern A/B of invasion are usual type, stage I and have good prognosis. Gastric EEC is not an infrequent histotype as much as we are able to recognize its morphological characteristics. It presents in older women compared with usual type, that have higher stage tumors. Endometrioid EEC is also seen at older age and has a pattern C of invasion but does not affect prognosis.

1202 PD-L1 Expression in Malignant Mixed Mullerian Tumors: A Potentially Actionable Biomarker

Andre Pinto, Nicholas Mackrides, Mehrdad Nadji. University of Miami / Jackson Memorial Hospital, Miami, FL.

Background: Malignant Mixed Mullerian Tumors (MMMT), also known as carcinosarcomas, are aggressive malignant neoplasms with a high recurrence rate and poor prognosis. Despite advances in adjuvant therapies in recent years, the prognosis of these tumors has not improved. In fact, there are currently no consensus guidelines for the treatment of these neoplasms, and the search for targetable biomarkers has not been successful so far. Programmed death-ligand 1 (PD-L1) has emerged as a potential target for therapeutics in a number of malignant tumors, including melanoma, lung and colorectal cancer. In normal conditions, PD-L1 is thought to promote immune homeostasis via a number of pathways, but mainly through downregulation of cytotoxic T-cells. In some human neoplasms, however, overexpression of PD-L1 has been observed, and this phenomenon can modulate the immune system to allow cancer cells to evade host response. In this study we evaluated the expression PD-L1 in a group of MMMTs using immunohistochemistry.

Design: A total of twenty nine (29) cases of MMMTs were analyzed, corresponding to tumors originating from uterus (25), ovary (2), fallopian tube (1), and pelvic epithelium (1). The material was retrieved from the files of the Department of Pathology at the University of Miami, Jackson Memorial Hospital. Immunohistochemistry for PD-L1 was performed on paraffin sections and the staining results were assessed semi quantitatively in both epithelial and mesenchymal components of each tumor.

Results: Positive reactions (any membranous staining) for PD-L1 were detected in a total of 25/29 tumors (86%). The epithelial components were strongly positive in 19/29 (65%) and weakly positive in 6/29 tumors (21%). The sarcomatous elements were strongly positive in 8/29 (27%) and weakly positive in 3/29 tumors (10%). All tumors with positive sarcomatous components also had staining of the carcinomatous element. Four (4) tumors were negative for PD-L1 in both components.

Conclusions: This study shows that PD-L1 is expressed by the majority of MMMTs, predominantly in the epithelial components. This is particularly important since most locoregional recurrences and distant metastases of MMMTs are of epithelial origin. Although clinical studies are needed to demonstrate the efficacy of PD-L1 inhibitors in this particular neoplasm, this finding may serve as a basis for therapeutic approaches using antibodies that have already shown significant value in a number of other malignant tumors.

1203 Hysterectomy Specimens of Patients with Lynch Syndrome: Clinicopathologic Study of 70 Cases

Ana S Pires-Luis, Carla Bartosch, Catarina Meireles, Carla Pinto, Jose M Lopes, Kristen M Shannon, Manuel R Teixeira, Esther Oliva. IPO-Porto, Porto, Portugal; CHSJ, Porto, Portugal; Massachusetts General Hospital, Boston, MA.

Background: Women with Lynch syndrome (LS) have a high risk of developing gynecological tumors. Since endometrial carcinoma not uncommonly is the first malignancy, prophylactic hysterectomy has been increasingly implemented.

Design: We reviewed the clinicopathologic features of 70 LS patients diagnosed at 3 tertiary referral centers (1995-2015) that underwent prophylactic (PH)(n=39) or non-prophylactic (NPH)(n=31) hysterectomy, and evaluated the gross methodology used as well as any differences.

Results: Among PH, only 2 out of 39 had an endometrial tumor seen grossly. Total inclusion of the endometrium was performed in 24 (61.5%). Abnormal histological findings were identified in 9 (23.1%): including 3 endometrial endometrioid carcinomas (EECs), 2 macroscopic (1.3 and 4.5cm) and 1 microscopic (0.6cm), and 4 atypical and 6 non-atypical hyperplasias.

NPH were performed for endometrial or ovarian cancer treatment. Tumor sampling followed standard protocols. Endometrial carcinomas comprised 26 EEC and 1 clear cell carcinoma (median 3.7cm). Hyperplasia was observed in 10 (33.3%), in 4 showing atypia. Eight (29.6%) tumors were centered in the lower uterine segment. EEC were predominantly well-differentiated (53.8%) and FIGO stage I (77.8%). A papillary architecture was common (51.9%). Most endometrial tumors (81.5%) showed tumor intraepithelial lymphocytes counts $\geq 42/10$ HPF and 4 extensive necrosis. Eight patients had ovarian tumors (4 synchronous), including 2 endometrioid carcinomas, 2 clear cell carcinomas, 1 borderline clear cell adenofibroma, 1 Müllerian carcinoma of mixed cell types, 1 PNET and 1 metastatic melanoma.

Patients with NPH were older (median age: 51 vs. 45 years, $p=0.022$), had less frequent personal history of other tumors (51.6% vs. 79.5%, $p=0.013$), lower frequency of MLH1 mutations (12.9% vs. 48.7%, $p=0.002$), and higher frequency of MSH6 mutations (29.0% vs. 5.1%, $p=0.006$) when compared to patients with PH.

Conclusions: The phenotype of LS-associated endometrial and ovarian tumors is variable but frequently includes features not commonly observed in sporadic cancers. Total inclusion of the endometrium should be done in LS patients' uteri without macroscopic lesions as may harbor hyperplasia or early carcinoma. Differences in

mutations distribution correlate with the higher risk of endometrial cancer in MSH6 mutation carriers and more frequent history of MLH1 related colo-rectal neoplasms in PH group.

1204 Fumarate Hydratase Alterations Detected by S-(2-Succino)-Cysteine Expression in 6 Different Types of Uterine Smooth Muscle Tumors

Kate Poropatich, Qing Zhang, Julianne Martinez de Ubago, Norma Frizzell, Beihua Kong, Jian-Jun Wei. Northwestern University, Chicago, IL; University of South Carolina School of Medicine, Columbia, SC; Qilu hospital, Ji'nan, Shandong, China.

Background: Fumarate hydratase (FH) mutations (Reed's syndrome) is associated with uterine leiomyomatosis and occasionally with uterine leiomyosarcoma (LMS). Leiomyomas with FH alteration seems to have unique histologic findings. However, it currently remains unknown how FH alterations present in different types of uterine smooth muscle tumors (USMT). In this study, we examined the distribution of FH positive and negative tumors in a wide spectrum of USMT and compare the histologic features.

Design: Retrospectively collect 184 cases of USMT, including 46 usual type (ULM), 7 mitotically active (MALM), 22 cellular (CLM), 53 atypical (ALM) leiomyoma, 18 STUMP and 38 LMS (Table 1). All cases were re-reviewed to confirm the diagnosis. Immunohistochemistry analysis of S-(2-succino)-cysteine (2SC), a protein modification that accumulates in the presence of increased fumarate concentrations (most likely as a result of FH inactivating mutations) was examined and scored.

Immunostains for ER, PR, P16, P53 and Ki-67, and MED12 mutation were included. Histologic analysis of 2SC-positive and -negative tumors were performed.

Results: Immunostain for 2SC is specific to USMT and it is either positive or negative. Among 6 different types of USMT, 2SC was positive in order of highest to lowest frequency as: ALM (50%), STUMP (17%), CLM (14%), LMS (3%) and ULM (2%), respectively. When H/E slides were further reviewed, the majority of cases (77%, 27/33) with 2SC positive tumors had FH-associated histologic features. FH-positive tumors also showed different immunoprofile from FH negative tumors. Mutational analysis of FH for 2SC positive tumors is currently ongoing.

Morphologic, Molecular and Immunohistochemical Characteristics of FH-Positive USMT

	S2CS/FH status		With FH features	Without FH features	Immunoreactivity ² and MED12 mutations (%)											
	No. cases	FH+ (%)			ER		PR		Ki-67		p16		p53		MED12	
					+	-	+	-	+	-	+	-	+	-	+	-
LMS	38	1 (3.0)	1	0	5	12	0	12	50	29	23	69	0	27	0	11
STUMP	18	3 (16.7)	1	2	43	58	83	90	1	8	20	33	23	10	0	15
ALM	53	27(50.3)	24	3	41	40	84	91	1	2	24	37	12	27	0	10
CLM	22	3 (13.6)	0	3	47	72	84	80	<1	2	2	15	0	10	0	17
MALM	7	0 (0)	-	-	66	-	79	-	1	-	12	-	10	0	85	
ULM	48	1 (2.1)	1	0	-	36	-	63	-	7	1	12	10	-	0	67

1. FH features include large round and oval nuclei with prominent nucleoli and perinuclear halo.
2. Average % of immunostain positive cells in five markers and % cases with MED12 mutations.

Conclusions: FH alterations/mutations are very common in ALM, but it can also be seen in other variants of USMT. The findings suggest that histologically-defined tumor types cannot accurately predict FH status. 2SC immunostain can be a useful biomarker for screening for FH-associated USMT and further assist clinical management.

1205 Fumarate Hydratase Alteration and Other Molecular Changes in Two Histologic Variants of Atypical Leiomyomas

Kate Poropatich, Qing Zhang, Julianne Martinez de Ubago, Norma Frizzell, Beihua Kong, Jian-Jun Wei. Northwestern University, Chicago, IL; Qilu Hospital, Jinan, Shandong, China; University of South Carolina, Columbia, SC.

Background: Atypical leiomyoma (ALM) may be divided into two types based on their characteristic nuclear features. The recently described uterine smooth muscle tumors with fumarate hydratase alterations (SMT-FHs) seem to have similar nuclear features as type I ALM. In this study, we want to investigate whether histologically-defined types I and II ALM can be supported by molecular findings of FH status and other genetic alterations.

Design: A total of 53 ALM were selected that met the Stanford criteria and were further divided into type I (n= 30) and II (n= 23) based on nuclear features. Other histologic features were also analyzed, including cellularity, density of atypia, size of nucleoli, perinuclear halo, staghorn vessels and eosinophilic globules. IHC analysis of S-(2-succino)-cysteine (2SC) (most likely as a result of FH inactivating mutations) and mutation analysis of p53, MED12, PTEN and HMGA2 genes were performed.

Results: Two histologic types of ALM were defined as follows: type I ALM have large round-oval nuclei with well-defined nuclear membrane, open and vesicular chromatin and distinct nucleoli and type II ALM have large oblong-spindle nuclei with irregular nuclear membrane/contour, dark-smudgy chromatin and pinpoint or obscure nucleoli. 51% ALM (27 of 53) were positive for 2SC, among which, 73% were type I (22 of 30) and 22% were type II (5 of 23) ALM. All control myometrium cases (n= 44) were negative for 2SC. Overall, 80% of type I ALM with 2SC expression displayed the typical SMT-FHs features. Re-review of type II 2SC-positive ALM (n= 5) showed that two of these cases had some SMT-FHs morphologic features. Mutational analysis showed that MED12 and HMGA2 mutations skewed towards type II ALM (24% and 29% present, respectively) and were absent in type I ALM.

Conclusions: ALM is can be readily divided into two different types based on the distinct histological features. A combined histologic and 2SC IHC approach can identify most, but not all, type I ALM as SMT-FHs tumors. Type I ALM are characterized by increased fumarate, whereas type II ALM may more frequently contain MED12 mutations and/or HMGA2 overexpression, suggesting a different mechanism of tumorigenesis.

1206 Epidemiologic Dissociation between Two Subtypes of Molecularly Similar Tumors

Julio Poveda, Carmen Gomez-Fernandez, Paula Espinal, Ernesto Martinez-Duarte, Elena Vrotsos, Pan Yue, Andre Pinto. University of Miami / Jackson Health System, Miami, FL; University of Miami Miller School of Medicine, Miami, FL.

Background: Breast cancer of basal-like subtype, which corresponds to approximately 75% of triple-negative breast cancers (TNBC), has an increased incidence in younger women of African ancestry. Ovarian serous cancer is most prevalent in older Caucasian women. Recent studies have demonstrated that basal-like breast cancer (BLBC) and ovarian high grade serous carcinoma (HGSC) have significant similarities in terms of molecular signatures.

The current study aims to evaluate the demographic heterogeneity of these cancers, with special attention to serous carcinomas, on which published data is scant. Considering that similar molecular pathways may or may not reflect in some epidemiologic factors, we decided to analyze a cohort of high grade serous and basal-like breast carcinoma patients for comparison.

Design: We performed a systematic review of our database of a 12-year period. A total of 65 ovarian HGSC and 40 TNBC, of possible basal-like subtype, were retrieved. The latter was tentatively achieved by eliminating all apocrine (and/or with positive androgen receptor immunostain) and lobular carcinomas, and including all medullary and metaplastic types.

Due to limited sample size, we classified ethnicity and race into three groups: Hispanic Whites (HW), Non-Hispanic Whites (NHW) and Non-Hispanic African Americans (NHAA). Statistical analysis was implemented using SAS (SAS Institute, Version 9.1). **Results:** Of the 105 cases retrieved, 55 (52.4%) are HW, 28 (26.7%) are NHAA, and 22 (20.1%) are NHW. Chi-square tests were conducted and demonstrated significant ethnicity difference between the two cancers (p=0.0014).

In our institution, the majority of HGSC patients are HW (66.2%), while the majority of BLBC patients are NHAA (37.5%). We further examined the ethnicity difference of demographics and risk behaviors and found no difference for age, BMI and age at menarche. The remaining analyzed factors (number of pregnancies, BRCA status, use of OCPs, history of hormone replacement therapy, smoking history) were not significant.

Conclusions: Our results describe a significant ethnicity difference between BLBC and HGSC patients (p=0.0014), which paradoxically contrasts with the shared molecular equivalence among them. A study that includes a larger cohort is necessary in order to better comprehend this and the remaining associations (or lack thereof). A better understanding of the multifactor determinants of ovarian cancer may lead to the development of more effective screening programs.

1207 Loss of Expression of SMARCA4 (BRG1) and SMARCB1 (INI1) in Undifferentiated Carcinoma of the Endometrium Is Not Always Associated with Rhabdoid Morphology

Preeha Ramalingam, Sabrina Croce, W Glenn McCluggage. MD Anderson Cancer Center, Houston, TX; Belfast Health and Social Care Trust, Belfast, United Kingdom; Centre Regional de Lutte Contre Le Cancer, Bordeaux, France.

Background: Abnormalities of SMARCB1 (INI1) gene, a member of the SWI/SNF pathway, has been associated with pediatric and adult neoplasms such as atypical teratoid/rhabdoid tumor, epithelioid sarcoma and extraskeletal myxoid chondrosarcoma. Many of these neoplasms have rhabdoid morphology (RM) and molecular abnormalities result in loss of immunostaining with INI1. Recently, SMARCA4 (BRG1), another member of the SWI/SNF pathway, important in the development of ovarian small cell carcinoma of hypercalcemic type, has been investigated in a small cohort of poorly differentiated endometrial adenocarcinomas. In that study, 24 cases of grade 3 endometrioid adenocarcinoma and 1 case of de-differentiated adenocarcinoma (DDC) (mixed endometrioid adenocarcinoma and undifferentiated carcinoma) were evaluated for BRG1 and INI1 expression. INI1 expression was intact in all cases but loss of BRG1 was identified in one case of DDC with RM. The aim of our study was to evaluate the expression of INI1 and BRG1 in a larger cohort of undifferentiated endometrial carcinomas (UCA).

Design: Thirty-nine UCA (22 DDC and 17 pure UCA) were stained with BRG1 (n=39) and INI1 (n=27) on whole tissue sections. Both markers were assessed in tumor cells as intact (nuclear staining of any intensity) or lost (complete absence of nuclear staining). Loss of staining was considered only if there was a positive internal control (endothelial cells/stromal cells). Correlation of BRG1 and INI1 expression with clinical outcome was performed in 18 cases.

Results: BRG1 was intact in 29 of 39 (74%) and lost in 10 of 39 (26%) cases. INI1 was intact in 26 of 27 (96%) cases. RM was present in 3 of 10 (30%) BRG1 negative cases; one case with INI1 loss did not have RM. In the BRG1 intact group, 7 of 13 (54%) patients died of disease (DOD), 5 (38%) were alive with no evidence of disease (ANED) and 1 (8%) was alive with disease at 33 months. In the BRG1 negative group, 2 of 5 (40%) were ANED, 2 (40%) DOD and 1 (20%) died of other causes.

Conclusions: In our study, 26% of UCAs showed loss of BRG1 expression. Of these, only one-third was associated with RM. There was no correlation between BRG1 expression and outcome. Our preliminary data suggest that the SWI/SNF chromatin remodeling complex may be involved in the pathogenesis of UCA regardless of RM. Future studies should investigate the molecular changes underlying BRG1 loss.

1208 CD8, FoxP3 and CD45Ro Positive Tumor Infiltrating Lymphocytes in Endometrial Carcinomas: Is There a Difference between European American and African American Patients?

Tariq Rashid, Jennifer Young Pierce, Elizabeth Garrett-Mayer, Laura S Spruill. Medical University of South Carolina, Charleston, SC.

Background: The prognosis for African-American (AA) females with endometrial cancer, compared European-Americans (EA), is significantly worse across all stages and grades. The presence of tumor-infiltrating lymphocytes (TILs) has been demonstrated to be of prognostic significance in a variety of malignancies, including endometrial cancers. This study aims to determine whether clinically significant differences in levels of CD8+ cytotoxic T-lymphocytes, FoxP3+ regulatory T-lymphocytes and CD45RO+ memory T-lymphocytes exist between races and to document the clinical impact of TILs.

Design: One-hundred ten patients with endometrial adenocarcinoma, treated with hysterectomy from 2003-2011 were identified for study. Patients were selected to provide roughly equal representation across type and grade for both EAs and AAs. Slides were made from paraffin-embedded tissue and immunohistochemical stains were used to highlight CD8, FoxP3 and CD45Ro positive TILs at the endometrial-myometrial interface. Patients with “high” or “low” levels of TILs were compared with respect to the race, tumor type and survival.

Results: High levels of CD45RO+ TILs, compared to low levels, were associated with improved overall survival in EA women (HR 0.32, 95% C.I. 0.11-0.92, p=0.034). Comparatively, AA women with high levels of CD45RO+ TILs received no survival benefit (HR 0.96, 95% C.I. 0.35-2.64, p=0.94). High levels of CD8+ or FoxP3 positive TILs, alone, had no impact on survival. EA patients with TILs containing high levels of CD45Ro cells but low levels of CD8+ cells lost the survival benefit, however limited numbers preclude significant conclusions from this observation. Neither tumor type nor race were predictive of the levels of tumor infiltrating lymphocytes of any type.

Conclusions: Race does not impact the number or type of TILs in endometrial carcinoma. Despite this, EA patients, compared to AA patients, realize a survival benefit with increased numbers of CD45Ro positive TILs. These observations are applicable to Type I and Type II tumors. Further study with a larger sample size is required to determine the impact of more than one subtype of TIL on survival.

1209 Yolk Sac Tumor in Extragenital Gynecologic Sites Still a Diagnostic Challenge

Sanjita Ravishankar, Anais Malpica, Preetha Ramalingam, Elizabeth D Euscher. MD Anderson Cancer Center, Houston, TX.

Background: Yolk sac tumor (YST) is a diagnostic challenge when occurring outside typical age ranges or in extragenital (EG) sites. This study presents a series of such tumors (tu) at EG gynecologic (GYN) sites.

Design: Identified cases (1988-2015) were reviewed for: age, clinical presentation, tu location, FIGO stage, initial diagnosis (dx), histologic pattern (solid (S), reticular (Ret), papillary (Pap), glandular (Gld), hepatoid (Hep)), myxoid stroma (MS), Schiller-Duval bodies (SD), other germ cell or somatic tu, and immunohistochemical studies (IHC).

Results: Table 1 summarizes the clinicopathologic features of 12 cases.

Pt	Age	Symptoms	Primary Site	FIGO Stage	Associated Tu	Outside Dx	Histologic Pattern(s)	Myxoid Stroma	SD	F/U
1	71	Abnormal Vaginal Bleeding (AVB)	UT	IIIA	Serous, endometrioid (E) CA	Unkn	Ret, Pap	Yes	No	DOD
2	55	AVB	UT	II	Complex hyperplasia	ECA	S, Ret, Pap	Very focal	Rare	DOD
3	59	ABV, uterine (UT) mass	UT	IB	None	ECA	Gld, S	Focal	No	LTF
4	42	Hematuria, back pain	Bladder	NA	ChorioCA (only in metastasis)	Adeno CA	Gld	No	No	DOD
5	68	AVB, UT mass on surveillance imaging for colorectal CA	UT	IV	None	Met colorectal CA	Gld, S, Pap	No	Rare	DOD
6	77	AVB, UT mass	UT	IIIC	ECA, undiff-fca	MMMT	Gld, S	Yes	No	LTF
7	64	AVB	UT	IIIA	AdenoCANOS	Undiff CA	Hep, S, Gld	No	No	DOD
8	27	AVB	Vagina	II	None	YST	Ret, S	No	No	AWD
9	17	Right labial mass	Vulva	IIIB	None	Adeno CA	Ret, S	Yes	Rare	AWD
10	87	AVB	UT	II	Adeno CA NOS	Endocervical adeno CA	Ret, S	No	No	NED
11	41	Abdominal pain, bloating	Peritoneum	NA	Immature teratoma (IT)	IT	Ret	Yes	No	NED
12	61	AVB	UT	IA	None	Met colorectal CA	Gld	No	No	NED

IHC facilitated or confirmed the dx in all cases with the following positive results: cytokeratin (CK) 7, rare+ 2/12 cases; CK20, rare+ 5/10 cases; CDX2, 9/10 cases; PAX8, rare+ 1/7 cases; AFP 7/12 cases; glypican3 7/8 cases; SALL4 10/10 cases.

Conclusions: EGYST of the GYN tract is rare, usually presenting in older patients and may have associated an associated somatic carcinoma (CA). EGYST is usually misdiagnosed as CA when Gld or Ret patterns are usually present. Helpful features (MS, SD) are not prominent. IHC findings of EGYST of the GYN tract may overlap with colorectal CA (CK7-/CK20+, CDX2+), and in these cases SALL4 is useful. Patient outcome is variable, but 75% with advanced stage died of disease.

1210 Mucinous Proliferations of the Endometrium Subdiagnostic of Malignancy in Curettages and Biopsies: A Clinicopathologic Analysis of 41 Cases

Kojo R Rawish, Mohamed M Desouki, Oluwole Fadare. UC San Diego Medical Center, San Diego, CA; Vanderbilt University, Nashville, TN; Vanguard Pathology Associates, Austin, TX.

Background: Morphologic criteria that predict malignancy from mucinous proliferations in endometrial biopsies and curettages are known to be suboptimal. For the diagnosis of carcinoma, we have been applying a stringent set of criteria that emphasizes diagnostic specificity, and which is essentially identical to the criteria that are applicable for endometrioid proliferations. All other mucinous proliferations are classified as “complex mucinous proliferations” (CMP) with an explanatory comment. Herein, we evaluate the clinicopathologic features of the latter group

Design: 41 cases designated as CMP in sampling specimens were retrieved from our files. These represented 70% of 67 consecutive proliferations with the “mucinous” designation diagnosed during this period (the other 30% being carcinomas). Clinicopathologic features were assessed

Results: The average age was 46 years (range 37-59). Post-biopsy follow-up duration ranged from 15-109 weeks (mean 40). There was no follow-up resection in 12 patients (9 with repeat biopsies, all 9 NED, mean follow up of 43 weeks) and 29 patients underwent a hysterectomy an average of 2.4 months after the index biopsy. The distribution of pathologic findings in the uteri was as follows: No residual mucinous proliferation or carcinoma (5/29; 17%), residual CMP (11/29; 38%), adenocarcinoma (45%; 13/29). The 13 carcinomas were endometrioid (n=8), mucinous (n=3), and endometrioid with

mucinous differentiation (n=2). All were FIGO grade 1 and stage I. Only 3 (23%) carcinomas were myoinvasive, but 1 case, a mucinous carcinoma, showed >50% myometrial invasion. Comparative analysis of the biopsies that preceded the carcinoma and the CMP group showed no significant differences regarding frequency of grade 2/3 atypia, mitotic index, extent of extracellular proliferation, presence of glands with mucin depletion, tissue volume, patient age and necrosis

Conclusions: In sampling specimens, mucinous proliferations with features that are sub diagnostic of carcinoma represent a biologically-variable spectrum of lesions that includes mucinous hyperplastic proliferations, endometrioid and mucinous adenocarcinomas, and occasionally myoinvasive carcinomas. We did not identify any morphologic criteria predictive of the carcinoma subset of this group. Our findings suggest that there is a need for extra-morphologic tools to assist in predicting which mucinous proliferations are most likely to be associated with malignancy.

1211 Expression of PD-L1 in Ovarian Tumors May Provide Potential Immunotherapy Candidates

Opal L.Reddy, Itsushi P Shintaku, Neda A Moatamed. David Geffen School of Medicine at UCLA, Los Angeles, CA.

Background: Programmed death ligand 1(PD-L1) is a transmembrane protein involved in immune responses. The interaction of PD-L1 with its receptor PD-1 on T cells has been shown to block anti-tumor T-cell function. Tumor expression of PD-L1 has facilitated the development of immune therapies to treat malignancies such as melanoma and some lung carcinomas. This study is the first systematic evaluation of PD-L1 expression in ovarian neoplasms.

Design: We assessed PD-L1 expression on a tissue microarray of 227 normal and neoplastic ovarian tissues. Immunohistochemical staining of the tissues was carried out using anti-PD-L1 (rabbit monoclonal, clone SP142) antibody. Absent cell membrane staining of PD-L1 was scored as *negative* and present staining was scored as *positive*.

Results: Table 1 summarizes the frequency of PD-L1 positivity in ovarian tissues. Overall, PD-L1 was positive in 31% (54/174) of all ovarian malignancies. Sub-categorically, 48% (22/46) of serous, 38% (3/8) of clear cell, 37% (15/41) of endometrioid, 33% (1/3) of undifferentiated, 6% (1/18) of mucinous, and 7% (1/14) of metastatic carcinomas were positive. PD-L1 was also positive in 50% of germ cell tumors (10/20). All borderline and benign tumors as well as the normal ovary were negative for PD-L1 expression.

Table 1	PD-L1 Expression in Ovarian Tissue and Its Neoplasms, n=227		
	n	Expressed (n)	Expression (%)
Malignant Tumors	174	54	31%
Serous Carcinoma	46	22	48%
Clear Cell Carcinoma	8	3	38%
Endometrioid Carcinoma	41	15	37%
Undifferentiated Carcinoma	3	1	33%
Mucinous Carcinoma	18	1	6%
Metastatic Carcinoma	14	1	7%
Squamous Cell Carcinoma	1	1	100%
Germ Cell Tumor	20	10	50%
Malignant Mixed Mullerian Tumor	3	0	0%
Sarcoma	3	0	0%
Sex Cord Tumor	15	0	0%
Small Cell CA	1	0	0%
Lymphoma	1	0	0%
Borderline Tumors	13	0	0%
Benign Tumors	30	0	0%
Normal Ovary	10	0	0%

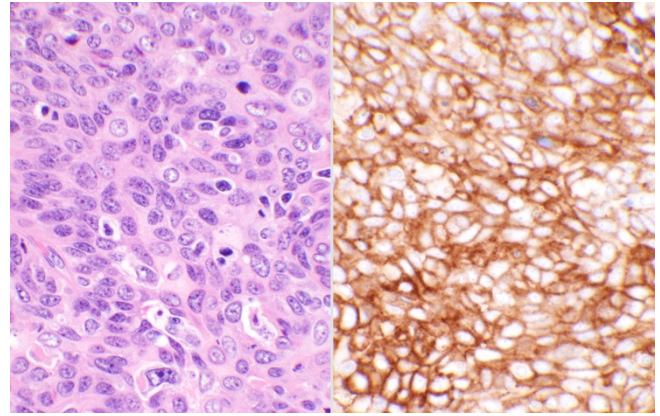
Conclusions: This study shows significant expression of PD-L1 in 31% of ovarian malignancies. Positive tumors may serve as potential candidates for the anti-PD-L1/PD-1 immunotherapies.

1212 Programmed Cell Death Ligand-1 Is Expressed in a Significant Number of Uterine Cervical Carcinomas

Opal L.Reddy, Itsushi P Shintaku, Neda A Moatamed. David Geffen School of Medicine at UCLA, Los Angeles, CA.

Background: Programmed cell death ligand 1 (PD-L1) is a transmembrane protein involved in the regulation of immune responses. PD-L1 by binding to its receptor PD-1 on the T cells, provides signals in regulating T cell activation and blocking anti-tumor immunity. The PD-1/PD-L1 axis has emerged as a promising new target for cancer therapeutics that has induced lasting responses in the treatment of metastatic renal and lung carcinomas, as well as melanomas. In this study, we investigated the expression of PD-L1 in human cervical tissue and cervical tumors.

Design: Immunohistochemistry was used to assess PD-L1 expression on a tissue microarray of 100 normal and neoplastic cervical tissues. Hematoxylin & eosin and PD-L1 immunohistochemical staining (clone SP142, rabbit monoclonal antibody) were performed. PD-L1 expression was scored as *positive* when present on cell membranes (Figure 1), regardless of cell numbers, and *negative* when absent.



Results: Table 1 summarizes the frequency of PD-L1 positivity in 100 cervical tissues. Overall, PD-L1 was positive in 72% (68/94) of cervical malignancies. Sub-categorically, 78% (57/73) of squamous cell carcinomas, 58% (7/12) of endocervical carcinomas, 43% (3/7) of adenosquamous carcinomas, and 100% (1/1) of small cell carcinomas were positive for PD-L1. It was negative in one endometrial carcinoma, benign lesions, and normal cervical tissues.

Table 1	PD-L1 Expression in Cervical Tissue and Its Neoplasms		
	n	Expressed (n)	Expression (%)
Malignant Tumors	94	68	72%
Squamous Cell Carcinoma	73	57	78%
Endocervical Carcinoma	12	7	58%
Adenosquamous Carcinoma	7	3	43%
Endometrial Carcinoma	1	0	0%
Small Cell Carcinoma	1	1	100%
Benign (Cervicitis)	3	0	0%
Normal Cervix	3	0	0%

Conclusions: This study shows significant expression of PD-L1 in 78% of the cervical malignancies, suggesting a role for future investigation of anti-PD-L1/PD-1 immunotherapies in the treatment of PD-L1-positive cervical tumors.

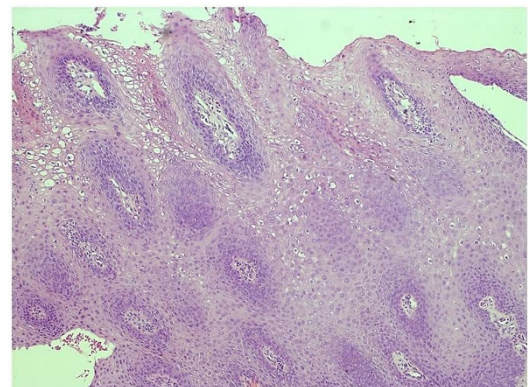
1213 PDL-1 Expression in Cervical Intraepithelial Neoplasia

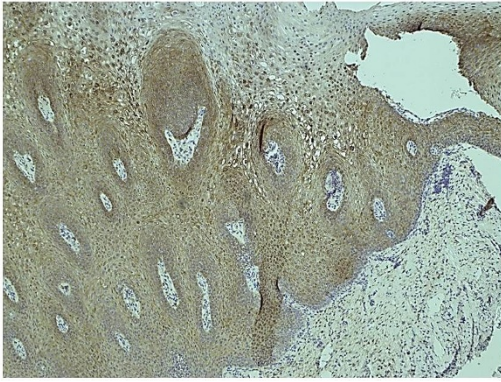Carolina Reyes, Deepti Adhikari Guragain, Kumarasen Cooper. Hospital of the University of Pennsylvania, Philadelphia, PA.

Background: Programmed death-ligand 1 (PD-L1) is a transmembrane protein that has been speculated to play a role in suppressing the immune system during particular events like pregnancy, autoimmune diseases and tissue allografts. In normal circumstances, immune system reacts to foreign antigens triggering proliferation of CD8+ T-cells. PD-L1 binds to its receptor PD-1 which is found on activated T-cells and transmits an inhibitory signal which reduces cytokine production and suppresses T-cell proliferation. It appears that up-regulation of PD-L1 may allow cancers to evade the host immune system and its up-regulation has been shown in various tumor types (melanoma, non-small cell lung cancer, multiple myeloma and ovarian cancer among others). The goal of our study was to assess PD-L1 immunohistochemical expression in cervical intraepithelial neoplasia (CIN1, CIN2 and CIN3) and compare the expression among them. We hypothesized that high grade squamous intraepithelial lesions (CIN2-3) will express higher levels of PD-L1.

Design: 29 cases of CIN1, 22 cases of CIN2 and 27 cases of CIN3 were retrieved from the archives of pathology from the University of Pennsylvania using database search. Unstained tissue sections were stained with anti-PD-L1 antibody. The intensity of PD-L1 staining was scored from 0-3+.

Results: Among the CIN1 cases (figure 1) and (figure 2), 10/29 (34%) expressed PD-L1 (2 cases showed 2+ and 8 cases showed 1+ intensity). In the CIN 2 category, 1/22 (4.5%) stained with PD-L1 with 2+ intensity. 5/27 (18.5%) cases of CIN3 expressed PD-L1 (3 cases with 2+ and 2 cases with 1+ intensity).





Conclusions: PD-L1 expression was mostly seen in CIN1 cases and only a minority in CIN2/CIN3 cases. Its expression may be related to the viral HPV particles that have not been integrated into the host genome as it usually happens in CIN2/CIN3 cases.

1214 The Utility of a Next-Generation Sequencing (NGS) Panel to Identify Germline Mutations Associated with Endometrial Cancer

Kari Ring, Amanda Bruegl, Brian Allen, Eric Elkin, Nanda Singh, Anne-Renee Hartman, Molly Daniels, Russell Broadus. M.D. Anderson Cancer Center, Houston, TX; Myriad Genetics, Inc., Salt Lake City, UT.

Background: Hereditary endometrial carcinoma (EC) is associated with germline mutations in Lynch syndrome (LS) genes. The role of other predisposition genes in EC is unclear. Our goal was to determine the prevalence of cancer predisposition gene mutations in an unselected EC patient cohort.

Design: Germline mutations in 25 genes associated with hereditary cancers were identified using an NGS panel applied to 381 unselected EC patients that had previously undergone tumor testing to screen for LS. Tumor testing consisted of IHC for MLH1, MSH2, MSH6, and PMS2, MSI, and *MLH1* methylation when the tumor had MLH1 loss.

Results: Thirty-five patients (9.2%) had a germline deleterious mutation (DM), 22 (5.8%) with DM in LS genes (3 *MLH1*, 5 *MSH2*, 2 *EPCAM-MSH2*, 6 *MSH6*, 6 *PMS2*) and thirteen (3.4%) with DM in 10 non-LS genes (4 *CHEK2*, 1 each in *APC*, *ATM*, *BARD1*, *BRCA1*, *BRCA2*, *BRIP1*, *NBN*, *PTEN*, *RAD51C*). Patients with DM in non-LS genes were more likely to have serous carcinomas (23.1% v 6.4%, $p=0.02$) than those with no DM. The 3 patients with non-LS DM and serous histology had mutations in *BRCA2*, *BRIP1*, and *RAD51C*, genes that have been linked to hereditary ovarian cancer. Of 20 patients with DM in LS genes and tumor testing, two (10%) had tumor testing suggestive of sporadic cancer but with DM in *MSH2* and *MSH6*. Of 10 patients with DM in *MLH1*, *MSH2*, and *EPCAM-MSH2*, 80.0% were younger than 50, 90.0% met SGO criteria for hereditary cancer screening, and 90.0% had a family history of LS associated cancer. Of 12 patients with DM in *MSH6* and *PMS2*, 83.3% were diagnosed at age greater than 50, 66.7% did not meet SGO criteria, and 66.7% did not have a family history of LS associated cancers. EC patients who were tumor testing positive but germline mutation negative had clinical and pathological features which were not clearly distinct from patients with identified germline DM or patients with sporadic endometrial cancer.

Conclusions: Current clinical testing paradigms for EC fail to identify a portion of actionable mutations in both LS and other hereditary cancer syndromes. 67% of cases in our study with *MSH6* and *PMS2* mutations lacked early age of diagnosis and family history of cancer. Universal tumor testing should be utilized to identify patients who may be missed by clinical criteria. Multi-gene panel testing can identify additional mutations, several of which have been previously linked to hereditary ovarian cancer.

1215 Frequency of High-Risk Human Papillomavirus Types in a Rural Appalachian Population

Ibrahim A Robadi, Majed Pharaon, Barbara Ducatman. West Virginia University, Morgantown, WV.

Background: West Virginia (WV) has a higher incidence rate for cervical cancer (10.2%) than the US as a whole (7.8%). In general, two high-risk Human Papillomavirus (hr-HPV), types 16 and 18, are presumably responsible for about 70% of cervical cancers.

Design: The objective of the study was to compare the rates and characteristics of women testing positive for hr-HPV 16/18 vs. hr-HPV/other in a rural Appalachian population. In a retrospective study (9/2013-12/2014), the charts of hr-HPV positive women (via the Roche Cobas® 4800) were reviewed for cytology results and demographic characteristics including body mass index (BMI), smoking status, HPV vaccination status and oral contraceptive pill use (OCP); these were correlated with the hr-HPV type (16/18 vs. other) and analyzed using JMP® Pro (SAS®).

Results: HPV testing was performed on 3515 Paps; 421 (12%) were positive for hr-HPV. Hr-HPV infection peaked in the 4th decade. Overall, the frequency of hr-HPV/other infection was 3x higher than hr-HPV 16/18 (75% vs. 25%, $p<0.05$). For 694 women with abnormal cytology, 193 tested positive for a hr-HPV type (27%), much higher than the overall rate. However, hr-HPV/other was more frequent in low-grade cytology, while the rate of hr-HPV 16/18 increased with cytologic severity. Of hr-HPV positive women (all types), the ever-smoking rate was 35%, compared to the state-wide rate of 26.5% (CDC data); however, there was no statistical difference between hr-HPV 16/18 and hr-HPV/other for ever-smokers vs. non-smokers. A higher smoking rate was associated with increasing cytologic abnormalities, 32% of women with ASC-US were ever-smokers vs. 41% for LSIL and 56% for HSIL. There were no significant

differences between types of hr-HPV in obese (BMI ≥ 30) vs. non-obese women and for OCP use. Women who received the HPV vaccination were more likely hr-HPV/other positive compared to hr-HPV 16/18 (83% vs. 17%; $p<0.05$).

Conclusions: A significant percentage of women in WV were infected with hr-HPV subtypes other than 16 and 18, although the latter were more likely associated with a severe cytologic abnormality. In contrast, hr-HPV/other was associated with prior vaccination. Smoking was also associated with increasing degrees of cytologic abnormalities, but as with obesity and OCP use, there were no significant differences in hr-HPV types. These findings have significance for the follow-up and vaccination of women in WV.

1216 Expression of GATA-3 in Testicular and Gynecological Mesothelial Tissues, Neoplastic and Non-Neoplastic

Arash Ronaghy, Guang-Qian Xiao, Eugene Santagada, Adnan Hasanovic, Pamela Unger. North Shore-LIJ - Lenox Hill Hospital, New York, NY; University of Rochester Medical Center, Rochester, NY.

Background: GATA-3, a zinc-finger transcription factor identified in T cells, but found to play a role in development of multiple organ systems. GATA-3 is a useful immunohistochemical stain in diagnosing breast and urothelial carcinoma. It is positive in a third of pulmonary mesothelioma cases. Its expression in testicular and gynecological mesothelial neoplasms such as adenomatoid tumors and benign mesothelium are unknown. We evaluated GATA-3 staining and compared it with the mesothelial markers calretinin and WT1 in urologic and gynecologic normal mesothelium, adjoining structures and adenomatoid tumors.

Design: Cases, from the files of Lenox Hill Hospital and the University of Rochester Medical Center, included 20 adenomatoid tumors (9/20 (para)testicular and 11/20 tubal or uterine) and 38 normal mesothelium (20/38 tunica albuginea and 18/38 fallopian tubes) were stained with GATA-3, WT1, and calretinin. Cases were graded as negative if 0 or $\leq 5\%$, +1 if $>5\%$ and $<25\%$, +2 if 25% and $\leq 50\%$, and +3 if $>50\%$ staining.

Results: Adenomatoid tumors: 2 urologic cases were GATA-3 positive (2/9, +3 and +1). No gynecological cases had GATA-3 reactivity (0/11). All adenomatoid tumors (20/20) were positive for WT1 and calretinin (+2 to +3). Normal mesothelium: 3/20 tunica albuginea were GATA-3 positive (+2) and all 20 cases were WT1 (+3) and calretinin (+2 to +3) positive. 18/18 gynecological cases with Walthard nests were GATA-3 positive (+3), 11 were WT1 positive (+2 to +3) and 1/18 was calretinin positive (+2). 18 normal nonmetaplastic gynecological mesothelium were GATA-3 negative (0/18) and positive for WT1 (+2 to +3) and calretinin (+2 to +3). 18 cases of epididymi and 11 cases of efferent ductules were also examined in urologic cases. All epididymi were GATA-3 positive (18/18, +3) and negative for WT1 (0/18) and calretinin (0/18). 11 efferent ductules were negative for GATA-3, WT1, and calretinin (0/11).

Conclusions: 1) Gynecological cases: Walthard nests are consistently positive with GATA-3 staining and loose mesothelial markers reflecting a metaplastic change. 2) GATA-3 may rarely stain adenomatoid tumors. It should be kept in mind when encountering frequent metastatic GATA-3 positive tumors to these sites. 3) Excluding the Walthard nests, GATA-3 is rarely positive in normal urologic and gynecologic mesothelium. 4) GATA-3 is uniformly positive in epididymi and negative in efferent ductules which may reflect the embryological evolution of these tissues.

1217 The Impact of Androgen Receptor Expression on Endometrial Carcinoma

Woodlyne Roquiz, Vishakha Pardeshi, Oudai Hassan, Eman Abdulfatah, Ankit Modh, Nagla Salem, MHD Fayeze Daaboul, Daniel Schultz, Mohamed A Elshaikh, Sudeshna Bandyopadhyay, Rouba Ali-Fehmi. Wayne State University/Detroit Medical Center, Detroit, MI; Henry Ford Hospital, Detroit, MI.

Background: Endometrial carcinomas (EC) are the most common gynecological cancers. The impact of androgen receptor (AR) on EC is not well studied. The aim of our study is to assess the role of AR expression in endometrial carcinomas.

Design: A retrospective review of 261 EC was conducted. H&E slides were reviewed and clinicopathologic parameters were analyzed. Immunohistochemical stains for AR, ER and PR was performed on tissue microarray. The hormonal expression was evaluated using a clinically validated cut-off established by ASCO/CAP. The data was analyzed using the Fisher exact test and Kaplan-Meier survival analysis.

Results: Patients age ranged from 31 to 91 (median = 65 years). Type I EC included 202 endometrioid and 7 mucinous carcinoma, whereas Type II included 34 serous, 16 MMMT and 2 clear cell carcinoma. Although not significant, AR expression showed more frequent association with Type I, early FIGO stage (I-II), and low FIGO grade (1-2) EC. AR expression significantly correlated with absence of lymphovascular invasion ($P=0.041$) and decreased LN involvement ($P=0.048$). Patients with AR expression showed increased disease free survival (208 vs 165 months, $P=0.008$). AR expression had a positive significant correlation with PR ($P<0.001$) and ER ($P=0.037$) expression.

Table 1. Correlation of AR with clinicopathologic parameters

Clinical characteristics	AR(-) N(%)	AR(+) N(%)	P
Age			
≤50yrs	23(18)	18(13)	.309
>50yrs	103(82)	117(87)	
FIGO Grade			
Low (1+2)	84(67)	102(76)	.074
High (3)	42(33)	33(24)	
Histologic Type			
I	95(75)	114(85)	.324
II	31(25)	21(15)	
Lymphovascular invasion			
Absent	99(79)	118(87)	.041
Present	27(21)	17(13)	
FIGO Stage			
Low (I+II)	107(85)	120(89)	.221
High (III)	19(15)	15(11)	
Lymph node status			
Positive	12(9)	5(3)	.048
Negative	114(91)	130(97)	
Recurrence			
Yes	25(20)	12(9)	.019
No	101(80)	123(91)	

Table 2. Correlation of AR expression with ER and PR expression

Immunoprofiles	AR(-) N(%)	AR(+) N(%)	P
ER	-	31(25)	.037
	+	95(75)	
PR	-	43(34)	<.001
	+	83(66)	

Conclusions: Expression of AR shows a significant positive correlation with ER and PR. AR expression might be useful as a good prognostic indicator in EC.

1218 Incidence of Occult Carcinomas in Fallopian Tubes in High-risk Patients – A Prospective Study from North Shore – LIJ Health System

Sudarshana Roychoudhury, Peter Farmer, Cathy Fan, Sharon Liang. Hofstra North Shore -LIJ Health System, Lake Success, NY.

Background: Fallopian tubes harbor occult serous carcinomas in many risk-reducing salpingo-oophorectomy specimens (RRSO), a preventive measure to reduce ovarian carcinomas in patients with high-risk factors including germline BRCA1/2 mutations or hereditary breast ovarian cancer syndrome (HBOC). The purpose of this study was to determine the incidence of occult malignancies in the fimbria with or without risk factors. **Design:** 187 surgical specimens were collected from January 2012 to September 2015, and processed following the standard SEE-FIM protocol. Ninety-four patients underwent RRSO and 93 bilateral salpingo-oophorectomy (BSO with/without hysterectomy) for other gynecologic conditions. Patients' demographics and significant histopathologic findings of the fallopian tubes were recorded.

Results: Four (4.3%) of 94 RRSO had occult non-invasive serous carcinoma in the fimbria (1-5 mm), while none were identified in BSO group (p=0.044). All these 4 patients (3 BRCA1, 1 BRCA2) were asymptomatic with normal CA-125. Three were stage 1A and 1 stage 3B (treated with chemotherapy). All four patients were alive without disease during 6 to 36 month follow-up. Another 60 y.o patient (BRCA1) with negative findings in RRSO had peritoneal serous carcinoma 26 months later. She received chemotherapy and currently is disease free.

In addition, serous tubal intraepithelial carcinoma (STIC) was identified in 2 RRSO, both associated with occult carcinoma. Two BSO had incidental STIC. One patient with BRCA1 mutation had p53 signature. Other benign epithelial changes (adenofibroma and mucinous metaplasia) were also noted in RRSO group (6 and 5) and BSO group (5 and 2). Three of 5 mucinous metaplasia in RRSO were seen in patients with breast carcinoma.

Conclusions: The incidence of occult carcinomas in fallopian tubes was 4.3% in high-risk group in this cohort, which is comparable with reported incidence. Risk of peritoneal carcinomas after RRSO remains. None of 12 patients with HBOC syndrome had occult malignancies, raising a question of whether family history alone without BRCA status is justifiable to receive RRSO.

	RRSO (n=94)	BSO (n=93)	P value
Age (range)	51.8 YO (34-72)	50 YO (29-87)	
Breast cancer	33	10	< 0.001
Risk factors	BRCA1 (63), BRCA2 (16), HBOC (12), other mutations (3)	N/A	
Occult serous carcinoma	4 (3 BRCA1; 1 BRCA2)	0	0.044
STIC	2	2	
p53 signature	1	0	
Adenofibroma	6	5	
Mucinous metaplasia	5	2	

1219 Validation of Pattern-Based Classification of Endocervical Adenocarcinoma (EAC)

Joanne KL Rutgers, Andres A Roma, Kay J Park, Richard Zaino, Dean Daya, Golnar Rasty, Abbey Johnston, Teri A Longacre, Brigitte M Ronnett, Elvio G Silva. Cedars Sinai, LA, CA; Memorial Sloan Kettering, NY, NY; Cleveland Clinic, Cleveland, OH; MD Anderson, Houston, TX; Penn State Hersey, Hershey, PA; Juravinski, Hamilton, Canada; University Toronto, Toronto, Canada; Ohio Health, Columbus, OH; Stanford, Stanford, CA; Johns Hopkins, Baltimore, MD.

Background: We published a 3-tiered pattern-based system for EAC of usual type. Pattern A: well demarcated glands without destructive stromal or lymphovascular invasion; B: localized destructive invasion arising from A glands & C diffuse destructive stromal invasion or significant confluence. A has none, B <5%, and C >25% + nodes or recurrence. Validation of reproducibility of this system is critical.

Design: 84 cases, 24 A, 22 B, 38 C from original study with reference diagnosis (RD) established by original group, & arbitration of difficult cases by 1st & last authors. 1 H&E slide/case mailed to 7 gyn pathologists, 4 from original study. Overall kappa (K) (agreement among raters) & individual weighted K calculated; 4-.6 is moderate & .6-.8 substantial agreement. Cases with major discordance were reviewed.

Results: All but 1 pathologist had substantial agreement to RD (K .52-.78). Overall K was .49; highest for C, & lowest for B. Agreement not improved by combining B+C. The majority agreed with RD in 68 (81%) cases with complete or near-complete (6/7) agreement in 50%. Overall concordance is 74%.

	7 pathologists diagnoses of 84 cases			total
	A	B	C	
RD A	129	33	6	168
RD B	31	104	19	154
RD C	16	45	205	266
total	180	179	229	588

C was called A 16 times in 6 cases; recurrent problems included confluent/ labyrinthine tumor filling 4x field, linear destructive invasion >5 mm, & solid architecture, & 1 pathologist had difficulty recognizing destructive stromal invasion. A was called C in 6 cases; several lacked lobulation as seen in majority of A. A with foci of inflamed, loose or desmoplastic stroma without infiltrative tumor cells accounted for up-grading to B. Conversely, missing rare individual cells was a cause of undercalling B as A.

Conclusions: Substantial agreement with RD was found. The 3-tiered classification should be maintained, not condensed to 2-tiers. High power examination of focal desmoplasia for individual tumor cells can differentiate A from B; confluent growth is most difficult criteria for C. Further validation including application to EAC variants should allow use of this powerful classification system to delineate which EAC can be safely treated conservatively.

1220 p16 Staining Has Limited Value in Predicting Progression in Women with Histological Low-Grade Squamous Intraepithelial Lesions of the Cervix

Amaia Sagasta, Natalia Rakislova, Paola Castillo, Adela Saco, Aureli Torne, Roser Esteve, Lorena Marimon, Marta del Pino, Jaumeordi. Hospital Universitario Araba, Vitoria-Gasteiz, Spain; Hospital Clinic, Barcelona University, Barcelona, Spain; Center Int. Health Research (CRESIB), Barcelona, Spain.

Background: To evaluate the usefulness of p16 staining as a marker of risk of progression in patients with a histological diagnosis of low-grade squamous intraepithelial lesion/cervical intraepithelial neoplasia grade 1 (LSIL/CIN1).

Design: We prospectively recruited all the patients referred to colposcopy from 2003 to 2011 due to an abnormal screening test results and diagnosed with LSIL at biopsy (n=507). All biopsies were stained for p16, and were reevaluated after three years by the same gynecological pathologist using the LAST criteria. Follow-up was conducted every 6 months and included a Papt test (liquid based cytology), high-risk human papillomavirus testing (Hybrid capture 2 test) and colposcopy. Mean follow-up was 27.9 months. Progression was defined as a histological diagnosis of high grade SIL/cervical intraepithelial neoplasia grade 2-3 (HSIL/CIN2-3).

Results: During follow 86/507 women initially diagnosed of LSIL (17.0%) progressed to HSIL. After reevaluation, the diagnosis of LSIL was confirmed in 416/507 biopsies (82.1%) whereas 58 (11.4%) were reclassified as negative and 33 (6.5%) as HSIL. The rate of progression to HSIL was 3.4% (2/58) in the women with biopsies reclassified as negative, 16.8% (70/416) in the group with confirmed LSIL and 42.4% (14/33) in the

group reclassified as HSIL ($p < 0.001$). p16 was positive in 245/507 patients (48.3%) and in 210/416 patients (50.5%) with confirmed LSIL at reevaluation. Although in the overall group of patients with LSIL a positive p16 immunostaining was associated with risk of progression in the multivariate analysis (Hazard ratio (HR) 1.9; 95% confidence interval (CI): 1.2-3.1; $p = 0.009$), this association was not verified in the subset of patients with confirmed LSIL at reevaluation (HR: 1.6; 95% CI: 0.9-2.6; $p = 0.095$).

Conclusions: p16 usefulness in LSIL lesions should be limited to equivocal cases in which HSIL is included in the differential diagnosis and has low value in clinical practice as a marker of progression of LSIL.

This work was partly supported by Instituto de Salud Carlos III-Fondos de Investigación Sanitaria and ERDF (PI12/01231 and PI12/01165).

1221 Analysis of Ovarian Mucinous Neoplasms by Single Nucleotide Polymorphism/Copy Number Variation Assays

Ozlen Saglam, Jacob P Crowley, Sean Yoder, Robert M Wenham, Anthony M Magliocco. Moffitt Cancer Center, Tampa, FL; Affymetrix, Santa Clara, CA.

Background: Mucinous tumors of the ovaries represent a spectrum of neoplastic disease, including benign mucinous cystadenoma (10-15%), mucinous tumors of low malignant potential (borderline tumor) (MBT) (67%), and mucinous ovarian carcinoma (MOC). A continuum appears to be present from benign to borderline to malignant, which is less common in other types of epithelial ovarian cancers (EOC). Chromosomal aberrations were documented in the EOC. However, it is not definite which alterations are significant from benign to borderline to malignant tumor transition.

Design: Representative sections from 4 paired MOC with background MBT (n=8) and 2 pure MBT were selected from archival material. A metastatic site was included in a cancer case. Of 4 MOC, 2 showed stromal invasion and 2 had invasion by expansion. Following DNA extractions from macro-dissected tissue guided by matching H&E sections, Affymetrix OncoScan Assay was performed in 11 specimens. The copy number aberrations and genome-wide LOH were analyzed by the OncoScan Nexus Express Software.

Results: Eight of 11 samples passed quality control: 1. All samples from MBT (n=5), MOC (n=2) and metastatic site (n=1) showed copy number aberration at loci encoding the glutathione-S-transferase (GST) enzymes at 22q11.23. All aberrations were deletions except one MBT with gain at this site. 2. KRAS mutation (KRAS:p.G12D/V) was identified in all samples. 3. Multiple aberrations were observed both in MBT and MOC. The most common aberration was gain in chromosome 1 observed in 4 MBT and 1 MOC. The most common allelic imbalance was seen at 9p where all samples had LOH. 4. Both cancer cases showed gains in chromosome 12. Also seen in cancer case by expansion were gains in chromosomes 2, 7, 8, 18 and 19. Its background MBT and metastatic lesion showed copy number neutral LOH and an allelic imbalance in multiple chromosomes. 5. The cancer case with stromal invasion had gains in chromosomes 1 and 12 and losses in 9, 11, 17, 19 and X. Its background MBT showed same gains and losses.

Conclusions: 1. Reportedly, GST gene expression was associated with chemo-resistance in EOC. Its role in MOC treatment should be further explored. 2. MBT in the background of cancer by expansion had genomic changes similar to metastatic lesion. Relatively less complex genetic changes in the latter sample can be due to masked chromosomal deletions by gains. 3. Similar chromosomal gains and losses were observed in the carcinoma with stromal invasion and its background MBT. 4. MBT and MOC are genetically similar in this limited sample size.

1222 ALK-1 Expression in Uterine Leiomyomas with Myxoid Change and Its Utility in Distinguishing from Inflammatory Myofibroblastic Tumor

T Danielle Samulski, Julieta E Barroeta, Carolina Reyes. Hospital of the University of Pennsylvania, Philadelphia, PA; Pennsylvania Hospital, Philadelphia, PA.

Background: Inflammatory myofibroblastic tumor (IMT) is rare in the uterus, but can occur. These tumors may have similar morphology as myxoid leiomyomas, but are typically ALK-1 + and harbor an ALK translocation. However, ALK-1 expression has not been examined in myxoid leiomyomas, and therefore its utility in differentiating these entities is unknown. We aim to define the value of this immunohistochemical (IHC) marker in resolving this diagnostic dilemma.

Design: Cases of uterine leiomyomas with myxoid change diagnosed at our institution from 01/2008 to 12/2014 were identified. Representative blocks from these cases that demonstrated morphologic overlap with IMT were selected and stained for ALK-1 (Dako). Expression was graded as positive (1+, 2+, 3+) and negative (0).

Results: During a six year period at our institution, 26 leiomyomas with myxoid change and overlapping morphologic features of IMT were identified. Of these 26 cases, the majority (18) demonstrated no appreciable staining with ALK-1 (grade 0). A smaller portion of cases (8, 30%) demonstrated focal areas of patchy 1+ staining.

Conclusions: Through evaluation of a considerable number of cases, we define the expression of ALK-1 in leiomyomas with myxoid change via IHC analysis, which has not been formally investigated to date. While the majority of cases were negative for ALK-1 via IHC, few cases demonstrated only focal 1+ staining. The evaluating pathologist should be aware of this possibility in the workup of myxoid spindle cell lesions of the female genital tract, and reserve a diagnosis of IMT for those cases which demonstrate strong, diffuse staining, ideally with molecular confirmation.

1223 CXCL14-CXCR4 and CXCL12-CXCR4 Axes May Play Important Roles in Achievement of Unique Invasion Process of MELF Pattern Myoinvasive Endometrioid Carcinoma

Sakiko Sanada, Kaori Yasuda, Sachiko Ogasawara, Jun Akiba, Hirohisa Yano. Kurume University School of Medicine, Kurume, Japan; Cell Innovator Inc., Fukuoka, Japan.

Background: Microcystic elongated and fragmented (MELF) pattern is a unique type of myometrial invasion in endometrioid carcinoma (EMC), and MELF is associated with lymph node metastasis even in low grade EMC. However, its molecular mechanism is not well understood. This study explores to search unknown factor of MELF in vivo and in vitro.

Design: Laser microdissection and RNA extraction were performed on frozen sections of myoinvasive EMC with MELF and conventional case as a control. cDNA microarray revealed overexpression of chemokine receptor CXCR4 and its ligand CXCL14. Although there is no CXCL12 overexpression, we added to search as CXCL14 is known to modulate CXCL12-CXCR4 axis. Based on this context, clinico-pathologic features such as age, histological grade, lymphovascular invasion, and lymph node metastasis were compared in 40 cases of MELF and 40 cases of conventional cases of EMC. Immunohistochemical studies for CXCR4, CXCL14 and CXCL12 were performed on surgically resected tissues, qRT-PCR, western blotting and matrigel invasion assay were performed on primary and metastatic (lymph node) EMC cell lines.

Results: The median age for the patients with MELF and control was 59 and 57, respectively. G1 was 35 (87.5%) and 31 (77.5%), G2 was 5 (12.5%) and 9 (22.5%) in MELF and control, respectively. Lymphovascular invasion was present in 60% of MELF and 7.5% of control cases. Lymph node metastasis was found in 43.6% of MELF and in 2.5% of control. Strong and diffuse positive reaction of CXCR4 was found in both MELF and control. CXCL14 and CXCL12 were exclusively positive in the areas with an infiltrative growth in MELF ($p < 0.01$), but both were sporadically positive in control. CXCR4 and CXCL14 were expressed in RNA and protein levels in both primary and metastatic EMC cell lines, while CXCL12 RNA expression was not found in metastatic EMC. CXCL12 protein expression was not found in both primary and metastatic EMC. Invasion assay revealed increased invasiveness under CXCL14 and CXCL12 recombinant added medium respectively.

Conclusions: MELF pattern has aggressive invasive features associated with lymph node metastasis. CXCL14-CXCR4 and CXCL12-CXCR4 axes may play important roles in achievement of unique invasion process.

1224 SATB2 Expression Is Sensitive but Not Specific for Osteosarcomatous Components of Gynecologic (GYN) Tract Carcinosarcomas (CS): A Clinicopathologic Study of 60 Cases

Ankur R Sangoi, Malti Kshirsagar, Andrew E Horvai, Andres A Roma. El Camino Hospital, Mountain View, CA; UCSF, San Francisco, CA; Cleveland Clinic, Cleveland, OH.

Background: The novel marker Special AT-Rich Sequence Binding Protein (SATB2) is highly sensitive for mesenchymal tumors with osteoblastic differentiation. However, SATB2 expression in GYN tract CS has not been previously explored. Given the potential prognostic and therapeutic implications of heterologous CS in the GYN tract, this study investigates the utility of SATB2 in identifying osteosarcomatous elements.

Design: A multi-institution database review identified 60 cases of GYN tract CS including both heterologous and homologous types. Clinicopathologic parameters were recorded. Nuclear SATB2 immunoreactivity was scored from 1 representative whole-slide section from each case.

Results: 60 GYN tract CS were identified (uterine corpus=47, ovary=11, fallopian tube=1, cervix=1) and included 32 heterologous type (7 osteosarcoma, 3 mixed osteosarcoma/chondrosarcoma, 6 chondrosarcoma, 12 rhabdomyosarcoma, 4 mixed chondrosarcoma/rhabdomyosarcoma) and 28 homologous type. Patient ages ranged from 41 to 90 years (average 67.9 years). FIGO stage at diagnosis included 1A (n=11), 1B (n=9), 1C (n=2), 2 (n=4), 3A (n=4), 3B (n=3), 3C (n=8), 3C1 (n=10), 3C2 (n=4), 4A (n=3), 4B (n=2). Mostly diffuse strong SATB2 positivity was present in 10/10 (100%) of cases containing osteosarcoma. In these cases, SATB2 positivity was seen in malignant cells admixed with either osteoid or bone [3/10 (30%) of these cases additionally showed patchy weak/moderate SATB2 staining in areas of non-osteogenic sarcoma elsewhere in the same tumor]. SATB2 positivity was present in 30/50 (60%) of cases lacking osteosarcoma, predominantly as patchy moderate staining within undifferentiated sarcoma. No cases showed SATB2 positivity in chondrosarcoma or rhabdomyosarcoma components.

Conclusions: SATB2 is a highly sensitive marker for osteosarcomatous differentiation in GYN tract CS, and is also highly specific when used to differentiate osteosarcoma from chondrosarcoma and rhabdomyosarcoma elements in these tumors. However, a positive SATB2 result lacks reliable specificity for differentiating osteosarcoma from an undifferentiated sarcoma component.

1225 PD-L1 Expression Is Uncommon in Advanced-Stage Endometrial Carcinoma

Jennifer L Sauter, Rondell Graham, Jo Marie Janco, Andrea Mariani, Sarah E Kerr. Mayo Clinic, Rochester, MN; Scripps Memorial Hospital, La Jolla, CA.

Background: PD-L1 immunohistochemistry has been proposed as a biomarker predicting tumor response to PD-1 immune checkpoint inhibitor therapy. In the emerging literature, expression in both tumor cells and tumor infiltrating inflammatory cells has been described in a variety of tumors, including gynecologic cancer. PD-L1 has not been specifically investigated in a cohort of advanced stage endometrial carcinoma (ASEC), the patient population most likely to benefit from immunotherapy.

Design: Patients with ASEC (FIGO stage III or IV) were identified retrospectively. Histology was reviewed for tumor subtype, grade, quantification of tumor infiltrating

lymphocytes (TILs) (0, none; 1, 1-25%; 2, 25-50%; 3, >50%), and the presence of a Crohn's like response (CLR). IHC was performed for PD-L1 (E1L3N, Cell Signaling), CD3, CD20, and CD163. PD-L1 was assessed in the tumor compartment and in the inflammatory compartment. PD-L1 was considered positive if membranous staining was observed in $\geq 1\%$ of tumor cells or $\geq 1\%$ of total inflammatory cells.

Results: 76 ASEC patients were identified. Of these, 22 (29%) were endometrioid grade 1 or 2, 17 (22%) were endometrioid grade 3, and 37 (49%) were serous. As defined, PD-L1 expression was negative in all tumors; PD-L1 expression in $<1\%$ of tumor cells was seen in 4 cases, but this did not seem to correlate with morphologic factors. PD-L1 was positive in the inflammatory compartment (1-3% of cells) in 3 separate cases from those with focal tumor staining; all 3 tumors exhibited a CLR and had a TIL score of 1. In 28 (37%) tumors, PD-L1 was noted to stain a substantial proportion of tumor infiltrating macrophages, but did not reach the 1% threshold for positivity when all inflammatory cells were combined.

Conclusions: The utility of predictive biomarkers for immunotherapy response remains unproven in ASEC. PD-L1 immunopositivity, as defined by thresholds studied in other tumor types, is uncommon in otherwise unselected ASEC. Staining of tumor macrophages with PD-L1 may warrant further investigation. Because other biomarkers such as microsatellite instability and mutation burden have also shown promise in predicting response to immunotherapy in other tumor types, further study of PD-L1 in ASEC enriched for these phenotypes may be useful.

1226 Yolk Sac Tumor of the Ovary in Adult Women: Analysis of a Case Series

John Schoolmeester, Brigitte M Ronnett, Robert J Kurman. Mayo Clinic, Rochester, MN; The Johns Hopkins Hospital, Baltimore, MD.

Background: Ovarian yolk sac tumor (YST) in adult women is uncommon as either a pure tumor, presumably of germ cell origin, or as part of a mixed tumor comprised of YST and one or more forms of müllerian adenocarcinoma (endometrioid, serous or clear cell carcinoma) which is thought to represent divergent differentiation of a somatic-type carcinoma. Given its rarity as a pure tumor in this age group, YST is subject to misclassification, which can have therapeutic implications.

Design: Eight cases of pure YST unassociated with teratoma or müllerian adenocarcinoma were identified from the pathology files of 1 institution. All available slides and clinical data were reviewed.

Results: Two cases were in-house and 6 were consultations; diagnostic considerations, when offered, included clear cell carcinoma (3), sex cord-stromal tumor (1), sertoliform variant of endometrioid carcinoma (1) and high grade serous carcinoma (1). Patient age ranged 47-86 years (mean 54). Tumor size ranged 6.2-25 cm (mean 15; 4 right, 3 left, 1 bilateral). Preoperative serum AFP levels were known for 3 cases, ranging from 3590 IU/mL to 555,130 ng/mL. Tumors were largely characterized by a glandular growth pattern with well-formed, endometrioid-like structures containing brightly eosinophilic secretions. Cyst formation, solid nests, and sheet-like growth were other architectural patterns. Cytologically, all cases had primitive high grade nuclei of notably discordant grade relative to the well-differentiated glandular structures. Immunohistochemical analysis demonstrated AFP expression in 8 tumors analyzed (diffuse/strong in 4; patchy/strong in 3; focal/weak in 1), glypican 3 expression in 4 tumors analyzed (diffuse/strong in 2; patchy/strong in 2) and SALL4 expression in 5 tumors analyzed (diffuse/strong in 4; patchy/strong in 1). Follow-up was available for two patients, both of whom died of disease (24 months and 36 months postoperatively).

Conclusions: Pure YST of the ovary tends to occur in peri- and postmenopausal women and typically has an endometrioid-like glandular pattern which is distinguished from endometrioid carcinoma by the presence of high grade primitive nuclei which are discordant relative to the well-differentiated architecture. Recognition that YST can occur in adult women is important to avoid misclassification of this aggressive tumor as endometrioid carcinoma and allow for appropriate clinical management.

1227 Refined Characterization of Hepatoid Differentiation in Gynecologic Tract Neoplasms

Angela R Shih, Xiuli Liu, Annacarina Silva, Anna Pesci, Robert Soslow, Vikram Deshpande, Esther Oliva. Massachusetts General Hospital, Boston, MA; Cleveland Clinic, Cleveland, OH; Memorial Sloan Kettering Cancer Center, New York City, NY.

Background: Hepatoid differentiation in gynecologic tract neoplasms is uncommon but often presents a diagnostic dilemma. Differentiating between hepatoid yolk sac tumor (HYST), hepatoid carcinoma (HC), and metastatic hepatocellular carcinoma (HCC) can be difficult due to morphologic and immunohistochemical overlap. Hepatoid morphology may also be simulated by abundant oxyphilic cytoplasm, as may be seen in Müllerian carcinomas. This study aims to explore the utility of immunohistochemical markers in differentiating these entities.

Design: A cohort of 15 neoplasms with hepatoid differentiation from the ovary (n=11) and uterus (n=4) were collected. Relevant demographic and clinical information was collected when available. Immunohistochemistry for alpha-fetoprotein (AFP), Glypican-3 (Gly3), and Arginase-1 (Arg1), and in-situ hybridization for albumin were performed. Three conventional YSTs as well as 360 serous and 66 endometrioid ovarian carcinomas from tissue microarrays were also evaluated.

Results: Based on clinical and morphologic features, ovarian neoplasms were classified as follows: HYST (n=3); primary HC (n=3); and metastatic HCC (n=5). Uterine neoplasms were classified as follows: HYST (n=2); endometrioid carcinoma with YST and hepatoid areas (n=1); and HC with focal serous morphology (n=1). Ovarian HYST occurred in younger patients compared to primary HC (mean age: 19 versus 77 years), but morphologic overlap was striking. No conventional areas of YST were identified. In uterine cases (mean age: 71 years), hepatoid areas were seen adjacent to YST, endometrioid adenocarcinoma (high grade), and serous-type morphology. Among all 15 tumors, staining was positive for AFP (15/15; 100%), Gly3 (14/15; 93%), and albumin

(13/15; 87%). Staining for Arg1 was uniformly negative except for one metastatic HCC. Conventional YSTs were uniformly positive for albumin, AFP, and Gly-3, and negative for Arg1. Among ovarian serous carcinomas, 22/360 were positive for Gly3 (6%) and only 2/360 for AFP ($<1\%$); all were negative for albumin and Arg1. Among 66 ovarian endometrioid carcinomas, 1 was positive for albumin (1.5%).

Conclusions: Neoplasms with hepatoid differentiation are exceedingly rare. Albumin and AFP, but not Gly3, are helpful in confirming hepatoid differentiation in gynecologic tract tumors. However, these markers are not useful in distinguishing primary neoplasms with hepatoid differentiation from metastatic HCC. Positivity for Arg1, although rare, would favor a metastatic origin.

1228 Ovarian Endometrioid Adenocarcinomas: Morphology, Associations and Outcomes in 79 Patients

Annacarina Silva, Jennifer A Bennett, Rouba Ali-Fehmi, Sudeshna Bandyopadhyay, Esther Oliva. Dana-Farber Cancer Institute, Boston, MA; Lahey Hospital and Medical Center, Burlington, MA; Wayne State University, Detroit, MI; Massachusetts General Hospital, Boston, MA.

Background: OEC have a varied morphological spectrum. Most unusual patterns are noted from consultations; however, true incidence in daily practice as well as outcome is not well known and association with hereditary syndromes is now emerging.

Design: 79 OEC were evaluated for architecture (glandular, papillary, sex cord-like, transitional-like, microglandular-like), metaplasias (squamous, mucinous, tubal, clear cell, oxyphilic), grade, tumor infiltrating lymphocytes (TILs), peritumoral lymphocytes (PTL), lymphovascular invasion (LVI), necrosis, precursor lesions, stage, adjuvant therapy, follow-up and associations.

Results: Patients' age ranged from 38 to 81 (mean 56.1) years. 21 tumors were bilateral, 14 with synchronous uterine endometrioid carcinoma (8 G1, 6 G2, all IA). They ranged from 2.5 to 30 (mean 14) cm; 57 were solid and cystic. Predominant pattern was glandular while microglandular hyperplasia-like was least common. 36 OEC had papillae; villoglandular pattern was most common although not diffuse (31/79). Small non-villous papillae were rare (4/79). Sex cord differentiation was seen in 24% and transitional "like" pattern in 2%. Squamous metaplasia was most common. There were 28 G1, 38 G2, and 13 G3 tumors. LVI was seen in 6% and necrosis in 41% OEC. 67/79 OEC had TILs (32 had $>40/10\text{hpf}$) and only 3 tumors had dense PTLs. Endometriosis, adenofibroma and borderline tumor was noted in 65.8%, 24% and 9.7% of OECs. 48, 20, 7, and 4 tumors were stage I, II, III, and IV respectively. 53 of 65 patients received adjuvant chemotherapy. Mean follow up was 96 (range 1-286) mo; 64 patients being alive and well (25 G1, 33 G2, and 6 G3) (45, 18, and 1 stage I, II, and III respectively); 4 alive with disease (3 G2 and 1 G3) (1, 1 and 2 stage, I, II, and III); 8 died of disease (2 G2, 6 G3) (4 each stage III and IV) and 3 died of other causes. 10 patients had breast cancer (BRCA mutation negative in 4 OEC), 2 colonic carcinoma (one confirmed Lynch Syndrome), and pancreatic carcinoma, pulmonary non-small cell carcinoma, nasopharyngeal carcinoma, renal oncocytoma, adrenal cortical adenoma in 1 each. 4 additional patients had colonic tubular adenomas. OEC was the first malignancy in both patients with colon and in 4 with breast cancer.

Conclusions: Overall, OECs are associated with good outcome as they often present at stage I. Unusual morphologies are uncommon with apparently very low association with Lynch Syndrome.

1229 Inter-Observer Agreement in Assessment of Response to Neo-Adjuvant Chemotherapy in Tubo-Ovarian High-Grade Serous Carcinoma

Naveena Singh, Ian Said, Asma Z Faruqi, Sarah L Leen, Georgia Trevisan, Lynn Hirschowitz, Raji Ganesan, Jo Vella, Glenn McCluggage, Blake Gilks, Steffen Boehm. Bart's Health NHS Trust, London, United Kingdom; University College Hospital, London, United Kingdom; Birmingham Women's Hospital, Birmingham, United Kingdom; Royal Victoria Hospital, Belfast, United Kingdom; Vancouver General Hospital, Vancouver, Canada.

Background: The chemotherapy response score (CRS) stratifies tubo-ovarian high-grade serous carcinoma (HGSC) patients into different prognostic groups as determined by progression-free and overall survival, providing opportunities for early treatment modulation. CRS is assessed on omental sections from interval debulking surgery specimens after neo-adjuvant chemotherapy for HGSC.

CRS	Criteria
1	Mainly viable tumour with minimal regression limited to a few foci
2	Multifocal or diffuse regression ranging from viable tumour in sheets, streaks or nodules, to extensive regression with multifocal residual tumour which is easily identifiable.
3	Complete or near-complete response with no residual tumour OR minimal irregularly scattered tumour foci seen as individual cells, cell groups or nodules up to 2mm in maximum size

We sought to determine inter-observer agreement in CRS assignment.

Design: After online training (<http://www.gpecimage.ubc.ca/aperio/images/crs>), all omental sections (4-10 slides) from 40 cases were scored independently by 15 study pathologists, 3 from each of 5 categories: original study pathologists, junior trainees, senior trainees, new consultants (<2 years since appointment) and experienced gynecological pathologists (>15 years' specialist experience). Interobserver agreement was assessed within and between groups.

Results: Kappa scores, Kendall's coefficient of concordance and absolute agreement for the different groups and overall are shown below.

Group	Kappa score	Kendall's coefficient of concordance	Absolute agreement (%)	P value
Original	0.901	0.951	92.5	<0.0001
Trainees (J)	0.791	0.958	81.6	<0.0001
Trainees (S)	0.806	0.952	82.5	<0.0001
Consultants (J)	0.932	0.973	94.7	<0.0001
Consultants (S)	0.547	0.846	62.5	<0.0001
Overall (majority)	0.853	0.974	84.7	<0.0001
Overall (individual)	0.761	0.909	47.0	<0.0001

Conclusions: CRS assignment is highly reproducible amongst pathologists, irrespective of experience. This allows uniform treatment response evaluation applicable in routine clinical and trial settings.

1230 Vulvovaginal Smooth Muscle Tumors

Shahrazad Slater, Jesse Hart, Maria Garcia-Moliner, Ali Amin. Women and Infants Hospital, Providence, RI; Rhode Island Hospital, Providence, RI; Warran Alpert Medical School of Brown University, Providence, RI.

Background: Vulvovaginal smooth muscle tumors (VSMT) are rare soft tissue lesions with histopathology that closely resembles smooth muscle tumors in the uterus; however, the histologic criteria which predict recurrent potential is stricter for soft tissue genital sites compared to the uterus. Nucci et al propose that infiltrative margin, nuclear atypia, & any mitotic activity should elicit the diagnosis of "atypical smooth muscle tumor" as these lesions may recur late (Nucci Histopath. 2000; v. 36). To examine these criteria, we evaluated VSMTs from 5 Rhode Island (RI) hospitals.

Design: The pathology archives of 5 RI hospitals were evaluated from the system start date (1986 for 3 hospitals & 2007 for 2 others) through 2014 for VSMTs. The original slides, histopathologic features & clinical information available in the EMRs were reviewed by the authors. This study was approved by appropriate IRBs.

Results: Of over 980,000 cases searched, 20 cases of vaginal leiomyoma (VaLM), 2 of vulvar leiomyoma (VuLM), 7 of atypical smooth muscle tumor (aSMT), & no cases of leiomyosarcoma were identified. 5 cases (14%) had confirmatory IHC performed. All cases were solitary and well-circumscribed. 2 cases (6%) were not excised. 7 were prolapsed from the uterus (uLM). 6 of the 7 aSMT cases were originally designated leiomyomas, but are aSMT based on Nucci criteria (one vulvar, the rest vaginal). No cases recurred in the follow up period of up to 14 years. See Table 1 for further results. Table 1. Summary of VSMT Features

Lesion	No.	Age (mean)	Size; cm (mean)	Ulceration	Hypercellular	Mitosis >1/10HPF	Nuclear atypia	Follow up; mo (mean)
VaLM	20	36-66 (47)	0.6-9 (3.4)	2 (10%)	5 (25%)	0 (0%)	0 (0%)	0-220 (52)
VuLM	2	44-49 (47)	1.4-1.4 (1.6)	0 (0%)	0 (0%)	0 (0%)	0 (0%)	4-14 (9)
uLM	7	34-83 (49)	1.8-10 (5.9)	1 (14%)	1 (14%)	0 (0%)	0 (0%)	0-87 (23)
aSMT	7	36-51 (44)	2.9-10 (5.9)	3 (43%)	5 (71%)	6 (86%)	3 (43%)	0-93 (16)

Conclusions: VSMTs are rarely encountered in practice & have not recently been studied systematically. Of the lesions encountered, 19% were aSMTs & while the follow up is relatively short, none recurred. Therefore further evaluation of the criteria is warranted. Practicing pathologists should be aware of VSMTs & their differences from corpus SMTs (including prolapsing tumors) as the current diagnostic criteria is strict.

1231 Mucinous Differentiation with Tumor Infiltrating Lymphocytes Is a Feature of Sporadically Methylated Endometrial Carcinomas

Emily A Sloan, Christopher A Moskaluk, Anne M Mills. University of Virginia, Charlottesville, VA.

Background: Defects in the DNA mismatch repair (MMR) system are identified in ~30% of endometrial carcinomas (ECs). While some are due to germline Lynch Syndrome (LS)-associated mutations in MMR genes (*MLH1*, *PMS2*, *MSH2*, or *MSH6*), the majority demonstrate sporadic hypermethylation of the *MLH1* promoter with subsequent loss of *MLH1* and *PMS2*. *MLH1* promoter hypermethylation characterizes a unique histologic subset of colorectal cancers with a relatively poor prognosis; however the histopathologic features and behavior of sporadically methylated endometrial carcinomas (SMECs) are less well understood.

Design: Departmental files were searched for *MLH1*/*PMS2*-deficient ECs identified on universal MMR-immunohistochemical (IHC) screening from 1/2013-9/2015. Cases with PCR-confirmed *MLH1* promoter hypermethylation were assessed for histologic type, FIGO grade, stage, tumor location, biphasic/de-differentiation, mucinous differentiation, and tumor infiltrating lymphocytes (TILs); the latter 3 features were compared to a previously defined series of 26 LS-associated ECs.

Results: 52 cases of endometrial carcinoma with dual *MLH1*/*PMS2* loss were identified, representing 20% (52/256) of all cases tested. 20 cases were evaluated for *MLH1* promoter hypermethylation and all were positive. Most SMECs were located in the uterine fundus (85%, 17/20) and the majority displayed Grade 1 (45%, 9/20) or Grade 2 (45%, 9/20) endometrioid morphology. Dedifferentiation was rare (5%, 1/20). Mucinous differentiation was present in 50% of cases (10/20). TILs were present in

60% (12/20) of SMECs, and in 90% (9/10) of those with mucinous differentiation. A subset of LS-associated ECs showed biphasic/de-differentiation (23%, 6/26) and TILs (23%, 6/26), but mucinous differentiation was rare (4%, 1/26). The majority of SMECs presented at a low stage (85%, 17/20). Of the 3 cases presenting at high stage, 1 had mucinous differentiation, and 2 had associated TILs.

Conclusions: Dual *MLH1*/*PMS2* loss was frequently observed in MMR-deficient ECs. *MLH1* promoter hypermethylation was present in all tested cases, supporting a sporadic origin. In contrast to LS-associated ECs, SMECs commonly showed mucinous differentiation and TILs, but rarely demonstrated biphasic or dedifferentiated morphologies. These results suggest histopathologic distinctions between SMECs and other MMR-deficient cancers. A larger study is needed to further define these features and the potential prognostic significance of different molecular signatures.

1232 Frequent Homozygosity in Both Mature and Immature Ovarian Teratomas: A Shared Genetic Basis of Tumorigenesis

Olivia L Snir, Maura DeJoseph, Natalia Buza, Pei Hui. Yale University School of Medicine, New Haven, CT; Office of the Chief Medical Examiner, Farmington, CT.

Background: It is believed that teratomas are of germ cell origin and often demonstrate partial or complete homozygosity – a phenomenon rare in neoplasia and supportive of the theory of their origin from a germ cell that has undergone the first meiotic division. Although homozygosity is well documented in mature teratomas, the genetic zygosity of immature teratomas is less well studied.

Design: Ten cases of mature ovarian teratomas and seventeen cases of immature ovarian teratomas were retrieved from our departmental archives and reviewed. Target tumor tissue and paired nonneoplastic normal tissue were microscopically dissected for short tandem repeat (STR) genotyping.

Results: All mature teratomas were classic mature cystic teratomas with the patients' age ranging from 16 to 67 years. Immature teratomas had an age range from 9 to 48 years and tumor grade ranging from G1 to G3. Six of the immature teratomas contained additional tumor types including yolk sac, clear cell carcinoma, embryonal, and choriocarcinoma. Of the mature teratomas, 5 cases showed partial or complete homozygosity (63%) with 2 cases demonstrating complete homozygosity (25%) (Table 1). Of the immature teratomas, 9 cases showed partial or complete homozygosity (75%) with 2 cases demonstrating complete homozygosity (17%). Additionally, homozygosity was present in immature teratomas both with and without other tumor components.

Conclusions: Both immature and mature teratomas demonstrate frequent genetic homozygosity, implying a shared cellular origin involving germ cells at the same developmental stage.

Teratoma Type	Heterozygous	Partial Homozygosity	Complete Homozygosity	Percentage with Homozygosity
Mature	3	3	2	5/8*=63%
All Immature Cases	3	7	2	9/12*=75%
Immature Alone	1	4	2	6/7=86%
Immature + Other Components	2	3	0	3/5=60%
Total	6	10	4	14/20=70%

*The total case numbers are less than the initial number due to PCR amplification failure.

1233 Inactivating BAP1 Mutations Causing Loss of Nuclear Expression Define the Majority of Malignant Peritoneal Mesotheliomas

David A Solomon, Yunn-Yi Chen, Charles Zaloudek, Nancy Joseph. University of California, San Francisco, San Francisco, CA.

Background: Malignant mesothelioma is a rare cancer that arises from the mesothelial cells that line the pleural cavity and less commonly in other body cavities including the peritoneum. Most pleural mesotheliomas arise in patients with a history of asbestos exposure, whereas peritoneal mesotheliomas do not have well described carcinogens or risk factors. Genomic analysis has defined the spectrum of molecular alterations that drive pleural mesothelioma including *CDKN2A* deletion (>50% of cases), *NF2* mutation (~40% of cases), and *BAP1* mutation (~30% of cases). In contrast, the recurrent genetic alterations which drive peritoneal mesotheliomas remain unidentified.

Design: Targeted next-generation sequencing of >500 cancer-associated genes was performed on 9 malignant peritoneal mesotheliomas and matched normal tissue. Average read depth was approximately 500x. Immunohistochemistry for *BAP1* was performed on these 9 malignant peritoneal mesotheliomas, 7 well-differentiated papillary mesotheliomas (WDPM) of the peritoneum, and 12 peritoneal metastases of low grade serous carcinoma of the ovary (LGSCO).

Results: Somatic biallelic inactivating mutations or homozygous deletions of the *BAP1* gene on chromosome 3p were identified in 7 of the 9 malignant peritoneal mesotheliomas. Loss of nuclear staining for *BAP1* protein was seen in each of these seven malignant peritoneal mesotheliomas and in no WDPM of the peritoneum or peritoneal metastases of LGSCO. In all cases with *BAP1* loss, retained expression was present in non-neoplastic stromal and endothelial cells.

Conclusions: These studies identify inactivating mutations of *BAP1* as the most frequent genetic alteration in peritoneal mesotheliomas identified to date and suggest that *BAP1*-mediated transcriptional deregulation is a key oncogenic mechanism in mesothelial tumorigenesis. The resulting loss of *BAP1* nuclear expression is a helpful biomarker for the pathologic identification of malignant peritoneal mesotheliomas, as intact *BAP1* expression was seen in all cases of potential histologic mimics such as WDPM and peritoneal metastases of LGSCO.

1234 Serial Sectioning and TP53 Sequencing of Occult Intraepithelial Lesions in Distal Fallopian Tubes: Implications for the Origin of High-Grade Ovarian Serous Carcinoma

Thing Rinda Soong, Brooke E Howitt, Helena M Ditzel, Alexander Miron, Frank Campbell, Christopher P Crum. Brigham and Women's Hospital, Boston, MA; Case Western Reserve University, Cleveland, OH; Covariance Biosciences, Cleveland, OH.

Background: The distal fallopian tube (DFT) has been proposed as an origin of pelvic high-grade serous carcinoma (HGSC) based on the presence of serous tubal intraepithelial carcinoma (STIC) in ~50% of HGSCs. A fundamental question is whether STIC-negative (STICn) HGSCs have specific tumor features or histologically occult tubal precursors. To address this question, we compared the morphologies between STIC-positive (STICp) and STICn HGSCs. We also serially sectioned a cohort of DFTs initially diagnosed as STICn in HGSC resections to identify previously occult STICs and tubal intraepithelial lesions with atypia (TILAs), and characterized the genetic link of TILAs to HGSC in the same resections by comparing their *TP53* mutation profiles. **Design:** Extrauterine HGSC resections done at our institution during 2009-2015 were retrospectively reviewed. Paraffin blocks of initially STICn DFTs (n=32) with no tubal mucosal carcinoma or prior neoadjuvant therapy were serially sectioned to exhaustion without wash levels for examination. DNA extracted from TILAs found after extensive sectioning was tested using a multiplexed PCR platform with barcoded primers to amplify and sequence all coding regions of *TP53* on a MiSeq instrument. Findings were compared between TILAs and HGSC samples submitted from the same resections. Clinicopathologic features were also compared between STICn cases (n=26) and a random selection of STICp HGSC resections (n=28).

Results: A hundred and ten of 515 (21%) extrauterine HGSC resections were STICp. No difference was observed between STICn and STICp HGSCs regarding clinical stage, pattern of ovarian involvement and tumor morphology. DFTs in 32 STICn cases were serially sectioned, revealing DFT abnormalities in 44% (14/32) of cases, including mucosal carcinoma (6%), STICs (6%), and TILAs (37%) of which 54% were positive for p53 on immunostain. Identical *TP53* mutation profiles were seen between TILAs and HGSC in the same resections in 25% (3/12) of cases.

Conclusions: Serial sectioning of DFTs uncovers a putative DFT origin (STICs and TILAs) in a subset of HGSCs that were initially classified as STICn. *TP53* sequencing confirms a definite genetic link between at least a portion of TILAs and HGSC, underscoring the potential role of TILAs as direct tumor precursors that were previously under-appreciated in STICn HGSCs.

1235 The Cancer Genome Atlas-Based Molecular Classifier Identifies Prognostically Significant Subgroups of Grade 3 Endometrioid Carcinoma of the Endometrium

Robert Soslow, Blake Gilks, Douglas A Levine. Memorial Sloan Kettering Cancer Center, New York, NY; Vancouver General Hospital, Vancouver, Canada.

Background: The Cancer Genome Atlas survey of endometrial carcinomas identified four genomic subtypes: POLE mutant (favorable prognosis), high copy number alterations or CNH (poor prognosis) and tumors with microsatellite instability (MSI) or low copy number alterations (CNL), both of which have an intermediate prognosis. We hypothesized that grade 3 endometrioid carcinomas of endometrium could be subclassified into prognostically significant groups using a TCGA-based molecular classifier.

Design: 192 cases diagnosed as grade 3 endometrioid carcinoma (EC) were subclassified based on POLE exonuclease domain hotspot mutation, p53 immunostaining and mismatch repair protein immunohistochemistry (MMR, a marker of MSI). Tumors with p53 aberration lacking POLE mutation and aberrant MMR were categorized as CNH and those with physiological p53 staining were categorized as CNL provided they lacked POLE exonuclease domain hotspot mutations and had intact mismatch repair.

Results: There were 23 POLE mutant, 36 CNH, 55 CNL and 78 MSI tumors. Patients with POLE mutant grade 3 EC have a significantly better prognosis (relative risk 0.060) than those with CNL (relative risk 1), MSI (relative risk 0.67) or CNH (relative risk 1.5) grade 3 EC (p=0.0004) when considering disease specific survival. The CNH tumors show a trend to a worse prognosis, that does not reach statistical significance (95% confidence interval for relative risk 0.73 – 3.1).

Conclusions: Grade 3 ECs are a mix of molecular subtypes of EC, rather than a homogeneous group, and subclassification into TCGA-based molecular subtypes is of prognostic significance.

1236 Immunohistochemical Characterization of Endometrial Carcinomas Grouped by the TCGA Molecular Classification Scheme

Robert Soslow, Lien Hoang, Angela Cheng, Maria Bisogna, Narciso Olvera, Jessica N McAlpine, David G Huntsman, Douglas A Levine, Blake Gilks. Memorial Sloan Kettering Cancer Center, New York, NY; Genetic Pathology Evaluation Center, Vancouver, BC, Canada; University of British Columbia, Vancouver, BC, Canada.

Background: While the immunohistochemical phenotype of histologically defined subgroups of endometrial carcinomas is well described, there exists limited information on the immunohistochemical characteristics of endometrial carcinomas defined by the TCGA classification scheme. We performed an immunohistochemical survey on endometrial carcinomas that have been previously molecularly categorized using a panel of markers that have been reported to be useful in histotype discrimination (ARID1A, PTEN, IMP3) and prognostication (ER, HER2, ZEB1, Stathmin).

Design: A series of endometrial carcinomas from Vancouver General Hospital were categorized into four molecular groups (MSI, POLE, CN-L, CN-H) analogous to the TCGA classification. Tissue microarrays were constructed encompassing 362

endometrial carcinomas. Immunohistochemical stains were assessed as follows: PTEN and ARID1A – retained or loss, ER – positive or negative, HER2 – positive if 3+ staining, IMP3, Stathmin, and ZEB1 – positive if strong intense staining.

Results: The immunohistochemical results are summarized in Table 1. Loss of ARID1A and PTEN were highest in the MSI and CN-L groups. Stathmin and IMP3 were lowest in the CN-L group and IMP3 was highest in the CN-H group.

Table 1. Immunohistochemical characteristics of endometrial carcinomas stratified into 4 groups based on the TCGA molecular classifier.

	ARID1A*	PTEN*	ER	HER2	ZEB1	Stathmin	IMP3
MSI	45/60 (55%)	28/84 (33%)	68/84 (81%)	0/84 (0%)	4/107 (4%)	20/84 (24%)	36/67 (35%)
POLE	7/25 (28%)	3/23 (13%)	18/23 (78%)	0/23 (0%)	2/36 (6%)	6/23 (26%)	16/36 (44%)
CN-L	32/99 (32%)	40/77 (52%)	63/77 (82%)	0/77 (0%)	4/161 (2%)	7/77 (9%)	15/154 (10%)
CN-H	4/41 (10%)	11/48 (23%)	34/48 (71%)	3/48 (6%)	2/58 (3%)	12/48 (25%)	34/54 (63%)

*Values are for ARID1A and PTEN loss of expression; All other values depict positive staining / overexpression

Conclusions: The immunohistochemical phenotype of endometrial carcinomas in each TCGA group is different, although considerable overlap is apparent. These patterns may also reflect histotype distribution. Further studies are needed to determine if these patterns correlate with clinical outcome.

1237 Uterine Smooth Muscle Tumor of Uncertain Malignant Potential: Clinicopathologic Study of 45 Cases

Sucheta Srivastava, Laura Moench, Teri A Longacre. Stanford Hospital, Stanford, CA.

Background: Uterine smooth muscle tumor of uncertain malignant potential (STUMP) encompasses a group of smooth muscle tumors that cannot be unequivocally diagnosed as benign or malignant. Data are limited concerning recurrent potential and long term clinical follow up.

Design: The surgical pathology archives at a single institution were reviewed from 2005 to 2015 for diagnoses of uterine “STUMP”. The severity of cytologic atypia, cellularity, mitotic index, type of necrosis (coagulative, hyaline/ischemic, or uncertain), cell morphology (epithelioid vs. spindle vs. myxoid) and status of tumor margins with adjacent myometrium or adhesion to adjacent organs were recorded. Medical records were reviewed for patient age, hormone use, tumor size, number and location within the female genital tract, surgical procedure, therapy, and follow-up.

Results: 45 STUMPs with available slides were identified. Patient age ranged from 29 to 81 years (mean 49). Follow up ranged from 5 to 180 months (mean 41). The most common reason for STUMP diagnosis was diffuse moderate to severe atypia (21/45), accompanied by 5-9MF/10HPF in 9 cases and necrosis of uncertain type in 5 cases. Epithelioid morphology was the second most common finding (14 cases), accompanied by <5MF/10HPF and/or cytological atypia. Six neoplasms had myxoid features accompanied by mitosis of <2MF/10HPF in all cases and focal severe atypia in 2.

9 patients (20%) developed recurrent disease at 12 to 90 months (mean 38). 5 had epithelioid histology accompanied by necrosis of uncertain type in 3 cases (1 also with diffuse severe atypia), diffuse severe atypia in 1 case and <5MF/10HPF with increased cellularity in one case. 3 had diffuse severe atypia and 5-9MF/10HPF. One had increased cellularity and severe atypia. One patient developed intrauterine recurrence at 20 months following myomectomy. Two patients developed pelvic recurrences at 24 and 43 months; 4 developed abdominal recurrences at 12, 17, 25, and 90 months; and two developed lung metastasis at 28 and 84 months. One had a second abdominal recurrence at 34 months. Eight of nine patients had history of either morcellation or myomectomy at the time of initial diagnosis. No patient succumbed to disease in the follow up period.

Conclusions: STUMPs may recur in the pelvis, abdomen, or lungs, particularly following morcellation. STUMP with epithelioid histology accompanied by either atypia or necrosis of uncertain type is the most common STUMP to recur. As most recurrent STUMPs in this series were associated with previous morcellation, seeding secondary to abdominal spillage cannot be excluded.

1238 The Use of Immunohistochemistry in Distinction between Clear Cell and Squamous Differentiation in Adenocarcinoma of the Endometrium

Michelle Stram, Dinesh Pradhan, David Dabbs, Rohit Bhargava, Agnieszka Onisko, Mirka W Jones. University of Pittsburgh, Pittsburgh, PA.

Background: Endometrial endometrioid adenocarcinoma often shows admixture of other histologic types, like squamous or clear cell. While the presence of squamous differentiation does not alter prognosis or recurrence rate, the finding of clear cell component implies a more aggressive behavior. Areas of clear cell morphology in squamous component of endometrioid adenocarcinoma are often difficult to distinguish from a true clear cell carcinoma, since squamous component may mimic its solid pattern. We analyzed immunohistochemical differences between squamous differentiation and clear cell differentiation in endometrioid carcinoma and compared them with clear cell carcinoma.

Design: 56 endometrioid adenocarcinomas with clear cell differentiation (ECCD) and with squamous differentiation (ECS) and clear cell carcinomas (CCC) of endometrium were identified in retrospective surgical pathology database search of academic medical center from 2007 to 2014. Representative sections immunostained with ER, PR, CK5, p63, HNF-1 β and p53 were evaluated by two pathologists. Immunohistochemical staining was graded semi-quantitatively using H score method. Positive immunostaining

was defined as H score 10 or higher for all antibodies except p53 which was defined as H score of 150 or higher. Statistical analysis with Kruska-Wallis test was performed using H score.

Results: The squamous and clear cell differentiation in endometrioid adenocarcinoma have different immunohistochemical profiles. Immunoreexpression of CK5, p63 and HNF-1 significantly differs between ECCD and ECSD (p values of 0.000043, 0.015883, 0.029031 respectively) and between ECSD and CCC (p values of 0.000000, 0.000045, 0.000000 respectively). There is no significant difference in ER and PR expression between squamous and clear cell differentiation and between clear cell carcinoma and areas of squamous differentiation in endometrioid carcinoma, both markers being negative or weakly positive.

	ECCD	ECSD	CCC
ER	11/16 (68.8%)	11/23 (47.8%)	1/17 (5.9%)
PR	6/16 (37.5%)	0/23 (0.0%)	0/17 (0.0%)
CK5	11/16 (68.8%)	23/23 (100.0%)	8/17 (47.1%)
P63	5/16 (31.3%)	18/23 (78.3%)	0/17 (0.0%)
HNF-1	12/16 (75.0%)	8/23 (34.8%)	17/17 (100.0%)
P53	2/16 (12.5%)	0/23 (0.0%)	8/17 (47.1%)

Conclusions: A combined panel of CK5, p63, and HNF-1 helps in distinction between squamous and clear cell differentiation in endometrioid adenocarcinoma. Clear cell carcinoma and clear cell differentiation in endometrioid carcinoma share a similar immunohistochemical profile.

1239 The Clinicopathologic and Immunohistochemical Features of Adenomyomatous Polyps

Kyle C Strickland, Bradley J Quade, Marisa R Nucci, Brooke E Howitt. Brigham and Women's Hospital, Boston, MA.

Background: Adenomyomatous polyps (APs) of the uterus (aka polypoid adenomyomas and pedunculated adenomyomas) are exophytic polyps composed of myomatous stroma admixed with glands and may be mistaken for more worrisome entities. To date, APs have been the subject of only a few case reports, and its clinicopathologic features are not well characterized.

Design: Our pathology database was searched (2000-2015) to retrospectively identify APs. Cases with available material were evaluated for the following morphologic features: stromal cellularity, pattern of myomatous features (type 1: vaguely fascicular myomatous stroma intimately admixed with glands; type 2: well-defined fascicles with a hamartomatous appearance, predominantly in the stalk of the polyp but also entrapping glands). Immunohistochemistry (IHC) for CD10, desmin, and caldesmon was performed. Clinical data was obtained from the medical record. For cases seen in consultation, the referring pathologists' favored diagnoses were recorded.

Results: APs were seen in consultation ~10 times per year (2007-2015, n=76) and were associated with a broad differential diagnosis that included adenocarcinoma (13), endometrial neoplasia/carcinoma (7), endometrial stromal tumor (6) and atypical polypoid adenomyoma (4). The in-house cohort included 89 patients (age 27 to 89 years, mean 51 years) with histologically-confirmed APs (average size 2.4 cm, range 0.4 to 10.2 cm). 58% (52/89) presented with abnormal uterine bleeding, and, clinically, 22% (20/89) of polyps were thought to represent submucosal leiomyomas. By H&E review, we identified 51 type 1 APs, 34 type 2 APs, and 4 polyps with mixed features. For cases with tissue blocks available, CD10 was positive at least focally in all specimens examined (n=77), and 91% (70/77) stained strongly positive for desmin. Of type 2 APs, 97% (28/29) were positive for caldesmon while only 6.8% (3/44) of type 1 APs had more than focal caldesmon positivity. A subset of type 1 APs (11%, 5/44) were desmin negative.

Conclusions: This study represents the first comprehensive clinicopathologic and immunohistochemical characterization of adenomyomatous polyps. They are not uncommon in routine diagnostic practice and may be misinterpreted as a more worrisome lesion. The majority of patients with APs present with abnormal uterine bleeding, and APs can be mistaken for submucosal leiomyomas on ultrasound or hysteroscopic examination. The lack of caldesmon positivity suggests that a subset of cases classified as adenomyomatous on H&E may represent endometrial polyps with cellular endometrial stroma.

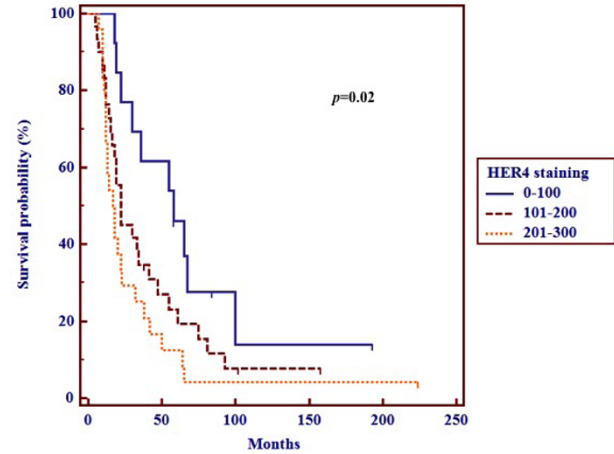
1240 HER4 Expression and Overall Survival in Ovarian Serous Carcinoma

Carolina Strosberg, Robert M Wenham, Ardeshr Hakam, Anthony M Magliocco, Ozlen Saglam. Moffitt Cancer Center, Tampa, FL.

Background: The human epidermal growth factor (HER) receptor family is extensively involved in carcinogenesis. While the prognostic impact of HER1 (EGFR) and HER2/neu has been characterized in numerous cancers, there is little data on the role and prognostic/predictive impact of HER4 in ovarian cancer.

Design: Levels of HER4 expression were evaluated in a tumor microarray (TMA) consisting of 177 tissue samples including 100 ovarian serous carcinoma (OSC) specimens (50 complete responders (CR) and 50 incomplete responders (IR) to platinum-based chemotherapy), 51 tissue samples from normal, non-neoplastic ovarian and fallopian tube control, and 16 platinum resistant cell lines (PRCL). Levels were scored by "H"-score. Expression scores were arbitrarily classified into 'low' (0-100), 'intermediate' (101-200) and 'high' (201-300) categories. Category frequencies were compared between tumor specimens versus controls using chi-square methodology. Among tumors, category frequencies were compared between CR and IR to chemotherapy; and overall survival (OS) was stratified by category and compared using Kaplan-Meier methodology.

Results: In total, 74 OSC (32 CR and 42 IR), 28 normal control and 16 PRCL specimens were evaluable. The median years of age at diagnosis was 62. High-level HER4 cytoplasmic and nuclear expression (201-300) was observed at a significantly higher frequency in OSC versus normal tissue controls, whereas low-level expression (0-100) was seen at significantly higher frequency in control specimens (p=0.001). Among tumor specimens, HER4 expression was significantly higher in patients with IR to chemotherapy versus CR (p=0.04). OS was inversely correlated with HER4 expression levels, with a median OS of 18 months (95% CI 12-23) among high-expressing tumors, 22 months (16-14) among intermediate expressing tumors, and 58 months (30-100) among low-expressing tumors. No difference was observed between small number of PRCL and OSC specimens.



Conclusions: HER4 expression by immunohistochemistry appears to correlate with chemotherapy-resistant phenotype of OSC, and with shortened survival. Further studies are needed to confirm the role of HER4 as a prognostic and predictive marker in OSC.

1241 Dedifferentiated Endometrial Carcinoma - A Clinicopathologic Study of 5 Cases

Hongying Tan, Chisa Aoyama. Olive-View UCLA Medical Center, Sylmar, CA.

Background: Dedifferentiated endometrial carcinoma (DEMC) is a recently characterized entity with a highly aggressive clinical behavior. It tends to be under-recognized and misdiagnosed as endometrioid carcinoma, FIGO grade II-III, due to coexistence of low-grade endometrioid and undifferentiated carcinoma. An association with Lynch syndrome has also been proposed, most reported to be loss of MLH1 and PMS2.

Design: Five cases of DEMC between 2012-2015 in our institution are reevaluated for the clinicopathologic features, histologic and IHC findings, including CK AE1/AE3, CK18, PAX8, ER/PR, Vimentin, E-cadherin, p53, c-Myc, Cyclin D1, CD117 and MSI proteins (MLH1, PMS2, MSH2, and MSH6).

Results: The age at onset ranges from 36 to 64 years old, with an average of 51.2 years old. All patients presents with advanced stage at onset (>= stage 3a). Histologically the tumor shows abrupt transition from well-differentiated endometrioid carcinoma to completely undifferentiated carcinoma. The amount of undifferentiated component ranges 25-70%. Tumor involvement of lower uterine segment, lymph node metastasis, and lymphovascular invasion are frequently found. 3 of 5 cases demonstrate MSI, all with loss of MLH1 and PMS2, secondary to hypermethylation of MLH1 (sporadic MSI). Comparison of IHC results of undifferentiated to those of differentiated component reveals: 1) frequent loss of epithelial markers; 2) loss of lineage specific markers PAX 8 and ER/PR; 3) stronger p53, c-Myc, Cyclin D1 and CD117 expression; 4) higher proliferation index; 5) partial loss of cell adhesion protein E-cadherin.

Conclusions: The unique features of DEMC, such as advanced stage at presentation, aggressive clinical behavior and frequent association with MSI are confirmed. In our study, MSI is due to hypermethylation (sporadic) in all 3 cases. Undifferentiated component demonstrates loss of epithelial and lineage specific markers, progressive gaining of genetic abnormalities, high proliferation rate, and partial loss of cell adhesion molecule E-cadherin, which may be associated with epithelial-mesenchymal transition.

1242 False Negative Endometrial Sampling in Patients with Endometrial Carcinoma

Catalin Taraboanta, Heidi Britton, Blake Gilks. University of British Columbia, Vancouver, BC, Canada.

Background: Endometrial cancer is the most common gynecological, and the fourth most common cancer in women. Outpatient endometrial sampling is highly accurate in diagnosing endometrial cancer, if an adequate sample is obtained. A negative result however is less reassuring with a post-test probability for endometrial cancer of 0.9% (95% CI: 0.4% - 2.4%). Our goal was to determine: false negative rate and sensitivity of endometrial sampling in patients with endometrial carcinoma from our region.

Design: In a retrospective cross-sectional design, we identified all hysterectomies with pathology reported between February 2013 and May 2015 in our regional anatomical pathology data base, by querying the terms "carcinoma", "adenocarcinoma" or "hyperplasia" in the final diagnosis. Cases of primary ovarian, cervical, or fallopian tube carcinoma, metastatic carcinomas, outside consultations and cases with no endometrial sampling were excluded. The cases identified were then cross-referenced with patient's

endometrial sampling results, reported up to five years prior to hysterectomy. We defined negative endometrial samples as either benign or non-diagnostic, excluding cases of atypical hyperplasia and those where follow-up sampling was recommended. **Results:** We reviewed 1,330 pathology reports and identified 931 cases of hysterectomy for endometrial carcinoma or atypical hyperplasia. In 119 cases there was a previous negative biopsy: 92 benign and 27 non-diagnostic. Out of these, 98 (82%) cases were diagnosed as endometrioid adenocarcinoma, 6 (0.5%) serous carcinoma, and 13 (10%) atypical hyperplasia on the hysterectomy specimen. The median time between negative biopsy and hysterectomy was 163 days (IQR: 84 – 547) and FIGO stage was 1 in 67%, 2 in 23% and 3 in 10% of carcinoma cases. A total of 11,787 negative endometrial biopsies were reported in our region between February 2013 and May 2015. The false negative rate (miss rate) was 12.7% for carcinoma or atypical hyperplasia. Calculated sensitivity was 87.2% with a post-test probability of endometrial cancer, given a negative endometrial sample, of 1.0%.

Conclusions: Our findings are comparable with those published more than a decade ago. There remains a significant lack of sensitivity with outpatient endometrial sampling in the diagnosis of endometrial malignancy and pre-malignancy; both pathologists and primary care physicians should be aware of this.

1243 Application of Triage Markers for Management of HPV Positive Women Presenting at Colposcopy with Minor Cytological Abnormalities

Prerna Tewari, Christine White, Lynne Kelly, Padraig Kearney, Loretto Pilkington, Tom D'Arcy, Cliona Murphy, Nadine Farah, Eimear Lee, Dorinda Mullen, Jacqui Barry-O'Crowley, Sharon O'Toole, Linda Sharp, John O'Leary, Cara Martin. Trinity College, Dublin, Ireland; Coombe Women & Infants University Hospital, Dublin, Ireland; Newcastle University, Newcastle, United Kingdom.

Background: HPV DNA (test of risk) has improved the management of cervical disease. However, due to the high prevalence of transient HPV infections, the specificity of HPV DNA testing is limited. In this study we evaluated alternative approaches; HPV 16/18 genotyping, HPV mRNA testing, p16/Ki67 expression and cytology to triage HPV positive cases presenting in colposcopy.

Design: Patients were recruited through the Colposcopy clinic in the Coombe Womens & Infants University Hospital, Dublin, Ireland, following a referral for abnormal smears. A smear sample was taken for cytological evaluation and the residual sample was tested with the Cobas HPV DNA test, Aptima mRNA test and CINtec PLUS (p16/Ki67). Clinical performance of the assays was evaluated with reference to histological diagnosis.

Results: 896 women were tested, of which 67% were HPV DNA positive. Clinical sensitivity and specificity for detection of CIN2+ was 89.5% and 54.3% for the Cobas test and 88.5% and 60.0% for the Aptima test in women referred with minor abnormalities (n = 300). We also applied the data to model the potential to reduce colposcopy referral rate following HPV DNA/ mRNA testing and triage of HPV positive cases with HPV16/18 genotyping or cytology. In HPV positive women, the sensitivity for detecting CIN2+ remains high and the referral rate would drop to 60% of the overall population indicating a potential reduction of 40% in referrals. Where HPV positive women had a cytology test applied, the referral rate would drop to 38%, the sensitivity for detecting CIN2+ remains high. HPV 16/18 genotyping could reduce the referral rate by a similar proportion, however, the sensitivity was considerably lower which could result in delayed diagnosis of CIN2+. CINtec PLUS data is currently under review.

Conclusions: The specificity of HPV testing can be improved by including additional biomarkers as tests of disease.

1244 Analysis of Pathologic Parameters in Adenocarcinoma In Situ of the Cervix: Clinical Correlates and Outcomes

Koah R Vierkoetter, Teresa C Porter, Keith Terada, David Shimizu. John A Burns School of Medicine, Honolulu, HI.

Background: Upon detection of the precursor of adenocarcinoma of the cervix, adenocarcinoma in situ (AIS), hysterectomy with routine surveillance is considered the definitive treatment. However, conclusive management may be problematic, particularly in women who wish to maintain fertility. Hence, select patients may be treated conservatively. Thus far, the leading factor demonstrated in predicting subsequent disease is the status of the excisional margin. Further pathologic factors that may identify patients appropriate for conservative management remain undefined. The present study aims to determine the outcomes of women with AIS, to establish the impact of an expanded set of pathologic parameters detectable at cervical conization.

Design: A retrospective review of cases of AIS diagnosed in a cervical conization from 2000 to 2014 was conducted. Clinical, pathologic and temporal variables were collected for the excisions, hysterectomies and post-operative surveillance.

Results: Fifty patients with AIS were identified. The mean age at diagnosis was 37 (range 17-76 yrs). Nineteen patients (38%) underwent hysterectomy. In the hysterectomies, there was one case of adenocarcinoma, residual AIS was noted in 5 patients (26%) and 13 (68%) were free of residual disease. The remaining 31 women (62%) were treated conservatively. Of these, one showed adenocarcinoma in a subsequent excisional specimen and all were free of disease at last contact; average length of follow-up was 61.1 months (range 3-172). Patients with residual AIS or adenocarcinoma were significantly older than those without residual/progressive disease (48.7 vs. 35.3, p=0.0010). A significant difference was not found between those with AIS/progressive disease and those free of disease in regards to associated squamous dysplasia, disease extent (quadrants/sections involved, horizontal/vertical extension, multifocality), or the qualitative/quantitative status of the margins (direct/close involvement, distance to margins) in either the entire cohort or hysterectomy group alone.

Conclusions: These results suggest that following a cervical excisional procedure, conservative management with routine surveillance may be an acceptable approach in the management of AIS. Older age at diagnosis may pose an increased risk for residual

or progressive disease. Evaluation of pathologic parameters related to the burden of disease and margin does not appear to correlate with the presence of residual/persistent AIS or disease progression.

1245 OTUB1 Exhibits a Subtype-Specific Expression and Predicts Poor Prognosis by Promoting Tumor Progression in Ovarian Epithelial Cancer

Yiqin Wang, Midie Xu, Weiwei Weng, Qiongyan Zhang, Xianrong Zhou, Xiang Du. Obstetrics and Gynecology Hospital of Fudan University, Shanghai, China; Shanghai Cancer Center, Shanghai, China.

Background: Ovarian cancer is the leading malignancy in the female genital tract with a poor prognosis for its multiple subtypes, high invasiveness and metastasis. Deubiquitinase OTUB1 plays critical oncogenic roles and facilitates tumorigenesis. Whether OTUB1 was expressed in ovarian cancer and correlated with prognosis was unknown.

Design: We conducted immunohistochemistry of OTUB1 in 265 cases of ovarian cancer and we analyzed the correlation of OTUB1 with clinicopathological parameters in these 265 cases of ovarian cancer. The Kaplan-meier analysis was done to detect the influence of OTUB1 on DFS and DSS. The Cox-regression analysis was done to detect whether OTUB1 was the independent risk factor of prognosis.

Moreover, we investigated the biological functions of OTUB1 in cells by conducting CCK8, colony-forming and EdU immunofluorescence, Transwell and wound-healing. The xenograft model was built to see the in vivo oncogenicity of OTUB1.

Results: OTUB1 was highly expressed in cancer lesions compared with paratumorous area (P<0.05). OTUB1 was diffusely and strong expressed in clear cell carcinoma (80/80, 100%) compared with serous (42/75, 56.00%), mucinous (20/50, 40.00%) and endometrioid (11/60, 18.33%) (P<0.05). OTUB1 was tightly correlated with tumor size and tumor invasion-related parameters, lymph node metastasis and recurrence (P<0.05). OTUB1 was the independent risk factor for both DSS and DFS (P<0.05).

CCK8, colony-forming and EdU immunofluorescence found that OTUB1 promoted cell proliferation in ovarian cancer cells. Transwell and wound-healing assays showed that OTUB1 enhanced cell invasion in ovarian cancer cells. Finally, xenograft models showed that OTUB1 accelerated tumor growth and elevated tumor weight/volume in vivo.

Conclusions: Our study suggests that OTUB1 presents a subtype-specific expression in ovarian epithelial cancer and predicts poor prognosis and promotes tumor progression in ovarian cancer. OTUB1 could be used as a biomarker in differential diagnosis of ovarian carcinoma and a prognostic predictor in clinical practice.

1246 Endometrioid Adenocarcinoma and Adjacent Atypical Endometrial Hyperplasia Harbor Identical Somatic Mutations by Next Generation Sequencing

Joshua I Warrick, Jordan M Newell, Joshua P Kesterson, Rebecca Phaeton, Nadine Hempel, Carrie Hossler, James Broach, Kathryn E Sheldon, Mariano Russo, Kenneth R Houser, Richard D Bruggeman, Richard Zaino. Penn State University School of Medicine, Hershey, PA.

Background: Atypical endometrial hyperplasia is thought to represent a direct precursor to endometrioid adenocarcinoma of the uterine corpus. Next generation sequencing (NGS) on endometrioid carcinoma and associated endometrial hyperplasia has not been reported to our knowledge. We thus set out to perform NGS on a case of endometrioid adenocarcinoma and associated atypical hyperplasia, to investigate genetic commonality between these processes.

Design: A simple hysterectomy case was identified that contained endometrioid adenocarcinoma and morphologically distinct atypical endometrial hyperplasia. Areas of atypical hyperplasia and endometrioid adenocarcinoma were macrodissected from formalin fixed paraffin embedded tissue. Normal ovary was macrodissected as germline material. DNA was extracted using Quagen extraction kits. NGS was performed on the three specimens using the Ion Proton Instrument (Life Technologies) and the Ion Ampliseq Comprehensive Cancer Panel, which targets the coding regions of 409 cancer-associated genes. Variants were called in carcinoma and atypical hyperplasia samples using the ovarian DNA as normal germline. Called variants were filtered using a standard set of parameters.

Results: The endometrioid adenocarcinoma and endometrial hyperplasia samples harbored identical somatic mutations in three genes commonly mutated in endometrioid adenocarcinoma: *PIK3CA* (p.Arg88Gln), *PTEN* (p.Arg130Gly; p.Ala121fs), and *KMT2D* (p.Leu4214Ter). Identical mutations in *BCL9* (p.His1122Pro) were also identified in hyperplasia and carcinoma. The endometrioid adenocarcinoma harbored mutations not present in the atypical hyperplasia. These included *ARID1A* (p.Arg2158Ter) and *CTNNB1* (p.Ser33Tyr), genes commonly mutated in endometrioid adenocarcinoma.

Conclusions: The findings in this study corroborate that atypical endometrial hyperplasia is a direct precursor to endometrioid adenocarcinoma, as several identical mutations in this case were present in both hyperplasia and carcinoma. That *ARID1A* and *CTNNB1* were present in the carcinoma, but not in the hyperplasia, suggests these may be involved in progression from atypical hyperplasia to fully-developed endometrioid adenocarcinoma.

1247 Classic Vulvar Intraepithelial Neoplasia with Superimposed Lichen Simplex Chronicus: A Potential Pitfall in the Diagnosis of Differentiated Vulvar Intraepithelial Neoplasia

Jaclyn C Watkins, Eric Yang, Christopher P Crum, Marisa R Nucci. Brigham and Women's Hospital, Harvard Medical School, Boston, MA; Stanford University Hospital, Palo Alto, CA.

Background: High-grade vulvar intraepithelial neoplasia (VIN), a precursor lesion to vulvar squamous cell carcinoma, can be subdivided into two types: usual or classic VIN (CVIN) and differentiated VIN (DVIN). CVIN, which is associated with high risk HPV, is usually readily distinguished from DVIN, a p53 dependent process, by its distinct histomorphologic and immunohistochemical characteristics. However, distinguishing CVIN with superimposed lichen simplex chronicus (LSC) from DVIN can be a diagnostic challenge.

Design: Cases of CVIN with superimposed LSC as well as cases demonstrating classic histomorphologic features of DVIN or LSC were included in the study. Repeat biopsies from the same patient were only included if they were from separate anatomic sites. Cases were reviewed for a number of histomorphologic features, including abnormal keratinization, spongiosis, hyperkeratosis, and basal atypia. All cases were stained immunohistochemically for p53, p16, and MIB-1.

Results: 12 cases of dVIN from 6 patients, 7 cases of LSC from 6 patients, and 8 cases of CVIN with superimposed LSC from 7 patients were included in the study. DVIN cases uniformly demonstrated spongiosis, abnormal keratinization, and basal atypia. P53 staining was positive, and of moderate to strong intensity, in basal and parabasal cells. P16 was negative in all cases. CVIN with superimposed LSC cases frequently displayed spongiosis, hyperkeratosis, hyperchromasia involving the basal 3-4 cell layers, basal to full thickness atypia, and more frequent apoptosis. P16 staining was uniformly positive and intense, extending from the basal cells to the mid-epithelium. P53 staining demonstrated a unique pattern of parabasal and mid-epithelial weak to moderate staining with sparing of the basal cells. Cases of LSC demonstrated heterogeneous p53 staining and negative p16 staining. MIB-1 staining showed a similar range of positivity for all diagnoses.

Conclusions: While CVIN with superimposed LSC can closely resemble DVIN, morphologic features such as nuclear hyperchromasia involving the basal 3-4 cell layers, apoptosis, and absent or less pronounced cytoplasmic maturation are more suggestive of CVIN with superimposed LSC. In cases where the morphology remains ambiguous, IHC for p16 and p53 can be helpful. In particular, p53 parabasal and mid-epithelial staining without involvement of the basal layer appears to be a characteristic finding in CVIN with superimposed LSC.

1248 Molecular Alterations in Verruciform Lesions and Keratinizing Squamous Cell Carcinomas of the Vulva

Jaclyn C Watkins, Brooke E Howitt, Neil Horowitz, Lauren L Ritterhouse, Fei Dong, Marisa R Nucci, Christopher P Crum. Brigham and Women's Hospital, Harvard Medical School, Boston, MA.

Background: HPV-negative vulvar carcinogenesis is best known for the presence of TP53 mutations in both the precursor (differentiated vulvar intraepithelial neoplasia (DVIN)) and its invasive counterpart, keratinizing squamous carcinoma (KSCC). However, a range of atypical verruciform lesions (AVL), some of which defy classification, have also been associated with KSCC. This study examined and compared the spectrum of mutations associated with both AVLs and KSCCs.

Design: Samples of AVLs (n=7) included cases resembling verruciform DVIN, verruciform hyperplasia, and verrucous carcinoma. For comparison, 12 HPV-negative KSCCs were also included. DNA isolated from paraffin embedded tissue sections underwent an established hybrid capture/next generation sequencing assay evaluating 300 genes for mutations and copy number alterations (CNAs).

Results: In the AVLs, recurrent mutations were identified in *PIK3CA* (n=5), *HRAS* (n=2), and *ARID2* (n=2). No TP53 mutations were identified. In the KSCCs, the most common mutations were in *CDKN2A* (n=4) and *TP53* (n=10). *PIK3CA*, *HRAS*, and *ARID2* mutations were identified in one case each. The *PIK3CA* and *HRAS* mutations identified were well characterized activating mutations (such as *PIK3CA* E545K and *HRAS* G13V). High gene level amplification of *CCND1* and *EGFR* was identified in KSCC (n=2 and 1, respectively). The majority of the chromosomal and arm level gains/losses were identified in KSCCs, including 3p loss (n=7), 3q gain (n=7), 7p gain (n=6), 8p loss (n=7), 8q gain (n=9), and 17p loss (n=7). Some of the AVLs harbored similar copy number alterations including 7p gain (n=2) and 8p loss (n=1), most of these in lesions resembling DVIN.

Conclusions: While the majority of mutations and CNAs were identified in SCC, the sharing of similar alterations by a significant subset of verruciform lesions supports their role as precursors, even when features of DVIN are absent. Hence, the term well-differentiated verruciform neoplasia is warranted rather than "hyperplasia" for this group, and they should be managed as potential cancer precursors, as clinically appropriate. The presence of *PIK3CA* mutations - many of which can be targeted therapeutically - may have clinical relevance. Additionally, mutations in *ARID2*, which were present in both lesion types, have not previously been reported.

1249 The Clinical and Pathological Features of Maternal Gastric Adenocarcinoma Metastatic to the Placenta

Ping Wei, Mulan Jin. Beijing Chao Yang Hospital, Capital Medical University, Beijing, China.

Background: Gastric carcinoma metastatic to the placenta is extremely rare and only 7 cases reports. The cancer-related gastrointestinal symptoms are often mistaken as nonspecific gastrointestinal complaints associated with pregnancy and leading to a

delayed diagnosis. The gross and histologic examination of the placenta may be the first detection of the metastatic carcinoma. However, the metastatic foci in placenta are always unremarkable both on gross and microscopy examinations.

Design: We report two cases of maternal gastric adenocarcinoma metastatic to the placenta and summarize the clinical and pathological features of all cases in literatures.

Results: In all 148 cases gastric carcinoma associated with pregnancy, there are only 9(6%) cases involved placenta.

author	Year	Age	Early stage abdominal pain	Spread to fetal	Survival
Bender S	1950	40	Yes	n.a.	n.a.
Lee MS	1998	27	Yes	No	20days
Lee HS	1999	28	Yes	No	n.a.
Khatib F	2003	26	Yes	No	2days
Baker AM	2010	22	Yes	No	1days
Miller K	2012	35	Yes	No	31days
Jeong B	2014	37	Yes	n.a.	8days
Case1	2014	35	Yes	No	180days
Case2	2014	30	Yes	No	19days

The mean age is 31 years. All the patients felt non-specific abdominal pain that with varying degree and location. The median survival after surgery was only 8 days and no fetal was involved by the carcinoma. In pathologic examination, most(78%) cases showed normal placental in gross.

Author	placental size	Gross deposits	involving the intervillous spaces	villous invasion
Bender S	n.a.	No	Yes	No
Lee MS	Normal	Yes	Yes	No
Lee HS	Normal	No	Yes	No
Khatib F	n.a.	No	Yes	No
Baker AM	Normal	No	Yes	No
Miller K	Normal	No	Yes	No
Jeong B	n.a.	Yes	Yes	No
Case 1	Normal	No	Yes	No
Case 2	Normal	No	Yes	No

Under microscope, scattered bluish nests in the intervillous space were observed. All cases demonstrated adenocarcinoma infiltration in the intervillous space and no villous involvement. Fibrin deposited around massive villous were noted in 30% (3/9) cases.

Conclusions: Placental involvement is often identified only microscopically without macroscopic evidence. Carcinoma infiltrates in intervillous space as small bluish nests. A thorough microscopic examination of the placenta is important in cases with maternal gastric carcinoma.

1250 Uterine Adenosarcomas Are Mesenchymal Neoplasms

Britta Weigelt, Salvatore Piscuoglio, Kathleen Burke, Charlotte KY Ng, Anastasios D Papanastasiou, Felipe C Geyer, Gabriel S Macedo, Luciano G Martelotto, Ino De Bruijn, Maria Rosaria De Filippo, Anne M Schultheis, Rafael Ioris, Douglas A Levine, Robert Soslow, Brian P Rubin, Jorge S Reis-Filho. Memorial Sloan Kettering Cancer Center, New York, NY; Cleveland Clinic, Cleveland, OH.

Background: Uterine adenosarcomas (UA) are biphasic lesions composed of sarcomatous stroma and epithelial components. We hypothesized that akin to breast fibroepithelial lesions, UAs are mesenchymal neoplasms where clonal somatic genetic alterations are restricted to the sarcomatous stroma.

Design: To characterize the somatic genetic alterations in UAs and to test our hypothesis, we subjected 20 UAs to a combination of whole-exome massively parallel sequencing (MPS, n=6), targeted capture MPS using the MSK-IMPACT assay (n=13) and/or RNA-sequencing (n=6). Somatic genetic alterations (mutations, copy number alterations and fusion transcripts) were identified using state-of-the-art bioinformatics algorithms. The findings obtained from the high throughput technologies were validated with standard molecular pathology techniques. The epithelial and mesenchymal cells from 3 UAs were separately laser-capture microdissected to ensure >99% purity of the cells of each component. Fluorescence *in situ* hybridization (FISH) was employed to validate selected fusion genes and amplifications.

Results: Whole-exome and MSK-IMPACT sequencing revealed the heterogeneity of UAs at the genomic level, as only two genes, *FGFR2* and *DICER1*, were recurrently mutated in 2 of 19 cases each. Both *DICER1*-mutant UAs displayed a rhabdomyoblastic component. *MDM2/CDK4/HMG2* and *TERT* gene amplifications were detected in 26% (5/19) and 21% (4/19) of UAs, respectively, and two cases expressed in-frame fusion transcripts involving *NCOA* family members. Using a combination of laser capture microdissection and FISH, we demonstrated that the somatic genetic alterations detected by MPS were restricted to the sarcomatous stroma and absent in the epithelial cells.

Conclusions: UAs are molecularly heterogeneous, with recurrent *MDM2/CDK4/HMG2* and *TERT* amplifications but few recurrently mutated genes, which may vary according to the histologic features of the stromal component. Our findings suggest that UAs are unlikely driven by a highly recurrent fusion gene. Importantly, clonal genetic alterations were detected in the cells of the stromal but not the epithelial components, suggesting that UAs are primarily mesenchymal neoplasms.

1251 Systems Biology Approaches to Cervical Pre-Cancer Diagnostics

Christine White, Lynne Kelly, Csaba Jenej, Prerna Tewari, Sarah Mahan, Salih Bakhiet, Helen Keegan, John J O'Leary, Cara Martin. Trinity College Dublin, Dublin, Leinster, Ireland; Coombe Women and Infants University Hospital, Dublin, Leinster, Ireland; CellCall, Budapest, Hungary.

Background: Systems biology uses computational and simulation approaches to interrogate gene expression datasets, extrapolate from existing data sets, and explore biological pathways and their relationships. By employing systems biology and data mining tools we can identify new biomarkers and their possible use in cervical cancer and pre-cancer studies. Our objective was to ascertain the utility of a novel panel of pre-selected, systems biology derived proteomic biomarkers in cervical pre-cancer for more accurate grading and stratification of CIN disease.

Design: This project is conducted within the framework of a FP7 funded programme called "SYSTEMCERV". Gene pathways were analysed using MATLAB and SIRENE. Along with KEGGS online database for gene prediction and DAVID for gene functional classification we identified a novel panel of biomarkers. This panel was visualised using Gephi software to explore the internal network of cellular pathways which has identified communities of genes related to cervical pre-cancer and cancer progression. Clinical validation was performed by immunohistochemistry on range of cervical lesions (Normal, CIN1, CIN2 and CIN3). All patients gave written informed consent. In parallel, p16ink4a IHC was performed on all specimens as a benchmark stain. IHC was performed manually and on the BenchMark ULTRA (Ventana Medical Systems).

Results: The biomarker panel included TP63, epiregulin and Desmoglein-3. Each have been tested on up to 113 patient specimens including 13 with no CIN (Normal), 32 with CIN 1, 34 with CIN 2 and 31 with CIN 3. Altered expression patterns were identified in CIN lesions as compared to matched normal cases. TP63 demonstrated both increased expression through the epithelium and increased staining intensity in areas of dysplasia. This difference increased with disease progression. Epiregulin played a suggestive role in identifying virally infected cells. Desmoglein-3 demonstrated a change in expression in CIN compared to normal epithelium.

Conclusions: Novel biomarkers have the potential to distinguish between different grades of cervical intraepithelial neoplasia based on the protein expression status in cervical tissue. This systems biology-based approach for identifying novel markers within gene pathways may significantly improve cervical cancer clinical studies in the future.

1252 Correlates of Physiologic and Neoplastic Human Fallopian Tube Stem Cells

Wa Xian, Yusuke Yamamoto, Gang Ning, Brooke E Howitt, Molly Brewer, Frank D McKeon, Christopher P Crum. National Cancer Center Research Institute, Tokyo, Japan; The Jackson Laboratory, Farmington, CT; Brigham and Women's Hospital, Boston, MA; University of Connecticut Health Sciences Center, Farmington, CT; University of Houston, Houston, TX.

Background: Pelvic High-grade serous cancer (HGSC) typically presents at Stage II or higher (95%) with a 10-year survival rate of ~30%. Studies of women at high risk for HGSC (BRCA mutation+) and women with symptomatic HGSC have documented a frequent origin in the fallopian tube via "serous tubal intraepithelial carcinoma" or STIC. Moreover, non-malignant proliferations, termed p53 signatures, secretory cell outgrowths (SCOUTs) and lower grade serous tubal intraepithelial neoplasms (STINs) share similar alterations in expression, suggesting an underpinning of genomic disturbances involved in or occurring in parallel with serous carcinogenesis.

Design: To gain insight into the cellular origins of this unique tubal pathway to HGSC, we cloned and both immortalized and transformed fallopian tube stem cells (FTSC). A whole-genome transcriptome analysis of benign FTSC, immortalized FTSC, and transformed FTSC was performed and compared not only between these entities but with SCOUTs and STINs.

Results: Pedigrees of FTSCs were capable of multi-potent differentiation and the tumors derived from the transformed FTSC shared the same histological and molecular features with HGSC. Altered expression of some biomarkers seen in transformed FTSCs and HGSCs (Stathmin, EZH2, CXCR4, CXCL12 and FOXM1) could be seen as well in immortalized cells and their *in vivo* counterparts SCOUTs and STINs. Thus, a whole-genome transcriptome analysis comparing FTSC, immortalized FTSC, and transformed FTSC showed a clear molecular progression sequence that is recapitulated by the spectrum of accumulated perturbations characterizing the range of proliferations seen *in vivo*.

Conclusions: This is the first study demonstrating a stem cell phenotype in FTSCs with multiple differentiation pathways. Biomarkers unique to STIC relative to normal tubal epithelium provide a basis for novel detection approaches to early HGSC. However, they must be viewed critically given their potential expression in non-malignant proliferations. Expression profiles seen in immortalized and transformed FTSCs can be superimposed on the spectrum of tubal proliferations seen *in vivo* and provide unique early targets for prevention strategies. Central to these efforts has been the ability to clone and perpetuate multi-potent FTSCs.

1253 Morphologic Features of High Grade Serous Carcinoma of Adnexal/Peritoneal Origin Treated with Neo-Adjuvant Chemotherapy

Anna Yemelyanova, Anais Malpica, Elizabeth D Euscher, Preetha Ramalingam. UT MD Anderson Cancer Center, Houston, TX.

Background: Neo-adjuvant chemotherapy (NA-CT) is becoming the treatment of choice for advanced stage adnexal/peritoneal cancer, particularly in cases where optimal primary debulking (DB) is not feasible. The initial diagnosis is often made based on minimal material, and definitive tumor classification can be problematic. Secondary debulking (SDB) usually provides abundant tissue for examination, but the extent,

distribution, and tumor morphology are frequently altered by treatment, which leads to diagnostic challenges. The goal of this study is to describe the morphologic features of high grade serous carcinoma (HGSC) treated with NA-CT.

Design: Twenty-three cases of HGSC derived from SDB surgeries post NA-CT were reviewed with attention to morphologic features, mitotic count (MC), patterns causing diagnostic challenge and immunohistochemical stains (IHC) when available. NA-CT regimen and number of cycles were recorded.

Results: Of the 23 cases, 8 (35%) were not readily recognizable as HGSC. Tumors were predominantly papillary in 5 (22%), glandular 3 (13%), solid 7 (30%), and 8 (35%) cases displayed combination of patterns. MC ranged from 0-34 mitotic figures/10 HPF (median/mean 4/6.3) with abnormal forms seen in 9 cases (39%). Marked nuclear atypia with syncytiotrophoblast-like cells and smudged chromatin, beyond what is typically seen within the spectrum of HGSC was seen in 19 (83%) cases; the remaining 4 cases displayed relatively monotonous nuclear features. Cytoplasmic clearing mimicking clear cell carcinoma was observed in 11 (48%) cases; sarcoma-like changes were seen in 3 cases. In 14 (61%) cases residual carcinoma was associated with extensive collections of foamy histiocytes. Marked fibrosis with myxoid-like stromal changes was seen in 11 (49%) and single cell infiltration in 13 (57%) cases. The diagnosis of HGSC was supported by IHC (WT-1+, PAX8+, p53+) in 9 cases. All patients received platinum-based NA-CT (3-18 cycles; mean 4.4).

Conclusions: Chemotherapy related changes in tumor morphology can lead to difficulties in diagnosing pelvic HGSC in up to one third of SDB cases. Awareness of altered features distinct from the treatment naive tumors is important given the increased use of NA-CT for HGSC. Prominent therapy related morphologic changes can result from as few as 3 cycles of NA-CT. High MC is not a reliable feature of treated HGSC and cannot be used to support this diagnosis in cases with cytologic monotony. Immunohistochemical analysis can assist in correct classification as expression is generally preserved in treated carcinomas.

1254 Most High Grade Serous Carcinomas Arising in Low Grade Serous Carcinomas Do Not Show Evidence of TP53 or BRAF Mutations

Shabnam Zarei, Sarah E Kerr, Yan Wang, Sarah M Jenkins, Debra A Bell. Mayo Clinic, Rochester, MN.

Background: Typical high grade serous carcinomas (HGSCA) of the fallopian tube/ovary/pelvis have distinct molecular alterations including TP53 mutations (96%) and high levels of chromosomal instability/copy number changes. In contrast, low grade serous carcinomas (LGSCA) are near diploid, TP53 wild-type, and some show KRAS or BRAF mutations. Despite this apparent mutually exclusive molecular pathogenesis of LGSCA and HGSCA, cases with mixed morphologic features of LGSCA and HGSCA have been reported. Little is known about molecular alterations in such tumors. The aim of this study is to evaluate molecular aberrations in high and low grade components of mixed cases and compare them with pure LGSCA and HGSCA. Immunohistochemistry (IHC) for p53 and BRAF as potential diagnostic tools in these cases were evaluated.

Design: A review of the serous tumors from the tumor repository at our institution from 1995 to 2012 revealed 376 pure HGSCA, 20 pure LGSCA and 17 GSCA apparently co-existing with LGSCA. We used all mixed grade and pure LGSCA, as well as 14 representative HGSCA cases, using the MD Anderson diagnostic criteria. IHC of representative sections of each tumor (including low and high grade components of mixed tumors) were performed using antibodies to p53 and BRAF V600E. p53 IHC was interpreted as abnormal (indicative of TP53 alteration) if strongly and diffusely overexpressed or completely negative in tumor cells.

Results: All 51 cases of serous carcinoma were negative for BRAF, regardless of grade. The majority (85%) of pure HGSCA showed abnormal p53, whereas only 3 mixed grade carcinomas had abnormal staining in the high grade component with wild-type staining in the low grade component. Two cases showed abnormal staining in both low and high grade components, implying the possibility of misclassification by morphology. The remaining 12 mixed cases showed normal p53 staining in both components. All LGSCA showed normal p53 staining.

Conclusions: Mixed grade serous carcinomas are rare, and the morphologic criteria and molecular biology of these tumors is poorly understood. A minority of our cases showed differential p53 staining in the low and high grade components, but most cases either showed completely normal (or more rarely abnormal) staining in both components, suggesting alternative molecular biology for these tumors or an imperfect morphologic gold-standard.

BRAF staining was not diagnostically useful in our study. More comprehensive mutational and copy number studies are in progress in an attempt to better understand the molecular biology of these diagnostically problematic tumors.

1255 Distribution and Potential Significance of Placental Intravillous Particulate Microcalcifications

Jennifer Zeng, Alan Marcus, Tatiana Buhotiarova, Khushbakhat Mittal. NYU Langone Medical Center, New York, NY.

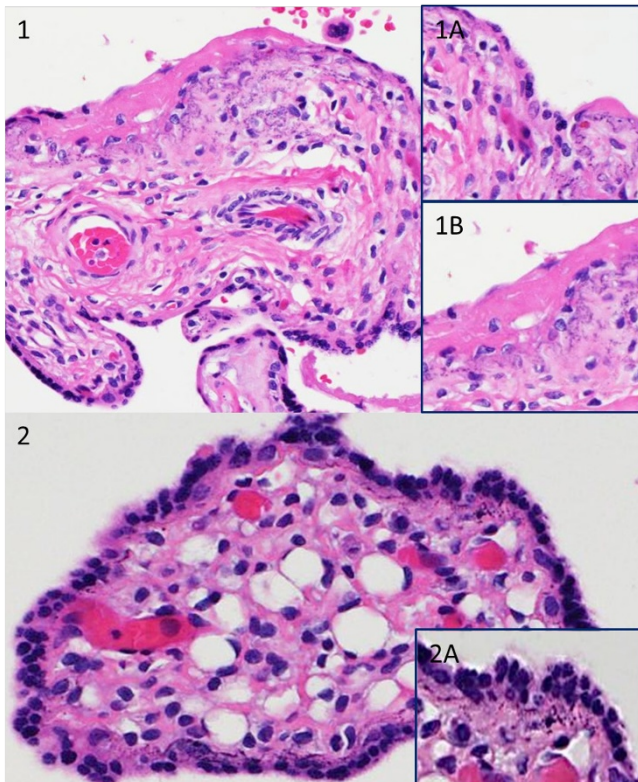
Background: One type of placental calcification is typically located at the basement membrane of trophoblasts, has a fine particulate appearance, and can be only seen microscopically (fig. 1). We have designated these calcifications as Intravillous Particulate Microcalcifications (IPMC). In this study we examined the distribution and potential significance of IPMC.

Design: Placentas with the following diagnoses were retrieved from the pathology database between 2014-2015 and reviewed by one of the authors (JZ): preterm birth, post term birth, gestational diabetes (GDM), intrauterine fetal demise (FD), intrauterine growth restriction (IUGR), chorioamnionitis, and chronic villitis. Percentage of villi involved by IPMC was compared between groups of placentas and quantified as <1%, 1-5%, 5-10% and >10%.

Results: IPMC involved >5% of villi in 11 of 17 placentas (65%) from FD cases, but only 1 of 118 from live births (0.8%, $p < 0.0001$). IPMC involved >10% of villi in 5 of 17 placentas (30%) from FD cases and none from live births (0%, $p < 0.0001$). Clinical data for 11 of the 17 FD cases was available. IPMC in >5% of villi were seen in 3 of the 7 cases where fetus was delivered within 1 day, versus 4 of 4 cases where fetus was retained for >1 days after demise ($p < .05$). Frequency of IPMC in categories other than fetal demise are shown in table 1.

Percentage of Villi involved by IPMC (%)	Chorioamnionitis (n=19), n(%)	GDM (n=20), n(%)	Post Term Births (n=12), n(%)	IUGR (n=15), n(%)	Chronic Villitis (n=15), n(%)
<1	10(50)	12(60)	5(42)	9(60)	8(53)
1-5	6(30)	6(30)	2(17)	3(20)	2(13)
5-10					1(6)
>10					
None	3	2	3	3	4

Figures 1 and 2: IPMC in the basement membranes of villi with perivillous fibrin and within the perivillous fibrin (1A and 1B). However, IPMC was also present in otherwise seemingly normal villi, without any perivillous fibrin (2A).



Conclusions: Association of IPMC with fetal demise, duration of fetal demise and perivillous fibrin suggests that IPMC may be a response to a local hypoxic environment. Presence of IPMC in more than 10% of villi may be used to support a diagnosis of intrauterine fetal demise in forensic and medico-legal cases.

1256 Immunohistochemical Profile of Pure Endometrial Mucinous Adenocarcinoma

Gloria Zhang, Charles V Biscotti, Tao Wu, Xiangdong Ding, Bin Yang. Cleveland Clinic, Cleveland, OH; Kingmed Diagnostics, Guangzhou, OH.

Background: Most endometrial mucinous carcinomas (EMC) have a major mucinous component (>50%) and minor endometrioid component. Pure EMC occurs rarely. EMC's deceptively bland histopathologic features with low grade nuclear atypia complicate recognition particularly in endometrial biopsy /curetting specimens. We analyzed the clinicopathologic and immunohistochemical features of a series of pure EMC.

Design: Seventeen cases of pure EMC (>95% neoplastic mucinous component), including 8 in-house and 9 consultation cases, were identified from pathology database. These included 17 biopsies/curettings and 10 hysterectomy specimens. 13 cases had tissue blocks available for immunostaining with PAX2, PAX8, ER, PR, p16, p53. Ten cases of benign endometrium and benign endocervix served as controls.

Results: Patients' age ranged from 50 to 81 years (mean 59). Thirteen patients including 4 with voluminous mucinous discharge had abnormal uterine bleeding. Histologically, fifteen cases (88%) were FIGO 1 and two cases were FIGO 2. Fourteen cases (82%) had endocervical-type mucinous glands including three cases with a predominant microglandular pattern. Three cases (18%) consisted of either gastric or intestinal-type mucinous glands. All 17 cases had mild to moderate cytologic atypia with minimal or no mitotic activity. Subsequent hysterectomy specimens were available in 10 cases. Six tumors lacked myometrial invasion, 2 tumors invaded 1/3 of the myometrial thickness and 2 tumors had deeper myometrial invasion (85% and 90% respectively).

Immunohistochemical study showed consistent loss of PAX2 nuclear staining in 100% cases regardless of endocervical-type or gastrointestinal-type. All cases showed positive PAX8 staining and wild-type p53 staining pattern including those of gastrointestinal type. ER was diffuse (>70%) and strong in eleven cases (85%), focal and moderate in two cases. PR was negative in six cases, focal and moderate in four cases, diffuse and strong (>70%) in three cases. P16 was either negative (5) or focally positive (8).

Conclusions: Pure EMC is diagnostically challenging due to its bland histologic features. Our study demonstrates that loss of PAX2 staining was observed in all cases regardless of endocervical or gastrointestinal cell type. Retaining strong ER expression and variable loss of PR expression occurred in most pure EMC (77%). A panel of immunostains including PAX2, ER and PR can help identify EMC in problematic biopsy/curetting specimens.

1257 Pattern C Invasive Endocervical Adenocarcinomas: Can We Identify the More Aggressive Subset?

Ranran Zhang, Erin E Medlin, Paul S Weisman, Ahmed Al-Niaimi, Aparna Mahajan. University of Wisconsin Hospital and Clinics, Madison, WI.

Background: A recently proposed classification for endocervical adenocarcinoma (EA) has shown that the vast majority of EAs with lymph node metastases (LNM) and/or recurrences display a frankly invasive pattern (pattern C). However, even in pattern C tumors, LNM are seen in less than a quarter of cases (24%) and the factors that predict aggressive behavior in this group remain unclear.

Design: All available resections of usual type EA with negative margins at our institution from 2002-2014 were retrieved. Other histologic subtypes were excluded. Pattern C assignment required agreement by 2 pathologists (AM, PSW). Tumors were stratified as follows: Greatest horizontal extent (GHE) <1 cm vs \geq 1cm; depth of invasion (DOI) <1 cm vs \geq 1cm; % cervical wall invasion (CWI) <50% vs \geq 50%; presence of lymphovascular invasion (LVI); and presence of microcystic, elongated, and fragmented pattern invasion (MELF). LNM and recurrence data were recorded. Statistical analysis utilized the 2-tailed Fisher's exact test.

Results: 44 cases of EA were available. 14 cases of other histologic subtypes were excluded, leaving 30 cases of usual type EA (15 pattern A or B, 15 pattern C). LN dissection had been performed in all pattern C cases and in 13/15 pattern A or B cases. All LNM (2 cases) and recurrences (2 cases) occurred in pattern C cases. Among pattern C cases, 11/15 (73%) had GHE \geq 1cm, 6/15 (40%) had DOI \geq 1cm, 10/15 (67%) had %CWI \geq 50%, 3/15 (20%) had LVI, and 10/15 (67%) had MELF. While all 4 cases with LNM and/or recurrences had GHE \geq 1cm, CWI \geq 50%, and MELF, none of these trends reached statistical significance [GHE \geq 1cm (4/11 vs 0/4, $p = 0.52$); CWI \geq 50% (4/10 vs 0/5, $p = 0.23$); MELF (4/10 vs 0/5, $p = 0.23$)].

Conclusions: While limited by its small size, our study demonstrates that large tumor volume (\geq 1cm GHE), invasion into the outer aspect of the cervix (\geq 50% CWI), and MELF are frequent findings in pattern C tumors with LNM and/or recurrence. Larger studies are required to determine if these features can reliably predict which pattern C tumors are more likely to run an aggressive clinical course.

Head and Neck Pathology

1258 Sinonasal leiomyosarcoma: Analysis of 9 Cases Exploring Their Clinicopathological and Morphological Spectrum with Emphasis on Previous Irradiation and Association with Other Malignancies

Abbas Agaimy, Sarina Muller, Lester DR Thompson. University Hospital of Erlangen, Erlangen, Germany; Woodland Hills Medical Center, Woodland Hills, CA.

Background: Sinonasal tract leiomyosarcoma is exceedingly rare with less than 100 cases reported. Their exact pathogenesis remains unknown and their relationship to retinoblastoma and previous irradiation has not been specifically explored.

Design: Routine and consultation cases were reviewed for histologically and immunohistochemically proven sinonasal leiomyosarcomas. The tumors were tested with antibodies directed against alpha smooth muscle actin, desmin, h-caldesmon, HMB45, Rb1 and MDM2.

Results: The 9 cases included 5 males and 4 females aged 26 to 77 years (median: 48 years). Tumor sites were maxillary sinus (n=4), nasal cavity (n=3) and combined nasal and sinuses (n=2). Three patients had previous irradiation (2 for retinoblastoma, 1 for fibrous dysplasia) and another patient had chemotherapy and stem cell transplantation for Hodgkin lymphoma. All patients with follow-up developed either local recurrences or/and metastases, mainly to lung (time to metastasis: 16-55 months). Histologically, all tumors but one were conventional high-grade leiomyosarcomas indistinguishable from their somatic soft tissue counterparts; one of these had a glycogen-rich clear cell (PEComa-like) morphology. The low-grade primary tumor, showed grade 2 features in the recurrence and grade 3 features in the lung metastases. Two cases showed dedifferentiation to anaplastic pleomorphic (MFH-like) phenotype. Immunohistochemistry (IHC) showed strong diffuse expression for at least two smooth muscle markers and no reactivity for HMB45. None of the cases expressed MDM2. Rb1 IHC showed inconsistent pattern.

Conclusions: Sinonasal tract leiomyosarcomas are rare aggressive sarcomas that frequently develop in a background of previous cancer therapy, often radiation for retinoblastoma. The frequency of leiomyosarcoma in this particular clinical setting merits further genetic analysis to identify tumors that are *Rb1*-derived. A history of irradiation might have been a confounding factor preventing recognition of hereditary leiomyosarcoma in the setting of retinoblastoma syndrome.