

and even immunophenotypical features. To this end, we performed a comprehensive immunohistochemical analysis using traditional and novel markers in 40 cases of adrenocortical carcinoma.

**Design:** Forty cases of resected adrenocortical carcinoma were reviewed and representative whole tissue sections were selected for immunohistochemical studies using antibodies directed against high molecular weight cytokeratin (HMWCK), low molecular weight cytokeratin (CAM5.2), inhibin- $\alpha$ , melan A, chromogranin A, synaptophysin, calretinin, steroid receptor coactivator-1 (SRC1), Pax8 and Ki67. The percentage of positive tumor cells as well as the intensity of staining were evaluated and scored; for Ki67 the percentage of positive tumor cells was recorded.

**Results:** Positive staining was observed for SRC1 (39/40; 97.5%), inhibin- $\alpha$  (37/40; 92.5%), calretinin (32/40; 80%), synaptophysin (29/40; 72.5%) and melan A (26/40; 65%). CAM5.2 was expressed in 9/40 tumors (22.5%). Rare cases showed positivity for chromogranin A (2/40; 5%) and Pax8 (1/40; 2.5%). None of the cases showed any reactivity with HMWCK. The Ki67 proliferative index ranged from <5 to 20%.

**Conclusions:** There are no specific markers to reliably distinguish adrenocortical carcinomas from other primary or metastatic neoplasms. However, a combination of immunohistochemical stains in a panel consisting of SRC1, inhibin- $\alpha$ , calretinin and HMWCK may be of aid in the differential diagnosis of these tumors. In addition, Pax8 is only rarely positive in adrenocortical carcinomas which is a useful tool in their separation from renal neoplasms.

### 583 PAX8/PPAR $\gamma$ Rearrangements of Thyroid Tumors: Assessment of Distribution Frequency, Histopathological Features and Cytological-Histopathological Correlations

H Yang, M Armstrong, S Carty, P Otori, Y Nikiforov. University of Pittsburgh, Pittsburgh, PA.

**Background:** PAX8/PPAR $\gamma$  rearrangements have been found in follicular thyroid carcinoma (FTC), follicular variant papillary thyroid carcinoma (FVPTC), and follicular adenoma. However, large-scale data have not been reported regarding its prevalence, cytological-histopathological correlation, and histopathological features. We reported the retrospective findings of thyroid tumors for positive PAX8/PPAR $\gamma$  rearrangements.

**Design:** We reviewed all cases for PAX8/PPAR $\gamma$  rearrangement of at our institution in the interval of 2007 to 2012. Its distribution frequency, histopathological features and cytological-histopathological correlations were assessed. Tumor size, vascular and capsular invasion, resection margins, extra-thyroid extension, encapsulation, thickness of capsule, solid growth, metastatic status of regional lymph nodes was also recorded.

**Results:** During a 6-year period of 2007-2012, 16 cases of PAX8/PPAR $\gamma$  rearrangement were identified. In cytology FNA aspirations, this rearrangement was found in 9 (64.3%) follicular lesion/neoplasm (FNL), 2 (14.3%) oncocyctic (Hürthle cell) lesion/neoplasm (OHNL), 2 (14.3%) FLUS, 1 (7.1%) negative. 14 PAX8-PPAR $\gamma$  rearrangement-positive thyroid cancers included 9 FVPTC (64.3%), 3 FTC (21.4%), 2 PTC solid variant (14.3%). Among 9 FVPTC, the cytology FNA diagnosis were 5 FNL, 1 OHNL, 1 FLUS, 1 negative and 1 not-done. Two of 3 FTC were FNL. All 2 PTC solid variant were FNL. Average tumor size of TFC, FVPTC and PTC solid variant was 3.4, 3.7, 4.0 cm respectively. Variable solid growth pattern was present in both FTC (0-40%) and FVPTC (0-30%). All 3 FTC, 9 FVPTC and 2 PTC solid variant were encapsulated and none of them showed extrathyroid extension, positive lymph nodes and positive margins. Vascular invasion of FTC, FVPTC, PTC solid variant was 66% (2/3), 33% (3/9), 50% (1/2) respectively. The capsular invasion of them was 100% (3/3), 56% (5/9) and 50% (1/2) respectively.

**Conclusions:** Our data indicated that: 1) Most thyroid tumors with PAX8/PPAR $\gamma$  rearrangement are encapsulated FVPTC, followed by FC and PTC solid variant; 2) PAX8/PPAR $\gamma$  was not present in other subtypes such as infiltrative/nonencapsulated FVPTC; 3) PAX8/PPAR $\gamma$ -positive encapsulated FVPTC had features of high frequency of capsular invasion, vascular invasion, thick capsule, presence of variable solid growth, and absence of LN and extrathyroid extension.

### 584 The Utility of Cyclin D1 in Distinguishing Encapsulated Follicular Variant of Papillary Thyroid Carcinoma from Follicular Adenoma

DA Zakhia, W Adwar, Z Zhang, O Alassi. Henry Ford Health System, Detroit, MI.

**Background:** Distinguishing encapsulated follicular variant of papillary carcinoma (E-FVPC) from follicular adenoma (FA) depends on the classic nuclear features of papillary carcinoma. These features are subjective and dependant on fixation and tissue processing. There is significant interobserver variability among pathologists distinguishing these lesions. In this study, we investigated whether cyclin D1 IHC has a diagnostic value for discriminating E-FVPC from FA.

**Design:** 23 E-FVPC and 18 FA were stained by IHC for Cyclin D1. All cases of carcinoma were reviewed by two pathologists. Two FA were excluded due to presence of atypical features suspicious for E-FVPC. Staining intensity was graded as negative (0), weak (1+), moderate (2+) or strong (3+). Stain distribution was negative (0%); 1+ (<25%); 2+ (25-75%) or 3+ (>75%) of tumor cells. Mann-Whitney U test was used for statistical analysis.

**Results:** E-FVPC expressed Cyclin D-1 strongly in 22/23 (96%) of cases (3+ in 70%, 2+ in 26%). Cyclin D1 distribution was 3+ in 74% and 2+ in 22% of E-FVPC. One case (4%) of E-FVPC showed only 1+ intensity and 1+ distribution of cyclin D1. Cyclin D-1 was expressed strongly in 9/18 (50%) of FA (3+ in 11%, 2+ in 39%). Four of the FA with 3+ and 2+ intensity had oncocyctic metaplasia and one FA with strong intensity (5.5%) had a background of Hashimoto thyroiditis. Cyclin D1 distribution was diffuse in 8/18 (44%) FA (3+ in 22%, 2+ 22%). 9/18 (50%) FA showed a 1+ staining distribution. A statistically significant association was found between tumor type and cyclin D1 staining distribution and intensity. There were fewer cyclin D1-positive FA than E-FVPC (39% vs. 96%, respectively; p<0.001). Stain distribution was greater in E-FVPC than in FA (96% vs. 44%, respectively; p=0.001).

**Conclusions:** Cyclin D-1 is a useful marker in distinguishing E-FVPC from FA when there is strong and diffuse staining. Almost all E-FVPC show strong, diffuse staining, however, this marker is not helpful if the adenoma shows oncocyctic metaplasia/ changes or there is Hashimoto's thyroiditis. Cases diagnosed as FA may require a review by a second pathologist to exclude the possibility of E-FVPC.

## Gastrointestinal

### 585 Pathway-Dependent Roles of ARID1A Expression Loss in Gastric Cancer: Relationships with Epstein-Barr Virus Infection and Microsatellite Instability

H Abe, D Maeda, T Hishima, Y Iwasaki, M Fukayama. Graduate School of Medicine, University of Tokyo, Bunkyo-ku, Tokyo, Japan; Tokyo Metropolitan Cancer and Infectious Diseases Center Komagome Hospital, Bunkyo-ku, Tokyo, Japan.

**Background:** The AT-rich interactive domain 1A gene (ARID1A), which encodes one of the subunits in the Switch/Sucrose Nonfermentable (SWI/SNF) chromatin remodeling complex, is occasionally mutated and is responsible for loss of protein expression in gastric carcinoma (GC), particularly with Epstein-Barr virus (EBV) infection and microsatellite instability-high (MSI-H) phenotype. However, the clinicopathological significance of ARID1A loss and the relationship with EBV infection or MSI-H were unknown.

**Design:** We applied immunohistochemistry of ARID1A to the tissue microarray of 857 GCs, including 67 EBV(+) and 136 MLH1-lost (corresponding to MSI-H phenotype) GCs. Whole sections of some GC cases were also stained to assess the distribution of ARID1A-lost carcinoma cells. In order to compare with gastric carcinoma, eight nasopharyngeal carcinomas, 15 lymphomas with EBV infection, and 173 colorectal carcinomas were also examined.

**Results:** Loss of ARID1A expression was significantly more frequent in EBV(+) (23/67; 34%) and MLH1-lost (40/136; 29%) GCs than in EBV(-)MLH1-preserved (32/657; 5%) GCs (P<0.01). Loss of ARID1A correlated with larger tumor size, advanced invasion depth, lymph node metastasis and poor prognosis in EBV(-)MLH1-preserved GC. A correlation was found only with tumor size and diffuse-type histology in MLH1-lost GC, and no correlation was observed in EBV(+) GC. Loss of ARID1A expression in EBV(+) GC was highly frequent in the early stage of GC. In whole section staining, all of 14 EBV(+) GCs with ARID1A loss were totally negative for ARID1A in the entire lesion. However, 7 of 17 MLH1-lost GCs with ARID1A loss showed regional expression loss (p=0.02). EBV(+) nasopharyngeal carcinomas and lymphomas failed to show loss of ARID1A. In 173 colorectal carcinomas, only four cases showed ARID1A-loss, and these were also MLH1-lost.

**Conclusions:** ARID1A expression loss may be an early change in carcinogenesis of EBV(+) GC. It specifically occurs in gastric epithelial cells but not in EBV-infection in nasal epithelial cells or lymphocytes. Loss of ARID1A is also frequent in MLH1-lost GC, but it is a late stage event. ARID1A-loss is infrequent, but is related with poor prognosis in EBV-negative and MLH1-preserved GC. ARID1A expression loss has different and pathway-dependent roles in GC.

### 586 Immunohistochemistry Using a BRAF V600E Mutation-Specific Monoclonal Antibody Is Not a Useful Surrogate for Genotyping in Colorectal Adenocarcinoma

CA Adackapara, LM Sholl, JA Barletta, JL Hornick. Brigham and Women's Hospital, Harvard Medical School, Boston, MA.

**Background:** Chemotherapy combined with anti-EGFR monoclonal antibodies prolongs survival in patients with advanced colorectal carcinoma (CRC). BRAF V600E and KRAS activating mutations are identified in around 20% and 50% of CRC, respectively, leading to constitutive EGFR pathway activation and lack of response to anti-EGFR therapy. Therefore, predictive mutation screening is routinely performed in patients with metastatic CRC. BRAF testing is also performed on CRC that demonstrate high-level microsatellite instability, since the presence of a BRAF mutation indicates the tumor is sporadic (i.e., not associated with Lynch syndrome). A novel BRAF V600E-specific monoclonal antibody has recently become commercially available. The aim of this study was to determine whether immunohistochemistry (IHC) for BRAF V600E can predict BRAF mutations in CRC.

**Design:** Whole tissue sections from 52 genotyped cases of CRC (46 primary tumors and 6 metastases) were examined. BRAF codon 600 and KRAS codons 12 and 13 were genotyped by pyrosequencing in a CLIA-certified laboratory. Cases included 17 tumors with BRAF V600E, 18 with KRAS mutations, and 17 wild-type for BRAF and KRAS. IHC was performed following pressure cooker antigen retrieval with an anti-BRAF V600E monoclonal antibody (Spring Bioscience; clone VE1; 1:50 dilution with overnight incubation). Cytoplasmic staining was scored as negative, weak, moderate or strong, with a known BRAF V600E-mutant melanoma serving as a positive control. Two authors scored the slides, with discrepancies resolved across the microscope.

**Results:** Cytoplasmic staining was observed in 71% of tumors with BRAF V600E mutation. Staining was moderate or strong in 50% of the positive cases (35% of BRAF-mutant cases overall). Weak cytoplasmic staining was detected in 17% of KRAS-mutant cases and 35% of wild-type cases. Non-specific nuclear staining in both tumor cells and normal colonic epithelium was a common finding. The sensitivity and specificity of BRAF V600E IHC for BRAF V600E mutation is 71% and 74%; if only moderate or strong staining is considered positive, the specificity is 100%, but the sensitivity is only 35%.

**Conclusions:** Overall, BRAF V600E mutation-specific IHC is not specific for BRAF mutations in CRC. While moderate or strong cytoplasmic staining is specific for BRAF

V600E mutations, this antibody is insufficiently sensitive to serve as an effective screening tool for CRC. Weak staining lacks specificity, as it is observed in *BRAF*-mutant, *KRAS*-mutant, and wild-type tumors.

### 587 Pseudoadenomatous Transformation of Tubal Gut Mucosa Secondary to Metastasis, Including a Unique Cytokeratin 7 Positive Type Not Previously Described

*C Adackapara, R Odze.* Brigham and Women's Hospital, Boston, MA.

**Background:** Metastasis to the tubal gut may involve the mucosa in a manner that simulates adenomatous (in-situ) change, termed "pseudoadenomatous transformation" (PAT). As a result, metastatic tumors may be erroneously interpreted as primary lesions. We have noted, anecdotally, a previously undescribed type of PAT composed of non-neoplastic (reactive) epithelium that can also simulate in-situ change. The aim of this study was to evaluate the clinical, pathologic, and immunohistochemical features of patients with PAT of the tubal gut with particular emphasis on the type composed of reactive (non-neoplastic) epithelium.

**Design:** 54 tubal gut resection specimens identified via a 20 year search through the pathology files of a major university hospital coded as tubal gut metastasis (N>1000) were evaluated for the clinical, pathologic, and immunohistochemical features of the primary tumor and metastasis, and for evidence of PAT in the latter. Immunohistochemistry of the primary and secondary tumors was performed and included both general and tumor specific markers.

**Results:** Overall, 23 of 54 (43%) patients (M/F ratio: 1.1:1, mean age: 61 years) with tubal gut metastasis to the mucosa showed PAT. Metastatic tumors included adenocarcinomas from the small or large bowel (7/23), lung (3/23), pancreas/gallbladder (3/23), appendix (2/23), kidney (1/23), breast (1/23), uterus (1/23) and melanoma (5/23). PAT involved the small bowel more often than the large bowel (70% versus 30%;  $p=0.048$ ). Microscopically, two patterns of PAT were detected; one in which metastatic neoplastic cells formed tubules or villi lined by basement membrane simulating in-situ disease [9/23, 39% (type A)], and the other in which peritumoral non-neoplastic epithelium revealed reactive (non-neoplastic) cytologic and architectural features simulating adenomatous epithelium [(11/23, 48% (type B)]. Three cases (13%) showed a mixture of both types of PAT. Peritumoral reactive PAT (type B) showed a previously unreported pattern of CK7 staining in 6/14, (43%) of cases, despite negativity in the normal epithelium, all type A PAT foci, and in the tumor metastasis ( $p<0.05$ ).

**Conclusions:** Mucosal metastasis to the tubal gut may induce PAT either by direct cancerization of the mucosa, or by inducing a unique adenoma-like reactive atypia in the peritumoral epithelium which also showed upregulation (overexpression) of CK7. CK7 is helpful in identifying the latter and differentiating it from true neoplastic epithelium.

### 588 Base Pair Changes in Assessing Microsatellite Instability and Correlation to Mismatch Repair Status by Immunohistochemistry

*K Affolter, A Wilson, W Samowitz, K Geiersbach.* University of Utah, Salt Lake City, UT; ARUP Institute for Clinical and Experimental Pathology, Salt Lake City, UT.

**Background:** Microsatellite instability (MSI) testing by PCR amplification and capillary electrophoresis is a standard method of assessing mismatch repair status in patients with colorectal and other Lynch associated cancers. Many laboratories use a commercial kit (MSI Analysis System, Promega Corp.) containing five mononucleotide microsatellite markers (BAT-25, BAT-26, MONO-27, NR-21, and NR-24). The Promega kit defines MSI-High tumors as being unstable for at least 2 of the 5 markers and instability is defined as an allele size shift of at least 3 base pairs (bp) between the tumor and non-tumor tissue. The current available data to support the threshold of 3 bp or more for instability is limited.

**Design:** We retrospectively identified 175 adenocarcinomas (mostly colorectal and endometrial) which had been evaluated by both the Promega kit for microsatellite instability and immunohistochemistry for mismatch repair genes. MSI results were re-classified into groups according to the specific number of base pair changes. MSI data were then compared to immunohistochemistry results for mismatch repair proteins (MLH1, MSH2, MSH6, PMS2) on the same tumor.

**Results:** One of 72 tumors with no change in repeat size and one of 73 tumors with a one base pair change in repeat size as compared to normal were associated with abnormal IHC results (loss of MSH2/MSH6 and isolated loss of PMS2, respectively). Two of six tumors with a two base pair change in at least one repeat were associated with abnormal IHC results (MLH1/PMS2 loss and isolated PMS2 loss). Twenty-three of 24 tumors with a three or more base pair change in at least one repeat were associated with abnormal IHC results. The proportion of tumors with a two ( $p=0.0001$ ) or three base pair change ( $p<0.0001$ ) and abnormal IHC results was significantly greater than that seen with either no change or a one base pair change.

**Conclusions:** This study confirms the notion that a three base pair change in a mononucleotide repeat is an excellent marker for mismatch repair deficiency. Although further study is necessary, these data also suggest that a 2 base pair change in a mononucleotide repeat may be indicative of mismatch repair deficiency, and that IHC testing may be helpful in such cases. Finally, mismatch repair deficiency as indicated by abnormal IHC testing may occur in tumors without detectable microsatellite instability; optimal detection of mismatch repair deficiency probably requires both testing modalities.

### 589 BRAF V600E Immunohistochemical Stain in Colorectal Carcinomas

*K Affolter, S Page, S Tripp, M Bronner, W Samowitz.* University of Utah Health Sciences Center, Salt Lake City, UT; ARUP Institute for Clinical and Experimental Pathology, Salt Lake City, UT.

**Background:** The serine/threonine-protein kinase B-raf (BRAF) is an oncogene mutated in various neoplasms, including five to ten percent of colorectal carcinomas. The T1799A point mutation, responsible for a large majority of these alterations, results in a valine to glutamate amino acid substitution at position 600 (V600E) and causes the constitutive activation of a protein kinase cascade. BRAF V600E in MLH1 deficient tumors implicates somatic tumor-only methylation of the MLH1 promoter region instead of a germline mutation. BRAF V600E also predicts poor prognosis in microsatellite stable colorectal cancers and may also be a marker of resistance to anti-EGFR therapy in metastatic disease. Currently, only molecular methods are available for assessing BRAF mutational status. An immunohistochemical approach is evaluated here.

**Design:** Serial colon cancers from 2008 to 2012 tested by pyrosequencing for BRAF V600E mutation were selected for study. A total of 14 formalin-fixed paraffin-embedded tumors with the BRAF V600E mutation and 17 without it or other BRAF mutations were analyzed by immunohistochemistry using a commercially available mouse monoclonal antibody to BRAF V600E.

**Results:** All 14 colorectal carcinomas with the BRAF V600E mutation demonstrated cytoplasmic positivity in tumor cells with the anti-BRAF antibody. In a minority of cases the staining intensity for the mutated tumor samples was weak or heterogeneous; however, the majority of cases showed diffuse cytoplasmic positivity. None of the 17 BRAF wild type colorectal cancers showed immunoreactivity to the anti-BRAF V600E antibody.

**Conclusions:** Detection of the BRAF V600E mutation in colorectal cancer by immunohistochemistry is a viable alternative to molecular methods. This option may allow laboratories able to do immunohistochemistry but not high complexity molecular analysis to perform BRAF V600E mutational testing. It may also prove to be a more cost effective approach. Furthermore, it provides an option for detecting mutational status in cases not amenable to molecular testing, such as samples with very few tumor cells or samples with numerous contaminating non-neoplastic cells.

### 590 Residual Tumor Burden in Rectal Cancer: A New Method of Assessing Pathologic Response to Neoadjuvant Therapy

*A Agarwal, G Chang, Y-C Hu, M Taggart, A Rashid, S Kopetz, D Maru.* Baylor College of Medicine, Houston, TX; University of Texas MD Anderson Cancer Center, Houston, TX.

**Background:** We assessed implications of residual tumor burden categories and tumor regression grade (TRG) as predictors of recurrence-free survival (RFS) in a large patient population with long term (median:70 months) follow up.

**Design:** Retrospective study of 251 patients with locally advanced rectal adenocarcinoma treated with neoadjuvant therapy followed by resection was performed. The extent of residual carcinoma was assessed irrespective of nodal status by estimating the proportion of residual cancer cells in relation to the total tumor area. Four subsets were analyzed: no residual cancer cells (complete response),  $\leq 5\%$  residual cancer cells (near complete response),  $>5\%$  and  $<50\%$  residual cancer cells (major response) and  $\geq 50\%$  residual cancer cell (minor response). TRG was categorized as: no viable tumor cells (0), small groups of cancer cells (1), residual cancer outgrown by fibrosis (2) and minimal or no tumor kill (3). The pathologist was blinded from all clinicopathologic parameters.

**Results:** 157 men and 94 women were studied. ypT0N0 was in 19%, ypT1-2N0 in 27%, ypT3-4N0 in 21%, and N+ in 33%. Lymphovascular invasion in 24% and perineural invasion in 10%. 9 had positive margin. Pathology response was complete in 21%, near complete in 20%, major in 37% and minor in 22%. TRG 0 in 21%, 1 in 33%, 2 in 38% and 3 in 8%. Log-rank test indicated difference in RFS by categories of response and TRG was significant ( $p<.001$ ). The 3 & 5 years RFS, by categories of residual tumor burden: complete 98% & 95%; near complete 88% & 88%; major 74% & 69% and minor 71% & 62% ( $p<.001$ ). The 3 and 5 years RFS by categories of TRG: 0, 98% & 96%; 1, 83% & 81%; 2, 67% & 59% ( $p<.001$ ) and 3, 95% & 95%. RFS between patients with TRG 2 & major response was better than TRG 2 & minor response ( $p=.02$ ). In univariate analysis, factors associated with shorter RFS were major or minor response, high grade (HR:1.98 CI:1.07-3.65), lymphovascular invasion (HR:2.2 CI:1.24-3.72), perineural invasion, higher pT, N+ disease, and positive margin (HR:3.01 CI:1.19-7.63). Major (HR:3.11 95% CI: 0.99-9.71) & minor response (HR: 4.32 95% CI: 1.31-14.19) and perineural invasion (HR:2.44 95% CI: 1.13-5.26) remained significant in the multivariate analysis.

**Conclusions:** Residual tumor burden is a predictor of RFS in patients with resected rectal cancer after neoadjuvant therapy, and if validated may be a surrogate biomarker suitable for prospective clinical trial. This parameter is complementary in further stratifying prognosis of patients with TRG 2.

### 591 Multicenter Validation Study of Pathologic Response and Tumor Thickness at the Tumor-Normal Liver Interface as Independent Predictors of Disease-Free Survival after Preoperative Chemotherapy and Surgery for Colorectal Liver Metastases

*A Agarwal, A Brouquet, G Zimmitti, S Kopetz, J Stif, C Julie, A-I Lemaistre, S Benoist, B Nordlinger, A Gandini, M Rivoire, S Stremtizer, T Gruenberger, J-N Vauthey, D Maru.* Baylor College of Medicine, Houston, TX; Ambroise Paré Hospital, Paris, France; University of Texas MD Anderson Cancer, Houston, TX; Medical University of Vienna, Vienna, Austria; Centre Léon-Bérard, Lyon, France.

**Background:** To validate previously described pathologic markers of response to preoperative chemotherapy as predictors of disease-free survival (DFS) after resection of colorectal liver metastases (CLM).

**Design:** One hundred seventy one patients who underwent resection of CLM after preoperative chemotherapy at 4 major hepatobiliary centers were studied. Pathologic response defined as proportion of tumor cells remaining (categorized as complete; no residual tumor cells, major; 1-49% residual tumor cells or minor;  $\geq 50\%$  residual tumor cells) and tumor thickness at the tumor normal interface (TNI) (categorized  $< 0.5$  mm,  $0.5$  mm- $< 5$  mm and  $\geq 5$  mm) were assessed by blinded review by central pathology reviewer and pathologists from each institution.

**Results:** Oxaliplatin based regimen+bevasizumab was given in 62%, Irinotecan based regimen+bevasizumab in 28% and  $> 1$  regimens in 10% patients. Liver resection was minor in 46% and major in 54%. Pathologic response was complete in 8%, major in 49% and minor in 43%. Tumor thickness at TNI was  $< 0.5$  mm in 21%,  $0.5$  mm- $< 5$  mm in 56% and  $\geq 5$  mm in 23%. Eight patients had positive margin. By log-rank analysis, survival difference between complete and major response ( $p=0.004$ ), major and minor response ( $p=0.049$ ), tumor thickness at TNI  $.5$  mm and  $.5$ - $< 5$  mm ( $p=0.002$ ), and tumor thickness at TNI  $.5$ - $< 5$  mm and  $\geq 5$  mm ( $p=0.002$ ) were significant. In univariate analysis, factors associated with worse 3 & 5 years DFS were preoperative CEA ( $p=0.005$ ), minor vs. major or complete response, major vs. complete response, tumor thickness at TNI  $> 0.5$  mm,  $> 3$  months of preoperative chemotherapy, and positive margin. In Cox regression multivariate analysis minor ( $p=0.002$ ) and major ( $p=0.009$ ) response, tumor thickness at TNI  $> 0.5$  mm ( $p<0.001$ ),  $> 3$  months of chemotherapy ( $p=0.043$ ),  $> 3$  tumor nodules ( $p=0.037$ ), and positive margin ( $p=0.016$ ) remained significant. Tumor size was predictor of pathologic response. Predictors of tumor thickness at TNI were tumor size, oxaliplatin based regimen and inclusion of bevasizumab. Agreement between central reviewer and local pathologists was near perfect ( $\kappa=0.82$ ) for pathologic response and substantial ( $\kappa=0.76$ ) for tumor thickness.

**Conclusions:** Pathologic response and tumor thickness at TNI are valid predictors of DFS after preoperative chemotherapy and surgery for CLM.

#### 592 Clinicopathologic Predictors of Long Term and Disease-Free Survival in Esophageal Adenocarcinomas with Complete Pathologic Response to Neoadjuvant Chemoradiation

*AT Agoston, Y Zheng, R Bueno, GY Lauwers, RD Odze, A Srivastava.* Brigham and Women's Hospital, Boston, MA; Massachusetts General Hospital, Boston, MA.

**Background:** Neoadjuvant chemoradiation treatment has improved outcomes for esophageal adenocarcinoma (EAC). Patients with pathologic complete response (pCR) to therapy have favorable long term and disease-free survival but there remains significant heterogeneity in outcome within this group. The aim of this study was to determine clinicopathologic predictors of long term and disease-free survival among patients with EAC who had pCR to neoadjuvant chemoradiation.

**Design:** 93 patients with EAC who had pCR to neoadjuvant chemoradiation were identified. A pre-determined set of clinicopathologic variables was examined for each case including: age, gender, tumor type and grade (pre-treatment biopsy), tumor location, tumor size (pre-treatment endoscopy), pre-treatment endoscopic ultrasound T and N stage, extent of pathologic sampling (# of sections from tumor bed, complete histologic examination of entire tumor bed), presence and depth of acellular mucin pools in the tumor bed, hyalinization, fibrosis, and acellular mucin pools within lymph nodes, and number of lymph nodes evaluated. Follow up data including overall survival (OS) and time to recurrence (TTR) were obtained by medical chart review, and were analyzed by a Cox Proportional Hazards Model.

**Results:** Of the 93 patients (mean age 62.7 years, M:F ratio 7.5:1), 57 patients (61%) died and 32 patients (34%) had documented local ( $n=2$ ) or distant ( $n=30$ ) recurrence (mean follow up time: 6.3 yrs). Histologic examination of the entire tumor bed was the most significant predictor of favorable outcome in this group (Hazard Ratio [HR]=0.39 for OS and HR=0.40 for TTR;  $p$ -values 0.0005 and 0.0115, respectively). The presence of any poorly differentiated component in the pre-treatment biopsy was associated with an unfavorable outcome (HR=1.88 for OS, HR=1.67 for TTR;  $p$ -values 0.02 and 0.15, respectively). None of the other clinicopathologic parameters examined were significantly different in those with or without an adverse outcome.

**Conclusions:** Complete histologic examination of the entire tumor bed and poorly differentiated phenotype in pre-treatment biopsies are important predictors of disease-free survival in patients with EAC and pCR. Our findings also confirm heterogeneous outcomes in pCR patients and suggest that histologic examination of the entire tumor bed is necessary to identify the subset of complete responders with a uniformly favorable outcome within this group.

#### 593 A Large Cohort of Consecutive Patients Confirmed Frequent HER2-Positivity in Gastric Carcinomas with Advanced Stages

*S Ahn, J Cho, CK Park, S Kim, K-M Kim.* Samsung Medical Center, Sungkyunkwan University School of Medicine, Seoul, Republic of Korea.

**Background:** Trastuzumab in association with systemic cytotoxic chemotherapy is the standard of care for patients with advanced HER2-positive gastric carcinoma (GC) and gastroesophageal (GE) junction cancer based on ToGA trial. However, the role of HER2 as a prognostic factor in GC remains controversial. This study was performed to investigate the clinicopathologic characteristics of HER2-positive GC in a large cohort of consecutive patients.

**Design:** HER2 overexpression/amplification was evaluated by immunohistochemistry (IHC) and silver in situ hybridization (SISH) in 2,798 GCs obtained from 2,727 total/subtotal gastrectomy specimens and 71 open/laparoscopic biopsy specimens from patients with peritoneal seeding. Regional heterogeneity was defined as the proportion of tumor cells showing membranous staining in 10% to 70% of tumor cells in a representative block of surgical specimens. Genetic heterogeneity was determined by the existence of HER2/CEP17 ratio higher than 2.0 in 5-50% of the tumor cells.

**Results:** In IHC, 184 cases (6.6%) were 3+ and 44 cases (1.6%) were 2+. Out of 44 HER2 2+ cases, SISH showed HER2 gene amplification in 21 cases (47.7%), chromosome 17 polysomy in 6 cases (13.6%), and genetic heterogeneity in 5 cases (11.4%). HER2-positivity found in 7.3% of GCs was significantly associated with older age, male gender, intestinal histology, upper third in location, higher lymph node stage ( $p<0.002$ ) and AJCC stage ( $p=0.033$ ). Regional heterogeneity of HER2 expression was closely associated with 2+ (70.5% vs 42.9% in 3+,  $p=0.001$ ) and diffuse or mixed histologic type (68.4% and 70.0% vs 43.1% in intestinal-type,  $p=0.005$ ).

**Conclusions:** Regional heterogeneity of HER2 expression was closely associated with weak HER2 overexpression (2+) and with diffuse or mixed histology. Polysomy of chromosome 17 would be an important cause of HER2 2+ in IHC. Frequent HER2-positivity observed in GCs with advanced stages suggests that HER2 may be involved in tumor progression and poor prognosis.

#### 594 Does Barrett's Carcinoma Always Arise from Intestinal Metaplasia? Detailed Histologic Examination of EMR Specimens

*J Aida, T Arai, M Vieth, C Ell, A May, H Neuhaus, K Takubo.* Tokyo Metropolitan Institute of Gerontology, Tokyo, Japan; Tokyo Metropolitan Geriatric Hospital, Tokyo, Japan; Dr. Horst Schmidt Clinic, Wiesbaden, Germany; Evangelisches Krankenhaus, Duesseldorf, Germany.

**Background:** The diagnostic criteria for Barrett's esophagus in the USA include the presence of intestinal metaplasia with goblet cells. This is because, in the USA, Barrett's carcinoma is considered to arise only in intestinal-type mucosa. We have reported that cardiac, rather than intestinal-type, mucosa is observed in the background of minute Barrett's carcinoma (Hum Pathol 2009, 40: 65-74). However, as we examined only one histologic section in each case, this may have been insufficient for determining the cancer origin. Therefore, we examined all sections and confirmed all borders between Barrett's carcinoma and surrounding mucosa.

**Design:** We examined 665 microscopic sections of Barrett's carcinoma within the mucosal layer from 56 endoscopic mucosal resection (EMR) specimens, and categorized histologically all of the non-neoplastic mucosae adjacent to Barrett's carcinoma as either the cardiac/fundic or intestinal type. In each case, we also estimated the proportion occupied by each mucosal type, for which purpose we carried out immunohistologic staining for mucin (MUC2, MUC 5AC, and MUC6).

**Results:** Histologically, the 56 tumors were either papillary or well to moderately differentiated tubular adenocarcinoma. Twenty-six cases (46.4%) comprised cardiac-type mucosa alone, and 12 (21.4%) were surrounded predominantly by cardiac-type and partly by intestinal-type mucosa. Twelve other cases (21.4%) comprised intestinal-type mucosa alone, and four (7.1%) were surrounded predominantly by intestinal-type and partly by cardiac-type mucosa. Two cases (3.6%) were surrounded equally by cardiac- and intestinal-type mucosa.

**Conclusions:** Cardiac-type mucosa is located adjacent to carcinoma much more frequently than is intestinal-type mucosa, thus supporting the former study. Therefore, it cannot be proven histogenetically that the background mucosa of Barrett's carcinoma is the intestinal type. In addition, from this histogenetic standpoint, it seems better to define Barrett's esophagus as metaplastic columnar-lined esophagus alone, without requiring the presence of goblet cells.

#### 595 Vascular Ectasia/Congestion as an Early Manifestation of Gastrointestinal Histopathology in Behcet's Disease: A Study of 184 Biopsies from 24 Patients

*M Alimchandani, P Bagi, T Heller, CH Sibley, MM Quezado.* National Institutes of Health, Bethesda, MD.

**Background:** Behcet's disease is a rare disease, more common in people with ethnic backgrounds from the Middle East and far East. It is characterized by systemic inflammatory lesions and vasculitis of unknown pathogenesis. There is significant morbidity associated with gastrointestinal (GI) manifestations of this disease. The histopathology of the gastrointestinal manifestations in this disease is not well characterized.

**Design:** We analyzed samples from the gastrointestinal tract of 24 patients diagnosed with Behcet's disease. The biopsies were collected at the National Institutes of Health (NIH) from 2009 - 2012. We reviewed 184 samples: 6 esophageal, 45 gastric, 25 duodenal, 17 terminal ileal, and 91 colonic biopsies. In our evaluation, special attention was paid to the following parameters: vascular changes, inflammation, polyps, dysplasia.

**Results:** In our cohort, there were a total of 24 Behcet's patients, mostly females (22 females and 2 males), ranging in age from 15 to 57 years (mean age 36 years) with vague to symptomatic clinical presentation. We find vascular changes in majority of biopsies (138/184; 75%), regardless of the site in the gastrointestinal tract. The vascular changes range from mild vascular congestion/ectasia to ischemic-like colitis in 2 cases. Additionally, vascular thrombi are identified in 2 cases. We did not encounter vasculitis with fibrinoid necrosis in any of our cases. There was evidence of chronic or acute inflammation in 21 cases (11%), most often in gastric biopsies. Nine polyps were identified - six fundic gland polyps from gastric biopsies, one hyperplastic polyp and one serrated adenoma from the colonic biopsies.

**Conclusions:** Though the gastrointestinal pathology encountered in Behcet's disease is largely non-specific, we find a high incidence of vascular changes that range from vascular ectasia to thrombi and ischemic-like colitis. There was prominent vascular congestion/ectasia throughout the GI tract, not associated with inflammation, that may represent an early GI manifestation of this disease. Inflammation was most often encountered in biopsies from the stomach. When reviewing gastrointestinal biopsies from a Behcet's patient, the pathologist needs to have a high index of suspicion for these vascular changes.

**596 Utility of pHH3 Immunohistochemistry in Risk Stratification of Gastrointestinal Stromal Tumors: An Inter-Observer Variability Study**

*A Alkhasawneh, L Vila Duckworth, X Lu, T George, J Reith, T Zuluaga Tora.* University of Florida, Gainesville, FL.

**Background:** Gastrointestinal stromal tumors (GIST) are graded based on mitotic count (low grade  $\leq 5$  mitoses/5mm<sup>2</sup>, high grade  $> 5$  mitoses/5mm<sup>2</sup>). However, mitotic counts are subject to interobserver variability. Phospho-histone H3 (pHH3) is a recently described mitosis-specific antibody which may decrease the interobserver variability. Our aim was to evaluate the mitotic count interobserver variability of GIST by comparing counts on H&E slides vs pHH3 immunostains. To our knowledge, no previous studies have evaluated mitotic activity of GIST using pHH3.

**Design:** 70 GIST cases ( $\geq 2$  cm) resected between 2000-2011 were identified. All cases with mitotic rates  $> 5$  mitoses/5mm<sup>2</sup> (10 cases) were included. 40 of the remaining 60 cases with  $\leq 5$  mitoses/5mm<sup>2</sup> were randomly selected for a total of 50 cases. All slides from each case were reviewed to identify the slide with most "hotspots" (areas with readily identifiable mitotic figures). In cases lacking prominent mitoses, slides with hypercellular areas and/or nuclear pleomorphism were selected. pHH3 immunohistochemistry (IHC) was performed on the corresponding block. Quantitative analysis of mitotic activity was performed independently by four pathologists (1 soft tissue pathologist, 1 gastrointestinal pathologist, 1 gastrointestinal pathology fellow, and 1 pathology resident) on H&E and pHH3-stained slides by counting the number of mitoses/5mm<sup>2</sup> area. An interclass correlation analysis was performed to test the interobserver variability for all cases.

**Results:** Kappa values showed very good interobserver variability for mitotic counts on both H&E and pHH3-stained slides. Of the 200 total mitotic counts on H&E slides, 141 had  $\leq 5$  mitoses/5mm<sup>2</sup> (low grade) and 59 had  $> 5$  mitoses/5mm<sup>2</sup> (high grade). However, using pHH3 IHC, 30 (21%) of the low grade counts had  $> 5$  mitoses and 6 (10%) of the high grade counts had  $\leq 5$  mitoses. Overall, at least one observer's mitotic count changed in 25 of 50 cases.

**Conclusions:** The current risk stratification for GIST is based on site, tumor size, and accurate mitotic count. In this study, interobserver variability was very good for both methods used. However, pHH3 IHC may alter mitotic counts in a significant number of GIST, and may be a valuable adjunct in the assessment of mitoses in GIST.

**597 Loss of SMAD4 Expression Is a Poor Prognostic Factor in Ampullary Adenocarcinoma**

*A Alkhasawneh, L Vila Duckworth, N Desai, X Lu, A Sommerfeld, T George, T Zuluaga Tora.* University of Florida, Gainesville, FL.

**Background:** Adenocarcinomas of the ampulla of Vater may be classified based on morphology into biliary and intestinal subtypes, with the former having a more aggressive behavior. *SMAD4* is a tumor suppressor gene that when down regulated has been shown to be an adverse prognostic factor in pancreatic adenocarcinoma. Though a prior study failed to demonstrate a difference in *SMAD4* expression in intestinal versus biliary subtypes of ampullary adenocarcinomas (McCarthy et al. 2003), there is limited data on *SMAD4* expression in ampullary tumors.

**Design:** 63 cases of ampullary adenocarcinomas resected between 2000 and 2011 were assessed for *SMAD4* expression by immunohistochemistry. Morphologic type (intestinal versus biliary or indeterminate), age, gender, tumor stage, lymph node (LN) status, and measures of clinical outcome (death, recurrence) were recorded. *SMAD4* expression was assessed as follows (adapted from Tascilar et al. 2001): negative (complete absence), trace (weak reactivity relative to surrounding normal pancreas), focal (two cell populations with a subset of clearly negative cells) and positive (strong staining comparable to surrounding pancreas).

**Results:** 22 cases were *SMAD4* negative, 28 had decreased *SMAD4* expression (9 focal, 19 trace), and 13 were *SMAD4* positive. 68% (15/22) of the *SMAD4* negative patients had biliary morphology, while 38% (5/13) of *SMAD4* positive were of biliary subtype. Tumor stage was higher in *SMAD4* negative patients (72% were stage T3/T4) versus *SMAD4* positive patients (54% were T3/T4). Lymph node metastasis was also higher among the *SMAD4* negative patients (50% LN positive) versus *SMAD4* positive patients (38%). In patients with available clinical follow-up, 57% (8/14) of patients who recurred were *SMAD4* negative. Death rate was also higher in *SMAD4* negative patients (54%) versus *SMAD4* positive patients (31%).

SMAD4 expression in subtypes of ampullary tumors

SMAD4	Biliary	Intestinal	Indeterminate	Total
Negative	15	4	3	22
Trace	9	4	6	19
Focal	2	5	2	9
Positive	5	5	3	13
Total	31	18	14	63

Clinical characteristics based on SMAD4 expression

SMAD4	Stage T1/T2	Stage T3/T4	Lymph node metastasis	Recurrence	Deceased
Negative	6	16	11	8	12
Trace	2	17	9	4	13
Focal	3	6	4	0	4
Positive	6	7	5	2	4
Total	17	46	29	14	33

**Conclusions:** Loss or decreased expression of *SMAD4* in ampullary adenocarcinoma was associated with more aggressive clinical behavior. *SMAD4* negative patients were more likely to have higher tumor stage, lymph node metastasis, recurrence and death.

**598 Neoadjuvant Radiochemotherapy in Esophageal Adenocarcinoma Is Associated with a Dense IgG4 Plasma Cell Response**

*D Allen, S Lu, L Noble, J Fanion, MB Resnick, E Yakirevich.* Rhode Island Hospital and the Alpert Medical School of Brown University, Providence, RI.

**Background:** Lymphoplasmacytic infiltrates, the primary immune component infiltrating solid tumors, are considered to be a manifestation of the host anti-tumor response. Recently we have noticed the presence of a dense plasma cell infiltrate in esophagectomy specimens of patients with esophageal adenocarcinoma who underwent neoadjuvant radiochemotherapy. The aim of this study was to quantify and further characterize the plasma cell infiltrates in esophageal adenocarcinomas with respect to IgG4 expression.

**Design:** Fifty consecutive esophagectomy specimens of esophageal adenocarcinoma were selected including 35 following neoadjuvant radiochemotherapy, and 15 with no previous history of radiochemotherapy (NT). The treatment response was evaluated as complete (CR), partial (PR), or no response (NR). Formalin-fixed paraffin embedded sections were stained for IgG4 and IgG by immunohistochemistry. Areas with the highest density of IgG4+ and IgG+ plasma cells were selected, the average of the three most cellular areas per high power field (hpf) were counted, and IgG4+ to IgG+ ratios were calculated.

**Results:** Of the 35 patients treated with neoadjuvant radiochemotherapy six had a complete response, 23 partial response and six no response. None of the patients had an IgG4-related sclerosing disease. The number of IgG4+ plasma cells varied between 0 and 297 per hpf; the number of IgG+ plasma cells ranged between 0 and 336 per hpf. The absolute number of IgG4+ plasma cells was increased in the area of the tumor bed in the CR group as compared to the PR, NR, and NT groups (114.5 $\pm$ 55.3, 79.0 $\pm$ 18.9, 23.7 $\pm$ 8.2, and 35.6 $\pm$ 11.9 per hpf, respectively). Furthermore, the ratio of IgG4+/IgG+ plasma cells was markedly elevated in the CR group and PR group as compared to the NR group (44%, 40%, and 18%, respectively). The CR group contained significantly more tumors with  $> 50$  IgG4+ plasma cells per hpf and  $> 50\%$  IgG4+/IgG+ ratio as opposed to PR and NR (50%, 39%, and 0%, respectively, p=0.05). At this point it is not clear whether the degree of the IgG4 response confers a survival advantage.

**Conclusions:** This is the first study to identify and characterize a dense IgG4 plasma cell infiltrate in esophageal adenocarcinoma following neoadjuvant radiochemotherapy. The association of elevated IgG4+ plasma cells with complete treatment response suggests that it may play a role in the neoadjuvant therapy related immune response.

**599 Histologic Features Can Distinguish Non-Celiac Causes of Villous Atrophy from Those of Celiac Disease**

*SJ Almahat, K Pallav, D Leffler, CP Kelly, JD Goldsmith, RM Najarian.* Beth Israel Deaconess Medical Center & Harvard Medical School, Boston, MA; Beth Israel Deaconess Medical Center, Boston, MA; University of Mississippi Medical Center, Jackson, MS.

**Background:** Villous atrophy and crypt hyperplasia are relatively specific histologic features of celiac disease (CD). These features are additionally found in patients with other diseases and result in misdiagnoses and inappropriate treatment recommendations. No studies to date have systematically examined the histologic features that can aid the pathologist in recognizing non-celiac enteropathies (NCE) and how they differ from celiac disease.

**Design:** 32 patients (mean 56 y; 69% F), with negative genetic and serologic tests for CD, but with duodenal biopsies demonstrating villous atrophy were identified by clinical referral. 58 biopsies from these patients were evaluated for the following: mean number of intraepithelial lymphocytes (IEL); presence of intraepithelial lymphocytosis (defined as  $> 30$  lymphocytes/100 enterocytes); active neutrophilic inflammation (AI); villus/crypt ratio (VCR); and other histologic features. Indications for endoscopy, comorbidities, serologic data, related extraintestinal biopsy findings, and final clinical diagnoses were obtained following the blinded biopsy review. 16 patients (mean 45 y; 69% F) with clinical and histologic evidence of CD were used as a control group for comparison.

**Results:** The proportion of NCE biopsies with AI was twice that of CD biopsies (62 vs 31%; p=0.0173), with CD patients never demonstrating involvement of deep crypts. In contrast, CD biopsies had a higher number of mean IEL when compared to NCE (66 vs 33/100 enterocytes; p<0.0001), with only half of NCE biopsies having intraepithelial lymphocytosis. CD biopsies also had lower VCR than those of NCE (0.3 vs. 0.7; p=0.008). Foveolar metaplasia and lymphoid aggregates were seen in both groups without significant differences. Over a mean follow-up period of 30 months, 14 NCE patients were found to have an immune-related disorder, including post-viral and de novo autoimmune enteropathy, as potential causes of their villous atrophy. Additionally, peptic duodenitis, collagenous sprue, CVID, Crohn's, bacterial overgrowth, eosinophilic gastroenteritis, and food allergy were found in 6, 4, 3, 2, 1, 1, and 1 patients, respectively.

**Conclusions:** The presence of AI, especially that found within crypts, and the absence of intraepithelial lymphocytosis are features that suggest causes of duodenal villous atrophy other than celiac disease.

**600 Loss of Cables Expression in Neuroendocrine Tumors (NETs) of the Gastrointestinal Tract, Pancreas, and Lung**

*T Arnason, MS Pino, DC Chung, HL Sapp, D Rayson, V Deshpande, LR Zukerberg.* Massachusetts General Hospital, Boston, MA; Queen Elizabeth II HSC, Halifax, NS, Canada.

**Background:** In the pathogenesis of NETs, several chromosomal deletions have been identified, but few tumor suppressor genes, apart from MEN1, have been implicated. Chromosome 18 deletions are present in nearly 70% of ileal NETs. The Cables gene, which maps to chromosome 18q11-12, is a tumor suppressor gene in human cancers.

Loss of Cables expression has been detected in many carcinomas, including colon cancer, which has frequent chromosome 18 loss. There are no prior studies of Cables expression in NETs.

**Design:** IHC for Cables was applied to tissue microarrays containing FFPE tumor tissue from 310 NETs. Nuclear expression of Cables was interpreted as intact, partially lost, or completely lost and correlated with stage, grade, and survival in a subset.

**Results:** Cables expression was completely lost in 44% of 310 NETs tested. Cables expression was intact less often in ileal tumors (8%) compared to tumors from all other sites combined (35%,  $p < 0.025$ ) and compared to other small intestinal (SI) sites (51%,  $p < 0.01$ ).

Table 1

Primary site	Complete loss of Cables	Partial loss of Cables	Cables intact
SI	18(25%)	17(24%)	36(51%)
Ileum	11(44%)	12(48%)	2(8%)
Pancreas	31(43%)	20(27%)	22(30%)
Appendix	4(40%)	0	6(60%)
Lung	74(57%)	21(16%)	36(27%)

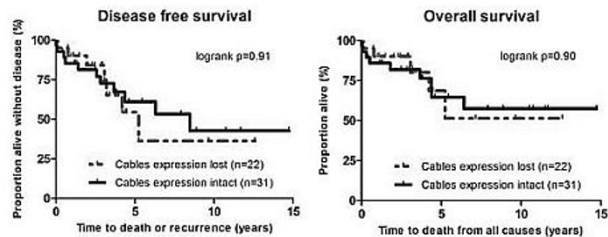
Loss of Cables expression was not associated with a significant difference in stage or grade in a subset of primary pancreatic (n=34) and SI (n=32) NETs.

Table 2

ENETS* stage	Complete loss of Cables	Partial loss of Cables	Cables intact
1	4(18%)	2(15%)	5(16%)
2a	2(9%)	2(15%)	6(19%)
2b	3(14%)	1(8%)	6(19%)
3a	3(14%)	1(8%)	0
3b	6(27%)	6(46%)	10(32%)
4	4(18%)	1(8%)	4(13%)
Grade			
1	17(77%)	12(92%)	26(84%)
2	4(18%)	1(8%)	3(10%)
3	1(4%)	0	2(6%)

\*European NET Society

Complete loss of Cables expression was not associated with a difference in disease free or overall survival in a subset of 53 patients with pancreatic and SI NETs.



**Conclusions:** Cables expression is lost in a significant proportion of NETs. Ileal NETs have frequent deletions of chromosome 18, which is one mechanism for loss of Cables. Loss of Cables expression in NETs from other sites with infrequent chromosome 18 deletions suggests that Cables is lost by other mechanisms such as epigenetic silencing and suggests that Cables is a tumor suppressor gene in NETs.

### 601 Collagenous Gastritis: A Morphologic and Immunohistochemical Study of 27 Cases

T Arnason, I Brown, B O'Brien, C Wilson, H Winter, GY Lauwers. Massachusetts General Hospital, Boston, MA; Royal Brisbane and Women's Hospital, Brisbane, Qld, Australia; Sullivan Nicolaides Pathology, Brisbane, Qld, Australia.

**Background:** Collagenous gastritis (CG) is defined by the histologic finding of a superficial subepithelial collagen layer. Disease associations include celiac disease (CD), collagenous sprue (CS) and collagenous colitis (CC). The cause of increased collagen deposition remains undetermined. This study aims to further characterize the morphologic spectrum of CG through histologic study of the largest series of cases to date and investigate two possible pathogenetic mechanisms related to eotaxin and IgG4.

**Design:** All diagnoses of CG, including consults, were identified at three hospitals. Slides were reviewed for features including collagen thickness, intraepithelial lymphocyte (IEL) count and eosinophil count. Immunohistochemical stains for eotaxin and IgG4/IgG were applied to a subset. Clinical records were reviewed for demographics and medical history.

**Results:** 27 cases of CG (19 female, 8 male) were identified with a mean age at onset of 33 years (range 3-89 years). 56% of patients (15/27) presented between ages 12-35 years. 4 patients had associated CD and 6 had CS and/or CC (1 patient had all 3). Histologic review confirmed subepithelial collagen (mean thickness 49µm, range 15-145µm) and at least focal surface epithelial sloughing in all cases. Two distinct inflammatory patterns were observed, eosinophil rich (>30 eosinophils/HPF) and lymphocyte rich (>25 surface IELs/100 epithelial cells) inflammation. The eosinophil rich pattern was observed in 12/27 (44%) cases and was more frequent in younger patients, with mean age 19 years vs. 41 years for those without this pattern ( $p = 0.022$ ). There were increased surface IELs in 4 cases, all of which had associated CD, CS, and/or CC, which was a more frequent rate of associated disease than in the remainder of the population ( $p < 0.01$ ). No increased eotaxin expression was identified in 9 cases tested. 1 of 11 cases tested had increased IgG4 positive cells (100/HPF) with an IgG4/IgG ratio of 55%. The other 10 cases had a mean IgG4/IgG ratio of 18%. No patients had evidence of systemic IgG4 related disease.

**Conclusions:** This study identified two distinct inflammatory patterns in CG. A lymphocytic pattern (increased surface IELs) was more common in the setting of

CD, CS, and CC. An eosinophilic pattern was identified in younger patients, but the absence of increased eotaxin expression did not suggest an allergic/atopic mechanism. The finding of an increased IgG4/IgG ratio was too infrequent to implicate IgG4 as a major pathway in the pathogenesis of CG.

### 602 Renvela Crystals in the Gastrointestinal (GI) Tract: A New Entity

CA Arnold, BN Limketkai, T-C Liu, E Montgomery, K Nazari, MS Torbenson, MM Yearsley, D Lam-Himlin. Ohio State University, Columbus, OH; JHMI, Baltimore, MD; Washington University, St. Louis, MO; Mayo Clinic, Scottsdale, AZ.

**Background:** Medication injury to the GI tract is common owing to polypharmacy and an aging population. Pathologists play an important role in recognizing these agents on biopsy specimens. We report the first description of Renvela (Sevelamer carbonate) crystals in the GI tract. Renvela is a phosphate lowering agent used in patients with end stage renal disease.

**Design:** We prospectively collected cases with histologically identical crystals from 2 major academic centers over a one year period. Pertinent clinicopathologic features were recorded.

**Results:** Renal disease and Renvela usage were demonstrated in all cases (n=13 total cases, 5 patients). The characteristic crystal consisted of non-refractile, broad "fish scales" with curved points of intersection, bright pink linear accentuations, and a yellow backdrop. Additional comorbidities included IBD (n=1), amyloidosis (n=1), diabetes (n=3), SLE (n=1), and hypertension (n=4). Sites of involvement include the esophagus (n=1), small bowel (n=2), and colon (n=10). Mucosal associations include acute inflammation (n=4), inflammatory polyps (n=2), ischemic injury (n=1), necrosis (n=1), ulceration (n=1), a mucosal prolapse polyp (n=1), and a tubular adenoma (n=1). The background mucosa was normal in only one case. To validate the histological findings, Renvela powder and crushed pills were submitted for routine histological processing: the findings were identical to those seen in the patient specimens. The possibility of Kayexalate had been raised in error (n=2 patients). Kayexalate, however, has narrow "fish scales" with linear points of intersection and a purple color. We also studied the histologic features of the bile acid sequestrants Cholestyramine (n=3 cases) and Welchol (n=4 cases). We found these latter crystals lack the characteristic "fish scale" pattern described above, are eosinophilic, and are unassociated with mucosal injury.

**Conclusions:** In summary, we report the first series of Renvela crystals in the GI tract. These distinctive crystals are found in renal failure patients and can be associated with inflammation, ischemia, and necrosis. While further study is required to determine if Renvela plays a causal role in these injuries, this crystal is an important mimic of Kayexalate, Cholestyramine, and Welchol. Since the history of Renvela administration was not included in any provided requisitions, it is crucial for the pathologist to be aware of its characteristic features for accurate diagnosis and to avoid the diagnostic pitfalls of its mimics.

### 603 Clinical Experience with Mismatch Repair (MMR) Status and OncoType DX® Colon Cancer Recurrence Score® Assay in 917 Patients With Stage II Colon Cancer

H Bailey, J Anderson, V Tan, AC Tsiatis, FL Baehner, J Liu, M Lopatin, M Lee, C Millward. Genomic Health, Inc., Redwood City, CA; University of California, San Francisco, CA.

**Background:** Standardized clinically-validated tools to quantify recurrence risk can improve adjuvant treatment decisions for colon cancer patients. MMR status by immunohistochemistry (MLH1 and MSH2) and Recurrence Score by quantitative RT-PCR have been validated as independent predictors of colon cancer recurrence risk in QUASAR (J Clin Oncol, 10;29(35):4611-9, 2011), CALGB 9581 (J Clin Oncol, 29(Suppl): Abstract 3518, 2011), and NSABP C-07 (O'Connell, ASCO Annual Meeting, 2012). Here we report our experience for stage II colon cancer patients who obtained MMR status and Recurrence Score values from the Genomic Health Clinical Laboratory.

**Design:** MMR status was determined using immunohistochemistry (IHC) assays for MLH1 and MSH2 (validated in 170 colon cancer specimens by comparing to assessments from the CAP/CLIA-certified reference laboratory (Vitro, Miami, FL) used in the QUASAR clinical validation study, with a concordance rate of 99.2% (95% CI 95.8-99.9%) for MMR). Standardized quantitative RT-PCR analysis for the 12 genes was performed on 30 µm manually-microdissected fixed primary tumor tissue. Recurrence Score values were calculated according to the pre-specified algorithm.

**Results:** Between Jan and Sept 2012, MMR status was assessed for 917 patients (51% female, 40% ≥70 years old, 10% with mucinous carcinoma). 197 (21%) were MMR-deficient (MMR-D) and 720 (79%) were MMR-proficient (MMR-P). As expected, among the MMR-D tumors, loss of MLH1 expression by IHC was more common (87%) than loss of MSH2 expression (13%). Patients with MMR-D tumors were more likely to have mucinous histology (19% vs 8%), older age (54% vs 36% with age ≥ 70) and to be female (61% vs 49%), all  $p < 0.01$ . Recurrence Score results were available for 665 MMR-P patients for whom both MMR and the Recurrence Score were ordered. Scores spanned a wide range from 0 to 67, with a median of 26 and an interquartile range of 19-34. No significant differences were observed by gender or age.

**Conclusions:** The Genomic Health Clinical Laboratory MMR IHC Assay has been rigorously validated, and further studied in a large cohort of contemporary stage II colon cancer patients. Stage II colon cancer patients with MMR-P tumors represent a heterogeneous population with a wide range of colon cancer biology as revealed by the Recurrence Score result.

**604 Analysis of Columnar Lined Esophagus Reveals Less Frequent Mutations in Non-Goblet Cell Metaplasia Than Intestinal Metaplasia**

S Bandler, JH Peters, D Ruff, S-M Chen, C-Y Li, K Song, K Thoms, VR Little, T Watson, N Chapurin, A Pennathur, JD Luketich, D Peterson, A Dulak, L Lin, A Bass, DG Beer, TE Godfrey, Z Zhou. URM, Rochester, NY; University of Pittsburgh, Pittsburgh, PA; Life Technologies, Foster City, CA; Dana Farber Cancer Center, Boston, MA; University of Michigan, Ann Arbor, MI.

**Background:** Gastroesophageal reflux causes the formation of columnar metaplasia of esophageal mucosa, which is classified as either intestinal type (IM) defined by goblet cells or as non-goblet type (NGM). In the United States, the presence of goblet cells is required for the diagnosis of Barrett's esophagus (BE), the strongest known risk-factor for development of esophageal adenocarcinoma (EAC). Worldwide, there is considerable debate regarding the cancer risk of NGM and whether it should be included in the definition of BE. IM is known to harbor frequent genetic alterations that are often observed in adenocarcinoma. The aim of this study was to investigate the frequency of EAC-associated genomic mutations in NGM and IM as a means to infer relative cancer-risk of the two epithelia.

**Design:** 19 NGM, 16 IM and 5 composite tissues (both NGM and IM) were analyzed along with matched normal squamous specimens using targeted re-sequencing of 20 genes found to be frequently mutated in EAC. Sequence data from metaplasia samples was compared with patient-matched normal DNA in order to filter sequence polymorphisms and identify variants. In addition, mutation data from 66 EAC samples was compared with that from metaplasia samples to see if mutation load could classify disease status. A pairwise Receiver-Operator Characteristic (ROC) analysis was used.

**Results:** This analysis revealed a total of 16 non-synonymous and 5 synonymous mutations. 2 mutations were observed in independent NGM samples (2/19; 10.5%) in *CDKN2A* and *COL11A1*. 14 (14/21; 66.7%) mutations were observed in the IM and composite samples including non-synonymous mutations in *TP53* (n=4; 24%), *SMARCA4* (n=2; 12%), *LRP1B* (n=3; 18%), *ERBB2* (n=1; 6%) and *CDKN2A* (n=1; 6%) and synonymous mutations in *APC*, *ERBB2* and *LRP1B*. Mutation load was found to have strong power to classify EAC versus metaplasia. ROC analysis resulted in an area under the curve of 0.954 for EAC vs. any metaplasia and 0.915 for IM alone versus EAC.

**Conclusions:** Our results show that IM has a much higher frequency of cancer-associated mutations than NGM and is therefore the potential to pose a higher risk for development of EAC. In addition, the mutation load appears to have good potential for detecting disease status in patients with BE. This approach could be applied to cytology specimens for BE surveillance.

**605 An Unexpected Trend in the Prevalence of Microsatellite Instability in Colon Cancer**

BD Barrows, N Zarrin-Khameh, BL Musher. Baylor College of Medicine, Houston, TX.

**Background:** Lynch Syndrome (Hereditary Non-polyposis Colon Cancer) is an important cause of familial colon cancer with a reported prevalence of 10-15%. Paired mutations of DNA mismatch repair (MMR) genes are indirectly responsible for the development of neoplasia in Lynch Syndrome due to accumulation of mutations and microsatellite instability. The syndrome is inherited in an autosomal dominant pattern, although the tumors behave similar to a recessive disease due to the requirement of a somatic mutation to inactivate the uninvolved allele. The presence of MMR gene mutations is now reliably detected in tumor tissue by methods including immunohistochemistry and polymerase chain reaction (PCR) of MMR genes. Despite the reliability of current detection methods, additional investigation is required to better understand the natural progression and overall prevalence of this disease.

**Design:** To evaluate the prevalence of Lynch syndrome in our patient population, we performed a retrospective analysis of all colonic adenocarcinoma related surgical specimens collected at our General Hospital from 2009-2012. One hundred and fifty-one cases were identified and screened for mutation of MMR genes by immunohistochemistry.

**Results:** MMR gene mutation analysis showed a markedly reduced prevalence of confirmed Lynch syndrome, specifically in the African-American and Latino-American subgroups of our patient population (see table). The age range for the 8 cases showing positive MMR gene mutation was 33-66 years old with a mean age of 49. Tumors were predominantly found to arise in the ascending colon followed by transverse, descending, sigmoid and rectum (3, 2, 1, 1, 1 respectively).

Colon cancer patient subpopulations	Number of patients	MMR gene mutation detected	MMR gene mutation absent	Prevalence
African American	45	1	44	2%
Asian	15	0	15	0%
Caucasian	23	2	21	9%
Latino-American	64	4	60	6%
Middle Eastern	4	1	3	25%
Total	151	8	143	5%

**Conclusions:** The overall prevalence of Lynch syndrome in our patient population is markedly lower than reported in literature, especially with respect to the African-American and Latino-American subgroups. Through better understanding the overall prevalence of Lynch syndrome we hope to contribute to the development of more efficient screening methods and future research concerning the natural progression of this disease.

**606 Granular Cell Tumors of the Gastrointestinal Tract: Clinicopathologic Associations in a Large Series**

B Bhattacharya, S Samaha. Miraca Life Sciences Research Institute, Phoenix, AZ.

**Background:** We designed this study to use a large national pathology database to better characterize the demographic and clinicopathologic features of granular cell tumors (GCT) of the gastrointestinal tract. Because these tumors are relatively uncommon, their characteristics remain poorly defined.

**Design:** From the Miraca Life Sciences database we extracted demographic data, location, presentation, endoscopic features, method of removal, and follow up data from all patients who had a diagnosis of GCT between 1.2008 and 12.2010. All pertinent slides, including special and immunostains, were retrieved and re-examined.

**Results:** There were 63 GCT from 62 patients (median age 50 years, range 22-75; 60% female). There were 30 GCTs in the esophagus (15 in the lower third; 8 in the mid-esophagus; 2 in the upper esophagus; 5 unspecified); 2 in the stomach; and 31 in the colon (25 in the ascending colon; 2 in the transverse; 3 in the descending; and 1 in the rectum). Patients with esophageal GCTs presented with epigastric pain (13 patients) and gastroesophageal reflux disease (GERD) (11 patients); in contrast, 71% of colonic GCTs were discovered incidentally during screening colonoscopy. The endoscopic appearance was non-specific, variously described as polyps, nodules, and submucosal lesions. Most tumors were biopsied, particularly in the esophagus, while approximately 25% (mostly in the colon) were snared. All tumors were smaller than 1 cm (range 2 to 9 mm). The pattern of growth differed slightly in the esophagus and colon: esophageal tumors tended to exhibit a sub-epithelial nodular expansive proliferation. Colonic GCTs showed submucosal and mucosal proliferation, with nested or infiltrative pattern and some hyalized stroma. None of the tumors showed mitotic activity, necrosis or pleomorphism. Metastases were not reported in any of the patients.

**Conclusions:** In our series, GCTs of the gastrointestinal tract were predominantly found in the esophagus (mostly in the lower third) and the right colon. Essentially all cases were detected incidentally, either during screening colonoscopy or during esophagogastroduodenoscopy performed for unrelated indications (GERD and abdominal pain). None of the tumors had either histopathological or clinical features of malignancy.

**607 Phosphorylation of EGFR in Colorectal Cancer**

JR Bledsoe, DE Shvetz, M Mino-Kenudson. Massachusetts General Hospital, Boston, MA.

**Background:** Dysregulated signaling through the MAP-Kinase (MAPK) pathway has been implicated in colorectal cancer (CRC) and occurs in the setting of mutations resulting in constitutive activation of pathway intermediates such as *KRAS* and *BRAF*. In CRC the *BRAF* mutation is associated with a worse prognosis and decreased response to EGFR inhibitors. *BRAF*-mutated CRC also shows a poor response to *BRAF* inhibitors in comparison to *BRAF*-mutated melanoma. Recent studies have shown that activation of EGFR may result in maintenance of MAPK signaling in *BRAF*-mutated CRC in the presence of *BRAF* inhibitors, thereby resulting in diminished efficacy of the inhibitor. However, the activation status of EGFR in CRC before treatment with *BRAF* inhibitors is not known.

**Design:** The study cohort consisted of 122 CRC cases. As part of the clinical workup, all cases had undergone analysis of driver mutations using a multiplex PCR assay. Of those, 22 cases harbored *BRAF* V600E mutations, none of which had been treated with a *BRAF* inhibitor prior to sample acquisition. Immunohistochemistry for EGFR, its activated form p-EGFR, and the activated MAPK effector p-ERK was performed on tissue microarrays and tumor sections. Average composite scores for staining were assigned using the H-score (maximum score 300) for each case. For each antibody, the cut-off for positive expression was determined based on the expression seen in normal colonic epithelium. P-EGFR expression was correlated with EGFR and p-ERK expression, driver mutation, and clinical parameters including clinical stage and prognosis.

**Results:** Positive expression of p-EGFR was seen in 7.6% of the examined cases, that of EGFR in 26%, and that of p-ERK in 26%. The expression level of p-EGFR was correlated with EGFR (p<0.0001) and p-ERK (p=0.0112) expression in the tumor samples. Positive p-EGFR expression was seen in one case with a *BRAF* mutation, 3 cases with *TP53* mutations, and 5 cases without any mutations. EGFR and p-EGFR expression was not significantly associated with specific mutations, including *BRAF* and *KRAS* mutations. Increased MAPK activation, as determined by p-ERK over-expression, was seen in cases with *KRAS* (p=0.0079), but not *BRAF* mutations. There was no difference in the clinical parameters and prognosis between cases with and without positive p-EGFR expression.

**Conclusions:** Activation of EGFR is not frequent in "BRAF inhibitor-naive" CRC although it can be seen in rare *BRAF* mutated tumors, and is associated with activation of downstream target, ERK. Further studies are warranted in order to elucidate post-treatment changes in EGFR activation in *BRAF*-mutated CRC treated with *BRAF* inhibitors.

**608 Loss of Expression of ARID1A and BRG1 in Colorectal Cancer Occurs Infrequently and Is Associated with BRAF Mutation and Microsatellite Instability**

JR Bledsoe, M Kamionek, DE Shvetz, M Mino-Kenudson. Massachusetts General Hospital, Boston, MA.

**Background:** The ARID1A, BRG1, and PRBM1 genes encode proteins that are major components of the SWI/SNF chromatin remodeling complex. Loss of expression of these proteins has been implicated in the tumorigenesis of many human cancers including a small proportion of colorectal cancers (CRC). Microsatellite instability and epigenetic phenomena such as CpG island methylation have been postulated to

play a role in the inactivation of these proteins. However, better characterization of the pathologic features, prevalence, and clinical implications seen in CRC with SWI/SNF abnormalities is necessary.

**Design:** Immunohistochemistry for ARID1A, BRG1, and PBRM1 was performed on tissue microarrays and tumor sections of 122 cases of CRC. Corresponding clinicopathologic data was collected including tumor mutational status as determined by multiplex PCR directed at a panel of commonly mutated genes, as well as microsatellite instability (MSI) status. Semi-quantitative determination of the level of nuclear staining for each antibody was calculated by H-score (maximum score 300) based on staining intensity and distribution. The cut-off for preserved expression was set at the score of 100.

**Results:** Loss of ARID1A expression was seen in three cases (2.5%) and loss of BRG1 expression was seen in nine (7.6%). Two cases showed combined loss of ARID1A and BRG1 expression and there was a significant correlation between expression level of ARID1A and BRG1 ( $p=0.0197$ ). Preserved PBRM1 expression was seen in all samples. All cases with loss of ARID1A carried the BRAF V600E mutation and showed MSI. Four of nine (44%) cases with loss of BRG1 expression also carried the BRAF mutation and three showed MSI. All with ARID1A loss were poorly differentiated and had a medullary morphology with syncytial tumor growth and tumor-infiltrating lymphocytes, features characteristic of MSI. The majority (75%) of tumors with BRG1 loss were also poorly differentiated. No significant association between loss of protein expression and prognosis or other clinicopathological features was found.

**Conclusions:** The results confirm that loss of ARID1A and/or BRG1 expression is seen in only a minority of CRC and is most likely due to BRAF mutation in association with microsatellite instability and/or CpG island methylation. ARID1A loss is associated with medullary morphology in our cohort. The clinicopathological characteristics and clinical significance of SWI/SNF chromatin remodeling complex abnormalities need to be evaluated further in larger scale studies.

### 609 Necrotizing Sialometaplasia-Like Change of the Esophageal Submucosal Glands Is Associated with Barrett's Esophagus

*DR Braxton, DC Nickleach, Y Liu, AB Farris.* Emory University School of Medicine, Atlanta, GA; Winship Cancer Institute of Emory University, Atlanta, GA.

**Background:** The esophageal submucosal glands (SMG) secrete mucins and bicarbonate that function to protect the squamous epithelium from insults such as gastroesophageal reflux. We have observed metaplastic changes within the SMG that we have termed oncocytic glandular metaplasia (OGM), and necrotizing sialometaplasia-like change (NSMLC). We hypothesize that these metaplasias arise from reflux-induced damage of the SMG. The aim of this study is to evaluate the associations between these metaplasias and clinicopathological parameters.

**Design:** Routinely stained sections from adult esophagectomy cases were retrospectively evaluated for SMG metaplasia and assigned to either a BE or control group. SMG involved by, or adjacent to, tumor were excluded. Clinicopathological data was collected for each case. Univariate analysis was performed using chi-square tests or ANOVA. Separate multivariable logistic regression models were performed for each main predictor, IM (intestinal metaplasia), BE, and GERD, to assess the adjusted association with NSMLC and OGM.

**Results:** A total of 82 esophagi containing SMG were studied. NSMLC was found in 25/45 (56%) of BE cases and 8/37 (22%) of control cases. OGM was in 15/37 (41%) of controls and 29/45 (64%) of BE cases. On univariate analysis NSMLC was associated with BE ( $p=0.002$ ) and GERD ( $p=0.005$ ). There was no relationship between NSMLC and patient age, sex, tumor size, or treatment history (i.e. fundoplication, myotomy, surgical resection, chemoradiation). OGM was associated with IM ( $p=0.005$ ), BE ( $p=0.031$ ), and GERD ( $p=0.01$ ). No relationship was found between OGM and patient age, sex, tumor size, or T stage. On multivariable analysis NSMLC was independently predicted by BE (OR 5.50,  $p$ -value=0.002) and GERD (OR 5.22,  $p$ -value=0.006). OGM was independently predicted by IM (OR 2.87,  $p$ -value=0.035), and GERD (OR 3.36,  $p$ -value=0.019). Treatment history was also a predictor of NSMLC (OR 3.38,  $p$ -value=0.028).

**Conclusions:** NSMLC is strongly associated with BE and GERD on multivariable analysis. OGM is associated with IM, and GERD, but to a lesser degree than NSMLC. While our study suggests that SMG metaplasia may be the result of reflux-induced pathology, an association with treatment history was also found. Thus, while reflux appears to be the major contributor to NSMLC, the causes may be heterogeneous.

### 610 Carbonic Anhydrase IX: A Marker of Hypoxia Expressed in Active Ulcerative Colitis

*AJ Carterson, S Rosen, RM Najarian.* Beth Israel Deaconess Medical Center & Harvard Medical School, Boston, MA.

**Background:** Hypoxia in the GI tract is generally regarded as the diminishment or abolition of blood flow resulting, in its acute phase, in frank infarction that is easily identified histologically. Currently, recognition is being given to a more localized hypoxia within the intestinal mucosa which may be present in normal physiologic states, but can be augmented by inflammatory processes such as inflammatory bowel disease. Hypoxia-inducible factor 1 $\alpha$  is upregulated in hypoxic states and its closely allied gene target, carbonic anhydrase IX (CAIX) is present at low intensity in normal intestinal crypt epithelium.

**Design:** Using immunohistochemistry, we investigated whether hypoxia, as indicated by the presence of CAIX-positive colonic crypt epithelium, plays a contributory role in active ulcerative colitis (UC). Distal colonic biopsies in successive cases of symptomatically-active UC were examined ( $n=20$ ), with UC surveillance biopsies in asymptomatic patients ( $n=14$ ) used as "controls". CAIX expression was quantitated by evaluating the number of CAIX-positive epithelial cells/100 crypts and the number of positively-stained epithelial cells/individual crypt.

**Results:** 2642 crypts were examined overall (1478 in the surveillance UC and 1164 in the active UC groups), with 160 and 326 crypts demonstrating positive staining with CAIX, respectively. For every 100 individual crypts examined in surveillance cases, 12 crypts showed positivity with  $0.5\pm 0.1$  CAIX-positive epithelial cells identified per crypt. In contrast, within the active UC cases, 34 crypts showed positivity per 100 crypts examined ( $p=0.001$ ) and contained  $2.5\pm 0.7$  CAIX-positive epithelial cells/crypt ( $p=0.01$ ). Immunoreactivity was most intense in areas of greatest inflammation; however, foci with limited inflammation exhibited prominent epithelial positivity as well. Therefore, in the material examined, there was a distinct increase in CAIX expression, both in terms of individual crypt upregulation and the extent of mucosal staining in patients with active UC versus asymptomatic patients biopsied at surveillance colonoscopy.

**Conclusions:** These findings show that CAIX is consistently expressed in active UC. CAIX upregulation in the colonic mucosa may be an adaptive mechanism aimed at preservation of tissue viability during hypoxic stress. These studies suggest a role for hypoxia in active IBD, supporting studies that have shown that ameliorating hypoxia reduces such injury in experimental models. Further work to investigate the role of hypoxia in IBD and its contributory effects is needed.

### 611 Clinicopathological Characterization of 437 Hyperplastic and Sessile Serrated Polyps

*Z Chen, EA Krauss, L Zhang.* Merck & Co., Rahway, NJ; University Medical Center of Princeton, Plainsboro, NJ; Robert Wood Johnson Medical School, New Brunswick, NJ.

**Background:** Sessile serrated adenoma/polyp (SSA) is a relatively new concept and major differential diagnosis of serrated polyps. Its clinical and pathologic features are not fully understood.

**Design:** We included the consecutive hyperplastic polyp (HP) and SSA specimens collected at our institution from Aug. 2011 to Aug. 2012. With IRB approval, the following data were collected and analyzed: age, sex, polyp site, aggregated polyp size on H&E slide (APS), and synchronous neoplasm (SN) including adenoma, SSA and cancer. Statistical analyses were conducted by using Stata (ver. 12).

**Results:** A total of 437 specimens were chosen including 353 HP and 84 SSA. The APS of SSA was larger than HP ( $0.80\pm 0.56$  cm vs.  $0.47\pm 0.39$  cm,  $P<.0001$ ). Compared with HP, SSA was more likely associated with proximal colon ( $P<.0001$ ) and synchronous SSA ( $P=.0009$ ), but not synchronous HP or synchronous cancer. Multivariate regression analysis (MRA) showed that SSA was more likely diagnosed in the polyps in proximal colon (Odds ratio [OR] 3.6,  $P<.0001$ ), of larger APS (OR 4.0,  $P<.0001$ ) and with synchronous SSA (OR 3.0,  $P=.027$ ). MRA also showed SN was more likely found in patients of male gender (OR 1.94,  $P=.001$ ), of older age (OR 1.02,  $P=.039$ ), and with the index polyp in proximal colon (OR 1.27,  $P=.047$ ), but not related to polyp type (SSA vs. HP) or APS.

**Conclusions:** SSA and HP have equal likelihood of a SN, while male gender, older age and location of the index serrated polyp (HP or SSA) in the proximal colon are more likely associated with a SN. There is no correlation between the size of the index serrated polyp (HP or SSA) and the presence of a SN. To diagnose SSA, larger APS, synchronous SSA, and location in proximal colon may be useful.

Table 1 Characteristics of HP and SSA

	HP (%)	SSA (%)	P*
Case	353 (80.8)	84 (19.2)	
age (yr, mean $\pm$ SD)	59.4 $\pm$ 10.4	57.7 $\pm$ 9.12	0.175
Sex			
Female	191 (54.11)	162 (51.81)	0.715
Male	162 (45.89)	40 (48.19)	
Aggregated polyp size (cm, mean $\pm$ SD)	0.47 $\pm$ 0.39	0.80 $\pm$ 0.56	<.0001
Site in colon			
Right	46 (13.07)	41 (48.81)	<.0001
Transverse	30 (8.52)	29 (34.52)	
Left	276 (78.41)	14 (16.67)	
Synchronous			
None	285 (80.74)	61 (72.62)	0.136
HP	68 (19.26)	23 (27.38)	
Synchronous			
None	337 (95.47)	73 (86.90)	0.009
SSA	16 (4.53)	11 (13.1)	
Synchronous			
None	211 (59.77)	41 (48.81)	0.085
Neoplasm †	142 (40.23)	43 (51.19)	
Synchronous			
None	222 (62.89)	47 (55.95)	0.262
Adenoma & cancer	131 (37.11)	37 (44.05)	

HP: Hyperplastic polyp; SSA: Sessile serrated adenoma/polyp; \*Fisher exact or ANOVA test;

†Includes adenoma, SSA & cancer.

### 612 Semi-quantitative Histologic Evaluation Improves Diagnosis of Esophageal Carcinoma Cuniculatum on Biopsy

*D Chen, J Goldblum, M Landau, R Pai, S-Y Xiao, X Liu.* Cleveland Clinic, Cleveland, OH; University of Chicago, Chicago, IL.

**Background:** Carcinoma cuniculatum (CC), a unique variant of well-differentiated squamous cell carcinoma, has been only rarely reported in the esophagus. Preoperative diagnosis of this entity is extremely difficult, particularly in small biopsies. This study was performed to determine if a previously observed common histologic pattern for CC is diagnostically useful in esophageal mucosal biopsy specimens.

**Design:** Thirty-five esophageal mucosal biopsies from 25 procedures in 11 patients with resection-proven CC were compared to 92 esophageal biopsies from 69 patients with benign diagnoses (control). All biopsies were assessed for the presence of hyperkeratosis, acanthosis, dyskeratosis, abnormal keratinization, intraepithelial neutrophils (IEN), neutrophilic microabscesses (NM), cytologic atypia, koilocyte-like cells, and keratin-filled cysts/burrows. Each feature, if present, was given 1 point, and the final histologic score was calculated for each biopsy by summing the points.

**Results:** The frequencies of each feature in the resections and mucosal biopsies from CC were significantly higher than those in esophageal mucosal biopsies from patients with benign diseases (Figures 1A&B). Mean histologic score was 6.66 (SD 1.88) in

biopsies from CC vs. a mean score of 1.93 (SD 1.75) for biopsies with benign diagnoses ( $p < 0.0001$ ). Using a cut-off value of 7 for CC, 57.1% of biopsies (20/35) from 64% esophagogastroduodenoscopy procedures (16/25) in 90.9% patients (10/11) would be diagnostic, in comparison to the initial diagnostic rates for carcinoma of 8.6%, 12%, and 27.2%, respectively ( $p < 0.0001$  for all). None of the 92 benign biopsies showed a score of  $\geq 7$ .

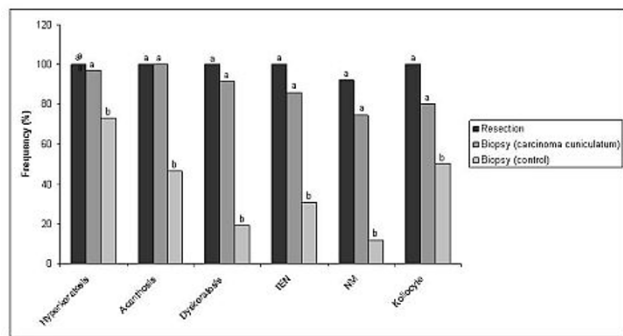


Figure 1A

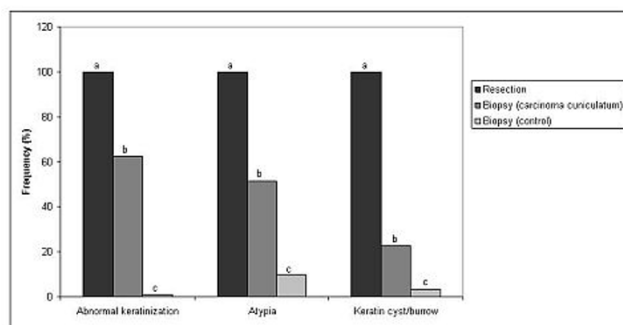


Figure 1B

**Conclusions:** A semiquantitative histologic evaluation of mucosal biopsies taken from an esophageal mass greatly improves the diagnostic sensitivity for CC, with 100% specificity. Larger studies are necessary to confirm these findings.

**613 Like Eosinophilic Esophagitis, Reflux Esophagitis with Moderate to Abundant Eosinophils Is a Type 2 Immune Response with IgE-Staining Mast Cells**

*F Clayton, LA Vinson, KA Peterson.* University of Utah, Salt Lake City, UT.

**Background:** Aspects of the cause of eosinophilic esophagitis (EoE) and its relationship to reflux esophagitis with abundant eosinophils are unclear. Distinguishing them on a pathologic basis is problematic.

**Design:** 18 adults with recently diagnosed EoE were given an elemental diet, generally for 4 weeks. The histologic findings, immunofluorescent and immunoperoxidase staining, and ELISA assays were done on esophageal biopsies before and after treatment. Also examined were 9 to 11 subjects each in the following categories: normal controls, reflux esophagitis with few eosinophils, and reflux esophagitis with  $\geq 3$  eosinophils/hpf (RE-E), but not meeting consensus EoE criteria. Esophageal slides from 56 autopsies (without history of esophageal disease) were also examined for IgE-staining mast cells.

**Results:** On the elemental diet, mean tissue eosinophil content decreased from 54 to 10/hpf. In EoE (before and after treatment) and RE-E, type 2 immune response-related nuclear transcription factors (phosphoSTAT5, phosphoSTAT6, and GATA3) were abundant in the mononuclear inflammatory cells and were dramatically increased compared to normal controls ( $p < 0.05$ ). More than 3 intraepithelial IgE-staining mast cells were present in 96% of EoE cases, 50% of RE-E cases, and only 3% of normal controls ( $p < 0.01$ ). Eotaxin-3 by ELISA and dendritic cells (CD11c staining) also were more abundant in EoE and RE-E than in normal controls ( $p < 0.01$  to 0.05). Findings which best distinguished untreated EoE from RE-E and treated EoE were tissue basophil and CRTH2 immunostaining. Basophils and CRTH2-staining cells were present in 81% and 74% of untreated EoE, but only in 11% and 0% of RE-E cases and 10% and 0% of treated EoE patients, respectively ( $p < 0.01$  for EoE treated versus untreated, and RE-E versus untreated EoE). Immunostaining results for treated EoE and RE-E were not statistically different, except for a less than 2-fold higher GATA3 content in RE-E relative to treated EoE ( $p = 0.03$ ).

**Conclusions:** EoE is a type 2 adaptive immune response, possibly allergic. RE-E was mostly similar to EoE after treatment, having a type 2 polarized inflammatory response with eosinophils, eotaxin-3, appropriate nuclear transcription factors, and increased IgE-staining mast cells. Both lacked the tissue basophils, CRTH2, and the degree of inflammation seen in active, untreated EoE. Further work is needed to determine whether RE-E is a precursor to EoE or, in some cases, a mild, relatively inactive form or phase of EoE.

**614 Gastroduodenal Pathology in Inflammatory Bowel Disease**

*A Cockburn, R Genta.* Miraca Life Sciences Research Institute, Irving, TX.

**Background:** Focal active gastritis has been reported in various percentages of patients with Crohn's disease (CD) (Oberhuber *et al.*, *Gastroenterology* 1997; Sonnenberg *et al.*, *Inflamm Bowel Dis.* 2011) whereas chronic gastritis has been associated with ulcerative colitis (UC) (Lin *et al.*, *Am J Surg Pathol*, 2010). It remains unclear how these findings could help establish a specific diagnosis in patients with suspected inflammatory bowel disease (IBD). This study was designed to assess the prevalence and types of gastritis and duodenitis in patients with a synchronous diagnosis of IBD.

**Design:** Using a nationwide pathology database, we extracted all patients who had a bidirectional endoscopy between Jan 2008 and Dec 2012 and both gastric and ileocolonic biopsies. Study patients were those with a clinicopathologic diagnosis of IBD (UC, CD, or indeterminate, IND); controls were patients with a normal colon and ileum. All subjects with history or diagnosis of malignancy, upper GI surgery, autoimmune, or infectious diseases were excluded. Gastritis was classified according to the Updated Sydney System.

**Results:** There were 699 patients with CD (57.4% female; median age 46 years, range 5-86), 988 with UC (51.6% female; median age 51 years, range 9-93); 246 with IND (47.2% female; median age 50 years, range 3-92); and 26,409 controls (67.3% female; median age 49 years, range 1 mo - 98 years). Table 1 summarizes the results of the gastric pathology. Gastric granulomas were found in 4 patients with CD (0.6%), and in one each of UC, IND, and control subjects. Active duodenitis was significantly more common in all IBD patients (14.4%) than in controls (7.5%), with the highest prevalence (17.6%) in those with CD (OR 2.68, 95% CI 2.07-3.37).

	H. PYLORI-NEGATIVE ACTIVE GASTRITIS			CHRONIC INACTIVE GASTRITIS			H. PYLORI GASTRITIS		
	n	%	OR (95% CI)	n	%	OR (95% CI)	n	%	OR (95% CI)
Normal Controls (n = 26,409)	738	2.8%	1 (ref)	1,257	4.8%	1 (ref)	1,950	7.4%	1 (ref)
Crohn's Disease (n = 699)	156	22.3%	9.99 (6.24-12.11)	77	11.0%	2.48 (1.94-3.16)	31	4.4%	0.58 (0.40-0.84)
Ulcerative colitis (n = 988)	70	7.1%	2.65 (2.06-3.42)	85	8.6%	1.88 (1.49-2.36)	59	6.0%	0.80 (0.61-1.05)
IBD - Indeterminate (n = 246)	30	12.2%	4.83 (3.27-7.13)	17	6.9%	1.48 (0.90-2.44)	19	7.7%	1.5 (0.66-3.69)

**Conclusions:** One in 5 patients with CD and one in 10 with UC have *H. pylori*-negative gastritis (focal or diffuse). While these associations may be pathogenetically important, as they reflect a wide involvement of the gastrointestinal tract in IBD, neither the prevalence nor the type of gastritis and duodenitis are sufficiently distinctive to help pathologists focus on a diagnosis of CD versus UC.

**615 Correlation of Ki67 Labelling Index in FNA and Biopsy of GIST with Ki67 and Mitotic Rate in Resection Specimens**

*JA Collins, WS Twaddell.* University of Maryland Medical Center, Baltimore, MD.

**Background:** Predicting the behavior of gastrointestinal stromal tumors (GISTs) is difficult and dependant on many different factors. Among these, the mitotic rate is particularly important; but even in tumors showing a relatively high mitotic rate this may be as low as 6 mitoses per 50 high-power fields (HPFs). Often, the diagnosis of GIST is made prior to resection or other treatment via biopsy or fine-needle aspiration (FNA). Given the small size of such samples, the 50 HPFs needed to assess for mitoses may not be present, or may not be representative of the final specimen. Immunostaining for Ki67, a protein indicating cellular proliferation, is utilized to calculate proliferation index. Therefore, staining for Ki67 may be useful for assessing proliferative rate in small GIST specimens obtained prior to resection.

**Design:** 19 cases were identified by a retrospective review in which both a resection specimen and a pre-resection were available: 18/19 were from the stomach, 1/19 from the duodenum with 13/19 from cytological specimens and 6/19 from biopsies. The mitotic rate was determined by 2 independent reviewers and the mean calculated. Immunohistochemical staining for Ki-67 was performed on all specimens and quantitated by computer-assisted image analysis using the Aperio system. The Ki-67 index of the cytology or biopsy specimen was correlated to the Ki-67 index and mitotic count of the final resected specimen.

**Results:** The Ki-67 index for the resection specimen was dichotomized based on the mitotic count of 5/HPF. For  $\leq 5/50$ hpf (n=11) the range was from 0.5-3.76 and for  $>5/50$ hpf (n=8) the range was from 5-25. Correlation between mitotic count and ki-67 index on resection is  $r^2=0.94$  with a p-value  $< 0.0001$ . The mean Ki-67 count for mitotic counts  $\leq 5$  is 1.8 (1.04-2.47 95% CI), the mean Ki-67 count for mitotic rates  $> 5$  is 9.3 (2.37-16.2 95% CI). Correlation of Ki-67 index between cytological/biopsy specimen and resection specimen is  $r^2= 0.33$  (p-value  $< 0.001$ ) but with exclusion of inflamed biopsy specimens (in which staining of inflammatory cells may inflate the proliferative index) correlation is  $r^2= 0.73$  (p-value  $< 0.0001$ ).

**Conclusions:** The importance of mitotic rate in risk stratification for GISTs is well-accepted and is incorporated into the cancer protocols used by the College of American Pathologists (CAP). In the context of our limited study it appears that the utilization of Ki67 in biopsies and cytological specimens has a good correlation to the final specimen.

**616 MiRNA Profiling of Colorectal Carcinoma and Lymph Node Metastases**

*S Costinean, V Balatti, P Dama, L Cascione, J Rock, CM Croce, WL Frankel.* Ohio State University, Columbus, OH.

**Background:** Colorectal cancer (CRC) is the third cause of death due to cancer in the US. Many of these deaths are due to the lack of early diagnosis and widespread metastases at the time of presentation. The molecular mechanisms of metastasis have



been intensively studied in recent years. miRNAs are involved in posttranscriptional regulation. Studies show that miRNAs are deregulated in cancer and could represent a genetic signature of normal and malignant tissues. Deregulation of specific miRNAs could be partially responsible for the metastatic potential of a tumor. Knowing the mechanism of metastasis has prognostic and therapeutic applicability. We compare miRNA profiles of microsatellite stable colorectal carcinomas (MSS-CRC) to corresponding lymph node (LN) metastases to assess differences.

**Design:** We selected 40 MSS-CRC and 42 corresponding LN metastases from the tissue archives. MSS-CRC were identified by previously documented intact mismatch repair proteins by immunohistochemistry. Representative areas of the tumors (primary and metastatic) were cored. RNA was analyzed using Nanostring.

**Results:** We identified 12 miRNAs deregulated in LN vs. the corresponding CRC. 6 miRNAs were upregulated in the LN compared to the CRC (miR150, miR142-3p, miR342-3p, miR195-5p, miR146-5p and miR4741) and 6 were downregulated (miR200a-3p, miR200b-3p, miR200c-3p, miR429 and miR196b-5p). Of these genes, miR150 seems to have the highest level of expression in the metastases compared to the primaries: 3.1 times more expressed in the LN compared to the CRC.

**Conclusions:** A limited number of miRNAs are markedly deregulated in the LN metastases compared with the CRC. MicroRNA miR150, a known repressor of the powerful p53 protein, was identified as being 3.1 times more expressed in the metastases compared to the primaries. In contrast, all 3 members of the miR200 family (a, b and c), targeting a large array of important transcription factors, were found downregulated in metastases compared to primaries. These miRNAs offer important insight into mechanisms possibly responsible for initiation of the metastatic process in CRC and might suggest novel molecular therapies.

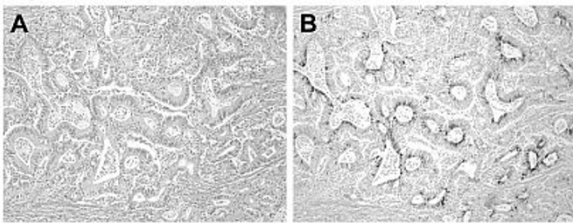
### 617 Napsin-A Expression in Esophageal and Gastric Adenocarcinoma Affected by Choice of Primary Antibody

MW Cruise, EA Montgomery, JM Davison, RK Pai, AD Singhi. Johns Hopkins University, Baltimore, MD; University of Pittsburgh Medical Center, Pittsburgh, PA.

**Background:** Distinguishing between a primary lung and esophageal adenocarcinoma can be challenging, especially in small biopsies and EUS, and a reliable IHC stain would be helpful. Napsin-A is normally expressed in the cytoplasm of type II pneumocytes and has been reported to be a sensitive and specific marker for primary lung adenocarcinomas. Recently, napsin-A expression has also been demonstrated in papillary renal cell and thyroid carcinoma. However, there are no published studies examining napsin-A expression in esophageal adenocarcinomas.

**Design:** A total of 1088 esophageal and 215 gastric adenocarcinoma resection specimens were identified and confirmed to be esophageal or gastric primary adenocarcinoma. FFPE tissue sections were stained with a monoclonal antibody (Clone IP64, cat# NCL-L-Napsin A; Leica Biosystems) and a polyclonal antibody (rabbit polyclonal, cat# 352A; Cell Marque) against napsin-A. Of note, both of these antibodies are utilized in clinical labs. Strong granular cytoplasmic staining was interpreted as positive.

**Results:** The mean age of the patient population is 64 and there was a male predominance with most of the patients having stage III or IV disease. Evaluation of the esophageal adenocarcinomas with the polyclonal antibody demonstrates cytoplasmic staining in 36% of the specimens. In contrast, the monoclonal antibody was negative, only labeling the control lung tissue. Interestingly, only 2 of the gastric tumors were positive for napsin-A by the polyclonal antibody but all were negative by with the monoclonal antibody. Panel A of the figure demonstrates the H&E of an esophageal adenocarcinoma and Panel B demonstrates the corresponding labeling by the polyclonal napsin-A antibody.



**Conclusions:** The usefulness of Napsin-A in determining the differential diagnosis between esophageal adenocarcinoma and pulmonary adenocarcinomas appears to be related with the primary antibody used. Specifically, the monoclonal antibody against napsin-A did not stain the tumors while the polyclonal antibody labeled greater than 1/3 the esophageal adenocarcinomas. Importantly, the expression of napsin-A, as demonstrated by the polyclonal antibody, did not correlate with stage or progression of the disease.

### 618 Intratumoral Budding (ITB) in Pre-Operative Biopsies: A Strong Indicator of Lymph Node Positivity in Colon and Rectal Cancer Patients

H Dawson, M Haedrich, V Koelzer, D Inderbitzin, M Borner, I Zlobec, A Lugli. Institute of Pathology, University of Bern, Bern, Switzerland; Inselspital, Bern University Hospital, Bern, Switzerland; Centre Hospital Biel, Biel, Switzerland.

**Background:** Conventional tumor budding in colorectal cancer occurs at the invasion front and despite its well-established value as an indicator of tumor progression cannot be assessed in preoperative biopsies. Nonetheless, tumor budding can be observed within the main tumor body and therefore the term "intratumoral budding, ITB" was introduced in 2011 to describe this occurrence. The aim of this study was to investigate the possible clinical role of ITB in pre-operative biopsies.

**Design:** Pan-cytokeratin (AE1/AE3) staining was performed on 139 pre-operative biopsies from patients with colorectal cancer treated at the Bern University Hospital, Switzerland between 2002-2011. Based on receiver operating characteristic (ROC) curve analysis, high-grade ITB was defined as >10 buds/hotspot (40x).

**Results:** On average, 8.2 biopsies were taken per case of which 81% contained cancer. High-grade ITB was detected in 26.6% of all patients and linked to more advanced pT (p=0.02) and pN (p<0.001) stage, higher tumor grade (p=0.004) and lymphatic node metastasis was 86.7% and 75.6%, respectively. This result was confirmed for patients with either rectal (p=0.033) or colon (p=0.007) cancer and independent of the number of biopsies taken (p=0.008).

**Conclusions:** ITB predicts lymph node positivity in both colon and rectal cancer and therefore should be considered in the pre-operative management of these patients.

### 619 Correlation of Mutational Change with Histological Disease Progression in Barrett's Esophagus

G Deftereos, C Narick, JF Silverman, LL Freed, EMG Ellsworth, SA Jackson, SD Finkelstein. Allegheny General Hospital, Pittsburgh, PA; RedPath Integrated Pathology, Inc., Pittsburgh, PA.

**Background:** Barrett's Esophagus (BE) is a pre-cancerous condition that can progress to low grade dysplasia (LGD) and/or high grade dysplasia (HGD) and ultimately to adenocarcinoma. Current BE classification is based on microscopic features. Although mutations are fundamental to disease progression, the role of mutational analysis to help better classify and characterize BE remains unclear.

**Design:** Formalin-fixed, paraffin-embedded gastroesophageal biopsy/resection specimens from 42 patients were examined. From those, 89 targets representing areas histologically diagnosed as intestinal metaplasia (IM), LGD, HGD and carcinoma (CA) were microdissected and examined for loss of heterozygosity (LOH) and microsatellite instability (MSI) using PCR/capillary electrophoresis. A panel of 22 DNA markers at 10 different genomic loci was tested. The frequency which mutations occurred at each genomic locus for each histology was determined.

**Results:** The percentage of targets with mutations at each locus generally increased with progressively worse histology. In targets diagnosed as CA, nearly all loci examined were mutated in ≥ 50% of targets (Table). Mutations of TP53 (17p) and CDKN2A (9p), known to play an important role in progression of BE to cancer, were among the most frequently detected in IM, but were always accompanied by other mutations in LGD/HGD. Of note, the size of chromosomal deletion as well as evidence of MSI increased in relationship to progressive level of dysplasia.

Histological Classification	Number Of Mutations At Each Genomic Locus									
	1p	3p	5q	9p	10q	17p	17q	18q	21q	22q
IM n=19	4 (21%)	1 (5%)	2 (11%)	10 (53%)	0 (0%)	3 (16%)	5 (26%)	2 (11%)	0 (0%)	0 (0%)
LGD n=22	5 (23%)	11 (50%)	6 (27%)	14 (64%)	2 (9%)	15 (68%)	7 (32%)	10 (45%)	5 (23%)	2 (9%)
HGD n=32	15 (47%)	14 (44%)	10 (31%)	25 (78%)	10 (31%)	29 (91%)	13 (41%)	23 (72%)	11 (34%)	9 (28%)
CA n=16	15 (94%)	14 (88%)	6 (38%)	14 (88%)	7 (44%)	14 (88%)	9 (56%)	14 (88%)	10 (62%)	8 (50%)

**Conclusions:** Using a panel of genomic loci readily detects mutations associated with HGD and CA. Many of the loci were also frequently mutated in LGD and IM, suggesting that these mutations begin to accumulate early during BE and may play a role in driving the morphological changes associated with disease progression. Various patterns of molecular change are increasingly more evident from dysplasia to carcinoma, including deletion size and microsatellite instability. Analyzing patterns of molecular changes that correlate with histologic stages of disease progression may add an additional dimension to the microscopic evaluation of BE.

### 620 sLe<sup>a</sup> on CD44v6 Is a Potential Biomarker of Severity in Inflammation-Associated Mucosal Disease

MA Delgado, JC Brazil, NA Louis, CA Parkos, AB Farris. Emory University, Atlanta, GA.

**Background:** A paucity of effective markers limits inflammatory bowel disease (IBD) progression risk stratification and therapeutic response prediction. CD44v6 protein expression is upregulated in IBD and cancer. The tetrasaccharide glycoepitope sLe<sup>a</sup> has been described as a prognostic marker in IBD patients with primary sclerosing cholangitis associated cholangiocarcinoma. We generated a novel monoclonal antibody (GM35) that recognizes sLe<sup>a</sup> displayed on CD44v6 with great affinity. Using GM35 and an anti-peptide CD44v6 mAb, we characterized staining for CD44v6 and sLe<sup>a</sup> on CD44v6 in chronic active colitis (CAC), chronic colitis (CC) and uninvolved mucosa (UM) in ulcerative colitis (UC) and Crohn's disease (CD).

**Design:** IBD patients (n = 24, 13 UC and 11 CD) were included with tissue from different colonic portions ranging from severe chronic active colitis to uninvolved mucosa (21 CAC, 18 CC and 15 UM). Both biopsies and resections were included (with 1-3 representative sections/patient). Slides were immunostained with either anti-CD44v6 mAb or GM35. Apical surface, cytoplasmic, basal membrane and lateral membrane staining intensities were graded on a 5-tier scale from 0-4 in CAC, CC and UM. T-test or Chi square tests were performed.

**Results:** Statistically significant differences in staining patterns were found between the CD44v6 anti-peptide mAb and GM35. CD44v6 protein expression was seen at the basolateral membrane while GM35 bound to sLe<sup>a</sup> in the cytoplasm and cell apex (Table 1). Anti-CD44v6 mAb stained the mucosal lower half while GM35 stained the upper half (Chi square p = <0.0001, for the distribution). CD44v6 staining became full thickness with increasing disease severity (Chi square p = <0.0001). Further, GM35 stained neutrophils in crypt abscesses while anti-CD44v6 mAb did not. There was no statistically significant difference in staining of either molecule between UC and CD.

**Table 1: Staining Intensity**

	CD44v6 (Mean ± S.D.)	sLe <sup>a</sup> (GM35) (Mean ± S.D.)
Apical surface	0	2.05 ± 1.81*
Cytoplasm	0.15 ± 0.36	1.05 ± 1.20*
Basal membrane	2.13 ± 0.94	0.02 ± 0.13*
Lateral membrane	2.13 ± 0.96	0.09 ± 0.39*

\*CD44v6 and sLe<sup>a</sup> intensity difference statistically significant, p = <0.0001 (T-test)

**Table 2: Staining intensity by disease severity**

		CAC (Mean ± S.D.)	CC (Mean ± S.D.)	UM (Mean ± S.D.)
CD44v6	Apical surface	2.7 ± 1.0	1.7 ± 0.59***	1.7 ± 0.80**
	Basal membrane	2.7 ± 1.0	1.7 ± 0.58**	1.7 ± 0.80**
	Lateral membrane	2.8 ± 1.0	1.7 ± 0.59***	1.7 ± 0.80**
sLe <sup>a</sup> (GM35)	Apical surface	2.7 ± 1.8	1.9 ± 1.8	1.1 ± 1.5*
	Basal membrane	0.045 ± 0.21	0	0
	Lateral membrane	0.23 ± 0.61	0	0

CAC vs CC and UM statistically significant: \*0.05>p>0.005, \*\*0.005>p>0.0005, \*\*\*p<0.0005

**Conclusions:** We have shown differential expression of CD44v6 and sLe<sup>a</sup> on CD44v6 (GM35) in colonic mucosa with varying severities of IBD, suggesting that post-translational modifications, and in particular the glycosylation status of CD44v6, plays an important role in inflammation. Targeting sLe<sup>a</sup> with specific mAbs such as GM35 thus warrants further investigation as an inflammation-associated disease process biomarker.

**621 Interstitial Cells of Cajal in Gastrointestinal Leiomyoma**

A Deshpande, V Deshpande, MJ O'Brien. Boston Medical Center, Boston, MA; Massachusetts General Hospital, Boston, MA.

**Background:** Leiomyomas (LM) of the gastrointestinal tract arise within the muscularis mucosae (superficial) and muscularis propria (deep). There are isolated reports of CD117 positive cells, presumed interstitial cells of Cajal (ICC) within gastrointestinal leiomyomas. We have encountered esophageal LM with high proportion of CD117 and DOG1 positive spindle shaped cells, an appearance that mimicked gastrointestinal stromal tumor (GIST). Our aim was to explore the prevalence of ICC in LMs of the gastrointestinal tract and to explore the etiopathogenic significance of these cells in this benign neoplasm.

**Design:** We identified 30 esophageal LMs, 7 gastric LMs and 3 small bowel LMs (all lesions in muscularis propria). We performed immunohistochemical stains for desmin, CD117 on these neoplasms. In addition immunohistochemical stains for DOG-1 (n=10), CD34 (n=10), and mast cell tryptase (n=4) were performed. We also evaluated a selected cohort (n=12) of superficial colonic LMs. ICC were distinguished from mast cells based on morphology (elongated and occasionally branching spindle shaped cells) and the presence of DOG-1, and CD34 reactivity and absence of tryptase activity.

**Results:** There were 22 males and 18 females. The mean age was 56 years. 10 of the esophageal LMs were incidentally detected (mean size 0.5 cm), the other 20 were non-incidentally (mean size 3.4 cm). ICC were identified in all esophageal LMs and constituted an average of 20% of the neoplastic cells. Focally, these cells constituted up to >50% of the lesional cells. The density of these cells was significantly higher than the background muscularis propria. Hyperplasia of ICC was not identified in the adjacent muscle. ICC were identified in 5 of 7 gastric LMs and they constituted an average of 5% of the neoplastic cells. ICC were identified in 1 of 3 small bowel LMs and were entirely absent in all superficial colonic LMs.

**Conclusions:** ICC are universally present in deep esophageal LMs, and may be mistaken for GISTs, particularly on biopsy samples, an error associated with adverse clinical consequence. ICC are also identified in gastric and intestinal LMs, albeit in a smaller proportion of cases. Intralesional ICC could either represent hyperplastic ICC colonizing LM; alternatively, these LMs may represent a hamartomatous process.

**622 Systemic Mastocytosis of the Gastrointestinal Tract: Clinicopathologic Analysis of 21 Cases**

LA Doyle, MJ Hamilton, C Akin, MC Castells, JL Hornick. Brigham and Women's Hospital, Harvard Medical School, Boston, MA.

**Background:** The major diagnostic criterion for systemic mastocytosis (SM) is the presence of mast cell aggregates in bone marrow or extracutaneous organs. The diagnosis of mastocytosis in gastrointestinal (GI) mucosal or liver biopsies therefore has significant therapeutic and prognostic implications, but the features of SM in GI biopsies are not well described. The aims of this study were 1) to determine the utility of GI biopsies for the diagnosis of SM and 2) to characterize the clinical, histologic and immunohistochemical features of SM in the GI tract.

**Design:** 21 patients with SM involving the GI tract were identified. Clinical, pathologic and immunohistochemical features were evaluated.

**Results:** 98 GI/liver biopsies (65 involved by SM; 62 mucosal, 3 liver) from 17 women and 4 men were evaluated (median age 55 yrs; range 18-77). The most commonly involved site was colon (17 patients, 81%) followed by duodenum (10), stomach (5), ileum (5), and liver (3). 15 patients had documented cutaneous mastocytosis. In 14

cases (67%) the first diagnosis of SM was made on GI biopsy. 17 patients had indolent disease and 4 aggressive (including 2 of 3 with liver involvement). 10 patients had documented D816V KIT mutation. Symptoms included diarrhea (15), abdominal pain (8), nausea (6), weight loss (3), and bloating, vomiting or reflux (2 each). Liver disease presented with hepatomegaly and ascites. Endoscopic abnormalities (in 58%) included erythema, granularity and nodules. Histologically, biopsies showed lamina propria infiltrates of ovoid to spindle-shaped mast cells in aggregates or sheets. 15 biopsies had only focal involvement (single aggregate). Mast cell density ranged from 42-278 per HPF (median 125). Prominent eosinophils were seen in 48% of involved colonic/ileal and 17% of gastric/duodenal biopsies; 2 patients were initially misdiagnosed as eosinophilic colitis. 16 (26%) positive biopsies showed other findings: architectural distortion (4), chronic duodenitis (3), villous blunting (4), chronic gastritis (3), and chronic active colitis (2; patient with co-existing ulcerative colitis). Mast cells were highlighted by diffuse staining for KIT and CD25 in all cases. Expression of tryptase was variable; 57% showed only scattered positive cells.

**Conclusions:** GI (especially colonic) biopsies can establish a diagnosis of SM in patients with GI symptoms. GI involvement is usually subtle and often associated with an eosinophilic infiltrate, which may obscure the mast cell infiltrate. KIT and CD25 are invaluable markers for the diagnosis. GI involvement does not correlate with aggressive disease.

**623 Hedgehog Pathway Proteins Glioma-Associated Oncogene-1 (GLI-1) and Smoothed (Smo) Expression in Colorectal Cancer (CRC)**

O Elkadi, D Middleton, M Barrett, DM Jones, CE Sheehan, JS Ross. Albany Medical College, Albany, NY.

**Background:** The Hedgehog (Hh) signaling pathway is involved in the normal organ development during embryogenesis and been implicated in the development of numerous pediatric and adult malignancies. The recent approval of the hedgehog pathway inhibitor vismodegib for basal cell skin cancer has prompted keen interest in finding additional indications for this drug in other tumor types such as CRC.

**Design:** Formalin-fixed, paraffin embedded sections from 156 colorectal adenocarcinomas (CRCs) were immunostained by automated methods (Ventana Medical Systems, Inc, Tucson, AZ) with goat polyclonal GLI-1 and Smo antibodies (Santa Cruz Biotechnology, Inc, Santa Cruz, CA). Nuclear and cytoplasmic immunoreactivity for each protein was semiquantitatively assessed in the tumor for all cases. Scoring was based on staining intensity and distribution and results were correlated with morphologic and prognostic variables.

**Results:** Nuclear GLI-1 overexpression was noted in 42% tumors and correlated with early AJCC stage (51% of stage I/II and 33% stage III/IV; p=0.025), negative lymph node status (56% of node negative and 30% of node positive, p=0.001), and lengthened overall survival (Cox univariate, p=0.049). Cytoplasmic GLI-1 overexpression was noted in 64% tumors, but there were no significant correlations. Nuclear Smo overexpression was noted in 79% tumors and correlated with high tumor grade (88% of grade 3 vs 78% grade 2 vs 56% grade 1, p=0.017). Cytoplasmic Smo overexpression was noted in 43% tumors, but there were no significant correlations other than with nuclear Smo immunoreactivity (p=0.001) in the same case. On multivariate analysis, pathologic stage (p<0.0001) independently predicted overall survival.

**Conclusions:** Nuclear GLI-1 protein expression in CRC is associated with favorable prognostic variables, including early stage, negative node status, and lengthened overall survival; while increased nuclear Smo protein expression is associated with high tumor grade. We conclude that hedgehog pathway signaling may play a role in CRC development and progression warranting further study.

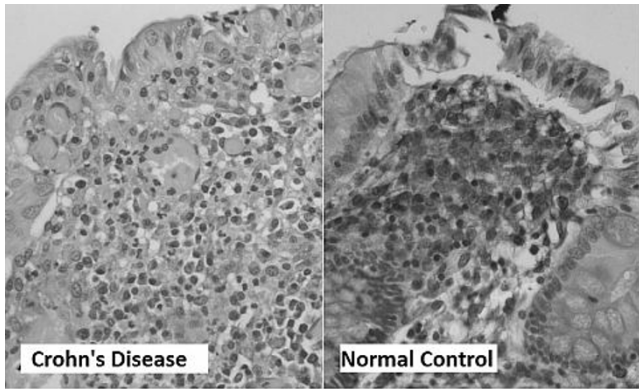
**624 A Potential Role of Annexin A5 in Inflammatory Bowel Disease**

KA Friedman, E Lin, Y Wu, A Nguyen, J Sunkara, Q Liu, J Rand. Montefiore Medical Center, Bronx, NY; CUNY-Queensborough, Queens, NY.

**Background:** The intestine has a remarkable tolerance to resident flora, the details of which are unknown. Annexin A5 (AnxA5) is a protein that protects cell membranes from auto-antibodies by forming a shield, the loss of which is associated with antiphospholipid syndrome. Our previous work has shown that AnxA5 can directly bind lipopolysaccharide (LPS) and block inflammatory response to Gram-negative bacteria. Abnormal down-regulation of AnxA5 in macrophages may result in loss of protection against LPS, leading to immune dysregulation. We hypothesized that AnxA5 expression is decreased in inflammatory bowel disease (IBD) as compared to normal patients.

**Design:** Paraffin embedded colon or small bowel tissue sections from 13 patients with resections for ulcerative colitis (UC) or Crohn's disease (CD) and 6 sections of control tissue from benign margins in colonic resections were selected and immunohistochemically stained with antibodies to AnxA5 and PGM1 for macrophages. ImageJ (NIH) was used to measure the ratio of macrophage to background staining. Double fluorescent microscopy using green fluorescent protein (GFP) for macrophages and AnxA5, and quantitative PCR were performed in a mouse model of IBD and compared to normal. Statistical analysis was performed using a two-tailed t-test.

**Results:** Macrophages subadjacent to the colonic epithelium in UC and CD patients had significantly smaller stain ratios for AnxA5 as compared to controls (0.02 vs 0.12, p=0.01), with no significant difference between UC and CD (0.016 vs 0.020, p=0.5). There was also a decrease in GFP+/AnxA5+ macrophages in IBD mice, despite an overall increase in GFP+ cells. Finally, qPCR revealed a 5 fold decrease in AnxA5 expression by LPS-stimulated macrophages from IBD mice, while inflammatory cytokines were overexpressed 6 fold.



**Conclusions:** This study shows that reduction of expression of AnxA5 by gut macrophages correlates with IBD on histology. The IBD mouse model verifies this reduction along with an increase in inflammatory cytokines. Further exploration is needed to elucidate the role of AnxA5 in the pathogenesis of IBD. To our knowledge, this is the only study to characterize the expression of AnxA5 in human IBD.

## 625 Spectrum of Histopathological Changes Encountered in Stented Colorectal Carcinomas (CRC)

*E Fryer, LM Wang, R Guy, R Chetty.* John Radcliffe Hospital, Oxford, United Kingdom.

**Background:** Presentation with obstruction is a poor prognostic feature in CRC, with surgery for obstruction carrying higher mortality and complication rates. Stenting can be used as a "bridge to surgery", allowing optimisation of patient condition before surgery. Our institution has excellent clinical experience with stenting, with a high rate of successful relief of obstruction and subsequent elective surgery. Elective surgery results in better outcomes in terms of stoma avoidance and more rapid recovery as many cases can be performed laparoscopically. The histological features produced by stenting in the colon are poorly documented, with only case reports and one small case series reported. We present the largest series to date of stented CRC, performed and reported at a single institution.

**Design:** Stented CRC received January 2006 - December 2011 were identified from our pathology database using the search term "stent" in the clinical information or macroscopic description. The slides for each case were independently reviewed by two pathologists and a consensus reached.

**Results:** 72 CRC were identified, 15 right sided (including 2 from the ascending colon) and 57 left sided. 36 were stage pT3 and 36 pT4. Diverticulosis was present in 14 cases. Perforation was observed in 14 cases (8 tumour related, 6 non-tumour related). The effects of stenting on the tumour include tumour necrosis (100%) with flat ulceration (77.8%). Stent effects on the uninvolved bowel are given in table 1. The spectrum of changes includes mimics of inflammatory bowel disease, tumour regression post-neoadjuvant therapy and ischaemia.

Stent-associated features in background bowel

Feature	No. of cases (%)
Mimics of IBD	
Hyperplastic mucosa	53 (73.6)
Pseudopolyp-like features	35 (48.6)
Fissuring ulceration	24 (33.3) [median depth 2.5 mm, range 1-13 mm]
Fissures without ulceration	14 (19.4)
Mucosal Crohn's like features	10 (13.9)
Eosinophil-rich inflammation	6 (8.3)
Abscess formation	5 (6.9)
Granulomas	0
Mimics of neoadjuvant regression	
Fibrosis	37 (51.4)
Mucin pools	18 (25)
Foreign body giant cells	13 (18.1)
Calcification	9 (12.5)
Other features	
Ischaemia-like features	54 (75)
Fat necrosis	6 (8.3)

**Conclusions:** Given the success of our institution with stenting of colorectal tumours as a bridge to surgery, we anticipate seeing increasing numbers of such cases. From our study, a wide range of changes are encountered. They may mimic other bowel diseases from simple fissuring through to chronic inflammatory bowel disease and neoadjuvant regression change.

## 626 Histologic Features Predicting High Risk of Submucosal Invasion in Mucosal Biopsies of Esophageal Adenocarcinoma

*B Fu, T Foxwell, H Hu, AM Krasinskas, KS Nason, JM Davison.* University of Pittsburgh School of Medicine, Pittsburgh, PA.

**Background:** Esophageal adenocarcinoma (EAC) is diagnosed at an early, superficial stage with increasing frequency. In some cases, treatment options depend entirely on the extent of local invasion. Pathologists are often challenged to make the distinction in mucosal biopsies between early, intramucosal and more locally advanced EAC, which can be difficult in the absence of endoscopic ultrasound and other clinical correlates. We designed a case control study to evaluate the odds of submucosal invasion associated with different morphologic patterns seen in mucosal biopsies of EAC.

**Design:** We identified pre-operative endoscopic mucosal biopsies from 43 patients with adenocarcinoma of the distal esophagus or GE junction demonstrating at least

submucosal invasion (stage T1b-T4). For controls, we identified biopsies from 29 patients with high grade dysplasia or intramucosal adenocarcinoma (stage Tis-T1a). All patients were treated by esophagectomy without induction therapy between 1996 and 2010. Blinded to the final pathologic stage, we evaluated the pre-operative biopsies for the presence of multiple morphologic patterns believed to correlate with early mucosal invasion (e.g. foci of single cell invasion) as well as patterns that may be indicative of more advanced local invasion (e.g. desmoplasia).

**Results:** Results are summarized in Table 1.

Table 1	T Stage Classification at Esophagectomy			p-value
	T1b-T1a [N=29]	T1b-T4 [N=43]	Crude OR [95% CI]	
<b>Group A: Features with Significant Risk of T1b-T4 Invasion</b>				
Ulcerated carcinoma	10.3%	74.4%	25.2 (6.4-100)	<0.001
Haphazard infiltration	28.0%	90.7%	24.4 (6.5-90.9)	<0.001
>2 foci of single cell invasion	13.8%	60.5%	9.6 (2.8-32.4)	<0.001
Cells/glands obliterating the LP (>50% of tumor)	14.3%	55.8%	7.6 (2.2-25.6)	0.001
Never-ending pattern	13.8%	55.8%	7.9 (2.3-26.6)	0.001
Poorly differentiated carcinoma (>5% of tumor)	6.9%	31.0%	6.1 (1.2-29.3)	0.025
Complex atypical papillary structures	0.0%	25.0%	N/A	.002*
<b>Group B: Rare Features of T1b-T4 Invasion</b>				
Unequivocal desmoplasia	0.0%	16.3%	N/A	.037*
Pagetoid spread	0.0%	2.3%	N/A	1.000*
Destructive invasion of adjacent glandular mucosa	0.0%	7.0%	N/A	.259*
Definite angiolymphatic invasion	0.0%	2.3%	N/A	1.000*
Cytologic anaplasia at 10x	0.0%	7.0%	N/A	.273*
Poorly differentiated carcinoma (>50% of tumor)	3.4%	11.9%	3.8 (0.4-31.2)	0.236
<b>Group C: Features that Do Not Distinguish Tis-T1a from T1b-T4 Invasion</b>				
Cribiform or back to back glands	51.7%	67.4%	1.9 (0.7-5.1)	0.182
Dilated glands w/ luminal debris	48.3%	32.0%	0.5 (0.2-1.4)	0.182
Budding tubule pattern	51.7%	60.5%	1.4 (0.6-3.7)	0.463
Abortive angulated glands	27.0%	51.2%	2.8 (1.0-7.6)	0.050
Neoplastic glands involving squamous ep.	27.0%	32.0%	1.3 (0.5-3.6)	0.054
Solid growth pattern	7.1%	23.3%	3.9 (0.8-19.6)	0.094

\* Fisher's exact test

Several morphologic features (Group A) were significantly more common in T1b-T4 EAC. The greatest odds of submucosal invasion was associated with ulcerated adenocarcinoma. Desmoplasia was one of several rare features (Group B) seen almost exclusively in T1b-T4 EAC. A final group of morphologic characteristics (Group C) was present with nearly equal frequency in Tis-T1a and T1b-T4 EAC.

**Conclusions:** Unequivocal desmoplasia was rarely identified in mucosal biopsies of locally advanced (T1b-T4) EAC. Multiple histologic features in addition to desmoplasia can be used to assess the risk of submucosal or deeper local invasion in EAC in pre-operative mucosal biopsies.

## 627 Prevalence of Different Polyp Types in MSI and MSS Age and Gender Matched Cohorts of Colorectal Cancer Resections

*D Gibbons, CH Ng, R Geraghty, E Rinehart, J Hyland, RP O'Connell, D Winter, H Mulcahy, G Doherty, D O'Donoghue, F David, S Kieran.* St Vincent's University Hospital, Dublin, Ireland; Brigham and Women's Hospital, Boston, MA.

**Background:** The sessile serrated pathway has gained increased recognition in recent years. Up to 30% of colorectal tumours are thought to arise in this manner. The significance of sessile serrated adenomas (SSAs) in this pathway is being elucidated. We sought to establish the prevalence and significance of this finding in curative resections for colorectal carcinoma.

**Design:** All colorectal carcinomas resected with curative intent, with immunohistochemical characterization of microsatellite status at diagnosis, over an eight year period were identified. 1415 colectomy specimens were identified of which 126 had microsatellite instability (MSI). An age and gender matched MSS cohort was generated. A careful gross examination described and sampled all polyps. All polyps were reviewed, enumerated and classified as SSA (sessile serrated adenoma), adenoma or hyperplastic. Appendiceal polyps were excluded. Mean numbers of polyps, total and subtypes were compared in the MSI and MSS groups. A two-tailed t-test was used.

**Results:** 57% of MSI cases and 50% of MSS cases had polyps in the resection. In MSI cases there were a total of 5 SSAs, 92 adenomas and 37 hyperplastic polyps, total = 134. In MSS cases there were 0 SSAs, 62 adenomas and 23 hyperplastic polyps, total = 95. There was no significant difference in numbers of adenomas, hyperplastic polyps or total polyps in both groups. However there were significantly more SSAs in the MSI group (p=0.0239).

Polyp Numbers in MSI and MSS Resections

	MSI	MSS
Total Polyps	134	85
Adenomas	92	62
Hyperplastic	37	23
SSAs	5	0

**Conclusions:** Although absolute numbers are low, the finding of an SSA in a cancer colectomy specimen is a strong indicator that the carcinoma will be microsatellite unstable (MSI).

### 628 Well Differentiated Neuroendocrine Tumors of the Duodenum: A Clinicopathologic Profile and Somatostatin Receptor 2 Expression

MA Gilger, L Cassani, E Lindsey, F Revetta, E Liu, C Shi. Vanderbilt University School of Medicine, Nashville, TN.

**Background:** Duodenal neuroendocrine tumors (NETs) present as either functional or nonfunctional tumors. Based on the World Health Organization (WHO) grading system, duodenal NETs are further classified into grade 1 (G1) or grade 2 (G2) well-differentiated NET or grade 3 (G3, poorly differentiated) neuroendocrine carcinoma. Expression of somatostatin receptor 2 (SSTR-2) has been described in other NETs including pancreatic and small intestinal NETs. In this study, we examined 36 cases with duodenal NET and their expression of SSTR-2.

**Design:** Between 2003 and 2012, 36 patients with a diagnosis of duodenal NET were identified from our surgical pathology database. Demographics and clinical data were obtained from our electronic clinical database. Immunohistochemical (IHC) stains for Ki-67 and SSTR-2 expression were performed on paraffin-embedded formalin fixed tissue. The IHC results were interpreted by 2 pathologists.

**Results:** Of the 36 patients, 19 were males and 17 were females, with a mean age of 57.5 years (range 38 to 84 years). 46 total specimens were identified from the 36 patients; 24 cases were biopsies, 13 were Whipple resections, and 9 were local excisions. 13.9% of patients (5/36) had functional tumors, 4 of these were gastrinomas and 1 was a somatostatinoma. 52.8% of patients (19/36) were symptomatic while 47.2% (17/36) were incidental findings. 7% (4/36) patients had an associated diagnosis of multiple endocrine neoplasia syndrome – type 1. Of cases with endoscopic data available, 54.5% (12/22) were nodules, 40.9% (9/22) were polyps, and 4.6% (1/22) was an ulcer. There were 23 G1, 12 G2, and 1 G3 based on mitotic rate and Ki-67 proliferative index. Out of the 5 functional tumors, 2 were G1, 2 were G2, and 1 was G3. SSTR-2 staining in a membranous pattern was observed overall in 33/36 (91.7%) of cases. Staining was observed in 87.0% of G1 (20/23), 100% of G2 (12/12), and 100% of G3 (1/1). 4 of the 5 (80%) functional tumors expressed SSTR-2.

**Conclusions:** The majority of duodenal NETs are well-differentiated and non-functional. SSTR-2 shows strong membranous staining in over 91% of duodenal NETs. SSTR-2 can be potentially used in cancer imaging and targeted therapeutic strategies for duodenal NETs.

### 629 Prevalence and Characteristics of Lymphocytic Esophagitis in Barrett's Esophagus

KL Golden, C Sanchez, D Cowan, B Reid, P Blount, R Odze, A Srivastava. Brigham and Women's Hospital, Boston, MA; Fred Hutchinson Cancer Center and University of Washington, Seattle, WA.

**Background:** Lymphocytic esophagitis (LE) is a recently recognized disorder in which the pathogenesis, risk factors and clinical significance remain poorly understood. Lymphocytic esophagitis has been reported to be causally associated with Crohn's disease, celiac disease, several drugs, and possibly gastroesophageal reflux disease, but it has never been systematically evaluated in the setting of Barrett's esophagus (BE). The aim of this study was to evaluate the prevalence, and the clinical and pathologic features, of LE in BE and to determine its association with aneuploidy, as determined by flow cytometry on frozen samples of tissue.

**Design:** Mucosal biopsies of squamous epithelium located proximal to BE were evaluated from 184 consecutive BE patients enrolled in a long term prospective surveillance program. All biopsies were reviewed for the presence, grade (low or high, based on the degree of lymphocytosis, 11-30 vs. >30 lymphocytes/HPF), and location of LE, based on previously reported criteria (peripapillary lymphocytosis, spongiosis, absence of other inflammatory cells). The data was correlated with clinical, endoscopic, and pathologic features, such as length of BE, dysplasia type and grade, and aneuploidy, and compared between patients with or without LE, and between LE patients with low or high-grade lymphocytosis.

**Results:** Overall, 23 of 184 patients (12.5%) met criteria for LE. 12 (6.5%) were considered low-grade and 11 (6%) were high-grade (>30 lymphocytes per HPF). Patients with LE (either low or high-grade) had a significantly higher incidence of dysplasia (p=0.02), but did not differ from patients without LE with regard to any of the other clinical, endoscopic, or pathologic variables analyzed, including the presence or absence of aneuploidy. No differences were noted between patients with low versus high-grade LE. 9 of 23 patients had follow-up biopsies, obtained 1-4 years later, available for review. Of these, 4 showed persistent LE of equal grade, whereas 5 had reverted back to normal.

**Conclusions:** In this BE cohort, the prevalence rate of LE was 12.5%. The reasons for the observed association with dysplasia are uncertain and need to be explored in future studies. In some patients, LE is temporary, reverting to normal without any additional or specific form of treatment.

### 630 Should Mesenteric Tumor Deposits Be Included in Staging of Small Intestine Neuroendocrine Tumors?

RS Gonzalez, EH Liu, MK Washington, C Shi. Vanderbilt University Medical Center, Nashville, TN.

**Background:** Small intestine neuroendocrine tumors (SI-NETs) are capable of widespread metastases before the primary tumor causes clinical symptoms. They have a propensity to spread to lymph nodes (LN) and the liver. They also can give rise to mesenteric tumor deposits (MTDs), though MTDs are not included in the current American Joint Committee on Cancer (AJCC) staging system for SI-NETs, and whether these MTDs are harbingers of distant metastases is unknown.

**Design:** Seventy-three SI-NET resections were identified in our files with slides and radiographic follow-up available. Each case was assessed for the presence or absence of LN metastases and MTDs, lymphovascular invasion (LVI), and liver metastases (pathologic and/or radiologic). AJCC T-stage was also noted. MTDs were defined as

discrete mesenteric tumor nodules > 1mm with an irregular growth profile. Similar lesions clearly resulting from extranodal extension or direct contiguous spread by the primary lesion were excluded.

**Results:** Forty-four of the 73 SI-NET cases had MTDs (60%), which were typically adjacent to a large blood vessel and entrapping nerves. MTDs were significantly associated with LN metastases, liver metastases, LVI, and pT3 or pT4 disease (see table). Six cases (8%) had positive LNs and liver disease, but no MTDs, while 4 cases (5%) had MTDs and liver mets, but no LN disease. There were 9 cases with resected liver mets and no residual liver disease on post-surgical imaging; 5 had both LN mets and MTDs, and 4 had LN mets but no MTDs. All 4 cases with MTDs and no LN disease had residual liver disease on imaging (typically multiple lesions), while 4 of the 6 cases with LN disease and no MTDs had no residual liver disease on imaging, and the other 2 had quantifiable, rather than innumerable, lesions.

	MTD present	MTD absent	P-value
LN metastases	38/44 (86%)	18/29 (62%)	0.0236
Liver metastases	24/44 (55%)	6/29 (21%)	0.0070
LVI	41/44 (93%)	17/29 (59%)	0.0007
pT3 or pT4	40/44 (91%)	17/29 (59%)	0.0029

**Conclusions:** MTDs are present in the majority of cases of SI-NET, and they are associated with LVI, LN and liver metastases, and advanced T-stage. A proportion of cases where MTDs are present but no LN disease is identified microscopically have liver metastases, and patients with MTD may be less amenable to surgical cure of liver disease. Given the above findings, we suggest that MTDs may have a place in the staging summary for SI-NETs, perhaps as analogous to LN disease.

### 631 Anal Canal Syphilis: A Challenging Diagnosis for the Gastrointestinal Pathologist

P Gopal, RM Genta, R Shah. Miraca Life Sciences Research Institute, Irving, TX.

**Background:** The incidence of syphilis has been increasing over the past few years. Its manifestations as a venereal disease are well described; in contrast, its presentation as primary anal canal disease remains relatively unexplored and gastrointestinal pathologists may rarely consider it in their differential diagnosis. In addition, the demonstration of serum antibodies has traditionally remained the mainstay for diagnosis. The aims of this study are to describe the clinical and histological aspects of anal syphilis and explore the diagnostic utility of *T. pallidum* IHC.

**Design:** From a series of 11,374 anal biopsies received between 2002-2012, after excluding cases of anal intraepithelial dysplasia/condyloma, neoplasms, and inflammatory bowel disease, we identified patients biopsied for evaluation of isolated anal ulcers. Clinical and histologic characteristics, and *T. pallidum* IHC stains were reviewed.

**Results:** Ten patients (9 men and 1 woman) met our inclusion criteria. In 5 cases syphilis was suspected and *T. pallidum* IHC was performed; 3 (all men) were positive. Histologic features included: ulcer with non-specific chronic inflammation; band-like chronic inflammatory infiltrates rich in plasma cells and rare poorly-formed granulomas. *T. pallidum* IHC highlighted numerous organisms in the epidermis, the dermo-epidermal junction and the papillary dermis. Syphilis was neither previously diagnosed nor suspected in any of these patients. Serologic testing, performed after *T. pallidum* was identified histologically, was positive in all 3 patients, one of whom was also HIV positive. One patient subsequently developed syphilitic encephalitis.

**Conclusions:** Syphilis can present as primary anal disease, especially in men with high-risk behaviors, but this clinical suspicion is rarely conveyed to the pathologist. Therefore, it should be suspected in biopsies from isolated anal ulcers, particularly in the presence of inflammatory infiltrates rich in plasma cells. *T. pallidum* IHC is a useful tool that may lead to an early diagnosis and help clinicians to properly manage these patients.

### 632 Interobserver Variability in the Recognition of Desmoplasia in Colorectal Carcinoma

JV Groth, CW Cheng, L Rooper, S Prabhu, Z Lewis, C Dowlatabadi, B Chung, W Song, C Grace, A Bandy, S Garzon, O David, HH Kim, A Kajdacsy-Balla, RJ Cabay. University of Illinois Hospital & Health Sciences System, Chicago, IL; Johns Hopkins University School of Medicine, Baltimore, MD.

**Background:** Desmoplasia is a descriptive term applied to the presence of excessive connective tissue deposition at the advancing front of invasive carcinoma. Desmoplasia may also provide some clues regarding the potential of metastatic disease for some tumors. The histologic appearance of desmoplasia is variable, and the assessment of the microscopic features of desmoplasia is not part of common pathology practice. A categorization of desmoplasia as mature, intermediate or immature has been proposed in advanced rectal cancer (Ueno et al. Gut 2004;53:581-586). We questioned whether this classification scheme can be easily utilized and reproduced in daily practice.

**Design:** Five pathologists and five residents at our institution determined the absence or presence of desmoplasia and, when appropriate, after reading the above cited article, applied the categorization scheme to two selected areas in each of 20 colorectal carcinoma cases. No training sessions were given. Interobserver agreement was measured using the categorization scores each observer assigned.

**Results:****Interobserver Agreement**

Desmoplasia	Observers	Kappa	Standard Error	Prob>Z
Presence/absence	Pathologists + Residents	0.124	0.024	0.000
	Pathologists	0.157	0.050	0.001
Categorization	Residents	0.094	0.050	0.030
	Pathologists + Residents	0.187	0.014	0.000
	Pathologists	0.254	0.031	0.000
	Residents	0.166	0.030	0.000

Desmoplasia categorization scores: 0 = No desmoplasia, 1 = Immature, 2 = Intermediate, 3 = Mature

**Conclusions:** Pathologist, resident and overall kappa scores showed substantial interobserver variability in both the identification and characterization of desmoplasia. This demonstrates the difficulty in achieving agreement regarding the microscopic nature of desmoplasia and identifies the need for additional training measures. Extra educational experiences, such as live or computer-based training sessions, may lead to reduced interobserver variability and increase the likelihood of adding the assessment of desmoplasia to routine clinical practice should subsequent analyses of associated outcome data warrant it.

### 633 Immunohistochemical Study of Ampullary and Small Bowel Adenocarcinomas

R Guo, A Rashid, M Overman, H Wang, J Abbruzzese, H Wang. UT MD Anderson Cancer Center, Houston, TX.

**Background:** Multiple types of epithelium including duodenal, pancreatic duct and common bile duct epithelium meet within the ampulla of Vater. The exact epithelial origin for ampullary adenocarcinoma (AA) is not known. The aim of this study is to compare the immunohistochemical profile between the AAs and primary small bowel adenocarcinomas (SBAs).

**Design:** We retrospectively reviewed 50 archival cases of SBA and 116 cases of AA that were diagnosed at our institution. The tissue microarrays were constructed using the formalin-fixed paraffin embedded tissue with two 1.0 mm cores from representative areas of each tumor. A panel of four markers, including P53, CyclinD1, BCL2 and P21 were examined by immunohistochemistry. The immunohistochemical staining results from the AAs and SBAs were compared using Chi-square analysis.

**Results:** Of the 50 cases of SBA, 32 cases (64%) were positive for cyclin D1, which was significant lower than 79% (92/116) in AAs (P<0.04). P21 and BCL-2 are positive in 12% (6/50) and 12% (6/50) of SBAs respectively, compared to 41% (48/116) and 0% (0/116) of AAs (p=0.0002 and p=0.001 respectively). However we did not observe significant difference between SBAs and AAs in the expression of p53 [60% (30/50) in SBAs vs 51% (59/116), p=0.30].

**Conclusions:** Our study indicated that AAs are immunophenotypically different from SBAs.

### 634 Morphologic Reappraisal of Traditional Serrated Adenoma in 43 Cases

S Hafezi-Bakhtari, KP Batts, D Snover, E Torlakovic. University Health Network, University of Toronto, Toronto, ON, Canada; Hospital Pathology Associates, Minneapolis, MN; Fairview Southdale Hospital, Edina, MN.

**Background:** In 2003 the traditional serrated adenoma (TSA) was for the first time distinguished as a separate lesion from other serrated polyps and in 2008 further diagnostic criteria was proposed to facilitate its diagnosis. However, the field of serrated polyps of the colorectum remains diagnostically challenging. The current study was performed to evaluate characteristics of different histologic subtypes of TSA.

**Design:** The archives of Hospital Pathology Associated, Minneapolis, MN were searched for polyps diagnosed as TSA. 43 most recent cases were selected based on the quality of histologic sections. TSA cellular composition in all cases included eosinophilic cells (EOC) as well as variable mucinous compartment (MUC). In all cases the EOC compartment contained variable number of goblet cells (GC). Following variables were evaluated: content of eosinophilic cells, content of non-eosinophilic/mucinous cells, and the GC content admixed with EOC compartment, which were scored from 1 (rare GC) to 4 (abundant GC). Furthermore, the presence of putative precursor lesion as well as the presence of conventional dysplasia were also recorded.

**Results:** EOC compartment accounted from 5 to 100% of the polyps with the remaining represented by MUC compartment. MUC uniformly failed to show microvesicular mucin except in one polyp (8% of MUC lesions or 2% of all TSAs). Conventional dysplasia was significantly more frequent in TSAs with MUC (Spearman Correlation, r=-0.403, p=0.007). Putative precursor lesions were detected in 32% cases; there was no association of precursor type with dysplasia or extent of MUC.

**Conclusions:** Although the majority of TSAs exhibit a major component of EOC, lesions with a significant component of mucinous differentiation exist and when they account for >20% of the lesion, they are more likely to be associated with conventional dysplasia than pure EOC TSAs.

### 635 Correlation of the C>T SNP (rs16906252) with MGMT Promoter Hypermethylation, KRAS Mutation Status and Clinicopathologic Features in Colorectal Cancer

CE Hagen, JA Lefferts, GJ Tsongalis, LJ Tafe. Dartmouth-Hitchcock Medical Center, Lebanon, NH.

**Background:** Promoter hypermethylation of O<sup>6</sup>-methylguanine-DNA methyltransferase (MGMT), a DNA repair enzyme, is an early event in the carcinogenesis of colorectal cancer (CRC). Recent data show an association between MGMT methylation and the

C>T SNP (rs16906252) within the first exon of MGMT. The goal of our study was to determine the prevalence of the C>T SNP (rs16906252) in a group of patients with CRC and to associate these findings with MGMT methylation status, KRAS mutation status, pathologic features, and patient mortality data.

**Design:** Thirty-five patients (mean age 61.7; M:F 18:17; average follow up 43 mos.) with a history of CRC were included. DNA previously extracted from formalin-fixed, paraffin-embedded tumor tissue for determination of KRAS status was used for analysis. MGMT methylation status was determined using bisulfite converted DNA. DNA concentrations ranged from 0.9 ng/ul to 910 ng/ul as determined by UV spectrophotometry. DNA (10 ng/ul) was amplified using primers flanking the C>T SNP and genotyping was performed using TaqMan probes specific for the C and T alleles. Pathologic and clinical information were collected through medical chart review.

**Results:** Two patients (5.7%) were found to be heterozygous for the C>T SNP. No patients were found to be homozygous for the T allele. In our cohort the frequency of the T allele was 4%. Ten patients (32.3%) were positive for MGMT methylation. Of the two C>T SNP heterozygous patients, one was associated with MGMT methylation (10% of methylated group) while the other was unmethylated (4% of unmethylated group). Neither of the SNP heterozygous patients had an associated KRAS mutation. The average age of the heterozygous SNP patients was 68.5 yrs. compared to 60.9 yrs. in the wild type group. Both heterozygotes were male with left-sided CRC. One was pathologic stage 3 at diagnosis while the other was stage 4. One was deceased at last follow-up while the other was still living (average follow-up 41 mos.).

**Conclusions:** Although our rate of MGMT methylation in CRC (32.3%) is similar to previously reported values, in our population, the overall rate of C>T SNP (rs16906252) is much lower than previously reported. There was no association with the C>T SNP and KRAS status. Further studies are needed to understand the relationship of MGMT methylation in CRC and the C>T SNP (rs16906252) in given populations.

### 636 Adenoma Size and High Calcium Intake Are Independent Predictors of Cyclin D1 Overexpression: An Analysis of 339 Polyps

CE Hagen, AS Andrew, Z Li, MA Greene, ME Goodrich, LF Bitterly, JA Baron, AJ Dietrich, A Srivastava. Dartmouth-Hitchcock Medical Center, Lebanon, NH; Brigham and Women's Hospital, Boston, MA.

**Background:** Cyclin D1 and COX2 are overexpressed in a subset of colorectal cancer (CRC), while Vitamin D may have an inhibitory role; ornithine decarboxylase (ODC) may be overexpressed in premalignant states. The role of these markers in precursors of CRC has not been systematically evaluated. The aim of this study was to evaluate Cyclin D1, ODC, Vitamin D, and COX2 expression in colonic adenomas and their correlation with patient characteristics, adenoma size, location, and CpG methylation (CIMP).

**Design:** Tissue from patients in the New Hampshire Colonoscopy Registry (NHCR) was used for tissue microarray. Demographic data and endoscopic findings were retrieved from the NHCR database. Immunostaining was graded for extent (0=0-5%, 1=5-25%, 2=25-50%, 3=50-75%, 4=>75%) and intensity (0=negative, 1=weak-moderate, 2=strong). Cyclin D1 was evaluated for pattern (confluent/patchy). Multivariate analysis to determine odds ratio for "low" (intensity 0-1, extent 1) or "high" (intensity 2, extent 2-4, confluent) expression in relation to patient age, sex, polyp location, size, vitamin and calcium intake, and CIMP was performed. 339 tubular adenomas (M/F: 211/128; mean age: 57.4 years) were examined. Diminutive (<5mm), small (5-9mm) and large (≥10 mm) adenomas comprised 36% (n=122), 50% (n=171) and 12% (n=42) of the study group, respectively. Diminutive polyps were the referent group for analysis. Polyps with missing covariates were excluded.

**Results:** High intensity Cyclin D1 staining was present in 188 (63%) polyps, high extent in 165 (55%) and a confluent pattern in 41 (13.6%). High Cyclin D1 extent was significantly increased in large (OR 4.05; p=0.002) and small (OR 2.41, p<0.001) polyps. Confluent staining was significantly higher in small polyps (OR 7.44, p<0.001) and approached significance in large polyps (OR 3.42, p=0.08). High calcium intake was significantly associated with confluent staining (OR 8.34, p<0.001) and high intensity expression (OR 2.62, p=0.02). High Cyclin D1 expression was not associated with any of the analyzed CIMP loci. High COX2 expression was significantly decreased in small (OR 0.3, p=0.004) and large (OR 0.16, p=0.004) polyps. High ODC and Vitamin D expression did not correlate with any of the analyzed variables.

**Conclusions:** Overexpression of Cyclin D1 increases with adenoma size and high calcium intake, suggesting a role in the adenoma-cancer pathway. COX2 is significantly decreased in large adenomas, suggesting overexpression may not occur until a later stage in carcinogenesis.

### 637 Should Histology Play a Role in Deciding Which Colorectal Carcinomas Should Be Tested for Lynch Syndrome?

STG Hammer, JK Greenon. University of Michigan Health System, Ann Arbor, MI.

**Background:** Recent publications have suggested that it is cost effective to test all colorectal cancers (CRCs) in order to identify patients with Lynch syndrome. Such testing typically includes microsatellite instability (MSI) testing, IHC stains for mismatch repair proteins (MMR) and Braf V600E analysis. We have previously published a morphology based predictive model of microsatellite instability (Am J Surg Pathol. 2009 Jan;33(1):126-33.) that we have used to select cases for Lynch syndrome testing. Starting in August of 2011, however we began testing all CRCs for MSI, MMR, and Braf if MSI-H. We reviewed all CRCs tested during the past year to see if we would have missed any Lynch syndrome cases had we used our morphologic predictor to direct testing.

**Design:** We performed a database review for all colorectal carcinoma resections performed from 8/1/2011 through 7/31/2012 which yielded 88 specimens. We then omitted cases with preoperative chemotherapy/radiation and carcinomas arising in polypectomy specimens (n=14). Each case was reviewed for age, tumor location,

histology, MSI status, IHC for MSH2, MSH6, MLH1, PMS2, and Braf mutation analysis. The histologic features used in our predictive model were number of tumor infiltrating lymphocytes/ high power field, Crohn's like reaction, mucinous differentiation, dirty necrosis, and tumor differentiation. These data were entered into our web based predictor of MSI ([http://sitemaker.umich.edu/gruber.lab/files/msi\\_pre.htm](http://sitemaker.umich.edu/gruber.lab/files/msi_pre.htm)) to see how well we could predict MSI status. We also calculated the total generated charge and potential savings if we had used this morphologic model rather than testing all tumors.

**Results:** We previously used a >5% likelihood of MSI-H as a cut-off to test tumors for Lynch syndrome. Thirty-six of 74 cases had morphologic path scores predicting a >5% likelihood of MSI-H. All eleven cases of MSI-H colorectal carcinoma (including 8 cases of Lynch syndrome) would have been selected for testing by this method. Thirty-eight cases of MSS CRC had a likelihood of MSI below 5%. The charge for MSI and IHC testing these 38 MSS stable CRCs was \$111,758 (\$2941/case).

**Conclusions:** Using our histology based MSI predictive model we could have omitted testing 38 of 74 cases of CRC without missing any MSI-H or Lynch tumors for a total savings of \$111,758. This would cut the cost of screening for Lynch syndrome and MSI by greater than 50%.

### 638 Histologic Correlation with the Clinical-Radiologic Acute Cholecystitis Syndrome

STG Hammer, KE Maturen, HD Appelman. University of Michigan Health System, Ann Arbor, MI.

**Background:** The syndrome of acute cholecystitis is clinically defined as the presence of right upper quadrant abdominal pain, fever, leukocytosis, and gallbladder abnormalities on radiologic exam. There is also histologic acute gallbladder inflammation seen as acute mucosal or mural necrosis with transmural inflammation (TI). Little is written about the association between the clinical acute cholecystitis syndrome and histologic acute inflammation. We examined histologic acute cholecystitis cases over one year and correlated them with clinical and radiological features to identify any association.

**Design:** We found 27 cholecystectomy cases resected in 2010 for primary biliary disease with TI and acute mucosal necrosis. The presence of mucosal neutrophils, transmural neutrophilic infiltrate, transmural and mucosal necrosis, hemorrhage, wall edema and thickness were evaluated. Controls were 27 non-inflamed gallbladders resected for gallstones. Clinical data included age, gender, ethnicity, temperature > 37C, leukocytosis > 10.0 K/mm<sup>3</sup>, right upper quadrant pain >24 hrs, and clinical response to resection. Radiologic studies were reviewed by a staff radiologist for gallstones/sludge, pericholecystic fluid, wall thickness, and sonographic Murphy sign.

**Results:** The study group was a mean 10 yrs older than controls (48 v 58 yrs), more often male (60% vs 40%), and more often had systemic symptoms like fever (19% v 4%) and leukocytosis (74% v 26%). Seventy-seven percent of the study group had either fever or leukocytosis, versus 4% of controls. Scintigraphic studies correlated with histology better in study patients [92% (n=12) v 20% (n=5)]. Sonographic findings correlated well with histology in both study and control groups (85% v 86%). Ultrasounds were available on 24 study patients and 21 controls. Study patients more often had thickened gallbladder walls, distention, pericholecystic fluid, loculated fluid collections, and impacted neck stones. The time from imaging to surgery was significantly longer in controls (70 days vs 1.3 days). The intraoperative impression correlated better in study group patients (89% v 67%). There was similar symptomatic response in both groups.

**Conclusions:** There is clear, but imperfect correlation between our definition of acute cholecystitis, radiologic, and clinical features of the acute cholecystitis syndrome. The patients are slightly male predominant with at least one systemic symptom, have characteristic radiographic findings, and have acute inflammation intraoperatively.

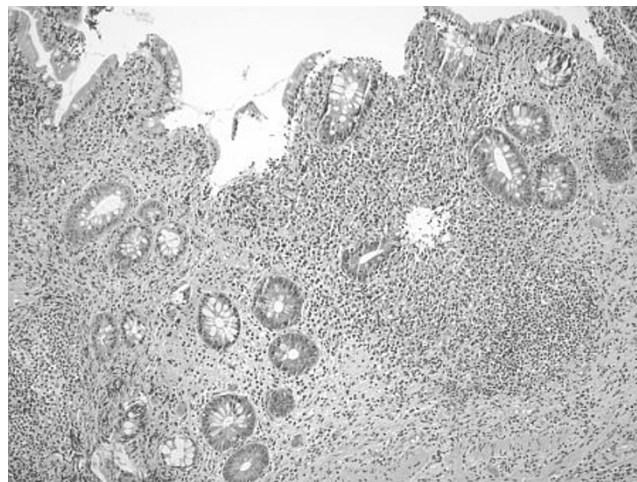
### 639 Pathy/Focal Chronic Pouchitis Is Related to Crohn's Disease

X Hao, W Xin. University Hospitals Case Medical Center, Cleveland, OH; Case Western Reserve University, Cleveland, OH.

**Background:** Restorative proctocolectomy with ileal pouch-anal anastomosis (IPAA) is the surgical option for ulcerative colitis (UC) refractory to medical treatment. One of the most common complications of IPAA is chronic pouchitis. Most pouchitis can be resolved by medical treatment. Some patients may develop chronic antibiotic-refractory pouchitis and Crohn's disease after close follow-up. Here, we carried out studies to evaluate morphologic features of pouchitis that can be used to predict the late development of Crohn's disease.

**Design:** 33 cases of pouch biopsies from 33 patients that have refractory chronic pouchitis were collected and reviewed. We divided them into two groups: 9 patients have confirmed Crohn's disease by histologically and clinically fistula formation of the pouch and 24 patients have non-Crohn's pouchitis. The following histologic features were compared between these two groups of patients: distribution of inflammation, granulomas, pyloric metaplasia, lymphoid aggregates, cryptitis/ulcer, crypt distortion, and tissue eosinophilia. Data were analyzed by Fisher's exact test.

**Results:** Of patients with Crohn's disease of the pouch, 8 of 9 (88.8%) have patchy/focal chronic inflammation compared to 9 of 24 patients (37.5%) who have non-Crohn's pouchitis (p=0.016).



The sensitivity and specificity of patchy inflammation in detecting Crohn's disease of the pouch is 88.8% and 62.5% respectively. Granulomas were only found in Crohn's disease of the pouch, but not in other conditions (1/9). There was no statistical significance between two groups as to pyloric gland metaplasia, lymphoid aggregates, cryptitis/ulcer, crypt distortion and tissue eosinophilia.

**Conclusions:** Patchy/focal chronic pouchitis is a predictor of late development of Crohn's disease of the pouch. Documentation of patchy/focal pouchitis in the biopsy is important and should raise the differential diagnosis of Crohn's disease.

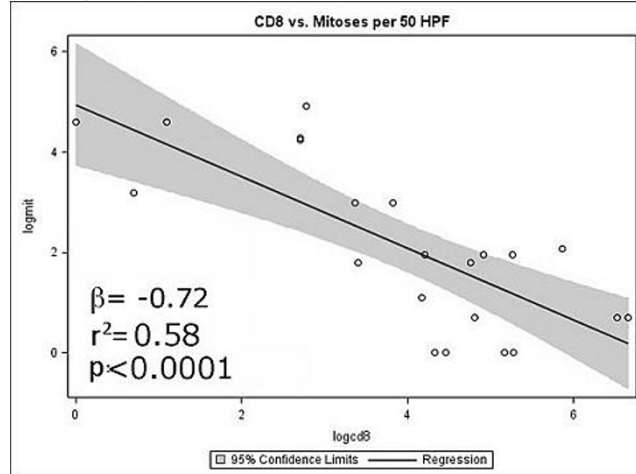
### 640 Intratumoral CD8+ Cells Are Strongly and Inversely Correlated with Mitotic Index and Estimated Recurrence-Free Survival in Treatment-Naive Gastric GISTs

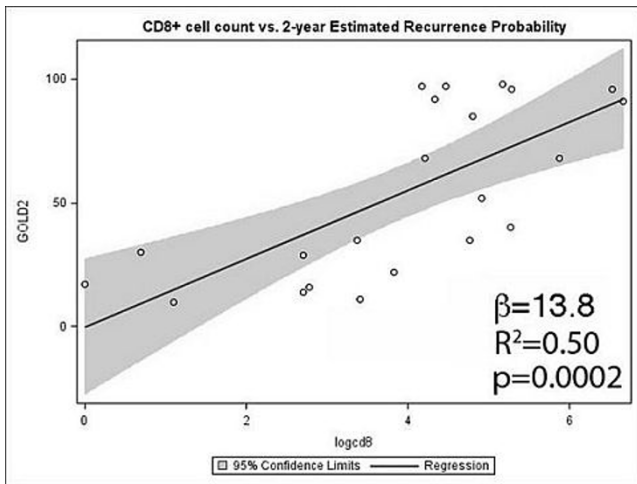
JF Hechtman, MJ Donovan, RB McBride, X Ding, A Chen, L Peters, D Chiang, N Harpaz. Mount Sinai School of Medicine, New York, NY.

**Background:** There is compelling evidence linking the immune contexture of epithelial and hematologic malignancies to clinical outcomes, but little is known regarding that of GISTs. We investigated whether intratumoral immune cells in untreated gastric GISTs are associated with variables of known prognostic significance.

**Design:** Immunohistochemistry was performed to identify the number of CD8+ cells, macrophages (CD68+, CD11b+) and presumed regulatory T cells (FOXP3+) in a series of consecutive gastric GIST resection specimens. The number of immunoreactive cells across 10 consecutive HPF was assessed, excluding necrotic tissue and vascular spaces. Associations with mitotic rate (MR), tumor size (TS) and estimated 2-year recurrence-free probability (RFS2) (Gold et al. Lancet Oncol 2009; 11:1045-1052) were separately evaluated using generalized linear models in SAS 9.2.

**Results:** We evaluated 22 GISTs (8 spindle cell, <5mitoses/50 HPF; 10 spindle cell and 4 epithelioid cell, ≥5 mitoses/50 HPF) from 13 males and 9 females, mean age 68.7y (range, 33-91y). Mean TS was 9.3cm (range, 1-27cm). MRs per 50 HPF were: mean 22, median 40, range 1-135. After log-transformation to achieve normality, CD8+ count was correlated with MR ( $\beta=-0.72$ ,  $R^2=0.58$ ,  $p<0.0001$ ) and estimated RFS2 ( $\beta=13.8$ ,  $R^2=0.50$ ,  $p=0.0002$ ). The association between CD8+ cells and MR remained significant after adjustment for TS, age and sex. ( $\beta=-0.58$ ,  $p=0.006$ ); the association with RFS2 remained significant after adjustment for, TS, age, sex and MR ( $\beta=3.45$ ,  $p=0.05$ ). No corresponding correlations with CD3, CD68, CD11b or FOXP3 were identified.





**Conclusions:** Intratumoral CD8<sup>+</sup> cells in gastric GISTs are strongly and inversely correlated with MR and may afford an independent clinical estimate of RFS2. Further study of intratumoral immune regulation should better define its mechanisms and potential therapeutic implications.

#### 641 Gene Expression Profiling of Serrated Colorectal Polyps: Identification of Genes That Differentiate Hyperplastic Polyps (HPs) from Sessile Serrated Polyps (SSPs)

*D Hernandez Gonzalo, KK Lai, X Liu, DT Patil, AE Bennett, JR Goldblum, WH Henricks, E Downs-Kelly, J Na, LA Rybicki, BL Shadrach, P Carver, RK Pai.* Cleveland Clinic, Cleveland, OH.

**Background:** SSPs are precursors to sporadic MSI-H colon cancers and their presence increases the risk of subsequent advanced neoplasia. Thus, distinguishing SSPs from HPs has important therapeutic implications. This distinction is difficult due to overlapping histologic features, poor orientation, mechanical artifact, and unusual location (eg, SSP located distal to splenic flexure).

**Design:** 110 serrated polyps were identified, randomized and independently reviewed by 7 GI pathologists. Consensus (defined as at least 6 pathologists agreeing) was achieved in 24 HPs, 21 SSPs, and 9 SSPs with dysplasia/carcinoma (SSPD). Of these consensus polyps, 6 HPs, 6 SSPs and 4 SSPDs were selected for whole genome microarray analysis in addition to 6 normal colonic biopsies (3 right and 3 left colon). RNA was isolated from paraffin-embedded tissue and expression analysis was performed using the Illumina DASL-HT assay. Raw data was analyzed using the R-limma package. Genes were defined as differentially expressed by an Fdr adjusted p value <0.05.

**Results:** 65 differentially expressed genes (DEGs) were identified when comparing SSPs and HPs. One DEG, Annexin A10 (ANXA10), was evaluated by immunohistochemistry on the following consensus polyps: HPs (19), SSPs (14) and SSPDs (8). Annexin A10 staining was evaluated according to intensity of nuclear staining (0-4) and percentage of nuclei staining (0-4). Staining was mostly present in upper 2/3 of the crypt. Using Wilcoxon rank sum test, staining intensity and percent positive nuclei were compared between groups.

##### Annexin A10 Immunohistochemical results

Polyp type	Mean percentage of positive nuclei (median)*	P-value***	Mean intensity (median)**	P-value***
SSP (14)	3.2 (3.5)	---	3.3 (3.5)	---
HP-all (19)	1.5 (1)	0.001	1.9 (2)	0.039
HP-left (13)	1.2 (0)	<0.001	1.5 (0)	0.014
HP-right (6)	2.2 (2.5)	0.1	2.7 (3.5)	0.65
SSPD-non dysplastic areas (8)	2.6 (3)	0.38	3.5 (4)	0.62

\* Percentage of staining: 0=<5%, 1=6-25%, 2=26-50%, 3=51-75%, 4=76-100%.\*\*Intensity graded from 0 to 4 (4=maximum staining).\*\*\*P-values compared to SSP.

**Conclusions:** In summary, using gene expression profiling we identified 65 DEG between SSPs and HPs. One DEG, ANXA10, may be helpful in distinguishing HPs from SSPs although immunohistochemical expression of ANXA10 is not specific for SSPs.

#### 642 Morphologic and Molecular Analysis of Appendiceal Serrated Lesions: Colonic Terminology May Not Be Applicable

*D Hernandez Gonzalo, X Liu, DT Patil, A Bennett, TP Plesec, JR Goldblum, S-F Kuan, E Downs-Kelly, B Shadrach, RK Pai, RK Pai.* Cleveland Clinic, Cleveland, OH; University of Pittsburgh Medical Center, Pittsburgh, PA.

**Background:** Classification of serrated appendiceal lesions can be difficult, and it is unclear if pathologists should apply terminology used in the colon. SSP/As of the colon almost always have mutations in BRAF; however, a recent study found that some appendiceal sessile serrated polyps/adenomas (SSP/As) demonstrate KRAS mutations. The aim of this study was to analyze appendiceal lesions for KRAS and BRAF mutations and correlate mutational analysis with histologic features.

**Design:** We classified 94 appendiceal lesions using current standard terminology (hyperplastic polyp [HP], SSP/As, SSP/A with dysplasia, traditional serrated adenoma [TSA], tubular/tubulovillous adenoma [TA/TVA], and low-grade mucinous neoplasm [LAMN]). Lesions were also classified using a simplified scheme based on the presence of epithelial serrations and cytologic dysplasia: serrated non-dysplastic, serrated dysplastic, and dysplastic not-serrated. KRAS and BRAF mutational analysis was

performed on isolated DNA via direct sequencing and allele specific PCR respectively.

**Results:** Using the simplified scheme, 32 cases were serrated non-dysplastic, 19 were serrated dysplastic, and 43 were dysplastic non-serrated. Based on standard terminology there were 9 HPs, 23 SSP/As, 9 SSP/As with dysplasia, 6 TSAs, 6 TA/TVA, and 41 LAMNs. BRAF mutations were found in 4 of 70 cases (5.7%). However, KRAS mutations were found in 22 of 43 cases (51.1%) tested. The histologic classification of the 40 cases that were analyzed for both KRAS and BRAF mutations are shown in Table 1.

##### KRAS and BRAF mutations in Appendiceal lesions

Conventional terminology	KRAS mutated	BRAF mutated	KRAS/BRAF WT
HP (1)	0	0	1 (100%)
SSP/A (9)	8 (89%)	1 (11%)	0
SSP/A with dysplasia (7)	4 (57%)	2 (29%)	1 (14%)
TSA (3)	1 (33%)	0	2 (67%)
TA/TVA (4)	2 (50%)	0	2 (50%)
LAMN (16)	7 (44%)	1 (6%)	8 (50%)
Simplified terminology			
Serrated non-dysplastic (10)	8 (80%)	1 (10%)	1 (10%)
Serrated dysplastic (13)	7 (54%)	2 (15%)	4 (31%)
Dysplastic non-serrated (17)	7 (41%)	1 (6%)	9 (53%)

**Conclusions:** Serrated lesions of the appendix that resemble SSP/As often harbor KRAS mutations, in stark contrast to the high percentage of BRAF mutations seen in SSP/As of the colon. These results indicate that the serrated pathway in the appendix may be different than the colon, and thus, colonic terminology may not be applicable to appendiceal lesions.

#### 643 High Proliferation Index Is Associated with Reduced Survival in Anorectal Melanomas – An Immunohistochemical and Molecular Study

*D Hershkovitz, E Simon, E Sabo, J Sandbank, G Groisman, V Doviner, I Cohen, O Ben-Izhak.* Rambam Health Care Campus, Haifa, Israel; Assaf Harofeh Medical Center, Zerifin, Israel; Hillel Yaffe Medical Center, Hadera, Israel; Hadassah University Hospital, Jerusalem, Israel; Western Galilee Regional Hospital, Nahariya, Israel.

**Background:** Melanoma of the anorectum (ARMM) is a rare yet lethal malignancy. It has worse prognosis compared to cutaneous melanoma (CM), and to date, very little is known about the molecular basis of ARMM and its markers of prognosis. Interestingly, recent studies have indicated some biological and molecular differences in the pathogenesis of ARMM and CM. Understanding the pathogenetic pathways specific for ARMM might allow the development and application of targeted therapies to ARMM patients. Additionally, identification of biological markers in ARMM might also aid determining patients' prognosis.

**Design:** We collected clinical and prognostic data from 61 cases of ARMM. Tissue samples from these patients' tumors were analyzed using immunohistochemistry for the expression of bcl-2, p53 and Ki67. Additionally, DNA was extracted from 26 samples, which were scrutinized for oncogenic mutations in BRAF and NRAS. We then correlated the immunohistochemical and molecular results with patients' clinical data and prognosis.

**Results:** The median survival in the group was 13 months. Thirty eight patients (62%) were females and 23 (38%) were males. The median age at diagnosis was 66 years. In the immunohistochemical analysis 32 (52%) were positive for bcl-2, 21 (34%) were positive for p53 and the median proliferation index measured with Ki67 was 44%. The molecular analysis identified NRAS mutations in 5 (19%) of the 26 cases analyzed. No mutations were identified in BRAF. Statistical analysis demonstrated an association between disease stage and patients' survival with 16 months survival in stage II compared to 8 months survival in stage IV (p=0.025). Additionally, high proliferation index was associated with survival (19 months in ≤44% compared to 8 months in >44%, p=0.0008). No association was found between patients' prognosis and other clinical or immunohistochemical variables. The presence of NRAS mutation was not associated with altered prognosis.

**Conclusions:** Our results indicate that in ARMM disease stage and proliferation index might serve as markers for prognosis. Additionally, we found oncogenic NRAS mutations in 19% of the cases undergoing molecular analysis, and possibly, treatments targeting this molecular pathway might be of benefit in this subset of patients.

#### 644 Staining Patterns of Anti-Apoptotic Protein Beclin-1 in Inflammatory Bowel Disease Associated Dysplasia and Carcinoma

*PJ Holmes, AV Gandhi, JP Palazzo.* Thomas Jefferson University Hospital, Philadelphia, PA.

**Background:** Beclin-1 plays a role in vesicle assembly during autophagy, a type of programmed cell death. It has been shown to be downregulated in several types of cancer (breast, prostate, and ovarian) and upregulated in gastric and colorectal cancers. This reflects the complex role of autophagy, and more specifically, Beclin 1, in the development and progression of cancer. Autophagy can inhibit apoptosis but also can result in an alternative cell death pathway and protect against carcinogenesis. The diagnosis and progression of inflammatory bowel disease (IBD) to dysplasia and cancer is important in order to identify and treat patients as early as possible. In this study we investigated the expression of Beclin-1 in patients with IBD with dysplasia and cancer in order to elucidate its possible role in this progression.

**Design:** We studied 64 patients with inflammatory bowel disease who underwent either a biopsy or surgical resection from 1976-1999 at TJUH. 7 patients had inactive disease, 16 had chronic active colitis, 28 had low grade dysplasia, 3 had high grade dysplasia, and 10 had invasive carcinoma. All sections were stained for Beclin-1 (1:200, EPR1733Y,

Epitomics, Burlingame, CA) with appropriate controls. Cytoplasmic staining was considered positive. We determined the intensity of staining (0 to 3+) and the distribution of staining (negative, focal, or diffuse). The study was approved by the IRB.

**Results:** Moderate or strong cytoplasmic staining was seen in 45/57 (79%) cases with chronic active colitis, dysplasia or cancer. Weak, focal, or negative staining was seen in 5/7 (71%) cases of non-inflamed mucosa. The majority of cases of chronic active colitis (81%), 74% of the dysplastic cases, and 90% of the cancers had moderate or strong diffuse staining patterns.

**Conclusions:** The increased expression of Beclin-1 seen in patients with active colitis, dysplasia, and cancer in patients with IBD supports the notion that autophagic mechanisms play a role in the progression of dysplasia and carcinoma. Increased inflammation and subsequent cell damage present in patients with inflammatory bowel disease may have a role in upregulating Beclin-1 and autophagy and protecting the cells against apoptotic stimuli that would normally induce cell death. Increased Beclin staining may be a marker for progression of inflamed mucosa to dysplasia and carcinoma in IBD patients.

#### 645 Clinicopathologic Features of Synchronous Colorectal Carcinoma: A Distinct Subset Arising from Multiple Sessile Serrated Adenomas and Associated with High-Levels of Microsatellite Instability and Favorable Prognosis

H Hu, DT Chang, MN Nikiforova, S-F Kuan, RK Pai. University of Pittsburgh, Pittsburgh, PA; Stanford University, Stanford, CA.

**Background:** Synchronous colorectal carcinomas (CRCs) provide insight into the common causative genetic factors in colorectal neoplasia. We analyzed the clinicopathologic and molecular features of synchronous CRCs compared with solitary CRCs.

**Design:** 58 consecutive synchronous CRCs were retrospectively identified between January 2002 and June 2012 and analyzed for grade, stage, tumor-infiltrating lymphocytes (TILs), Crohn's-like peritumoral reaction, mucinous/signet ring differentiation, and precursor and synchronous polyps. CRCs were grouped based on the type of precursor lesion and microsatellite instability (MSI) status. BRAF V600E mutation status was performed in all MSI-H CRCs. Overall survival was compared between synchronous CRCs and 109 consecutively resected solitary CRCs.

**Results:** Compared with solitary CRCs, synchronous CRCs were often MSI-H (36% vs. 12%;  $p=0.0005$ ) and right-sided (72% vs. 43%;  $p=0.0003$ ); displayed TILs (34% vs. 11%;  $p=0.0004$ ), mucinous histology (52% vs. 17%;  $p=0.0001$ ), and precursor sessile serrated adenomas (SSA) (21% vs. 2%;  $p=0.0001$ ); and had an improved 5-year survival (92% vs. 56%,  $p=0.02$ ). There was no difference in survival between MSI-H and MSS synchronous CRCs. A unique group of 12 synchronous CRCs had CRCs arising from SSAs. All 12 SSA-associated synchronous CRCs were MSI-H and BRAF positive, seen in patients >60 years, and right-sided. SSA-associated CRCs occurred in women (11/12, 92%), were stage I/II (9/12, 75%) and low grade (10/12, 83%), and exhibited mucinous histology (10/12, 83%), TILs (10/12, 83%), and Crohn's-like reaction (8/12, 67%). 5/12 (42%) patients with SSA-associated CRCs harbored additional SSAs, ranging from 1 to 6. Clinical follow-up for 10/12 SSA-associated synchronous CRCs demonstrated all patients alive with no evidence of disease.

**Conclusions:** A distinct subset of synchronous CRC arises from multiple SSAs and is MSI-H and BRAF V600E positive. SSA-associated synchronous CRCs account for 21% of synchronous CRCs, occur in elderly women, and have a favorable prognosis. The high proportion of SSA-associated synchronous CRCs contributes to the improved overall survival of synchronous CRCs compared with solitary CRCs. The increased frequency of SSA-associated synchronous CRCs provides support that SSAs are high-risk lesions and suggests that patients with SSAs have a "field defect" resulting in increased risk for synchronous and likely metachronous CRC.

#### 646 Microsatellite Instability-High (MSI-H) Left-Sided Colorectal Carcinoma Is Frequently Associated with Lynch Syndrome: Implications for Lynch Syndrome Screening and Detection

H Hu, DJ Hartman, RE Brand, N Bahary, B Dudley, SI Chiosea, MN Nikiforova, RK Pai. University of Pittsburgh, Pittsburgh, PA.

**Background:** Some institutions perform universal microsatellite instability (MSI) testing of CRCs to identify patients with Lynch syndrome (LS). Others triage CRCs for MSI testing based clinicopathologic variables within published predictive models for identifying MSI-H CRCs. We analyzed the clinicopathologic features of sporadic and LS-associated MSI-H CRCs and assessed the utility of predictive pathology models in identifying LS-associated CRCs.

**Design:** 149 MSI-H CRCs were identified between 2009 to June 2012 by MSI PCR (88 cases), mismatch repair (MMR) protein immunohistochemistry (IHC) (16 cases), or both PCR and IHC (45 cases). CRCs were analyzed for grade, location, tumor-infiltrating lymphocytes (TILs), Crohn's-like lymphocytic reaction, mucinous/signet ring cell histology, medullary growth, and histologic heterogeneity. MSI-H CRCs were divided into sporadic and LS-associated groups based on BRAF mutation, MLH1 promoter hypermethylation, family and personal cancer history, and germline MMR gene mutation. The utility of two predictive pathology models for MSI-H CRCs (PREDICT, Hyde A, et al. Am J Surg Pathol 2010 and MSPATH, Jenkins MA, et al. Gastroenterology 2007) were evaluated.

**Results:** Left-sided MSI-H CRCs were frequently associated with LS compared with right-sided MSI-H CRC (12/21, 57% vs. 16/127, 16%,  $p=0.0001$ ). 10/32 (31%) LS-associated CRCs were diagnosed in patients >60 years. There was no significant difference in tumor histology between LS-associated and sporadic MSI-H CRC. However, left-sided LS-associated CRC less frequently demonstrated TILs compared with right-sided LS-associated CRC (5/12, 42% vs. 15/20, 75%), although this was not statistically significant ( $p=0.13$ ). Neither the PREDICT or MSPATH models identified

all LS-associated CRCs (PREDICT: 27/32, 84%; MSPATH: 29/32, 91%); however, both models identified a significantly higher proportion of sporadic MSI-H CRCs (PREDICT: 111/117, 96%,  $p=0.038$ ; MSPATH, 117/117, 100%,  $p=0.009$ ).

**Conclusions:** 57% of left-sided MSI-H CRCs are LS-associated compared with 16% of right-sided MSI-H CRCs. Published models of predicting MSI-H fail to identify LS-associated CRC given their reliance on right-sided location. 31% of LS-associated CRC are identified in patients >60 years. These results support universal testing for MSI in CRC and indicate that finding MSI-H in left-sided CRC should heighten suspicion for LS.

#### 647 Clinicopathologic Features of Microsatellite Instability-High (MSI-H) Colorectal Carcinomas in Patients >60 Years of Age

H Hu, DJ Hartman, RE Brand, B Dudley, SI Chiosea, MN Nikiforova, RK Pai. University of Pittsburgh, Pittsburgh, PA.

**Background:** The Revised Bethesda Guidelines (RBG) for screening colorectal carcinomas (CRCs) to identify patients with Lynch syndrome (LS) provide no recommendations for microsatellite instability (MSI) testing in patients >60 years of age. We analyzed MSI-H CRCs identified in patients >60 years in an attempt to identify pathologic features which can help to identify LS-associated CRC in this patient population.

**Design:** 117 consecutive MSI-H CRCs were identified between 2009 to June 2012 in patients >60 years of age by MSI PCR (81 cases), mismatch repair protein (MMR) immunohistochemistry (14 cases), or both MSI PCR and MMR IHC (22 cases). All cases were analyzed for the RBG MSI-H histologic features of tumor-infiltrating lymphocytes (TILs), Crohn's-like lymphocytic reaction, mucinous/signet ring cell differentiation, and medullary growth pattern and additional pathologic features including grade, location, peritumoral lymphocytic reaction, histologic heterogeneity, and stromal plasma cells. MSI-H CRCs were stratified into sporadic and presumed LS-associated based on BRAF V600E mutation, MLH1 promoter hypermethylation, family and personal cancer-related history (Amsterdam I or II criteria), and germline MMR gene mutation analysis.

**Results:** Ten of 117 (8.5%) MSI-H CRCs were LS-associated. LS-associated CRCs were more frequently located in the left colon/rectum compared with sporadic MSI-H CRC (3/10, 30% vs. 7/107, 6.5%;  $p=0.04$ ). There was no significant differences in tumor histology between LS-associated and sporadic MSI-H CRC. Importantly, all 10 LS-associated CRCs demonstrated at least one of the four RBG MSI-H histologic features: 8/10 Crohn's-like peri-tumoral reaction; 7/10 TILs; 5/10 mucinous/signet ring histology; and 1/10 medullary histology. Most (100/107, 93%) sporadic MSI-H demonstrated at least one of the four RBG MSI-H histologic features.

**Conclusions:** In patients >60 years, 8.5% of MSI-H CRC are LS-associated. All LS-associated CRCs exhibited at least one of the RBG MSI-H histologic features. Our results indicate that in patients >60 years of age, the presence of any RBG MSI-H histologic features should prompt MSI screening to identify Lynch syndrome. Importantly, evaluation for RBG MSI-H histologic features should be performed on CRCs in patients >60 years of age regardless of tumor location as LS-associated CRCs can occur in the left colon and rectum.

#### 648 Small ( $\leq 2$ cm) Carcinomas in the Proximal Stomach Demonstrate Distinct Clinicopathologic Features from Those in the Distal and Corpus: A Proposal for Classification of Gastric Cancer by Location

Q Huang, J Shi, Q Sun, H Yu, J Chen, H Wu, JK Gold, H Mashimo, C Yu, GY Lauwers. Nanjing Drum Tower Hospital, Nanjing, China; VA Boston Healthcare System, West Roxbury, MA; Massachusetts General Hospital, Boston, MA.

**Background:** The pathobiology of proximal gastric cancer (PGC) is suggested to be more akin to that of esophageal cancer. However, recent Asian and German studies show that the prognosis of PGC is similar to neither esophageal nor distal gastric cancer (DGC). Because the incidence of PGC is high and the optimal therapeutic strategy is debated, we aimed to compare clinicopathologic features between small PGCs and non-PGCs with the hypothesis that they may be dissimilar.

**Design:** Surgically resected small ( $\leq 2$  cm) gastric cancer (GC) treated at the Nanjing Drum Tower Hospital in China from 2004 through 2009 was searched in pathology files, and divided by location as PGC (epicenter within 3 cm below the gastroesophageal junction), DGC (from the incisura to the pylorus), and CGC (corpus gastric cancer, between PGC and DGC). Exclusion criteria were: 1) size >2 cm, 2) cases with neoadjuvant therapy, 3) epicenter within the esophagus, 4) prior resection, 5) absence of archived tissues. Tumor classifications followed the 2010 WHO Classification of Tumours of the Digestive System. All tumors were staged according to the AJCC 7. Clinicopathologic variables between groups were compared with the Fisher's exact and two-tailed Student's  $t$  tests.  $P < 0.05$  was considered statistically significant.

**Results:** Of 1,973 consecutive GC resections, 226 (12%) were eligible with 73 (32%) PGCs, 129 (57%) DGCs, and 24 (11%) CGCs. PGCs were more polypoid and less ulcerated than non-PGCs ( $p < 0.05$ ). They were better differentiation ( $p < 0.001$ ) and more heterogeneous with adenosquamous, neuroendocrine, and medullary variants but fewer in signet-ring cell carcinoma than non-PGCs ( $p < 0.05$ ). The frequency of adjacent gastric dysplasia was lower ( $p < 0.001$ ) but the occurrence of gastritis cystica profunda was higher in PGCs than non-PGCs ( $p < 0.001$ ). In contrast, no significant differences were noted in all clinicopathologic features between DGCs and CGCs groups, nor in patient age, gender, *H. pylori* infection rate, status of adjacent mucosa (chronic inflammation, lymphoid follicle, intestinal metaplasia, and atrophy), tumor size, lymphovascular and perineural invasion, and tumor stage between PGCs and non-PGCs groups ( $p > 0.05$ ).

**Conclusions:** Small PGCs display distinct clinicopathologic characteristics, compared to non-PGCs. Given unique prognostic features, the results argue for considering PGC as a separate disease entity.



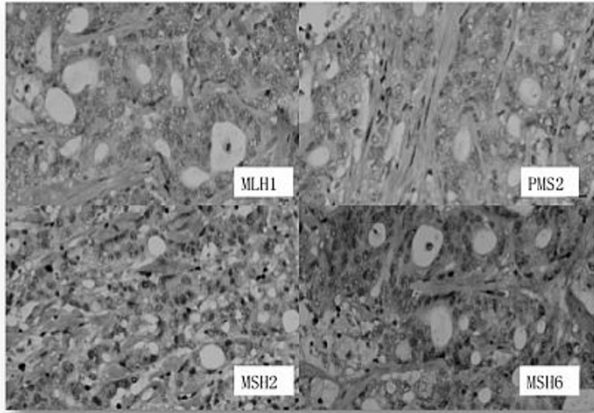
#### 649 Microsatellite Instability and DNA Mismatch Repair Protein Deficiency in Chinese Patients with Sporadic Colorectal Cancer

D Huang, X Chen, B Yu, W Sheng, X Du. Fudan University Cancer Center, Shanghai, China.

**Background:** Sporadic colorectal carcinoma (SCRC) is one of the most common malignancies in the world, and its incidence is highly increased with the changes of lifestyle in Chinese. Researches suggest some SCRCs are developing through the replication error pathways, which could be detected by microsatellite instability (MSI) or DNA mismatch repair (MMR) proteins. This study was to evaluate the prevalence of MSI and loss of MMR protein expression in Chinese.

**Design:** An auto-immunohistochemical staining including 4 antibodies (MLH1, MSH2, PMS2 and MSH6) were used in the paraffin embedded tissue samples from 452 SCRCs. A total of 144 SCRCs including all MMR protein abnormalities performed MSI testing using PCR amplification for five microsatellite locus (BAT25, BAT26, D2S123, D5S346 and D17S250).

**Results:** MMR protein deficiency was seen in 43 of 452 (9.51%) SCRCs. The loss of expression of MLH1, MSH2, PMS2 and MSH6 was identified in 29/452 (6.42%), 5/452 (1.11%), 29/452 (6.42%) and 11/452 (2.43%), respectively. The most common concurrent loss was MLH1 and (observed in 25/452), followed by MSH2 and MSH6 (4/452).



The abnormality of four MMR proteins was detected in one case. For 144 SCRCs in MSI testing, forty-one were classified as MSI-High (MSI-H) and 3 as MSI-Low (MSI-L). MSI-H were seen in 24/29 (82.76%), 5/5 (100%), 25/29 (86.20%) and 10/11 (90.90%) SCRCs with loss expressions of MLH1, MSH2, PMS2 and MSH6, respectively.

Comparison between IHC and MSI

	Cases	H-MSI	L-MSI	MSS
MLH1/PMS2	24	21	0	3
Only MLH1	3	2	1	0
Only PMS2	4	3	0	1
MSH2/MSH6	3	3	0	0
Only MSH2	1	1	0	0
Only MSH6	6	5	1	0
MLH1/MSH6	1	0	0	1
Loss of all	1	1	0	0
MMR-D	43	36	2	5
MMR-I	101	4	2	95
Total	144	40	4	100

Compared to MSI testing, the 2-antibodies immunohistochemical panel (PMS2 and MSH6) was an extremely sensitive (82.5%) and specific (94.2%), which was as good as 4-antibodies panel in screening DNA mismatch repair defects.

**Conclusions:** Our studies showed that the frequency of the replication error abnormalities appears lower in Chinese SCRCs compared with those reported in Western populations. The 2-antibodies immunohistochemical panel (PMS2 and MSH6) achieves good sensitivity and specificity as an alternative screening tool to detect MSI-H SCRCs.

#### 650 Inflammatory Reactions in Mesotheliomas: Diagnostic Pitfalls of Lymphohistiocytic Pattern, Lymphoid Reaction Mimicking Lymph Node Metastasis, and Fibrosclerosing Pattern Mimicking Sclerosing Mesenteritis

T Huebner, JA Collins, A Burke. UMMC, Baltimore, MD.

**Background:** Diffuse malignant peritoneal mesothelioma (DMPM) may be associated with a brisk inflammatory reaction. The histologic features of these tumors have not been studied.

**Design:** We retrospectively reviewed the histologic features of 66 DMPM to assess pitfalls in diagnosis associated with marked inflammatory reaction. In each case, debulking with multiple resection sites was performed prior to hyperthermic intraperitoneal chemotherapy treatment. Immunohistochemical studies were performed.

**Results:** Of 66 DMPM, there were 16 with a marked inflammatory reaction (24%) (9 women, 51 ± 11, 7 men, 61 ± 6 years). The inflammatory response comprised three patterns: nodular lymphoid hyperplasia with germinal centers (n=11); a lymphohistiocytic response (n=3) and a sclerosing mesenteritis-like pattern with broad fibrous bands and lymphoid aggregates (n=2). 3 patients had prior chemotherapy with pemetrexed and cisplatin; these tumors all had nodular lymphoid hyperplasia. 4/50 patients without inflammatory reaction had prior systemic chemotherapy (p=0.3). 4 tumors were epithelioid tubulo-papillary, 12 epithelioid with solid growth, and 2 biphasic with spindle areas. The inflammatory DMPM were more likely to have decidual

areas (n= 9) as compared to DPMP without inflammation (p=.01). Of the 11 tumors with nodular lymphoid hyperplasia, 4 had mesenteric nodules with a lymphoid reaction around them mimicking lymph node metastasis. None of the 66 tumors demonstrated true lymph node metastasis. 3 tumors had areas of lymphohistiocytic growth pattern, with plasmacytoid malignant cells; in two of these cases there was readily identified tubulo-papillary and epithelioid decidual features. In those tumors with a sclerosing mesenteritis-like pattern, there were large areas devoid of malignant cells in one case. Immunohistochemical staining demonstrated diffuse positivity for calretinin in 15/16, EGFR in 15/16, and D2-40 in 9/16. One tumor with a lymphoplasmacytic pattern was negative for all mesothelial markers as well as markers of serous papillary differentiation. **Conclusions:** A prominent lymphoid reaction is present in about 1 in 4 peritoneal mesotheliomas. The lymphoid hyperplasia may mimic lymph node metastasis. A lymphohistiocytic pattern can mimic an inflammatory or lymphoproliferative process, but typical epithelioid areas are usually present. A sclerosing mesenteric-like pattern can obscure the malignant process, but this pattern is the most unusual.

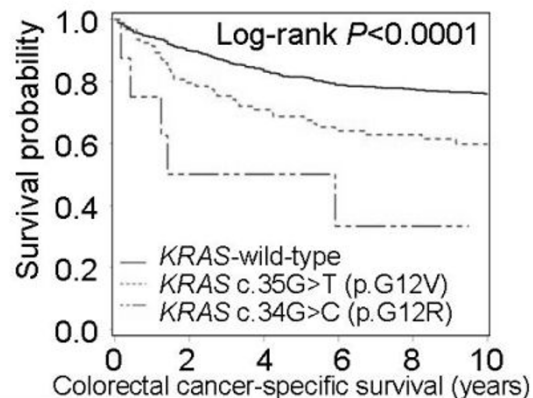
#### 651 KRAS c.35G>T (p.G12V) and c.34G>C (p.G12R) Mutations Predict Shorter Survival in 1925 Colorectal Cancers

Y Imamura, C Fuchs, S Ogino. Dana-Farber Cancer Institute, Boston, MA; Brigham and Women's Hospital, Boston, MA.

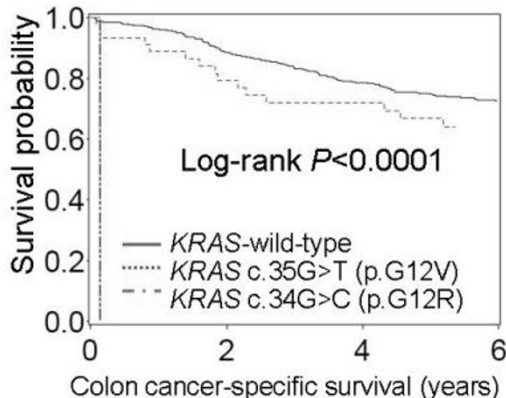
**Background:** KRAS mutation test has become routine for colorectal cancer. Experimental evidence indicates stronger oncogenic effects of KRAS c.35G>T (p.G12V) and c.34G>C (p.G12R) mutations, compared to other codon 12 and 13 mutations. We hypothesized that colorectal cancers with KRAS c.35G>T and c.34G>C mutations might behave more aggressively than tumors with other KRAS mutations and wild-type KRAS. **Design:** We sequenced KRAS codons 12 and 13 in 1925 colorectal cancers, including 1267 stage I-IV colorectal cancers (cohort A) and a validation set of 658 stage III colon cancers in a clinical trial (cohort B). Patient survival was assessed by Kaplan-Meier method, and by Cox proportional hazards model, which was adjusted for other variables, including stage and status of MSI and BRAF mutation.

**Results:** KRAS mutations were detected in 684 (36%) of 1925 tumors. In cohort A, Kaplan-Meier and multivariate Cox regression analyses showed that c.35G>T mutants (N=93) and c.34G>C mutants (N=8) were associated with significantly high colorectal cancer-specific mortality.

#### Cohort A (1267 stage I-IV colorectal cancers)



#### Cohort B (658 stage III colon cancers)



Individual KRAS mutations and colorectal cancer-specific mortality (cohort A)

KRAS	N	Univariate HR (95% CI)	P value	Multivariate HR (95% CI)	P value
Wild-type	635	1 (reference)		1 (reference)	
c.34G>A (p.G12S)	12	2.61 (1.15-5.91)	0.022	1.03 (0.44-2.44)	NS
c.34G>C (p.G12R)	8	4.22 (1.72-10.4)	0.002	3.39 (1.28-9.00)	0.014
c.34G>T (p.G12C)	44	1.70 (1.01-2.85)	0.045	1.56 (0.92-2.65)	NS
c.35G>A (p.G12D)	155	1.47 (1.07-2.04)	0.019	1.08 (0.76-1.51)	NS
c.35G>C (p.G12A)	19	1.36 (0.60-3.08)	NS	0.56 (0.24-1.30)	NS
c.35G>T (p.G12V)	93	1.84 (1.28-2.64)	0.001	2.00 (1.38-2.90)	0.0003
c.38G>A (p.G13D)	103	1.33 (0.90-1.96)	NS	0.88 (0.59-1.30)	NS

CI, confidence interval; HR, hazard ratio; NS, not significant. BRAF mutants were excluded to control for confounding by BRAF. Tumors with two or more different KRAS mutations were excluded.

Findings were essentially replicated in our validation cohort B (stage III colon cancers in the trial)(Figure, the bottom panel).

**Conclusions:** Colorectal cancers with KRAS c.35G>T and c.34G>C mutations are aggressive tumor subtypes, and KRAS status serves as a prognostic biomarker. Our data highlight the importance of accurate molecular characterization of colorectal cancer.

**652 The Incidence of EBV and Her2 Positivity in Gastric Cancers**

C Irkkan, S Balci, G Guler Tezel, B Akinci, B Yalcin, G Guler. Yildirim Beyazit University, Ankara, Turkey; Hacettepe University, Ankara, Turkey.

**Background:** After realisation of H.pylori pathogenesis, gastric carcinoma incidence declined in developed countries. New associations like Epstein Barr Virus (EBV) infection and Targeted therapy related comprehensive investigations of prevalence, prognostic value and associations of Her2 positivity emerged recently. Here we searched the association between EBV positivity and Her2 status of gastric carcinoma.

**Design:** From 106 gastrectomy specimens, most intestinal differentiated tumor tissue blocks were selected. Her2 was searched with clone:4B5 immunohistochemistry (IHC) and Brightfield Dual Silver In situ hybridisation (ISH) methods and EBV status is searched with Inform EBER ISH method; all techniques performed on the same automated platform.

**Results:** Her2 positive, EBER positive and tumors negative for both were different in terms of T stage and median survival but not other features.

Histomorphologic and survival features according to Her2 and EBV status

	All cases (n=106*)	Her2 positive (n=13)	EBER positive (n=7)	Negative for both (n=85)	P	
Age	59.5±13.5	64.6±12.6	62.0±16.6	58.7±13.4	0.307	
Gender M:F	79:27	11:2	7:0	60:25	0.153	
Histologic subtype	Diffuse	22(20.8%)	1(7.7%)	1(14.3%)	20(23.5%)	0.073
	Intestinal	49(46.2%)	10(76.9%)	1(14.3%)	38(44.7%)	
	Mixed	25(23.6%)	2(15.4%)	3(42.9%)	20(23.5%)	
	Undiff	10(9.4%)	0	2(28.6%)	7(8.2%)	
T	T1	7(6.6%)	1(7.7%)	0	6(7.1%)	0.038
	T2	12(11.3%)	1(7.7%)	0	11(12.9%)	
	T3	23(21.7%)	7(53.8%)	0	16(18.8%)	
	T4	64(60.4%)	4(30.8%)	7(100%)	52(61.2%)	
Lymph node	Negative	22(21.4%)	3(25.0%)	0	18(21.4%)	0.420
	Positive	81(78.6%)	9(75.0%)	6(100%)	66(78.6%)	
Metastasis	M0	46(59.7%)	5(50.0%)	4(66.7%)	36(60.0%)	0.777
	M1	31(40.3%)	5(50.0%)	2(33.3%)	24(40.0%)	
Tumor size(cm)	5.5±3.1	5.1±2.4	5.6±3.2	5.6±3.2	0.870	
LVI	61(57.5%)	4(30.8%)	5(71.4%)	52(61.2%)	0.089	
PNI	42(39.6%)	4(30.8%)	4(57.1%)	33(38.8%)	0.512	
Median survival(months)	18	20	11	19	0.005	

\*One case was positive for EBER and Her2 IHC and was borderline in ISH. It is included under descriptive statistics but discarded from statistical comparisons. Percentages are given for univariate.

**Conclusions:** EBV positive group had significantly shorter overall survival in univariate but not in multivariate analyses. This relation needs to be confirmed in larger cohorts. Ratios of EBV positivity (7.8%) and Her2 amplification (11%) of gastric carcinomas in our country are lower than western countries. Lower Her2 rates is thought to be related with higher diffuse type carcinoma incidence in our country.

**653 Correlation of Her2 Protein Expression and Gene Amplification between Endoscopic and Surgical Specimens of Gastric Cancer**

C Irkkan, S Balci, G Guler Tezel, B Akinci, B Yalcin, G Guler. Yildirim Beyazit University, Ankara, Turkey; Hacettepe University, Ankara, Turkey.

**Background:** Reported incidence of Her2 expressing gastric carcinoma is between 6-35%. Recent phase III trial has shown the survival benefit in metastatic gastric carcinoma treated with anti-Her2 therapy. Because of reported heterogenous expression pattern of Her 2 in gastric carcinoma, predictive power of endoscopic biopsies in determining the Her2 status is an important issue. Correlation of Her2 status determined by both immunohistochemistry (IHC) and In situ hybridisation (ISH) techniques in endoscopic biopsies (EB) and gastrectomy specimens (GS) was the aim of this study.

**Design:** GS and previous EB from 42 gastric tumors in our database are retrospectively searched for their Her2 status by clone:4B5 IHC and Brightfield Dual Silver ISH techniques. Both techniques are performed on the same automated platform (Ventana, Benchmark GX). Heterogeneity of Her2 IHC staining was categorised as dispersed or clustered in both EB and GS.

**Results:**

Comparison of IHC results in EB versus GS

	IHC GS			Total	
	0, 1+	2+	3+		
IHC EB	0, 1+	32	2	0	34
	2+	1	1	1	3
	3+	1	0	4	5
	Total	34	3	5	42

Among 5 (11.90%) discordant results; cause was heterogeneity in 3 (dispersed in 2, clustered in 1). Cause can be speculated as preanalytical in the other 2. Satisfactory reaction with ISH technique could not be achieved in some of the EB-GS pairs. Therefore only 28 of 42 EB-GS pairs were available to compare.

Comparison of ISH results in EB versus GS

	ISH GS			Total
	Negative	Borderline	Positive	
ISH EB	Negative	20	0	20
	Borderline	1	0	1
	Positive	0	0	0
	Total	21	0	21

Number of discordant results decreased with ISH (7.14%); and heterogeneity was the cause in both of them (1 dispersed, 1 clustered). Discordance rate with IHC was 16.66%, with ISH was 7.14%.

**Conclusions:** Her2 status heterogeneity was the major cause of discordant results between EB and GS. Dispersed heterogeneity is more effective than clustered in our cases. In 14 (33%) of our 42 cases, because of preanalytical variability of mainly fixation time, satisfactory reaction could not be achieved with ISH. IHC seems to be more effective in cases with preanalytical problems. Discordant results in EB did not cause overdiagnosis in any case which would have resulted in unnecessary treatment, however one patient with a negative Her-2 result in EB both by IHC and ISH, was found Her-2 positive in GS. Our results support the simultaneous use of ISH and IHC for Her-2 testing in gastric cancer.

**654 Intrarectal Patch of Primary Squamous Cell Carcinoma (SCC): A Rare HPV-Related Variant**

R Jain, I Lamzabi, S Jakate. Rush University Medical Center, Chicago, IL.

**Background:** Unlike adenocarcinoma, primary rectal SCC is extremely rare and largely presumed to be proximal extension of anal SCC. In the absence of anal SCC, an isolated intrarectal SCC is clinically and endoscopically unforeseen and poses challenges regarding its origin, pathogenesis, extent, behavior and management. We describe 6 cases of primary intrarectal SCC including possible pathogenetic pathway, distinctive patch-like endoscopic findings, management and follow-up.

**Design:** We recovered 6 cases of isolated rectal SCC (ages 41-94, median age 60) from our database between 2005-2012. Other cases with current or past anal or cervical condyloma, dysplasia or SCC were excluded. The clinical presentation, endoscopic findings, pathological features including HPV (in-situ hybridization for HPV6 and 16) and p16 immunostain, management and follow-up of these cases were reviewed.

**Results:** Males outnumbered females in our small population (2:1). Clinical presentation included rectal bleeding (2/6), screening colonoscopy (2/6), IBD surveillance (1/6) and colonoscopy after detection of liver metastasis (1/6). Endoscopically, no perianal or anal canal abnormality was seen, all tumors were above the dentate line (range of 1-6cm), surrounded on all sides by normal rectal mucosa and described either as irregular pale firm patch (4/6) or nodular carpet-like lesions (2/6). Histologically, 4/6 showed invasive moderately or poorly differentiated SCC and 2/6 SCC-in-situ (CIS). No squamous metaplasia was seen in the surrounding rectal mucosa. All 6 tumors (100%) were strongly and diffusely positive for p16 and 4/6 cases (66%) were positive for HPV 16 (high risk HPV). 2 patients with CIS underwent endoscopic mucosal resection (EMR), and 4 patients with invasive SCC underwent chemoradiotherapy (Nigro protocol). Patients with CIS remained disease-free, one patient with initial liver metastasis died and 1 of remaining 3 patients underwent subsequent APR (range of follow-up 6 months to 6 years).

**Conclusions:** Primary intrarectal SCC, unaccompanied by anal SCC is extremely rare and may be symptomatic or detected incidentally. Endoscopically, it is distinctly patch-like in most cases. While HPV is known to infect anal and cervical squamous epithelium, occasionally an isolated patch of distal rectal mucosa is infected by high risk HPV. Even when HPV cannot be demonstrated, the oncogenetic pathway appears to finally involve the cyclin-dependant kinase inhibitor 2A (P16). Even with uncertainty regarding its management, most patients are successfully treated by EMR for CIS and chemoradiotherapy for invasive SCC similar to anal SCC.

**655 An Institution-Wide Screening Program for Hereditary Non-Polyposis Colorectal Cancer Identified Microsatellite Instability in Patients Who Would Not Have Been Tested Using the Revised Bethesda Guidelines**

JL Jerz, H Takei, H Hendrickson, RJ Olsen, MR Schwartz. Methodist Hospital, Houston, TX.

**Background:** Hereditary non-polyposis colorectal cancer (HNPCC, Lynch Syndrome) is characterized by a germ line mutation in DNA mismatch repair (MMR) genes. Traditionally, the Revised Bethesda Guidelines (RBG) have been used to select patients for HNPCC screening. However, the RBG may not be all inclusive. Thus, our hospital implemented a standardized microsatellite instability (MSI) testing protocol for all newly diagnosed colorectal cancers in patients under the age of 70 years.

**Design:** Laboratory and medical records were reviewed from patients representing the first consecutive 100 MSI tests performed. MSI, immunohistochemistry staining for mismatch repair proteins, and BRAF gene mutation data were evaluated.

**Results:** 49 men and 51 women with newly diagnosed colorectal cancer were screened. The average age was 51 years (range 22 to 87 years). A few patients over the age of 70 had MSI testing ordered. Cancers of all stages and anatomic locations were represented, including 11 cases of metastatic disease. Of note, only 15 cases were mucinous adenocarcinomas, a morphologic feature of HNPCC and criterion in the RBG. Microsatellite testing was abnormal (MSI-high) in 15 cases. All MSI-high tumors underwent follow-up testing for the BRAF mutation. Nine showed an actionable, "wild-type" BRAF result that would warrant further genetic testing. Although seven of these patients were over the age of 50, four had mucinous features, which would have triggered MSI testing by RBG. The remaining three patients would have been missed by strict adherence to the RBG.

**Conclusions:** A hospital-wide screening protocol for MSI has been successfully implemented at our institution. MSI-high tumors occurred at a frequency similar to previous publications. Importantly, three patients would not have been screened using the RBG. This is significant since patients with microsatellite instability are managed differently than those with sporadic carcinomas. Our initial data set indicates that the RBG for HNPCC microsatellite screening may be too stringent, specifically the age and histologic features criteria which are the criteria most readily available to the pathologist.

#### 656 Abnormal Cyclin D1 and Chromosome 11 Centromere Detected by FISH in Non-Dysplastic Surveillance Biopsies Predicts Pouch Neoplasia

W Jiang, M Bronner, B Shadrach, X Wu, B Shen, X Liu. Jefferson Medical College, Thomas Jefferson University, Philadelphia, PA; University of Utah, Salt Lake City, UT; Cleveland Clinic, Cleveland, OH.

**Background:** The occurrence of adenocarcinoma following restorative proctocolectomy with ileal pouch-anal anastomosis (IPAA) for ulcerative colitis (UC) is an infrequent but lethal complication. Endoscopic biopsy surveillance has a low sensitivity for pouch neoplasia detection. The aim of this study was to determine if genomic biomarkers in non-dysplastic pouch/peripouch biopsies can improve neoplasia surveillance in patients with IPAA.

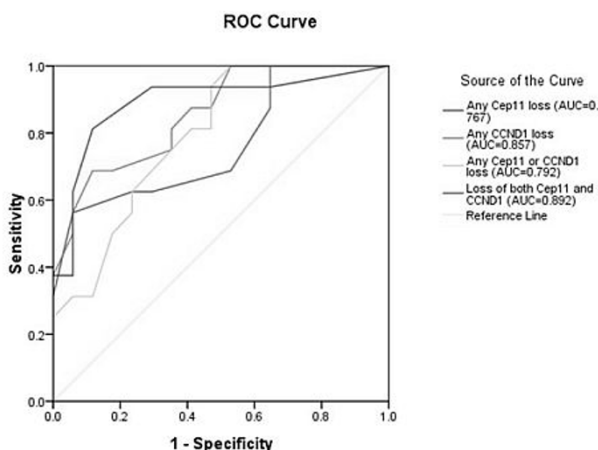
**Design:** Cyclin D1 (CCND1) and chromosome 11 centromere (CEP11) loci were analyzed by FISH in fixed, paraffin-embedded non-dysplastic pouch and peripouch biopsies from 13 patients with pouch neoplasia (progressors) and those without it (non-progressors, n=10). A total of 33 biopsies (16 from progressors and 17 from non-progressors) were examined. Results were expressed as % cells with abnormal CEP11 and/or CCND1 copy number.

**Results:** Loss of CCND1 and/or CEP11 was noted in more cells in non-dysplastic pouch biopsies from progressors than non-progressors (Table 1). In contrast, gain of cyclin D1 and/or CEP11 was noted more frequently in non-dysplastic biopsies from non-progressors than progressors. The distinction between progressor and non-progressor based on the loss of both CEP11 and CCND1 has an area under curve of 0.892 in ROC curve models (Figure 1).

Table 1. Frequency of CEP11 and CCND1 abnormality in non-dysplastic biopsies from UC patients with IPAA

Abnormality*	Progressor	Nonprogressor	p value
CEP11 loss	7.8 ± 6.1	3.4 ± 2.8	0.009
CCND1 loss	11.7 ± 5.4	5.0 ± 3.6	0.00047
CEP11 or CCND1 loss	14.0 ± 6.4	7.2 ± 4.9	0.0041
Loss of CEP11 and CCND1	5.5 ± 4.7	1.2 ± 1.4	0.00012
CEP11 gain	3.7 ± 2.4	7.0 ± 4.0	0.012
CCND1 gain	2.7 ± 2.2	5.2 ± 2.8	0.013
CEP11 or CCND1 gain	5.1 ± 2.6	8.8 ± 3.6	0.004
Gain of CEP11 and CCND1	1.4 ± 1.4	3.5 ± 2.9	0.028

\* Results were presented as % of cells, mean ± standard deviation



**Conclusions:** Genomic biomarkers in non-dysplastic pouch/peripouch biopsies distinguish progressors from non-progressors and improve neoplasia surveillance in patients with IPAA. Further studies are needed to confirm the current findings.

#### 657 BRAF V600E Mutation Analysis Simplifies the Testing Algorithm for Lynch Syndrome

M Jin, H Hampel, X Zhou, L Schunemann, MM Yearsley, WL Frankel. Ohio State University, Columbus, OH.

**Background:** Lynch syndrome (LS), the most common inherited predisposition to colorectal cancer (CRC), is associated with germline mutations in DNA mismatch repair (MMR) genes. Immunohistochemistry (IHC) staining for MMR proteins is well established in CRCs to identify patients who are more likely to have LS and to help direct gene testing. Reflex testing for the BRAF-V600E mutation analysis has been suggested when the MLH1 and PMS2 proteins are absent, since BRAF mutations are not present in CRCs from patients with LS but are associated with sporadic CRCs due to MLH1 promoter hypermethylation. We evaluated our experience to determine the impact of adding reflex BRAF analysis following IHC staining.

**Design:** All newly diagnosed CRCs at our institution are screened by IHC stains for the MMR proteins (MLH1, MSH2, MSH6 or PMS2). Proteins exhibiting any convincing nuclear staining (greater than 1-5%) were considered present. Since 1/1/09, BRAF V600E mutation analysis has been performed for CRC with absence of MLH1 and PMS2 proteins. Mutation analysis was carried out on genomic DNA extracted from paraffin embedded tumor tissue by PCR amplification of BRAF exon 15 followed by direct sequencing. Those patients with BRAF mutation were not contacted since they were presumed not to have LS, while those without BRAF mutation were contacted for follow-up genetic counseling and testing.

**Results:** From 1/1/2009 to 7/10/2012, 90 of 412 (22%) CRCs screened had at least one MMR stain absent. Sixty-five (15.8%) had MLH1 and PMS2 absent and 25 (6.1%) had any other stain(s) absent. BRAF V600E mutation was found in 36 of 65 (55%) CRCs with absent MLH1 and PMS2 stains. Of all cases screened, 54 of 412 (13%) required follow-up after the addition of BRAF analysis compared to 90 who would have required follow-up without BRAF analysis. Therefore, the addition of BRAF analysis to the testing algorithm reduced the number of CRCs requiring follow-up genetic counseling by 40% (54 vs. 90). Additional testing found that 4 patients with absent MLH1 and PMS2 and negative BRAF mutation had MLH1 hypermethylation.

**Conclusions:** Routine IHC staining of MMR proteins on newly diagnosed CRCs is feasible and can be clinically implemented. Reflex BRAF mutation testing in cases with absence of MLH1 and PMS2 reduced the number of patient contacts and simplified the genetic testing for LS, likely leading to cost savings. It appears that MLH1 promoter methylation testing may be even more effective at reducing the number of cases that need follow-up genetic counseling and testing.

#### 658 MLH1 Hypermethylation and BRAF Mutation Testing in Colorectal Cancer Patients with Mismatch Repair Defect

M Jin, M Clendenning, H Hampel, WL Frankel. Ohio State University Wexner Medical Center, Columbus, OH; Queensland Institute of Medical Research, Herston, Queensland, Australia.

**Background:** Lynch syndrome (LS) is associated with germline mutations in DNA mismatch repair (MMR) genes (MLH1, MSH2, MSH6 or PMS2), and accounts for 2-5% of all colorectal cancers (CRCs). Patients with LS almost never have a BRAF mutation or MLH1 hypermethylation in their tumor. We evaluated MLH1 hypermethylation and BRAF mutation testing following microsatellite instability (MSI) testing or immunohistochemistry (IHC) for MMR proteins to determine their utility in testing algorithms for identifying LS.

**Design:** 93 newly diagnosed CRC patients with either MSI-H (82) or at least one absent MMR protein (89) were included from a local LS study. BRAF mutation and MLH1 hypermethylation analyses were compared for cases with MSI-H and/or absence of MLH1 and PMS2 proteins. BRAF mutation (V600E) analysis was carried out by PCR amplification of exon 15 followed by direct sequencing. MLH1 hypermethylation status was studied by methylation specific PCR. Genetic germline mutation testing was performed on CRCs with MSI-H and/or any absent MMR protein.

**Results:** Of 82 MSI-H cases, 53/79 were BRAF mutation negative and 50/82 were not MLH1 hypermethylated. BRAF mutation was found in 25/32 (78%) MLH1 hypermethylated cases, and MLH1 hypermethylation was present in 25/26 (96%) with BRAF mutation. 3 fewer patients (50 vs. 53) would have needed further germline testing if MLH1 hypermethylation analysis were used rather than BRAF testing. Genetic testing confirmed 43/82 MSI-H had LS. Of 89 with at least one absent MMR protein, 46 had MLH1 and PMS2 absent and 43 had other stain(s) absent. Among 46 with MLH1 and PMS2 absent, 19/43 were not BRAF mutated and 14/46 were not MLH1 hypermethylated. 25/32 (78%) MLH1 hypermethylated cases had BRAF mutation, and 24/24 (100%) with BRAF mutation had MLH1 hypermethylation. 5 fewer patients (14 vs. 19) would have needed further germline testing if MLH1 methylation analysis were used rather than BRAF testing. 9/46 with absent MLH1 and PMS2 and 34/43 with absence of other MMR protein(s) were found to have LS by confirmatory genetic testing. None of 43 LS cases were found to have BRAF mutation or MLH1 hypermethylation.

**Conclusions:** Both BRAF mutation and MLH1 hypermethylation testing following MSI or MMR IHC are useful in identifying LS. MLH1 hypermethylation testing excludes more patients from further germline analysis, and is therefore potentially more cost effective.

#### 659 Cytomegalovirus (CMV) Infection in Inflammatory Bowel Disease: Role, Prevalence, Predictive Features, and Outcomes

A Jones, TC Smyrk, DH Bruining. Mayo Clinic, Rochester, MN.

**Background:** The role of CMV infection in inflammatory bowel disease (IBD) is unknown, particularly when deciding whether to initiate antiviral therapy. Clinical clues (systemic symptoms, exposure to immunosuppressive agents, lack of response to therapy, and marked disease activity) often generate requests for ancillary studies, in the hope that antiviral therapy in positive cases will improve the patient's clinical condition and avoid colectomy. We aimed to assess prevalence of CMV infection in IBD patients deemed at risk, evaluate predictive parameters, histopathology, and clinical outcomes.

**Design:** We searched the electronic pathology data base for the years 2005-2011 for all patients with IBD in whom CMV was suspected. Slides from all positive cases were reviewed for disease activity, ulcer and number of viral inclusions. Medical records were reviewed for clinical presentation, endoscopy, treatment, and outcome.

**Results:** CMV was suspected in 1293 IBD patients; 70 (5.4%) had a positive result. 73% patients had received steroids within 2 weeks of the diagnosis. Systemic symptoms were uncommon; only 19% had fever. The endoscopic impression was "severe colitis" in 51% of cases and 77% had visible ulcers. Microscopically, ulcers were identified in 35% of cases. Inclusions were documented by IHC/ISH in 56 and by H&E only in 14 cases. In cases subjected to IHC/ISH, 19 had only a single inclusion, and 37 had more than one inclusion. There were no differences between these two groups in terms of clinical

presentation, endoscopic findings or histopathologic activity. When CMV serology was performed, it was negative in 100% of patients with one inclusion, positive in 15% of those with 2-10 inclusions and positive in 70% of those with more than 10 inclusions. 50 patients received antiviral therapy; those with fewer inclusions were treated less often. Follow up endoscopy showed improvement especially in the treated group with higher number of inclusions. 47% of patients eventually had colectomy; treated patients were less likely to have colectomy in the first 60 days after positive CMV diagnosis. **Conclusions:** Clinical parameters suggesting CMV infection in IBD are not specific; only 5.4% of biopsy sets had a positive result. Failure to respond to escalating therapy, severe colitis and visible ulcers seem to be the most sensitive clinical clues. The seemingly poor response to antiviral therapy for patients with fewer inclusions may indicate that CMV is an innocent bystander in those cases.

#### 660 The Natural History of Anal Squamous Dysplasia – An 8 Year Follow Up Study

S Kavasi, MR Peterson. University of California, San Diego, CA.

**Background:** The natural history of HPV associated anal squamous dysplasia/anal intraepithelial neoplasia (AIN) has not been well studied, in contrast to cervical squamous dysplasia. A prior study was performed at our institution using a cross section of anal biopsies performed in 2004 that compared the morphologic grade of AIN to p16<sup>INK4A</sup> status and the results of HPV in situ hybridization. Using this prior data, we attempted to determine the outcome of the patients with AIN and correlate this with their prior AIN grade, p16<sup>INK4A</sup> status, and HPV in situ hybridization results.

**Design:** Data from the prior study was obtained, including the morphologic diagnosis, p16<sup>INK4A</sup> status, and the results of in situ hybridization for high-risk HPV subtypes. Follow up data, including both anal cytology preparations and anal biopsies, were collected from our pathology information system. Patients with less than 4 years of follow up were excluded. For the purposes of this study, ASCUS was considered synonymous with LSIL, and ASC-H with HSIL. The data from the prior study and the follow up material were compared.

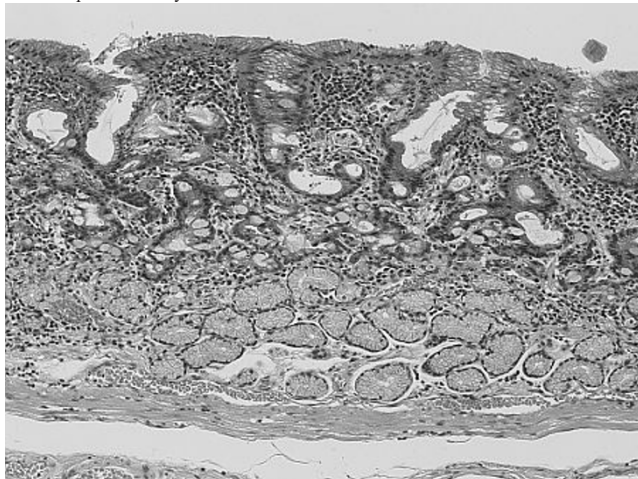
**Results:** A total of 51 patients with an original biopsy diagnosis of LSIL (AIN1) or HSIL (AIN2&3) were included. The follow up period was between four to eight years from the time of initial diagnosis in 2004 (mean= 6.81 years). None of the patients in this cohort developed invasive squamous carcinoma. The follow up by both biopsy and cytology was notably variable. 5 of 13 (38%) patients with LSIL at the index biopsy were found to have HSIL at some point in their follow-up, while 6 of 38 (16%) of patients with HSIL at the index biopsy showed no evidence of HSIL in any of the follow up material. 24 of the total of 51 (47%) patients had at least one benign sampling (and many with multiple). The best predictor of subsequent HSIL on follow up was histological HSIL in the index biopsy (RR 2.189, p=0.0030). P16<sup>INK4A</sup> status was also significantly associated with HSIL on follow up (RR 1.768, p=0.0273). Interestingly, the presence of high-risk types of HPV was not significantly associated with finding HSIL on follow up (RR 1.441, p=0.0578).

**Conclusions:** In the time frame of this study, with a mean follow up of almost 7 year and a total of 339 patient-years, none of the patients developed squamous carcinoma. This suggests that AIN typically follows a variable but generally indolent course. The single best predictor of a diagnosis of HSIL in subsequent sampling is a morphologic diagnosis of HSIL, with p16<sup>INK4A</sup> positivity also being significantly associated with subsequent HSIL.

#### 661 “Crawling-Type” Adenocarcinoma of the Stomach: A Distinct Entity Preceding Poorly Differentiated Adenocarcinoma

H Kawachi, N Okamoto, T Yoshida, K Kitagaki, M Sekine, M Kobayashi, K Kojima, T Kawano, Y Eishi. Tokyo Medical and Dental University/Clinica Las Condes, Santiago, Chile; Tokyo Medical and Dental University, Tokyo, Japan; Kudanzaka Hospital, Tokyo, Japan.

**Background:** Gastric “crawling-type” adenocarcinoma (CTAC) is a neoplasm histologically comprising irregularly fused glands with low-grade cellular atypia that tends to spread laterally in the mucosa.



Although the importance of this subgroup has been mentioned, the clinicopathological characteristics have not been adequately described.

**Design:** To elucidate the clinicopathological characteristics of CTAC, we evaluated 25 CTACs, 16 intramucosal (M-) and 9 submucosal invasive (SM-) cancers, clinicopathologically and immunohistochemically.

**Results:** CTAC was most frequently located in the lesser curvature of the middle-third of the stomach. Macroscopically, 21 lesions were superficial-depressed and 4 were superficial-flat type. Histologically, all CTACs had cystic dilated glands and 16 lesions had focal signet-ring cells. All invasive areas of the SM-CTACs were occupied by poorly differentiated adenocarcinoma with an infiltrative growth pattern and abundant stroma. Fifteen CTACs were surrounded by mucosa with partial or no intestinal metaplasia. In the intramucosal area, 24 lesions were mixed phenotype with mucin and brush border immunorexpression. SM-CTAC was frequent in lesions with an intramucosal poorly differentiated component (PDC) greater than 10 mm in size (P=0.041), and lymph node metastasis (LNM) was frequent in lesions with a PDC greater than 20 mm (P=0.039). The frequency of an expanded pattern (Ki-67-positive cells occupying > 50 % of the mucosa) was higher in SM-CTAC than in M-CTAC (P=0.027). p53 overexpression was not detected in the intramucosal areas of any of the lesions.

**Conclusions:** The use of the diagnostic term “CTAC” has implications for selecting a distinct subgroup of gastric adenocarcinomas in the early phase. A larger PDC area and an expanded of Ki-67-positive cells have practical implications for the prediction of submucosal invasion or LNM.

#### 662 Peritoneal Malignant Mesothelioma (PMM), Papillary Serous Adenocarcinoma (PSA), and Reactive Mesothelial Hyperplasia (RMH) of the Peritoneum. An Immunohistochemical and Fluorescence In Situ Hybridization (FISH) Analysis

T Kawai, S Hiroi, S Ogata, K Nakanishi, K Hiroshima, T Shinagawa, S Shimizu. National Defense Medical College, Tokorozawa, Saitama, Japan; Tokyo Women's Medical University Yachiyo Medical Center, Yachiyo, Chiba, Japan; Kawasaki Municipal Ida Hospital, Kawasaki, Kanagawa, Japan; Showa General Hospital, Kodaira, Tokyo, Japan.

**Background:** PMM is an uncommon tumor, accounting recently for only 7-9% of all mesotheliomas in Japan. Differential diagnosis between PMM and PSA may be difficult, and separating of RMH from PMM can be even more challenging. Studies describing the immunohistochemical and 9p21 FISH analyses of PMM are lacking. Differential diagnosis among PMM, PSA, and RMH of the peritoneum would be less difficult if it could be informed by mesothelial positive markers.

**Design:** To help differentiate PMM from PSA and RMH, we used (a) immunohistochemistry and (b) FISH to examine for: (a) mesothelial positive markers (calretinin, AE1/AE3, CK5/6, CAM5.2, D2-40, WT-1, HBME1, thrombomodulin), adenocarcinoma markers (CEA, BerEP4, MOC31, ER, PgR), and malignant and benign related markers (EMA, desmin, GLUT-1, CD146, and IMP3) and (b) homozygous deletion of 9p21. We used formalin-fixed, paraffin-embedded blocks from 20 PMMs (M:F=16:4; subtypes: 9 epithelioid, 6 biphasic, 5 decudoid), 11 PSAs, and 23 RMHs. **Results:** Fifteen of the mesotheliomas were classified as diffuse, while 5 were localized. Calretinin was at a high positive rate (90%) in PMM, but negative in PSA, with both sensitivity (90%) and specificity (100%) being very high. BerEP4 was at a high rate (100%) in PSA, but negative in PMM, with both sensitivity (100%) and specificity (100%) being very high. For the differentiation of PMM from RMH of the peritoneum, the sensitivity and specificity for EMA in mesothelioma were 65% and 100%, respectively. For GLUT-1, sensitivity was 50% and specificity 100%. For IMP3, sensitivity was 12% and specificity 95%. Homozygous deletion was considered to be present if both 9p21 signals were lost in at least 20% of nuclei and at least one signal for chromosome 9 copy number probe was shown in each nucleus. FISH analysis revealed homozygous deletion of the 9p21 locus in 11/11 of PMM, but in none of RMH.

**Conclusions:** Calretinin and BerEP4 may be the best positive markers for differentiating PMM from PSA of the peritoneum. EMA displayed high specificity, but a lower sensitivity than previously reported. Homozygous deletion of 9p21 (assessed by FISH) may be helpful for differentiating PMM from RMH.

#### 663 Lymphocytic Gastritis: A Distinct Nosologic Entity or a Histopathologic Expression of Other Conditions?

M Kherad Pezhouh, A Cockburn, R Genta. Miraca Life Sciences Research Institute, Irving, TX; University of Texas Southwestern Medical Center, Dallas, TX.

**Background:** Lymphocytic gastritis (LG) has been associated with a form of severely erosive nodular gastritis (varioliform gastritis). However, increased lymphocytic infiltrates in the gastric epithelium are reported in patients with *H. pylori* infection, celiac disease and microscopic colitis. This study was designed to determine whether LG is a distinct nosologic entity irrespective of its associations, or represents the histopathologic manifestation of other conditions.

**Design:** Using a nationwide pathology database, we extracted all patients who had an esophagogastroduodenoscopy (EGD) with a histopathologic diagnosis of LG and duodenal and colonic biopsies between 1/2008 - 12/2011. Patients with gastrointestinal cancer or surgery were excluded. LG patients were divided in two groups: LG without concurrent intestinal lymphocytosis (LG-Alone); and LG with intestinal lymphocytosis (duodenal, celiac sprue, or microscopic colitis; LG-IL). Patients with LG with *H. pylori* infection were also analyzed separately.

**Results:** There were 206 patients with LG and simultaneous duodenal and colonic biopsies: 91 patients (median age 61 years; 54% female) had LG-Alone (21 with *H. pylori* infection) and 115 (median age 65 years; 71% female) had LG-IL (5 with *H. pylori* infection). Compared to those with LG-IL, patients with LG-Alone were more likely to have erosions/ulcers (15.4% vs. 7.8%; OR 2.15) and twice as likely to be male (46% vs. 29%; OR 2.13). Anemia was a more common indication for EGD in patients with LG-Alone (22% vs. 14%), while diarrhea and vomiting were more common in patients with associated lymphocytosis than in those with LG-Alone. *H.*

*pylori* infection was more common in patients with LG-Alone than in those with LG-IL (23% vs. 4.4%; OR 6.54); however, when patients with *H. pylori* were excluded, the correlations remained similar.

**Conclusions:** These data suggest that gastric intraepithelial lymphocytosis may not be a single disease. In some patients it is the epiphenomenon of intestinal conditions characterized by intraepithelial lymphocytosis and a high prevalence of diarrhea. In other, younger and mostly male patients, it is restricted to the stomach, is associated with a higher prevalence of anemia and may be the expression of an autoimmune phenomenon. In a portion of LG-Alone patients intraepithelial lymphocytosis may be associated with or precipitated by *H. pylori* infection. The relative rarity of ulcers and erosions suggests that varioliform gastritis may have become an obsolete condition.

#### 664 Does Clear Cell Carcinoma of Stomach Exist? Clinicopathological and Prognostic Significance of Clear Cell Changes in 762 Gastric Adenocarcinomas

A Kim, J-Y Kim, N Shin, W-Y Park, DY Park. Pusan National University Hospital, Busan, Korea.

**Background:** Clear cell carcinoma as a variant of gastric adenocarcinoma is not well recognized in compared to that of ovary or uterine endometrium, which is a distinct subtype with poor survival.

**Design:** We have evaluated 762 gastric adenocarcinomas for the presence of clear cell changes of the cytoplasm and investigated its relationship with various clinicopathological features of gastric adenocarcinoma as well as the prognostic significance.

**Results:** We have found that 11.5% (n=88/762) of our gastric adenocarcinoma cases showed clear cell changes. Gastric adenocarcinoma with clear cell changes (clear cell proportion  $\geq 5\%$  of tumor mass) showed tubular (77.3%, 68/88), tubulopapillary (12.5%, 11/88), poorly solid (8.0%, 7/88) and papillary histologic features (2.3%, 2/88). Gastric adenocarcinoma with clear cell changes was significantly associated with increased age ( $p=0.000$ ), larger tumor size ( $p=0.015$ ), more excavated gross morphology ( $p=0.000$ ), intestinal histologic type ( $p=0.000$ ) and more antral location ( $p=0.000$ ). Also presence of clear cell component was associated with increase of depth of invasion ( $p=0.000$ ), increase of lymph node metastases ( $p=0.000$ ), presence of lymphovascular tumor emboli ( $p=0.000$ ) and perineural invasion ( $p=0.001$ ) in the 762 gastric adenocarcinoma patients. Gastric adenocarcinomas were also associated with poor prognosis (shorter survival) based on the proportion of clear cell component ( $< 5\%$ : 72.03  $\pm$  0.90, 5-15%: 61.58  $\pm$  4.55,  $> 15\%$ : 56.59  $\pm$  7.62,  $p=0.0013$ ). The presence of clear cell proportion was identified as an independent, poor prognostic factor using the Cox regression proportional hazard model (hazard ratio, 0.471;  $p = 0.001$ ) in gastric adenocarcinoma adjusted for age, site of location, Lauren classification, depth of invasion and lymph node status.

**Conclusions:** We suggested that gastric adenocarcinoma with clear cell changes could be a distinct subtype of gastric adenocarcinoma with poor prognosis. More detailed and multi-institutional studies are needed to determine precise significance of clear cell changes in gastric adenocarcinoma.

#### 665 Gastroesophageal Junction (GEJ) – Definition and Histopathologic Features – Eastern View

A Kim, J-Y Kim, N Shin, W-Y Park, DY Park. Pusan National University Hospital, Busan, Korea.

**Background:** There were debates about definition and features of GEJ and histopathologic features of gastric cardiac mucosa. However, most reports were originated from Western countries, which showed different prevalence of GEJ adenocarcinoma and GERD (gastroesophageal reflux disease) compared to Eastern countries.

**Design:** On this background, we have tried to investigate anatomic and histopathologic features of GEJ by histological mapping in 30 esophagogastricectomy specimens (mean age = 63) of middle and lower esophageal squamous cell carcinoma. We assessed following histologic features, including lengths of cardia mucosa (CM), oxyntocardiac mucosa (OCM), esophageal cardiac mucosa (ECM), and presence of intestinal metaplasia, pancreatic metaplasia, Brunner's like glands, submucosal esophageal gland beneath cardiac mucosa and their relationship with age, gross features of GEJ.

**Results:** Length of CM, ECM was significantly increased with age ( $< 63$ , 2767.86  $\pm$  734.95  $\mu$ m vs  $\geq 63$ , 5453.12  $\pm$  839.52  $\mu$ m,  $p=0.025$ ;  $< 63$ , 1151.78  $\pm$  452.81  $\mu$ m vs  $\geq 63$ , 2273.44  $\pm$  321.58  $\mu$ m,  $p=0.049$ ). Presence of intestinal metaplasia ( $p=0.003$ ), irregular GEJ ( $p=0.030$ ) and circumferential location of cardiac mucosa ( $p=0.019$ ) were also associated with increased with age. Presence of esophageal submucosal glands beneath cardiac mucosa, pancreatic metaplasia and Brunner-like glands were seen 8/30 (26.7%), 15/30 (50%), and 14/30 (46.7%) cases. Presence of ECM, columnar-lined esophagus was associated with irregular GEJ.

**Conclusions:** We concluded that gastric cardiac mucosa and irregularity of GEJ was associated with increase of age. Also these data indirectly suggest that gastric cardiac mucosa were originated from distal esophagus and presence of gastric cardia mucosa itself means evidence of GERD in similar with Western datasets of GEJ.

#### 666 Clinicopathologic and Molecular Features of CDX2-/CK20-/MSI+ Colorectal Cancer

JH Kim, Y-Y Rhee, JM Bae, N-Y Cho, GH Kang. Seoul National University College of Medicine, Seoul, Republic of Korea; SMG-SNU Boramae Medical Center, Seoul, Republic of Korea; Cancer Research Institute, Seoul National University College of Medicine, Seoul, Republic of Korea.

**Background:** CDX2 and CK20 are intestinal differentiation-associated proteins and useful diagnostic markers for colorectal-origins carcinomas. Several previous studies

have reported that CDX2-negative (CDX2-) and/or CK20-negative (CK20-) colorectal cancers (CRCs) were related to microsatellite instability-positive (MSI+) phenotype. We investigated clinicopathologic and molecular features of CDX2-/CK20-/MSI+ CRC.

**Design:** Immunostaining for CDX2 and CK20 were performed in a total of 109 MSI+ CRC tissue samples, which had been curatively resected at Seoul National University Hospital, Seoul, Korea from 2004 to 2007. Clinical, pathological and molecular data, including age, gender, tumor location, AJCC stage, tumor differentiation, mucinous histology, lymphocytic reaction, MLH1/MSH2 expression, *KRAS/BRAF* mutations and CpG island methylator phenotype (CIMP) status, were collected. Clinicopathologic characteristics and prognostic implications of loss of CDX2/CK20 expression were statistically analyzed in 109 MSI+ CRCs.

**Results:** Simultaneous loss of CDX2/CK20 expression (CDX2-/CK20-) was observed in nine out of 109 MSI+ CRCs (8.3%). CDX2-/CK20- phenotype of MSI+ CRC was significantly correlated with elderly patients ( $p=0.014$ ), stage III or IV ( $p=0.049$ ), poorly differentiated histology ( $p<0.001$ ), *BRAF* V600E mutation ( $p=0.02$ ) and CIMP-positive status ( $p<0.001$ ). CDX2-/CK20- group showed worse overall and disease-free survival compared with the CDX2+ and/or CK20+ group in MSI+ CRC patients (all  $p<0.001$ ). In multivariate analysis for disease-free survival, CDX2-/CK20- status was independently associated with poor prognosis ( $p=0.03$ ).

**Conclusions:** CDX2-/CK20- phenotype of MSI+ CRC was closely associated with old age, high stage, poor differentiation, *BRAF* mutation and CIMP. CDX2/CK20 loss is an independent poor prognostic factor for MSI+ CRC.

#### 667 Utilizing Image Analysis To Correlate Subsets of Tumor Infiltrating Lymphocytes with Prognosis in Colon Cancer Patients

Y Kim, JM Bae, N-Y Cho, GH Kang. Seoul National University Hospital, Seoul, Korea; Seoul National University College of Medicine, Seoul, Korea; Cancer Research Institute, Seoul, Korea.

**Background:** Tumor-infiltrating lymphocytes are white blood cells that have left the bloodstream and migrated into a tumor, and subset of the cells possesses capacity to kill tumor cells. Although high density of subset of TIL (e.g.: Tregs) is prognostic in various human carcinomas, its role in colorectal carcinoma is controversial.

**Design:** Density of TILs bearing CD3, CD45RO, CD8, or FOXP3 was measured by Aperio Imagescope from TMA samples obtained from 767 patients diagnosed as colorectal carcinoma between 2004 and 2006.

**Results:** TIL subset densities showed strong correlations between each other. CD45RO+, CD8+, and FOXP3+ densities were significantly associated with improved progression free survival (PFS) and overall survival (OS) regardless of chemotherapy status. The significance was confirmed by multivariate analyses. However, FOXP3+ density showed significant correlation with PFS only in low CD8+ or CD45RO densities. CD45+ density was positively correlated with PFS in MSI-H patients, which was confirmed by univariate and multivariate analyses.

**Conclusions:** CD8, CD45RO, and FOXP3 were meaningful prognostic factors even for patients with adjuvant therapy. Among the TIL subsets, CD45RO had prognostic value over MSI-H patients. Therefore, subset of TILs is considered a potential marker for colorectal carcinoma patients in various conditions.

#### 668 Classification and Significance of Serrated Colorectal Polyps in Inflammatory Bowel Disease

HM Ko, N Harpaz, AD Polydorides. Mount Sinai School of Medicine, New York, NY.

**Background:** Serrated colorectal polyps (SCPs) encompass pathologically distinct entities with different prognostic and management implications, but the significance of corresponding polyps in patients with IBD has not been thoroughly studied.

**Design:** We retrospectively identified 78 patients (47 male, 31 female, mean age 55.9 y) with longstanding ulcerative, Crohn, or indeterminate colitis (N=56, 19 and 3, respectively) who were diagnosed at surveillance colonoscopy with SCPs other than conventional hyperplastic polyps (HPs). Slides of the index SCPs were evaluated by 2 pathologists and classified as follows: (A) sessile serrated adenoma/polyp (SSA/P)-like (negative for cytologic dysplasia), (B) traditional serrated adenoma (TSA)-like (positive for low-grade dysplasia), and (C) cytologically atypical HP-like (indefinite for dysplasia). The patients' pathology results from all prior and subsequent surveillance examinations were reviewed and the presence of any synchronous or metachronous dysplasia (exclusive of sporadic adenomas) or carcinoma was recorded.

**Results:** We identified 29 patients with type A, 30 type B, and 19 type C SCPs (Table). Compared to type B and C SCPs, type A SCPs predominated in females (62% vs. 30% and 21%, respectively,  $p=0.007$ ) and were more frequently right-sided (59% vs. 23% and 21%, respectively,  $p=0.006$ ). None of the 29 patients with only type A SCPs was diagnosed with synchronous or metachronous dysplasia over a mean duration of 91.0 months and mean 6.3 examinations per patient, compared with 23 of 30 (77%) and 10 of 19 (53%) patients with type B and C SCPs, respectively ( $p=1 \times 10^{-8}$ ), evaluated over statistically comparable intervals and numbers of examinations. Type B and C SCPs were associated with 21 low-grade dysplasias, 7 high-grade dysplasias, and 5 invasive adenocarcinomas.

Serrated Colorectal Polyps in IBD

SCP (N)	Surveillance (mean, mo)	Exams (mean, #)	Age (mean, y)	Sex (M:F)	IBD (UC:CD:IC)	Site (R:L)	Neoplasia
Type A (29)	91.0	6.3	53.2	11:18	19:9:1	17:12	0/29
Type B (30)	83.6	8.3	58.4	21:9	22:6:2	7:23	23/30
Type C (19)	102.2	9.1	56.1	15:4	15:4:0	4:15	10/19
Total (78)	90.9	7.8	55.9	47:31	56:19:3	28:50	33/78
p value*	NS	NS	NS	0.007	NS	0.006	1x10-8

\* A vs. B vs. C (Student's t-test or Pearson's chi-squared test); NS: not significant

**Conclusions:** SSA/P-like polyps in IBD occur preferentially in females and in the right colon, analogously to their sporadic counterparts, however they are not associated with

synchronous or metachronous neoplasia. In contrast, TSA-like SCPs and cytologically atypical HP-like SCPs are significantly associated with synchronous or metachronous neoplasia.

**669 Loss of RKIP Expression in Colorectal Cancer Is Associated with Activation of the NF-κB Signaling Pathway and Epithelial-Mesenchymal Transition**

*VH Koelzer, H Dawson, E Karamitopoulou, A Lugli, I Zlobec.* University of Bern, Bern, Switzerland.

**Background:** Nuclear factor κB (NF-κB) signaling provides a fertile soil to invading cancer cells through regulation of stroma-associated genes and epithelial-mesenchymal transition (EMT). Raf-1 Kinase Inhibitor Protein (RKIP) counteracts NF-κB activation and impairs invasiveness and the ability to form metastases in cancer cells. The aim of this study was the combined geographic analysis of RKIP and NF-κB expression for the prediction of clinico-pathological features and outcome in colorectal cancer.

**Design:** RKIP expression was assessed in 221 CRCs with full clinico-pathological information by immunohistochemistry in 10HPF of normal mucosa, tumor center, invasion front and tumor buds using whole tissue sections; Nuclear NF-κB [expression in tumor cells was assessed using a multi-punch tissue microarray representing each histologic zone. The geographic expression pattern of RKIP was assessed for correlation with survival, clinico-pathological characteristics and features of EMT including tumor budding, infiltrative tumor border configuration and NF-κB activation.

**Results:** RKIP was diffusely expressed in normal mucosa and progressively lost towards tumor center and front (27%, 14% and 8% RKIP-positivity, respectively; p<0.0001). Only 0.4% of tumor buds were RKIP-positive. In the tumor center, loss of RKIP expression predicted metastatic disease (p=0.0307), vascular invasion (p=0.0506), frequent tumor budding (p=0.0112) and an invasive border configuration (p=0.0084). Further, loss of RKIP correlated strongly with NF-κB activation (p=0.0129). RKIP loss was more common in mismatch repair-deficient cancers (p=0.0191). Interestingly, KRAS mutation did not show an impact on RKIP expression. Loss of RKIP expression in the tumor center was an independent prognostic indicator for survival (HR (95%CI): 0.47 (0.28-0.79) p=0.0042) and predicted reduced response to adjuvant chemotherapy.

**Conclusions:** The clinical relevance of RKIP expression as an independent prognostic factor is restricted to the tumor center. Loss of RKIP in this geographic area strongly predicts features of EMT including an increased activation of the NF-κB signaling pathway and correlates with frequent distant metastasis.

**670 The Risk of Colonic Neoplasia in IBD-PSC Patients Is Dependent on Disease Presentation Phenotype**

*A Krizova, DF Schaeffer, S Hafezi-Bakhtiari, H Girgis, H El-Zimaity.* University Health Network, Toronto, ON, Canada; University of British Columbia, Vancouver, BC, Canada.

**Background:** Patients with inflammatory bowel disease (IBD) and associated primary sclerosing cholangitis (PSC) have a perceived elevated risk of developing colorectal neoplasia or invasive cancer than patients with only IBD. Thus, the frequency of neoplasia surveillance is currently recommended at an annual interval, but there are surprisingly few data to support this practice. Since we have recently demonstrated that IBD associated with PSC has a different phenotype depending on primary disease presentation (IBD preceding PSC vs. PSC preceding IBD), we studied whether the risk of colonic neoplasia is also dependent on disease presentation.

**Design:** We identified patients with PSC and IBD seen and followed up at the University Health Network, Toronto between 1985 and 2011 and divided them into two groups based on site of primary disease presentation (hepatic vs. colonic). The control group was comprised of patients with IBD, but without PSC. Primary outcome parameter was the development of colonic neoplasia.

**Results:** The average colitis follow up period was 10 years for PSC patients that developed colitis (PSC-IBD), 19 years for IBD patients that developed PSC (IBD-PSC), and 13 years for the control IBD group without PSC. Colonic neoplasia incidence was higher in IBD patients that subsequently developed PSC as compared to PSC patients that developed IBD (p= 0.005).

Disease presentation phenotype	Neoplasia in UC	Neoplasia in Crohn's disease	Total
IBD-PSC (n=51)	4 of 41 (10%)	2 of 10 (2%)	6 of 51 (12%), p=0.18
PSC-IBD (n=62)	0 of 55 (0%)	0 of 7 (0%)	0 of 62 (0%), p=0.15
Control group (n=102)	2 of 58 (3%)	3 of 44 (7%)	5 of 102 (5%)

The occurrence of colonic neoplasia in IBD preceding PSC (0.06 per 100 patient years of follow-up) was similar to the IBD control group (0.07 per 100 patient years of follow-up) compared to none in the PSC preceding IBD group. Neoplasia risk was similar in ulcerative colitis and Crohn's disease patients, irrespective of disease presentation (p = 0.2).

**Conclusions:** IBD patients that develop PSC have an increased risk of colonic neoplasia compared to PSC patients subsequently developing IBD.

**671 Assessment of BRAFV600E Mutation-Specific Antibody (VE1) in Colorectal Cancers**

*S-F Kuan, RK Pai, S Navina, MN Nikiforova, KL Cressman.* University of Pittsburgh, Pittsburgh, PA.

**Background:** BRAF V600E mutation occurs in about 10% of colorectal cancers (CRCs). Most of them are CRCs with high-levels of microsatellite instability (MSI-H CRCs) arising in sessile serrated adenoma (SSAs). BRAF mutation is an unfavorable prognostic factor and predicts resistance to anti-EGFR therapy. BRAF mutation status also helps to further subclassify of MSI-H CRCs into Lynch syndrome-associated CRCs

and sporadic MSI-H CRCs. Clinical testing of BRAF mutation by sequencing usually takes days to complete. An antibody targeting the BRAF V600E mutation (VE1) has recently become available (Spring Bioscience, CA). We tested the feasibility of this antibody to expedite clinical testing of BRAF mutation.

**Design:** Formalin-fixed, paraffin-embedded tissues from 76 colectomy cases for CRC were used to validate antibody VE1. BRAF V600E mutation status was first tested by sequencing. Then, immunohistochemical staining using VE1 was performed by manual methods as well as on Ventana Benchmark Ultra automated stainer after optimization of the procedure.

**Results:** The VE1 antibody was very sensitive to factors such as tissue fixation, antigen retrieval, and antibody incubation and had a narrow range for optimal conditions. Repeat attempts to optimize the staining by manual processing did not generate reproducible results. However, we were able to optimize the staining results using Ventana Benchmark Ultra instrument following the recommendations by the vendor. The slides were independently reviewed by 3 GI pathologists (SFK, RKP, and SN) and had 100% concordant readings. Discrete and recognizable positive staining for BRAF mutation was identified in the cytoplasm of all 31 CRCs with known BRAF mutation by sequencing. All 45 BRAF wild-type CRCs exhibited negative staining. The specificity and sensitivity of VE1 antibody were 100% in CRC. Three of 5 associated sessile serrated adenomas (SSAs) in this series showed weak positive VE1 staining while all 3 dysplastic foci within the SSAs were strongly positive. Nonspecific background staining was occasionally noted in smooth muscle, mucinous granules, and some nuclei on the surface crypts along with the edge artifacts.

**Conclusions:** Immunohistochemical staining using BRAF mutation-specific antibody in colon cancer had results completely concordant with those by sequencing. It is a useful ancillary test to assess the status of BRAF mutation. Clinical application requires careful optimization of conditions on automated stainers to minimize nonspecific staining. The VE1 antibody may also be useful in cellular localization and first-line screening of colon cancers for research purposes.

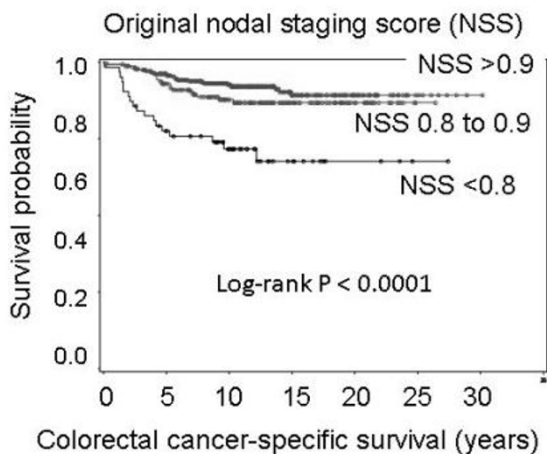
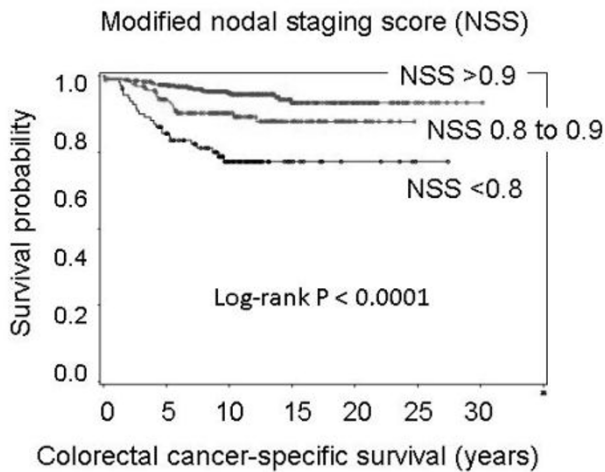
**672 Colon Cancer Nodal Staging Score: A Tool To Assess Adequacy of Nodal Harvesting in Pathology Practice**

*A Kuchiba, P Lochhead, S Ogino.* Dana-Farber Cancer Institute, Boston, MA; Brigham and Women's Hospital, Boston, MA.

**Background:** Lymph node status remains the most important predictor of patient survival in stage I-III colon cancer. A nodal staging score (NSS) is a function of pT-stage and the number of examined lymph nodes, and is an estimate of the negative predictive value (NPV, a probability of true negative given a negative result) in colon cancer nodal staging. We examined whether NSS could be improved by additional variables, including tumor molecular features.

**Design:** We utilized 1139 stage I-III colon cancer cases, with available information on the node count and patient survival. We created a "modified" NSS using a subset of 688 colon cancers with available data on additional pathologic, and tumor molecular characteristics, including microsatellite instability (MSI) and KRAS, BRAF, and PIK3CA mutations. We compared performance of our modified NSS to the original NSS, using patient survival as an outcome measure.

**Results:** Modified NSS was a function of pT-stage, the node count, plus tumor mucinous component, tumor grade, MSI, and colorectal cancer family history. Modified NSS was associated with patient survival, (Figure 1) and the performance of modified NSS was similar to the original NSS, using survival data.



Concordance statistics for colon-cancer specific survival were 0.61 [95% confidence interval (CI), 0.49-0.73] and 0.60 (95% CI, 0.47-0.73) for modified and original NSS, respectively.

**Conclusions:** Both the original NSS and the modified NSS are valid tools to estimate NPV in nodal staging for colon cancer. Our data support the utility of the easily-calculable original NSS (as a function of pT stage and the node count) for stage I-II colon cancer in routine pathology practice. NSS can be used to refine the recommendations in nodal harvesting in colorectal cancer.

### 673 The Effects of Proton Pump Inhibitors on the Oxyntic Mucosa Can Only Be Reliably Assessed in the Absence of *Helicobacter* Infection

KR Kumar, R Iqbal, E Coss, C Park, B Cryer, RM Genta. UT Southwestern Medical School, Dallas, TX; Dallas VAMC, Dallas, TX; Dallas VA Medical Center, Dallas, TX; Miraca Life Sciences Research Institute, Irving, TX.

**Background:** During proton pump inhibitor (PPI) therapy oxyntic glands may become unevenly dilated and acquire a ragged lining with protruding parietal cells. Although such changes are often referred to as PPI-effects, little evidence supports the accuracy of this designation. This study was designed to evaluate the strength of the association between parietal cell protrusions, dilated oxyntic glands, and use of PPIs and Histamine2-receptor blockers (H2-B).

**Design:** Topographically defined biopsies (2 each from corpus and antrum, and 1 from transitional zone) were obtained from patients recruited into a novel therapeutic trial for *H. pylori*. History of PPI and H2-B use was collected. Two blinded pathologists used a scale of 0 to 3 to grade the intensity of putative PPI effects on the oxyntic mucosa. PPI and H2-B use were then disclosed and the accuracy of pathologists' assessment was evaluated.

**Results:** Of 236 patients studied, 97 had *H. pylori* gastritis (median age 65 years; 89% men; 57% PPI users) and 139 did not (median age 66 years; 90% men; 81% PPI users). Table 1 shows the correlation between the pathologists' assessment and actual PPI use. Use of H2-B (data not shown) had no detectable effect on the oxyntic glands.

<i>H. pylori</i> -negative (n = 139)			<i>H. pylori</i> -positive (n = 97)		
PPI-effect grade	PPI use documented	% correct	PPI-effect grade	PPI use documented	% correct
0 (n = 37)	25	32.4	0 (n = 22)	14	36.4
1 (n = 61)	52	85.2	1 (n = 54)	29	53.7
2 (n = 29)	25	86.2	2 (n = 15)	9	60.0
3 (n = 12)	11	91.7	3 (n = 6)	3	50.0

**Conclusions:** In *H. pylori*-negative subjects, oxyntic gland dilatations and parietal cell protrusions are strongly related to documented PPI use. No such changes are associated with H2-B therapy. In contrast, in *H. pylori* gastritis so-called PPI-effects were equally

prevalent in PPI-users and non-users, suggesting that other factors other than these medications are involved in the induction of oxyntic cell hyperplasia (Krishnamurthy & Dayal, Hum Pathol, 1997). Therefore, pathologists should refrain from diagnosing "PPI-effects" in *H. pylori*-infected patients. Furthermore, since this piece of diagnostic information is of little use to the clinician, we suggest that comments regarding the supposed evidence of PPI use should be avoided in the diagnosis of all gastric biopsy specimens.

### 674 Proton Pump Inhibitor Use in Patients with *Helicobacter* Gastritis Increases the Risk for Corpus-Predominant Gastritis and Preneoplastic Lesions of the Proximal Stomach

KR Kumar, R Iqbal, E Coss, C Park, B Cryer, RM Genta. Miraca Life Sciences Research Institute, Irving, TX; UT Southwestern Medical School, Dallas, TX; Dallas VAMC, Dallas, TX; Dallas VAMC, Dallas, TX.

**Background:** Experimental studies have shown that proton pump inhibitors (PPI) use may cause a shift from *H. pylori* antrum-predominant (AP) gastritis to a corpus-predominant (CP) pattern. It is unclear whether in the clinical setting therapeutic PPI use affects the topography of gastritis. This study was designed to test the hypothesis that the patterns of gastritis in *H. pylori*-infected patients are different in PPI users and non-users.

**Design:** Topographically defined biopsies (2 each from corpus and antrum, and 1 from incisura) were obtained from patients recruited into a novel therapeutic trial for *H. pylori*. History of PPI and Histamine2-receptor blockers (H2-B) use was collected. Two blinded pathologists used the Updated Sydney System to evaluate the biopsies. Patients were assigned to one of 3 categories based on their gastritis scores: AP-gastritis (inflammatory scores of antrum and incisura were greater than the corpus); CP-gastritis (corpus scores were greater than antrum and incisura scores); and pangastritis (two sets of scores were identical). PPI and H2-B use were then disclosed and the topographic distribution of the components of gastritis was analyzed.

**Results:** There were 97 patients with *H. pylori* gastritis (median age 66 years, 89% men, 52% white). CP gastritis was found in 40% of PPI users versus 15% in non users (OR 4.19; 95% CI 1.47-11.9; p<0.01). PPI use was also associated with increased atrophy and intestinal metaplasia (IM) in the corpus (16.4% in users versus 7.3% in non-users) and IM in the incisura (18.8% vs. 9.7%), but the differences did not attain statistical significance. These associations remained similar for PPI use shorter or longer than one month. H2-blocker use was unrelated to the topography of gastritis. Age, sex, and race had no influence on the topography of gastritis.

**Conclusions:** Even short-term PPI use can affect the distribution of inflammation in *H. pylori* gastritis and may induce or accelerate the development of preneoplastic lesions in the transitional and oxyntic mucosa. Our results provide support for the Maastricht guidelines, widely followed in Europe but not formally espoused by the American College of Gastroenterology, that recommend eradication of *H. pylori* prior to long-term PPI use.

### 675 Brunner Gland Cysts: Morphologic and Endoscopic Features

DJ Lager, JA Nielsen, M Lewin, CA Roberts. ProPath, Dallas, TX.

**Background:** Brunner glands (BG) are mucosal and submucosal alkaline secreting glands concentrated in the first part of the duodenum decreasing in number in the second and third parts. The most common benign BG proliferative lesion is BG hyperplasia (BGHy) which is often associated with peptic duodenitis. Brunner gland hamartomas (BGHa) and BG cysts (BGCy) are less common; all can present as elevated duodenal lesions. The aim of this study is to more clearly define BGCy as a distinct entity.

**Design:** The Pathology files were searched from January 2008 to August 2012 for benign BG lesions in the duodenum. The H&E-stained slides from cases diagnosed as BGCy were reviewed, and endoscopic and demographic data were extracted from the patient records.

**Results:** Of the 236 specimens retrieved, 213 (90.2%) were classified as BGHy, 8 (3.4%) as BGHa and 15 (6.4%) as BGCy. The 8 females and 7 males with BGCy ranged in age from 25 to 86 years with a mean of 64 years. Indications for endoscopy were not directly attributable to the duodenal lesion. The lesion was described as a polyp in 7 patients, a nodule in 3, as submucosal in 3, as "polyp vs. nodule" in 1 and was not characterized in one patient. The BGCy was associated with a pyloric stricture in one patient, was ulcerated in one, was sessile in one and cystic/collapsible in two patients. The size of the lesion, indicated in 8 patients ranged from 3 to 10 mm and was described as "small" in one patient. The BGCy were located in the duodenal bulb or first part of the duodenum in 3 patients, the second part in 5, the third part in 2, and location was not indicated in 5 patients. Morphologically the cysts were unilocular and submucosal and were often multiple. Most had a thin rim of smooth muscle which was attenuated to absent in larger cysts. The cysts were adjacent to normal BG. The cyst-lining cells in all cases were cuboidal with finely granular, slightly eosinophilic cytoplasm resembling BG epithelium. No papillary structures or dysplastic features were present. Occasionally the cyst wall was partial and in two cases was separate from the duodenal mucosa.

**Conclusions:** Brunner gland cysts are an uncommon cause of duodenal mucosal elevation. They may be described as a nodule or polyp and may be obviously cystic. They occur in all portions of the duodenum and are not associated with overlying mucosal abnormalities. Because they are submucosal and may be only partially represented on biopsy, it is important that they not be overlooked in a duodenal biopsy as the explanation for a "polyp", avoiding additional unnecessary procedures.

**676 Clinical Outcome after the Diagnosis of Indefinite for Dysplasia in Patients with Idiopathic Inflammatory Bowel Disease**

*KK Lai, Y Wang, H Xie, B Shen, JR Goldblum, BL Lewis, X Liu.* Cleveland Clinic, Cleveland, OH; Cleveland Clinic Lerner College of Medicine of Case Western Reserve University, Cleveland, OH.

**Background:** The management of indefinite for dysplasia (IND) in patients with idiopathic inflammatory bowel disease (IBD) is controversial due to a paucity of published outcome data. The aim of this study was to examine the clinical outcome of patients with IBD after a diagnosis of IND from a single institution.

**Design:** Our surgical pathology database was searched from 1989 to 2004 for IBD, ulcerative colitis, Crohn's disease, colitis, and indefinite for dysplasia. Pathologic reports, clinical features and outcome data were reviewed. Chi square and Fisher's exact test were used for statistical analyses.

**Results:** A total of 125 IBD patients with a diagnosis of IND on biopsy were identified. Thirty-two patients were excluded due to a prior diagnosis of neoplasia (N = 12) or being lost to followup (N = 20). Twenty-two of the remaining 93 patients (23.7%) had a surgical resection within 6 months of the IND diagnosis; 6 (27.3%) had dysplasia (1 low-grade dysplasia [LGD] and 5 high-grade dysplasia [HGD]) in their colectomy specimens. The remaining 71 patients were followed with colonoscopy for a mean duration of 98.6 (SD: 65.0; range: 1.7 – 250.5) months; 17 patients (23.9%) developed dysplasia or carcinoma (10 LGD, 5 HGD, and 2 colorectal cancer [CRC]) with a mean interval period of 53.9 (SD: 36.9) months between IND and dysplasia or carcinoma diagnoses. Those who progressed were older than non-progressors (p=0.0063) (Table 1). Also, a diagnosis of IND made by a gastrointestinal (GI) pathologist was more than twice as likely to progress than one made by a non-GI pathologist (34.3% vs. 13.9%; p=0.044).

Clinical outcome of IBD patients with a diagnosis of indefinite for dysplasia followed with colonoscopy

	IND progressor (n=17)	IND non-progressor (n=54)	p value
Worst neoplasia* (LGD/HGD/CRC)	10/5/2	0/0/0	N/A**
Age, mean (SD), yrs	54.4 (12.6)	44.1 (13.3)	0.0063
Gender (M/F)	13/4	30/24	0.160
Extent of colitis (pan-/left-/rectum/others)	9/5/2/1	24/15/13/2	0.112
GI pathologist/non-GI pathologist	12/5	23/31	0.044

Note: \* worst neoplasia diagnosed in a followup specimen. \*\* not applicable.

**Conclusions:** A diagnosis of IND in patients with IBD is associated with a higher rate of synchronous or metachronous dysplasia or carcinoma. These patients warrant closer follow-up. Since a minority of patients progress, biomarkers that better stratify the risk of progression are needed.

**677 Nuclear Immunoreactivity of β-Catenin Is Associated with Higher Expression of AMACR, Lower Rate of Nodal Metastasis, and Left-Side Location in Surgically Resected Deeply Invasive Colonic Cancer**

*KK Lai, W Jiang, P Carver, A Liu, H Liu, B Zhang, H Xie, X Liu.* Cleveland Clinic, Cleveland, OH; Thomas Jefferson University, Philadelphia, PA.

**Background:** Dysregulation of the APC/Wnt/β-catenin signaling pathway is a key event in colonic carcinogenesis. Recently, alpha-methylacyl-CoA racemase (AMACR), a dietary enzyme involved in the β-oxidation of branched-chain fatty acids, has been reported to be upregulated in colonic adenocarcinomas. However, the mechanism underlying this upregulation remains unexplored. We aim to link AMACR expression in colon cancer with β-catenin nuclear translocation, an indicator of APC/Wnt signaling pathway dysregulation.

**Design:** Tissue microarrays (TMA) were constructed from 112 cases of surgically resected, deeply invasive (T3 and T4), sporadic colonic adenocarcinomas and used for immunohistochemistry with stains for β-catenin and AMACR. Any amount of nuclear staining for β-catenin, and any amount of cytoplasmic staining for AMACR, were considered positive. Continuous and categorical data were analyzed using the student t test and chi-square test, respectively.

**Results:** Fifty of the 112 tested colonic adenocarcinomas had nuclear β-catenin staining. Whereas 82% (41 of 50) of these deeply invasive carcinomas with nuclear β-catenin staining also expressed AMACR, AMACR was expressed in only 50% (31 of 62) of carcinomas lacking nuclear β-catenin (Table 1; p = 0.00044). Nuclear β-catenin expressing carcinomas also had a lower rate of nodal metastasis than tumors lacking nuclear β-catenin (32% vs. 58.4%; p = 0.00357). Lastly, nuclear β-catenin positive carcinomas were more likely to be left-sided (70.2% vs. 46.5%; p = 0.045).

Correlation of β-catenin nuclear immunoreactivity with AMACR expression, demographics and histologic tumor parameters in colonic adenocarcinoma

	β-Catenin nuclear stain (50)	Lack of β-Catenin nuclear stain (62)	p value
AMACR positive cases (%)	41 (82%)	31 (50%)	0.00044
Age, mean (SD), yrs	71.7 (10.2)	70.5 (11.2)	0.54
Male (%)	32 (64%)	36 (46.7%)	0.07
Left side (%)	33 (70.2%)	27 (46.5%)	0.014
Nodal metastasis (%)	16 (32%)	45 (58.4%)	0.00357

**Conclusions:** Our results, for the first time, suggest that APC/Wnt/β-catenin pathway dysregulation may induce AMACR expression during colonic tumorigenesis. Further study is needed to explore the relationship between APC/Wnt/β-catenin pathway dysregulation and AMACR expression in colon cancer including early, superficially invasive adenocarcinomas (T1 and T2).

**678 Helicobacter Carditis and Its Association with Symptoms, EGD Findings and Coexistent Helicobacter Gastritis, Helicobacter Duodenitis, Gastroesophageal Reflux and Barrett's Esophagus**

*I Lamzabi, R Jain, S Jakate.* Rush University Medical Center, Chicago, IL.

**Background:** During esophagogastroduodenoscopy (EGD), it is common to obtain random or targeted biopsies from all 3 sites - distal esophagus, stomach and duodenum

for a wide variety of symptoms such as pyrosis, dysphagia, dyspepsia, abdominal pain, anemia and weight loss. Such biopsies may also be performed in asymptomatic patients undergoing screening for Barrett's or varices. Occasionally, the GE junction biopsies show clinically unanticipated *Helicobacter pylori* (HP) carditis. We studied the association of this pathological finding with symptoms, EGD features and concomitant histological *Helicobacter* gastritis, *Helicobacter* duodenitis, gastroesophageal reflux disease (GERD) and Barrett's esophagus (BE).

**Design:** Between January 2008 and August 2012, 3962 EGDs were performed in our Medical Center where biopsies from 3 sites - distal esophagus or GE junction, stomach and duodenum were simultaneously obtained either randomly or targeted toward endoscopic abnormalities. 54 cases (1%) showed *Helicobacter* organisms and moderate or severe inflammation of the cardia at GEJ. The clinical, endoscopic and histological features of these cases were reviewed.

**Results:** HP carditis was not specifically associated with any particular symptom although symptomatic patients (92%) far outnumbered asymptomatic patients (8%). Certain symptoms such as pyrosis (29%), abdominal pain (18%), dysphagia and anemia (12% each) were most frequent. Endoscopically, GEJ was described as normal (46%), nonspecific and/or reflux esophagitis (40%), ulcerated (5%) or irregular Z line with questionable short Barrett's segment (9%). All cases (100%) showed coexistent moderate to severe *Helicobacter* gastritis. *Helicobacter* duodenitis was present in only 6/54 (10%) cases. Coexistent GERD was present in 26/54 (48%) cases and BE was rare and seen in only one case.

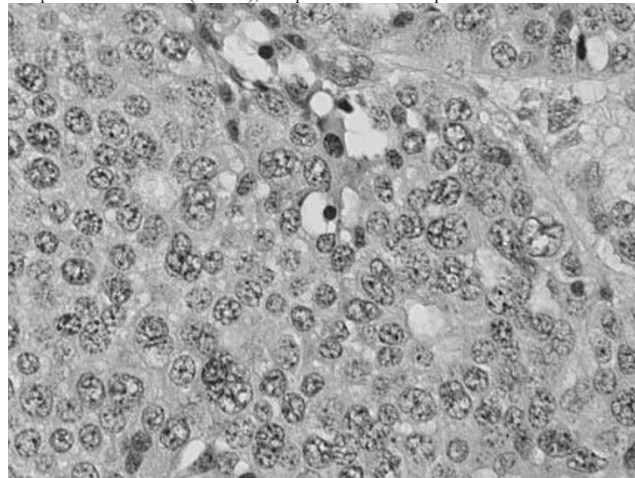
**Conclusions:** HP carditis is not selectively associated with any specific symptom or endoscopic finding and nearly half the patients may have normal-looking GEJ. Symptom of pyrosis and esophagitis on EGD are likely due to frequent association with GERD. Coexistent *Helicobacter* gastritis is universally present in 100% of patients but concomitant *Helicobacter* duodenitis is uncommon. Association of BE with HP carditis is extremely rare and correlates well with aversion of *Helicobacter* organisms to goblet cell metaplasia.

**679 Histopathologic Parameters of Gastrointestinal and Pancreatic Neuroendocrine Tumors/Carcinomas Can Predict Their Clinical Behavior**

*I Lamzabi, S Jakate, R Jain, L Cheng, P Gattuso.* Rush University Medical Center, Chicago, IL.

**Background:** Gastrointestinal(GI) and pancreatic(P) neuroendocrine tumors/carcinomas NET/C have a heterogeneous prognoses. WHO grading system based on mitoses and necrosis show weak prediction of clinical behavior especially for WHO grade I metastatic NET. We undertook a retrospective study to identify additional histopathologic parameters that might be useful in assessing the malignant behavior of GINEC/T and PNET/C.

**Design:** We searched our surgical pathology files for resection specimens of GINEC/T and PNET/C from 2000-2010. Pertinent clinico-pathological data was retrieved. Two pathologists independently reviewed several histologic parameters including nuclear size (NS) compared to the nuclei of small lymphocytes, number of very large nuclei (NVLN) (3 times larger than the nuclei of small neoplastic cells) per 10 hpf, number of mitotic figures(NMF) per 10 hpf, presence of nucleoli, apoptosis or necrosis, lymphovascular and perineural invasion (LVPNI), and presence of desmoplasia.



**Results:** Fifty six cases of NET/C including 6 gastric, 17 ileal, 8 appendiceal, 2 cecal, 13 pancreatic, 8 rectal and 2 liver metastases of PNET were selected. The clinico-pathologic data is summarized in table 1. The correlations between histopathologic parameters and T stage, LN and distant metastases are summarized in table 2.

Table 1: Clinicopathological data

	Stomach N=6	SB N=17	Pancreas N=13	Appendix N=8	Rectum N=8
Average Age	52	59	59	30	59
Male/Female	4/2	6/11	5/8	0/8	5/3
Grade I NET with LN metastasis	0	10	3	1	0
LN Metastases	0	15	4	1	1
Distant Metastases	0	3	2	0	1



Table 2: Correlation of Different Histological Parameters with Tumor Behavior

Correlations	T Stage	LN Metastasis	Distant Metastasis
Mitotic Activity	r=0.1(p=0.3)	r=0.2(p=0.04)	r=0.1(p=0.4)
NS	r=0.4(p=0.002)	r=0.3(p=0.06)	r=0.4(p=0.001)
NVLN	r=0.4(p=0.002)	r=0.4(p=0.003)	r=0.2(p=0.07)
LVPNI	r=0.4(p=0.003)	r=0.5(p<0.001)	r=0.4(p=0.001)
Necrosis/apoptosis	r=0.1(p=0.4)	r=0.1(p=0.3)	r=0.1(p=0.2)

**Conclusions:** This study confirms that most metastatic GI and pancreatic NET/C are WHO grade I. Also, the best predictors of aggressive behavior especially LN metastases might be LVPNI, NS and NVLN. Mitotic activity showed only a weak correlation with LN metastases, while necrosis was not associated with the behavior of these tumors.

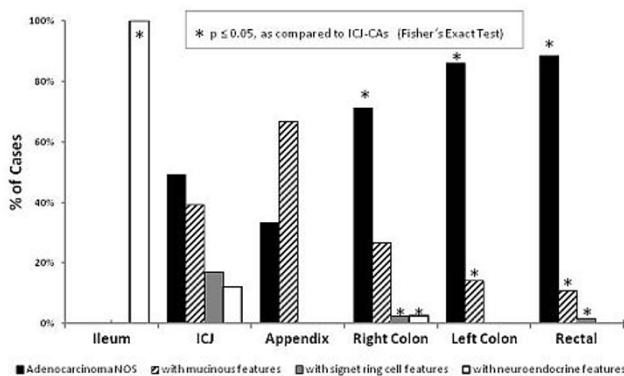
### 680 Ileocecal Junction Carcinoma: Clinical-Pathologic Features

L-H Lee, V Falck, X Gui. Calgary Laboratory Services and University of Calgary, Calgary, AB, Canada.

**Background:** Epithelial transition zones (TZs) are associated with unique or increased cancer susceptibility. In GI tract, carcinomas arising in some TZs such as esophagogastric and anorectal junctions show certain features. Carcinomas in ileocecal junction (ICJ) are not uncommonly seen. Whether they have distinct clinical-pathological features, however, has never been described. We attempt to explore this subject.

**Design:** All intestinal carcinoma resections in Foothills Hospital between 1/2009 and 6/2012 were retrieved. Those located at and distal to ileum were included into the study. Peritoneal carcinomatosis was excluded. Original reports and slides were reviewed to record tumor location, gross appearance, histologic type, grade, depth of invasion (T), nodal metastasis (N), and other features. The carcinomas with gross tumor edge within 5 cm proximal and distal to ICJ were labelled as ICJ carcinoma (ICJ-CA). For each aspect these carcinomas were compared with those at other locations.

**Results:** Of 376 cases in total, 59 (15.7%) were ICJ-CA, including 24 (6.4%) tumors crossed ICV. The others were located in ileum (6), right colon (83), left colon (86), rectum (139), and appendix (3). Clinically, ICJ-CAs were seen more in females as compared to carcinomas of left colon and rectum (57.6% vs 36.0% vs 30.9%,  $p < 0.05$ ). Grossly, ICJ-CAs were mostly fungating masses (67.8%). Histologically, the type distribution of ICJ-CA differed from that of carcinomas at other locations, as shown in Fig 1.



ICJ-CAs tended to have mucinous or/and signet ring cell or/and neuroendocrine features. 1 case showed all of these features. 8 cases were classified as mucinous carcinoma, 2 cases as signet ring cell carcinoma, 4 tumors involved appendix, including 2 cases associated with goblet cell carcinoma, likely originating from appendix. 4 ICJ-CAs confined to ileal side were all neuroendocrine carcinoma. ICJ-CAs also invaded deeper than those of left colon and rectum (T4: 25.4% vs 11.5%,  $p < 0.05$ ) but not different from those of right colon. The rate of positive nodes (N) in ICJ-CAs showed no difference from other CRCs.

**Conclusions:** Carcinomas of ICJ region seem to have some distinct features. Further study in more cases and more details would better define the 'ICJ carcinoma'.

### 681 Nuclear FOX M1 and Phosphorylated $\beta$ -Catenin S552 Expressions Are Observed in Barrett Dysplasia and Adenocarcinoma

G Lee, MM Kiefer, D Posca, B Rea, L Zak, D Massi, W Blosky, B Bryant, R Abraham, L Li, J Goldstein, TA Berrett, P Raychaudhuri, G Guzman. University of Illinois, Chicago, IL; Northwestern University, Chicago, IL; Stowers Institute, Kansas City, MO.

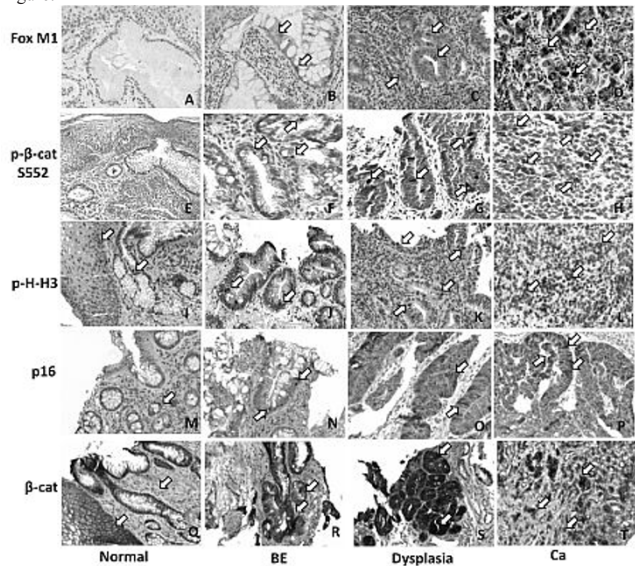
**Background:** Diagnosis and surveillance of Barrett esophagus (BE), dysplasia and adenocarcinoma (AdC) remains challenging. Fox M1, a cell cycle regulator known to cross-talk with PI3K/Akt pathway, is expressed in many cancers. Phosphorylated- $\beta$ -catenin S552 (P- $\beta$ -cat S552), a marker for activated nuclear  $\beta$ -catenin phosphorylated at S552 and an indicator of PI3K/Akt-mediated  $\beta$ -catenin signaling, is up-regulated in PTEN-deficient intestinal polyp and colitis-associated cancer. Our aim was to evaluate the expression of these two proteins along with reported biomarkers of disease progression of BE namely: p16Ink4a (p16),  $\beta$ -catenin ( $\beta$ -cat), phosphorylated-histone-H3 (p-H-H3), and DNA mismatch repair proteins, in BE-dysplasia-AdC progression.

**Design:** Twenty endoscopic esophageal biopsies consisting of normal, BE, dysplasia and AdC (n=5 / group) were evaluated by immunohistochemistry for Fox M1, P- $\beta$ -cat S552, p-H-H3, p16,  $\beta$ -cat, MLH1, MSH2, MSH6, and PMS2. Positively stained lesional nuclei were graded 0-3 for absent to strongest staining intensity.

**Results:** All samples were microsatellite-stable. FoxM1 showed increased (2 to 3)

nuclear and cytoplasmic staining in dysplasia and AdC in comparison to no or weak (0 to 1) cytoplasmic staining in BE [figure A-D]. P- $\beta$ -cat S552 [figure E-H] showed only nuclear staining and was markedly increased in dysplasia and AdC. Similar results were observed with p-H-H3 [figure I-L]. p16 showed increased nuclear and cytoplasmic staining in AdC [figure M-P].  $\beta$ -cat showed 2 to 3 nuclear staining in dysplasia and AdC in comparison to membranous staining in BE [figure Q-T].

Figure:



**Conclusions:** Here we show that nuclear expression of both Fox M1 and P- $\beta$ -cat S552 is absent in normal/reactive and Barrett esophagus, noted as early as Barrett dysplasia, and persists in Barrett AdC. These results correlate with the findings seen in reported Barrett biomarkers including p16Ink4a (p16),  $\beta$ -catenin ( $\beta$ -cat), phosphorylated-histone-H3 (p-H-H3), and DNA mismatch repair proteins. The switch to nuclear expression of both Fox M1 and P- $\beta$ -cat S552 in Barrett dysplasia and AdC suggests a possible role of PI3K/Akt signaling in Barrett disease progression.

### 682 SATB2 Is a Highly Sensitive Marker for Hindgut Well-Differentiated Neuroendocrine Tumors

Z Li, L Zhou, K Mei, L Jia, Q Kang, M Zhang, D Cao. Peking University Cancer Hospital, Beijing, China; Guangzhou Medical College, Guangzhou, China.

**Background:** Well differentiated neuroendocrine tumors (WDNETs) most commonly involve gastrointestinal (GI) tract, lung and pancreas. WDNETs often show similar morphology and determination of their origin in metastatic sites mainly relies on immunohistochemical markers. CDX2, TTF1 and PDX1 are relatively sensitive markers for WDNETs from midgut, lung and pancreas, respectively. However, there is no sensitive marker for hindgut (distant 1/3 transverse colon to rectosigmoid) WDNETs, which account for approximately 2/3 colorectal WDNETs. Here we investigated a novel marker SATB2 for its diagnostic utility in hindgut WDNETs.

**Design:** 81 WDNETs from GI tract were included (esophagus 10, stomach 11, small intestine 7, appendix 3, colon 6, rectum 44). One paraffin block from each case was used for immunostaining using a SATB2 monoclonal antibody. To test SATB2 specificity, we also included 43 WDNETs from other sites (pancreas 19, lung 19, mediastinum 5). Immunostains for CDX2 and TTF1 were also performed in all 124 WDNETs for comparison. Only nuclear staining was considered positive for these markers. The percentage of tumor cells stained was semi-quantitatively scored as 0 (no tumor cells stained), 1+ (1-25%), 2+ (26-50%), 3+ (51-75%), and 4+ (>75%).

**Results:** SATB2 staining was observed in 2/10 esophageal (1+, 4+), 0/11 gastric, 0/7 small intestinal, 1/3 appendiceal (4+), 0/4 right colonic, 0/1 transverse colonic at splenic flexure (TCSF), 1/1 sigmoid colonic (2+), 40/44 rectal (primary 36/40, metastatic 4/4; 1+ in 1, 2+ in 1, 3+ in 1, 4+ in 37), 5/19 pulmonary (primary 3/13, metastatic 2/6; 1+ in 1, 2+ in 2, 4+ in 2), 1/19 pancreatic (2+ in 1/10 primary, 0/9 metastatic), 0/5 mediastinal WDNETs. CDX2 staining was seen in 1/10 esophageal (1+), 3/11 gastric (all 2+), 1/7 small intestine (4+ in 1/1 ileal, 0/6 duodenal), 2/3 appendiceal (2+, 3+), 3/4 right colonic (all 4+), 1/1 TCSF (4+), 1/1 sigmoid colonic (4+), 2/44 rectal (2+ in 2/40 primary, 0/4 metastatic), 1/19 pulmonary (4+ in 1/13 primary), 4/19 pancreatic (2/10 primary, 2/9 metastatic; 2+ in 1, 4+ in 3), and 0/5 mediastinal WDNETs. TTF1 staining was seen in 1/10 esophageal (2+), 1/11 gastric (1+), and 9/19 pulmonary (primary 3/13, metastatic 6/6; 3 in 1, 4+ in 8) WDNETs and was negative in other WDNETs. The sensitivity and specificity of SATB2 for hindgut WDNETs is 89% and 88%, respectively.

**Conclusions:** SATB2 is a highly sensitive marker for hindgut WDNETs and is much more sensitive than CDX2. SATB2 should be included in the immunohistochemical panel for determining the primary site of a metastatic WDNET.

### 683 Retrospective Evaluation of Elastic Stain in the Assessment of Serosal Invasion of pT3N0Mx Colorectal Cancers

WY Liang, CY Hsu, T Arnason, AT Hawkins, P Sylla, GY Lauwers. Veterans General Hospital-Taipei, Taipei, Taiwan; Massachusetts General Hospital, Boston, MA.

**Background:** Peritoneal involvement is an important adverse prognostic factor in colorectal cancer (CRC) and determines a shift in pTNM stage. Peritoneal involvement

can be difficult to identify both macroscopically and microscopically. Ancillary studies, such as elastic stains and CK7 immunohistochemical (IHC) stains, have been used to highlight the elastic lamina and peritoneal surface. The aims of this study were to determine whether these stains are useful to refine the level of tumor invasion and determine if restaging based on the results of these stains has prognostic significance in pT3 CRCs.

**Design:** We retrospectively performed one elastic stain per case on 244 consecutively resected pT3N0Mx CRCs. CK7 IHC was performed in an unselected subset of 169 cases. Associations between peritoneal elastic lamina invasion (ELI) and outcomes (recurrence, metastasis, and survival) were evaluated.

**Results:** The elastic lamina was identified in only 101 cases (41%), at a frequency of 45% in the cecum/ascending colon, 37% in the transverse, 45% in the descending/sigmoid, and 32% in the rectum. In total, 60 cases (24.6%) displayed ELI. Table 1 shows that peritoneal ELI was associated with a higher rate of recurrence and metastasis (p=0.0001), more disease-related death (p<0.0001) and worse 5-year survival (p=0.001). Mesothelial cells were highlighted by CK7 staining in only 27 cases (16%) and helped demonstrate serosal invasion in only 5 cases (3%).

Table 1

	ELNI	ELI-	ELI+	Total	P value
Cases number	143	41	60	244	
Recurrent or metastasis	9.1%	7.3%	31.7%	14.3%	0.0001
Died of Disease	4.5%	2.4%	26.7%	9.8%	<0.0001
5 year survival	85.3%	92.7%	66.7%	82.0%	0.001

ELNI:elastic lamina not identified; ELI-/+ :elastic laminal invasion absent/present

**Conclusions:** ELI was detected in 24.6% of pT3 CRCs and was a powerful predictor of adverse outcome compared to patients with tumors lacking ELI. In the elastic lamina not identified cases, the prognostic trend was intermediate, which reflects the expectation that this group would include a few cases where ELI was missed due to inadequate elastic lamina sampling. CK7 IHC was not a sensitive method to indicate peritoneal involvement and was therefore less useful. A single elastic stain is a very useful and inexpensive method to demonstrate peritoneal involvement and should be considered for routine use in all pT3 CRCs. The pT3 tumors with ELI have an adverse prognosis and should be classified separately in a higher stage group than pT3 tumors without evidence of ELI.

**684 Morphology and Natural History of Familial Adenomatous Polyposis (FAP)-Associated Dysplastic Fundic Gland Polyps (FGPs)**

WY Liang, T Arnason, E Alfaro, P Kelly, M Genevay, RD Odze, GY Lauwers. Massachusetts General Hospital, Boston, MA; Brigham and Women's Hospital, Boston, MA.

**Background:** Up to 90% of patients with FAP develop gastric FGPs, which display low grade dysplasia (LGD) in up to 48% of cases. It is unclear if LGD in FGPs in this population carries a significant risk of progression to more advanced neoplasia. The aims of this study were to characterize the morphologic phenotype of dysplasia in FAP-associated FGPs and evaluate their natural history.

**Design:** All FAP patients with a dysplastic FGP diagnosed from 1999-2008 were identified at 2 hospitals. Slides were reviewed and dysplasia was classified as intestinal, gastric, or mixed phenotype. All follow up biopsies were reviewed. Outcomes were defined as: regression of dysplasia (dysplasia absent at last biopsy); persistent dysplasia (dysplasia of same grade present at last biopsy); progression to a more advanced lesion (diagnosis of higher grade neoplasm, eg. high grade dysplasia [HGD], adenoma, carcinoma); concurrent carcinoma (carcinoma diagnosis <3 months after initial biopsy). Outcomes were compared to FAP patients with FGPs without dysplasia and patients with sporadic gastric dysplasia.

**Results:** Table 1 shows clinicopathologic features and outcomes in the 3 cohorts. 3 cases of FAP associated FGPs with LGD progressed to 2 adenomas with LGD and 1 intramucosal carcinoma. Dysplasia in FGPs in FAP patients was less frequently associated with intestinal phenotype (p<0.001), HGD (p<0.01), and the finding of concurrent or subsequent carcinoma (p=0.05) when compared to sporadic gastric dysplasia.

	FAP with FGP, no dysplasia (n=15)	FAP with FGP with dysplasia (n=24)	Sporadic dysplasia (n=56)
Mean age at first diagnosis of FGP in years (range)	34.8(20-48)	33.6(13-63)	-
Mean age at first diagnosis of dysplasia in years (range)	-	35.1(13-64)	65.6(37-95)
<b>Phenotype of dysplasia</b>			
Gastric	-	22(92%)	30(54%)
Intestinal	-	0	24(43%)
Mixed	-	2(8%)	2(4%)
<b>Grade of dysplasia at diagnosis</b>			
LGD	-	23(96%)	39(70%)
HGD	-	1(4%)	17(30%)
Concurrent carcinoma*	0	0	6(11%)
<b>Outcome</b>			
Regression of dysplasia†	-	8(33%)	20(36%)
Persistent dysplasia‡	-	13(54%)	7(13%)
Progression to a more advanced lesion	0	3(13%)	7(13%)
Progression to carcinoma	0	1(4%)	7(13%)
Mean length of follow up in years (range)	3.3(0-10.3)	6.1(0.8-12.6)	2.6(0-11.3)
Mean number of endoscopies (range)	1.6(1-5)	5.7(2-22)	40 patients had ≥ 1 follow up biopsy

**Conclusions:** There is a low 5 year risk of progression to more advanced neoplasia in FAP-associated FGPs with LGD. The 3 year endoscopic surveillance schedule recommended for duodenal adenomas in FAP is also reasonable for these patients.

**685 KRAS Codon 12, 13, 61 and 146 Mutations in 1267 Colorectal Cancers: Clinicopathological, Molecular, and Survival Analyses**

X Liao, Y Imamura, S Ogino. Dana-Farber Cancer Institute, Boston, MA; Brigham and Women's Hospital, Boston, MA.

**Background:** KRAS mutations status is increasingly important for management of colorectal cancer patients. KRAS mutations typically occur in codons 12, 13, 61 and 146. There has been no large-scale study which has comprehensively examined clinicopathologic, molecular, and prognostic associations of KRAS codon 61 and 146 mutations in colorectal cancer.

**Design:** We performed PCR and pyrosequencing of KRAS codons 12, 13, 61 and 146 in 1267 colorectal cancers. We characterized other molecular features [BRAF and PIK3CA mutations; MGMT promoter methylation and loss of expression; microsatellite instability (MSI) status] Proportional hazards model was used to compute mortality hazard ratio (HR) and 95% confidence interval (CI), adjusting for potential confounders, including stage, BRAF mutations, and MSI.

**Results:** We found 505 (40% of 1267) KRAS-mutated colorectal cancers, including 19 cases (1.5%) in codon 61 mutations, 40 cases (3.2%) in codon 146 mutations, and 12 cases (0.9%) with two or more KRAS mutations.

KRAS mutations in 1267 colorectal cancers

Codon	No.	Proportion in 1267 tumors
Any	505	40%
12	344	27%
13	115	9.1%
61	19	1.5%
146	40	3.2%

There are cases with more than one KRAS mutations.

In codons 61 and 146, we found c.182A>G (p.Q61R; N=2), c.182A>T (p.Q61L; N=4), c.183A>C (p.Q61H; N=7), c.180\_181delinsAA (p.G61K; N=4), c.436G>A (p.A146T; N=21), c.436G>C (p.A146P; N=3), and c.437C>T (p.A146S; N=11). Regardless of codon, KRAS mutations appeared to be associated with cecal tumor location (P <0.001), and PIK3CA mutations (P <0.001). MGMT loss was associated with KRAS G:C>A:T mutations (P <0.001). Patients who had colorectal cancers with KRAS codon 61 and 146 mutations survived similarly (multivariate HR =0.86; 95% CI, 0.31-2.35; and multivariate HR =0.95; 95% CI, 0.42-1.74; respectively) to KRAS wild-type cases.

**Conclusions:** KRAS codon 61 and 146 mutations occur approximately 5% of colorectal cancers. Clinicopathologic and molecular features of colorectal cancers with KRAS codon 61 and 146 mutations appear to be similar to KRAS codon 12 and 13 mutations. Additional studies are necessary to determine clinical utility of KRAS codon 61 and codon 146 testing in colorectal cancer.

**686 Inflammatory Fibroid Polyps of the Gastrointestinal Tract: Spectrum of Clinical, Morphological, and Immunohistochemistry Features**

T-C Liu, M-T Lin, EA Montgomery, AD Singhi. Washington University, St. Louis, MO; Johns Hopkins University, Baltimore, MD; University of Pittsburgh, Pittsburgh, PA.

**Background:** Inflammatory fibroid polyps (IFP) are rare benign tumors that can occur throughout the gastrointestinal tract. While part of the molecular pathogenesis of these lesions has been characterized, their morphologic features often vary. We report the clinicopathologic findings of the largest series of IFPs to date.

**Design:** Medical record, histology sections, and available immunostains of IFP cases diagnosed at Johns Hopkins U. between 1999 and 2012 were reviewed. Histologic and immunohistochemical characteristics were documented and semi-quantification (0: none, 1+: weak; 2+ moderate; 3+: strong) were applied for each feature.

**Results:** A total of 83 IFPs were collected between 1999 and 2012, including 64 biopsies and 19 resections. A review of the clinical features identified a modest female predominance (47; 57%) with patients ranging from 26 to 87 years (mean, 60 years). Involved sites include esophagus (n = 2), stomach (n = 31; mainly antrum), small intestine (n = 15), appendix (n = 1), large intestine (n = 33; majority within the rectosigmoid), and anal canal (n = 1). While most had a nonspecific presentation, those with small intestinal lesions frequently presented with intussusception. Grossly, the tumors ranged in size from 0.2 to 4.2 cm (mean, 1.7 cm). Histologically, IFPs were centered within the submucosa in all resection specimens but mucosal extension was found in 74 of 83 (89%) cases. The tumors varied in both cellularity and degree of vascularity. However, the characteristic feature of perivascular onion-skinning was present in only 54% (45/83). Importantly, a short fascicular growth pattern was noted in 36% (30 of 83) of cases, while both features were present in 14 cases (17%). Eosinophils were present in 94% (78 of 83) of cases but varied widely in number from abundant (20/hpf) to sparse (1/hpf). Interestingly, in those cases with sparse eosinophils, prominent hyalinization was also present (11 of 78, 14%). In addition, while the majority of IFP expressed CD34, 6 of 44 (14%) did not. No associated dysplasia or malignancy was seen.

**Conclusions:** IFPs represent a diverse set of submucosal-based lesions that commonly extend into the mucosa, making them amenable to endoscopic biopsy. While their classic histologic features of perivascular onion skinning and predominance of eosinophils are well-described, they may alternatively present with a short fascicular growth pattern, a sparse number of eosinophils and prominent hyalinization.

**687 Distal Esophageal Squamous Papilloma Association with Eosinophilic Esophagitis and Gastroesophageal Reflux Disease: A Single Institution Large Cohort Study**

AA Lo, VL Kung, H Li, W Zhang, MS Rao, N Gonsalves, I Hirano, G-Y Yang. Northwestern University, Chicago, IL.

**Background:** Squamous papilloma (SP) is small (< 1 cm), rare lesion most commonly found incidentally in the lower third of the esophagus during endoscopy. The majority are exophytic growths composed of fibrovascular cores covered by mature squamous epithelium and a minority are endophytic growths composed of an inverted papillary

pattern covered by a smooth outer surface. Although there is no evidence that SP is a precursor lesion to squamous epithelial dysplasia or squamous carcinoma, the etiology of SP remains elusive. In the present study, we identified 84 SP cases and extensively analyzed if histologically diagnosed eosinophilic esophagitis (EoE) or clinically identified gastroesophageal reflux disease (GERD) correlated with SP development. We also used an immunohistochemical approach to determine if HPV was involved in SP development.

**Design:** SP was identified in 84 patients (52 female, 32 male, age 30-74) between 2002 and 2012. 57 had an exophytic and 27 had an inverted growth pattern. Chart review for each patient was performed to identify history of previous esophageal diagnosis or disorder. EoE was confirmed in previously diagnosed patients based on identification of at least three high power fields with >15 intraepithelial eosinophils. Immunohistochemistry (IHC) for Ki-67, p53, and p16 and in-situ hybridization for HPV were performed on the most recent exophytic cases (n=15). Expression patterns of each marker were compared to that of normal control esophagus.

**Results:** 48% of patients with SP (40 of the 84 cases) had concurrent or previously diagnosed EoE and/or GERD. Concurrent EoE was identified in 13 cases (10 exophytic, 3 inverted). 27 cases (18 exophytic, 9 inverted) were found to have a clinical history of GERD. Each of these SPs exhibited a typical morphology with occasional intraepithelial lymphocytes or eosinophils and no dysplasia. Ki-67 expression was limited to the proliferative zone, similar to control esophageal tissue. HPV, p16 and p53 were each negative in all cases.

**Conclusions:** We present the first study to demonstrate that EoE and GERD are highly associated with SP development. Although recent studies suggest HPV may be associated with SP in the distal esophagus, our study demonstrates that HPV is not associated with SP development. Our results indicate that EoE and GERD may play a significant role in SP development, and that the underlying mechanism/pathogenesis needs to be further elucidated.

#### 688 Microsatellite Instability (MSI) and BRAF Mutation Tests Jointly Provide Useful Prognostic Information in 1861 Colorectal Cancers

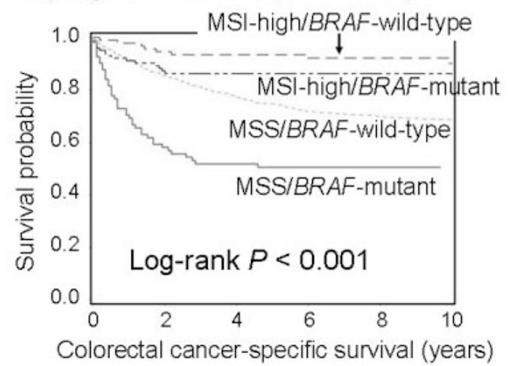
P Lochhead, C Fuchs, S Ogino. Dana-Farber Cancer Institute, Boston, MA; Brigham and Women's Hospital, Boston, MA.

**Background:** Microsatellite instability (MSI) and BRAF mutation analyses have become routine in the workup of colorectal cancers. For prognostication of all colorectal cancer patients, we examined the prognostic utility of combined MSI/BRAF status, and statistically assessed whether MSI status (or BRAF status) modified prognostic association of BRAF status (or MSI status).

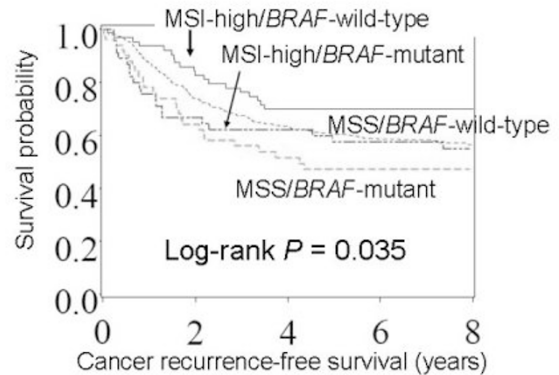
**Design:** We examined molecular features and survival in 1861 colorectal cancers, including 1253 stage I-IV colorectal cancers (cohort A) and a validation set of 608 stage III colon cancers in phase III clinical trial (cohort B). BRAF status was assessed by Pyrosequencing, and MSI status was determined using 10 microsatellite markers. Cox proportional hazards models were used to compute mortality hazard ratio (HR), adjusting for clinical, pathologic and other molecular features, including KRAS status.

**Results:** In both cohorts, the poorest colorectal cancer-specific survival was experienced by patients with microsatellite stable (MSS)/BRAF-mutant cancer, and the best survival by patients with MSI-high/BRAF-wild-type cancer in Kaplan-Meier analyses.

#### Cohort A (stage I-IV dataset; N = 1253)



#### Cohort B (stage III trial dataset; N = 608)



In both cohorts, multivariate survival analyses demonstrated that MSS/BRAF-mutant was the least favorable subtype, while MSI-high/BRAF-wild-type was the most favorable subtype.

Combined MSI/BRAF subtypes and mortality in colorectal cancer

MSI status	BRAF status	Cohort A (N=1253)		Cohort B (N=608)	
		Multivariate HR (95% CI)	P value	Multivariate HR (95% CI)	P value
MSS	Mutant	1 (reference)		1 (reference)	
MSS	Wild-type	0.63 (0.44-0.89)	<0.001	0.67 (0.43-1.04)	0.074
MSI-high	Mutant	0.30 (0.16-0.58)	<0.001	0.67 (0.35-1.26)	0.22
MSI-high	Wild-type	0.16 (0.07-0.35)	<0.001	0.48 (0.26-0.90)	0.022

CI, confidence interval; HR, hazard ratio

In both cohorts, there was no significant interaction between MSI and BRAF mutation in survival analyses (all  $P_{\text{interaction}} > 0.50$ ), suggesting independent roles of MSI and BRAF status in survival analyses.

**Conclusions:** MSI and BRAF mutation tests in colorectal cancer can jointly provide useful prognostic information. MSI-high/BRAF-wild-type is the most favorable group, while MSS/BRAF-mutant is the least favorable group, and MSI-high/BRAF-mutant and MSS/BRAF-wild-type are intermediate groups.

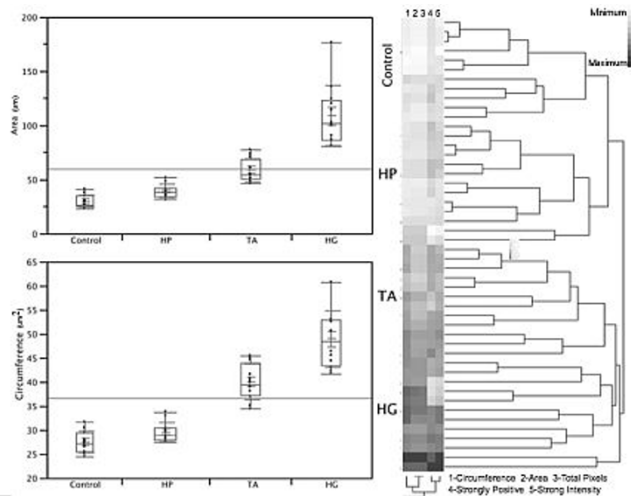
#### 689 Dysplasia in Colonic Polyps: Discrimination through Digital Image Analysis

DR Martin, AB Farris III. Emory University School of Medicine, Atlanta, GA.

**Background:** Determining the level of dysplasia within colon polyps is often difficult. This distinction is clinically important, as adenomas with high-grade dysplasia (HGD) are considered advanced lesions clinically and may warrant more stringent screening. Given apparent limitations in correlation between pathologists for the determination of low-grade vs high-grade dysplasia, we investigated polyp nuclear size using digital image analysis.

**Design:** Archived cases representing normal colonic mucosa (n=11), hyperplastic polyps (HPs) (n=13), conventional tubular adenomas (TAs) (n=12), and adenomas with HGD (n=12) were digitally scanned with a whole slide scanner. Representative nuclei from areas exhibiting the diagnostic pathologic change for each case were then circumscribed at 40x-magnification. Parameters for the discriminate analysis between groups included: nuclear circumference (um), area (um<sup>2</sup>), and 13 different nuclear staining measurements from a positive pixel count (PPC) algorithm.

**Results:** Average nuclear area and circumference progressed in the following order: normal colonic mucosa, HPs, TAs, and adenomas with HGD (Figure 1). Differences between groups were found to be statistically significant using a Student's t test (p<.0001 between all groups except HPs vs controls). Pleomorphism was also substantially greater in adenomas with HGD than tubular adenomas (standard deviation of 54.9 um<sup>2</sup> vs 15.2 um<sup>2</sup>). These findings were largely mirrored using the PPC algorithm, with statistical significance demonstrated between groups when evaluated for: number of strongly staining pixels, total staining pixels, and staining intensity. Hierarchical clustering showed that polyp types clustered into distinct groups based on their nuclear size and PPC algorithm measurements (Figure 1).



**Conclusions:** Our results confirm that quantitative image analysis is an effective measure that reflects dysplastic change in colon polyps. Nuclear area, circumference, and findings seen with the PPC algorithm distinguished polyp types from one another with statistical significance. Ultimately, precise quantification of cytologic nuclear size and staining intensity measurements may prove to be a useful diagnostic tool in determining the degree of dysplasia in colon polyps with equivocal or controversial histology.

#### 690 Gastrointestinal Biopsy Findings of Autoimmune Enteropathy – A Review of 20 Cases

R Masia, S Peyton, GY Lauwers, I Brown. Massachusetts General Hospital, Boston, MA; Pathology Queensland, Herston, Queensland, Australia.

**Background:** Autoimmune enteropathy (AIE) is a rare condition characterised by malabsorption, intractable diarrhea, and small intestinal inflammation. Most cases present in early childhood, often as an inherited disorder of immune regulation. Adult cases are increasingly recognised, although missed or delayed diagnosis remains common. Small intestinal biopsies in AIE reportedly show crypt apoptosis, intraepithelial lymphocytosis, and neutrophilic crypt abscesses. Similar changes are described in the colon. This study aims to better define the histological patterns of AIE and to characterise changes in extra-enteric biopsies.

**Design:** AIE cases from 2 institutions (Royal Brisbane Hospital and Massachusetts General Hospital) were reviewed. Biopsies were classified on the predominant small intestinal histological pattern as 1) active chronic duodenitis (ACD) – villus blunting, lamina propria chronic inflammation, neutrophilic cryptitis and crypt abscesses. 2) celiac-like – villus blunting and intraepithelial lymphocytosis. 3) Graft versus Host Disease-like (GvHD-like) – increased crypt apoptosis ± crypt dropout but minimal inflammation. 4) No predominant pattern – admixture of ≥2 patterns or mild chronic inflammation only. Biopsies from other gastrointestinal sites were reviewed.

**Results:** 20 AIE patients were identified (13 males, age range 1-80 years). 5 were adults (≥ 18 years); 11 were ≥ 10 years. The predominant pattern was ACD - 9 cases (45%), celiac-like - 5 cases (25%), GvHD-like - 2 cases (10%), and no predominant pattern - 4 cases (20%). Other gastrointestinal sites showed eosinophil infiltration >20/HPF in 3/15 esophageal biopsies (20%); inflammation in 14/19 gastric biopsies (74%), including active chronic gastritis - 3 cases, atrophic gastritis - 1 case, and GvHD-like pattern - 1 case; and abnormalities in 9/17 colon biopsies (53%, consisting of active colitis - 2 cases, GvHD-like pattern - 2 cases, lymphocytosis - 1 case, and mixed pattern - 4 cases). Inflammation was present outside the small intestine in all 19 cases with extraintestinal biopsies (100%).

**Conclusions:** AIE is characterised by a broader spectrum of pathological changes than previously recognised, and traditionally described features such as crypt apoptosis may be inconspicuous. The most common pattern on small intestinal biopsy is active chronic duodenitis, often with crypt abscesses. Histological changes are frequent outside the small intestine and AIE may be better regarded as a pan-gastrointestinal autoimmune disorder.

#### 691 Expression Microarray Analysis Identifies Novel Epithelial Derived Differentially Expressed Protein Markers in Eosinophilic Esophagitis

A Matoso, VA Mukkada, S Lu, R Monahan, K Cleveland, L Noble, S Mangray, MB Resnick. Rhode Island Hospital, Providence, RI.

**Background:** Gene expression studies in eosinophilic esophagitis (EoE) support an immune mediated etiology associated with differential regulation of inflammatory cells and epithelial derived genes. Our aims were to characterize epithelial gene expression alterations associated with EoE and to determine whether the differentially expressed proteins may prove to be useful immunohistochemical markers of EoE.

**Design:** Esophageal biopsies from pediatric patients with EoE before (EoE-BT) and after topical steroids therapy (EoE-AT; N=7) were screened by expression microarray (Affymetrix GeneChip), and the results validated by qRT-PCR. A larger group of biopsies from EoE patients (n=42) were used to evaluate protein expression by immunohistochemistry (IHC) compared with biopsies of patients with reflux esophagitis (GERD; n=15) and normal controls (n=17). IHC positivity was defined by moderate or strong staining in at least 10% of the epithelial cells.

**Results:** Microarray studies identified 31 epithelial derived genes differentially expressed (>3 fold change) including 12 upregulated and 19 downregulated genes. qRT-PCR validated overexpression of ALOX15 and TNFAIP6 and underexpression of FLG, SLURP1 and CRISP3. Compared to EoE-AT samples, expression of ALOX15 was 7.0 fold higher in EoE-BT ( $P=0.02$ ) and expression of TNFAIP6 was 6.1 fold higher in EoE-BT compared to EoE-AT samples ( $P=0.04$ ). Expression of the initially downregulated genes FLG, SLURP1 and CRISP3 were upregulated after therapy by a fold change of 5.3 for FLG ( $P=0.01$ ), 2.4 for SLURP1 ( $P=0.02$ ) and 40.1 for CRISP3 ( $P=0.02$ ). Cytoplasmic staining for ALOX15 was strongly and diffusely positive in 95% of EoE and negative in all controls, EoE-AT and GERD biopsies ( $P<0.001$ ). TNFAIP6 was positive in 88% of EoE and in 47%, 29% and 40% of controls, EoE-AT and GERD respectively ( $P=0.002$ ). FLG was positive in 88% of controls and 100% of GERD, but negative in all EoE, and re-expressed in 86% of EoE-AT ( $P<0.001$ ). SLURP1 expression was positive in all controls and GERD, but only positive in 5% of EoE and was re-expressed in EoE-AT ( $P<0.001$ ). The majority of controls (89%) and GERD (100%) were positive for CRISP3 while EoE-BT were positive in 14% of samples ( $P<0.001$ ) with partial recovery after treatment (43%).

**Conclusions:** We identified five novel epithelial proteins differentially expressed in EoE and easily detectable by IHC. One of these proteins, ALOX15, may prove to be a useful diagnostic marker and therapeutic target for EoE.

#### 692 RT-PCR Increases Sensitivity To Detect Cytomegalovirus in Paraffin-Embedded, Formalin-Fixed Tissue of Gastrointestinal Biopsies

MH McCoy, K Post, JD Sen, HY Chang, Z Zhao, J Lin. Indiana University School of Medicine, Indianapolis, IN.

**Background:** Cytomegalovirus (CMV) infections lead to a variety of active disease manifestations and have been described in all age groups, especially in immunosuppressed patients such as those with HIV/AIDS, recipients of solid organ or hematopoietic transplants and those receiving chemotherapy. Diagnosis of CMV often relies on histopathologic examination on hematoxylin and eosin (H&E) stained sections for the identification of classic viral inclusions along with the aid of immunohistochemistry (IHC) or in-situ hybridization. However, sensitivity in diagnosing CMV infection by non-classic appearing inclusions or atypical IHC staining patterns remains an ongoing concern for pathologists.

**Design:** We report the use of real time polymerase chain reaction (RT-PCR) on nucleic acid extracted from paraffin-embedded, formalin-fixed tissue of gastrointestinal (GI) biopsies (n=84) from cases of CMV infection diagnosed by H&E or IHC.

**Results:** Of the 84 biopsies diagnosed as positive for CMV infection, 78 (92.9% sensitivity) tested positive by RT-PCR. Of the accessions these biopsies comprised, 26 cases had additional biopsies (N=40) taken either during the same procedure or previous procedures, some taken just days prior, which were diagnosed as negative for CMV infection by H&E or IHC. Interestingly, 25 biopsies (62.5%), which were diagnosed as negative previously, tested positive for CMV by RT-PCR with appropriate controls.

**Conclusions:** In summary, we demonstrate that RT-PCR is a sensitive and rapid molecular tool that may be employed on small GI biopsies to aid in the diagnosis of CMV infection.

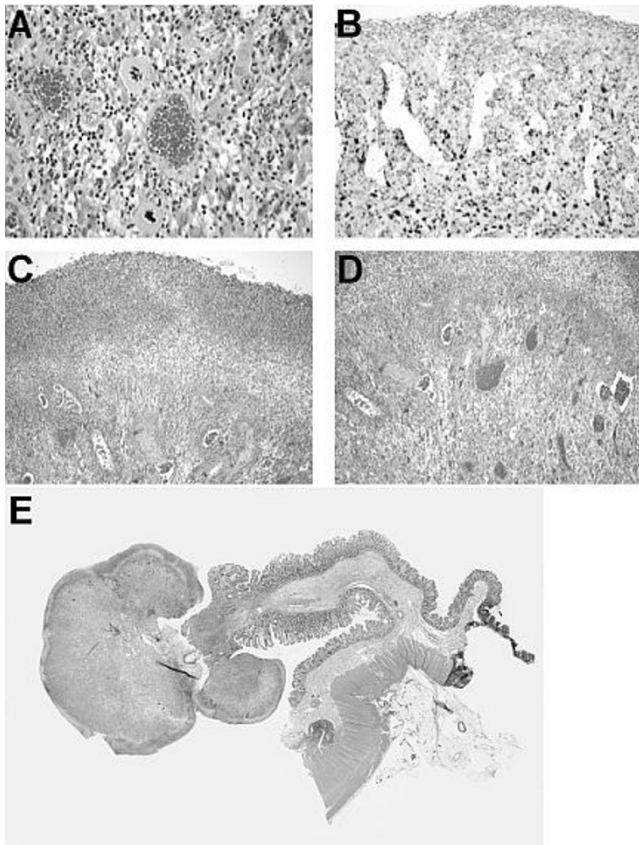
#### 693 Where the Living Meets the Dead: Rinds of Bizarre Stromal Cells with Atypical Mitoses in Pseudosarcomatous Gastrointestinal (GI) Tract Lesions

OG McDonald, EA Montgomery. Johns Hopkins Medical Institutions, Baltimore, MD.

**Background:** Pseudosarcomatous stromal lesions with bizarre cells are well-known in GI ulcers and polyps. They are benign, usually showing scant mitotic activity without atypical mitoses. We describe 8 additional cases with features distinct from those previously reported.

**Design:** Cases were retrieved from file; most (7/8) were consultation cases with an impression or diagnosis of malignancy. Follow-up (FU) was obtained. When possible, lesions were stained with p53 and Ki-67 as were TMA slides from high-grade pleomorphic sarcomas.

**Results:** Lesions involved the GI tract (7/8, 5 colorectal, 1 ileal) and a suprapubic ulcer. Patient ages ranged from 40-78 (median, 71) years. Available past medical history (4 cases) gave evidence of ischemia (septic shock, vasculitis, angioplasty and thrombosis, anemia), 2 patients had a history of radiation, and 1 had Crohn Disease. Lesions were inflammatory polyps (4), granulation tissue-predominant inflammatory polyps (3), or granulation tissue polyps (1). All cases showed bizarre pleomorphic fibroblasts (A-E), surface ulceration, and mitotic figures. Most (7/8) had atypical mitoses (A). All 8 cases had a thick well-organized, zonal "rind" of bizarre stromal cells between the ulcerated non-viable surface and deep granulation tissue (C-E). This architectural feature was diagnostic of a benign process. Tested pseudosarcomas were strongly, diffusely p53 reactive (B) (2/2, 100%), with low Ki-67 indices (5-10%, 4 cases). Control pleomorphic sarcomas (14) had variable p53/Ki-67 patterns. On FU (6 patients; 7-59 months; median 15 months), no lesion recurred or resulted in death of the patient.



**Conclusions:** Here we present a distinct series of ulcerated lesions with bizarre pseudosarcomatous stromal atypia. These lesions closely mimic sarcomas, including nuclear features that appear overtly malignant, mitotic activity, and atypical mitoses. Immunohistochemical staining for p53 and Ki-67 does not appear to discriminate these benign lesions from sarcomas. The diagnosis is made by low-power examination of H&E sections; a zonal “rind” of bizarre stromal cells can be seen within the (presumably) hypoxic zone located between granulation tissue and the ulcerated surface, i.e. “where the living meets the dead”.

#### 694 Classification of Colorectal Cancer Based on DNA Methylation Array Analysis

M Milewski, D Leahy, J Conroy, T Magalhaes, S Ennis, A Maguire, H Mulcahy, J Hyland, D O'Donoghue, K Sheahan. University College Dublin, Dublin, Ireland; St. Vincent's University Hospital, Dublin, Ireland.

**Background:** Colorectal cancers are usually classified based on a limited number of molecular features. Aberrant DNA methylation of CpG islands is considered to be an important influence on colorectal tumorigenesis. In this study, we present a novel classification scheme based solely on extensive genome-wide methylation analysis.

**Design:** We analysed a group of 102 samples. This group was composed of 70 colorectal tumors (both sporadic and Lynch syndrome) with 24 adjacent normal tissues. Mucosa from 8 diverticulosis cases was also included. All tumor samples had been tested for microsatellite instability and mutations in *BRAF* and *KRAS* and were classified using currently accepted criteria. Genomic DNA was extracted from formalin fixed paraffin embedded tissue and treated with sodium bisulfite. The methylation status of 1505 CpG sites in 807 genes was determined for each sample using the Illumina GoldenGate Methylation Assay methodology.

**Results:** Following unsupervised hierarchical clustering, four distinct tumor sub-groups emerged. The majority of Lynch syndrome samples were located in one group while a large proportion of sporadic microsatellite stable cases were gathered in another. Most of the sporadic MSI samples combined in a cluster showing a distinctive pattern of DNA methylation, highly correlated with *BRAF* mutation. All the normal samples clustered into two sub-groups separate from the tumor groups. While some of the methylation based sub-groups paralleled the traditional classification, there were significant differences and their importance remains to be determined.

**Conclusions:** Refining classification and determining the biological processes which underlie the sub-groups of colorectal cancer is necessary to optimise patient treatment. This study further highlights the importance of DNA methylation in the molecular pathology of colorectal carcinogenesis.

#### 695 Sessile Serrated Adenoma (SSA) and Borderline Sessile Serrated Adenoma (BSSA) Differ from Hyperplastic Polyp (HP) and Normal Colorectal Mucosa by the Status of Endocrine Cells

M Mohammadi, A Aziz, M Bzorek, S Holck. Hvidovre University Hospital, Hvidovre, Denmark; Hospital South, Naestved, Denmark.

**Background:** Dilatation and serration of cryptbases are important qualities of sessile serrated adenoma (SSA) and, to a lesser extent of its borderline variant (BSSA) [1]. We have previously reported additional qualities of BSSA, more in line with SSA than with hyperplastic polyps (HP), including proneness of large polyp size and demographic data [2]. A single communication [3] on SSAs has further noticed an absence of endocrine cells in SSA, a property not subsequently validated. Nor has this feature been addressed in relation to BSSA. Here, these serrated polyps are systematically examined for chromogranin A-positive cells, correlating the results with those of HP.

**Design:** The material, previously detailed [1], comprised 24 SSAs, 13 BSSAs, and 11 HPs matched for site and age as well as 10 biopsies of normal colorectum. The specimens were immunostained for the endocrine marker chromogranin A. The immunostained slides were scrutinized for the presence of labelled cells, the number of which was counted in 10 crypts per specimen (mode of selection: for SSA and BSSA structurally aberrant crypts were chosen, for HP and normal mucosa 10 contiguous, longitudinally or near longitudinally cut crypts were chosen).

**Results:** Immunopositive cells (any number) were recorded in 25%, 38%, 100%, and 100% of the studied SSAs, BSSAs, HPs, and normal mucosa, respectively. Among specimens with immunopositive cells, the average number per counted crypt was 0.12, 0.26, 2.34, and 2.45 for SSAs, BSSAs, HPs, and normal mucosa, respectively.

**Conclusions:** We have previously demonstrated that BSSA in several, albeit not all respects, resembles SSA more so than HP. Here we add the endocrine cell status to this notion, which may be exploited in the routine diagnostic process and which strengthens the idea that HP fundamentally differs from SSA and BSSA.

**Ref.:** 1. Mohammadi et al. Pathol Res Pract 2011; 207: 410-16; 2. Mohammadi et al. J Clin Pathol, 2012; 3. Torlakovic et al. Am J Surg Pathol 2003; 27: 65-81.

#### 696 The Optimal Number of Biopsy Fragments To Establish a Diagnosis of Eosinophilic Esophagitis

JA Nielsen, DJ Lager, M Lewin, CA Roberts. ProPath, Dallas, TX.

**Background:** Eosinophilic esophagitis (EoE) is characterized clinically by dysphagia, chest pain and food impaction and morphologically by increased numbers of intraepithelial eosinophils and marked basal hyperplasia of the squamous mucosa. The consensus criteria for a diagnosis of EoE include the presence of > 15 eosinophils/HPF in biopsies from both proximal and distal esophagus in the absence of other causes of esophageal eosinophilia, and the lack of a clinical response to proton pump inhibitor therapy. Because of the variability in the distribution of intraepithelial eosinophils among biopsy fragments and the lack of standardized biopsy practices, we sought to determine the optimum number of esophageal biopsies from the mid and distal esophagus needed to make a diagnosis of EoE.

**Design:** From 1/5/2009 to 9/26/2011, 771 patients were diagnosed with EoE at our institution. From that patient population, biopsies from 45 sequential cases were chosen for further study. All of the 45 patients had biopsies from the mid and distal esophagus. Cases with only gastric mucosa present and biopsies from patients undergoing therapy for EoE were excluded. The original H&E-stained slides were reviewed, and the number of biopsy fragments containing squamous mucosa was recorded. Using a 40X objective and 10X oculars (field diameter = 0.52 mm, field area = 0.849 mm<sup>2</sup>), the number of eosinophils per high power field (EOS/HPF) in up to three HPF was counted in each biopsy fragment.

**Results:** The EOS/HPF was counted in 487 biopsy fragments. The number of biopsy fragments obtained from the mid esophagus ranged from 1 to 14 (mean 6; median 6) and from the distal esophagus from 1 to 15 (mean 5; median 5). There was no significant difference between the mean number of EOS/HPF from the mid (20.85) and lower (23.77) esophagus ( $p=0.29705$ , 2-tailed T-test). When the total number of biopsy fragments containing 1 to 10 and >10 EOS/HPF was calculated, 71.1% of cases with 3 biopsy fragments and 90.5% with >10 biopsy fragments had >15 EOS/HPF. The probability of 1, 4, 5 and >6 biopsy fragments containing > 15 EOS/HPF was .55, .96, .98 and >.99 respectively.

**Conclusions:** From this data at least 4 biopsy fragments should be submitted from mid and distal esophagus to optimize the chances of a positive diagnosis of EoE, however the yield is not increased beyond 6 biopsy fragments. Although there was no statistically significant difference in EOS/HPF between mid and distal esophagus, biopsy of both sites is necessary to exclude reflux esophagitis.

#### 697 Digging Deeper into Problematic Polyps: Incidence of Diagnostic Change in Colorectal Polyp Specimens after Deeper Sectioning at Two Different Laboratories

JA Nielsen, DJ Lager, M Lewin, J Weber, CA Roberts. ProPath, Dallas, TX; Texas Digestive Disease Consultants, Southlake, TX.

**Background:** Clinically significant and completely benign polyps in colorectal (CR) biopsies are often asymptomatic and can be endoscopically homogenous. Among CR polyps, adenomas are of particular concern, because of their malignant potential and subsequent obligation for more extensive patient follow-up. Occasionally, endoscopically evident CR “polyps” are non-diagnostic (ND), and it is necessary to obtain deeper levels from the tissue block to improve diagnostic accuracy and provide the most effective patient treatment. The reported adenoma detection rates on deeper sectioning range from 1.29% to 19.7% of ND CR “polyps.” This study sought to determine the rate of adenoma detection on deeper sectioning from two laboratories staffed by the same pathologists.

**Design:** After the initial assessment, three deeper levels were obtained in a total of 100 sequential ND CR polyps from each laboratory, and the change in diagnosis was recorded. All ND biopsies were grouped into one of three categories based on original observations: no histologic abnormality (NA), lymphoid aggregate(s) (LA), or suggestive of hyperplastic polyp(s) (SHPP). The diagnoses with respect to biopsy location (ascending, transverse, descending, or rectosigmoid colon) were tabulated. All original slides and corresponding deeper levels were blindly reviewed by a second pathologist to confirm both the original impression and final diagnosis.

**Results:** Of the 2853 CR "polyp" biopsies accessioned during the period of study, 12.4% were considered ND. Within the subset of 200 ND cases from both laboratories with deeper level sectioning, new diagnostic information was rendered in 43 (21.5%) and adenomas specifically in 16 (8.00%). Each laboratory had an identical adenoma conversation rate of 8%. There was no correlation between the biopsy location and adenoma detection on deeper sectioning. Biopsies that were originally NA were statistically more likely to uncover new diagnostic information than those with either LA or SHPP.

**Conclusions:** These results support the routine ordering deeper levels on ND CR polyps to improve adenoma detection rates, especially those cases without any histologic abnormality. The location of the biopsy within the colon cannot be used to predict adenoma conversion. Deeper levels should be performed on ND CR polyps when only one polyp is biopsied but may not alter clinical management if other adenomas are present.

### 698 Hereditary Predisposition to LINE-1 Hypomethylated Colorectal Cancer: Potential Clinical Utility of Tumor LINE-1 Methylation Test for Familial Cancer Risk Assessment

R Nishihara, C Fuchs, S Oginio. Dana-Farber Cancer Institute, Boston, MA; Brigham and Women's Hospital, Boston, MA.

**Background:** Beyond known familial colorectal cancer (CRC) syndromes, the mechanisms underlying the elevated CRC risk associated with CRC family history (seen in ~[underline]20% of all newly diagnosed CRCs) remain largely unknown. Because LINE-1 hypomethylated CRCs are associated with young age of onset, we hypothesized that some LINE-1 hypomethylated CRCs may represent a new familial CRC predisposition syndrome, and that LINE-1 methylation test may help familial CRC risk assessment (beyond MSI).

**Design:** Using a population of 134,079 individuals with 3,184,415 person-years of follow-up, we prospectively examined the association between CRC family history and the risk of CRC (N=1,224) according to tumor LINE-1 methylation level. We excluded individuals with polyposis and those with inflammatory bowel diseases. We excluded MSI-high CRC from outcome, to eliminate the influence of Lynch syndrome (i.e., hereditary susceptibility to MSI-positive cancer).

**Results:** CRC family history significantly increased the risk of LINE-1 methylation-low CRC (P<0.001), and to a lesser degree, that of LINE-1 methylation-intermediate CRC (p=0.002).

Family History of CRC and Risk of Developing CRC according to Tumor LINE-1 Methylation Level

	No. of first-degree relatives with CRC	0	1	>=2	P value for trend
	Person-years of follow-up	2,787,643	370,088	26,684	
LINE-1 M-low (<=55% methylated)	Multivariate HR (95% CI)	1 (reference)	1.68 (1.19-2.38)	3.48 (1.59-7.63)	P<0.001
LINE-1 55-65% methylated	Multivariate HR (95% CI)	1 (reference)	1.50 (1.17-1.93)	1.42 (0.64-3.14)	P = 0.002
LINE-1 M-high (>=65% methylated)	Multivariate HR (95% CI)	1 (reference)	1.11 (0.83-1.48)	1.43 (0.59-3.49)	P = 0.35

CI, confidence interval; HR, hazard ratio; M, methylation. P value for trend indicates statistical trend for CRC risk from those with no family history, to those with 1 affected first-degree relative, to those with >=2 affected first-degree relatives.

In contrast, CRC family history did not elevate the risk of LINE-1 methylation-high CRC (P=0.35). The association between CRC family history and CRC risk significantly differed by tumor LINE-1 methylation level (P for heterogeneity =0.020).

**Conclusions:** CRC family history is associated with higher risk of LINE-1 hypomethylated CRC, implying a previously unrecognized familial CRC trait characterized by heritable predisposition to epigenetic alterations. Our data suggest that, similar to the MSI testing, LINE-1 methylation can serve as a tumor biomarker for familial cancer risk assessment.

### 699 The Significance of Epithelial-Mesenchymal Transition (EMT) in Extrahepatic Bile Duct Carcinoma: A Clinicopathologic Study of 122 Cases

T Nitta, T Mitsuhashi, Y Hatanaka, KC Hatanaka, S Hirano, Y Matsuno. Hokkaido University Hospital, Sapporo, Hokkaido, Japan; Hokkaido University Graduate School of Medicine, Sapporo, Hokkaido, Japan.

**Background:** EMT is characterized by a loss of cell adhesion and increased cell mobility due to cells gaining a mesenchymal phenotype, and is an important mechanism behind initiation of cancer invasion and metastasis. Although EMT has been documented in a large number of cancers, most studies have used in vitro systems that employ cell lines and focused on the detailed mechanism of EMT, identifying a number of transcription factors (TFs) and signaling pathways involved. Therefore, little is known about the exact pattern of EMT in patient cancer tissues or the clinical importance of EMT itself in extrahepatic bile duct carcinoma (EHBDC). This study was performed to clarify the involvement of EMT in the progression of EHBDC.

**Design:** A total of 122 cases of surgically resected EHBDC were examined. Immunohistochemical studies of the proteins known to be involved in EMT in various cancers (E-cadherin, CK19, S100A4, vimentin, fibronectin, N-cadherin, snail, slug, twist, zeb1 and zeb2) were performed using tissue microarray (TMA) (each consisted of a tumor center, an invasive front, and non-neoplastic bile ducts). Selected markers (E-cadherin, S100A4, zeb1 and zeb2) were studied also in 10 representative cases using whole sections to evaluate the tumor heterogeneity. The antibodies against TFs were validated using several cancer cell lines as positive controls. Survival curves were calculated by the Kaplan-Meier method and evaluated using log-rank test.

**Results:** The EMT-related proteins were expressed in the stroma and epithelium of a subset of EHBDC. The expression of these markers in the epithelium was not related to the tumor differentiation. The differences between the tumor center and the invasive front were not so evident. High EMT evaluated by the loss of epithelial E-cadherin was associated with reduced overall survival (ROS) in both the tumor center and the invasive front (p=0.0337 and p=0.025, respectively). Other markers such as S100A4, zeb1 and zeb2 were not significantly associated with ROS.

**Conclusions:** This is the first comprehensive study of EMT in tissues from patients with EHBDCs. A subset of EHBDCs is expected to lose their epithelial phenotype and sequentially acquire a mesenchymal phenotype. Although little has been known about the clinical significance of the different phenotypes of EMT in EHBDCs, the loss of epithelial E-cadherin might be a significant EMT-related event to predict a poor prognosis of EHBDC.

### 700 Tumor Budding Is a Predictor of Nodal Metastasis and Tumor Recurrence in T1 Esophageal Adenocarcinoma

JA Nowak, A Agoston, Y Zheng, R Bueno, RD Odze, A Srivastava. Brigham and Women's Hospital, Boston, MA.

**Background:** Endoscopic mucosal resection (EMR) is increasingly used for management of patients with T1 esophageal adenocarcinoma (EAC). Although the overall outcome is favorable in these patients, a subset shows recurrence and an adverse outcome. The aim of this study was to identify pathologic features that can help predict an adverse outcome in early stage EAC and which can, therefore, be used to optimize patient selection for EMR versus surgery and chemoradiation therapy.

**Design:** 42 patients with T1 EAC treated by primary surgical resection at a single institution between 1995-2005 were identified. A pre-determined set of pathologic variables were examined for each case including: tumor size, tumor grade, tumor type (intestinal versus non-intestinal), depth of invasion (above first, between first and second, and below second muscularis mucosae), presence of lymphovascular invasion, presence of lymph node metastases, and presence and extent of tumor budding (criteria similar to Ueno et al (2003) used previously in colorectal cancer). Follow up data including overall survival and time to recurrence was obtained by medical chart review, and was analyzed by both a Cox Proportional Hazards Model and Fisher's Exact Test. Correlation between potential predictive variables was evaluated by the Spearman Rank-order Correlation Coefficient.

**Results:** Mean patient age was 64.4 years (range: 46-87 yrs) and M:F ratio was 9.5:1. 22/42 patients (52%) died during follow up and 4 patients (9.5%) had a documented recurrence (3 distant and 1 combined local and distant). The presence of tumor budding was a strong predictor of tumor recurrence (Hazard Ratio [HR]=14.21 for time to recurrence, p-value 0.022) and the presence of >=10 buds per 20x field was associated with a nearly 20 fold increase in risk of tumor recurrence (HR=19.99, p-value 0.007). The amount of tumor budding also correlated positively with nodal metastases (Spearman rank-order correlation coefficient 0.6, p-value <0.001). The presence of lymph node metastases was also associated with a decreased time to recurrence (HR=7.75; p-value 0.041). High tumor grade correlated both with reduced overall survival (HR=3.06, p-value 0.015) and with tumor recurrence (Fisher Exact Test p-value 0.012).

**Conclusions:** Our findings suggest that tumor budding is a strong predictor of both tumor recurrence and nodal metastasis and can be used to identify a subset of T1 EAC patients at high risk for an adverse outcome.

### 701 CDKN1A, 1B, TP53 mRNA and miR-34a, 192, 215, 221 Expression of Crypts and Stroma in Human Colorectal Cancer

H Nozaka, A Mayama, T Miura, H Takami, K Takahashi, Y Konishi, Y Mue, M Suzuki, N Uesugi, K Ishida, T Sugai. Hirosaki University, Hirosaki-shi, Aomori, Japan; Iwate Medical University, Morioka-shi, Iwate, Japan.

**Background:** The carcinogenesis of colon is caused by accumulation of genetic alternation or mutation. Progress of human cancers is relevant to activation or inactivation of both oncogenes and cancer suppressor genes. Recent works have shown significant genomic DNA biomarkers, it is also reported the posttranscriptional regulation of gene by mRNAs or non-coding RNA. It is suggested that the functional mRNAs and miRNAs status are significance for clarification of cancer progress. However, it is not reported that mRNA/miRNA expression status as the clinicopathological biomarker in only crypts or stroma. In this study, we examined CDKN1A, 1B, TP53 mRNA and miR-34a, 192, 215, 221 expression of crypts/stroma in human colorectal cancer, and analyzed significance as the clinicopathological biomarker.

**Design:** Tumors were collected from 30 patients diagnosed with primary advanced colorectal cancer. After the surgery extraction, we collected a part of both normal and tumor tissues from fresh colon or rectum. Tissues were sliced with a razor into minute pieces, half of pieces were dissolved in TRIzol reagent (Whole). Crypt was isolated from the left-behind pieces by crypt isolation method, and dissolved in TRIzol reagent (Crypt). After extraction of total RNA, and CDKN1A, 1B, TP53 mRNA and miR-34a, 192, 215, 221 expression in crypts/whole were measured by qRT-PCR. The relative quantification values compared with normal tissues were calculated, and statistical analysis was carried out between pTMN Stage I+II and pTMN Stage III+IV group by SPSS.

**Results:** *CDKN1A*, *miR-192*, *215* showed down regulation in both crypt and whole, and *miR-34a* showed down regulation in only whole. Statistical analysis was shown in table 1. In the analysis of crypt, *CDKN1A* showed significantly down regulation in Stage III+IV group. In the analysis of whole, *miR-34a* and *221* showed significantly down regulation in Stage III+IV group.

mRNA and miRNA expression Stage I+II vs Stage III+IV

Gene ID	<i>CDKN1A</i>	<i>CDKN1B</i>	<i>TP53</i>	<i>miR-34a</i>	<i>miR-192</i>	<i>miR-215</i>	<i>miR-221</i>
Crypt	P<0.01	P=.953(N.S.)	P=.664(N.S.)	P=.722(N.S.)	P=.921(N.S.)	P=.527(N.S.)	P=.429(N.S.)
Whole	P=.859(N.S.)	P=.123(N.S.)	P=.385(N.S.)	P<.05	P=.067(N.S.)	P=.085(N.S.)	P<.05

**Conclusions:** It was suggested that down regulation of *CDKN1A*, *miR-192*, *215* was clinicopathological biomarker of human colorectal cancer. It was suggested that down regulation of *miR-34a* and *221* were caused in stroma. Therefore, microRNA status in stroma may be an index of invasion in human colorectal cancer.

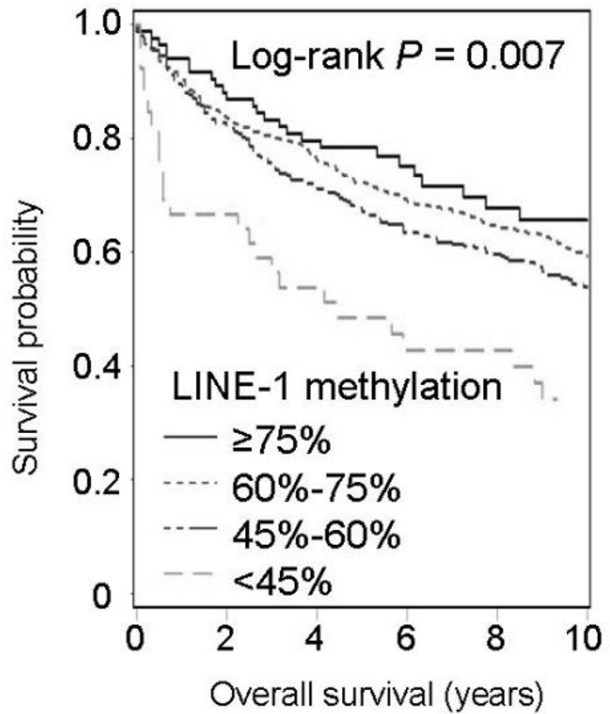
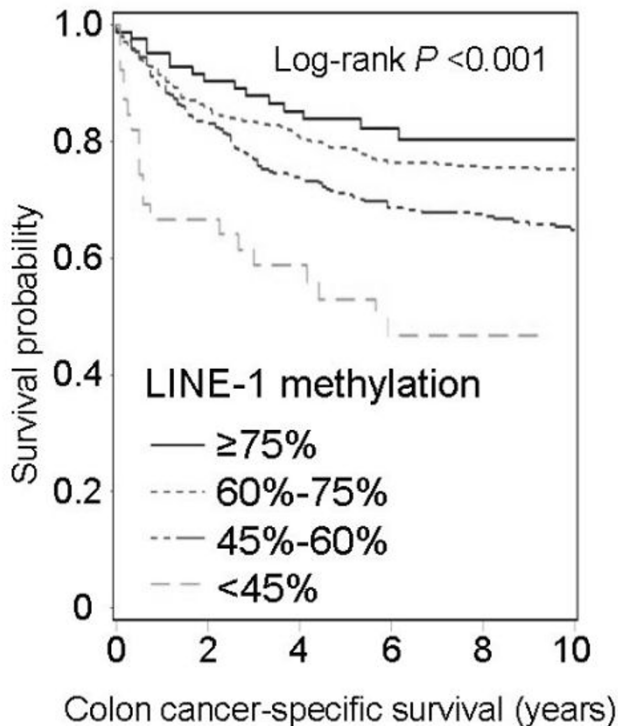
## 702 LINE-1 Hypomethylation and Patient Prognosis in 1253 Colorectal Cancers

*S Ogino, Y Imamura, C Fuchs.* Brigham and Women's Hospital, Boston, MA; Dana-Farber Cancer Institute, Boston, MA.

**Background:** Long interspersed nucleotide element-1 (LINE-1) repetitive elements occupy ~17% of nucleotides in the human genome. LINE-1 hypomethylation has been associated with global DNA hypomethylation, chromosomal instability, and carcinogenesis. We hypothesized that LINE-1 hypomethylation in colorectal cancer might predict aggressive tumor behavior.

**Design:** We quantified LINE-1 methylation by PCR-pyrosequencing in 1253 colorectal cancers. Kaplan-Meier method and Cox proportional hazards model were used to assess mortalities, according to LINE-1 methylation level. Multivariate analysis was adjusted for potential confounders including stage and status of MSI, *KRAS* and *BRAF*.

**Results:** LINE-1 hypomethylation in 978 colon cancers was associated with low colon cancer-specific and overall survival in Kaplan-Meier analyses.



In multivariate Cox regression analyses, LINE-1 hypomethylation in colon cancer was independently and linearly associated with an increase in colon cancer-specific and overall mortality.

LINE-1 Methylation Level and Colon Cancer Mortality

LINE-1 methylation level	N	Multivariate HR for cancer-specific mortality (95% CI)	Multivariate HR for overall mortality (95% CI)
≥75%	84	1 (reference)	1 (reference)
60%-75%	546	1.42 (0.81-2.48)	1.46 (0.98-2.20)
45%-60%	309	1.85 (1.04-3.31)	1.61 (1.05-2.46)
<45%	39	3.85 (1.86-7.96)	2.81 (1.59-4.98)
P value for trend		0.001	0.018

CI, confidential interval; HR, hazard ratio. P for trend was calculated using raw LINE-1

methylation value in each tumor to assess significance of the linear relationship with mortality.

In contrast, LINE-1 hypomethylation was not significantly associated with prognosis in 275 rectal cancers ( $P = 0.48$ ).

**Conclusions:** Tumor LINE-1 hypomethylation is associated with poor prognosis in colon cancer (independent of stage and other molecular factors examined), but not in rectal cancer. Our findings support tumor LINE-1 methylation as a prognostic biomarker in colon cancer.

## 703 Interobserver Variability in Assessing High-Grade Dysplasia and Architecture in Colorectal Adenomas: A Multi-Centre Canadian Study

*A Osmond, H Li Chang, R Kirsch, D Divaris, V Falck, DF Liu, C Marginean, K Newell, J Parfitt, B Rudrick, H Sapp, J Walsh, S Smith, F Wasty, D Driman.* Western University, London, Canada; University of Toronto, Toronto, Canada; Grand River Hospital, Kitchener, Canada; University of Calgary, Calgary, Canada; Woodstock General Hospital, Woodstock, Canada; University of Ottawa, Ottawa, Canada; Grey Bruce Health Services, Owen Sound, Canada; Dalhousie University, Halifax, Canada; Huron Perth Health Alliance, Stratford, Canada; St. Thomas Elgin General Hospital, St. Thomas, Canada.

**Background:** Colorectal cancer screening programs have been introduced throughout Canada. Standardized diagnosis of colorectal adenomas (CRAs) is required for risk stratification, establishing surveillance intervals, and analysis of epidemiologic data. Guidelines were developed by a pan-Canadian expert panel to standardize reporting of colorectal polyps. The aims of the present study were a) to assess interobserver variability in the classification of dysplasia and architecture in CRAs, and b) to determine if interobserver variability could be improved by the adoption of criteria specified in the guidelines.

**Design:** An *a priori* power analysis was used to determine an adequate number of cases and participants. Twelve pathologists, 6 in community practice and 6 in academic practice, independently classified 40 whole slide images of CRAs according to architecture (tubular, tubulovillous, villous) and dysplasia grade (low (LGD), high (HGD)). After a washout period of 30 days, participants were provided with the consensus guidelines and asked to reclassify the study set.

**Results:** At baseline there was moderate interobserver agreement for both architecture [ $K = 0.4700$ ; 95% CI 0.4427, 0.4972] and dysplasia grade [ $K = 0.5680$ ; 95% CI 0.5299, 0.6062]. Following distribution of the guidelines, there was improved interobserver agreement in assessing architecture [ $K = 0.5403$ ; 95% CI 0.5133, 0.5674]. For dysplasia grade, overall interobserver agreement remained moderate but decreased significantly [ $K = 0.4833$ ; 95% CI 0.4452, 0.5215], with the decrease in agreement being greater

amongst pathologists in community practice. Half of the cases in the study contained HGD. Six pathologists diagnosed HGD in 25-40% of cases, 4 diagnosed HGD in 41-50% of cases, and 2 diagnosed HGD in  $\geq 75\%$  of cases.

**Conclusions:** CRAs can be classified with only a moderate level of interobserver agreement. Adoption of the consensus guidelines resulted in improved interobserver agreement in assessing polyp architecture, but decreased agreement in grading dysplasia. The variability in the diagnosis of HGD, even following guideline review, suggests the need for more concerted knowledge-transfer exercises.

#### 704 Indefinite for Dysplasia in Inflammatory Bowel Disease: Subtypes and Clinical Outcomes

VL Owens, JE Eaton, TC Smyrk. Mayo Clinic, Rochester, MN.

**Background:** Interpreting surveillance biopsies in inflammatory bowel disease (IBD) is not always straightforward, thus the option for a diagnosis of "indefinite for dysplasia" (IND). The original description of IND included the category "IND, unknown," for "unexplained enlargement of nuclei that lack other characteristics of dysplasia." We have encountered many biopsies with enlarged, round nuclei, irregular nuclear membranes and macronuclei worrisome for dysplasia. Our descriptive term is "large cell change" and we categorize it as IND, even when the cytologic atypia is marked. We reviewed biopsies diagnosed as IND to better understand "large cell change."

**Design:** We reviewed all IBD surveillance biopsies called IND between 2000 and 2010 and retrospectively reclassified them as IND favor reactive, IND favor dysplasia and IND unknown, with the latter category used exclusively for biopsies with large cell change. Multiple clinical parameters were recorded from the medical record. Immunohistochemistry for p53 was performed on representative biopsies.

**Results:** 194 patients had biopsies called IND. 64 patients were excluded (11 with slides unavailable for review; 53 with prior or synchronous biopsy called low grade dysplasia, high grade dysplasia (HGD) or carcinoma (CA)). Of the remaining 130 patients (89M:41F), 112 had ulcerative colitis, 15 Crohn's, and 3 were unclassified. 53 patients had primary sclerosing cholangitis (PSC). Overall, 24 patients (18%) progressed to dysplasia, with 9 (7%) developing HGD/CA. We reclassified 46 patients as "reactive," 67 as "large cell," and 17 as "dysplasia." Many of the large cell patients had PSC (42/67), compared to 7 reactive and 4 dysplasia patients. Progression rates to dysplasia for these groups were 13%, 15% and 47%, respectively, with progression to HGD/CA occurring in 2% of reactive, 4% of large cell and 29% of dysplasia. 214 patient biopsies were stained for p53. Strong nuclear staining for p53 was seen in 13/60 (22%) biopsies classified as reactive, 40/126 (32%) called large cell, and 16/28 (57%) called dysplasia. Of the patients who progressed to HGD/CA, 6/9 (67%) had strong p53 in their IND biopsy. We did not identify a specific medication associated with large cell change.

**Conclusions:** The large cell change described here can be worrisome for dysplasia, but we believe the data justifies designating this lesion as IND. Strong p53 expression in areas of large cell change may indicate increased risk for progression, but we do not advocate routine use immunohistochemistry at this time. There seems to be an association with PSC, but the explanation for that association is not known.

#### 705 Histology and Histopathology of Minor Papilla (Accessory Ampulla): An Analysis of 160 Cases with Emphasis on Features with Potential Impact on Daily Surgical Pathology Practice

D Ozdemir, B Saka, P Bagci, N Dursum, I Erbarut, S Bandopadhyay, L Ducato, M Reid, AB Farris, O Basturk, V Adsay. Emory University, Atlanta, GA; Wayne State University, Detroit, MI; Memorial Sloan-Kettering Cancer Center, New York, NY.

**Background:** The histologic features and pathologic conditions of the minor papilla (MP) are poorly characterized. The literature is mostly based on limited data or autopsy material.

**Design:** MP from 160 pancreatoduodenectomy specimens was analyzed.

**Results:** MP was identified as a mucosal-covered polyp localized approximately 1.8 cm (1.3-2.5 cm) proximal and anterior to major papilla. The surface mucosa was composed of foveolar-type epithelium (prone to be mistaken as "peptic duodenitis" or heterotopias in biopsies) with scattered goblet cells, admixed with biliary type ducts, embedded in small intestinal mucosa in variable patterns. The submucosa comprised lobules of ductules with variable morphology, some showing small round ductular conglomerates lined by cuboidal cells characteristic of peribiliary glands, whereas some were elongated and lined by columnar mucinous pyloric-type cells. Often lobular, surrounded by muscular coat, the glandular units created an adenomyoma-like picture. Columnar thin dark cells with stratification resembling low-grade dysplasia were seen in 12%. Neuroendocrine cells were commonly encountered and also formed micronests in the stroma resembling microcarcinoids, which was prominent in 10%. Pancreatic acinar tissue was seen in 48%, either well-preserved (31%) or atrophic (17%), 54% of which also contained islets of Langerhans. Rare paneth cells were identified in the ducts. PanIN type changes were seen in the ducts in 14 cases (11-PanIN1, 3-PanIN2); 8 occurred in patients with PDAC. In addition to secondary invasion by carcinoma (8 cases), which could colonize the ducts (4), MP ducts were also involved by pagetoid spread from remote carcinomas (4) and mimicking PanIN. The MP was also the primary site of a substantial pathology in 18 cases: Paraduodenal (groove) pancreatitis- 14, intraductal papillary mucinous neoplasm - 3, and invasive carcinoma - 1.

**Conclusions:** MP forms a mucosal nodule that is prone to be mistaken for a neoplastic polyp endoscopically. The surface epithelium typically contains foveolar cells with the differential of heterotopia or peptic duodenitis. Neuroendocrine cell micronodules are a part of MP histology. Often, the submucosal architecture is that of an adenomyoma. PanINs can be found in MP ducts, and pagetoid intramucosal spread from underlying carcinomas also occurs. A variety of pathologic conditions, especially paraduodenal pancreatitis, but also IPMNs and invasive carcinoma can arise from MP.

#### 706 Ancillary Stains Do Not Improve *Helicobacter pylori* Detection in Patients with Mild Disease, Even if *Campylobacter*-Like Organism (CLO) Tests Are Positive

NC Panarelli, DS Ross, OE Bernheim, ZB Landzberg, AN Schuetz, SE Jenkins, BR Landzberg, RK Yantiss. Weill Cornell Medical College, New York, NY.

**Background:** *H. pylori* detection in endoscopic biopsies is important because patients with chronic infection are at risk for gastric neoplasia. Ancillary stains may enhance *H. pylori* detection among patients with low bacterial load, but are increasingly ordered "up front" despite limited evidence supporting this practice. Most show sensitivities and specificities for *H. pylori* detection comparable to H&E stains when biopsies contain chronic gastritis and their utility in biopsies with absent, or scant, inflammation has not been fully evaluated. In this study, we assessed the value of immunohistochemistry, histochemical stains, and a fluorochromatic dye for *H. pylori* detection in infected patients with biopsies that showed minimal, or no, chronic gastritis.

**Design:** We identified 56 patients with biochemical evidence of *H. pylori* infection [*i.e.* positive CLO tests] and gastric biopsies initially diagnosed as negative for organisms based on evaluation of H&E stained slides. All cases were subjected to *H. pylori* immunostains, Giemsa and Warthin-Starry histochemical stains, and a rapid fluorochromatic dye (acidine orange). The H&E stained slides were re-evaluated for presence and severity of inflammation and *H. pylori* after interpretation of ancillary stains. Ten CLO test positive/biopsy positive and 10 CLO test negative/biopsy negative controls were stained in parallel.

**Results:** All 4 ancillary stains detected *H. pylori* in 100% of positive controls and were uniformly negative for *H. pylori* in negative controls. Ancillary stains were negative for *H. pylori* in 50 (89%) study cases that showed near-normal histology, but organisms were identified with all stains in the remaining 6 (11%), including the H&E stained sections that, in retrospect, showed chronic inactive gastritis in the antrum or fundus.

**Conclusions:** H&E stains adequately demonstrate *H. pylori* in most infected patients. Failure to detect bacteria usually reflects their absence in biopsy material, even in CLO test-positive patients, and ancillary tests do not substantially improve *H. pylori* detection, especially when biopsies contain uninfamed mucosae. However, scarce organisms may be overlooked, particularly when inflammation is mild. Thus, selective use of ancillary stains with a low threshold for ordering them is appropriate and cost-saving. Immunohistochemistry, Giemsa, Warthin-Starry, and acidine orange are similarly sensitive for bacteria detection. Acridine orange is a low-cost alternative that can be performed and interpreted in approximately 5 minutes, avoiding a delay in signout.

#### 707 New Nodal Classification Discriminates Better Survival Time Than That of the 7<sup>th</sup> AJCC Cancer Staging in Patients with Small Intestinal Adenocarcinoma (SIAC): An Analysis with the SEER Database

H-S Park, D Pak, HJ Kang, E Yu, H Cho, S-M Hong. University of Ulsan College of Medicine Asan Medical Center, Seoul, Korea; Korea University, Seoul, Korea.

**Background:** The lymph node (LN) classification of the 7<sup>th</sup> edition of the AJCC cancer staging of SIAC divided the previous N1 (LN metastasis) into the new N1 (1-3 LNs metastasis) and N2 ( $\geq 4$  LNs metastasis) without providing any information for changes.

**Design:** From the SEER database, 3,199 surgically resected SIACs were evaluated. To identify optimal cut-off points for N classification, recursive partitioning technique was coupled with the log-rank test.

**Results:** All cases were classified as 3 groups (G1, no LN metastasis; G2, 1-2 LNs metastasis; G3,  $\geq 3$  LNs metastasis) with the optimal cut-off points of 0 ( $p < 0.0001$ ) and 2 ( $p < 0.0001$ ). The survival difference among 3 groups ( $p < 0.0001$ ) and multiple comparisons for the log-rank test of each group (G1 and G2,  $p < 0.0001$ ; G2 and G3,  $p < 0.0001$ ) were statistically significant. By 7<sup>th</sup> edition of the AJCC cancer staging, a significant survival difference was also observed among 3N classifications comparison ( $p < 0.0001$ ) and between N0 and N1 ( $p < 0.0001$ ), but no significant survival difference was observed between N1 and N2 ( $p = 0.84$ ).

**Conclusions:** New grouping of LN classification showed better discrimination of survival time in SIAC patients than the current LN classification. Therefore, we propose that the current LN classification of SIAC should be changed into N0 (no LN metastasis), N1 (1-2 LNs metastasis), and N2 ( $\geq 3$  LNs metastasis).

#### 708 A Bayesian Analysis of the Ratio, T1N1/T1N0, as a Marker of Relative Aggressive Potential in Colon Cancer

A Patel, N Tabbara, AM Schwartz, DE Henson, K Batich. George Washington University Cancer Institute, Washington, DC; George Washington University, Washington, DC.

**Background:** Colo-rectal carcinomas may present in a minority of cases with nodal metastases despite limited invasion in the submucosa (pT1). Cancers that are T1N1 relative to T1N0 are associated with increases in recurrence and decreases in overall survival. We have compared our surgical pathology experience with 93 pT1 colon cancers, of which 11 were pT1N1, with the SEER registry to identify pathologic and epidemiologic markers for relative tumor aggressive behavior in the form of increased ratios of T1N1/T1N0.

**Design:** Data were retrieved using NCI's SEER Program from 1988-2003. Extent of disease (EOD) codes from 1988-2003 were used to assess T1 invasion and positive/negative lymph node involvement (N1 and N0 respectively). Tumors greater or equal to T2, N2, and M1 were excluded. A Bayesian analysis was used to calculate the odds ratio of T1N1 rates to T1N0 rates according to age, gender, race, histologic type, and location in the colon. Epidemiologic data were compared and amplified by pathologic data. Age groups were separated into  $< 45$  years, 45-60, and  $> 60$ . Five year relative survival rates were calculated for positive and negative lymph node involvement among age cohorts and different histologic types (adenocarc., mucinous adenocarc., and signet ring cell ca.).

**Results:** The overall ratio T1N1/T1N0 was 0.12 for pathology cases and 0.09 for SEER cases. Pathologic features that increase the ratio are high histologic grade, lymphatic



invasion, and near muscularis propria invasion. Epidemiologic factors that increase nodal positivity are younger ages (age <45 years, ratio 0.24; >60 years, ratio 0.1), signet ring cell component (ratio 0.35), racial group (Blacks, ratio 0.12; Whites, ratio 0.09), and gender (male, ratio 0.09; female, ratio 0.08).

**Conclusions:** The rate ratio is higher among men than women only in the <45 year cohort. The odds of nodal positivity given T1 are greater in blacks than whites in all age groups. The rate ratio reflects the histologic type of the adenocarcinoma and decreases among all age cohorts. Using the odds of each prognostic variable (age, gender, race, histologic type) a combined risk for nodal metastases can be assessed for colorectal cancer.

#### 709 Frozen Diagnostic Features and Pitfalls of Needle Core Biopsies for Hepatocellular Mass Lesions

*N Patel, R Patel, J Wang.* University of Cincinnati, Cincinnati, OH.

**Background:** Frozen evaluation of liver masses provides fast diagnosis for patients and allows surgeons to manage the lesions immediately. Frozen diagnosis is quick, convenient and valuable for clinicians and patients; however, may be challenging for pathologists, especially on needle core biopsies. At our institute, frozen diagnosis on needle core biopsies has been a daily practice for several years. We reviewed cases in recent years and summarized the features and pitfalls of diagnosis.

**Design:** Needle core biopsies from 196 patients with hepatocellular mass lesions, including 157 hepatocellular carcinoma (HCC), 26 focal nodular hyperplasia (FNH) and 13 hepatic adenoma (HA), were identified from the archives in University Hospital at University of Cincinnati between 2007 and 2011. All frozen sections and corresponding paraffin sections were reviewed and evaluated. In addition, the background liver and the quality of frozen section were assessed.

**Results:** Diagnosis of moderately or poorly differentiated HCC is usually easy to make. FNH may be mistakenly called "normal". Frozen diagnosis of HA and well-differentiated HCC in non-cirrhotic liver remains the most challenging. Absence of portal tracts, unpaired vessels and pseudoglandular formation may be seen on both HA and HCC. Presence of a trabecular pattern, cells with higher N/C ratio along with the presence of fibrotic bands are more indicative of HCC while fatty changes are more commonly seen in HA. Young females, a history of taking OCP, lack of fibrotic bands (direct transition from tumor to normal tissue), and similar cytology (if no steatosis present) to normal liver contribute to a diagnosis of HA. A well-differentiated hepatocellular neoplasm in a background of cirrhosis is almost always HCC. Hepatocytes surrounded by or adjacent to a fibrotic band lacking inflammation and ductules are important clues favoring HCC as compared to a cirrhotic nodule.

**Conclusions:** Accurate frozen diagnosis can be made for majority of cases using the features and suggestions mentioned above. Among the lesions evaluated, HA has the highest discordance. "Well-differentiated hepatocellular neoplasm" is suggested to be used in non-cirrhotic livers if a definitive diagnosis cannot be made. In addition, there is great utility when we request lesional tissue and normal tissue in order to compare morphology. Deeper levels are useful when the lesional fragments are small, at the edge and/or poor section quality. Additional cores are required if original biopsy is inadequate for a definitive diagnosis. Consulting an experienced liver pathologist is recommended whenever needed.

#### 710 Diagnostic Approach to Anal Condylomas Using p16, HPV L1 Capsid Protein and HPV Chromogenic In-Situ Hybridization

*DT Patil, B Yang.* Cleveland Clinic, Cleveland, OH.

**Background:** Most anal condylomas arise as a result of low-risk HPV infection and thus behave in an indolent manner. In comparison to cervical neoplasia, there is conflicting data whether documentation of HPV infection alone qualifies anal condylomas to be classified as dysplastic lesions. It is also unclear as to what percentage of condylomas harbor dysplasia. The current study was undertaken to systematically evaluate p16 and HPV L1 capsid protein expression and correlate these findings with HPV status. In addition, we also analyzed the utility of these markers in diagnosing dysplasia in a background of condyloma.

**Design:** A total of 43 anal condylomatous lesions were histologically reviewed and evaluated for nuclear HPV L1 staining, p16 staining (diffuse or patchy/focal), and low-risk (LR) and high-risk (HR) HPV status by chromogen in-situ hybridization. Dysplasia (low-grade or high-grade anal squamous intraepithelial neoplasia; LG-ASIN, HG-ASIN) was diagnosed only in the presence of HR-HPV or combined LR and HR-HPV reactivity.

**Results:** Of 43 lesions examined from 42 patients (27 men, 15 women), 29 (67%) were negative for dysplasia and 14 (32%) had coexisting squamous dysplasia, including 12 cases of LG-ASIN and 2 cases of HG-ASIN. Among 29 cases of condylomas without dysplasia, 24 (85%) harbored LR-HPV and none had HR-HPV infection. All 29 cases (100%) showed negative or patchy p16 immunostaining, while 19 cases (66%) expressed HPV L1 capsid protein. All 14 cases of condylomas with dysplasia had detectable HR-HPV either alone or with LR-HPV. p16 immunostaining showed focal/patchy staining pattern in condylomas with LG-ASIN and diffuse staining pattern in condylomas with HG-ASIN. HPV L1 expression was seen in all 12 cases of condyloma with LG-ASIN and one of two cases of condyloma with HG-ASIN.

**Conclusions:** Our study indicates that nearly a third of condylomas show dysplasia, supported by detectable HR-HPV and increased p16 immunoreactivity. Diffuse p16 staining pattern is a hallmark of malignant transformation from condyloma to HG-ASIN. In contrast, expression of HPV L1 capsid protein in condylomas with LG-ASIN suggests the episomal non-integrated stage of HPV infection in the low-grade anal squamous lesions.

#### 711 Duodenal Intraepithelial Lymphocytosis with Normal Villous Architecture: An Association with Inflammatory Bowel Disease?

*ER Patterson, E Shmidt, AS Oxtenko, TC Smyrk.* Mayo Clinic, Rochester, MN.

**Background:** Duodenal intraepithelial lymphocytosis (IEL) with normal villous architecture is a non-specific finding; celiac disease, *H. pylori* gastritis, small intestinal bacterial overgrowth and non-steroidal anti-inflammatory drug (NSAID) injury are among the top etiologic considerations. Some studies have implicated inflammatory bowel disease (IBD) as a cause of duodenal IEL, but current summaries list neither Crohn's disease (CD) nor ulcerative colitis (UC) among the differential diagnoses. Our aim was to study the association of duodenal IEL with normal villous architecture in patients with IBD.

**Design:** We reviewed the Mayo Clinic pathology database for all duodenal biopsies revealing IEL with normal villous architecture from 2000-2010. Among 1154 patients with this histologic finding, 74 had IBD. Duodenal biopsies and medical records were reviewed to confirm the IEL finding, establish the clinical diagnosis and document concurrent medications. In addition, we reviewed all upper gastrointestinal biopsies obtained from our study patients.

**Results:** Of the 74 patients with isolated duodenal IEL, 13 had UC, 58 had CD, and 3 had indeterminate colitis. At the time of index biopsy, 15 patients were on NSAIDs (11 CD; 4 UC), 4 had *H. pylori* gastritis, 3 had systemic autoimmune disease, and 1 had documented celiac disease. Gastric biopsies from patients with UC or indeterminate colitis (n = 7) were non-descript (i.e. chronic gastritis, reactive gastropathy). Among patients with CD, 10/34 had active chronic gastritis (4 positive for *H. pylori*) and 16/34 had focally enhanced gastritis (only 2 of these were on NSAIDs). Esophageal biopsy findings from 10 patients were non-specific, except for granulomatous esophagitis in one patient with CD.

**Conclusions:** Duodenal IEL with normal villous architecture can be seen in patients with IBD in the absence of other conditions associated with this histologic finding. While duodenal IEL and focally enhanced gastritis are each non-specific findings, the combination of the two is suggestive of CD. Duodenal IEL is less common in patients with UC, and does not appear to be associated with specific gastric pathology.

#### 712 p53 and Racemase Immunohistochemistry in the Evaluation of Glandular Atypia Versus Low Grade Dysplasia/Indefinite for Dysplasia in a Large Cohort of Patients with Barrett Esophagus

*R Petras, J Jeung, T Ly, W Katzin.* AmeriPath Institute of Gastrointestinal Pathology and Digestive Disease, Cleveland, OH.

**Background:** Distinguishing regenerative atypia from low-grade dysplasia/indefinite for dysplasia (LGD/Ind) in Barrett esophagus (BE) is difficult. We have been using p53 and racemase (rac) immunohistochemistry (IHC) in this setting. The purpose of this study is to review the utility of IHC in the evaluation of glandular atypia in patients with BE, correlating staining with outcome.

**Design:** We searched the archives 2009-11 for patients with BE and p53 and rac IHC. Patients with a history of esophageal high grade dysplasia (HGD) or carcinoma (Ca) were excluded. Patient age, gender, pathology report, available images, and a subset of histological slides were reviewed. Abnormal p53 IHC (p53+) was defined as nuclear staining in atypical glands exceeding the internal control basal squamous cells or the total absence of nuclear staining in glandular atypia. Cytoplasmic staining for rac in atypical glands was required for rac positivity (rac+). Follow up data were based on patients with subsequent esophageal biopsy specimens. Groups were compared using the Fisher exact test.

**Results:** The 224 patients (65 women) ranged in age from 33 to 94 years (mean = 64.1) and included 104 patients derived from the consultation practice of one of the authors (RP). Eighty-four patients were p53+ including 31 that were also rac+. Thirty five patients were rac+ with 4 showing rac+ alone. Twenty five additional patients showed rac staining in benign glands. This was interpreted as negative. Follow up was available in 60 patients (1-26 mos, mean = 9.2 mos) including 23 p53-/rac-, 21 p53+/rac-, 15 p53+/rac+ and 1 p53-/rac+. Seven (33.3%) p53+/rac- patients and 12 (80%) p53+/rac+ progressed to HGD/Ca versus 1 (4.3%) with negative IHC (p = 0.019 and < 0.0001 respectively). In contrast 18 of 23 (78.3%) negative IHC patients remained negative for dysplasia versus 5 (23.8%) in the p53+/rac- group and 0 in the p53+/rac+ group (p = 0.0007 and < 0.0001 respectively). Follow up LGD/Ind was observed in 9 (42.8%) of the p53+/rac- patients, 3 (20%) of the p53+/rac+, and in 4 (17.4%) with negative IHC. Follow up on the 1 p53-/rac+ patient showed no dysplasia.

**Conclusions:** We conclude that a) p53 and rac IHC may be useful in stratifying patients with BE and glandular atypia into high-risk versus low-risk groups for progression to HGD/Ca; b) the combination p53+/rac+ defines a very high risk group for progression; and c) HGD/Ca occurs infrequently in patients without IHC abnormalities.

#### 713 Microsatellite Instability in Gallbladder Carcinoma

*A Primiani, M Shahid, O Yilmaz, CR Ferrone, DR Borger, AJ Iafate, AX Zhu, V Deshpande.* Massachusetts General Hospital, Boston, MA.

**Background:** Gallbladder carcinoma (GBC) is a rare neoplasm in the United States. However, the genetic abnormalities involved in the pathogenesis of GBC remain unclear. Microsatellite instability (MSI) has been described in many carcinomas, including colorectal, but little is known about the role and significance of mismatch repair (MMR) genes in gallbladder carcinogenesis.

**Design:** Using tissue microarrays, 69 primary GBCs and 16 metastatic GBCs from 84 patients were evaluated for MSI by analyzing protein expression of MSH2, MSH6, MLH1, and PMS2 with immunohistochemistry (IHC). MSI was defined as loss of expression of any of the MMR proteins. Histologic features of the specimens [i.e. tumor grade, extracellular mucin, and tumor infiltrating lymphocytes (TILs)] and patient survival were compared between cases with and without MSI. The presence of

TILs was defined as  $\geq 5$  intraepithelial lymphocytes per 10 high power fields (HPF). MSI was also evaluated by IHC in 9 gallbladders with high-grade dysplasia (HGD) and in 7 with pyloric gland adenomas (PGA). Fluorescence in-situ hybridization (FISH) was performed to evaluate amplification of human epidermal growth factor receptor 2 (Her2). Genotyping for selected genes was performed using a multiplex PCR platform. Survival was compared with the Kaplan-Meier analysis.

**Results:** By IHC, MSI was present in specimens from 10 (12%) patients, none of which had a history of malignancies typically associated with Lynch syndrome. Concurrent loss of MSH2 and MSH6 or of MLH1 and PMS2 was seen in 5 cases and 2 cases, respectively. Isolated loss of MSH2 or PMS2 was seen in 3 cases and 1 case, respectively. The presence of TILs was the only histologic feature significantly associated with tumors with MSI ( $p=0.06$ ). The median survival of patients with tumors with and without MSI was 24 and 28 months, respectively ( $p=NS$ ). Of note, MSI was not present within areas of flat dysplasia or PGA. Her2 amplification was detected in 4 cases without MSI. Among the 18 cases evaluated by genetic sequencing, 4 mutations (PI3K, KRAS, NRAS, and TP53) were identified in cases, all without MSI.

	Her2 amplification	p4E-BP1*	TIL+**	Mutations
With MSI	0/10	3/10	7/10	0/3
Without MSI	4/69	51/72	17/72	4/15

\*  $p=0.006$ , \*\* $0.009$

**Conclusions:** MSI was identified in a substantial minority of GBC cases. There does not appear to be an association between MSI in gallbladder carcinoma and Lynch syndrome. The presence of TILs suggests MSI. Tumors with loss of MMR proteins may represent a genetically unique cohort of GBC.

#### 714 CK17: An Adjunctive Marker of Invasion in Squamous Neoplastic Lesions of the Anus

A Primiani, RM Nazarian, K Linskey, LA Doyle, LM Duncan, R Odze, LR Zukerberg. Massachusetts General Hospital, Boston, MA; Brigham and Woman's Hospital, Boston, MA.

**Background:** Anal squamous cell carcinoma (SCC) is a rare malignancy often preceded by anal intraepithelial neoplasia (AIN). Establishing a diagnosis of anal SCC may be challenging in small biopsy specimens, particularly if poorly oriented. In addition, anal gland involvement by AIN can simulate invasion. Cytokeratin 17 (CK17) is a basal/myoepithelial cell keratin induced in activated keratinocytes and associated with disease progression in SCCs of the uterine cervix, esophagus, and oral cavity. The aim of this study was to investigate the utility of CK17 in diagnosing invasion in anal squamous neoplastic lesions.

**Design:** Immunohistochemical staining for CK17 was evaluated in anal squamous neoplastic lesions [11 AIN, 11 invasive SCC, 8 invasive SCC with basaloid features (BSCC), and 2 invasive pure basaloid carcinoma] from 25 patients. In 6 patients, concurrent AIN and invasive lesions were evaluated. We defined BSCC as a SCC with keratinization and basaloid features (i.e. peripheral palisading, small cells without distinct intercellular bridges, and retraction artifact). Pure basaloid carcinoma was defined as a tumor with basaloid features but without typical features of SCC and keratinization, thereby resembling cutaneous basal cell carcinomas. The pattern of CK17 staining was scored as superficial/central (staining of the superficial 2/3 of epithelial cells), peripheral/rim (staining of the basal 1/3 of epithelial cells), diffuse, or absent.

**Results:** All cases (100%) of invasive SCC and BSCC stained positive for CK17 by immunohistochemistry. Eleven of 11 (100%) SCC cases showed diffuse staining. Of the BSCC cases, 6 of 8 (75%) showed diffuse staining and 2 of 8 (25%) showed peripheral staining. Both pure basaloid carcinomas stained negatively for CK17. Finally, 3 of 11 (27%) AIN (all grade 3) showed superficial CK17 staining; all other AIN lesions were negative. Of the 6 patients with concurrent AIN and invasive carcinoma, only 1 showed superficial CK17 staining in AIN, but all SCCs showed diffuse staining. Sixteen patients tested for HPV (by a variety of methods) were positive.

**Conclusions:** Peripheral and diffuse staining for CK17 is a useful marker of invasion in anal squamous neoplastic lesions, especially in difficult cases with early/superficial or blunt-type invasion. However, a potential pitfall in the utility of CK17 is that the pure basaloid variant of anal carcinoma is negative for CK17. This finding may suggest a different pathogenesis of pure basaloid anal carcinoma compared to the other SCC variants.

#### 715 The PI3K/mTOR Pathway in Gallbladder Carcinoma

A Primiani, M Shahid, O Yilmaz, CR Ferrone, DR Borger, AJ Iafrafe, AX Zhu, V Deshpande. Massachusetts General Hospital, Boston, MA.

**Background:** Gallbladder carcinoma (GBC) is a highly aggressive malignancy. Currently, no targeted therapies are available for GBC patients as the molecular pathogenesis remains unclear. Mutations in the phosphoinositide-3 kinase (PI3K) pathway and gene amplification of human epidermal growth factor receptor 2 (Her2) have been described in a subset of GBC cases, suggesting that the PI3K pathway plays an important role in gallbladder carcinogenesis.

**Design:** Activation of the PI3K pathway was evaluated by using tissue microarrays containing 70 primary GBCs and 15 metastatic GBCs from a total of 82 patients. In addition, 9 gallbladders with high-grade dysplasia (HGD); 1 from a patient with concurrent GBC were evaluated. Both primary and metastatic lesions from 5 patients were evaluated. Protein expression of pS6 and p4E-BP1 was analyzed by immunohistochemistry (IHC). Her2 amplification was evaluated by fluorescence in-situ hybridization (FISH) in 91 cases. Genotypic analysis of PI3K was performed in 23 cases by using a multiplex PCR platform. Survival was compared using the Kaplan-Meier analysis.

**Results:** Twenty-eight (35%) GBC were negative for p4E-BP1, while 52 (65%) showed nuclear and cytoplasmic reactivity. Sixteen (20%) GBC were negative for pS6, while 63 (80%) showed cytoplasmic reactivity for this marker. The mean survival of patients

with p4E-BP1-negative GBC and p4E-BP1-positive GBC was 42.8 months and 11.33 months, respectively (log rank test 0.06). There was no association between tumor stage and p4E-BP1 expression. The mean survival of patients with pS6-negative GBC and pS6-positive GBC was 35 months and 20 months, respectively. (log rank test 0.6). Her2 amplification was detected in specimens from 4 of 82 (5%) patients with GBC. One case with Her2 amplification was negative for both p4E-BP1 and pS6 while the rest showed both p4E-BP1 and pS6 expression. PI3K mutations were identified in 3 of 23 (13%) GBC cases, all of which were negative for Her2 amplification and pS6 expression. One of the PI3K-mutant cases showed expression of p4E-BP1. Her2 amplification was not seen in any HGD cases. Among the HGD cases, 8 (89%) and 7 (78%) showed expression for p4E-BP1 and pS6, respectively.

**Conclusions:** The presence of Her2 amplification (5% of GBCs) and PI3K mutations (13% of GBC), which were mutually exclusive genetic abnormalities in this cohort, and the shorter survival of tumors expressing activating markers of mTOR pathway suggest that the PI3K/mTOR pathway is a critical (and potentially additive) pathway in GBC tumorigenesis. We hypothesize that PI3K/mTOR inhibition may have significant therapeutic effect in these tumors.

#### 716 What's up My Sleeve? High Prevalence of Unexpected Histopathologic Findings in Vertical Sleeve Gastrectomy Specimens

PW Raess, M Baird-Howell, R Aggarwal, NN Williams, EE Furth. University of Pennsylvania, Philadelphia, PA.

**Background:** Laparoscopic vertical sleeve gastrectomy is used with increasing frequency as a therapeutic option for morbid obesity. Prior to the procedure, patients undergo a rigorous pre-operative evaluation including upper GI series. Thus, these patients are presumed to have no significant gastric pathology. We performed a retrospective review of primary vertical sleeve gastrectomy specimens to determine the prevalence of unexpected histologic findings in sleeve gastrectomy specimens.

**Design:** Retrospective review of all primary vertical sleeve gastrectomy specimens performed for morbid obesity at our institution from July 2008 until August 2012 ( $n = 250$ ). Review of pathologic diagnoses and gross descriptions was performed for all specimens. Select cases were re-reviewed to confirm diagnoses.

**Results:** The median age of patients undergoing laparoscopic sleeve gastrectomy in this cohort was 43 (range 19-80) and the female:male ratio was 2.2:1. A median of 5 blocks were submitted for histologic analysis. While the diagnosis of "stomach tissue with no specific pathologic change" was the most prevalent, it accounted for only 35.2% of all cases. The other diagnoses and their frequency were: lymphoid aggregates, 31.2%; chronic inflammation, 12%; and gastritis (including all subtypes), 12%. Importantly, *H. pylori* was identified via morphology or immunohistochemistry in 5.2% of our total study population and in 33.3% of cases of gastritis. Autoimmune gastritis, intestinal metaplasia, or necrotizing vasculitis was identified in an additional 3.2% of cases. During laparoscopy, the surgeons identified unanticipated neoplastic findings in 0.8% of cases ( $n = 2$ ; ovarian mucinous cystadenocarcinoma, gastric lipoma).

**Conclusions:** Unanticipated diagnoses are prevalent in vertical sleeve gastrectomy specimens performed for morbid obesity. Only 35.5% of cases had unremarkable histopathology, and approximately 15% of cases had diagnoses requiring additional clinical follow-up. As only oxyntic mucosa lines these specimens, patients with gastritis will require subsequent endoscopy and antral biopsy to evaluate for *H. pylori*. Lymphoid aggregates occur frequently but are of unknown significance. Pathologists should be aware of the high prevalence of potential diagnoses requiring clinical follow-up when examining vertical sleeve gastrectomy specimens.

#### 717 Benign Epithelial Downgrowth in Gastric Carcinoid Tumors: A Potential Diagnostic Pitfall

M Ramineni, MW Taggart, SC Abraham. MD Anderson Cancer Center, Houston, TX.

**Background:** We have observed downgrowth of benign gastric glands into gastric neuroendocrine tumors (NET), leading to potential misdiagnosis as composite exocrine-endocrine carcinoma. Entrapment of benign glands in Peutz-Jeghers polyps, colonic adenomas, and pancreatic endocrine tumors is a well-recognized mimic of invasive adenocarcinoma (in polyps) or composite exocrine-endocrine tumors (in the pancreas). However, to our knowledge there has been only one previous report of this phenomenon in the stomach (2 cases reported by Luong TV et al. *Virchows Arch.* 2008;452:169-74).

**Design:** We studied all available resected gastric NET with at least submucosal invasion from 2002-2012. Cases were jointly reviewed for the following features: NET type (sporadic, MEN1-associated, or autoimmune gastritis [AIG]-associated), presence/depth of epithelial downgrowth, epithelial type (intestinal, fundic, or pyloric), glandular atypia, and mitotic activity of entrapped glands. Lymph node metastases, when present, were also reviewed. Duodenal NET resected during the same period served as controls.

**Results:** There were 54 gastric NET in 29 patients (1-13 tumors/patient). 30 NET arose in AIG, 13 in MEN1, and 11 were sporadic. Epithelial downgrowth occurred in 26 (48%) gastric NET but only 2 of 36 (6%) duodenal NET ( $p<0.001$ ). Downgrowth was slightly more common in patients with hypergastrinemia (51% vs 36%) but this was not statistically significant. Evidence for the non-neoplastic nature of epithelial downgrowth included: 1) its confinement to submucosa regardless of the depth of NET invasion, and 2) lack of glandular cells in the metastatic lymph nodes of 4 patients with epithelial downgrowth. Specific morphologic features are shown below:

Epithelial Downgrowth	All Gastric NET (n=54)	Sporadic (n=11)	AIG (n=30)	MEN1 (n=13)
Present	26 (48%)	4 (36%)	13 (43%)	9 (69%)
Depth	Submucosa (25, 96%); muscularis mucosae (1, 4%)	Submucosa (4, 100%)	Submucosa (12, 92%); muscularis mucosae (1, 8%)	Submucosa (9, 100%)
Type	Pyloric (22, 85%); intestinal (14, 54%); fundic (7, 27%)	Pyloric (4, 100%); intestinal (2, 50%)	Pyloric (13, 100%); intestinal (9, 69%)	Fundic (7, 78%); pyloric (5, 56%); intestinal (3, 33%)
Mitoses	9 (35%)	1 (25%)	6 (46%)	2 (22%)
Atypia	5 (19%)	1 (25%)	3 (23%)	1 (11%)

**Conclusions:** Epithelial downgrowth is a common phenomenon, present in almost half of gastric NET but few duodenal NET. Its lack of deep growth and lack of nodal metastases attest to its benign nature. However, reactive atypia and/or mitotic activity within the entrapped glands in some cases raises the potential for misdiagnosis as composite exocrine-endocrine carcinoma.

### 718 Molecular and Immunohistochemical Features of Mixed Conventional Adenomatous-Serrated Colonic Polyps

GF Reis, S Kakar, JP Grenert. UCSF, San Francisco, CA.

**Background:** Colorectal cancer is the second leading cause of cancer-related death in the United States. The disease can be largely prevented by removal of adenomatous polyps. While common polyps show either conventional adenomatous or serrated features, mixed polyps with both patterns present a challenge for diagnosis and treatment. Not only is there ambiguity about how to classify mixed polyps but also uncertainty regarding their clinical significance. Better characterization of mixed polyps would permit more accurate follow-up of patients and further studies to determine their clinical importance. BRAF mutations are rare in conventional adenomas but common in serrated lesions. We tested distinct areas of conventional adenoma and serrated polyp in mixed polyps for BRAF mutations and MUC6 and Ki67 immunohistochemistry to determine whether the origin of these polyps was a conventional adenoma, a serrated polyp or a collision of both polyp types.

**Design:** The pathology records of three medical centers were searched for mixed polyps with conventional and serrated features. Cases were screened based on the final pathologic diagnosis and reviewed to confirm the present of a mixed morphological pattern. The two distinct morphological areas were microdissected and submitted for BRAF<sup>V600E</sup> mutational analysis. Immunohistochemistry for MUC6 and MIB-1 (Ki-67) was also performed.

**Results:** We identified 12 cases with mixed conventional adenoma and serrated polyp (traditional or sessile serrated adenoma (TSA, SSA), or hyperplastic polyp (HP)). BRAF<sup>V600E</sup> analysis demonstrated that both components of conventional/TSA polyps were negative for BRAF mutation (N=8) while both components of conventional/SSA polyps were positive (N=2). Mixed conventional/HP polyps were negative for BRAF<sup>V600E</sup> (N=2). Immunohistochemistry with MUC6 and MIB-1 demonstrated positivity for MUC6 only in SSA areas. MIB-1 positivity was largely basal in hyperplastic and SSA areas but more diffuse with apical enhancement in conventional and TSA areas.

**Conclusions:** The findings suggest that TSA features in conventional adenoma represent a metaplastic change in the conventional adenoma rather than dysplastic progression of a serrated precursor. The presence of BRAF<sup>V600E</sup> in both the conventional and serrated areas of conventional-SSA mixed polyps, along with MUC6 positivity in the SSA component, suggest dysplastic progression of SSA, which some studies have shown may have a more rapid progression to carcinoma than conventional adenoma. Our study demonstrates the utility of BRAF mutational analysis in the diagnosis of challenging adenomatous polyps with mixed pattern.

### 719 Pseudo-invasion and Dysplasia in Peutz-Jeghers Hamartomatous Polyps

MP Riley, Z Yang. Penn State Milton S. Hershey Medical Center, Hershey, PA.

**Background:** Peutz-Jeghers syndrome (PJS) is an autosomal dominant genetic disorder characterized by the development of hamartomatous polyps in the gastrointestinal tract (GI) and mucocutaneous pigmentation. It is associated with an increased risk of GI and non-GI malignancies. However, there is still controversy about the magnitude of risk of GI carcinoma. Pseudo-invasion, or misplacement of the epithelium, is known to occur in PJS polyps and may closely mimic adenocarcinoma, which may lead to overdiagnosis of dysplasia and carcinoma.

**Design:** Sixty-six hamartomatous polyps from 17 PJS patients were retrospectively reviewed, which included 8 (12%) from stomach, 44 (67%) from small intestine, and 14 (21%) from large intestine. The clinicopathological features of each polyp including dysplasia and pseudo-invasion were assessed. Immunohistochemical staining for Ki67 and p53 was performed on polyps that were suspicious for dysplasia.

**Results:** Twenty-three polyps (35%) from 13 patients (76%) showed pseudo-invasion, and all of them were in the small intestine. Low-grade dysplasia or indefinite for dysplasia was diagnosed in 3 of the 23 polyps (13%) based on routine H&E stain; however, immunostain for Ki-67 and p53 showed a pattern indistinguishable from normal epithelium. No GI carcinoma was identified in any of the patients. In 3 of the 17 patients (18%) with pseudo-invasion, the clinical presentation was suspicious of malignancies thus the polyps were surgically resected. In each case, there was extensive pseudo-invasion into the serosa, without any evidence of dysplasia or carcinoma. Postsurgical follow-up (1 -12 months) revealed no complications or carcinoma.

**Conclusions:** Although PJS is traditionally thought to have an increased risk of GI malignancy, our data suggests that true dysplasia or carcinoma is distinctly rare in PJS polyp. However, deep pseudo-invasion is more common which may have led to an overdiagnosis of dysplasia and carcinoma.

### 720 Expression Analysis of AKT/mTOR Signaling Pathway in Primary Tumors and Cell Lines Derived from Gallbladder Cancer

JC Roa, P Leal, P Garcia, O Tapia, H Weber. Pontificia Universidad Catolica, Santiago, Chile; Universidad de La Frontera, Temuco, Chile.

**Background:** Gallbladder carcinoma (GBC) is a highly fatal disease with poor prognosis. The mammalian target of rapamycin (mTOR) is a serine/threonine kinase that plays a central role in cell growth and homeostasis. Its regulation is frequently altered in various tumors and is an attractive target for cancer therapy; however, its status in GBC remains unclear.

**Objectives:** To analyze the expression of mTOR signaling pathway in primary tumors and cell lines derived from gallbladder cancer and to evaluate the in vitro effect of mTOR inhibitors on cell viability and migration.

**Design:** The expression of five components of AKT/mTOR signaling pathway (phospho-mTOR and total protein of mTOR, AKT, 4EBP1, P70S6K and eIF4e) was examined by immunohistochemistry in tissue microarrays (TMAs) containing 128 advanced GBC and 99 cases of chronic cholecystitis (CC). Association between phospho-mTOR expression and clinical variables was evaluated. We also examined the activation of the AKT/mTOR pathway based on phospho-AKT, phospho-p70S6K, phospho-4EBP1 and phospho-eIF4e expression in eight GBC cell lines by Western blot. Finally, the effect of four mTOR inhibitors (LY294002, Rapamycin, Everolimus and AZD8055) on cell viability and in vitro migration was assessed by MTS and Transwell chamber assays. Statistical analysis was performed using a significance level  $P < 0.05$ .

**Results:** We observed a significant IHC overexpression of AKT-mTOR pathway component in primary tumor samples, compared to CC.

Immunohistochemical expression of AKT-mTOR pathway components in GBC and Chronic Cholecystitis (CC).

	CC %	GBC %
mTOR	44.4	63.7
AKT	48.6	82.4
4EBP1	13.1	53.9
eIF4E	4.9	89.3
P70S6K	22.9	68.1
p-mTOR	24	64.1

Survival analysis indicated that GBC patients whose tumors overexpressed phospho-mTOR had a poorer prognosis ( $P = 0.02$ ). TGBC2-TKB cell line showed a constitutive activation of the AKT/mTOR pathway (Western Blot Assay) and the treatment with different mTOR inhibitors significantly reduced its viability and migration capacity ( $p < 0.05$ ).

**Conclusions:** The AKT/mTOR signaling pathway is abnormally expressed in GBC which suggest that mTOR could be a potential therapeutic target for the treatment of advanced GBC. In addition, phospho-mTOR IHC expression characterizes a subset of GBC cancers that might optimally benefit with anti-mTOR therapies.

FONDECYT Project 1090171 and DIUFRO project DI11-0039.

### 721 SATB2 Double-Staining: Significant Improvement in Specificity for Colonic Adenocarcinoma

J Rock, R Roth, A Lehman, W Marsh, WL Frankel. Ohio State University Wexner Medical Center, Columbus, OH.

**Background:** The high prevalence of colonic adenocarcinoma (Ad) in the US has made the distinction of metastatic colon Ad from other primaries a commonly encountered clinical problem. The immunohistochemical (IHC) stains CDX2, CK20 and Villin are commonly used for this distinction with well-established sensitivities and specificities for each. Small biopsies or cytologic specimens limit the number of stains that may be attempted. The transcription factor SATB2 has been proposed as a potentially sensitive and specific marker for colonic Ad. To define the utility of SATB2 as a nuclear marker in double-stains (DS), we evaluated its sensitivity and specificity compared to CDX2 when combined with cytoplasmic stains CK20 and Villin.

**Design:** Tissue microarrays with 1 mm cores were made from right-sided colon Ad (222), breast Ad (45), hepatocellular carcinoma (67), lung Ad (32), ovarian Ad (18), neuroendocrine carcinoma (32), pancreatic Ad (40), prostate Ad (45) and gastric Ad (78). IHC DS were performed pairing CDX2 and SATB2 each with CK20 and Villin. Staining was graded as positive or negative, with a 5% threshold. DS were considered positive only when both nuclear and cytoplasmic staining was  $>5\%$ . Sensitivity and specificity were calculated and compared using McNemar's test for paired comparisons.

**Results:**

Stain Performance for Colonic Ad vs. Other Primaries

Stain	Sensitivity	Specificity	Overall % Correct
CDX2	0.99 (0.97, 1.00)	0.85 (0.80, 0.88)	0.90 (0.87, 0.92)
SATB2	0.95 (0.92, 0.98)	0.88 (0.84, 0.91)	0.91 (0.88, 0.93)
Villin	0.97 (0.94, 0.99)	0.56 (0.51, 0.61)	0.71 (0.67, 0.75)
CK20	0.93 (0.89, 0.96)	0.79 (0.74, 0.83)	0.84 (0.81, 0.87)
CDX2 + CK20	0.92 (0.88, 0.95)	0.93 (0.89, 0.95)	0.92 (0.90, 0.95)
CDX2 + Villin	0.96 (0.93, 0.99)	0.88 (0.84, 0.91)	0.91 (0.90, 0.93)
SATB2 + CK20	0.90 (0.86, 0.94)	0.98 (0.96, 0.99)	0.95 (0.93, 0.96)
SATB2 + Villin	0.93 (0.89, 0.96)	0.97 (0.94, 0.98)	0.95 (0.93, 0.97)

(95% CI)

CDX2 and SATB2 performed similarly and were the best overall single stains with CDX2 more sensitive and SATB2 more specific. DS significantly improved specificity over any single counterpart. While DS with CK20 and Villin varied in sensitivity and specificity, there was little difference in overall % correctness. DS with SATB2 showed similar sensitivities to those with CDX2, but statistically improved specificity.

**Conclusions:** SATB2 shows excellent sensitivity and specificity for colon Ad. When utilized in DS, SATB2 and CK20 are the most specific combination for colon Ad. The efficacy of SATB2 in DS makes it a valuable addition to existing IHC panels for identification of colon Ad particularly in evaluation of small biopsies.

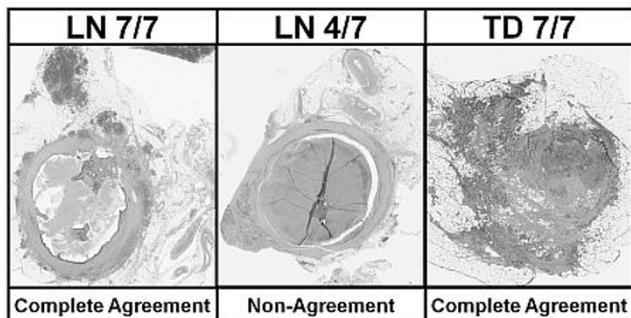
**722 Debating Deposits: An Inter-Observer Variability Study of Lymph Nodes and Pericolonic Tumor Deposits in Colorectal Adenocarcinoma**

*JB Rock, MK Washington, V Adsay, J Greenson, E Montgomery, M Robert, R Yantiss, A Lehman, WL Frankel.* Ohio State University, Columbus, OH; Vanderbilt University, Nashville, TN; Emory University, Atlanta, GA; University of Michigan, Ann Arbor, MI; Johns Hopkins University, Baltimore, MD; Yale University, New Haven, CT; Weill Cornell Medical College, New York, NY.

**Background:** The AJCC 7<sup>th</sup> Ed defines pericolonic tumor deposits (TD) as discrete foci of tumor in pericolic fat showing no evidence of residual lymph node (LN). This definition relies on subjective features rather than size (5<sup>th</sup> Ed) or shape (6<sup>th</sup> Ed) and includes the new category N1c. For staging data to be meaningful, pathologists must agree on features used to distinguish positive LN from TD. We evaluated interobserver variability and developed a list of features helpful in this distinction.

**Design:** Tumor metastases (25) from right-sided colorectal adenocarcinomas were selected where the distinction between a positive LN and a TD was challenging. Virtual slides were reviewed by 7 pathologists with an interest in GI pathology. A list of features thought helpful in distinguishing LN metastases was compiled and ranked for usefulness by all. Each metastasis was diagnosed as a positive LN or TD. For each case called a positive LN, features used in the distinction were listed.

**Results:** A "complete agreement" was found in 11 of 25 metastases (44%), of which 5 were deemed a positive LN and 6 a TD with a kappa statistic of 0.4 and 95% CI of (0.28, 0.67). In the remaining 14 cases, concurrence rates were 6/7 (4 cases), 5/7 (6 cases) and 4/7 ("non-agreement" 4 cases).



The top ranked discriminating feature was round shape followed by peripheral lymphocyte rim, peripheral lymphoid follicles, a subcapsular sinus, LN in surrounding fat and thick capsule. In practice, round shape was also the most utilized (89%) when diagnosing the 25 metastases followed by thick capsule, peripheral lymphoid follicles, peripheral lymphocyte rim and size >3 mm (each >60%).

**Conclusions:** Statistically significant agreement between evaluators was found, but some inconsistency remains. When the distinction between a positive LN and TD is difficult, we suggest using round shape, lymphoid follicles, peripheral lymphocyte rim, LN in surrounding fat, subcapsular sinus and thick capsule to aid in making a diagnosis.

**723 Calretinin Immunohistochemistry Versus Acetylcholinesterase Histochemistry in Rectal Biopsies for the Diagnosis of Hirschsprung's Disease**

*M Rodrigues, PL Lourencao, SA Terra, EV Ortolan, BK Takegawa.* Botucatu Medical School, University of São Paulo State, Unesp, Botucatu, Sao Paulo, Brazil.

**Background:** The pathological evaluation of rectal biopsies has been the gold standard for the diagnosis of Hirschsprung's disease (HSCR) and Calretinin has been described as an ancillary tool in the diagnosis of HSCR.

**Design:** We aimed to investigate prospectively, the diagnostic accuracy and applicability of Calretinin as compared with Acetylcholinesterase (Ache) histochemistry, in the evaluation of rectal biopsies from patients under investigation for HSCR. A total of 83 patients were investigated with anorectal manometry and/or barium enema as screening tests. Of them, 43 patients were submitted to rectal biopsies. Frozen tissue samples were used for Ache histochemistry and paraffin-embedded sections were stained with Hematoxylin and Eosin (H&E) and Calretinin immunohistochemistry.

**Results:** The analysis of serial H&E stained slides did not reveal the presence of ganglion cells in 24/43 (55.8%) cases. A positive reaction for increased Ache activity, which was considered diagnostic for HSCR, was demonstrated in 13/43 (30.2%) cases, in nerve fibers strongly stained in dark brown in the muscularis mucosa and lamina propria. The disagreement between H&E and Ache occurred in 11 cases, in which the negative results for H&E were due to the absence of ganglion cells in tissue samples. Absence of immunoreactivity for Calretinin was found in 14/43 (32.6%) cases. Typical positive staining for Calretinin in non-HSCR patients was observed in 29 cases (67.4%) and consisted of granular staining in ganglion cells and intrinsic nerve fibers in the lamina propria or muscularis mucosa. The disagreement between Ache and Calretinin methods occurred in only one case, in which the negative result for Calretinin was initially performed due to the absence of ganglion cells in the samples. The results on Calretinin were in good agreement with Ache histochemistry according to the Kappa index (0.946 p< 0.001) and presented significantly higher specificity (96.7 x 63.3 p<0.002) and accuracy (97.6 x 74.4 p<0.003) when compared with H&E. The final diagnosis of Hirschsprung's disease was confirmed in 13/43 (30.2%) patients who were submitted to surgical treatment. They were 9 boys (69.2%) and 4 girls (30.8%) and in 4 cases (30.7%) the diagnosis was performed during the neonatal period.

**Conclusions:** These results indicate that Calretinin is an accurate and less complex diagnostic tool than Acetylcholinesterase for the diagnosis of Hirschsprung's disease in rectal biopsies.

**724 Biomarkers in a Large Cohort of Gastric and GEJ Adenocarcinomas – Prevalence and Spectrum of Expression**

*S Rost, D Dunlap, S Chan, S Sa, S Mocci, H Koeppen.* Genentech, South San Francisco, CA.

**Background:** Gastric cancer is one of the most common causes of worldwide cancer-related death. The identification of biomarkers specific to gastric cancer is critical for the development of targeted therapies. Trastuzumab has been approved for the treatment of Her2-positive metastatic gastric cancer but there is no targeted therapy for patients with HER2-negative disease. An anti-Met antibody, onartuzumab, is being evaluated in patients with HER2-negative gastric cancer. We analyzed gastric and gastro-esophageal adenocarcinomas from 161 patients with various ethnic backgrounds for the expression of Her2, Met, PTEN, HGF, p53, ARID1A and FGFR2 to determine prevalence and potential overlap of these markers as well as differences in the expression pattern between different ethnic groups.

**Design:** Immunohistochemistry to determine expression of Her2, Met, PTEN, p53, beta-catenin and ARID1A was performed on paraffin sections. Expression of FGFR2 and HGF was evaluated by in-situ hybridization. Her2 expression was scored according to published guidelines. Expression of Met was scored based on intensity (negative to strong) and percent tumor cells positive with a 50% cutoff. PTEN was scored using an H-score with a range from 0 to 400; absence and decreased levels of PTEN were defined as H-scores of 0 and ≤ 100, respectively. Stains for p53 and ARID1A were evaluated for presence or absence of nuclear staining, respectively. ISH for FGFR2 and HGF was scored based on peak signal intensity in any area of the tumor.

**Results:** Her2-positive (IHC 3+) tumors accounted for 5% of all cases. Weak, moderate and strong expression of Met and FGFR2 were seen in 61, 7 and 2 and 22, 10 and 1% of cases, respectively; expression of these markers correlated with intestinal-type morphology (100% for Her2, 70% for Met and 66% for FGFR2). None of the Her2-positive cases showed strong expression of Met or FGFR2; two cases showed moderate expression of Met, one of which was also positive for FGFR2. Loss of or decreased PTEN were observed in 1% and 18% of cases, respectively. HGF RNA was observed in 23% (1+), 11% (2+) and 2% (3+) cases; expression was seen in stromal and/or malignant cells. 27% of cases showed staining for p53, loss of ARID1A staining was present in 10% of cases.

**Conclusions:** These data may guide the development of targeted therapies for gastric cancer. A significant proportion of Her2-negative patients express Met enabling clinical trials of Met inhibitors in this patient population. A detailed statistical analysis with respect to overlap of biomarkers and correlation with ethnicity will be described.

**725 PIK3CA Activating Mutation in Colorectal Carcinoma: A Stratified Analysis in a Prospective Cohort**

*C Rosty, JP Young, MD Walsh, M Clendenning, MA Jenkins, AK Win, MC Southey, S Parry, JL Hopper, GG Giles, E Williamson, DR English, DD Buchanan.* Queensland Institute of Medical Research, Brisbane, Australia; University of Queensland, Brisbane, Australia; Envoi Pathology, Brisbane, Australia; Sullivian Nicolaidis Pathology, Brisbane, Australia; University of Melbourne, Melbourne, Australia; Middlemore Hospital, Auckland, New Zealand; Cancer Council Victoria, Melbourne, Australia.

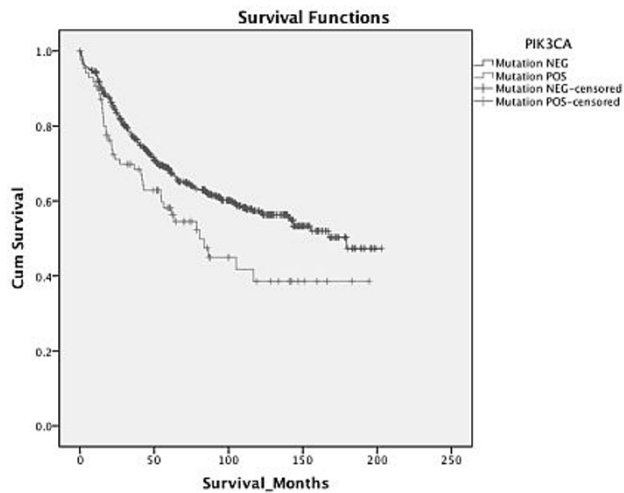
**Background:** Colorectal carcinomas (CRC) with somatic *PIK3CA* mutations comprise 10-15% of all CRCs. The aim of this study was to examine the characteristics of *PIK3CA*-mutated CRC in a large well-characterized prospective population-based cohort to determine how these mutations relate to pathology phenotype, clinical outcome, and to other molecular alterations.

**Design:** *PIK3CA* mutation testing was carried out on 780 incident CRCs from the Melbourne Collaborative Cohort Study (mean age at diagnosis: 68 years). MGMT status was assessed using both immunohistochemistry and methylLight techniques. Microsatellite instability phenotype, *KRAS* and *BRAF* V600E mutation status were derived from previous reports. Comparisons were performed using two-sided chi-square tests. Survival curves were plotted using the Kaplan-Meier method and a multivariate Cox regression analysis was performed to determine hazard ratio (HR).

**Results:** *PIK3CA* mutation was present in 107/780 (14%) of CRCs, and these showed significant differences in the following features when compared to CRC lacking a *PIK3CA* mutation:

	PIK3CA-mutated CRC n = 107	PIK3CA-wildtype CRC n = 673	P Value
Proximal Colonic Location	58/105 (55%)	222/418 (35%)	<0.001
KRAS Mutation	50/107 (47%)	169/673 (25%)	<0.001
Minor Mucinous Component	43/94 (46%)	142/602 (24%)	<0.001
Altered MGMT expression	35/97 (36%)	125/631 (20%)	0.001
CIMP-High	22/101 (22%)	75/646 (12%)	0.004

There was no significant overlap with *BRAF* V600E mutation (P=0.52). Patients with *PIK3CA*-mutated CRC had significantly poorer overall survival than those with *PIK3CA* wild-type CRC when *BRAF*-mutated CRC were excluded from the analysis (P=0.015; Log Rank Test; HR=1.51 95% CI 1.08 – 2.12).



**Conclusions:** *PIK3CA*-mutated CRCs are more likely to be located in the proximal colon and to demonstrate CIMP-high and *KRAS* mutations but not *BRAF* mutation. Among patients with wild-type *BRAF* CRC, *PIK3CA* mutation was associated with overall poorer survival.

#### 726 Serrated Pathway Colorectal Carcinoma without Microsatellite Instability Demonstrates Aggressive Features and Is Associated with Poor Overall Survival

C Rosty, JP Young, MD Walsh, R Walters, MA Jenkins, AK Win, MC Southey, S Parry, JL Hopper, GG Giles, DR English, DD Buchanan. Queensland Institute of Medical Research, Brisbane, Australia; University of Queensland, Brisbane, Australia; Envoi Pathology, Brisbane, Australia; Sullivan Nicolaidis Pathology, Brisbane, Australia; University of Melbourne, Melbourne, Australia; Middlemore Hospital, Auckland, Australia; Cancer Council Victoria, Melbourne, Australia.

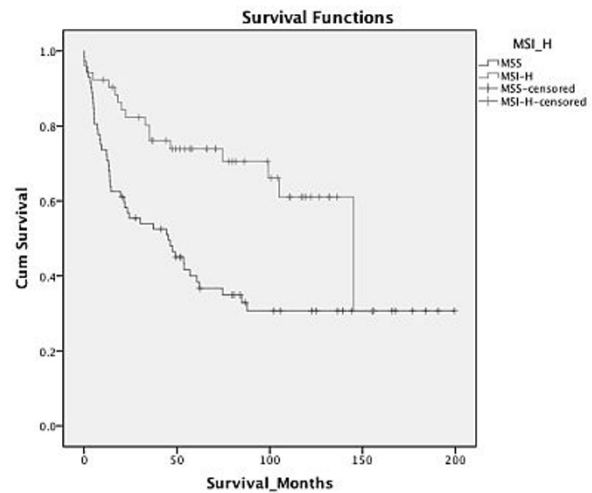
**Background:** The serrated pathway of colorectal carcinoma (CRC) is primarily defined by *BRAF* mutation. Within the *BRAF*-mutated subset of CRC, the microsatellite instability (MSI) phenotype divides the tumours into MSI-H CRC and microsatellite stable (MSS) CRC. MSS *BRAF*-mutated CRC are reported to be associated with poor prognosis.

**Design:** We analyzed the available data regarding clinical, pathologic and molecular features of *BRAF*-mutated CRCs from the Melbourne Collaborative Cohort Study. The features of *BRAF*-mutated MSS CRCs were compared with *BRAF*-mutated MSI-H CRCs using two-sided chi-square tests or t-test. Survival curves were plotted using the Kaplan-Meier method and a multivariate Cox regression analysis was performed to determine hazard ratio (HR).

**Results:** There were 127/765 CRCs with *BRAF* mutation (17% of all CRCs). Of those, 74 (56%) were MSS. Compared to MSI-H *BRAF*-mutated CRC, MSS *BRAF*-mutated CRC were significantly different for the following features:

	<i>BRAF</i> -mutated MSS CRC n = 74	<i>BRAF</i> -mutated MSI-H CRC n = 53	P value
Mean age at diagnosis (years)	68.0	72.7	0.001
Distal colonic location	39/72 (54%)	5/50 (10%)	<0.001
Mucinous differentiation	4/67 (6%)	14/37 (30%)	<0.001
Tumor budding	30/57 (53%)	8/45 (18%)	<0.001
Venous invasion	17/67 (25%)	3/49 (6%)	0.007
Metastatic lymph nodes	45/66 (68%)	16/51 (31%)	<0.001
P53 overexpression	41/69 (59%)	9/45 (20%)	<0.001
CIMP phenotype	25/68 (37%)	37/48 (77%)	<0.001

Patients with *BRAF*-mutated MSS CRC had a significantly poorer overall survival compared with patients with *BRAF*-mutated MSI CRC (HR = 2.5; 95%CI 1.44 - 4.40; P = 0.001).



**Conclusions:** *BRAF*-mutated MSS CRCs arise predominantly in the distal colon and show aggressive pathologic features, frequent p53 alteration and poor overall survival. This subtype of CRC, and potentially the polyps from which they develop, should be identified by pathologists with more readily available methods to routinely detect *BRAF* mutation.

#### 727 Lymph Node Yield and MRI Correlation of Pathological Lymph Nodes after Neoadjuvant Chemoradiation in Rectal Cancer: The Importance of Lymph Node Size

P Roy, A Chandra, M Kar, I Mallick, MK Roy, S Banerjee, D Midha, I Arun, SS Kurian. Tata Medical Center, Kolkata, West Bengal, India.

**Background:** Neoadjuvant chemoradiation (NACRT) is the current standard of care before surgery for rectal adenocarcinoma. Lymph node yield is reported to be poorer after NACRT and magnetic resonance imaging (MRI) is recognized to have only limited accuracy in identifying metastatic nodes. We aimed to perform a detailed analysis of the importance of the size of metastatic nodes in determining yield and identification on MRI.

**Design:** Pathological data from 21 patients who underwent concurrent radiotherapy and oral capecitabine followed by anterior or abdominoperineal resection were analyzed. The lymph node yield, size and involvement of each dissected node was documented. A radiologist blinded to the pathology was asked to scrutinize the post-NACRT MRI to detect metastatic nodes based on characteristics on T2 weighted and diffusion weighted images.

**Results:** A total of 310 nodes were dissected from 21 patients, with an average yield of 14.8 nodes / patient. Metastatic nodes (ypN+) were identified in 8/21 patients with a total of 32 positive nodes. The average size of dissected nodes was 2.8mm, with 286/310 (92%) nodes <=5mm and 263/310 (85%) nodes <=3mm. The average size of the nodes showing metastasis was 5 mm, and 21/32 (66%) nodes <=5 mm and 14/32 (44%) nodes <=3mm. The smallest metastatic node was 1mm in size. None of the positive nodes were >1cm in size. In our sample, MRI as a preoperative indicator of node positivity had only limited value with a sensitivity of 75%; specificity of 54%; positive predictive value of 50% and negative predictive value of 77%. In 2/2 patients with a false negative MRI all the pathological nodes were <= 5 mm. In 5/6 patients with false positive MRI reports there were at least 2 lymph nodes that were >4mm in size. [underline]

**Conclusions:** Lymph node yield after NACRT is not necessarily low if careful nodal examination is performed. Metastatic nodes after NACRT are often small in size and unless adequate sections of adipose tissue are submitted and diligently scrutinized, the identification of pathological nodes may be compromised. MRI is of limited value in predicting pathological nodal status after NACRT, and the lack of size correlation is likely to be an important cause.

#### 728 Duodenal Carcinomas of Non-Ampullary Origin Are Significantly More Aggressive Than Ampullary Carcinomas

B Saka, P Bagci, A Krasinskas, O Basturk, T Tajiri, N Ohike, GE Kim, S Balci, K-T Jang, S Bandyopadhyay, D Kooby, SK Maithel, J Sarmiento, C Staley, D Ozdemir, SY Kong, AB Farris, V Adsay. Emory University, Atlanta, GA; UPMC, Pittsburgh, PA; Memorial Sloan-Kettering Cancer Center, New York, NY; TUHH, Tokyo, Japan; SU, Tokyo, Japan; UCSF, San Francisco, CA; SMC, Seoul, Korea; Wayne State University, Detroit, MI.

**Background:** The information on duodenal carcinomas is fairly limited and those arising from non-ampullary duodenum are largely uncharacterized.

**Design:** 43 resected duodenal carcinomas that spared the ampulla were identified, and their clinicopathologic characteristics were contrasted with those of 298 ampullary and 295 pancreatic ca.

**Results:** See Table for clinicopathologic comparison. Other findings: Many showed ulcerating-plaque like growth; only 15 had identifiable adenoma component. Predominant pattern was pancreatobiliary (PB) in 22, intestinal-16, poorly diff-4 (2-medullary, 1-hepatoid), and mucinous-1. Other patterns encountered were squamous-4, oncocytic-1, and foveolar gland like-1. 3 had foci of distinctive and previously uncharacterized microcystic pattern.

Characteristics†	Ampullary (n = 298)	Pancreas (n = 295)	Duodenal (n = 43)	p-value‡
Age (±SD)	65.0 (11.8)	63.7 (11.2)	62.3 (14.7)	0.1995
<b>Gender</b>				
Female	120 (40%)	156 (53%)	19 (44%)	0.0073
Male	178 (60%)	138 (47%)	24 (56%)	
Overall Size, cm (range)	2.6 (0.3 - 8.0)	3.3 (0.7 - 11.0)	3.7 (0.1 - 8.0)	<0.0001
Size of Invasion, cm (range)	1.9 (0.2 - 6.0)	3.2 (0.7 - 11.0)	3.1 (0.1 - 8.0)	<0.0001
<1 cm	52 (18%)	1 (0.4%)	5 (12%)	<0.0001
≥1 cm	246 (83%)	272 (100%)	38 (88%)	
<b>LN Status</b>				
LN Positive	119 (42%)	177 (65%)	22 (58%)	<0.0001
LN Negative	163 (58%)	95 (35%)	16 (42%)	
<b>Margin Positivity Rate</b>				
R0	282 (96%)	175 (66%)	25 (96%)	<0.0001
R1	13 (4%)	89 (34%)	1 (4%)	
R2	0	2 (0.7%)	0	
Perineural Invasion	79 (27%)	158 (87%)	16 (40%)	<0.0001
Vascular Invasion	187 (63%)	84 (55%)	31 (76%)	0.0429
<b>Tumor Stage</b>				
T1	70 (24%)	13 (8%)	6 (14%)	<0.0001
T2	105 (36%)	66 (39%)	5 (12%)	
T3	98 (33%)	85 (50%)	21 (49%)	
T4	22 (8%)	5 (3%)	11 (26%)	
<b>Survival Rates</b>				
1-year	81%	53%	65%	<0.0001
3-year	57%	21%	45%	
5-year	42%	12%	25%	

†Subjects with missing values were excluded for each characteristic variable. ‡Based on t-test for continuous variables, Fisher's chi square test or exact test (if n<5) for categorical variables, and log-rank test for survival rates.

**Conclusions:** Non-ampullary duodenal cancers present with more advanced tumors than ampullary (larger overall and inv size, and higher incidence of LN mets, R1 rate, perineural-vascular inv), and have a significantly more aggressive clinical outcome. Morphologic patterns differ from lower-GI cancers with common plaque-like growth, predominant PB histology, and unusual patterns including a distinctive microcystic type and others.

**729 Lichenoid Esophagitis; Clinical Overlap with Established Esophageal Lichen Planus**

SN Salaria, MW Cruise, LD Wood, EA Montgomery. Johns Hopkins School of Medicine, Baltimore, MD.

**Background:** Lichen planus (LP) affects mucocutaneous surfaces, and is characterized by intra-epithelial and lamina propria lymphocytosis and squamous cell apoptosis (Civatte bodies). LP esophagitis (LPE) is under recognized; concurrent cutaneous disease is present in some patients, but LPE alone and/or with oral lesions is more common.

**Design:** We diagnose patients with characteristic pathologic findings of LP esophagitis and known correlation with skin disease or immunofluorescence (IF) results as LPE but use descriptive terminology ("lichenoid esophagitis pattern"/LEP) when confirmation is unavailable. We reviewed clinicopathologic features of cases diagnosed at our institution with LPE or LEP (1/2000 - 8/2012). Immunostains (CD3, CD20, FOXP3) were performed on biopsies from patients with 1) proven LPE, 2) proven LPE and oral LP 3) LPE plus known cutaneous LP, 4) LPE and nonspecific skin changes, and 5) patients with LEP on biopsy, with negative LPE IF studies.

**Results:** There were 88 specimens with LPE or LEP from 65 patients. Most (79%) patients were female. Seventeen (26%) patients had LPE confirmed by IF. Five (8%) patients had both esophageal (1 with IF) and skin LP.

Clinicopathologic Features of Lichen Planus Esophagitis (LPE) Versus Lichenoid Esophagitis Pattern (LEP)

	Established LPE % (N)	LEP % (N)	p
Number of patients	32% (21)	68% (44)	
Female	95% (20)	71% (31)	0.000001
Median Age	63	58	0.083
Dysphagia	43% (9)	23% (10)	NS
Structures	38% (8)	9% (4)	0.000001
Distribution - Med Esophagus	14% (3)	27% (12)	NS
Distribution - Upper and Lower Esophagus	33% (7)	18% (8)	NS
Associated Rheumatologic Disorders	24% (5)	11% (5)	0.00236
HIV	0% (0)	14% (6)	0.00007
Viral Hepatitis	0% (0)	9% (4)	<0.05
Takin >3 Medications	67% (14)	59% (26)	0.00001
Progression to Dysplasia/Carcinoma	5% (1)	7% (3)	NS

Immunolabeling with CD20, CD3, and FOXP3 did not allow distinction between LEP and LPE.

**Conclusions:** Both LPE and LEP present with dysphagia, with superimposable histologic features and immunolabeling with CD20, CD3, and FOXP3. About 5% of LPE patients have tandem skin manifestations. LPE is more likely than LEP to arise in women, result in stricture formation, and be associated with rheumatologic disorders, whereas LEP is associated with viral hepatitis, HIV, and use of multiple medications. Either process can be associated with progression to neoplasia in a minority of case. Since the risk of stricture formation is high in patients with LPE, it is worth performing pertinent IF studies to confirm LPE, although knowledge of the clinical association of LEP with viral hepatitis, HIV, and use of multiple medications is of value in daily practice.

**730 Interstitial Cells of Cajal Quantification on Full Thickness Gastric Wall Provides Prognostic Information for Treatment of Gastroparesis by Gastric Electric Stimulation**

A Sankineni, S Harbison, HP Parkman, RM Thomas. Temple University Hospital, Philadelphia, PA.

**Background:** Gastroparesis is a condition of delayed gastric emptying with symptoms of early satiety, nausea and vomiting. It occurs in patients with long-standing diabetes mellitus and after upper GI surgery, especially vagotomy; it is idiopathic in many patients. Interstitial cells of Cajal (ICC) are the electrical pacemaker cells of the GI tract; they occur in the inner circular and outer longitudinal muscle layers, and in the intermyenteric plexus. Patients with gastroparesis may have dysfunction or paucity of innervation and/or ICC that may contribute to the pathophysiology, symptoms and treatment outcomes. One therapy for patients with gastroparesis is the placement of an electrical stimulator in the gastric wall.

**Design:** The aim of this study was to evaluate gastric ICC and enteric innervation in patients with gastroparesis and to determine if these influence treatment outcomes with gastric electric stimulation (GES). Full thickness gastric specimens were obtained in patients undergoing surgical placement of a gastric electric stimulator. H+E stains, as well as immunohistochemistry with Neuron Specific Enolase for ganglion cells and c-Kit for ICC were evaluated. Patients were followed and classified as responders or non-responders to GES using the modified Clinical Patient Grading Assessment Scale (CPGAS).

**Results:** 74 patients with refractory gastroparesis (35 diabetic, 35 idiopathic, 4 post Nissen) underwent implantation of a gastric electric stimulator from July 2010 to November 2011. Of the 66 patients who had full thickness specimens, 47 improved with GES whereas 19 patients stayed the same or worsened. ICC were decreased in each layer in patients who did not improve with GES compared to those who improved: ICC/hpf in outer longitudinal muscle layer (0.82±0.11 vs 1.42±0.15; p=0.002); inner circular muscle layer (2.20±0.19 vs 2.86±1.49; p=0.028); and myenteric plexus (0.91±0.16 vs 1.02±0.09; p=0.54). The CPGAS improvement score at follow-up (average 6.5 months) correlated with the number of ICC in the outer longitudinal muscle layer (r=0.272; p=0.003), the inner circular muscle layer (r=0.210; p=0.021), and myenteric plexus (r=0.181; p=0.057). The number of ganglion cells and number of ganglia were similar in responders and nonresponders.

**Conclusions:** Gastroparetic patients who do not respond to GES had fewer ICC than patients who improved. Information from gastric full thickness biopsies may provide prognostic information on outcome of GES treatment for gastroparesis.

**731 Discovery of New Histological Prognostic Factors in Rectal Adenocarcinoma Treated by Radiochemotherapy Followed by Total Mesorectum Excision**

A Sannier, J Lefevre, F Bretagnol, D Cazals-Hatem, Y Panis, P Bedossa, N Guedj. Beaujon Hospital, Clichy, France, Metropolitan.

**Background:** Radiochemotherapy (RCT) followed by surgical resection became treatment of choice for patients with locally advanced rectal cancer. Specimen pathological diagnosis determine prognosis and further clinical management of patients. The aim of our study was to identify new histological prognostic factors in a consecutive series of surgical specimens of patients treated by neoadjuvant RCT.

**Design:** 113 patients were included. Macroscopic and microscopic examinations were performed according to the AJCC recommendations, with some additional criteria as the presence of buds or calcifications in the tumor bed. Modified Rectal Cancer Regression Grade (m-RCRG) was assessed. Lymph node (LN) reshuffles as fibrosis, necrosis, calcifications or macrophagic infiltration were notified. LN metastasis regression grading was also evaluated regarding the percentage of residual tumor cells. Univariate and multivariate analyses were used to identify histological prognostic factors.

**Results:** Disease-free survival (DFS) was 69 % at a mean follow-up of 25.2±16 months [2-57]. In univariate analysis, ypTN stage, tumor budding, circumferential resection margin, invaded margin, vascular and perineural invasion were prognostic factors (p<0.05). In multivariate analysis, presence of calcifications in tumor bed (p=0.027) and small circumferential margin (p=0.032) were the only two independent factors of worse DFS. mRCRG was not correlated to DFS. However, among the 50 mRCRG1 tumors, DFS was significantly better in ypT0 patients than in other ypT stages (p=0.032). We observed LN reshuffles among ypN0 and ypN+ patients respectively in 6% and 94%. The mean percentage LN metastasis regression was 23±19% [2-70%]. Patients with at least or more of 30% of LN metastasis regression had a tendency to have a better DFS compared to patients with < 30% of LN metastasis regression (p=0.1).

**Conclusions:** Presence of calcifications in tumor bed is a new major prognostic factor described for the first time in rectal cancer. The presence of tumor buds at the edge of the tumor was confirmed to be of prognostic value. Lastly, ypT stage appears as a more reliable predictor of oncological outcome than the more reproducible histological tumor regression grade according to Bateman and al study. In our study, LN metastasis regression grade had a tendency to be correlated with DFS. However, further studies focusing specifically on LN metastasis regression are needed to confirm its potential prognostic value.

**732 Prevalence of Plasma Cells and Lymphoid Follicles in Sleeve Gastrectomy Specimens: Redefining Normal Stomach Histology**

M Saroufim, G Shamseddine, B Safadi, F Boulos. American University of Beirut Medical Center, Beirut, Lebanon.

**Background:** The finding of lymphoid follicles/aggregates in gastric biopsies has been traditionally linked to *H. pylori* gastritis, and less commonly to other inflammatory and neoplastic conditions. The frequency of such aggregates in normal stomachs has yet to be adequately evaluated. This is especially relevant when it comes to diagnosing

non-specific chronic gastritis in biopsy specimens with chronic inflammation but no evidence of *H. Pylori* infection. Sleeve gastrectomies represent an opportunity to study adequately preserved gastric mucosa in patients who are likely to be asymptomatic and to lack a history of gastric disease.

**Design:** 68 bariatric sleeve gastrectomies were examined for multiple histologic features including type, quantity, and distribution of chronic inflammation and lymphoid follicles/aggregates. Presence of *H. Pylori* was documented by H&E and IHC. Clinical information including age, sex, medication intake, history of prior endoscopy and/or *H. Pylori* infection was recorded.

**Results:** 263 fundic sections (range 2-9, mean 4) from 68 patients (32 males, 36 females) were examined. Among 55 *H. pylori* IHC-negative (versus 13 IHC-positive) patients, the maximum number of superficial i.e. foveolar, and deep i.e. fundic inter-glandular plasma cells ranged from 0 to 7 (vs. 2 to 8) and 0 to 6 (vs. 0 to 4) respectively (mean: 2, <1 vs. 5, 1); similarly, the number of lymphoid aggregates/follicles per section ranged from 0 to 14 (vs. 1 to 10), (mean: 3 vs. 5) with 10% (vs. 20%) showing germinal center formation. The follicles ranged from 0.2 to 1.5 mm in greatest dimension (mean: 0.58). Focal acute inflammation was seen in 3 (vs. 4) patients. Clinical information revealed that 11 of the *H. Pylori*-negative cases had EGD, all of which showed endoscopic mild non-erosive to diffuse gastritis. The remaining had no documentation of symptoms or medication intake, including NSAIDs and PPI.

**Conclusions:** Although cases with *H. Pylori* infection show a qualitative and occasionally significant increase in inflammatory changes (e.g. germinal centers), there appears to be significant overlap and no pathognomonic features in the histology of stomachs with or without documented gastric symptoms and/or disease. Hence, the spectrum of acceptable "normal" chronic inflammatory changes in the stomach is possibly wider than currently believed. A high threshold for diagnosing chronic gastritis in patients without *H. Pylori* or other well-established causes of gastritis is therefore advised.

### 733 MicroRNAs as Regulators of Colorectal Cancer Hepatic Metastasis

A Scherl, JM Loo, FY Man, A Nguyen, S Tavazoie. Yale University School of Medicine, New Haven, CT; Rockefeller University, New York, NY.

**Background:** Colorectal cancer (CRC) is the second leading cause of cancer-related deaths in the US. The mortality of CRC is largely attributable to hepatic metastasis, rather than the primary tumor. Current clinical therapies have limited efficacy due in part to our poor understanding of metastatic progression. Recently, microRNAs (miRNAs) have been shown to regulate cancer metastasis; therefore, the aim of this study is to identify miRNAs that function as regulators of CRC hepatic metastasis.

**Design:** A novel *in vivo* hepatic colonization selection model was utilized to derive human CRC cell lines with greater metastatic potential than the weakly metastatic parental cell lines. Array-based profiling was used to identify potential metastasis-associated miRNAs. Candidate miRNAs were then evaluated as regulators of metastasis utilizing *in vivo* tumor xenograft assays. Quantitative real-time RT-PCR (qRT-PCR) was employed to determine expression levels of the metastasis-associated miRNAs in human primary and metastatic tumors. To examine the biology of these miRNAs in the context of tumor formation, we conducted morphometric analysis of metastatic xenograft tumors. To assess the effect of miRNA silencing with respect to CRC cell survival in liver parenchyma, we developed a novel *ex-vivo* hepatic organotypic slice metastasis assay.

**Results:** We identified two miRNAs that are significantly downregulated in aggressively metastatic cell lines as compared to parental controls. Utilizing *in vivo* metastasis assays, silencing of these miRNAs resulted in increased hepatic metastatic tumor burden. Conversely, overexpression of these miRNAs decreased metastasis. qRT-PCR showed significantly decreased levels of miRNA expression in human metastatic tumors as compared to primary tumors. Histologically, tumor xenografts with miRNA silencing had increased tumor burden due to greater numbers of similarly sized tumor nodules, rather than due to larger sized individual nodules. As demonstrated in hepatic organotypic slice cultures, silencing of these miRNAs enhanced CRC cell survival in the liver microenvironment.

**Conclusions:** We have identified two previously uncharacterized miRNAs that function as endogenous regulators of hepatic CRC metastasis. Silencing of these miRNAs results in increased CRC metastasis *in vivo*, and decreased levels of these miRNAs are present in human CRC hepatic metastases as compared to primary tumors. These results demonstrate the clinical relevance of these metastasis-associated miRNAs, highlighting their potential as future therapeutic targets.

### 734 Long Term Outcome Study of Patients with Both Inflammatory Bowel Disease and Microscopic Colitis during the Course of Illness

S Schulte, T Khor, C Hagen, R Najarian, G Lauwers, R Odze, A Srivastava. Brigham and Women's Hospital, Boston, MA; Massachusetts General Hospital, Boston, MA; Dartmouth-Hitchcock Medical Center, Dover, NH; Beth Israel Deaconess Medical Center, Boston, MA.

**Background:** Rarely, patients with IBD develop a microscopic colitis (MC)-like illness and, conversely, some patients with microscopic colitis develop an IBD-like illness. The aim of this study was to evaluate the clinical, endoscopic, and pathologic features of patients with IBD who also had a prior, concurrent or subsequent diagnosis of MC during the course of illness in order to determine the relationship, if any, between these disorders.

**Design:** The study group consisted of 20 patients (M/F: 5/15; mean age 61; range 23-85) who had a diagnosis consistent with both IBD and MC at different time points during their illness. These patients were collected via a search through the pathology files of four large hospitals over a 15 year period. Clinical and endoscopic findings at

each colonoscopy, treatment history, and patient outcome were determined by chart review. All biopsies were reviewed to confirm the diagnosis.

**Results:** Of the 20 study patients, 13 had clinical and pathologic features of IBD [8 Crohn's disease (CD), 5 ulcerative colitis (UC)] followed by development of a collagenous colitis (CC) (N=6) or lymphocytic colitis (LC)-like illness (N=7). 4 of 6 patients who developed CC, and 5/7 patients who developed LC, had clinical and pathologic confirmation of the diagnosis (watery diarrhea, normal endoscopy), whereas the remainder (2/6 CC and 2/7 LC patients) had pathologic features of MC in their biopsies, but had clinical and/or endoscopic features of IBD (bloody diarrhea, obstruction, stricture). Of the 7 patients who presented initially with clinically and pathologically confirmed CC (N=6) or LC (N=1), and then developed an IBD-like illness (5 CD, 2 UC), all had clinical and pathologic evidence of IBD at the most recent follow up.

**Conclusions:** Patients initially diagnosed with IBD who developed MC-like changes with time represent a heterogeneous group, including those who develop new onset MC unrelated to IBD, and some who develop MC-like histologic changes in their biopsies, but in patients with established IBD. In contrast, some patients with an initial diagnosis of MC develop true IBD with time. Further studies are needed to determine if MC represents a risk factor for IBD, or if this latter phenomenon represents the coincidental occurrence of two disorders in the same patient.

### 735 Counting Colonic Mast Cells Is Not Diagnostically Useful in Patients with Chronic Diarrhea of Unknown Etiology

A Sethi, D Jain, B Chander, J Kinzel, J Gibson, R Schrader, JA Hanson. University of New Mexico School of Medicine, Albuquerque, NM; Yale University School of Medicine, New Haven, CT.

**Background:** Mastocytic Enterocolitis (ME) is a recently described entity defined by chronic diarrhea of unknown etiology (CDUE) and normal GI biopsies with increased mast cells (MC) seen on special stains. Recent data suggest that patients with ME may benefit from MC stabilizers. This has led some authors to recommend MC stains in the work up of patients with CDUE. The current study represents the largest to date examining the diagnostic utility of colonic MC in patients with CDUE.

**Design:** Blinded MC counts using a c-kit stain were performed in 76 patients with CDUE who had normal colon biopsies and in 89 asymptomatic controls presenting for screening colonoscopy who had biopsies of normal colonic mucosa. MC were counted per single high power field (hpf) in the highest density area. A t-test was used to compare the counts and a receiver operating characteristic (ROC) curve was generated to determine if increased MC counts are a sensitive and specific marker of disease.

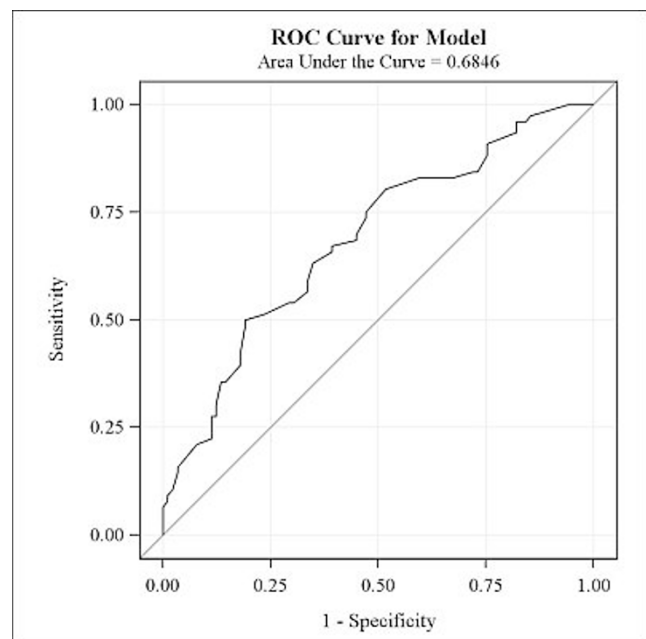
**Results:** For all colon biopsies independent of site, the study group averaged 31 MC/hpf (SD = 10.50) versus 24 MC/hpf in the control group (SD = 8.6, p<0.0001). When biopsies were stratified by location, a significant increase was seen in biopsies from the left but not right colon. ROC analysis revealed that MC counts do not yield a diagnostically accurate cutoff value (AUC = 0.68).

Left Colon

Group	N	Mean	Std. Dev.	p-value
Control	44	22.2159	8.5714	0.01
Patient	27	30.9444	15.8626	

Right Colon

Group	N	Mean	Std. Dev.	p-value
Control	47	25.4362	9.0197	0.3
Patient	20	28.2333	10.9801	



**Conclusions:** Although the absolute differences are small, MC counts are significantly increased in patients with CDUE, primarily in the left colon. In addition, ROC analysis shows that there is no cutoff value that would be considered diagnostically accurate.

Therefore, from a testing standpoint, performing MC stains on normal colon biopsies in patients with CDUE yields little useful information. Further case controlled studies are necessary to determine if ME truly represents a distinct disease entity.

### 736 Esophageal Intestinal Metaplasia (Barrett's Esophagus) Accompanies Most Esophageal and Gastroesophageal Junction Adenocarcinomas – A Single Institution Experience

*GV Shah, EA Montgomery.* Johns Hopkins Medical Institutions, Baltimore, MD.

**Background:** The American College of Gastroenterologists and the American Gastroenterological Association both currently require the presence of intestinal metaplasia to diagnose Barrett's esophagus and thereby enroll patients for follow-up screening for adenocarcinoma. Some observers believe that this requirement should be widened to include all columnar epithelium identified in the esophagus.

**Design:** We searched pathology archives of our institution for patients diagnosed with adenocarcinoma of the esophagus or gastroesophageal junction whose primary biopsies and resections and follow-up were at our institution between May 2002 and April 2012. We assessed for specimens obtained both prior to and after their adenocarcinoma diagnosis to learn if these patients had any samples in our institution's archives showing intestinal metaplasia in the esophagus (Barrett's esophagus).

**Results:** There were 241 patients diagnosed with adenocarcinoma said to be in the esophagus. In 21 patients (9%), there was no documentation of background esophageal intestinal metaplasia whereas the remaining 220 (91%) were shown to have intestinal metaplasia. Most of the esophageal adenocarcinomas unassociated with intestinal metaplasia were poorly differentiated (14/21, 67%). There were an additional 77 patients diagnosed with adenocarcinoma said to involve the "gastroesophageal junction". In 14 (18%), no esophageal intestinal metaplasia was identified, whereas esophageal intestinal metaplasia was identified in the remaining 63 (82%). Most of the tumors unassociated with intestinal metaplasia of the gastroesophageal junction were poorly differentiated (9/14; 64%). Overall, esophageal intestinal metaplasia was detected in 89% of persons diagnosed with esophageal or gastroesophageal junction adenocarcinoma.

**Conclusions:** These results support the current requirement for esophageal intestinal metaplasia as an entry point into adenocarcinoma surveillance protocols, both for esophageal adenocarcinomas and "gastroesophageal junction" adenocarcinoma; some of the latter are presumably gastric lesions, with slightly different risk factors.

### 737 Using Next Generation DNA Sequencing (NGS) To Select Targeted Therapies and Predict Resistance to Standard Therapies in Colorectal Cancer (CRC)

*CE Sheehan, A Parker, M Jarosz, S Downing, R Yelensky, D Lipson, G Otto, A Donahue, S Balasubramanian, P Stephens, G Palmer, M Cronin, JS Ross.* Albany Medical College, Albany, NY; Foundation Medicine Inc., Cambridge, MA.

**Background:** The recent introduction of massively parallel (NGS) DNA sequencing to clinical samples has enabled the discovery of novel and unanticipated genomic-derived drug targets of therapy for patients with relapsed and metastatic CRC. NGS can also identify markers of chemoresistance to standard therapies for CRC.

**Design:** DNA was extracted from 4 X 10 μ FFPE sections from 49 cases of primary CRC (52% male; 48% female; mean age 60 years; 10% Stages I/II; 40% Stage III; 40% Stage IV; 10% Stage unknown). NGS was performed on the primary tumor in 80% and on metastases in 20% of the CRC. The exons of 145 cancer-related genes were fully sequenced by NGS technology using the Illumina HiSeq 2000 (Illumina Inc. San Diego, CA) to an average sequencing depth of 253X. Tumoral DNA was evaluated for point mutations, insertions/deletions (indels), translocations and copy number alterations (CNA).

**Results:** NGS revealed 156 genomic alterations in the 49 CRC samples including base substitutions (58%), indels (28%), CNAs (12.7%) and translocations/rearrangements (1.3%). NGS derived gene mutation frequencies were similar to the COSMIC database with the exceptions of higher NGS rates of *TP53* mutation (71% vs 48%) and *APC* alterations (75% vs 29%). NGS derived alterations associated with sensitivity or resistance to targeted therapies were identified in 27 (55%) of CRCs including *FBXW7* (6 tumors); *BRAF* (5 tumors); *SMAD4* (5 tumors); *PIK3CA* (4 tumors); *BRCA1* (3 tumors); *STK11* (2 tumors); *ATM* (2 tumors) *BRC42* (2 tumors); *GNAS* (2 tumors) *CDK8* (1 tumor) and *HER2* (1 tumor). 2 tumors had 3 alterations each associated with potential treatment decisions. In one CRC, genomic sequences suggestive of a novel chromosome 2 rearrangement adjacent to the ALK kinase domain was identified and confirmed by analyzing a cDNA library constructed from the patient's FFPE tumor RNA. This in-frame fusion, not currently detectable by FISH, starts at the canonical exon 20 recombination site previously reported for the majority of *ALK* fusion genes and contains the same intracellular domain as other *ALK* rearrangements including *EML4-ALK*, known to be ALK kinase inhibitor sensitive.

**Conclusions:** NGS can be performed on FFPE CRC samples in a highly sensitive deep sequencing of genomic DNA which, when applied to a broad cancer-related gene survey, uncovers an unexpectedly high frequency of genomic alterations in CRC patients that can reveal actionable genetic events that inform treatment decisions.

### 738 Isolated Ileitis May Be a Manifestation of Crohn's Disease, but Only in Symptomatic Patients: A Multi-Institution Study of 131 Cases

*J Shen, RM Najarian, B Dessauvagie, V Deshpande, MP Kumarasinghe, M Hamilton, M Shahid, G Lauwers, RD Odze, A Srivastava.* Brigham and Women's Hospital, Boston, MA; Beth Israel Deaconess Medical Center, Boston, MA; PathWest & UWA, Perth, Australia; Massachusetts General Hospital, Boston, MA.

**Background:** Isolated ileitis may be detected during diagnostic work-up in symptomatic patients, or as an incidental finding on screening colonoscopy in asymptomatic patients. Its clinical significance in patients without a prior diagnosis of inflammatory

bowel disease is unknown. The current study was performed to determine clinical and pathologic features predictive of progression to Crohn's disease (CD) in patients with an isolated ileitis.

**Design:** 131 patients from 4 medical centers met our inclusion criteria of 1) index colonoscopy with definite endoscopic and histologic evidence of ileitis, and 2) at least 2 years of clinical follow-up. Patients with 1) a prior diagnosis of, or suspicion for IBD, 2) presence of colonic or upper gastrointestinal tract involvement, or 3) surgical pathology material unavailable for review, were excluded. Each case was histologically categorized into chronic active ileitis (CAI) or focal active ileitis (FAI), and clinical and endoscopic data was retrieved by chart review. Uni- and multivariate analysis was used to determine predictors of progression to CD.

**Results:** The study group consisted of 47 men and 84 women (mean age: 48 yrs; range 15-87 yrs). 84/131 patients underwent colonoscopy for diagnostic workup of either gastrointestinal symptoms (77) or abnormal laboratory findings (7). Abdominal pain (50.6%), diarrhea (42.8%), and rectal bleeding (22.1%) were the most common reported symptoms. 47/131 patients were asymptomatic, and ileitis was an incidental finding on screening colonoscopy. Endoscopic abnormalities were similar in both symptomatic and asymptomatic patients, the most common being aphthous erosions (41.5%), ulcers (34.4%), and erythema (39.7%). 20/131 patients had a definite diagnosis of CD at last follow-up (range 24-144 mth; mean 61 mth), and all were from the symptomatic group (20/83; 24%). This included 10/21 (48%) patients with CAI (OR=8.7, 95% CI [2.3, 33.2]), and 10/62 (16%) with FAI. In contrast, no patients with incidental asymptomatic ileitis (n=47) progressed to CD on follow-up (range 24-160 mth; mean 67 mth), including 7/47 (15%) with CAI.

**Conclusions:** Overall, 24% of symptomatic patients with an isolated ileitis progress to CD, and the risk is significantly higher (48%) in those with CAI. However, isolated asymptomatic ileitis detected incidentally during screening colonoscopy does not progress to CD, and should be managed conservatively.

### 739 HER2 Status in Gastric and Gastroesophageal Junction Adenocarcinoma: A Clinicopathologic and Prognostic Analysis from Four Chinese Clinical Centers

*W Sheng, D Huang, X Zhou, S Ni, X Du.* Fudan University Cancer Center, Shanghai, China.

**Background:** The purpose of this study was to analyze the incidence and patterns of HER2 expression in gastric and gastroesophageal junction cancer in China, to compare the classical hybridization method (fluorescence in situ hybridization, FISH) with the novel, fully automated brightfield dual color silver enhanced in situ hybridization (DSISH) detection, and to evaluate the relationship between HER2 status and clinicopathologic features and outcome of gastric cancers.

**Design:** HER2 expression was investigated in 726 consecutive gastric or gastroesophageal junction cancer samples in the northern, southern, western and eastern China populations from four hospitals. All the samples were analyzed for HER2 status by immunohistochemistry (IHC), FISH and DSISH. The association between HER2 overexpression and the clinicopathologic characteristics was analyzed.

**Results:** On the basis of immunohistochemistry, which was applicable in 726 cases, 84 tumors (11.6%) were scored as IHC 2+ and 74 tumors (10.2%) were scored as IHC 3+. Concordance of FISH results, 94 tumors (12.9%) were HER2-amplified. Of HER2-amplified cases, 69 tumors (73%) scored IHC 3+, showing the correlation between HER2 gene amplification and overexpression (P<0.001). The DSISH assay showed a 96% concordance rate with FISH results in 726 samples (p<0.001). No significant trend was observed in four different populations of China. Ninety-one adenocarcinomas (12.5%) were HER2 positive. HER2-positive cases were more frequently found in men, gastroesophageal junction cancers, the intestinal type by Lauren classification and well to moderate differentiated cancers. There was no significant difference of 3 years overall survival between HER2 positive and negative patients.

**Conclusions:** These results reveal that HER2 status was reliable determined and no regional difference was observed in Chinese population. DSISH represents an excellent alternative for the evaluation of HER2 status in gastric and gastroesophageal junction cancer.

### 740 Epithelial-Mesenchymal Transition Phenotype Is Associated with Patient Survival in Small Intestinal Adenocarcinoma

*HC Shin, A Kim, YK Bae, MJ Gu, ES Jung, Y-H Oh, H-I Bae, HJ Lee, S-M Hong.* Yeungnam University College of Medicine, Daegu, Republic of Korea; Catholic University of Korea College of Medicine, Seoul, Republic of Korea; Hanyang University College of Medicine, Seoul, Republic of Korea; Kyungpook National University School of Medicine, Daegu, Republic of Korea; Seoul National University Bundang Hospital, Seongnam, Republic of Korea; Asan Medical Center, University of Ulsan College of Medicine, Seoul, Republic of Korea.

**Background:** Small intestinal adenocarcinomas (SIACs) are rare, and their molecular pathogenesis is largely unknown. Epithelial-mesenchymal transition (EMT) of epithelial tumor is defined as a reversible process characterized by loss of epithelial characteristics and acquisition of a mesenchymal phenotype. We investigated the clinical significance of EMT in SIACs based on the expression pattern of EMT-related proteins.

**Design:** We performed immunohistochemistry for epithelial (E-cadherin and β-catenin) and mesenchymal (vimentin and fibronectin) markers on tissue microarray slides constructed with 194 SIACs. Based on the combined results, we divided the 194 cases into three groups: complete EMT type (negative for epithelial markers and positive for any mesenchymal marker), wild type (positive for any epithelial marker and negative for mesenchymal markers) and incomplete type (neither complete nor wild type). And the data were compared with clinicopathologic factors, including overall survival of SIAC patients.



**Results:** Complete EMT phenotype was observed in 7.6% (14/184 informative cases) of SIACs. Wild and incomplete phenotype consisted of 63.6% (117/184) and 28.8% (53/184) of SIACs, respectively. Complete EMT phenotype was significantly associated with polypoid growth pattern ( $P=0.01$ ), undifferentiated carcinoma ( $P<0.001$ ), advanced pT classification ( $P=0.03$ ) and presence of lymphovascular invasion ( $P=0.05$ ). Overall survival for SIAC patients with complete EMT phenotype was significantly shorter than those for patients with incomplete and wild types, as determined by univariate ( $P<0.001$ ) and multivariate analyses ( $P<0.001$ ).

**Conclusions:** In conclusion, complete EMT phenotype was significantly associated with major clinicopathologic parameters and it was an independent prognostic factor for overall survival in patients with SIACs.

#### 741 Intralymphatic Tumor in Duodenal Biopsies: Clinicopathologic Features

S Shroff, MW Taggart, SC Abraham, A Rashid. MD Anderson Cancer Center, Houston, TX.

**Background:** Duodenal biopsies are occasionally taken for suspected metastases or identification of nearby tumors (e.g., pancreatic, ampullary). Rarely, metastatic tumor cells are identified only in lymphatic spaces of the biopsy. The clinicopathologic features of this unusual phenomenon have not been described.

**Design:** We searched the computerized pathology database at our institution from 1992-2012 for duodenal biopsies containing distant or loco-regional metastases. Cases in which neoplastic cells were only present in lymphovascular spaces were selected and the histologic slides were reviewed. Clinical data (gender, age, symptoms, and history of malignancy) and endoscopic appearance of the duodenum were collected from electronic medical records.

**Results:** Thirty-three patients (18 M:15 F) ranging from 26-75 (mean 60) years had neoplastic cells exclusively in duodenal lymphovascular spaces. Endoscopy reports were available for review in all but 3 patients (91%). Endoscopy was performed on 13 patients (43%) to evaluate gastrointestinal symptoms (nausea, vomiting, abdominal pain, early satiety, new onset reflux and/or bleeding/melena). In the other 17 patients (57%), endoscopy was prompted by clinical and/or radiologic suspicion of a duodenal mass. Endoscopic appearance of the duodenum was variable and included mass (9), nodularity (6), ulcer (6), stricture (5), "thickening" of duodenum or thickened duodenal folds (4), edema (2), erythema (2), and mucosal friability (1). The primary tumors were all carcinomas with the exception of one (3%) metastatic melanoma. Eleven patients (33%) had loco-regional primary sites (pancreas-8, extrahepatic bile ducts-2, duodenum-1), 19 (58%) had metastases from distant primary sites (colorectum-4, kidney-3, lung-2, ovary-2, breast-2, skin-2, uterus-1, bladder-1, gastroesophageal junction-1 and small intestine-1), and in 3 patients (9%) the primary site remained unknown. In 10 patients (30%), the duodenal biopsy provided the first diagnosis of malignancy.

**Conclusions:** Exclusive involvement of lymphovascular spaces by metastatic tumors in the duodenum is a rare finding, with only 33 cases identified over a 20 year period at a busy cancer center. This phenomenon occurs almost exclusively in carcinoma, rarely in melanoma and never in sarcoma. In nearly one third of such cases, the duodenal biopsy served as the initial diagnostic material for identification and classification of malignancy. When a neoplastic process is suspected endoscopically but the low power appearance of the duodenal biopsy is unremarkable, close attention should be directed lymphovascular spaces for evidence of microscopic disease.

#### 742 A Practical Diagnostic Panel for Distinguishing between Hepatocellular Lesions

F Siadat, P Williams, C Margean. Ottawa Hospital and University of Ottawa, Ottawa, ON, Canada.

**Background:** Histopathologic distinction between well differentiated hepatocellular carcinoma (HCC), hepatocellular adenoma (HA) and focal nodular hyperplasia (FNH) can be challenging, especially on small biopsies. We studied the immunohistochemical (IHC) expression of Hepatocyte Specific Antigen (HSA), Insulin-Like Growth Factor II mRNA-Binding Protein 3 (IMP3), Glypican-3 (GPC3), and Glutamine Synthetase (GS) in order to determine their diagnostic value in the distinction between hepatocellular mass lesions.

**Design:** A total of 59 liver lesions were stained for the four antibodies, including 26 well differentiated HCC (23 resections; 3 biopsies), 13 HA (12 resections; 1 biopsy) and 20 FNH (14 resections; 6 biopsies). IHC was performed using HSA (Abcam), IMP3 (DAKO), GPC3 (Santa Cruz) and GS (Millipore, MAB302). Cytoplasmic granular staining was considered positive for HSA, IMP3 and GS and cytoplasmic, and/or membranous staining was considered positive for GPC3. The percentage and distribution of immunoreactive tumour cells was recorded for all antibodies and the staining intensity was graded as weak (1+), moderate (2+), or strong (3+).

**Results:** Strong HSA reactivity was detected in 19/20 (95%) of FNH, all HA (100%), and 23/26 (88%) of HCC. Staining for IMP3 was observed in all HCC (100%) and none of the FNH or HA. IMP3 showed a stronger (3+) staining at the periphery of the tumours. GPC3 showed strong (3+) reactivity in 18/26 (69%) of HCC, in 1/13 (8%) HA and was negative in all FNH. GS was strong and diffuse in all HCC (100%), strong and diffuse in 2/13 (15%) of HA, and showed a typical strong reactivity in "map-like" pattern in all FNH (100%).

**Conclusions:** HSA is a strong marker of hepatocytic lineage, however it is not useful in the differential diagnosis of HCC, HA and FNH. GPC3 and IMP3 are positive in most HCC and negative in the benign lesions. GPC3 staining may be focal in HCC, and lack of staining does not exclude a well differentiated HCC, in keeping with previous published results. GS is strongly positive in all HCC, weak or negative in the majority of HA and shows a typical "map-like" pattern in all FNH, evident even

in small biopsies. In summary, morphology associated with a panel including GPC3, IMP3 and GS can differentiate between well differentiated hepatocellular lesions, even when limited tissue is available.

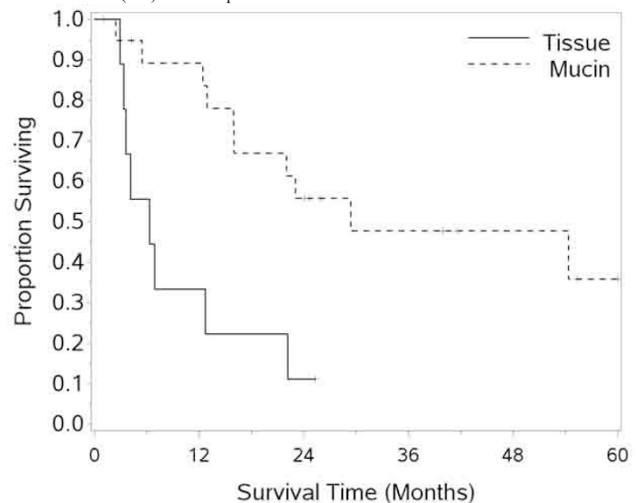
#### 743 Significance of Signet-Ring Cells in Extracellular Mucin Pools Versus Tissue in High-Grade Mucinous Carcinoma Peritonei

J Sirintrapun, A Blackham, G Russell, J Stewart, P Shen, E Levine, K Geisinger, S Bergman, A Cimic. Wake Forest Baptist Health, Winston Salem, NC; UNC Chapel Hill, Chapel Hill, NC.

**Background:** Bradley et al.(2006) termed appendiceal pseudomyxoma peritonei as mucinous carcinoma peritonei (MCP) and proposed a two tiered (low vs high) scheme. Later Chua et al.(2012) validated this classification with 2,298 patients. Under this scheme, signet-ring cells (SRC) are classified as high-grade mucinous carcinoma peritonei (HG-MCP). Unknown was whether SRC occurs in otherwise low-grade mucinous carcinoma peritonei (LG-MCP) and whether SRC within extracellular mucin pools and in tissue differ prognostically.

**Design:** Our hypotheses are 1) SRC occurs only in HG-MCP and 2) SRC invading tissue conveys a worse prognosis vs SRC within mucin pools. We retrospectively examined appendiceal MCP (n=55) and confirmed cases as LG-MCP or HG-MCP. Extra attention was given for SRC presence (n=29) which was then subdivided into Group A SRC within mucin pools (n=20) and Group B SRC invasive in tissue (n=9).

**Results:** Zero LG-MCP cases (n=12) and 29 of 43 HG-MCP cases had SRC. In cases with SRC (Groups A and B), all non-SRC tumoral areas met Bradley criteria for HG-MCP. Group A was younger than Group B (mean age 46.8 vs 54.5,  $p=0.03$ ) with no differences with race or sex. In Group A, 15 cases showed focal vs abundant SRC in mucin pools. In Group B, 1 of 10 cases showed focal vs extensive SRC tissue invasion. Kaplan-Meier analyses with log-rank approximation of chi-square test showed shorter overall survival (OS) for Group B.



For Group A, 1 and 2 year OS was 89.2% (+/-SE 7.2%) and 55.7% (+/-SE 11.7%) respectively. For Group B, 1 and 2 year OS was 33.3% (+/-SE of 15.7%) and 11.1% (+/-SE 10.5%) respectively. Group A median OS was 29.4 months vs 6.3 months for Group B ( $p=0.0025$ ).

**Conclusions:** SRC does not occur with LG-MCP. SRC in mucin pools is often focal, but non-SRC areas meet Bradley criteria for HG-MCP. SRC therefore equates with HG-MCP. SRC tissue invasion most often was extensive. Group A behaved similar to published data of HG-MCP but Group B showed more dismal prognosis. Qualification of SRC in extracellular mucin or tissue appears justified in reporting of HG-MCP with SRC.

#### 744 Molecular Subtypes of Gastric Cancer Are Associated in Part with Tumor Histology

O Speck, W Tang, DR Morgan, MO Meyers, RL Dominguez, E Martinez, P-F Kuan, ML Gulley. University of North Carolina Hospitals, Chapel Hill, NC; Lineberger Comprehensive Cancer Center, Chapel Hill, NC; UNC Hospitals, Chapel Hill, NC; Western Regional Hospital, Santa Rosa de Copan, Honduras; Hospital Evangelico, Siguatepeque, Honduras; UNC, Chapel Hill, NC.

**Background:** Gastric adenocarcinoma is one of the most common fatal malignancies worldwide and is characterized by marked morphologic and clinical heterogeneity. Intestinal and diffuse gastric cancers distinguished by the Lauren classification have different epidemiologic characteristics. Several additional distinct histologic types show prognostic differences. Gastric cancers that are infected with Epstein-Barr virus (EBV) may have yet another distinct clinicopathologic profile. Finally, gastric adenocarcinomas frequently exhibit neuroendocrine differentiation. In this study, we examined histologic features of gastric adenocarcinoma in correlation with molecular subtypes as defined by RNA expression profiling.

**Design:** H&E stained sections of 103 gastric adenocarcinomas were scored for 1) chronic and 2) acute inflammation, 3) stromal desmoplasia, 4) histologic subtype, 5) Lauren classification, 6) T stage, and 7) location within the stomach. Each paraffin embedded tumor was profiled on the Nanostring nCounter system targeting 93 human and viral RNAs and then was classified into molecular subtype by hierarchical clustering. Fisher's Exact test was used to analyze associations between each histologic variable and molecular subtype.

**Results:** In unsupervised analysis, cancers were clustered into three molecular subtypes. Group 1 (n=14) was EBV infected as confirmed by Q-PCR for DNA viral load and by *EBER in situ* hybridization. These cancers lacked neuroendocrine appearance in concert with low levels of *GAST* (gastrin) and *CHGA* (chromogranin) RNA, while they had significantly higher levels of chronic inflammation (p=0.0117) and decreased stromal desmoplasia (p=0.003). The uninfected cancers were divided into two molecular subtypes distinguished in part by moderate or high *GAST* and *CHGA* levels. Other parameters such as Lauren classification, anatomic location, and T stage were not associated with molecular subtype in this study.

**Conclusions:** These data suggest that molecular classification of gastric cancer could complement histologic evaluation to advance our understanding of disease biology and identify molecular signatures that distinguish gastric cancer subtypes.

#### 745 Routine Genotyping of Tubal Gut Adenocarcinomas Yields Novel Molecular Insights

*M Stachler, N Lindeman, R Odze, A Srivastava.* Brigham and Women's Hospital, Boston, MA.

**Background:** Gastrointestinal adenocarcinomas (ACA) develop through the inflammation-dysplasia-carcinoma pathway and depending on location, are believed to carry a predictable underlying mutational phenotype. Routine tumor genotyping has the potential to identify novel mutations, for targeted therapy, that may occur at a low frequency and to identify unique combinations of mutations that may be relevant to clinical trial design. We describe herein our initial observations from routine genotyping of tubal gut adenocarcinomas.

**Design:** 152 ACAs [12 esophagus, 15 stomach, 3 duodenal, 1 small intestinal unspecified, 118 colorectum (46 right colon, 36 left colon, 32 rectum, 4 unspecified), and 3 appendix] were genotyped on a Sequenom platform for 471 mutations in 41 genes. The genotyping results for each case were analyzed for prevalence of various mutation combinations in the panel of 41 genes. A Fisher's exact test was used to test significance of the observed differences.

**Results:** At least 1 mutation was present in 100/152 (66%) of all cases tested. Two concurrent mutations were present in 32 (21%), three in 10 (7%) and four in 4 (3%) cases. Five (4%) of the CRC cases had concurrent mutations in *APC*, *TP53*, and *KRAS* and another 22 (19%) had a mutation in 2 out of these 3 genes. Two cases showed concurrent *BRAF* and *TP53* mutation and 1 case was positive for both *BRAF* and *KRAS* mutation. Previously reported mutations in *PIK3CA*, *NRAS*, and *CTNBN1* were found in 12%, 5% and 4% of CRC cases. Rare mutations not typically associated with CRC identified by routine genotyping included *AKT*, *IDH1*, *KIT*, *MAP2K1*, and *GNAS*. Interestingly, 4 cases with *GNAS* mutations were identified and all had mucinous differentiation compared to non-*GNAS* mutant tumors, where only 15% had mucinous differentiation (p=0.0007). The 4 *GNAS* mutated tumors involved the cecum, transverse colon, appendix, and duodenum, and the mean patient age was 55 yrs. A similar genotyping approach in pancreatic cancers (n=26) identified 1 *GNAS* mutation which was a case of a mucinous ACA arising in an IPMN.

**Conclusions:** Routine tumor genotyping provides useful information for targeted therapy, and also offers novel insights into the molecular pathogenesis of tubal gut ACAs. The identification of mutations involving multiple genes suggests a more complicated process of carcinoma pathogenesis than previously recognized and this has important implications for clinical trial design. It can also help in identifying unique genotype-phenotype correlations such as the association of *GNAS* mutations with mucinous ACAs.

#### 746 BRAF-Mutant Colon Cancers with and without High-Level Microsatellite Instability Are Distinguished by Histology and Methylation Phenotype

*BW Steussy, AM Bellizzi.* University of Iowa Hospitals and Clinics, Iowa City, IA.

**Background:** The histologic features (fx) of high-level microsatellite unstable (MSI-H) colorectal cancers (CRCs) are well-characterized, and these tumors are associated with a relatively favorable prognosis. Most are sporadic and believed to arise from *BRAF*-mutant sessile serrated polyps (SSP). Somewhat surprisingly, *BRAF* mutation in CRC has repeatedly been shown to adversely affect prognosis. Recently, it was shown that this is explained by the especially poor prognosis of *BRAF*-mutant, non-MSI-H tumors; the histologic features of this group of tumors has not been characterized.

**Design:** Cases were selected from a population-based cohort of CRCs based on the presence of *BRAF* mutation and available H&E slide(s) of primary tumor. MSI-H was defined as instability at  $\geq 40\%$  of loci tested. CpG island methylator phenotypes (CIMP) were defined as follows: CIMP-0, 0/8 methylation-positive loci; CIMP-L 1-5/8; CIMP-H  $\geq 6/8$ . Age, sex, and tumor location (right, left) were recorded and the following assessed: tumor type (adenocarcinoma [adca], mucinous [muc] adca, medullary [med] carcinoma [ca]); presence of any muc, med, or signet-ring fx; grade (high, low); tumor border (pushing, infiltrative); tumor budding (bud); tumor infiltrating lymphocytes (TIL) per high-power field (HPF); and Crohn-like reaction (CLR). Fisher's exact test was used to analyze categorical data and the Mann-Whitney test for age and TIL counts (significant at p<0.05).

**Results:** There are 50 MSI-H (47%) and 56 non-MSI-H CRCs, occurring at median ages of 66 and 67 (p=0.54), and with median TIL counts of 11 and 1.3 (p<0.0001). While all MSI-H tumors are CIMP-H, the non-MSI-H tumors are 16% CIMP-0, 41% CIMP-L, and 43% CIMP-H. Categorical data are shown in the Table.

Clinicopathologic Features by MSI Status

	MSI-H (%)	non-MSI-H (%)	p
Right	81	85	0.79
Woman	84	84	1
Muc Adca	12	7.1	0.51
Any Muc	62	46	0.12
Differentiation (Dif)	12	8.9	0.75
Signet-ring Fx	8	0	0.046
Med Ca	30	8.9	0.0066
Any Med Dif	60	43	0.085
High-Grade	90	57	0.0003
Pushing Border	14	45	0.0006
Tumor Bud	72	32	<0.0001
>2 TIL/HPF	76	62	0.14

**Conclusions:** *BRAF*-mutant CRCs are right-sided, female, have mucinous features, and are high-grade, regardless of MSI status. *BRAF*-mutant non-MSI-H tumors are distinguished by infiltrative growth, tumor budding, and infrequent TIL, histologic correlates of their aggressive biology. Although nothing is known about the precursor lesion of this group, we speculate that the CIMP-H group (43%) also arises via the SSP, while in the CIMP-0/L group (57%) *BRAF* mutation may arise at a later stage of neoplastic progression.

#### 747 HER2 Protein Overexpression and Gene Amplification in Colorectal Adenocarcinomas

*Y Sun, L Zhou, D Cao.* Peking University Cancer Hospital, Beijing, China.

**Background:** HER2 serves as a prototype of targeted therapy in which Trastuzumab, a human monoclonal antibody, is used to treat breast and gastric carcinomas with HER2 protein overexpression and gene amplification. Colorectal adenocarcinoma (CRC) is one of the leading causes in the world, but there is little data on HER2 protein overexpression/gene amplification in CRCs. Here we investigated the prevalence of HER2 protein overexpression and gene amplification in a large series of surgically resected CRCs. We determined the concordance rate between HER2 protein overexpression determined by immunohistochemical staining (IHC) and HER2 gene amplification determined by Fluorescence in situ hybridization (FISH).

**Design:** 1197 consecutive surgically resected CRCs between 2009 and 2012 were included. One representative paraffin block from each case was used for HER2 IHC staining with a rabbit monoclonal antibody (Clone 4B5, prediluted, Ventana PATHWAY) and FISH study using the PathVysion HER2 DNA probe kit (Vysis/Abbott, Abbott Park, Illinois). The IHC staining was scored: 0 (no staining or membranous staining in less than 10% tumor cells), 1+ (faint/barely visible membranous staining in at least 10% cells or staining in part of their membrane), 2+ (weak to moderate complete or basolateral membranous staining in at least 10% tumor cells), 3+ (strong complete or basolateral membranous staining in at least 10% tumor cells). The total numbers of HER2 and CEP17 signals were counted in at least 20 tumor cell nuclei in 2 different areas. The criteria for HER2 gene expression was defined as HER2 to CEP17 signal ratio at 2.0 or higher or presence of tight gene clusters.

**Results:** HER2 IHC score 3+, 2+, 1+ and 0 was seen in 31 (2.6%), 104 (8.7%), 477 (39.8%) and 585 (48.9%) tumors, respectively. Among the tumors with IHC 3+ and 2+ scores, the mean tumor cells with positive IHC staining was 90% (median 100%, range 40-100%) and 67% (median 75%, range 5-95%), respectively (p<0.05). HER2 gene amplification was seen in 24/29 (83%), unreadable in 2/31 tumors with IHC 3+, 5/25 (20%), unreadable in 2/27 tumors with IHC 2+, and 0 (0/10) tumors with IHC 1+ score. Among tumors with IHC 2+ score, those with HER2 gene amplification had a higher number of tumor cells with positive IHC staining (N=5, mean 93%, median 95%, range 90-95%) than those without (N=20, median 50%, range 5-95%) (p<0.05).

**Conclusions:** HER2 overexpression (IHC score 2+ and 3+) is seen in a small percentage of colorectal adenocarcinomas. HER2 gene amplification occurs in the vast majority of tumors with 3+ IHC score but in a much lower percentage of tumors with 2+ IHC score.

#### 748 ARID1A Expression and Association with Mismatch Repair Gene Status in Gastric Carcinomas

*K Sy, S Hafezi-Bakhtiari, SJ Catherine, CA Blaise.* University of Toronto, Toronto, ON, Canada; University Health Network, Toronto, ON, Canada; St. Michael's Hospital, Toronto, ON, Canada.

**Background:** ARID1A, a tumor suppressor gene is an important component of the multiprotein SW1/SNF chromatin remodeling complex which has multiple cellular functions including DNA repair. Loss of ARID1A has been described in gastric carcinoma(GC) and has been associated with poor outcome. In this study, we analyze expression of ARID1A and its correlation with mismatch repair gene (MMR) status and patients' clinical parameters in patients with GC.

**Design:** 113 resection specimens of invasive GC (2000-2011) were identified and a duplicate core tissue microarray (TMA) constructed. Tumor histomorphology and patient follow up data were retrieved. The TMA was interrogated for ARID1A and MMR protein (MLH1, MSH2, MSH6, and PMS2) expression.

**Results:** The mean patient age was 66.1 years and 31 patients were Asian. 19 /113 (16.9%) of the carcinomas were located in the proximal stomach. 25/113 (22.1%) patients were diagnosed as early Stage disease (T1). 61.1% of cases were intestinal-type carcinoma, 29.2% diffuse-type, 8.0% mixed carcinomas and 1.8% of cases were undifferentiated carcinomas. Follow-up data was available in 108/113 patients with a mean of 34 months (range: 1-128 months). 25/113 (22.1%) cases showed loss of expression of both MLH1 and PMS2 with a single case (0.9%) showing loss of both MSH2 and MSH6. 20/104 (19.3%) cases showed loss of ARID1A staining. (See Table 1) Loss of ARID1A expression was significantly associated with older age and loss of MLH1 expression. Patients with loss of ARID1A expression had a significantly worse

mean survival (1.46 years) than those with normal expression (3.80 years). Multi-variate analysis indicates that tumor stage and ARID1A expression are independent prognostic factors in this patient cohort.

Correlation of clinicopathologic parameters with ARID1A expression in gastric carcinomas

	ARID1 LOSS	ARID1 INTACT	P-VALUE
SEX			
MALE	11	54	0.453
FEMALE	9	30	
AGE (years+/-standard deviation)	72.6+/-3.0	64.4+/-1.5	0.016*
ETHNICITY			
ASIAN	7	26	0.791
NON-ASIAN	13	58	
STAGE			
EARLY (T1)	3	18	0.758
ADVANCED	17	66	
HISTOLOGIC TYPE			
INTESTINAL	12	52	1.000
NON-INTESTINAL	8	32	
MLHI			
LOSS	10	13	0.002*
INTACT	10	71	
MEAN SURVIVAL (years+/-standard deviation)	1.46+/-0.21	3.53+/-0.20	0.004*

**Conclusions:** Loss of ARID1A expression is significantly associated with loss of MLH1 expression in gastric carcinomas. Loss of ARID1A expression is an independent poor prognostic factor in this cohort of patients with gastric carcinomas.

#### 749 Amplification of the Genes on Chromosome 19q13.3 Represents the Signature Molecular Event Predicting the Clinical Outcome of Gastric Adenocarcinoma

D Tan, T Khour. MD Anderson Cancer Center, Houston, TX.

**Background:** A handful evidence suggests that multiple genetic alterations are involved in the complex carcinogenic process of gastric adenocarcinoma (GAC). Although a number of genetic changes have been reported in GAC, including amplification of *c-MET* and *FGFR2*, and mutations of *CDH1* and *KRAS*, the molecular events leading to GAC and its progression remain largely unknown. To assess global molecular changes in GAC, we use high thorough-put whole genomic assay to evaluate human GAC samples.

**Design:** Oligonucleotide array comparative genomic hybridization (aCGH) was performed on 48 GAC samples using a high-density (244K) aCGH method (Agilent Technologies). For each aCGH probe, each sample was classified as having normal, gained, or lost DNA copy number based on log 2 ratio thresholds of 0.15. An independent set of tissue arrayed samples (n=77) was further validated by fluorescent in-situ hybridization (FISH) by using probes visualizing 19q13.3 (red signal) and the centromere (green signal). Amplification of 19q13.3 was defined if the ratio of 19q13.3 to centromere is greater than 2.2. The mean patient's survival follow-up time was 76 months.

**Results:** aCGH identified 1271 genes with DNA copy loss and 1449 genes with DNA copy gain in gastric cancer. Among these identified genes, 11 deleted and 198 amplified genes were observed to have significant association with patient's survival. Forty-eight of amplified genes were specifically located on chromosome 19q13.3, including *CRX*, *DACT3*, *DKK1*, *EHD2*, *EMP3*, *HIF3A*, *HRC*, *IGFL2*, *IGFL3*, *KPTN*, *LIG1*, *PNKP*, and *PTOVI*. Compared with all other patients, those (n=16) with gene amplification on 19q13.3 had a significantly poorer prognosis (p<0.01), independent of other conventional prognosis factors including TNM stage. These results were further confirmed by FISH method and amplification of 19q13.3 was identified in 20 cases with unfavorable clinical outcome.

**Conclusions:** This genome-wide study identified a panel of critical genes associated with progression of GAC. Amplification of the genes on chromosome 19q13.3, a possible signature event in gastric carcinogenesis, represents a potentially useful prognostic biomarker for this aggressive malignancy. Relevant functional studies are to be confirmed the potential value of these genes in the management of gastric cancer.

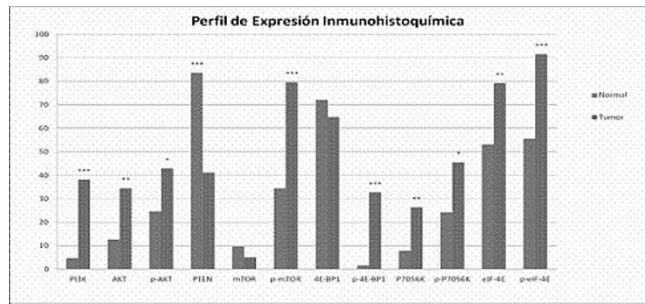
#### 750 Level of miR-125B and miR-451 and Deregulated Expression of PI3K/AKT/mTOR Pathway in Gastric Cancer

O Tapia, I Riquelme, A Sandoval, P Letelier, P Leal, JC Roa. University of La Frontera, Temuco, Chile.

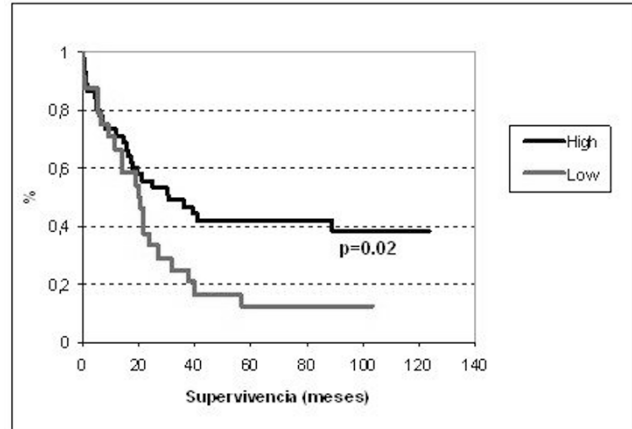
**Background:** Gastric cancer (GC) is the second most lethal malignancy worldwide and the leading cause of death relating to neoplastic disease in Chile. Authors have reported that PI3K/AKT/mTOR pathway could play an important role in the development of GC, moreover, some microRNAs (miRs) could regulate post-transcriptionally the gene expression of this pathway. The aim of this study was to evaluate both the protein expression of the components of PI3K/AKT/mTOR pathway by immunohistochemistry (IHC) and the expression of miR-125b and miR-451 in a cohort of GC cases.

**Design:** The protein expression of PI3K/AKT/mTOR was performed by IHC in Tissue microarray of 71 tumors and 71 normal tissues from patients with GC. The proteins were PI3K, PTEN, AKT, phospho-AKT, mTOR, phospho-mTOR, p70S6K, phospho-p70S6K, 4E-BP1, phospho-4E-BP1, eIF4E and phospho-eIF4E. Then the expression of miR-125b and miR-451 was analyzed in 22 hispanic/american GC and 22 control normal using TaqMan® miRNA assays qRT-PCR in these fresh frozen tissues.

**Results:** High protein expression was found for 9 the 12 proteins in tumor tissue compared with normal tissue (p<0,05).



Conversely, a high expression of PTEN was found in normal tissues (p<0.001). Kaplan-Meier analysis exhibited a poor survival in those patients with low expression of 4E-BP1 (p<0,05).



In miRs analysis, a downregulation of miR-125b and miR-451 was observed in tumor tissues vs paired normal mucosa (p<0.05).

**Conclusions:** These data show that PI3K/AKT/mTOR pathway is activated in tumor tissues of GC and that 4E-BP1 could be a potential prognosis biomarker in this cancer. Moreover, the downregulation of miR-125b and miR-451 suggests an important role of these miRs in carcinogenesis probably targeting AKT and TSC1 within PI3K/AKT/mTOR pathway. These data could be an initial approach to promote a new therapy strategy on this pathway.

#### 751 Ki67 Proliferative Index: A Sensitive Indicator of Prognosis in Gastric Neuroendocrine Neoplasms

H Tatli Dogan, A Kilicarslan, S Balci, O Basaran Aydogdu, G Guler. Yildirim Beyazit University, Ankara, Turkey.

**Background:** Gastric neuroendocrine neoplasms (GNEN) display a diverse spectrum of clinical behavior. It is not easy to predict the clinical course of the disease because of wide variation in their potential to metastasize and progress. We aimed to search the association of Ki67 index with tumor size, mitotic rate, presence of lymphovascular invasion and distant metastasis.

**Design:** A retrospective study was performed by reviewing data for surgically and endoscopically resected GNENs from pathology database between 2007 to 2012. Mitotic count in 10 HPF's and Ki67 proliferation index, as a percentage of 500 cells are counted in areas of strongest nuclear labeling. Grading is reevaluated according to WHO 2010 gastrointestinal NET classification. Localization of the tumor, multifocality, metastasis, lymphovascular invasion, and adjacent intestinal metaplasia are also noted.

**Results:** 30 GNENs were identified among 80 gastroenteropancreatic neuroendocrine tumors. In GNENs the mean age of the patients was 56,53 ± 13,001 (range 31-81). There was a slight female predominance (16 F, 14 M). Intestinal metaplasia and atrophic gastritis were found in 46,7%, multifocality was found in 33% of the cases. 16 (53,3%) of the cases were in corpus, 7 (23,3%) in antrum, 4 (13,3%) in fundus. The localisation of 3 were unknown. 16 (53,3%) of 30 cases were grade 1, 7 (23,3%) grade 2, and 7 (23,3%) poorly differentiated neuroendocrine carcinoma (PDNEC). There was a positive correlation between Ki67 index and mitosis (r<sup>2</sup>=0.914, p<0.001). We analysed Ki67 index association with different cutoff values. Tumor size was greater (average: 4,8cm) in Ki67>10% group, compared with Ki67< 10% ones (p<0,001). Lymphovascular invasion (LVI) and liver metastasis were seen only in cases with Ki67>2% (p=0,002). 5 of the 6 cases with LVI had >10% Ki67 indices.

**Conclusions:** Ki67 index is a sensitive indicator of aggressive behaviour. Our data indicate that LVI is seen in 83,3% of patients with Ki67 index >10% whereas in 54% of patients with Ki67 index >2%. Further studies including more patients are needed to test different Ki67 cut off values on prognosis of GNENs.

**752 Molecular, Histologic and Clinical Features of Persistent Intestinal Spirochetosis**

*K Threlkeld, T Trainer, C Adamson, M Evans, R Wilcox.* University of Vermont, Burlington, VT.

**Background:** Although human intestinal spirochetosis (IS) is a well-documented entity, its clinical significance remains controversial. *Brachyspira aalborgi* and *pilosicoli* are the species most commonly associated with human IS. We performed a retrospective analysis of colorectal biopsies in patients found to have persistent IS with the goal of highlighting molecular, histologic and clinical features.

**Design:** We identified all pts diagnosed with IS in our institution over the last 11 yrs. Of these pts, those with at least one additional lower GI specimen in our database were defined as study patients. Retrospective exam of study slides (documenting IS, associated histology, recognition of IS in SP reports) and clinical data (reason to biopsy, symptoms, additional diagnoses, immune status) was performed. Primary molecular detection was achieved by amplifying species-specific portion of 16S ribosomal RNA. Non-amplified cases were tested for viable DNA using  $\beta$ -globin.

**Results:** 29 pts (70 biopsies) had persistent (2mo-14yr) IS (66% male; 35-91 yrs; mean 57.9 yrs). In 32/70 biopsies (46%), IS was identified by H&E and on retrospective review only (not documented in SP report). 8/29 pts had a history of immunosuppression (treated IBD, carcinoma, lymphoma). Reason to biopsy, associated histology and causative species are summarized in Table 1. The 9 samples (17%) positive for IS on H&E but not amplified by PCR all had additional biopsies that speciated as *B. aalborgi*. 27 additional pts had "non-persistent" IS (IS at one point in time with negative prior or subsequent colorectal biopsies). These cases all typed as *B. aalborgi* with an exception of one *B. pilosicoli*. The pt with *B. pilosicoli* was a homosexual male with diarrhea and active colitis.

Findings in 29 Patients (70 biopsies) With Persistent IS

Reason to Biopsy	Histology*	Species
Screening	WDA	59% <i>B. aalborgi</i> 83%
Diarrhea/R/O Microscopic Colitis	Polyp: HP	33% Non-Amplified 17%
Heme + Stool	Polyp: TA	9%
Unknown	Active Colitis	6%
IBD Surveillance	Polyp: SSA	4%
Hx of Colitis	Polyp: TVA	1%
Other	Chronic Active Colitis	1%

\*Refers to area directly involved by IS

**Conclusions:** In our 29 pts with persistent IS, the overwhelming majority were asymptomatic/non-immunocompromised. In fact, 5 of the 8 immunocompromised pts were found to have IS in biopsies prior to their immunocompromised state. *B. aalborgi* was the only species isolated in all persistent IS cases. In this study population, *B. aalborgi* appears to be a colonizer rather than a pathogen and may be more common than reported as it is often found in asymptomatic "low-power diagnoses" (e.g. HPs in screening colonoscopies).

**753 Fundic Gland Polyps with Dysplasia: Prevalence and Risk Factors**

*D Torrence, M Balakrishnan, R Yantiss, S Lagarde, J Gibson, D Jain.* Yale School of Medicine, New Haven, CT; Weill Medical College of Cornell University, New York, NY; Yale New Haven Hospital, New Haven, CT.

**Background:** Dysplasia in fundic gland polyps (FGP) is uncommon and has been previously recognized in familial polyposis syndrome (FAP). However, the prevalence and significance of dysplasia in sporadic FGP have not been well studied. The goal of the study was to estimate the prevalence of and characterize the histologic features of dysplasia in sporadic FGPs and identify any risk factors, such as proton pump inhibitors (PPI) and non-steroidal anti-inflammatory drugs (NSAID).

**Design:** The institutional pathology database was searched for FGPs with dysplasia (FGP-D) diagnosed between 1994-2012. Detailed histopathologic assessment was performed, including evaluation of the morphologic features of dysplasia, background gastric mucosal changes, H. pylori status and presence of intestinal metaplasia. Duration of medication use, including PPI and NSAID, was recorded, when available. Similar number of age and gender matched patients who had FGPs without dysplasia was also evaluated. Patients with FAP were excluded.

**Results:** A total of 28 FGP-D were identified during the study period, out of a total of 1934 FGPs, in 28 patients. Patient mean age was 55.1 years and 9/28 were men. 3/28 (10.7%) patients were diagnosed before and 25/28 (89.3%) after the year 2000. Histologically, the dysplasia resembled the recently described foveolar-type dysplasia and was characterized by the presence of nuclear hyperchromasia, enlargement and crowding, as well as increased mitoses and minimal to no surface maturation. None of the FGP-D showed intestinal metaplasia, H. pylori, intestinal type or high grade dysplasia or carcinoma. Three patients (10.7%) with FGP-D had documented use of PPI (n=3) and NSAID (n=2).

**Conclusions:** Dysplasia in FGPs is uncommon, occurs in 1.4% of FGPs, and is morphologically characterized by low grade foveolar dysplasia-type histology. The increase of FGP-D is attributable at least in part due to increasing number of endoscopies and biopsies performed. Use of PPIs has been associated with increased incidence of FGPs, but evidence linking PPIs and/or NSAIDs to dysplasia is lacking. Although there is no evidence so far to suggest that FGP-D increases risk of gastric cancer, the relationship of FGP, with or without dysplasia, to fundic gland carcinoma, a recently described unique gastric carcinoma variant, remains unknown and needs further study.

**754 Intratumoral Genetic Heterogeneity: A Frequent Finding in Gastric Carcinoma**

*AD Treacy, A Grin, CJ Streutker.* St. Michael's Hospital, Toronto, Canada.

**Background:** Gastric and gastroesophageal junction (GEJ) adenocarcinoma has been shown to display significant heterogeneity in HER2 protein expression by immunohistochemistry (IHC). Genetic heterogeneity may also be seen in HER2 gene amplification. This may have important clinical implications in identifying a subpopulation of tumor cells that are responsive to treatment. Genetic heterogeneity is not well defined or well studied in gastric/GEJ tumors. In breast carcinoma, intratumoral heterogeneity has been defined as a tumor showing at least 5% but <50% of tumor nuclei with a ratio of >2.2. Our study's aim was to evaluate the frequency and distribution of intratumoral genetic heterogeneity in gastric/GEJ tumors.

**Design:** We identified 360 consecutive gastric/GEJ tumors tested for HER2 by IHC and in situ hybridization (ISH) (Dual ISH, Ventana) from Nov. 2011-Sept. 2012. At least 20 nuclei were scored, with counts focused within IHC positive areas. In order to identify intratumoral heterogeneity, individual tumor cell HER2/CEP17 ratios were calculated for each case and the percentage of tumor cells with a ratio  $\geq 2.0$  (gastric/GEJ criteria) determined. Adapting the recommended breast criteria, a tumor was considered genetically heterogenous if at least 5% but <50% of tumor nuclei had a ratio of  $\geq 2.0$ . The tumor was considered amplified if the overall HER2/CEP17 was  $\geq 2$ .

**Results:** 57 cases (15.8%) were HER2 amplified (overall HER2/CEP17 ratio  $\geq 2.0$ ). The percentage of amplified nuclei was compared between the two groups. Whilst the majority of amplified cases showed >50% amplified tumor cells, five (9%) were genetically heterogenous (4 of 5 were 3+ on IHC, ratios 2.0 - 2.5). Interestingly, 97% (293/303) of non-amplified cases showed genetic heterogeneity as per breast criteria. 10 non-amplified cases had >50% amplified cells (5 cases were 0+, 2 cases were 1+ and 3 cases were 2+ on IHC, ratios 1.36 - 1.81). Furthermore, 21 non-amplified cases (overall ratios 1.21 - 1.75) contained 40-49% amplified cells.

**Conclusions:** Gastric/GEJ tumors show considerable intratumoral genetic heterogeneity when breast criteria are applied as a single amplified nucleus meets diagnostic threshold. Scattered amplified cells can be found in the majority of non-amplified cases. Many non-amplified tumors also contained  $\geq 40\%$  amplified cells, a finding that may reflect ambiguous classification and requires further study. Since breast criteria for genetic heterogeneity have not been robustly tested in gastric/GEJ tumors we would advocate further evaluation prior to adopting this definition.

**755 Methylguanine Methyltransferase (MGMT) Expression in Neuroendocrine Tumors of the Gastrointestinal Tract and Pancreas**

*A Treece, L Council, J Posey III, S Harada.* University of Alabama, Birmingham, AL.

**Background:** Methylguanine methyltransferase (MGMT) is a tumor suppressor gene located on chromosome 10 that removes adducts from O<sup>6</sup>-guanine in DNA which could result in cell death or carcinogenesis. Loss of expression, often by hypermethylation of promoter regions, has been documented in several cancers. MGMT methylation has been associated with longer survival in patients with glioblastoma multiforme undergoing treatment with temozolomide. Loss of MGMT confers less resistance to chemotherapeutic alkylating agents, thus increasing treatment efficacy. Currently, there is no extensive examination of the role of MGMT expression in neuroendocrine tumors. We undertook immunohistochemical study of MGMT expression in gastrointestinal (GI) and pancreatic neuroendocrine biopsy and resection specimens.

**Design:** Search of the patient electronic medical record identified 116 patients over the past five years with neuroendocrine tumors for which paraffin blocks were available. From these, seventy GI tract and pancreatic neuroendocrine tumor specimens (from 69 patients) were retrieved. Immunohistochemical staining was performed using the MGMT antibody and slides were reviewed by two pathologists. Low MGMT expression was defined as IHC intensity of 1 or overall staining present in 50% or less of the tumor cells. High MGMT expression was defined as IHC intensity of 2 or 3 and overall staining greater than 50%. Patient demographic and outcome data was extracted from the electronic medical record and analyzed.

**Results:** Of the 70 specimens, 65 had evaluable MGMT IHC staining. Low MGMT expression was seen in 35 of 65 cases (54%) and was not significantly associated with age, sex, or race. Recurrence was present in 9 of the low expression cases versus 2 of the high expression cases (p=0.021). Cases with tumor stage of 4 trended toward lower expression, but results were not statistically significant (p=0.066). Tumor grade and presence of metastases were not significantly associated with MGMT expression.

**Conclusions:** These results suggest that loss of MGMT expression may be associated with more aggressive neuroendocrine tumors of the GI tract and pancreas. Though recurrence was the only characteristic that had a significant association with MGMT expression, higher tumor grade, tumor stage greater than 1, and presence of metastases were all more common in cases with lower MGMT expression. This may reach statistical significance with a greater number of cases. Further studies including analysis of tumors from other sites and correlation with MGMT methylation status are needed.

**756 Plexiform Fibromyxoma of the Gastric Antrum: Clinicopathologic and Molecular Characterization of 5 Cases**

*M Tripathi, H Li Chang, D Divaris, R Pace, E Szentgyorgyi, A Grin, B Dickson, A Pollett, C Streutker, R Riddell, R Kirsch.* St. Michael's Hospital, Toronto, ON, Canada; Mount Sinai Hospital, Toronto, ON, Canada; Grand River Hospital, Toronto, ON, Canada; Toronto General Hospital, University Health Network, Toronto, ON, Canada.

**Background:** Plexiform fibromyxoma is a recently described distinctive, mesenchymal neoplasm of the gastric antrum, which may be confused with a myxoid GIST, neurofibroma or inflammatory fibroid polyp. To date less than 20 cases have been reported. Limited follow-up data suggests that this tumor is benign. We report five additional cases with detailed clinicopathologic, histomorphological & molecular characterization.

**Design:** Five cases of plexiform fibromyxoma were retrieved from the consult files of 3 major academic centers in Toronto. Resection specimens were available on all cases. Clinicopathologic, histologic, immunohistochemical and molecular characteristics of these tumors were documented.

**Results:** Patients included three females & two males with an age range of 39 to 83 years (median age: 49). Presenting symptoms included epigastric discomfort & pain (n=4) and massive upper GI hemorrhage (n=1). All tumors involved the gastric antrum and one case also involved the first part of the duodenum. One case was associated with an incidental small intestinal GIST. Histologically, all five cases demonstrated a distinctive multinodular plexiform growth pattern which dissected through the muscularis propria. The tumors were composed of spindle to oval cells in a variably myxoid to collagenised stroma. A delicate arborizing vascular network was seen in 4 cases. Distinctive pseudolacunar spaces surrounded by a delicate fibrous meshwork were identified in 3 cases. Immunohistochemically all five cases were strongly positive for smooth muscle actin but negative for desmin, CD117 and DOG-1 and one showed patchy CD10 positivity. Of the 4 cases tested for KIT and PDGFRA mutations, all showed wild-type DNA sequences.

**Conclusions:** We describe a series of five plexiform fibromyxomas with similar clinical, morphologic, immunohistochemical and molecular features to the limited number previously reported. Awareness of its distinctive topographic, morphologic and immunohistochemical features should readily facilitate its distinction from potential mimics including myxoid GIST, inflammatory fibroid polyp and neurofibroma.

### 757 Importance of Stromal Desmoplasia in Staging Early Esophageal Adenocarcinoma on Endoscopic Mucosal Resection Specimens

M Tripathi, A Grin, C Streutker. St. Michael's Hospital, Toronto, ON, Canada.

**Background:** One of the important challenges in assessing endoscopic mucosal resection specimens is to provide accurate depth of invasion and presence or absence of submucosal invasion. This distinction is crucial as submucosal invasion generally indicates a need for esophagectomy, but may be very difficult in cases where submucosal glands or vessels are not present to define the presence of submucosal tissue. It is a common perception that presence of stromal desmoplasia usually signifies submucosal invasion and that it is absent or poorly developed at the intramucosal stage of invasion. However, to date no studies have documented the incidence and frequency of stromal desmoplasia in esophageal adenocarcinomas.

**Design:** In this study we retrospectively reviewed a cohort of 60 endoscopically resected cases of early esophageal adenocarcinomas to evaluate tumor differentiation & depth of invasion with presence or absence of stromal desmoplasia. Histologically, desmoplastic response was defined by presence of large stromal cells with increased loose extracellular matrix. If present, desmoplasia was graded as mild, moderate or extensive by three gastrointestinal pathologists. Based on the depth of invasion, the cases included in the study were sub-classified as- M1/2 (lamina propria or superficial muscularis mucosae invasion, n=17), M3 (invasion between the layers of duplicated and true muscularis mucosae, n=7), M4 (true muscularis mucosae invasion, n=17) & SM1 (early submucosal invasion, n=23).

**Results:** Patient age range was 39-90 years (M:F=51:9). 91% of submucosal invasive tumors had at least focal desmoplasia (Mild 47.7%, Moderate 26%, Extensive 17.3%). Within the intramucosal tumors, 40% had a mild to moderate degree of desmoplasia (Mild 24%, Moderate 16%). All of these were deep mucosal tumors (M3/M4) with moderate to poor differentiation. None of the superficial intramucosal tumors (M1/2) showed any desmoplasia and none of the deep intramucosal tumors (M3/4) had extensive desmoplasia.

**Conclusions:** Stromal desmoplasia is not conclusively limited to the submucosal invasive tumors. Moderate to poorly differentiated deep intramucosal tumors may also develop a degree of stromal desmoplasia. The finding of desmoplasia can therefore not be used as an absolute indicator of submucosal invasion, as it may be present in intramucosal lesions and focal or absent in some tumours definitively invading submucosal tissue. These findings may aid in the assessment of depth of invasion which is a deciding factor for further surgical therapy for patients with early esophageal carcinomas.

### 758 Diagnosis of IgG4-Related Disease: No Longer an IS(H)-Sue?

JY Tse, N Riggi, DT Ting, JH Stone, M Rivera, V Deshpande. Massachusetts General Hospital, Boston, MA.

**Background:** IgG4-related disease (IgG4-RD) is a tumefactive fibroinflammatory disease with elevated levels of serum and tissue IgG4. A histologic diagnosis of IgG4-RD requires the presence of elevated numbers of IgG4-positive plasma cells and an elevated IgG4 to IgG ratio (>40%). However, immunohistochemical (IHC) stains for IgG4 and IgG are frequently associated with high background signal, an artifact that makes quantitative analysis difficult. RNA in-situ hybridization (ISH) offers an attractive alternative assay to quantitate expression of genes that are challenging for IHC, however, this method has historically been difficult to perform in a reliable fashion. Recently developed branched DNA (bDNA) technology has overcome this limitation of RNA ISH and has been successfully applied to formalin-fixed, paraffin-embedded tissue, providing a novel clinical diagnostic.

**Design:** Modified bDNA ISH probes were developed for IgG4 and IgG with Affymetrix QuantiGene ViewRNA technology. The probe for IgG4 was based on a sequence unique to this isotype, while the probe for IgG was based on a sequence common to all isotypes as identified in the NCBI nucleotide database. We evaluated 14 cases of IgG4-RD and 30 control cases that mimicked IgG4-RD either clinically or histopathologically, including biopsies from all sites known to be involved by the disease. IHC analysis for IgG4 and IgG was also performed. Three high power fields (HPF) were counted on the ISH and IHC stains and the results expressed per HPF.

**Results:** ISH stains for IgG4 and IgG showed strong signal in plasma cells without background. This high quality signal was also seen in the 14 cases in which IHC stains for IgG4 and/or IgG showed strong background staining that precluded quantitative evaluation. The mean number of IgG4-positive cells per HPF by ISH was 23.42, and 27.24 by IHC (p-value = 0.17). The mean number of IgG-positive cells per HPF by ISH was 104.6, and 80.6 by IHC (p-value = 0.006). The mean IgG4 to IgG ratio by ISH was 0.17, and 0.32 by IHC (p-value = 0.001). The IgG4 counts and IgG4 to IgG ratio quantified by ISH provided a more robust distinction of IgG4-RD from cases mimicking IgG4-RD. Also significantly, IgG4-positive lymphocytes were identified in 5 of 14 cases of IgG4-RD, but in only 1 of the 30 control cases.

**Conclusions:** ISH stains for IgG4 and IgG provide a high signal to noise ratio, increasing the accuracy of quantitative evaluation. The IgG counts performed by ISH tend to be lower than by IHC. Our data also suggests the presence of IgG4-positive lymphocytes in tissue may represent an additional marker for distinguishing IgG4-RD from its mimics.

### 759 Upregulation of A20 Is Induced by Helicobacter pylori Infection in Gastric Epithelial Cells

T Uchida, LT Nguyen, M Moriyama. Oita University, Yufu, Oita, Japan; 108 Hospital, Hanoi, Viet Nam.

**Background:** A20 is well known as a NF- $\kappa$ B suppressor and proapoptotic protein. NF- $\kappa$ B pathway activation caused by *H. pylori* infection induces inflammatory responses from host cells. However, the process by which gastric epithelial cells counteract *H. pylori* induced-NF- $\kappa$ B activation to avoid overreactions has not well analyzed yet. In this study, we investigated the role of A20 in *H. pylori*-gastric epithelium interaction. **Design:** Gastric epithelial cell lines; AGS cell and MKN 45 cell were used. *H. pylori* were infected to gastric epithelial cells at MOI=100. A20 expression was analyzed by real-time RCR. NF- $\kappa$ B activation were quantified by luciferase assay. IL-8 concentration in supernatant were measured by ELISA.

**Results:** Upon *H. pylori* infection, A20 was upregulated in a time- and MOI-dependent manner. A20 mRNA increased sharply within 3 hours and then decreased gradually to the baseline after 36 hours. The induction of A20 by *H. pylori* depended on type IV secretion system as *cagE* and *cagPAI* mutants of *H. pylori* lost almost all the ability to induce A20. Nevertheless, *cagA* mutant strain is still able to trigger A20 upregulation but this ability was reduced considerably, indicating that A20 induction was partly *cagA*-dependent. Because *H. pylori* injects CagA protein and its peptidoglycan into the host cell via type IV secretion system. Transfection of *cagA* vector and *H. pylori* peptidoglycan resulted in a significant increase of A20 expression. We overexpressed A20 in gastric cells and infected them with *H. pylori*. We saw that the activation of NF- $\kappa$ B in these cells was suppressed significantly. Similarly, the knock-down of A20 by siRNA increase NF- $\kappa$ B activation dramatically.

**Conclusions:** These findings indicate that *H. pylori* induces A20 expression in host cell to restrain *H. pylori*-activated NF- $\kappa$ B. This negative feed-back loop will establish the balance between host and infectant.

### 760 Focally Enhanced Gastritis in Pediatric Inflammatory Bowel Disease: Patterns, Associations and Significance

T Ushiku, CJ Moran, GY Lauwers. Massachusetts General Hospital, Boston, MA.

**Background:** Upper gastrointestinal manifestations of inflammatory bowel disease (IBD) are well established, particularly in Crohn's disease (CD). Although focally enhanced gastritis (FEG) is thought to be a characteristic gastric manifestation of IBD, most studies focus predominantly on adults. This study aims to describe detailed histological features of upper gastrointestinal manifestations of IBD including FEG in pediatric patients.

**Design:** We selected 119 consecutive pediatric patients (1-20 years old) with confirmed IBD (62 CD and 57 ulcerative colitis [UC]), who underwent both upper and lower gastrointestinal biopsies before therapy was initiated. Upper GI biopsies from age-matched healthy controls (n=66) were also evaluated. Histological review, blinded to the final diagnosis, was performed to determine the incidence of FEG and its relationship to age group and other histologic findings.

**Results:** FEG was present in 43% of IBD patients (CD 55% vs. UC 30%, p=0.0092) and in 5% of controls. Among CD patients, the frequency of FEG was higher in younger patients (73% at age  $\leq$ 10, 43% at age >10, p=0.0358) with peak in the 5-10 years age-group (80%). In addition, the presence of FEG was significantly associated with the identification of granulomas in the entire gastrointestinal tract (p=0.0006). Comparing CD patients with and without FEG, the prevalence rate of active small bowel inflammation (presence of active duodenitis or ileitis) was higher in patients with FEG (62% vs. 36%, p=0.0412). Furthermore, the total number of glands involved in FEG foci was significantly higher in UC (6.4 $\pm$ 5.1 glands) than in CD (4.0 $\pm$ 3.0 glands, p=0.0465). Granulocytic infiltrates were more often observed in UC (47%) than in CD (24%), but this did not reach statistical significance. Finally, in UC patients, there was no correlation between the presence of FEG and other gastrointestinal findings, including the activity of proctocolitis.

**Conclusions:** We demonstrate that the differences in FEG between CD and UC relate not only to their frequencies, but also to their morphology and their relationship with other gastrointestinal findings. Notably, FEG is more common in younger patients. Furthermore, in pediatric CD, FEG may be an indicator of disease activity as its presence is commonly associated with small bowel disease.

**761 Very Well Differentiated Gastric Cancer of Intestinal Metaplasia-Type: A Systemic Analysis**

*T Ushiku, S Ban, T Arnason, T Hishima, M Fukayama, GY Lauwers.* Massachusetts General Hospital, Boston, MA; University of Tokyo, Tokyo, Japan; Saiseikai Kawaguchi General Hospital, Saitama, Japan; Tokyo Metropolitan Komagome Hospital, Tokyo, Japan.

**Background:** Very well differentiated gastric adenocarcinoma of intestinal metaplasia-type (VWDAIM) is a rare variant characterized by morphologic differentiation towards intestinal metaplasia (IM) and low-grade cytologic atypia. Because it mimics IM, a definite biopsy diagnosis is challenging. Small series have been published, but detailed diagnostic criteria and clinical behavior are not fully established.

**Design:** Slides from the resection specimens of 21 cases of VWDAIM were reviewed and their cytoarchitectural features recorded. Forty histologic pictures of benign IM and VWDAIM were also assessed by a blinded independent reviewer to determine the sensitivity & specificity of the diagnostic features of malignancy. Pre-resection biopsies from 19 cases were also evaluated.

**Results:** Characteristic architectural features of VWDAIM were branching (100%), tortuous (95%), anastomosing (95%), distended (90%), abortive (81%), spiky (76%), and budding (71%) glands. Cytologic atypia was mild in all cases (Figure 1). Sensitivity and specificity of these features for malignancy are shown in Table 1.

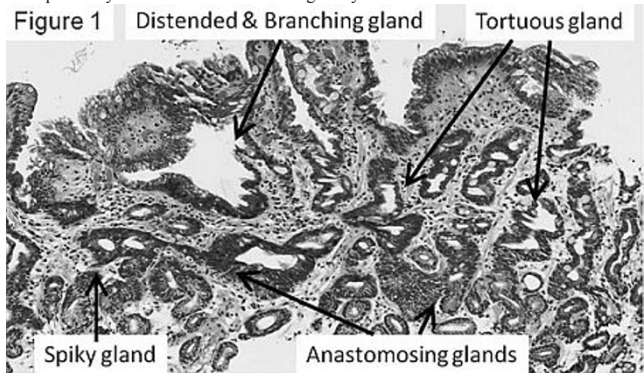


Table 1

Findings	VWDAIM (n=20)	IM (n=20)	p-value	Sensitivity	Specificity	Odds Ratio
Tortuous glands	10	12	0.7512	0.5	0.4	0.67
Branching glands	20	12	0.0033	1	0.4	-
Distended glands	17	6	0.0011	0.85	0.7	13.20
Abortive glands	9	0	0.0012	0.45	1	-
Anastomosing glands	17	2	<0.0001	0.85	0.9	51.0
Spiky glands	11	1	0.0012	0.55	0.95	23.2
Budding glands	16	0	<0.0001	0.8	1	-

The original preoperative biopsy diagnoses for 19 patients were adenocarcinoma (36%), suspicious for adenocarcinoma (14%), indeterminate for neoplasia (21%), and reactive IM (29%). One patient with a pT4 tumor showing concomitant diffuse-type carcinoma died of disease, while all others were alive and without disease at a mean 13 month follow-up (range 1-56 months).

**Conclusions:** The features that best differentiate VWDAIM from IM are anastomosing, spiky, abortive, and budding glands. However, a preoperative biopsy diagnosis is achieved in only 50% of the cases. Although VWDAIM is typically thought to be a low-grade cancer, rare cases are associated with diffuse-type carcinoma and have aggressive behavior.

**762 Immunohistochemical Detection of the BRAF V600E Mutant Protein in Colorectal Adenocarcinoma**

*E Vakiani, Y Zhou, DS Klimstra, J Shia.* Memorial Sloan-Kettering Cancer Center, New York, NY.

**Background:** Reliable assessment of the BRAF mutation status is becoming increasingly important in the clinical management of colorectal carcinomas (CRC). BRAF mutations occur in approximately 10% of CRC and the vast majority are characterized by a missense substitution of valine by glutamic acid at amino acid position 600 (V600E). The presence of BRAF V600E mutation can help guide targeted therapy as it is associated with resistance to EGFR inhibitors, while in microsatellite unstable cases it can differentiate sporadic from hereditary CRC. The aim of this study was to investigate the use of a recently developed mutation-specific antibody to detect expression of the BRAF V600E protein in routinely processed formalin-fixed paraffin-embedded (FFPE) tissue.

**Design:** We analyzed 49 FFPE cases (44 resections, 5 biopsies) that had been previously evaluated for the presence of BRAF mutations using a MALDI-TOF mass-spectrometry based genotyping assay. For the immunohistochemical detection of the mutant protein we used the BRAF V600E mutation-specific antibody VE1. Cases were evaluated by two pathologists who were blinded to the genetic data and were considered positive when there was distinct homogeneous cytoplasmic staining in the tumor cells.

**Results:** The analyzed cases included 1 sessile serrated polyp (SSP), 1 adenoma with intramucosal carcinoma, 24 primary invasive CRC and 23 metastases. Twenty three cases (47%), including the SSP, were scored as positive and all these cases were found to have the BRAF V600E mutation by genetic analysis. Twenty six (53%) cases including all biopsies were scored as negative; of those cases, 3 (11.5%) showed a BRAF V600E mutation based on DNA sequencing. The three discrepant cases included the adenoma

with intramucosal carcinoma and two resections of metastases; all three cases showed weak cytoplasmic staining that was not clearly different from a weak background staining. Two cases that showed a BRAF D594G mutation by genetic analysis were negative immunohistochemically, as expected.

**Conclusions:** Distinct and diffuse cytoplasmic staining with the BRAF V600E specific antibody VE1 appears to reliably predict for the presence of the BRAF V600E mutation in the tumor cells. Some cases, however, may show a weak staining reaction leading to false negative results. A larger number of cases needs to be analyzed to confirm these findings and to further explore the utility of immunohistochemistry in small specimens.

**763 Morphologic and Immunohistochemical Characteristics of Colonic Serrated Polyps with Dysplasia**

*K Viani, K Kim, A Srivastava, R Odze.* Brigham and Women's Hospital, Boston, MA; Samsung Medical Center, Sungkyunkwan University School of Medicine, Seoul, Korea.

**Background:** The serrated pathway of colon carcinogenesis proposes that some cancers develop via a sessile serrated adenoma/polyp (SSA/P) or a traditional serrated adenoma (TSA)-dysplasia-carcinoma sequence. The types of dysplasia that arise in benign serrated polyps, their grading, morphologic and immunohistochemical characteristics are poorly defined. The aim of this study was to evaluate the morphologic and selected immunohistochemical characteristics of serrated polyps with dysplasia to better define neoplastic progression in serrated polyps.

**Design:** 99 serrated polyps (61 SSA/P, 40 with dysplasia, 21 with no dysplasia; 38 TSA all with dysplasia) were evaluated for the type (serrated, adenomatous) and grade (low and high) of dysplasia according to predetermined objective pathologic criteria. All polyps were stained immunohistochemically for p53,  $\beta$ -catenin, p16, MIB1, MUC6, and MLH1 and scored as either positive or negative in the various types and grades of dysplasia in each polyp. MIB1 was scored in the superficial third of the polyp and scored as grade 1 = <25%, 2=25-50%, 3= $\geq$ 50% positive cells.

**Results:** In TSA, p53 showed increasing positivity in low (27%), and high-grade dysplasia (80%) (P<0.05). Nuclear  $\beta$ -catenin was present in 13% and p16 in 18% of TSA, both with values similar in low and high-grade dysplasia. In contrast, p53 was rarely positive in SSA/P (3% in low grade dysplasia; 0% in high grade dysplasia). p16 and  $\beta$ -catenin were negative in all SSA/P with or without dysplasia. MLH1 staining was lost in 10% of dysplastic SSA/P but was intact in all grade of dysplasia in TSA. MIB1 staining in both TSA and SSA/P showed a significant increase with increasing grade of dysplasia (P<0.05). MUC6 stained the majority of TSAs (82%) and SSPs (93%). No significant differences in staining patterns were observed between polyps located in the left and right colon or between serrated and conventional adenomatous dysplasia in each polyp group.

**Conclusions:** Our grading system of dysplasia suggests that hyperproliferation, p53,  $\beta$ -catenin, and p16 play a role in the progression of neoplasia in TSAs, whereas these abnormalities are not important in the progression of SSA/P. Serrated and adenomatous dysplasia appear to develop via a similar molecular pathway and both types likely portend a similar risk of cancer progression.

**764 Clinicopathologic Features of Ampullary Adenocarcinoma of Indeterminate Histologic Type (Non-Intestinal, Non-Biliary)**

*L Vila Duckworth, A Alkhasawneh, N Desai, X Lu, A Sommerfeld, T George, T Zuluaga Toro.* University of Florida, Gainesville, FL.

**Background:** Ampullary adenocarcinoma (CA) can be categorized morphologically into biliary and intestinal types. However, some cases fail to show classic morphologic features of either subtype. This study aims to describe the immunophenotypic and clinical characteristics of ampullary CA with indeterminate morphology.

**Design:** 63 cases of ampullary CA resected between 2000-2011 were assessed for CK7, CK17, CK20, SMAD4 and CDX2 expression by immunohistochemistry. Age, gender, tumor stage, and clinical outcome (death, recurrence) were recorded. Patients were divided into 3 groups based on tumor morphology: biliary (cuboidal lining), intestinal (columnar cells and/or cribriform architecture) or indeterminate (overlapping features or unusual morphology). CK7, CK17 and CK20 were interpreted as positive ( $\geq$ 5% reactivity) and negative (<5% reactivity). CDX2 was interpreted as homogeneous (strong nuclear staining in  $\geq$  75% of tumor), heterogeneous (weak nuclear staining in <75% of tumor), or absent. SMAD4 was interpreted as positive (strong staining in all or subset of tumor cells) and impaired (absent or weak reactivity relative to surrounding normal pancreas).

**Results:** 14 cases were of indeterminate subtype. The following staining profile was observed: 79% CK7 positive, 50% CK17 positive, 38% CK20 positive, 7% CDX2 positive, and 64% impaired SMAD4. 71% of these patients were stage T3/T4 and 57% had lymph node metastasis. Recurrence rate was 44% and death rate was 43% in patients with indeterminate tumors.

	Indeterminate (n=14)	Biliary (n=31)	Intestinal (n=18)
Mean age	65.5	69.3	68.1
Male: Female ratio	1	1.2	1.6
CK7 positive	11	29	9
CK17 positive	7	22	3
CK20 positive	5	3	15
CDX2 positive	1	15	1
Impaired SMAD4	9	24	8
Stage T1/T2	4	4	9
Stage T3/T4	10	27	9
Lymph node metastasis	8	17	4
Recurrence	4	8	1
Deceased	6	20	7

**Conclusions:** The immunophenotype of the indeterminate tumors more closely resembles the biliary subtype of ampullary CA (CK7 positive, heterogeneous to absent

CDX2, and impaired SMAD4). The clinical behavior of these tumors is intermediate between that of the biliary and intestinal subtypes, though closer to the biliary type.

### 765 The Pattern of CDX2 Expression in Ampullary Adenocarcinomas Predicts Biliary Versus Intestinal Phenotype: Prognostic Implications

*L Vila Duckworth, A Alkhasawneh, N Desai, A Sommerfeld, X Lu, T George, T Zuluaga Toro.* University of Florida, Gainesville, FL.

**Background:** CDX2 (caudal-related homeobox 2) is a nuclear transcription factor implicated in intestinal differentiation, and thus tumors with intestinal phenotype demonstrate CDX2 nuclear expression by immunohistochemistry (IHC) regardless of the organ of origin. We assessed the pattern of CDX2 expression in ampullary adenocarcinoma and its relation to different histologic subtypes and clinical parameters.

**Design:** Sixty-three cases of ampullary adenocarcinomas resected between 2000 and 2011 were assessed for CDX2 expression by IHC. Morphologic type (intestinal, biliary, or indeterminate), tumor stage, and measures of clinical outcome (death, recurrence) were recorded. Nuclear CDX2 expression was assessed as follows: negative (complete absence), heterogeneous (weak to moderate nuclear staining in <75% of tumor cells; pattern similar to background pancreas) and homogeneous (strong, diffuse nuclear staining in ≥75% of tumor cells; pattern similar to background duodenal epithelium) (adapted from Chu et al. 2005). For assessment of clinical outcome, only cases with homogeneous CDX2 expression were considered positive, while the negative and heterogeneous CDX2 cases were merged into one group.

**Results:** Seventeen cases were positive for CDX2 in a diffuse, homogeneous pattern, and 46 were CDX2 heterogeneous to absent. 88% of the CDX2 homogeneous cases were of intestinal subtype, while 93% of the heterogeneous to negative cases were either biliary or indeterminate subtype. Lymph node metastasis was significantly higher in the group with heterogeneous to absent CDX2 expression compared with cases with homogeneous CDX2 ( $p = 0.01$ ).

Table 1. Correlation of CDX2 patterns and morphologic subtypes

CDX2	Biliary	Intestinal	Indeterminate	Total
Negative	18	1	6	25
Heterogeneous	12	2	7	21
Homogeneous	1	15	1	17
Total	31	18	14	63

Table 2. CDX2 expression and clinicopathologic characteristics

	Homogeneous (n=17)	Heterogeneous/negative (n=46)
stage T1/T2	41% (7)	22% (10)
stage T3/T4	58% (10)	78% (36)
Lymph node involvement	12% (2)	37% (17)
Recurrence	6% (1)	28% (13)
Deceased	35% (6)	59% (27)

**Conclusions:** Diffuse, homogeneous expression of CDX2 is seen almost exclusively in intestinal type ampullary tumors. Heterogeneous and negative CDX2 patterns are usually seen in biliary and indeterminate tumors and correlate with higher tumor stage, lymph node metastasis, disease recurrence and death.

### 766 Ueno Method Substaging pT1 Colorectal Adenocarcinoma by Depth & Width Measurement: An Interobserver Study

*LM Wang, EP Fryer, P Gill, C Hughes, A Szuts, R Perera, R Chetty.* John Radcliffe Hospital Oxford University Hospital, Oxford, United Kingdom.

**Background:** Early pT1 polyp colorectal cancers (CRC) present challenges for accurate pathology substaging. The Haggitt and Kikuchi stages for pedunculated and sessile polyps respectively depend on polyp morphology and are often difficult to apply due to suboptimal specimen orientation or fragmentation. The Kikuchi method requires division of the submucosal region into thirds, requiring the presence of the muscularis propria, usually not included in endoscopic polypectomy or submucosal resection specimens. The European guidelines for quality assurance in CRC diagnosis suggest using the more objective approach by Ueno using depth and width beyond muscularis mucosae. We investigate the interobserver variability in the Ueno approach to early polyp CRC.

**Design:** The previous ten pT1 polyp CRC were identified by a search through the cellular pathology database. The section with the deepest advancing tumour edge for each polyp was selected. The slides were assessed by six GI pathologists and the depth and width of the invasive tumour in the submucosa were submitted independently. Results were recorded and agreement was assessed by Kendall's coefficient of concordance (KCC) and  $\kappa$  statistics. Polyp CRC is classified as high risk (HR) if depth  $\geq 2000\mu\text{m}$  or width  $\geq 4000\mu\text{m}$  and low risk (LR) if depth  $< 2000\mu\text{m}$  or width  $< 4000\mu\text{m}$ .

**Results:** Data for the depth and width are shown in table 1.

TABLE 1 Depth & Width of invasion: Mean  $\pm$  [SD] & range. 6 pathologists' collective data.

POLYPS	DEPTH OF INVASION ( $\mu\text{m}$ )		WIDTH OF INVASION ( $\mu\text{m}$ )	
	Mean $\pm$ [SD]	Range	Mean $\pm$ [SD]	Range
A	3883 $\pm$ 1120	3100	7070 $\pm$ 2600	5900
B	1033 $\pm$ 207	600	3217 $\pm$ 1415	4000
C	900 $\pm$ 963	2600	3050 $\pm$ 1694	4200
D	3367 $\pm$ 423	1000	3383 $\pm$ 483	1000
E	667 $\pm$ 207	500	1333 $\pm$ 378	1000
F	2233 $\pm$ 393	1000	4833 $\pm$ 1571	4500
G	2533 $\pm$ 903	2600	4400 $\pm$ 2510	7200
H	6783 $\pm$ 677	1800	14333 $\pm$ 1862	5000
I	3483 $\pm$ 1089	2800	5250 $\pm$ 3100	8100
J	5917 $\pm$ 1839	5100	8180 $\pm$ 2470	6300

The KCC for depth is 0.89 and width is 0.79. When polyp CRC are stratified into high and low risk categories based on depth, there is total agreement in 8 of ten cases,  $\kappa = 0.780$ . When based on width, only 4 of ten have complete agreement,  $\kappa = 0.403$ . Disagreement cases are listed in table 2.

TABLE 2 Disagreement cases

POLYPS	HR:LR
BY DEPTH	
C	1:5
G	4:2
BY WIDTH	
B	1:5
C	2:4
D	2:4
F	5:1
G	3:3
I	3:3

**Conclusions:** Ueno's method has the advantage of being independent of polyp morphology. Our study shows that there is great concordance amongst pathologists by depth measurement and allows good reproducibility in risk categorization of pT1 CRC. There is poor agreement when based on width, which should therefore be discouraged.

### 767 HER2 Status in Biopsy vs. Resection Specimens of Gastric and Gastroesophageal Adenocarcinoma - Is Tumour Heterogeneity a Problem?

*T Wang, ET Hsieh, P Henry, W Hanna, CJ Streutker, A Grin.* University of Toronto, Toronto, ON, Canada; Sunnybrook Health Sciences Centre, Toronto, ON, Canada; St. Michael's Hospital, Toronto, ON, Canada.

**Background:** In advanced gastric and gastroesophageal (GE) adenocarcinomas that overexpress HER2, treatment with trastuzumab confers a survival benefit. To select patients for treatment, HER2 status is evaluated by immunohistochemistry (IHC) and in situ hybridization. It has been noted that gastric and GE adenocarcinomas demonstrate heterogeneity in HER2 expression. Nonetheless, testing is often performed on biopsy specimens alone, which raises the issue of non-representative sampling. In this study, we investigated the correlation of HER2 status between matched biopsy and resection specimens as well as the role of tumour heterogeneity in contributing to discrepancy.

**Design:** A total of 121 patients with gastric and GE adenocarcinoma had tissue available from an initial biopsy and subsequent resection. HER2 (4B5, Ventana) IHC was performed and evaluated by the criteria established in the ToGA clinical trial. In situ hybridization (Ventana) was performed on equivocal (2+) cases by IHC in either the biopsy or resection. Tumour heterogeneity in positive cases was defined as less than 25% of tumour cells staining 3+ or 2+ in the resection.

**Results:** Most tumours were intestinal (61%), 18% were diffuse, and 21% were mixed subtype. HER2 was overexpressed in 16 tumours (13%), with an overall biopsy-resection concordance of 96.7%. Overexpression was not seen in any diffuse adenocarcinomas, and only in 1 mixed adenocarcinoma. Four cases were discrepant; 2 were positive on biopsy only, and 2 were positive on resection only. Significant tumour heterogeneity was seen in 2 of 4 discrepant cases, one of which was mixed subtype; heterogeneity was not present in any concordant case ( $p=0.05$ ). The average biopsy had 5.8 fragments in which 3.9 had tumour. However, in one discrepant case with a negative biopsy, only 1 of 7 fragments contained tumour.

**Conclusions:** Our study of gastric and GE junction adenocarcinoma demonstrates strong concordance (96.7%) between biopsy and resection specimens for HER2 overexpression. However, discordance may occur in tumours which exhibit significant heterogeneity, especially with biopsies that have poor tumour sampling. Overall, both biopsy and resection specimens are appropriate for HER2 testing, but generous sampling for biopsy specimens is necessary to ensure accurate assessment.

### 768 Plexitis at Primary Ileocaecal Resection Margins as Predictive Factor for Subsequent Recurrence in Crohn's Disease

*LM Wang, CE Koh, A Szuts, S Olonso-Goncalves, A Tzvinakis, H Misteli, R Guy, B George, NJ Mortensen.* John Radcliffe Hospital Oxford University Hospital, Oxford, United Kingdom; Royal Prince Alfred Hospital, Sydney, Australia.

**Background:** 50-90% Crohn's patients experience disease recurrence after surgery requiring further treatment. Predictive histological factors are sought to identify patients at high risk of recurrence for maintenance therapy to prevent subsequent Crohn's related complication and repeated surgery. We investigate the relationship between plexitis and subsequent recurrence suggested by Ng [2009].

**Design:** Primary ileocolic resections identified from pathology database 2000-2010 with slides of excision margins available were examined (2 pathologists LMW & AS). Myenteric plexus at the margins was assessed for plexitis (presence of 1 or more chronic inflammatory cells in contact with or within ganglion cells or nerve bundles) and graded in the most severe areas (mild G1 <4 cells/HPF, G2 4-9/HPF & G3 >10/HPF) [Ferrante 2006]. Clinical data was obtained from clinical notes, endoscopy and radiology reports. Clinical recurrence (CR) is presence of symptoms attributable to Crohn's disease requiring investigation and confirmed on radiology/endoscopy. Surgical recurrence (SR) is needing repeat surgical intervention.

**Results:** Of the 87 patients (37 men, 50 women; median age 31.5,  $\pm 14.0$ ), 56 (64.4%) patients were free from recurrence, 16 (18.4%) had SR and 15 (17.2%) had CR. Plexitis and granulomas at proximal and distal margins are shown in Table 1.

Table 1 Myenteric plexitis & presence of granuloma at Proximal & Distal margins

	PROXIMAL MARGIN	DISTAL MARGIN
PLEXITIS	(%) [77*/87]	(%) [78*/87]
G0	23 (29.9)	38 (48.7)
G1	31 (40.3)	33 (42.3)
G2	14 (18.2)	6 (7.8)
G3	9 (11.7)	1 (1.2)
GRANULOMAS	(%) 84/87	(%) 83/87
Present	7 (8.3)	2 (2.4)

\*no. of cases with preserved myenteric plexus

Fistulating disease is associated with recurrence ( $p = 0.047$ ), proximal plexitis is associated with distal plexitis ( $p = 0.003$ ) and granuloma is associated with plexitis ( $p = 0.003$ ).

= 0.032) by univariate analysis. Severe plexitis at proximal margin is associated with increased risk of subsequent surgical recurrence Table2.

Table2. Univariate analyses between G2&3 plexitis & the following variables

	P value (χ <sup>2</sup> )	
	Any recurrence	Surgical recurrence
Proximal plexitis	0.567	0.238
G2	0.360	0.082
G3	0.040	0.033
Distal plexitis	0.910	0.361
G2	0.684	0.770
G3	0.454	0.633
Proximal granuloma	0.684	0.442
Distal granuloma	0.287	0.497

**Conclusions:** Severe myenteric plexitis at the proximal resection margin of primary ileocecal resections is a predictive factor for any recurrence, surgical or clinical.

**769 Clinical Outcomes and Microsatellite Instability Testing of Advanced Colorectal Adenomas in Patients under 45**

*RF Watson, VM Kushnir, J Goodwin, E Safar, RV Chokshi, NO Davidson, RA Azar, I Nalbantoglu.* Washington University School of Medicine, St. Louis, MO.

**Background:** Colorectal cancer (CRC) is the second leading cause of death in the United States. Approximately 10% are diagnosed in patients under 50 years old. The rate of CRC in this age group appears to be increasing and is associated with poorer outcome. One of the most common causes of hereditary CRC is Lynch Syndrome (LS). Revised Bethesda criteria (clinical) are used to detect patients with LS and are known to miss approximately 25% of the cases. LS patients are diagnosed with CRC at an average age of 45, in contrast, <2% of normal populations develop adenomas by 40. Advanced colorectal adenomas (ACA) (villous histology, high grade dysplasia, >1 cm adenoma, or >2 adenomas of any size) represent the final stop on the pathway to CRC. However, their natural history in young patients is incompletely defined. The purpose of this study is to determine the natural history and mismatch repair (MMR) protein status of ACAs by immunohistochemistry (IHC) in the absence of a diagnosis of LS and to establish whether these could represent an additional clinical and tissue marker for LS.

**Design:** Patients aged 18-45y with identified ACAs from 2001-9 were included. Patients with polyposis syndromes, inflammatory bowel disease, CRC, or follow up of < 1 year were excluded. IHC for the DNA mismatch repair proteins MLH1, PMS2, MSH2, and MSH6 were evaluated as a surrogate marker for microsatellite instability (MSI). Cases were deemed MSI if there was concurrent loss of nuclear staining for MLH1/PMS2 and MSH2/MSH6 or individual loss of PMS2 and MSH6.

**Results:** 76 patients were identified with a mean age of 40.6y, 40.1% were male and 22 (28.9%) African-American. 17 (24.3%) had a first degree relative with CRC, 24 (34.8%) were smokers, and the mean body mass index was 30.7. All adenomas were resected; average size was 12.9 mm. Mean follow up was 3.3 y; 24 (31.6%) had recurrence (mean time to recurrence of 26.4m). No cases of CRC were identified in follow up. IHC was performed on 66 ACAs with tissue available and only one patient showed MSI with loss of PMS2/MLH1 without recurrence at follow up. However, 36 (44.7%) patients met Bethesda criteria for LS.

**Conclusions:** Patients <45y with ACAs and without LS had an adenoma recurrence rate comparable to patients with LS. MSI testing by IHC was not informative in this patient population. However, the clinical findings suggest that ACA should prompt close follow up and investigation for LS.

**770 Immunohistochemistry Improves the Detection of Adenovirus, but Not Cytomegalovirus, in Gastrointestinal Biopsies from Hematopoietic Stem Cell Transplant Recipients**

*SR Weidner, J Jessurun, RK Yantiss, NC Panarelli.* Weill Cornell Medical College, New York, NY.

**Background:** Gastrointestinal (GI) infections by cytomegalovirus (CMV) and adenovirus (ADV) may complicate hematopoietic stem cell transplantation (HSCT). Histologic evaluation is commonly used to detect these infections and to differentiate them from other complications such as graft versus host disease and drug toxicities. Although these viruses produce recognizable cytopathic changes, they may be subtle, and thus, viral immunohistochemistry (IHC) may aid in their identification. The aim of this study is to evaluate whether routine IHC is necessary to detect these viral infections.

**Design:** Hematoxylin and eosin (H&E) stained sections were prepared from 105 GI biopsy cases from 77 HSCT recipients and reviewed by 3 pathologists. Biopsies were classified as showing 1) no evidence of, 2) cellular changes suspicious for, or 3) cytopathic changes diagnostic of CMV and/or ADV infection. Cases were evaluated for other features suggestive of infection: apoptosis, ulcers and crypt injury (cryptitis, abscesses, loss, degeneration and remodeling). CMV and ADV IHC stains were performed on all cases and the results compared to interpretations of H&E stained sections.

**Results:** The study group contained 77 adult HSCT patients (mean age: 54 years) with GI symptoms. Samples were obtained from the upper GI tract (n=51), lower GI tract (n=23), or both (n=31), (mean: 5 biopsies/case). One reviewer classified 10 and 13 cases as suspicious for or diagnostic of CMV and ADV infection, respectively, compared to 6 and 10 for the second and 2 and 1 for the third reviewers. Two CMV and 2 ADV positive cases were detected by IHC. The 2 cases that were positive for CMV were recognized in H&E sections by all reviewers. By contrast, all reviewers identified only 1 of the 2 ADV positive cases and missed the second one, the latter of which contained rare viral inclusions in only 1 of 6 biopsies on retrospective review of the H&E stained slides. All 4 positive cases showed only minimal or focal inflammatory changes.

**Conclusions:** CMV infection may be reliably identified on H&E stained section of GI biopsies from HSCT recipients and, thus, confirmatory IHC should be reserved for select cases. However, routine IHC stains for ADV are necessary since cytopathic

changes may be difficult to discern and easily missed on H&E stained sections. Since both viruses may elicit only minimal inflammatory/degenerative changes, the absence of these features does not exclude an infection.

**771 Mesenteric Lipodystrophy: A Frequently Underdiagnosed Entity**

*JM Wells, Z Yang.* Penn State Milton S. Hershey Medical Center, Hershey, PA.

**Background:** Mesenteric lipodystrophy (ML) often has a clinical impression of mass lesion but the biopsy is frequently reported as nonspecific findings, which provides little guidance to patient management. Recently we encountered several cases and none of them was initially diagnosed correctly. This prompted us to further review the clinicopathologic features of this entity.

**Design:** The pathology database from the last 20 years was queried using the term 'mesenteric', 'mesenteritis', 'lipodystrophy', and 'fat necrosis'. All reports and slides were reviewed, and the clinicopathologic features were evaluated. Immunostain for IgG4 was performed on selected cases.

**Results:** Fifteen patients were identified, the age ranged from 26 to 81, with M:F ratio of 4:1. Twelve patients (80%) presented with mesenteric mass, and the size ranged from 2.1 to 8 cm. Microscopically, fat necrosis was seen in all cases, nodular hyalinizing fibrosis was seen in 13 cases (87%); fibrosis encasing the vessel, nerve and lymph nodes was seen in 12 (80%), 6 (40%), and 4 (27%) cases, respectively. The lesion showed infiltrative margins in all cases. The IgG4+ plasma cells varied from 0 to 80 /HPF. Only seven patients (47%) were correctly diagnosed at initial review. Five patients (33%) had a history of malignancy, and six patients (40%) had a history of abdominal surgery.

**Conclusions:** ML is an underdiagnosed entity. Correlation with clinical/radiological findings such as mass lesion, and attention to the pathologic features such as fat necrosis with nodular hyalinizing fibrosis and encasement of various structures is the key to a correct diagnosis and optimal patient care. IgG4+ plasma cells vary in ML thus do not appear to be helpful in the differential diagnosis.

**772 Crohn's-Associated Small Bowel Adenocarcinomas Exhibit Gastric Differentiation**

*E Whitcomb, X Liu, S-Y Xiao.* University of Chicago, Chicago, IL; Cleveland Clinic, Cleveland, OH.

**Background:** Long-term Crohn's enteritis increases the risk of small bowel adenocarcinoma (SBA), which, when compared to *de novo* SBA, usually occurs at a younger age, is frequently located in the ileum, and is more often poorly differentiated. In addition, we have observed that some cases of SBA in Crohn's disease exhibit gastric-type morphology, which may be related to pyloric gland metaplasia (PGM), a common finding in Crohn's disease. To investigate if this feature is unique to Crohn's SBA, a retrospective study (compared with non-Crohn's, *de novo* SBA) is performed.

**Design:** Cases of Crohn's-associated and *de novo* SBA were identified from the surgical pathology archives. H&E sections were examined for PGM. IHC was performed for CK20, CDX2, MUC2, CK7, MUC5AC and MUC6. Staining was scored on the invasive component as follows: 0 = entirely negative, 1+ = focally positive, and 2+ = diffusely positive. The two groups were then compared for their IHC expression frequencies.

**Results:** Seven cases of SBA in Crohn's disease were found and had adequate material for IHC evaluation and 7 *de novo* SBA cases were used as controls. Five of 7 Crohn's cases had PGM, which was absent in all *de novo* cases. By IHC, all *de novo* SBAs were positive for intestinal markers (CK20, CDX2, and MUC2) and 6 out of 7 were negative for gastric markers (CK7, MUC5AC, and MUC6). In contrast, all cases of Crohn's SBA were positive for a mixture of both intestinal and gastric markers. See Table 1.

Table 1. Expression of Intestinal and Gastric Markers in *de novo* and Crohn's-associated SBA

	De Novo SBA (n = 7)	Crohns SBA (n = 7)
Intestinal Markers (% positive)		
CK20	100% (n = 7)	86% (n = 6)
CDX2	100% (n = 7)	86% (n = 6)
MUC2	100% (n = 7)	71% (n = 5)
Gastric Markers (% positive)		
CK7	14% (n = 1)	71% (n = 5)
MUC5AC	0% (n = 0)	71% (n = 5)
MUC6	0% (n = 0)	71% (n = 5)

**Conclusions:** These findings suggest that gastric differentiation and aberrant expression of gastric mucin markers is a common occurrence in Crohn's SBA while a rare occurrence in *de novo* SBA. Given that PGM is a well-known change in Crohn's disease, it is conceivable these cancers may arise out of gastric metaplasia (similar to adenocarcinoma arising from intestinal metaplasia in Barrett's esophagus), and thus, the presence of PGM may contribute to risk for development of adenocarcinoma in Crohn's enteritis. Further investigation may shed new light on the pathogenesis of this disease. In addition, the frequent aberrancy of staining should be considered when evaluating an unknown primary in a patient with Crohn's enteritis.

**773 Upper GI Tract Lesions in Familial Adenomatous Polyposis (FAP): Enrichment for Pyloric Gland Adenomas and Other Gastric and Duodenal Neoplasms**

*LD Wood, SN Salaria, MW Cruise, EA Montgomery.* Johns Hopkins University, Baltimore, MD.

**Background:** FAP is an autosomal dominant cancer predisposition syndrome caused by germline mutations in the adenomatous polyposis coli (*APC*) gene. Patients with FAP develop numerous colonic adenomas and invariably develop carcinoma unless a colectomy is performed. In addition, patients with FAP also develop neoplasms of the upper gastrointestinal tract, but these lesions are less well characterized than those in the colon.

**Design:** All upper gastrointestinal biopsy specimens in patients with FAP were identified at a single institution over a 25 year period. Specimens without neoplasms/polyps or



mass lesions were excluded, as were patients with only a single biopsy at our institution. The remaining biopsy specimens were examined histologically to characterize the spectrum of upper gastrointestinal tract neoplasms in patients with FAP.

**Results:** We identified specimens from 321 endoscopies in 66 patients with FAP. The most common neoplasms were tubular adenomas of the small bowel – we identified 371 tubular adenomas, and at least one tubular adenoma was present in 89% of the included patients. Although tubular adenomas were common in the small bowel, we identified only one case with high grade dysplasia and one case with invasive carcinoma (in patients aged 61 years and 37 years, respectively). Gastric fundic gland polyps were also very common, with 203 total polyps and 65% of patients with at least one fundic gland polyp. Most fundic gland polyps (66%) lacked dysplasia, about 33% had low grade dysplasia and high grade dysplasia was rare (<1%). In addition, several gastric foveolar type gastric adenomas were also identified – 43 adenomas were identified, affecting 23% of patients. Pyloric gland adenomas (PGAs) were also enriched for in FAP patients – 7 PGAs were identified in 4 patients. Although PGAs are uncommon in patients with FAP, they occur at a higher frequency (6%) than in another classic condition with enrichment of PGAs, namely autoimmune gastritis (1%). In spite of the variety of gastric neoplasms reported in this series of FAP patients, only one patient developed invasive carcinoma in the stomach at 39 years.

**Conclusions:** Although patients with FAP frequently develop neoplasms in the upper gastrointestinal tract, current screening procedures with removal of suspicious lesions prevent the vast majority of carcinomas in these patients. In addition to fundic gland polyps and gastric foveolar type gastric adenomas, patients with FAP are also predisposed to pyloric gland adenomas, a novel finding in this study of upper gastrointestinal tract lesions in FAP.

#### 774 Utilization of Reciprocal Expression Pattern of CRABP2 and CDX-2 in Diagnosing Pancreatic Ductal Adenocarcinoma

W Xiao, H Hong, A Awadallah, W Xin. University Hospitals Case Medical Center, Case Western Reserve University, Cleveland, OH.

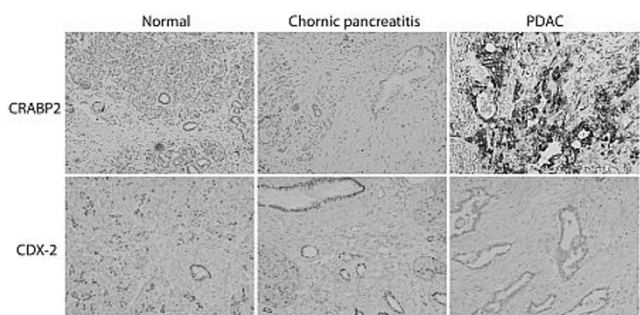
**Background:** Distinguishing pancreatic ductal adenocarcinoma (PDAC) from extensive chronic pancreatitis can be histologically challenging. Molecular biomarkers with high sensitivity and specificity for PDAC have been rigorously searched with some success. CRABP2, a retinoid acid binding protein, shuttles retinoid acid from cytosol into the nucleus and forms a complex with nuclear retinoid acid receptor to facilitate transcriptional activities of retinoid acid. CDX-2 is a homeobox domain-containing transcription factor involved in intestinal development and is expressed in the nuclei of epithelial cells throughout the intestine. In the following study, we would like to investigate whether the expression patterns of CRABP2 and CDX-2 could help us to distinguish PDAC from benign and pre-cancerous pancreatic lesions.

**Design:** Formalin-fixed paraffin-embedded blocks from surgically resected PDAC were extracted from our surgical pathology archive. Polyclonal anti-CRABP2 and anti-CDX-2 were used and immunohistochemical staining was performed in our hospital diagnostic lab. The control groups include normal pancreatic tissue, chronic pancreatitis, and pancreatic intraepithelial neoplasia (PanIN) 1-3.

**Results:** No expressions of CRABP2 were detected in normal pancreatic parenchyma, ductal epithelium and chronic pancreatitis.

Table 1. Reciprocal expression of CRABP2 and CDX-2 in PDAC

	Normal Parenchyma	Normal Ducts	Chronic Pancreatitis	PDAC	Metastatic PDAC
CRABP2	0/51 (0)	0/26 (0)	0/54 (0)	56/56 (100%)	4/4 (100%)
CDX-2	7/7 (100%)	7/7 (100%)	8/8 (100%)	2/18 (11%)	1/10 (10%)



In contrast, CRABP2 expression was universally detected in all PDACs. CRABP2 staining was also observed and progressively increased from PanIN 1 to 3. On the other hand, CDX-2 expression was readily detected in normal pancreatic parenchyma, ductal epithelium and chronic pancreatitis, but largely undetected in PDACs.

**Conclusions:** Our study demonstrates over-expression of CRABP2 and loss-of-expression CDX-2 in PDACs. The reciprocal changes of CRABP2 and CDX-2 are probably late events of pancreatic carcinogenesis, and it could be used as diagnostic markers to distinguish PDAC from benign pancreatic conditions.

#### 775 Diagnostic Utility of p53 and Cytokeratin 7 Immunohistochemistry in Idiopathic Inflammatory Bowel Disease-Associated Neoplasia

H Xie, S-Y Xiao, R Pai, K Lai, Y Wang, B Shen, X Liu. Cleveland Clinic, Cleveland, OH; University of Chicago, Chicago, IL.

**Background:** Long-standing inflammatory bowel disease (IBD) is associated with increased risk of developing colorectal adenocarcinoma. Significant intra- and inter-observers' variability exists in histologic interpretation of dysplasia in surveillance biopsies. The aim of this study is to evaluate the utility of a panel of

immunohistochemical markers in diagnosing IBD-associated neoplasia.

**Design:** We reviewed 39 colectomy specimens with IBD-associated neoplasia. In these 39 cases, we identified 172 foci of interest (5 normal, 58 negative for dysplasia, 15 indefinite for dysplasia, 59 low-grade dysplasia, 18 high-grade dysplasia, and 17 invasive adenocarcinoma). They were subjected to immunohistochemistry for p53 and cytokeratin 7 (CK7). Logistic regression was used to evaluate their association with the presence of dysplasia. Receiver operating characteristic (ROC) curves were used to determine the optimal cutoffs and assess the diagnostic performance of p53 and CK7. **Results:** Both p53 nuclear staining and CK7 immunoreactivity gradually increased in the progression of IBD-associated neoplasia ( $P < 0.0001$ ). CK7 immunoreactivity increased along with an increase in inflammation severity ( $P = 0.0002$ ) as well as reactive changes ( $P = 0.04$ ) in the colonic mucosa. But p53 nuclear staining was independent of either feature. When both p53 > 8% and CK7 > 30% as identified from logistic regression and ROC curves were used to diagnose dysplasia, the specificity achieved was 95%. When either p53 > 8% or CK7 > 30% was used to diagnose dysplasia, the sensitivity achieved was 82% (Table 1).

Table 1. Predictive value of p53 and CK7 to the presence of dysplasia

Variable	Cutoff	Sensitivity	Specificity	PPV	NPV	AUC
p53	8%	60%	87%	0.83	0.67	0.75
CK7	30%	63%	72%	0.72	0.64	0.65
p53>8% and CK7>30%	N/A	36%	95%	0.88	0.58	N/A
p53>8% or CK7>30%	N/A	82%	56%	0.66	0.75	N/A

PPV: positive predictive value; NPV: negative predictive value; AUC: area under the curve; N/A: not applicable

**Conclusions:** Our results suggested that a combination of p53 and CK7 immunohistochemistry may be helpful in diagnosing IBD-associated dysplasia in difficult cases.

#### 776 Inflammatory Bowel Disease (IBD)-Associated and Sporadic Colorectal Adenocarcinoma Is Immunophenotypically Different

H Xie, W Jiang, B Shadrach, P Carver, X Liu. Cleveland Clinic, Cleveland, OH; Jefferson Medical College, Thomas Jefferson University, Philadelphia, PA.

**Background:** While sporadic and IBD-associated colorectal neoplasia has been shown to be a multistep process of progression from low-grade dysplasia, high-grade dysplasia, and invasive adenocarcinoma, morphologically, most lesions of these two entities are thought to be similar. Our recent studies (Jiang W et al., 2012; Liu X et al., 2012) revealed that IBD-associated colorectal adenocarcinoma (CAC) is morphologically different from sporadic microsatellite stable CAC and 54.5% of ulcerative colitis peri-pouch adenocarcinoma had expression of cytokeratin 7 (CK7), a cytokeratin, not normally expressed in large intestine. These findings prompted us to further investigate the immunophenotype of IBD-associated CAC.

**Design:** Tissue microarrays (TMA) consisting of 65 IBD-related CACs [duplicate cores (2 mm in diameter) from each tumor] and 135 sporadic CACs were constructed and used for immunohistochemistry for CK7, CK20, p53,  $\beta$ -catenin, and a-methylacyl-CoA racemase (AMACR). Presence of immunoreactivity in  $\geq 15\%$  and any cancerous nuclei is considered positive for p53 and  $\beta$ -catenin, respectively. AMACR was graded as 0 (none), 1 (weak), and 2 (strong) according to the stain intensity. Categorical data were analyzed using the chi-square test. A  $p$  value < 0.05 was considered statistically significant. **Results:** The results are shown in Table 1.

Table 1. Immunophenotype of sporadic CAC and IBD-associated CAC

	Sporadic CAC (n=135)	IBD-associated CAC (n=68)	p value
# of cases with CK7 positivity (%)	8 (5.9%)	37 (54.4%)	<0.00001
# of cases with CK20 positivity (%)	107 (79.9%)	64 (95.5%)	0.006
# of cases with p53 positivity (%)	60 (44.4%)	39 (60%)	0.049
# of cases with $\beta$ -catenin nuclear immunoreactivity (%)	50 (39.4%)	7 (10.4%)	0.00002
# of cases with strong AMACR positivity (%)	52 (38.5%)	14 (21.6%)	0.024

CAC: colorectal adenocarcinoma; IBD: inflammatory bowel disease; strong AMACR stain: stain intensity of 2.

**Conclusions:** Expression of CK7 and lack of  $\beta$ -catenin nuclear immunoreactivity are quite unique to IBD-associated CACs. While IBD-associated CAC has slightly higher rates of p53 immunoreactivity and CK20 expression, it is less likely to show strong AMACR expression. The underlying mechanism leading to this different immunophenotype remains to be determined. Collectively, our previous morphological study (Liu X et al., 2012) and the current study strongly suggest that IBD-associated CAC and sporadic CAC are histomorphologically and immunophenotypically different.

#### 777 Lymphocytic Esophagitis Is Associated with CD4+ T-Cell-Predominance and Esophageal Dysmotility

Y Xue, SL Gabbard, RI Rothstein, X Liu, A Suriawinata, M Lisovsky. Dartmouth-Hitchcock Medical Center, Lebanon, NH.

**Background:** The presence of increased intraepithelial lymphocytes (IEL) as a predominant or sole histologic abnormality in the esophageal mucosa is uncommon and has been referred to as "lymphocytic esophagitis" (LE). The features of LE remain poorly defined and its clinical significance is largely unknown. The goal of this study was to characterize clinicopathologic and immunophenotypic features of LE.

**Design:** Fifteen biopsy cases of LE were identified during routine diagnostic work over the period of 24 months in 2010-2012. LE was diagnosed when conspicuously increased IEL were present in the absence of other features of esophagitis, such as basal hyperplasia, a single intraepithelial eosinophil or neutrophil, and erosion/ulceration. IEL were counted by 2 pathologists (Y.X. and M.L.) in one x400 high power field (HPF) from the most affected area. LE was deemed focal when present in <50% of a biopsy and diffuse when present in  $\geq 50\%$ . Biopsies from 17 patients with reflux esophagitis

(RE) and increased IEL comprised the control group. Cases of RE with demonstrated esophageal dysmotility were excluded. CD4 and CD8 T-cell subsets were analyzed by routine immunohistochemistry. Data is presented as mean  $\pm$  SD.

**Results:** Patients with LE (age  $58.2 \pm 12.9$ ) were predominantly females (M:F=1 : 2.8) and presented with dysphagia (11/15), heartburn (3/15) and melena (1/15). Endoscopy was normal in 9/15 patients, all with dysphagia. Eight patients with dysphagia and normal endoscopy underwent manometry and/or barium swallow and all showed abnormal esophageal motility patterns including nutcracker esophagus (n=3) and diffuse esophageal spasm (n=2). Histologically, LE was focal (10/15) and localized to the peripapillary areas in 13/15 cases. There were  $183.1 \pm 95.7$  IEL/HPF and CD4+ T-cells were predominant over CD8+ T-cells (CD4:CD8=3.6  $\pm$  2.7). In comparison, patients with RE did not differ significantly in age,  $53.5 \pm 13.1$  (p=0.312), but were predominantly males (M:F=2.4 : 1, p=0.032). Only 5/17 presented with dysphagia (p=0.032), and only 4/17 had normal endoscopy (p=0.070). In RE, there were  $122.4 \pm 107.7$  IEL (p=0.08) and peripapillary localization of IEL was present in only 2/17 (p < 0.001). In contrast to LE, CD4+ T-cells were in minority (CD4:CD8=0.92  $\pm$  0.71, p=0.004), suggesting discrete types of lymphocytic inflammation in LE and RE.

**Conclusions:** LE is a distinct histologic pattern that is associated with dysphagia, esophageal dysmotility and CD4+ T-cell predominance. The results suggest a possible role of LE in primary motility disorders of the esophagus.

### 778 Strong IMP3 Expression Is Associated with Reduced E-Cadherin Level and Decreased Survival in Rectal Adenocarcinoma Patients after Neoadjuvant Therapy

X Yang, EF Cosar, L Hutchinson, Z Jiang, K Dresser, H Lee. UMass Memorial Medical Center, Worcester, MA; Albany Medical College, Albany, NY.

**Background:** Preoperative neoadjuvant therapy has become a standard management for locally advanced rectal adenocarcinoma. No promising biomarkers to predict outcomes following neoadjuvant therapy and surgery have been found. IMP3, an oncofetal protein, is a member of the insulin-like growth factor-II mRNA-binding protein family and has been used as a biomarker for both epithelial and mesenchymal malignancies. E-cadherin, an epithelial cell-cell adhesion protein, is often lost in advanced cancers and may play a role in epithelial-to-mesenchymal transition. In this study, we investigated the expression patterns of IMP3 and E-cadherin in tumor cells and their potential association with prognosis in rectal adenocarcinomas resected after neoadjuvant therapy.

**Design:** Rectal adenocarcinomas resected after neoadjuvant therapy at our institution from 2002 to 2010 with at least 2 years of follow up were retrieved. IMP3 and E-cadherin immunohistochemical stains were performed on representative paraffin-embedded tumor tissue blocks. IMP3 and E-cadherin staining were quantitatively scored as 3+, 2+, 1+, and negative with a cutoff of >40%, 16-39%, 5-15%, and <5% of tumor cells staining, respectively. Survival data were obtained from the Tumor Registry Office.

**Results:** Thirty four cases were available, with 17 macroscopic and 17 microscopic residual tumors. Twenty were male and 14 were female with the median age at resection of 58 years. Two-year survival rate was 66% in macroscopic and 100% in microscopic tumor cases. IMP3 showed 3+, 2+, 1+ and negative staining in 4, 2, 2, and 7 macroscopic tumor cases, respectively. Majority of the macroscopic tumor cases showed 3+ positivity for E-cadherin. All four 1+ E-cadherin positive cases showed 3+ IMP3 staining. The 4-year overall survival rate was 88% in negative and 1+ IMP3 positive cases and 62% in 2+ and 3+ IMP3 positive cases. Scarcity of the tumor cells and exhaustion of the blocks precluded a reliable comparative assessment of the stains in the microscopic tumor cases and 2 macroscopic tumor cases.

**Conclusions:** Our preliminary data suggest that strong IMP3 expression in residual tumor cells is associated with reduced E-cadherin level and decreased 4-year survival in treated rectal adenocarcinomas with macroscopic residual disease. Opposing expression pattern of IMP3 and E-cadherin in tumor cells may be a novel dual biomarker in predicting outcomes after neoadjuvant therapy.

Abstract #779 has moved to Liver

### 780 ARID1A in Colorectal Carcinoma: Loss of Expression Is Associated with DNA Mismatch Repair Protein Deficiency

J Ye, Y Zhou, D DeLair, R Soslow, J Shia. Memorial Sloan-Kettering Cancer Center, New York, NY.

**Background:** ARID1A is a subunit of the SWI/SNF chromatin remodeling complex, and is believed to provide specificity to this complex in the regulation of gene expression by binding to AT-rich DNA sequences. Recent data indicate that ARID1A is frequently mutated in ovarian clear cell carcinoma and behaves as a tumor suppressor. This gene has also been shown to be mutated in several other tumors including 10% colorectal carcinomas (CRCs) by DNA sequencing. Intriguingly, ARID1A mutations frequently involve a seven base G tract; thus, it has been hypothesized that the mutations may result from defects in the DNA mismatch repair (MMR) system. The aim of this study was to evaluate the prevalence of loss of ARID1A expression in CRC by utilizing immunohistochemistry (IHC), and to explore the relationship between ARID1A and MMR protein in these tumors.

**Design:** A consecutive series of 302 CRCs from patients fulfilling the Bethesda guidelines for microsatellite instability testing was included. IHC for MLH1, MSH2, MSH6 and PMS2 was performed on whole sections in all cases. Tissue microarray (TMA) was constructed. IHC using a polyclonal antibody against ARID1A (Sigma-Aldrich HPA005456) was performed on TMA sections and the results were correlated with MMR IHC and tumor pathologic characteristics.

**Results:** The rate of TMA tissue loss was 13%, yielding 263 analyzable tumor samples, 67 of which (25%) showed MMR protein loss (76% lost MLH1 and/or PMS2, and 24% lost MSH2 and/or MSH6). Overall, loss of ARID1A expression was detected in 22 of the

263 (8.4%) tumors. It was detected in 14 of 67 (21%) MMR-deficient tumors, but only in 8 of 196 (4%) MMR-proficient tumors (p<0.001). Among the 22 ARID1A negative tumors, 12 of the 14 (86%) that were also deficient in MMR occurred in the right colon and 8 of the 8 that were MMR proficient occurred in the left colon/rectum. Furthermore, 13 of the 14 (93%) ARID1A negative/MMR deficient tumors were deficient in MLH1/PMS2 and the 14<sup>th</sup> case was deficient in MSH6. We did not detect a significant difference in tumor staging between ARID1A positive and negative groups either among the entire cohort or upon stratification by MMR protein status.

**Conclusions:** Loss of ARID1A as detected by IHC is significantly more common in MMR protein-deficient CRCs when compared with MMR protein-proficient tumors (21% vs 4%). There appears to be a tendency for tumors deficient in both MMR and ARID1A to occur in the right colon and to be associated with MLH1/PMS2 abnormality. Further studies are warranted to better understand the biologic implication of ARID1A deregulation in CRC.

### 781 Diagnostic Value of HMGA, P53 and $\beta$ -Catenin in Discriminating Adenocarcinoma from Adenoma or Reactive Atypia in Ampulla and Common Bile Duct Biopsies

V Zakharov, B Ren, Q Yang, M Loralee, W Cao. University of Rochester Medical Center, Rochester, NY.

**Background:** Interpretation of biopsies from the ampulla of Vater and common bile duct are often challenging due to small sample sizes, frequent acute and chronic inflammation, and reactive changes. The markers explored in the previous studies are not widely used clinically due to low sensitivity, specificity or technique difficulty. We investigated the expression patterns of HMGA1, HMGA2,  $\beta$ -catenin and p53 in the biopsy specimens to evaluate the potential diagnostic value of these proteins in differentiating adenocarcinoma from reactive atypia or adenoma.

**Design:** 48 biopsies (10 from common bile duct and 38 from ampulla) were selected for immunohistochemical studies, which included 14 reactive atypia, 12 adenoma and 22 adenocarcinoma cases. Patterns of expression of HMGA, p53 and  $\beta$ -catenin were evaluated and the associations of their expression with clinicopathological factors were analyzed.

**Results:** Expression of HMGA1 was seen in 22% of reactive atypia, 42% adenoma, and 91% adenocarcinoma. HMGA2 was positive in 17% of reactive atypia, 42% adenoma, and 86% of adenocarcinoma. Staining intensity of HMGA1 or HMGA2 was also significantly higher in adenocarcinoma compared to adenoma or reactive atypia. Interestingly, expression of both HMGA1 and HMGA2 was found in 86% of adenocarcinoma, 0% of reactive atypia and 8% of adenoma cases (p<0.001). 8 of 48 cases had initial nonmalignant diagnosis were diagnosed with carcinoma by either follow-up biopsy/resection specimens or imaging proven metastasis. 75% of them were stained positive with both HMGA1 and HMGA2. 100% of them were either HMGA1 or HMGA2 positive. P53 and  $\beta$ -catenin did not demonstrate significant differences among reactive atypia, adenoma and carcinoma.

Diagnostic value of HMGA1, HMGA2 and combined HMGA1+HMGA2

	Sensitivity	Specificity	PPV	NPV
HMGA1	91%	36%	71%	90%
HMGA2	86%	41%	73%	86%
HMGA1+HMGA2	86%	92%	95%	89%

PPV: Positive Predict Value; NPV: Negative Predict Value

**Conclusions:** HMGA1 and HMGA2 may serve as the potential discriminators among reactive alterations, adenoma, and adenocarcinoma in ampulla and common bile duct biopsies. The combined HMGA1 and HMGA2 may significantly improve the accuracy of malignant diagnosis. The results from P53 or  $\beta$ -catenin seem not to display the diagnostic significance in differentiating adenocarcinoma from benign lesions in the biopsy specimens.

### 782 Beta-Catenin and c-Met Provide a Useful Panel To Predict the Development of Dysplasia in Barrett's Esophagus

X Zhang, M Westerhoff, J Hart. University of Chicago, Chicago, IL; University of Washington, Seattle, WA.

**Background:** Barrett's esophagus (BE) is the only known precursor lesion for esophageal adenocarcinoma (EAC). The BE-dysplasia-EAC sequence is well established, but the risk of progression to EAC is low. Therefore, biomarkers to stratify risk of progression would be helpful to optimize surveillance and management strategies. Abnormal expression of c-met, p16, and beta-catenin is frequent in dysplastic BE mucosa, but has not been studied extensively in non-dysplastic BE. The use of these markers to predict the future development of dysplasia is the focus of this study.

**Design:** A surgical pathology database was searched from 1990 to 2008 to identify patients with an initial biopsy revealing non-dysplastic BE who during follow-up developed dysplasia. Among a group of 258 new BE patients, 13 later developed dysplasia (dysplasia group [DG]). For each case in the DG, 1 age and sex matched control was selected from the 245 BE patients who never developed dysplasia. Immunostains for c-met, beta-catenin, and p16 were performed on the initial biopsies. The results were interpreted by two pathologists independently in a masked manner.

**Results:** There was no significant difference in the number of biopsies and follow-up duration between the DG and the control group. The average time interval between the initial biopsy and the biopsy showing dysplasia was 4.9 years, with 5/13 cases developing dysplasia within 1 year. Abnormal cytoplasmic beta-catenin expression was present in 12/13 of the cases in the DG and in 3/13 controls. Cytoplasmic c-met immunoreactivity was seen in 9/13 DG cases and in 5/13 controls. All the biopsies in the DG and 6/13 of the controls exhibited positivity for at least 1 of these 2 markers. Immunoreactivity for both markers was seen in 8/13 DG cases and 1/13 controls.

Sensitivity, specificity, positive/negative predictive value, and the odds ratio of the 2 markers were summarized in Table 1. There was no difference in p16 expression between the DG and control group.

Table 1. Summary of sensitivity, specificity, PPV, NPV, and OR.

	Sensitivity (%)	Specificity (%)	PPV (%)	NPV (%)	OR
beta-catenin	92.3	76.9	80.0	90.9	40.0
c-met	69.2	61.5	64.3	66.7	3.6
Either	100.0	53.8	68.4	100.0	13.9*
Both	61.5	92.3	88.9	70.6	19.2

NPV, negative predictive value; PPV, positive predictive value; OR, odds ratio. \*, estimated OR.

**Conclusions:** The combination of c-met and beta-catenin provides a relatively specific panel to identify patients with BE who are at increased risk for future development of dysplasia.

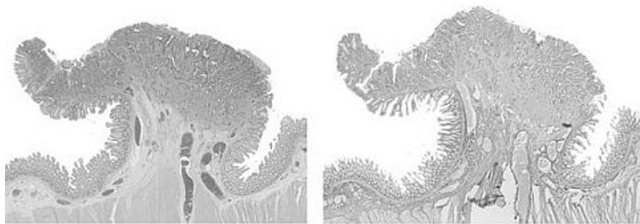
### 783 Microfibrillar Associated Protein 5 (MFAP 5): A Marker for Desmoplasia That Facilitates the Distinction between an Invasive Component and Pseudoinvasion in Colonic Adenomas

L Zhao, T Antic, S-Y Xiao, C VanSlambrouck, J Hart. University of Chicago, Chicago, IL.

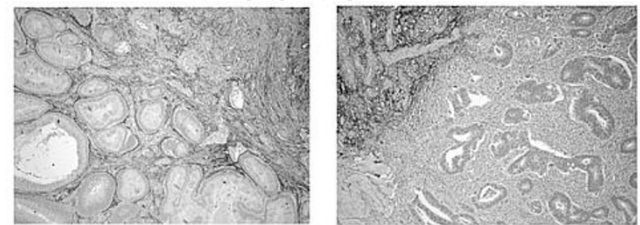
**Background:** Distinction between invasive adenocarcinoma and submucosal displacement of adenomatous mucosa in colonic polyps can be problematic in clinical practice. Recent microarray studies have demonstrated that tumor stroma exhibits reproducible gene-expression changes compared to normal stromal tissue. MFAP5, a 25-kD glycoprotein that is involved in elastic microfibril assembly, has been demonstrated to be significantly **down regulated** in tumorous stroma [Jia et al. *Cancer Res* 2011]. The aim of this study is to confirm the reduced expression of MFAP5 in tumor stroma by immunohistochemistry and evaluate the utility of MFAP5 as a diagnostic marker.

**Design:** An immunohistochemical stain for MFAP 5 (Sigma) was first performed on ten invasive colon cancer resection specimens to compare the its expression pattern in invasive tumor and in the surrounding lamina propria and submucosa. Then a total of 24 diagnostically challenging adenomatous polypectomy specimens (6 with an invasive focus and 18 with pseudoinvasion) were used to evaluate the diagnostic value of MFAP5.

**Results:** In all 10 colon cancer resection cases there was **no reactivity in the desmoplastic stroma** surrounding the invasive component, while the **uninvolved lamina propria and submucosa exhibited strong diffuse reactivity** in stromal cells.



In 16 out of 18 polypectomy specimens with pseudoinvasion, strong reactivity was preserved in the stroma surrounding the displaced adenomatous mucosa (left panel of figure below). Lack of staining in the stroma surrounding small foci of invasive tumor was observed in all 6 malignant polyps (right panel of figure below).



**Conclusions:** MFAP5 is a useful marker to demonstrate tumor associated desmoplastic stromal proliferation. It facilitates the distinction between pseudoinvasion and true invasive cancer in colonic adenomatous polyps with high sensitivity and specificity.

### 784 ALK Status in Esophageal Adenocarcinoma and Squamous Carcinoma Studied by DNA Microarray, FISH and Immunohistochemistry

Z Zhou, S Bandla, J Ye, L Li, T Godfrey, N Wang. University of Rochester Medical Center, Rochester, NY.

**Background:** The *anaplastic lymphoma kinase (ALK)* gene encodes a tyrosine kinase receptor that belongs to the insulin receptor superfamily. The 3'-tyrosine kinase domain is fused to a variety of partners such as *NPM-ALK* or *EML4-ALK* leading to express fusion proteins that play oncogenic roles in a variety of malignancies. Using mass spectroscopy alone, *TPM4-ALK* fusion protein was detected in esophageal squamous cell carcinoma (SCC). To verify the possible role of *ALK* in SCC and esophageal adenocarcinoma (EAC), we use different approaches to study *ALK* gene arrangement, amplification or expression.

**Design:** Genomic DNA from 116 EAC (95 M and 21 F) fresh tissue was analyzed for copy number aberrations using Affymetrix SNP 6.0 arrays. Tissue microarrays constructed at the University of Rochester between 1997 and 2005 included squamous mucosa (SE), EAC and SCC. *ALK* amplification and rearrangement were detected by FISH and *ALK* expression was tested by immunohistochemistry (IHC).

**Results:** By genomic analysis, *ALK* amplification was found in 7% (8/116) EAC frozen tissue cases by SNP analysis which was confirmed by FISH test in TMA cases (7%; 5/74). However, no *ALK* expression was identified either in EAC (0/112) or in SCC (0/33) by IHC. No gene rearrangement of *ALK* was detected in either EAC (0/74) or

SCC (0/33) by FISH. No difference of overall survival time was observed between amplified and non-amplified groups in EAC patients.

**Conclusions:** *ALK* amplification was present in 7% of EAC cases, but *ALK* rearrangement and expression was not present. No *ALK* amplification, rearrangement and expression were detected in SCC. *ALK* amplification is not associated with EAC patients' overall survival.

### 785 Mitosis-Specific Marker PHH3 Immunostain Is a More Sensitive and Efficient Method To Evaluate the Mitotic Activity in Gastrointestinal Stromal Tumor (GIST)

S Zhu, F Lin, ZE Chen. Geisinger Medical Center, Danville, PA.

**Background:** Mitotic activity is an important prognostic factor in GIST. The accurate identification of mitotic figures on the H&E stained slides could be challenging due to processing artifact, degeneration, apoptosis, or lymphocytic infiltration. Mitosis-specific marker PHH3 was proven as a sensitive and reliable method to assess the mitotic activity in various tumors. The aim of the current study was to compare the PHH3-stained mitotic counts and the time for counting on immunostained slides with the mitotic counts and the time for counting on H&E stained slides in GIST.

**Design:** Immunohistochemical stain for PHH3 and routine H&E staining were performed on 45 cases (41 non-malignant and 4 malignant at the time of sampling) of GIST. The mitotic counts were assessed on both immunostaining slides and H&E stained slides. The PHH3-stained mitotic counts were compared to the mitotic counts on the H&E stained slides. The time to count the mitosis by two methods was recorded too.

**Results:** For 41 non-malignant GIST cases, the mean mitotic count on the H&E stained slides was 1.9 per 50 high power fields and the mean PHH-stained mitotic count was 4.9 ( $p < 0.001$ ) per 50 high power fields. For 4 malignant GIST cases, the mean mitotic count on the H&E stained slides was 47.5 per 50 high power fields and the mean PHH-stained mitotic count was 90 per 50 high power fields. The mean time to count the mitotic figures for 50 high power fields on the H&E stained slides was 2 minutes and 50 seconds. The mean time to count the PHH3-stained mitotic figures for 50 high power fields was 40 seconds ( $p < 0.001$ ).

**Conclusions:** PHH3 immunostain is a more sensitive and efficient method to evaluate the mitotic activity in GIST. The malignant GISTs demonstrate significant higher mitotic counts by both PHH3 immunostain and H&E stained slides.

### 786 Etiology and Histomorphology of Esophagogastric Junction Intramucosal Adenocarcinoma (IMC): In Comparison to Esophageal IMC

H Zhu, Z Li, H Xie, TW Rice, LA Rybicki, JR Goldblum, X Liu. Cleveland Clinic Foundation, Cleveland, OH; Second Military Medical University, Shanghai, China.

**Background:** While it is clear Barrett Esophagus (BE) predisposes to esophageal adenocarcinoma, controversy exists regarding the etiology of esophagogastric junction (EGJ) adenocarcinoma. The aim of this study is to evaluate the clinical and pathologic features of EGJ IMC and compare them to IMC of the distal esophagus, as these tumors are smaller than more deeply invasive ones and allow for a better comparison of the surrounding mucosal changes which are often obscured by larger tumors.

**Design:** 149 cases of IMC from an esophagectomy database (1983 – 2010) were identified by reviewing medical charts and slides from these resection specimens. Clinicopathologic features were compared between IMC arising in the esophagus versus EGJ.

**Results:** Of these 149 cases; 54 cases (36.2%) were EGJ and 95 (63.7%) were esophageal IMC. Mean age and gender were not significantly different between these two groups [(61.8 yrs vs. 64.7,  $p=0.12$ ; 92.6% male vs. 83.2%,  $p=0.14$ )]. Hiatal hernia was present in 87.5% and 90.5% of EGJ and esophageal IMC ( $p=0.51$ ); hiatal hernia length was shorter in patients with EGJ IMC [median: 3 cm vs. 4 cm,  $p=0.007$ ]. Compared with esophageal IMC, intestinal metaplasia (IM) in the esophagus was absent in 8 of 54 EGJ IMC (14.8% vs. 0%,  $p<0.001$ ) and lack of dysplasia in IM of the esophagus was noted in patients with EGJ IMC (18.8% vs. 4.2%,  $p=0.012$ ). Tumor histomorphologic features including macroscopic abnormalities, focality, size, depth of invasion, grade, and lymphovascular invasion were similar. Both EGJ and esophageal IMC had low rates of nodal metastasis (0% and 1.1%). Of the 8 EGJ IMC patients without esophageal IM, 3 had long-standing GERD, 3 had cardia/EGJ IM associated with chronic gastritis (2) and reflux (1), 1 had a clinical history of familial adenomatous polyposis (FAP), and 1 had no apparent gastric or esophageal diseases.

**Conclusions:** Similar to esophageal IMC, most EGJ IMC arise in patients with reflux disease and intestinal metaplasia with hiatal hernia, but hiatal hernias were shorter compared with esophageal IMC patients. About 7.5% EGJ IMC occurred in patients without GERD and may be associated with *H. pylori* infection or genetic predilection. Our study supports the current view that EGJ and esophageal IMC in the USA share similar etiology, tumor morphology and clinical behavior.

## Genitourinary

### 787 "More Cocktails, More Cancer"; Do Pathologists Who Use Immunohistochemistry More Frequently on Prostate Biopsies, Diagnose Prostate Cancer More Frequently?

SAI Diffalha, W Roquiz, GA Barkan, EM Wojcik, MM Picken, SE Pambuccian. Loyola University Chicago, Maywood, IL.

**Background:** Atypical small acinar proliferations (ASAP), found in 1.5-5% of all prostate biopsies, are very small foci of atypical glands (usually  $<10$  glands and  $<0.5$  mm), which show no definite histologic features of malignancy and cannot be reproducibly classified as benign or malignant based on routine histology. Immunohistochemical (IHC) stains for basal cells (p63, HMWCK) and alpha-Methylacyl-CoA Racemase