

potentially important role for miRNAs in the process of epithelial cell differentiation. The disruption of polarity in epithelial cells is associated with poor prognosis for carcinomas. However, in mesenchymal tumor such as osteosarcoma, the miRNAs function is largely unknown. The miR-891a is known to be associated with BLCAP (bladder cancer associated protein). This gene encodes a tumor suppressor protein that reduces cell growth by stimulating apoptosis. Further studies about the specific function of three miRNAs in osteosarcomas is needed.

84 ALK Immunoreexpression and Gene Status in Rhabdomyosarcomas

A Yoshida, S Wakai, T Ushiku, K Tsuta, A Makimoto, M Fukayama, K Furuta, H Tsuda, T Shibata. National Cancer Center, Tokyo, Japan; The University of Tokyo, Tokyo, Japan.

Background: Anaplastic lymphoma kinase (ALK) is overexpressed via gene alteration in a number of neoplasms, and it has recently become a promising target of a specific inhibitor. Although ALK expression is immunohistochemically detectable, recent studies on ALK-rearranged lung cancer showed that staining according to the conventional protocol is unreliable. As a result, several sensitive staining methods have been developed. ALK expression in rhabdomyosarcoma (RMS) has been reported in a few studies, but sensitive staining method has not been tested. In addition, the genetic basis of ALK expression in RMS remains poorly understood.

Design: We performed a previously validated (Am J Surg Pathol. 2011;35:1224-38) sensitive ALK immunostaining for 106 RMSs (35 embryonal, 56 alveolar [ARMS], 7 pleomorphic, 8 adult-spindle/sclerosing). The staining results were correlated with the clinicopathological findings and *FOXO1* status studied by FISH. Selected cases were also tested for ALK rearrangement (with ALK break-apart probes) and copy number change (with *ALK/CEN2* probes) by using FISH and for ALK somatic mutation by PCR and sequencing.

Results: ALK expression was identified in 2 (5.7%) embryonal, 38 (68%) alveolar, and 0 (0%) pleomorphic and spindle/sclerosing types. Staining was diffuse (>50%) in most (90%) positive cases. ALK-positive ARMS more commonly presented with metastasis than ALK-negative ARMS ($p < 0.01$). *FOXO1* rearrangement was present in 38/43 of the ARMS, and all the 5 *FOXO1*-wild-type ARMSs were ALK-negative. ALK rearrangement was absent in all the tested ALK-positive cases (0/12). Gene amplification (median *ALK/CEN2* ≥ 2), low-level gain ($2 > \text{median } ALK/CEN2 > 1$), and high polysomy (≥ 4 ALK copies in >40% of cells) were identified in 1, 3, and 9 of the 48 successfully studied cases, respectively, and these were all positive for ALK expression. Mutation was present in 1 of the 19 successfully studied cases, but the mutated tumor was an ALK-negative embryonal type.

Conclusions: ALK expression is relatively specific to the alveolar type and seems limited to the *FOXO1*-rearranged subset. Positive staining in ARMS may indicate a subgroup with a proclivity to early metastasis. ALK copy number change is related to protein expression, but this was observed in only a subset (~30%) of the immunopositive cases. ALK gene rearrangement and mutation do not seem to play a major role in RMS. These data may help to preselect patients with RMSs for ALK-targeted therapy in future clinical trials.

85 Comprehensive Analysis of Cathepsin K Expression in Human Neoplasms

Zheng, G Martignoni, C Antonescu, E Montgomery, C Eberhart, G Netto, J Taube, W Westra, J Epstein, T Lotan, A Maitra, E Gabrielson, M Torbenson, C Iacobuzio-Donahue, A Demarzo, IM Shih, P Illei, D Clark, TC Wu, P Argani. Johns Hopkins Hospital, Baltimore, MD; University of Verona, Verona, Italy; Memorial Sloan-Kettering Cancer, New York.

Background: Cathepsin K is a papain-like cysteine protease which is responsible for degradation of collagen type I and other bone proteins. Cathepsin K is expressed in osteoclasts under the control of Microphthalmia Transcription Factor (MiTF), and has been shown to be expressed in melanoma which is also MiTF positive. We have recently shown that Cathepsin K is consistently and diffusely expressed in alveolar soft part sarcoma (ASPS) and a subset of translocation renal cell carcinomas (RCC) which overexpress gene fusions involving the related transcription factors TFE3 and TFEB, but is not expressed in conventional RCC. However, a systemic analysis of Cathepsin K expression in human neoplasms, particularly those in a differential diagnosis of ASPS and translocation RCC, has not been performed.

Design: We constructed tissue microarrays (TMA) from a wide variety of human neoplasms, spanning approximately 9000 spots from 1562 samples derived from 72 different tumor types. The TMA were labeled for Cathepsin K by immunohistochemistry. Labeling was scored for percentage labeling (0-100%) and intensity (0=none, 1=weak, 2=moderate, 3=strong), and these were multiplied to give an H-score (0-300). Labeling yielding an H score of 20 or more was considered positive.

Results: Only 2 of 956 carcinomas from various sites (0.2 %) were positive for Cathepsin K; almost all were completely negative. However, Cathepsin K was expressed in many non-epithelial lesions, some of which fall in differential diagnosis of ASPS. Notably, Cathepsin K was expressed in granular cell tumor (57% of cases), juvenile xanthogranuloma (78% of cases), and (as previously reported) melanoma (66% of cases). In contrast, clear cell sarcoma (12 cases), adrenal cortical neoplasms (36 cases) and paragangliomas (19 cases) were consistently negative for Cathepsin K.

Conclusions: Among carcinomas, Cathepsin K labeling is highly specific for translocation RCC. While it is a highly sensitive marker for ASPS, Cathepsin K labeling among soft tissue tumors is not specific, in that it is expressed in a variety of mesenchymal lesions, including some of those in morphological differential diagnosis of ASPS. In particular, Cathepsin K expression in granular cell tumor and histiocytic lesions warrants diagnostic caution. However, the absence of diffuse Cathepsin K expression in clear cell sarcoma, adrenal cortical neoplasms and paraganglioma can help distinguish these 3 lesions from ASPS.

Breast

86 Breast Cancer HER2 Heterogeneity by FISH Pre and Post Neoadjuvant Chemotherapy: A Pilot Study

KH Adamson, SM Dintzis, RA Schmidt, D Mankoff, KH Allison. University of Washington, Seattle, WA.

Background: In 2009 a College of American Pathologist expert panel (CAP-EP) published recommendations for reporting HER2 "heterogeneous" cases in which 5-50% of individual cells are amplified for HER2 by fluorescence in situ hybridization (FISH). As a pilot study to examine the potential implications of HER2 heterogeneity by these criteria, we examined a series of cases before and after neoadjuvant chemotherapy to see if minor populations of amplified cells changed with therapy.

Design: HER2 FISH was performed on 34 cases of locally advanced breast cancer, including 17 biopsies and their matched surgical excision specimens after treatment with neoadjuvant chemotherapy. The percentage of cells with HER2 amplification by HER2:CEP17 individual cell ratio (ICR) and HER2 individual signals per cell (ICS) were analyzed and compared between the pre-neoadjuvant and post-neoadjuvant specimens.

Results: Based on the 2009 CAP-EP guidelines for HER2:CEP17 ICR, 47% (8/17) of patients had HER2 heterogeneity either pre or post chemotherapy (see below table). The percent amplified cells in these cases increased post-treatment in 63% (5/8) of these cases and decreased in 38% (3/8). Interestingly, 50% (4/8) of cases that had <5% amplified cells by ICR became heterogeneous in the post treatment specimen and one case became amplified (case 3 below). Using ICS criteria, heterogeneity was less common: 0% (0/17) of pre-neoadjuvant and 12% (2/17) of post-neoadjuvant cases had HER2 heterogeneity. Both ICS heterogeneous cases had increased HER2 heterogeneity in the post-neoadjuvant cases (2.5%→8% and 0%→37.5%).

Heterogeneity by HER2:CEP17 ratio (ICR)

	Pre-Neoadjuvant (N=17)	Post-Neoadjuvant (N=17)
Heterogeneous Cases:	% Individual Cells With Ratio >2.2	
1	25	4
2	11	0
3	8	63*
4	0	27.5
5	37.5	4
6	0	11.4
7	0	5
8	0	8
Cases With Heterogeneity:	24% (4)	24% (4)

*Amplified >50%; does not meet criteria for heterogeneity

Conclusions: The clinical significance of HER2 heterogeneity by FISH using the CAP-EP recommended criteria is still unclear. Minor populations of amplified cells can both increase and decrease post-chemotherapy and would be reported differently if ICR or ICS criteria are used. We plan to expand these studies to determine if there are more clinically and biologically relevant thresholds that should be used to report HER2 heterogeneity.

87 Metastatic Non-Small Cell Lung Carcinoma (NSCLC) Masquerading as Primary Breast Cancer (PBC) – A Rare yet Major Pitfall in Pathologic Diagnosis

R Ali, T Mohammad, M Hayes, D Ionescu. BC Cancer Agency, Vancouver, BC, Canada.

Background: PBC is the most common malignancy of women but metastatic malignancy to the breast has a reported frequency of 0.4 - 1.3%. The commonest non-mammary tumors (NMT) in the breast are hematological malignancies, malignant melanoma, lung tumors, renal cell carcinoma, ovarian tumors, and thyroid carcinoma. Accurate and timely diagnosis of metastatic NMT in the breast is mandatory to enable proper treatment. We compared clinical and pathological characteristics of metastatic NSCLC to breast with PBC to provide practical tools for pathologists in this essential differential diagnosis.

Design: Cases of non-hematopoietic NMT diagnosed in breast specimens were collected from archives of the BCCA Department of Pathology and the private collection of one author (MH). Clinical charts and pathologic slides were reviewed and ancillary tests performed where appropriate.

Results: 28 cases of metastatic NMT were identified including: 13 lung tumors, 6 melanomas, 4 ovarian tumors, 1 renal cell carcinoma, 1 vulvar carcinoma, 1 thymic carcinoma, 1 gastric carcinoma, and 1 carcinoid. NSCLC was the most common metastasis. Adenocarcinoma of lung (ACL) was most frequent (8/13), followed by small cell carcinoma (2/13). There was one case each of adenosquamous carcinoma, large cell neuroendocrine carcinoma and pulmonary carcinoid. The clinical and pathological features are summarized in table 1.

Table1: Clinicopathological characteristics of metastatic NSCLC to breast

Age/gender	Lung ca known at time of breast bx	Breast mass multifocality	DCIS	ER	TTF1	Axillary LNs	Distant metastases
64/F	Y	solitary	N	-	-	+	Y
70/F	N	two	N	+	+	+	NA
72/F	N	solitary	N	-	+	+	Y
76/M	N	two	N	-	-	-	Y
63/F	N	two, bilateral	N	-	+	+	Y
45/F	Y	solitary	N	-	+	-	Y
70/F	Y	solitary	N	-	NA	-	Y
69/F	N	solitary	N	-	+	+	Y
77/F	Y	solitary	N	-	-	NA	Y
65/F	N	solitary	N	NA	+	-	Y
55/F	Y	multiple bilateral	N	-	+	-	Y

Y=yes; N=no; NA=not available

Conclusions: Although rare, ACL can masquerade as PBC and needs to be considered in the differential diagnosis because the treatment and prognosis differ significantly. Even in the absence of a clinical history of lung carcinoma, metastatic carcinoma to the breast should be considered in at least one of the following scenarios: (1) single or multiple well circumscribed lesions of the breast with distant metastases but negative axillary lymph nodes, (2) cases which lack an in situ component and are triple negative yet not poorly differentiated or (3) those presenting as stage 4 PBT and/or having an unusually aggressive clinical course on standard breast therapy.

88 Intracystic Papillary Carcinoma (IPC) of the Breast: A Clinicopathological Study of 125 Cases

I Alvarado-Cabrero, R Valencia-Cedillo, S Barroso-Bravo. Mexican Oncology Hospital, IMSS, Mexico, DF, Mexico.

Background: IPC is an uncommon breast neoplasm. Because of its rarity, data about its epidemiology is limited. On the other hand, IPCs have traditionally been considered to be a variant of ductal carcinoma in situ, however, it is not clear if some of these lesions might represent a special type of invasive carcinoma. The goals of this study were: to identify specific characteristics of patients (pts) with IPCs and investigate its natural history (behavior).

Design: We searched the pathology database from 1990-2010 for IPC and solid papillary carcinomas (SPCs). Two pathologists reviewed all H&E slides. We evaluated the expression of myoepithelial cell (MEC) markers, p63 and calponin as well as the expression of Estrogen Receptors (ER), Progesterone Receptors (PR) and HER2 in all cases. Clinical management and follow-up were obtained from clinical charts.

Results: 106 (85%) intracystic and 19 (15%) solid papillary carcinomas were the study group. The mean age at diagnosis was 59 years and the mean tumor size 2.2cm. From 106 IPCs cases, 82 were pure, 14 were IPC with microinvasion (IPC+Mi), and 10 cases were IPC with invasive carcinoma (IPC+IC). Six (32%) of SPCs were associated with invasive carcinoma (SPC+IC). All 125 cases showed complete absence of MEC at the periphery of the nodules, also, all tumors were ER and PR positive and HER2 negative. 52 pts underwent mastectomy, of these, 6 cases with IPC+IC, 3 with SPC+IC, 2 with pure IPC and 1 with pure SPC, respectively, had lymph node metastases. 73 pts underwent lumpectomy, of these pts, 48 received radiation and 25 hormonal treatment. Eight of 73 (11%) pts treated conservatively (1 with pure IPC, 4 with IPC+IC, one with IPC+Mi, and 2 with SPC+IC) recurred locally, including one who later developed lung metastases.

Conclusions: Pure IPCs and SPCs: have excellent prognosis; because they are strongly ER and PR positive, hormonal therapy should be pursued for its management; routine use of chemotherapy is clearly not appropriate. Sentinel Lymph node biopsy may be a prudent way to evaluate axillary involvement.

89 Inter-Observer Agreement among Pathologists for Assessing Ki-67 Labeling Index on Whole Slides and "Hot Spots" in Breast Carcinomas

M Amin, D Cohen, DJ Dabbs, KL Cooper, TE Jones, M Jones, GA Trucco, M Chivukula, R Bhargava. Magee-Womens Hospital of UPMC, Pittsburgh, PA; University of Pittsburgh Cancer Institute, Pittsburgh, PA.

Background: Tumor proliferation rate is an important prognostic factor in breast carcinoma. Ki-67 immunohistochemical labeling index (LI) is helpful in determining the tumor rate of proliferation. However, it remains unclear whether the entire tumor should be considered for calculating the LI or the most proliferative regions (so called "hot spots"). Moreover, data on inter-observer agreement for such semi-quantitative scoring methods is limited.

Design: 74 resected ER+ invasive breast cancer specimens were considered for this study. Ki-67 was performed on 4-micron thick tissue sections using clone 30-9 (Ventana). The whole slide Ki-67 LI (WSLI) was estimated as the percentage of positive cells within the entire tumor section. The "hot spot" Ki-67 LI (HSLI) was scored as the percentage of positive cells in the most densely staining region of the slide. Four pathologists independently scored each slide and recorded the WSLI and HSLI. Agreement between observers was analyzed via intraclass correlation coefficient (ICC). Both ICC(A,1) and ICC(C,1) are reported.

Results: The difference between HSLI and WSLI for observers 1, 3, and 4 was between 0-10 percentage points in >80% of cases. Observer 2 scores showed a 0-20 percentage point difference in 73% of cases and a 0-10 percentage point difference in 51% of cases (table 1).

Table 1. Difference Between WSLI and HSLI for 4 Observers

	Correlation coefficient between WSLI and HSLI	Mean difference HSLI minus WSLI (95% CI)
OB1	0.984	8.9 (7.8, 10.0)
OB2	0.875	16.3 (13.0, 19.6)
OB3	0.945	5.0 (3.7, 6.2)
OB4	0.949	8.0 (6.6, 9.4)

OB: Observer; CI: confidence intervals.

The agreement for WSLI and HSLI between 4 observers is shown in table 2.

Table 2. Agreement for WSLI and HSLI Between 4 Observers

	ICC(A,1) [95% CI]	ICC(C,1) [95% CI]
Ki-67 WSLI	0.55 [0.27, 0.73]	0.71 [0.62, 0.79]
Ki-67 HSLI	0.50 [0.17, 0.72]	0.74 [0.66, 0.82]

ICC(A,1): two-way random effects model measuring absolute agreement of values; ICC(C,1): two-way random effects model measuring consistency of scores; CI: confidence intervals.

Conclusions: Tumor proliferation in ER+ breast cancers appears fairly homogeneous as the difference between HSLI and WSLI is ≤ 10 percentage points in most cases. The more variable component of Ki-67 LI appears to be inter-observer variability as some pathologists consistently score higher or lower than others. Image analysis systems that can distinguish invasive from non-invasive cells may help improve Ki-67 scoring.

90 CEP17 "Polysomy" (CEP17P): Definition and Impact on HER2 Copy Number (CN) in Breast Carcinoma

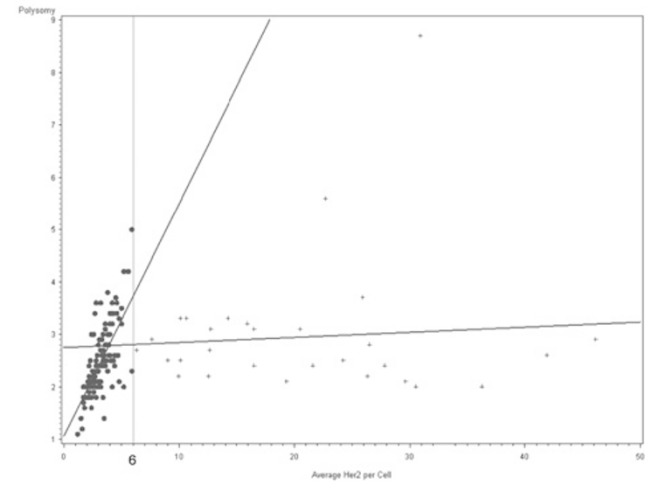
K Astvatsaturyan, J Mirocha, S Bose. Cedars-Sinai Medical Center, Los Angeles, CA.

Background: CEP17P is a frequent finding in breast cancer and complicates the interpretation of HER2 amplification results. Its reported frequency and definition varies considerably. Various studies have used mean cut off values between 2.1 to 3. Recent reports suggest that CEP17P results from centromeric amplification and is not linked to true polysomy of chromosome 17. Therefore its use in the evaluation of HER2 status may provide misleading information. This study aims at defining CEP17P and determining its relationship with HER2 CN.

Design: 235 consecutive cases of invasive breast cancer diagnosed between 4/1-8/30/10 were reviewed. Fixation of breast tissue and evaluation of prognostic markers were in accordance with 2007 CAP guidelines. Mean CEP17 CN/cell was recorded to determine incidence and relationship to various prognostic markers including tumor size, tumor grade, lymph node metastasis, ER, PR, Ki-67, and HER2 expression, amplification and presence of genetic heterogeneity (GH). Spearman correlation, Fisher exact test, Wilcoxon rank sum test and linear regression analyses were performed. A two sided p-value of 0.05 was considered significant.

Results: Mean CEP17 CN/cell varied from 1.1 to 8.7 (median 2.1). Values of ≥ 2.2 were noted in 44% (104/235) cases while 15% (36/235) demonstrated ≥ 3 CEP17/cell. A significant positive correlation between CEP17 CN and lymph node metastasis, proliferation rate (Ki67), mean HER2 CN/cell and HER2 GH and a significant negative correlation with ER and PR levels was noted. These associations were maintained at CEP17 CN of ≥ 2.2 (Wilcoxon rank sum test). The positive correlation observed between CEP17 and HER2 CN was seen in cases with ≤ 6 HER2 copies/cell representing cases without true HER2 amplification (Figure 1, blue line). No correlation was observed in cases with true amplification (Figure 1, purple line).

Correlation of CEP17P and Mean HER2 CN



Conclusions: CEP17 CN/cell of ≥ 2.2 is observed in 44% and ≥ 3 in 15% of breast cancers.

Correlation with adverse pathological features is noted at CEP17 CN/cell of ≥ 2.2 indicating that this may be the appropriate definition of CEP17 polysomy. Strong correlation is noted between CEP17 and HER2 CN of ≤ 6 indicating that CEP17P is associated with concurrent increase in HER2 CN in cases without true HER2 amplification.

91 Breast Carcinomas with Equivocal HER2/Neu Amplification: Morphologic Features, CEP17 Polysomy and HER2 Genetic Heterogeneity

K Astvatsaturyan, S Bose. Cedars-Sinai Medical Center, Los Angeles, CA.

Background: Her2/neu (HER2) status determines eligibility for targeted therapy with the anti-HER2-humanized monoclonal antibody, Trastuzumab in breast carcinoma. Expression is commonly assessed by immunohistochemistry (IHC) and amplification by fluorescent in situ hybridization (FISH). Amplification determines patient selection for therapy in breast carcinoma with equivocal IHC results. An equivocal FISH result, however causes uncertainty amongst clinicians regarding therapeutic options. The recent ASCO/CAP guidelines recommend additional testing for final determination. This study aims at determining the characteristics of breast carcinomas with equivocal HER2 amplification (average HER2/CEP17 ratio of 1.8-2.2) (EqHER2) and the role of chromosome 17 polysomy (CEP17P) and/or HER2 genotypic heterogeneity (GH).

Design: Our anatomic pathology database was searched for cases diagnosed as EqHER2 on FISH analysis between April 2010 and August, 2011. Breast carcinomas were fixed and evaluated in accordance with the 2007 ASCO/CAP guidelines. ER, PR, HER2 and Ki-67 expression was evaluated by IHC using image analysis while HER2 and CEP 17 copy number were evaluated by FISH. EqHER2 cases were charted to determine incidence and histopathologic features including tumor size, tumor grade, axillary lymph node metastasis, ER, PR, Ki-67, and HER2 expression, amplification, GH and presence of CEP17P (≥ 3 CEP17 signals/cell).

Results: 20 of 671 (3%) breast carcinomas were reported as EqHER2. Tumors varied in size from 7-50 mm (median 20.5 mm), with Bloom Richardson scores of 4-9 (median 8). 18 (90%) were ER positive, 13 (65%) were PR positive with high Ki67 proliferation index (2-68%, median 31%). Axillary lymph node metastasis was present in 8 of the 13

(62%) cases with axillary dissections. Two of the cases demonstrated overexpression (IHC3+), one of which contained >6 *HER2* signals/cell. One additional case with >6 *HER2*/cell (IHC 2+) was present in this cohort. 6 (30%) cases demonstrated CEP17P. GH was noted in 15 (75%) cases with 15 to 50% (median 23%) of the neoplastic cells demonstrating *HER2* amplification. Overall 12 (60%) cases demonstrated GH in the absence of CEP17P. There were 3 cases with CEP17P alone (without GH) and 3 with GH.

Conclusions: Breast carcinomas with EqHER2

- are rare, constituting 3% of invasive carcinomas
- are larger, poorly differentiated, positive for ER and PR with high proliferation rates (luminal B phenotype)
- demonstrate GH in 75% cases and polysomy in 30%.

92 Metastatic Melanoma Presenting as Isolated Breast Tumor: A Study of 20 Cases

CE Bacchi, SC Wludarski, AB Ambaye, J Lamovec, G Falconieri. Consultoria em Patologia, Botucatu, SP, Brazil; Institute of Oncology, Ljubljana, Slovenia; University of Vermont, Burlington, VT; General Hospital, Udine, Italy.

Background: Breast may be involved by metastasis in widely metastatic melanoma (MM) which is easily recognized microscopically if clinical information is available. However, MM presenting as an isolated mammary tumor may be more challenging to recognize since it may simulate a primary tumor clinically and morphologically.

Design: Cases of MM clinically presenting as breast tumors were retrieved. Breast MM in patients with systemic metastases or melanoma of the mammary skin were excluded. A panel of antibodies against keratins, S100 protein, gp100, and melan A was applied.

Results: 20 cases (17 females; 3 males) fulfilling the search criteria were included in the study. The age range was 27 to 91 years, median 47.5 years. A history of cutaneous melanoma was obtained in 19 cases; 1 patient had a history of choroid melanoma. Tissue material consisted mostly of core needle biopsy or limited excision specimens, although mastectomy was performed in two cases. 6 cases had been submitted as consultation material for "suspected breast cancer" for confirmation and/or for ER/PR and Her2 status assessment. The initial diagnoses proffered included high-grade invasive ductal (5 cases) or papillary carcinoma (2 cases) due to sheets of polygonal cells or pseudopapillary fronds, respectively. Diverging differentiation findings were also noticed, including sheets of monotonous small cells percolating through the breast fat (suggesting large-cell lymphoma), intersecting fascicles of cohesive cells (sarcomatoid carcinoma), cell nests admixed with lymphoid stroma (medullary carcinoma), lipoblast-like cells within a myxoid stroma (liposarcoma or lipophyllodes tumor). Tumor cells were negative for keratins and positive for S100 protein (20/20), gp100 (16/18) and melan A (14/16).

Conclusions: MM involving the breast may simulate a wide spectrum of primary breast malignancies. Although the application of a simple panel of antibodies assist in rendering the correct interpretation, a significant diagnostic bias may be introduced by lesions presenting as isolated tumors, especially when a timely history of primary cutaneous melanoma is not available or is even neglected by the patient. Further challenges are introduced by the extraordinary phenotypic plasticity of MM. Awareness of this pattern variance in the breast may be useful to avoid inappropriate treatment, especially in cases simulating a "triple negative" poorly differentiated carcinoma of the breast.

93 Morphological Characteristics of HER2 Over-Expressing and Basal-Like Breast Cancers and the Association between Lymphocytic Tumor Infiltrate and Prognosis

AL Bane, S Parpia, G Pond, V Kumar, G Gohla, MN Levine, T Whelan. McMaster University, Hamilton, ON, Canada.

Background: Gene expression profiling of human breast cancers has defined 5 molecular subtypes; luminal A/B, HER2 over-expressing, basal-like and claudin-low. Distinguishing morphological features have been described for some molecular subtypes particularly basal-like tumors. The goal of this study was to identify morphological characteristics associated with each of the molecular subtypes of breast cancer and examine their association with prognosis.

Design: 943 T1 and T2, lymph node negative, primary invasive breast cancers treated with breast conserving surgery (BCS) and adjuvant radiation had formalin fixed paraffin embedded (FFPE) tumor blocks available for TMA construction. On the basis of IHC expression of ER, PR, HER2, Ki67, EGFR, CK5/6, Claudins 3,4,7 and E-cadherin the tumors were classified as luminal A, luminal B, HER2 over-expressing, basal-like or claudin-low. A centralized pathology review was additionally performed on one full face section of each tumor by an expert breast pathologist who was unaware of the molecular subtype at the time of review. Kaplan-Meier methods were used to estimate overall survival at 12 years. Chi-square and log-rank tests were used to compare tumor characteristics and overall survival between subtypes.

Results: A molecular subtype was assignable in 872 of 943 tumors (83%), of which 357 (46%) were luminal A, 222 (28%) were luminal B, 32 (4%) were HER2 over-expressing, 110 (14%) were basal-like and 61 (8%) were claudin-low. When compared to luminal A type tumors, HER2 over-expressing and basal-like tumors were more likely to be grade III (43% and 81% vs 3%, p<0.001), have an extensive lymphocytic infiltrate (39% and 47% vs 4%, p<0.001), to have a central scar (28% and 45% vs 17%, p<0.001) and to have circumscribed tumor margins (38% and 49% vs 9%, p<0.001). HER2 over-expressing and basal-like tumors with an extensive lymphocytic infiltrate had a statistically significant (p=0.011) better overall survival (82.0% at 12 years, 95% confidence interval: 67.6% to 90.5%) than ER negative tumors without such an infiltrate (62.9% at 12 years, 95% confidence interval: 49.9% to 73.4%).

Conclusions: HER2 over-expressing and basal-like breast cancers share a number of morphological characteristics in common and both are distinctly different from luminal A tumors. HER2 over-expressing and basal-like tumors frequently demonstrate an extensive lymphocytic infiltrate which has prognostic significance in these ER negative subtypes.

94 Intraoperative Evaluation of the Nipple Margin in the Decision Making for Nipple Sparing Mastectomies

AL Barbieri, V Bossuyt. Yale-New Haven Hospital, New Haven, CT.

Background: Nipple-sparing mastectomies (NSMs) are increasingly performed for the surgical treatment of invasive and in situ breast cancer. Evaluation of the nipple margin by frozen section is used to decide at the time of surgery whether or not to preserve the nipple. We examined the effectiveness of this approach.

Design: We studied a consecutive series of NSMs at our institution (6-2010 to 5-2011). Discrepancies between frozen section and final permanent diagnoses were recorded. We retrospectively reviewed both frozen section and permanent slides of all cases.

Results: Sixty five nipple-sparing mastectomies were sent to Pathology in one year. Fifty five (85%) with separate designated "nipple-core" margins. Of these 55 nipple margins, 41 (75%) were sent for intraoperative evaluation.

Table 1: Nipple Margin Specimens

Number of Cases	Frozen Section Diagnosis	Permanent Diagnosis	Nipple Preserved?
51	Benign breast tissue	Confirmed	Y (Yes)
4	Intraductal hyperplasia	Confirmed	Y
1	Minimal epithelial proliferation with atypia	Discrepant, Benign breast tissue	Y
1	Extensive involvement by invasive lobular carcinoma	Confirmed	N (No)
1	Papillary lesion, no evidence of carcinoma	Confirmed	Y
1	Focal intraductal proliferation suspicious for atypia	Discrepant, Benign breast tissue	N
1	IDP with intraductal hyperplasia	Confirmed	Y
1	Cannot rule-out low grade DIN	Confirmed	Y

DIN=ductal intraepithelial neoplasia, IDP=intraductal papilloma

Review of frozen section and permanent diagnoses revealed two discrepancies: a diagnosis of "minimal epithelial proliferation with atypia" and "ductal proliferation suspicious for atypia" were not confirmed on permanent sections. One of these cases resulted in surgical excision of the nipple. Subsequent evaluation of the nipple revealed no abnormalities. In thirty nine cases the intent to preserve the nipple was maintained; in two cases the decision was changed. The diagnosis triggering this decision could not be confirmed on review of permanent sections in one of these two cases. Retrospective review of the slides revealed tangential sectioning and sloughing of epithelial cells as common potential pitfalls.

Conclusions: Findings necessitating surgical excision of the nipple are infrequent at the nipple margin. Our data suggests that there is a significant risk of overinterpreting findings at the nipple margin as atypical leading to inappropriate excision of the nipple. In our series no false negative frozen section diagnoses were recorded.

95 c-MET Overexpression Is Associated with Breast Cancer Distant Metastasis and Loco-Regional Recurrence

JP Bergeron, HT Richard, JA Almenara, MO Idowu. Virginia Commonwealth University, Richmond, VA.

Background: Dysregulation of the c-Met receptor tyrosine kinase has been shown to confer resistance to DNA-damaging chemotherapeutic agents and is also associated with overall poor prognosis in a variety of tumors. Several clinical trials are currently investigating the use of novel c-Met inhibitors as a potential target for future therapeutic modalities. In particular, the agent ARQ 197 (Ds-5178) is currently being tested in a clinical trial for lung carcinoma. Currently, limited information is available on the association of c-Met overexpression with distant metastatic or recurrent disease in breast carcinomas. This study evaluated the relationship between c-Met expression and distant metastases along with a variety of other clinico-pathologic parameters including Ki-67 expression, local recurrence, triple negative hormone receptor status, and lymph node status.

Design: The clinical outcome and pathologic characteristics of breast carcinoma cases from 1992 to 2008 with adequate follow up information were reviewed. A minimum of 60 months of follow-up was required for inclusion of cases without recurrence or metastases. For each case, tissue microarrays (TMA) were created by obtaining 1 mm cores in triplicate from different areas of the tumor using an automated TMA system (Beecher ATA-27). The specimens were stained with a rabbit polyclonal antibody to c-MET (Abcam, MA USA). Cases with moderate to intense membranous staining were considered positive. Statistical significance was determined using a Chi-squared test.

Results: Of 281 cases, 84 had distant metastases and 33 had loco-regional recurrence. The median follow-up period for all cases was 72 months, and ranged from 12 to 228 months. A greater proportion of cases with distant metastases and cases with local recurrence were associated with c-MET positivity (67 vs 17, p<0.05) and (26 vs 7, p<0.05), respectively. Additionally, c-MET positivity was associated with high Ki-67 (>30%), triple negative hormone receptor status, axillary lymph node positivity, and high histologic grade.

	c-MET pos	c-MET neg	
% dist mets (n=84)	80% (67)	20% (17)	1.1 x 10 ⁻⁵
% local recur (n=33)	79% (26)	21% (7)	1.93 x 10 ⁻⁵
% grade III (n=109)	72% (79)	28% (30)	1.98 x 10 ⁻⁵
% high Ki67 (n=95)	75% (71)	25% (24)	3.22 x 10 ⁻⁵
% triple neg (n=74)	66% (49)	34% (25)	7.26 x 10 ⁻⁶
% LN pos	85% (97)	15% (17)	3.16 x 10 ⁻⁷

Conclusions: c-MET positive breast carcinomas are associated with increased incidence of metastases and loco-regional recurrence. Therefore, c-MET may be a useful marker for prognosis as well as a potential therapeutic target.

96 LYRIC Is Associated with an Increased Incidence of Distant Metastasis and Loco-Regional Recurrence in Patients with Breast Carcinoma

JP Bergeron, HT Richard, J Richey, JA Almenara, MO Idowu. Virginia Commonwealth University, Richmond, VA.

Background: Overexpression of LYRIC, also known as astrocyte elevated gene-1 (AEG-1)/metadherin, has been reported to be associated with breast cancer progression. However, limited information is available on the association of LYRIC overexpression and distant metastatic or recurrent disease in breast carcinomas. Elucidation of pathways that lead to tumor progression and metastases is vital for the development of targeted therapy. This study evaluated the relationship between LYRIC expression and loco-regional recurrence, distant metastasis, axillary lymph node status, histologic grade, and triple negative tumors.

Design: The clinical outcome and pathologic characteristics of breast carcinoma cases from 1992 to 2008 with adequate follow-up information were reviewed. A minimum of 60 months of follow-up was required for inclusion of cases without recurrence or metastases. For each case, tissue microarrays (TMA) were created by obtaining 1 mm cores in triplicate from different areas of the tumor using an automated TMA system (Beecher ATA-27). The specimens were stained with a rabbit polyclonal antibody to LYRIC (Abcam, MA USA). The cases were reviewed independently by two pathologists. Cases with moderate to intense cytoplasmic and nuclear staining were considered positive. Statistical significance was determined using a Chi-squared test.

Results: Of 285 cases, 86 were found to have distant metastases and 34 had loco-regional recurrence. The median follow-up period for all cases was 72 months, and ranged from 12 to 228 months. A greater proportion of cases with distant metastases and cases with local recurrence were associated with LYRIC positivity (59 vs 27, $p=0.006$) and (26 vs 8, $p=0.004$), respectively. Additionally, LYRIC positivity was associated with axillary lymph node metastasis (92 vs 26, $p=0.004$), high histologic grade (74 vs 37, $p=0.003$) and triple negative hormone receptor status (48 vs 27, $p=0.003$).

	LYRIC pos	LYRIC neg
% distant mets (n=86)	69% (59)	31% (27)
% local recur (n=34)	76% (26)	24% (8)
% grade III (n=111)	67% (74)	33% (37)
% high Ki67 (n=95)	69% (66)	31% (29)
triple neg (n=75)	64% (48)	36% (27)
% LN pos (n=118)	78% (92)	22% (26)

Conclusions: LYRIC positive tumors are associated with increased incidence of metastases and loco-regional recurrence. Therefore, LYRIC may be a useful marker for prognosis as well as a potential additional therapeutic target in breast cancer patients.

97 Predictors of Response to Standard Neoadjuvant Chemotherapy in Estrogen Receptor Positive, HER2 Negative Breast Cancer

R Bhargava. Magee-Womens Hospital of UPMC, Pittsburgh, PA.

Background: In contrast to estrogen receptor (ER) negative tumors, ER+/HER2- tumors rarely achieve pathologic complete response (pCR) to standard neoadjuvant chemotherapy. Nevertheless, tumor volume reduction secondary to NACT in ER+/HER2- tumors help these patients undergo breast conserving therapy, which is the primary goal of NACT. Therefore, it is important to know which routinely assessed parameters predict for >50% tumor volume reduction (TVR), so that patients are appropriately selected for NACT. We performed subset analysis (from a previously reported dataset of 359 cases: Cancer. 2010;116:1431-1439) of 119 ER+/HER2- cases treated with standard NACT at our institution from 1999-2006.

Design: Semi-quantitative H-scores for ER, progesterone receptors (PR), age, pre-therapy tumor size were available on all cases. H&E slides were available on 75 cases. Numerous morphologic parameters were analyzed in the pre-therapy biopsy including Nottingham score, grade and individual grading components, and absolute mitosis count/10 high power fields (hpf). The following features were considered present if identified in >10% of the tumor: lobular-like growth pattern, apocrine differentiation, intra-tumoral lymphocytic infiltrate, and geographic necrosis. Nucleoli were considered prominent if visible at 10X objective and substantial apoptosis was considered present if easily visible at 10X. All parameters were statistically analyzed using t-test to determine if they predict for >50%TVR.

Results: Of the 119 patients, 24 (20%) showed >50% tumor volume reduction and 95 (80%) showed ≤50% TVR. The mean and median PR H-scores for tumors that showed >50% TVR were 90 and 70 respectively compared to 132 and 140 for cases that showed ≤50%TVR ($p=0.03$). The other parameters that predicted >50% TVR were mitotic activity score of 2/3 ($p=0.01$), Nottingham score of 7 or higher ($p=0.04$), Nottingham grade of 3 ($p=0.02$). Patient's younger age and tumor high absolute mitotic count/10 hpf showed a trend for >50% TVR ($p=0.07$). All other clinical and morphologic parameters including ER H-score did not reach statistical significance in predicting >50%TVR.

Conclusions: Semiquantitative PR H-score and tumor mitotic activity are the 2 most important parameters that predict for significant tumor volume reduction to standard NACT in ER+/HER2- tumors. Although not analyzed in this study, Ki-67 labeling index may also provide information similar to tumor mitotic activity. Therefore PR H-score and some measure of tumor cell proliferation should be taken into account in selecting ER+/HER2- patients for standard NACT.

98 HER2 Overexpression Is a Major Risk Factor for Recurrence in pT1a-b, N0 Breast Cancer: A French Regional Population-Based Study of 671 Patients

F Bibeau, F Boissiere-Michot, A Denouel, V Szablewski, H Perrocchia, C Pignodel, A Gudin de Vallerin, C Leaha, M-C Chateau, G Barneon, P Vic, A Garnier, M Granier, P Roger. CRLCC Val d'Aurelle, Montpellier, Hérault, France; Hôpital Gui de Chauliac, Montpellier, Hérault, France; Groupe Hospitalo-Universitaire, Nîmes, Gard, France; Centre de Pathologie, Montpellier, Hérault, France; CACP Les Tonnelles, Montpellier, Hérault, France.

Background: Only very few studies have been performed about HER2 status in small breast cancer. We aimed to evaluate the prognostic impact of HER2 overexpression (3+) in patients with pT1a-b, node negative (N0), breast cancers.

Design: From 1999 to 2004, 1127 pT1a-b, pN0 breast cancer patients were identified, thanks to the ONCO LR Southern French regional network. Treatments were: conservative (95%), tamoxifen (80%), chemotherapy (5%). HER2 status was retrospectively assessed in 671 samples (121 pT1a/549 pT1b) by immunohistochemistry (IHC) (HER-2/neu (4B5) Primary Antibody, Ventana®). Amplification was tested by dual in situ hybridization (Inform HER2 Dual ISH assay or DISH, Ventana®).

Results: HER2 3+ was observed in 5.2% of the patients and most frequently identified in: pT1a lesions (12.3% vs 3.6%; $p=0.0001$), mastectomies (14% vs 4.4%; $p=0.023$), grades 2-3 (91% vs 50%; $p<0.0001$), estrogen receptor (ER) negative (-) tumors (57% vs 30%; $p<0.0001$), progesterone receptor (PR) negative (-) tumors (74% vs 42%; $p=0.0002$). 33 relapses (5%) were observed (median follow-up: 6.4 years (range, 0.3 to 9.9 years)). The 5-year DFS rates were 78% and 95% in HER2 3+ and HER2 non overexpressed (-) tumors, respectively ($p=0.017$). According to the IHC phenotype, 5-year DFS, were 95%, 94%, 85% and 73.6% for ER+PR+/HER2- ($n=502$, 75%), ER-/PR-/HER2- ($n=134$, 20%), ER+/PR+/HER2 3+ ($n=15$, 2%) and ER-/PR-/HER2 3+ tumors ($n=20$, 3%), respectively ($p=0.02$). In univariate analysis, HER2 3+ tumors ($p=0.017$), phenotype classification ($p=0.02$) and adjuvant treatment ($p=0.013$) were significant prognostic factors. In multivariate analysis, HER2 3+ patients had higher risks of recurrence than HER2- tumors ([HR], 2.41; 95% CI: [1.06-5.53]; $p<0.05$). DISH interpretation is ongoing and results will be presented at the meeting.

Conclusions: pT1a-b, pN0 HER2 3+ breast cancer patients have a significant risk of recurrence. In ER+/PR+ patients, HER2 3+ status is associated with a worse DFS than patients with triple negative tumors, in spite of tamoxifen. HER family pathway might be the cause of prognostic variability within these ER+ tumors. In the light of the worse prognosis of HER2 3+ pT1a-b, pN0 tumors, HER2 testing is necessary and further investigation of a potential benefit from an HER2 treatment is warranted.

99 High Concordance of 6 HER2 In Situ Hybridization Methods with Abbott FISH

JE Boers, C Netjes, HC Meeuwissen, C Prinsen, C van Krimpen, J Bart, EMJ van der Logt, E Schuurink. Isala Klinieken, Zwolle, Netherlands; Canisius Wilhelmina Ziekenhuis, Nijmegen, Netherlands; Kennemer Gasthuis, Haarlem, Netherlands; University Medical Center Groningen, Groningen, Netherlands.

Background: HER2 *in situ hybridization* (ISH) has become a common test in breast cancer. Abbott FISH was used in most clinical studies showing the efficacy of anti-HER2 treatment in HER2 positive carcinomas. Only reports comparing one or two of newly developed ISH assays with Abbott FISH have been published previously. We conducted a comprehensive concordance study of 6 ISH methods with Abbott FISH in a large series of breast carcinomas.

Design: Tissue Micro Arrays (TMA) were constructed by taking three 0.6 mm tissue cores from formalin-fixed/paraffin-embedded tissue-blocks from 402 primary breast carcinomas diagnosed in 2007 (supported by the Dutch Pathological Society). Up to 384 cases were analyzable in the TMA. ISH was performed after ample experience with 7 ISH assays. Scoring was performed by two independent observers without knowledge of the other ISH data according to the ASCO-guidelines for HER2-testing. HER2 and chromosome 17 (Chr17) signals were counted separately, the HER2:Chr17 ratio was calculated and considered positive when the ratio was ≥ 2.0 . In cases with a ratio was between 1.8 and 2.2, additional enumeration was performed. The discordant cases were reviewed and scores were reassigned on consensus of opinion. Concordance and Cohen's kappa score were calculated in relation to FISH, Abbott.

Results: are presented in the table:

Methods	Analyzable cases	HER2 ratio ≥ 2.0	Concordance	Kappa-score
FISH, Abbott	372	45 (12.1%)	X	X
FISH, DAKO	352	40 (11.4%)	98.1%	0.90
FISH, Zytovision	357	45 (12.6%)	99.1%	0.96
single probe SISH, Ventana	357	43 (12.0%)	98.9%	0.95
dual probe SISH, Ventana	371	47 (12.7%)	99.4%	0.97
duoCISH, DAKO	364	38 (10.4%)	97.2%	0.86
duoCISH, Zytovision	344	43 (12.5%)	99.1%	0.96

Concordance / Kappa-score: compared to Abbott FISH

Conclusions: Concordance of 6 HER2 ISH assays with Abbott FISH were shown to be 97.2% or higher. In this study, DAKO assays had a lower kappa score with Abbott FISH than Ventana or Zytovision assays.

100 Changing Frequency of Equivocal HER2/Neu Scores and Factors Predictive of Negative HER2/Neu Fluorescent In-Situ Hybridization in Invasive Carcinomas of the Breast

FI Boulos, CJ Youssef Massad, FA Fedda, CG Farra, EM Saad Aldin, H Doumiati, AN Tawil, A Tjajli. American University of Beirut Medical Center, Beirut, Lebanon.

Background: Since the introduction of HER2 FISH testing to the pathology laboratory at the American University of Beirut Medical Center, a notable increase in the percentage of HER2 immunohistochemistry (IHC) equivocal (2+) cases was recorded (24 to 46%).

This was initially attributed to a greater tendency for pathologists to default to FISH testing in cases that were not extremes of positivity and negativity. A closer look at these cases was however deemed necessary, to ensure and maximize consistency as a first endpoint, and as a second endpoint, to identify predictors of FISH negativity in tumors with equivocal IHC. This is especially relevant in the Lebanese patient population which comprises a significant number of self-payers with limited financial resources. **Design:** Beginning in January 2010, 73 cases with a score of HER2 2+, HER2 FISH testing and full available clinicopathologic information were reviewed. HER2 IHC score was reassessed by FB and FF. Variables including age, site, size, grade (proliferation rate, pleomorphism and tubule formation), lymphovascular invasion, lymph node involvement, estrogen and progesterone receptor, and HER2 staining in normal glands were recorded. Univariate and multivariate regression analysis was performed to identify statistically significant associations between different variables and HER2 FISH status. **Results:** Of the 73 cases blindly reviewed, 13 were downgraded to 1+, and 4 were upgraded to 3+. This resulted in a drop from 47% to 33% in the overall percentage of HER2 2+ cases. There was no FISH HER2 amplification in the downgraded cases. Of the 4 cases that were upgraded, one was not FISH amplified. Analysis of the remaining 56 cases showed the following: 20% (11/56) were FISH amplified, all 14 cases that were grade 1 were FISH negative ($p=0.014$), only 1 of 14 cases with low proliferation was FISH amplified ($p=0.012$). This case was 3 mm in size. Finally, none of the 4 cases with strong diffuse positivity for ER and PR in all tumor cells was positive by FISH ($p=0.028$). Of note is that 10 cases with strong (equivalent to 2+) staining in normal glands were all negative by FISH ($p=0.001$).

Conclusions: In order to decrease the number of potentially unnecessary FISH tests, we suggest review of the HER2 IHC by at least two pathologists to increase scoring accuracy. Also, in cases where cost may be a problem, FISH testing may not be necessary in cases that are grade 1, have strong diffuse ER and PR staining, or show strong non-specific staining in normal breast epithelium.

101 Contralateral Breast Cancer Risk Following a Diagnosis of Ductal Carcinoma In Situ

FI Boulos, JF Simpson, PA Schuyler, WD Dupont, DL Page, ME Sanders. American University of Beirut, Beirut, Riad El Solh, Lebanon; Vanderbilt University, Nashville, TN.

Background: The number of women choosing contralateral prophylactic mastectomy following a diagnosis of ductal carcinoma (DCIS) appears to be on the rise. The risk of subsequent contralateral invasive breast cancer (IBC) following a diagnosis of IBC is well established (approximately 0.5-1.0% per year). Natural history studies of DCIS indicate risk is exclusively ipsilateral but follow-up data from retrospective and prospective intent-to-treat studies clearly demonstrate a range of contralateral risk.

Design: We assessed contralateral breast cancer risk in women enrolled in the Nashville Breast Cohort diagnosed as having DCIS between 1950-2009, no prior history of IBC and at least contralateral remaining breast tissue. Laterality, cancer type, cancer grade and time to cancer diagnosis were correlated with survival.

Results: Among 288 women with a diagnosis of DCIS and available follow-up, 41 (14%) developed a subsequent IBC in either breast at an average of 8 years (range 1-42 yrs) and 14 (4.8%) developed a second DCIS in either breast at an average of 8 yrs (range 2-25 yrs) after their original DCIS diagnosis. Laterality of IBC: 29 (10%) ipsilateral, 9 (3.1%) contralateral, 3 unknown. Laterality of second DCIS: 7 (2.4%) ipsilateral, 6 (2.1%) contralateral, 1 unknown. The average time to ipsilateral IBC was 8.9 yrs (range 1-42) vs. 5.2 yrs (range 1-14) for contralateral IBC. The average time to ipsilateral DCIS was 7 yrs (range 3-25) vs. 4.2 yrs (range 3-6) for contralateral DCIS. There was no apparent relationship between the type and grade of the initial DCIS and the contralaterally-occurring IBC or second DCIS. The grade of the ipsilaterally-occurring IBC and second DCIS generally paralleled grade of the original DCIS. There were 7 breast cancer deaths among women developing ipsilateral IBC but none in the women with contralateral IBC.

Conclusions: The risk of contralateral IBC following a diagnosis of DCIS in this population based cohort (3%) is less than one third that of ipsilateral risk (10%) but with an earlier occurrence. Interestingly, the risk of contralateral DCIS (2.4%) was approximately the same as ipsilateral DCIS (2.1%), likely the result of greater tendency to treat the incident DCIS by mastectomy in the early years of this study. We found risk of contralateral IBC following a diagnosis of DCIS to be 0.22% per year. This rate is comparable to the 0.34% yearly incidence rate in the general population, and our data suggest prophylactic contralateral mastectomy following a diagnosis of DCIS provides no survival advantage.

102 Patterns of Oncotype DX Recurrence Scores – Analysis Based on Levels of ER & PR Expression and Proliferation Markers

M Burge, S Frame, P McGrath, E Romond, M-L Fjallskog, C Ahlin, M Cibull, Y Brill, LM Samayoa. University of Kentucky, Lexington, KY; Uppsala University, Uppsala, Sweden.

Background: In 2010 we reported that in 20 – 30% of patients undergoing Oncotype DX, the test was probably of no clinical significance, since Low (L) and High (H) Recurrence Scores (RS) for Grade (G) I & GIII tumors could be accurately predicted based on tumor differentiation, Progesterone (PR) status (+/-) and high Estrogen (ER) expression (95% of tumor cells). We currently test the possibility of identifying other groups of ER (+) patients with predictable RS by analyzing the role of proliferation markers (PM) and levels of PR expression in the same patient population.

Design: Histopathologic material from 72 patients with known Oncotype DX RS was analyzed for the following: tumor grade (Elston Modification of Bloom-Richardson Score), levels (%) of ER and PR expression, proliferating index (PI) according to Cyclin A and Ki-67 expression (%), and number of mitoses in 10 high power fields (HPF). All analyses were performed in sections from definitive surgical specimens.

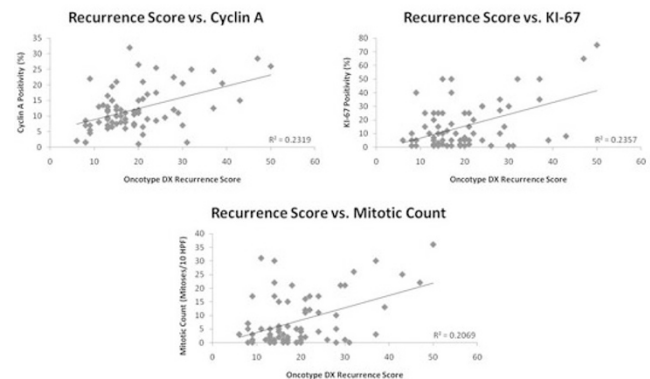
Levels of ER, PR, Ki-67 and Cyclin A were performed by Immunohistochemistry (IHC) and scored by a consensus of 3 pathologists. Each variable was then correlated with the corresponding RS.

Results: See Figures 1 and 2.

Table 1. Oncotype DX Recurrence Scores according to PR expression and average Cyclin A and Ki-67 levels.

Patients with > 80% ER (+)	PR expression (%)				Oncotype DX (RS)			Aver RS	Aver Cyclin A (%)	Aver Ki67 (%)	Aver Mitotic count/10HPF
	0	1-30	31-75	76-100	Low (0-10)	Int (10-31)	High (31-50)				
GII PR (+/-) (n=18)	3	3	1	11	16	2 (<20)*	-	13	8.8	4.5	1.6
GII PR (+) (n=15)	-	-	-	18	11	7 (<21)*	-	16	11	10	4.4
GII PR (+) (n=15)	-	11	4	-	5	9	1	20	12	17	5
GII PR (-) (n=4)	4	-	-	-	-	4	-	25	8	11.6	3.6
GIII PR (+) (n=11)	-	-	4	7	7	2	2	21	17	21	23
GIII PR (+) (n=3)	-	3	-	-	-	2	1	33	16	30	20
GIII PR (-) (n=3)	3	-	-	-	-	1	2	40	22	37	26

* Actual RS



Conclusions: 1) The combination of tumor grade and levels of PR expression in patients with tumors showing >80% (+) ER are predictors of Oncotype RS. 2) Although average values of Cyclin A, Ki-67 and mitotic counts correlated with average RS accordingly, regression analysis failed to show an acceptable correlation in predicting RS scores individually. 3) Depending on clinical judgement, these observations may result in stricter indications for Oncotype DX, i.e.: only in patients with GII < 75% PR (+) tumors and GIII > 30% PR (+) tumors, ultimately resulting in cost containment equivalent to > 50% (28/72) of resources currently disbursed without clinical validation.

103 Characterisation of the Repertoire of Gene Copy Number Changes and Gene Mutations in the Progression from In Situ to Invasive Breast Cancer

A Campion-Flora, L Hernandez, P Wilkerson, MB Lambros, DN Rodrigues, A Gauthier, A Mackay, R Natrajan, JS Reis-Filho. The Institute of Cancer Research, London, United Kingdom; Institut Curie, Paris, France.

Background: The underlying mechanisms of the progression of ductal carcinoma *in situ* (DCIS) to invasive ductal carcinoma (IDC) are yet to be fully elucidated. There is evidence to suggest that breast cancers are composed of a mosaic of non-modal cancer cell populations that harbour specific genetic alterations in addition to the founder genetic hits. Progression from DCIS to IDC may be mediated by the selection of a subpopulation of cancer cells with specific genetic aberrations, or by the acquisition of new genetic aberrations including specific copy number aberrations. The aims of this study were to determine the gene copy number aberrations and repertoire of mutations in common oncogenes in matched DCIS and IDC.

Design: Fresh frozen samples of breast cancer containing *bona fide* areas of DCIS and IDC in the same specimen were retrieved from thirteen patients. Twenty 10µm sections per case were microdissected under a stereomicroscope, with IDC and DCIS components collected separately. DNA was extracted and subjected to i) microarray-based comparative genomic hybridisation (aCGH), and ii) Sequenom Oncocarta v1.0 panel to determine the prevalence of hot-spot mutations in 19 known oncogenes. Fluorescence *in situ* hybridisation and Sanger sequencing were employed to validate the aCGH and Sequenom findings, respectively.

Results: In 9 of the 13 cases, the gene copy number profiles and mutational spectrum of matched DCIS and IDC components were strikingly similar. In the remaining four cases, high level gene amplifications of five loci (i.e. 1q41, 2q24, 6q22, 8q21 and 9p13) were either restricted to the IDC component or the number of cells harbouring the amplification were higher in the IDC than in the DCIS component, suggesting enrichment of cells harbouring those amplicons in the IDC component. Sequenom MassArray identified *PIK3CA* mutations restricted to the DCIS component in two cases, suggesting selection of a clone that did not harbour the mutation in the process of invasion.

Conclusions: Our results provide strong circumstantial evidence to suggest that, in some cases, the progression of DCIS to IDC is driven by the selection of non-modal

clones that harbour a specific repertoire of genetic aberrations, whilst in other cases by the negative selection of clones that harbour specific genetic aberrations (e.g. *PIK3CA* mutations in oestrogen receptor positive breast cancer). Genetic aberrations other than gene copy number changes or epigenetic aberrations may drive progression from DCIS to IDC in the majority of other cases.

104 Controlling Preanalytic Variables Eliminates Her2 and Estrogen Receptor Status Discordance among 50 Paired Breast and Axillary Node Core Biopsies

C Carter, JM Avent, RE Rosenthal, MEH Hammond, DV Miller. Intermountain Medical Center/LDS Hospital, Salt Lake City, UT.

Background: Discrepancy in Her2 and estrogen receptor (ER) status among primary breast tumors and their axillary lymph node metastases has been reported in the range of 6-18%, leading to confusion as to the optimal sample for testing. In these reports, however, the preanalytic conditions (particularly time to fixation and fixation duration) for the samples were either nonuniform or unspecified. Whether the discrepancies are due to innate biologic factors (such as intratumoral heterogeneity) versus assay performance due to differing preanalytic conditions is therefore unclear.

Design: Core biopsy samples from 50 primary breast invasive ductal carcinomas and their corresponding ipsilateral axillary lymph node metastases obtained at the same procedure, using the same core biopsy sampling device, fixed under the same conditions, stained on the same staining runs (Dako HercepTest and ER clone 1D5), and analyzed using digital image analysis constitute the study cohort. Patient demographics and tumor characteristics (from subsequent excision specimens or clinical imaging) were obtained from electronic medical records.

Results: The mean age of the 50 women was 51.72 (27-86). Mean time to fixation was 2.55 minutes and the mean duration of fixation was 12.87 hours (6.4-29.7). The Her2 scores were 0 = 2, 1+ = 13, 2+ = 12, 3+ = 23. Complete agreement in Her2 scores was seen among all paired samples. For 3+ cases, the mean tumor size was 3.47 cm, 44% were ER negative and the mean tumor grade was 2.61 (of 3). For 0/1+ cases, the mean tumor size was 3.86 cm, 38% were grade 3 and triple negative, and the mean tumor grade was 2.46 with three grade 1 tumors (seen only in this group). The ER (Allred) scores were 0 = 17, 3 = 1, 4 = 1, 5 = 3, 6 = 9, 7 = 7, 8 = 12. For ER negative tumors the mean tumor grade was 2.76. For ER positive tumors the mean tumor grade was 2.39 including all 3 grade 1 tumors. Only minor discrepancies in Allred scores occurred between the paired samples; 5 with a difference of 1 (6-7, 7-8, 8-7, 7-6, 8-7, and one with a difference of 2 (8-6). The mean age did not differ significantly by ER or Her2 status.

Conclusions: Under matched processing conditions, these 50 paired primary breast tumors and their lymph node metastases show congruent Her2 and ER staining results. Minor differences in staining intensity and percent positive cells were noted. It is possible these minor differences, if magnified through the influence of disparate fixation conditions, could account for the higher discrepancy rates reported in the literature.

105 Comparison of FISH and SISH Methods for HER2 Testing in Breast Carcinoma: A Validation Study Emphasizing Automated Methods

MC Chang, M Rogers, G Kuruzar, M Reid, M Mendes, P Plotnick, A Azad. Mount Sinai Hospital, Toronto, ON, Canada; Univ of Toronto, Toronto, ON, Canada.

Background: Amplification for the HER2 gene is of prognostic and predictive significance in breast carcinoma. The standard methodology for assessing HER2 amplification is FISH. Silver-based methods (SISH) represent newer technology that allow assessment of HER2 status, but using brightfield microscopy. Our goal is to evaluate and validate more automated methods of HER2 testing.

Design: Cases of invasive breast carcinoma tested for HER2 status by FISH were identified and selected to provide a sample representative of the patient population. A total of 100 cases were selected: 78 HER2-negative, 21 HER2-positive, and 1 HER2-equivocal. FISH processing used Vysis Pathvision probes (HER2 and CEP17, Abbott Laboratories). The original interpretation was by manual counting. Additional 4 µm sections were cut and SISH performed (Ventana Benchmark Ultra), with HER2 and Chromosome 17 tests on 2 separate slides. Manual counting of both slides was performed to calculate the ratio of HER2 to Chromosome 17. SISH slides were interpreted by automated imaging (Ventana VIAS), and the results compared to the manual counts (both SISH and FISH). FISH slides were interpreted using the Visiopharm Integrator System (Visiopharm, Denmark). The discordances between methods were analyzed, with the original FISH result as the "gold standard".

Results: Using both manual counting and automated scoring, SISH was concordant with manual FISH in 95% of cases. These discordances were either false negatives (up to 2.6%), or cases in which there was disagreement between positive and equivocal interpretations. The manual and automated scoring methods of SISH were 98% concordant with each other. The automated method of interpreting FISH was 93% concordant with the manual method. Compared to FISH, the SISH method demonstrated the following advantages: automated slide processing, faster interpretation by brightfield microscopy, and room-temperature slide storage. The main source of discordances between FISH and SISH was difficulty in the latter of interpreting clustered HER2 and Chr17 signals.

Conclusions: The FISH and SISH methods are highly concordant for the determination of HER2 status. FISH has the advantage of enabling the spectral filtering of signals for counting, and for evaluating the ratio within each cell. SISH, although requiring separate scoring of HER2 and Chr17 signals, has the advantages of automated processing and enabling scoring under brightfield microscopy. Both methods are amenable to automated interpretation.

106 Lobular Neoplasia on Core Needle Biopsy: Clinical and Radiopathologic Correlation Study with Follow-Up Excision Biopsy of 87 Cases

S Chaudhary, L Lawrence, G McGinty, K Kostroff, R Robbins, T Bhuiya. North Shore LIJ Health System, Lake Success, NY; North Shore LIJ Health System, New Hyde Park, NY; Nassau Radiologic Group, Lake Success, NY.

Background: Lobular neoplasia (LN) which includes Lobular carcinoma in situ (LCIS) and Atypical lobular hyperplasia (ALH) may be identified in breast core biopsies as an incidental finding with microcalcifications, mass lesion or indeterminate enhancements. Several studies have shown variable upgrade rates (1-40%), but many of these are limited by small sample size, selection bias and discordant radiopathologic correlation. The aim of our study was to assess the risk of invasive carcinoma/DCIS at the site of the isolated LN diagnosis on core biopsy and to assess any significant factors associated with the upgrade.

Design: The data base was searched for breast core biopsies from Jun 06- Jun 11 with the diagnosis of LCIS/ALH. Any case with coexistent pleomorphic LCIS, ADH, flat epithelial atypia, papilloma or radial scar was excluded from the study. Core and excision biopsy slides of all cases were reviewed using Page's criteria. Radiopathologic correlation was done for all cases. 87 cases with follow up excision biopsy qualified for study. Presence of invasive carcinoma/DCIS in direct correlation to initial biopsy site with LN defined the lesion as upgrade. The proportion of upgrade on excision and 95% confidence intervals (CI) were calculated.

Results: Our study consisted of 83 females, mean age 55 yrs (age range=37-88yrs) with 87 core biopsies showing isolated LN (22 ALH, 44 LCIS and 21 ALH&LCIS). Of these, 13 had family history and 28 had history of breast cancer (2 bilateral, 16 contralateral and 10 ipsilateral). Core biopsy indication included calcification in 36 (41%), non mass like enhancements in 17 (20%) and solid nodules or mass enhancement 34 (39%). 3/87 (3.4%) cases upgraded on excision biopsy. The upgraded lesions included low grade invasive ductal carcinoma (6mm), invasive lobular carcinoma (4mm) and pleomorphic LCIS with focal low grade DCIS. 2 of the upgraded cases were BIRADS 6 and 1 was BIRADS 4a. LCIS extent and associated microcalcifications showed no correlation with upgrade.

Conclusions: With a good sample size and radiopathologic correlation, our study showed a 3.4%(95%CI, 1-10%) upgrade on follow up excision for core biopsy with isolated LN. Our study essentially highlights benign outcome for isolated ALH/LCIS on core biopsy and gives a valid reason for rethinking the current practice of surgical excision for these patients.

107 Variation in Assessment of ER and PR Expression of the Same Tumor Block with Repeated IHC Stainings by Computer Assisted Imaging Analysis and Manual Analysis

H Chen, J Wang, L McMahon, Q Yang, H Bu, DG Hicks, P Tang. University of Rochester Medical Center, Rochester, NY; RTI Health Solution, Research Triangle Park, NC; West China Hospital of Sichuan University, Chengdu, Sichuan, China.

Background: The accurate assessment of estrogen receptor (ER) and progesterone receptor (PR) in breast cancer significantly impacts the decision of adjuvant therapy. Multiple pre-analytic, analytic and post-analytic factors have been implicated in affecting the accuracy of ER and PR assessment, which may impact patient outcome. Here, we sought to investigate the affect of repeating immunohistochemical (IHC) stainings of the same tissue block on ER and PR interpretation, comparing manual readings to computer assisted image analysis.

Design: We identified 48 cases of breast cancer with reported negative, weak, or strong staining for ER and PR from our 2009 departmental file. One representative block from each case was selected for IHC analyses for ER and PR. The IHC stainings were first scored manually with both percentage (0-100%) and intensity as (0-3). Two more IHC stainings for ER and PR were performed one week apart. Automated computer analysis with percentage (0-100%) and intensity (0-255) for ER and PR was then conducted on 10 representative tumor areas selected by a pathologist for each case. Direct comparison among three automated readings for percentage and intensity, and comparison between one automated and manual reading for ER and PR were performed for these cases.

Results: We found that 1) there were significant difference in percentage and intensity of ER and PR readings among the three different IHC stainings; 2) between any two automated readings for percentage, there was one of the six groups showing significant difference for ER (0.0028), and none for PR; 3) between automated and manual readings for percentage, there was significant difference for PR (0.0468) but not for ER (0.6848); 4) among 3 groups of automated reading for intensity, 2/3 groups showed significant difference when compared two groups at a time for ER or PR. No disagreement between automated and manual assessment case using 1% cut off for positive ER and PR as recommended by 2010 ASCO/CAP guidelines.

Conclusions: Although significant difference are present ER and PR interpretation, there is no difference in classification of ER and PR as positive or negative regardless of the different repeats of IHC stainings or the methods of assessment (automated or manual).

108 Molecular Difference between Pure Ductal Carcinoma In Situ (DCIS) and the DCIS Component of Invasive Ductal Carcinoma

H Chen, J Wang, B Wei, J Da, DG Hicks, P Tang. University of Rochester Medical Center, Rochester, NY; RTI Health Solution, Research Triangle Park, NC.

Background: Ductal carcinoma in situ (DCIS) is considered to be a non-obligatory precursor for invasive ductal cancer (IDC) and in all likelihood represents a heterogeneous group of lesions, with varying potential for progression. The factors underlying the evolution from DCIS to IDC are poorly understood. Here, we sought to compare a panel of biomarker expression between pure DCIS and the DCIS component of IDC in order to better define key molecular distinguishing features between these two groups.

Design: We identified 140 cases of pure DCIS between 1997 and 2008 from our departmental file, along with 212 cases of DCIS with co-existing IDC. Tissue microarrays (TMAs) were constructed for these cases. Immunohistochemical (IHC) analyses were performed on these TMAs for ER, PR, HER2, Ki-67, EGFR, CK5/6, C35, IMP3, AR and p53. ER, PR and AR were recorded as Allred scores (3 and greater as positive); HER2 was scored as CAP 2007 guidelines (>30% of tumor cells with 3+ membrane staining as positive); Ki-67 was scored as positive with >15% of nuclear staining; EGFR was designated as positive if any tumor cells showed 1+ positive stain; any strong cytoplasmic stain was considered as positive for CK5/6, C35 and IMP3; and >10% strong cytoplasmic stain was considered as positive for p53.

Results: Among the cases we were able to obtain IHC data for above molecules, we compared their IHC expression patterns between pure DCIS and the DCIS of component with co-existing IDC. We found 1) there were significant differences in the expression patterns with Ki-67 (2% in DCIS vs. 11% in DCIS component), IMP3 (1% in DCIS vs. 8% in DCIS component) and p53 (57% in DCIS vs. 39% in DCIS component) between these two groups; 2) although no difference on the expression patterns (negative, borderline and positive) was found between these two groups, the rate of HER2 over-expression was higher in pure DCIS (15% vs. 9% in DCIS component of IDC); 3) no significant difference were noted with ER, PR, EGFR, CK5/6, C35 and AR between these two groups.

Conclusions: Our data suggests that molecules including Ki-67, IMP3 and p53 may play critical roles in the progression of DCIS to IDC of breast cancer. These finding will need further validation in an independent cohort of DCIS with data of clinical outcome.

109 Higher TRPS-1 Expression Independently Predicts Better Clinical Outcome in ER+ Breast Cancer

JQ Chen, L Xiao, Y Wu, J Litton, R Zhou, X Shen, AA Sahin, RL Katz, M Bondy, JL Murray, LG Radvanyi. UT MD Anderson Cancer Center, Houston; VA Baylor College of Medicine, Houston.

Background: The Trichorhinophalangeal Syndrome-gene (TRPS-1), a novel GATA transcription factor family member, is one of the most prevalent genes expressed in breast cancer based on microarray and immunohistochemistry (IHC) screening. Recent studies have found that TRPS-1 is an EMT inhibitor targeted by miR221/222 in breast cancer (BC). In this study, we developed a new quantitative IHC (qIHC) method to determine whether TRPS-1 may be a clinical prognostic marker in BC patients, especially in early stage ER+ patients receiving anti-hormone therapy alone.

Design: TRPS-1 expression was measured as a Quick Score (QS) derived from the Labeling Index (LI) and Mean Optical Density (MOD) after IHC and applied to 341 Stage I-III BC patients who did not receive preoperative chemotherapy. Nuclear staining and QS ≥ 4 for TRPS-1 of tumor cells was defined as high expression, while a QS < 4 was considered low expression. The association of TRPS-1 with E-cadherin was also assessed in 36 ER+ invasive ductal carcinoma samples. The relationship between TRPS-1 expression and overall survival (OS), disease-free survival (DFS), as well as tumor characteristics and other biomarkers (ER and GATA-3) were examined.

Results: TRPS-1 protein was found to be heterogeneously and widely expressed in the nuclei of ductal epithelial cells. Higher TRPS-1 expression was significantly associated with a number of clinical and pathological characteristics including clinical stage, nodal status, tumor size, Black's Nuclear Grade, ER status, HER2 status and tumor subtype. Univariate and multivariate Cox regression analysis found that high TRPS-1 expression (QS ≥ 4) significantly associated with improved OS and DFS. Moreover, in early stage (stage I/II) ER+ BC patients receiving anti-hormone therapy alone, higher TRPS-1 expression was significantly associated with prolonged OS and DFS compared to cases with lower TRPS-1 expression (QS < 4). In comparing TRPS-1 and ER expression and GATA-3, we found TRPS-1 out-weighted ER and GATA-3 in multivariate analysis as a parameter predicting improved OS and RFS.

Conclusions: The level of TRPS-1 expression can predict clinical outcome in BC patients independently, and may be even a more powerful biomarker than ER for clinical use. The results suggest that TRPS-1 can be used as a marker together with ER, PR and HER2/neu staining, especially to predict the efficiency of anti-hormone therapy. The level of TRPS-1 may be used as a guide to select ER+ BC patients who have lower TRPS-1 expression for more aggressive or alternative therapies to prevent relapse.

110 Long Non-Coding RNA and Polycomb Protein Expression Levels Are Increased in Metastatic Versus Primary Breast Carcinoma

KM Chisholm, R Li, Y Wan, H Chang, RB West. Stanford University School of Medicine, Stanford, CA.

Background: Tumor development involves the alteration of gene expression patterns due to epigenetic changes. Polycomb group (PcG) proteins work in multiprotein complexes called Polycomb Repressive Complexes (PRCs) that repress transcription of gene expression by modification of chromatin. EZH2, the enhancer of zeste homolog 2, is a PcG protein in the PRC2 complex. Long intervening non-coding RNA (lincRNAs) may be one of the regulators of PcG proteins. Experimental evidence suggests that in cancer, lincRNAs can influence Polycomb repressive complexes to re-target to an occupancy pattern resembling that of the embryonic state. *HOTAIR* lincRNA has been reported to be increased in primary tumors and metastases, and its expression level in primary tumors a predictor of eventual metastasis and death. The current project is undertaken to determine if *HOTAIR* lincRNA and EZH2 Polycomb protein have increased expression in matched primary and metastatic breast carcinomas.

Design: An RNA in situ hybridization probe of 400 to 500 nucleotides was created for *HOTAIR*. EZH2 expressed was evaluated by immunohistochemistry (BD Transduction Laboratories, clone 11). These two markers were examined on two breast cancer microarrays containing 283 primary breast carcinomas and 110 matched metastases. The

stains were scored by eye on a three-tiered scoring system, and the scores from matched primary and metastatic breast cancers were correlated. Statistics were performed using a two-tailed Fisher exact test and Chi-squared test.

Results: In matched primary and metastatic cancers, both *HOTAIR* and EZH2 had increased expression in the metastatic carcinomas. From primary to matched metastatic carcinoma, 93% of pairs had an increased or equivalent EZH2 expression, and 40% had an increased EZH2 expression, while 83% of pairs had an increased or equivalent *HOTAIR* expression, and 52% had an increased *HOTAIR* expression. In addition, EZH2 and *HOTAIR* expression levels were highly correlated ($p = < 0.0001$).

Conclusions: This is the first study to look at matched primary and metastatic breast cancers and correlate EZH2 protein and *HOTAIR* expressions in archival material. The data support increased expression of both the protein and the lincRNA in metastatic cancer, compared to primary carcinomas. This protein together with this lincRNA may be influencing chromatin remodeling and the expression of other proteins to increase cancer invasiveness.

111 Tumor-Associated Macrophages and Tumor-Infiltrating CD8+ Lymphocytes in Breast Cancer: Its Association with Epithelial-Mesenchymal Transition and Breast Cancer Stem Cell Phenotype

Y Choi, DI Kim, EJ Kim, SY Park. Seoul National University Hospital, Seoul, Republic of Korea; Seoul National University Bundang Hospital, Seongnam, Republic of Korea; Seoul National University College of Medicine, Seoul, Republic of Korea.

Background: Recent studies have shown that immune response to tumor can promote epithelial-mesenchymal transition (EMT) and generate cancer stem cells (CSC). Moreover, it has been associated with clinical outcome of breast cancer. In this study, we evaluated the association of tumor-associated macrophages (TAM) and tumor-infiltrating cytotoxic T lymphocytes (CTL) with clinicopathologic features of breast cancer including EMT, CSC phenotype and clinical outcome of the patients.

Design: CD68+ TAM and CD8+ CTL were assessed in tumor nests (intra-tumoral) and in stroma adjacent to tumor cell nests (peri-tumoral) by immunohistochemical staining of tissue microarrays from 170 invasive breast cancers. The expression of EMT-related (Vimentin, N-cadherin, E-cadherin) or CSC markers (CD44+/CD24-, ALDH1) was also assessed.

Results: Infiltration of intra-tumoral and peri-tumoral TAM was significantly correlated with high histologic grade, high proliferation index, vimentin expression. Moreover, peri-tumoral TAM was associated with ALDH1 and N-cadherin expression, and p53 overexpression. Presence of intra-tumoral and peri-tumoral CTL was associated with high histologic grade, basal-like subtype, vimentin expression and E-cadherin loss. Especially, intra-tumoral CTL was associated with presence of CD44+/CD24- cells in tumor. In survival analyses, the patients with high level of intra-tumoral TAM tended to have short disease-free survival.

Conclusions: Our study shows that infiltration of TAM and CTL is associated with EMT and CSC phenotype, and is correlated with poor prognostic factors of breast cancer, suggesting potential roles of immune response in the development of aggressive breast cancer.

112 A 2-Marker IHC Panel of Nestin and INPP4B for Detection of Basal-Like Breast Cancer Defined by Gene Expression

JR Choo, D Gao, G Chao, C Chow, S Aparicio, CM Perou, TO Nielsen. Genetic Pathology Evaluation Centre, Vancouver, Canada; University of British Columbia, Vancouver, Canada; University of North Carolina, NC.

Background: Basal-like breast cancer, originally defined by gene expression profiling, is an aggressive subtype unresponsive to available targeted therapies and characterized by poor prognosis. Surrogate immunohistochemical definitions for basal-like breast cancer rely on lack of ER, PR and HER2, and can be improved with additional markers such as cytokeratin 5 and EGFR. Many additional biomarkers have since been proposed, but rarely validated against a gene expression profile gold standard. We recently performed a large survey to assess the most sensitive and specific biomarkers, including nestin (a stem cell marker) and INPP4B (a negative regulator of phosphatidylinositol signaling). Building on this study, an optimized immunopanel for basal-like breast cancer was determined.

Design: Whenever possible, the scoring system used for each proposed biomarker was taken from the original literature associating that biomarker with basal-like breast cancer. Only cases with complete data were included in preliminary model building for development of an optimized immunopanel. A kappa statistic was used to assess the level of agreement between gold standard and surrogate immunopanel. The strength of agreement was interpreted for kappa values as follows: < 0.00 = poor, $0.00-0.20$ = slight, $0.21-0.40$ = fair, $0.41-0.60$ = moderate, $0.61-0.80$ = substantial and $0.81-1.00$ = almost perfect.

Results: INPP4B possessed the best combination of sensitivity (61%) and specificity (99%) using a 5% cutoff predefined in the literature. With an odds ratio of 108.4, it was the single best biomarker for basal-like breast cancer among those surveyed. The combination of negative INPP4B expression and/or positive nestin expression provided the most sensitive (83%) and specific (98%) panel for detection of basal-like breast cancer against a PAM50 gene expression profile gold standard ($\kappa = 0.83$).

Conclusions: Loss of INPP4B expression is the best single biomarker for basal-like breast carcinoma. The combination of negative INPP4B expression (at 5% cutoff) and/or positive nestin expression (at 1% cutoff) provides the most sensitive and specific 2-marker panel for detection of basal-like breast cancer. Validation on a large independent series is pending.

113 Incidence of an Anatomically Separate Carcinoma of the Breast in Patients Diagnosed with a Papillary Lesion on Breast Core Biopsy

M Chung, N Shapiro, T Koehnberg, S Fineberg. Montefiore Medical Center, Bronx, NY.

Background: The need for surgical excision in patients diagnosed with a papillary lesion on breast core biopsy is controversial. The concern is that one may miss an associated cancer at the same site which may not be evident on the core biopsy. In our practice, however, we further noted a high incidence of an anatomically separate breast carcinoma (BCa) in patients diagnosed with a papillary lesion on breast core biopsy. We report this incidence.

Design: The pathology database of The Medical Center was searched for all breast core biopsies from 2008 through 2010. All cases with a core biopsy diagnosis of a papillary lesion were included. In all cases other pathologic diagnosis were reviewed and if a diagnosis of BCa was also found it was then determined if it was anatomically separate from the papillary lesion, defined as within a different quadrant of the ipsilateral breast or occurring in the contralateral breast. We also recorded whether the BCa occurred prior to, concurrent with, or after the diagnosis of the papillary lesion. As a comparison group we recorded a similar number of cases with a BCa diagnosis (either invasive cancer or DCIS) on breast core biopsy during 2008 to 2010 to determine the incidence of an anatomically separate second cancer in this known high risk group.

Results: Between 2008 and 2010 there were 125 papillary lesions diagnosed on breast core biopsy. In 25 of these 125 cases there was an anatomically separate BCa for an incidence of 20%. Of note in 23 of these 25 cases the core biopsy showing a papillary lesion contained a papilloma and 2 showed denovo papillary cancer. The anatomically separate Bca was contralateral in 20 cases, ipsilateral in 4 cases and bilateral in one case. The cancer occurred prior to the papillary diagnosis in 11 cases, concurrently in 11 cases and afterward in 3 cases. In the control group of 125 patients with a breast core biopsy diagnosis of Bca over the same time period there were only 12 anatomically second separate breast cancers diagnosed for an incidence of 10%.

Conclusions: A diagnosis of a papillary lesion on breast core biopsy was associated with a 20% incidence of an anatomically separate breast cancer and the majority of these cancers were in the contralateral breast. Our results suggest that some patients with a papillary lesion on breast core biopsy may benefit from high risk imaging surveillance and clinical screening. Additional study is warranted to define this group.

114 A Subset of Malignant Phyllodes Tumors Harbors Rb/p16 Pathway Alterations

A Cimino-Mathews, JL Hicks, R Sharma, R Vang, PB Illei, A De Marzo, P Argani. Johns Hopkins Hospital, Baltimore, MD.

Background: Breast phyllodes tumors are rare fibroepithelial neoplasms with variable risk of aggressive local recurrence and distant metastasis. The molecular pathogenesis of phyllodes tumors is unclear. One study showed loss of chromosomes 13p14 (*Retinoblastoma (Rb)* locus) and 9p21 (*p16* locus) in malignant/borderline phyllodes; however, another showed increased Rb and p16 labeling by immunohistochemistry (IHC) in malignant phyllodes. Rb plays a role in cell cycle regulation, and loss of Rb in human cancers typically results in compensatory upregulation of p16, and vice versa. Here, we systematically study p16 and Rb expression in a series of benign (BP), low grade (LGP) and malignant phyllodes (MP) tumors in relation to proliferation.

Design: Tissue microarrays (TMAs) were constructed from paraffin tissue blocks of 34 phyllodes tumors including 10 BP, 10 LGP and 14 MP tumors (5 spots per tumor), and from 10 FA (2 spots per tumor). TMAs were labeled by IHC for p16, Rb and Ki67. Cytoplasmic p16 labeling was scored by percentage labeling (0-100%, diffuse defined as >95%) and labeling intensity [weak (W), moderate (M) or strong (S)]. Nuclear Rb labeling was scored by percentage labeling (0-100%, diffuse defined as >75%) and labeling intensity [W, M, S]. p16 and Rb labeling were repeated on whole slide sections of donor blocks from cases with absence of Rb labeling on the TMA.

Results: 29% (4/14) MP showed diffuse strong p16 expression with Rb loss in cytologically malignant cells (diffuse p16+/Rb-), while 21% (3/14) MP showed the reverse pattern of p16 loss with diffuse strong Rb expression (p16-/diffuse Rb+). In cases with Rb loss in the malignant stromal cells, there were abundant admixed vessels and nonatypical stromal cells (likely representing entrapped native stroma) which exhibited intact Rb labeling. Results were consistent between TMA and whole sections. No LGP, BP or FA showed the diffuse p16+/Rb- or p16-/diffuse Rb+ phenotypes. Average Ki67 proliferation indices were as follows: 15% (range <1-50%) in MP, 1.7% (range <1-10%) in LGP, 0.5% (range <5%) in BP, and 0% (range <1%) in FA. Ki67 index did not correlate with patterns of p16/Rb labeling.

Conclusions: Approximately 50% MP tumors display evidence of Rb/p16 pathway alterations. A subset of MP cases demonstrates loss of p16 with diffuse Rb labeling, likely reflecting p16 inactivation. Another subset of MP demonstrates diffuse p16 expression with loss of Rb labeling in the pleomorphic cells, suggesting Rb inactivation. These and other mechanisms likely contribute to the increased proliferation in MP relative to other fibroepithelial neoplasms.

115 ERCC1 Expression and Complete Pathologic Response to Platinum-Based Therapy for Patients with Triple Negative Breast Cancer

M Cioffi-Lavina, J Hurley, G Walker, JJ Hu, M Jorda, C Gomez-Fernandez. Jackson Memorial Hospital, Miami, FL; University of Miami School of Medicine, Miami, FL; Sylvester Comprehensive Cancer Center, Miami, FL.

Background: Platinum-based chemotherapy exerts its cytotoxic effects by forming intra-strand DNA adducts that inhibit replication. Excision Repair Cross Complementing group 1 protein (ERCC1) plays a critical, yet undesirable, role in repair of DNA damage induced by platinum. Absence of immunohistochemical expression of ERCC1 has been shown to be associated with response to platinum-based chemotherapy

regimens in non small cell lung carcinomas. Experimental data suggests that triple negative breast cancers (TNBC) may have increased sensitivity to platinum-based chemotherapy, particularly in BRCA1 mutation carriers, whose cancers cluster among the basal-like subtype, as defined by gene expression profiling. We investigated the immunohistochemical expression of ERCC1 in relation to response to neoadjuvant platinum-based chemotherapy in a cohort of patients with TNBC.

Design: We reviewed the diagnostic core biopsies of 80 TNBC patients treated with neoadjuvant docetaxel plus platinum-based salts at our institution between 1999 and 2007. Twenty-eight (35%) study patients had pathologic complete response (pCR), defined by the absence of invasive carcinoma in the breast and axilla. Immunohistochemistry for ERCC1 (ABCAM) was performed in all cases using the LSAB method. A nuclear immunohistochemical reaction in >1% of the tumor cells was scored as positive for ERCC1. Fisher's exact test was used to compare pCR rates by ERCC1 status.

Results: Of 80 TNBC, 55 (69.75%) were positive for ERCC1 by immunohistochemistry. Reactivity was present in 10 to 100% of the tumor cell nuclei. The remaining 25 (31.25%) carcinomas were definitively negative for ERCC1. A higher pCR rate was found among patients with ERCC1(-) tumors, 12/25 (48%), compared to 16/55 (29.1%) patients with ERCC1(+) tumors, but did not reach statistical significance $p=0.131$. A one-sided test for higher pCR rates among ERCC1(-) patients was marginally significant, $p=0.083$, Fisher's exact test.

Conclusions: Absence of immunohistochemical expression for ERCC1 was marginally predictive of higher pathologic complete response to platinum-based neoadjuvant chemotherapy for patients with TNBC. A larger study is needed to further elucidate the relationship between ERCC1 expression and response to platinum-based therapy for patients with TNBC.

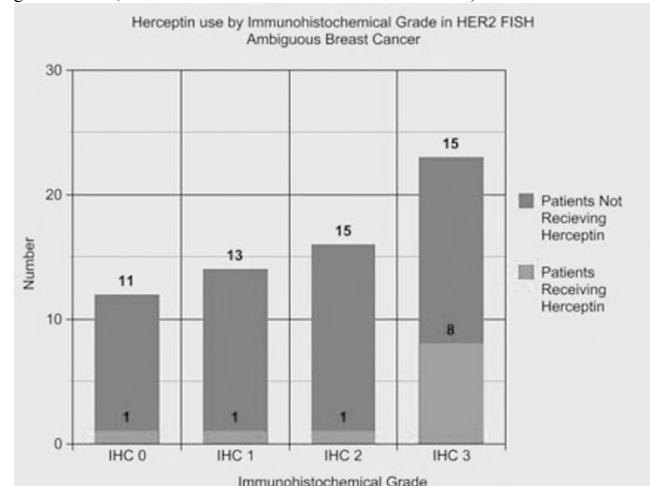
116 Clinicopathologic Characteristics of HER2 FISH Ambiguous Breast Cancer at a Single Institution

MR Clay, KC Jensen. Stanford Hospital and Clinics, Stanford, CA; Veterans Affairs, Palo Alto Health Care System, Palo Alto, CA.

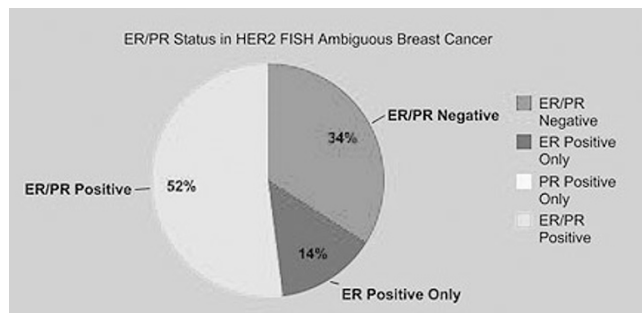
Background: The typical algorithm for HER2 testing is immunohistochemistry (IHC) followed by reflex HER2 fluorescence in situ hybridization (FISH) for HER2 IHC ambiguous (2+) cases. At our institution, HER2 FISH testing is initially performed as part of routine breast cancer testing, with HER2 FISH ambiguous (HER2:CEP17 ratio 1.8-2.2) cases reflexed to HER2 IHC. This provides a unique dataset for lesions that may not routinely undergo FISH testing. The clinicopathologic characteristics of HER2 FISH ambiguous cases are described.

Design: The electronic pathology database in our institution was searched for HER2 FISH ambiguous cases from 2007 to July 2011. All breast pathology reports were reviewed, and retrospective clinical charts were examined for details on treatment and outcome.

Results: Sixty-four cases from 59 patients (all female, age range 23-90, mean age 56) were reported as HER2 ambiguous during this period. Reflex HER2 IHC testing was performed on 55 cases, of which 25 were HER2 IHC negative (0-1+), 15 were HER2 IHC ambiguous (2+), and 15 were HER2 IHC positive (3+). Thirty-three cases had associated ductal carcinoma in situ. Of the HER2 FISH ambiguous patients with available clinical records, 42 were considered for anti-HER2 therapy (28 patients with FISH ratios < 2.0 and 14 patients with FISH ratios 2.0-2.2) and of these 11 pursued anti-HER2 treatment (8 with HER2 IHC 3+, 2 with HER2 IHC negative but FISH ratios greater than 2, and 1 with HER2 IHC 2+ and FISH ratio 1.91).



Conclusions: Reflex HER2 IHC testing after initial HER2 FISH testing provides definitive HER2 status information in a majority of cases (73%). However, a substantial percentage (27%) of HER2 FISH ambiguous cases are also HER2 IHC ambiguous, suggesting an intermediate HER2 biology. Most HER2 FISH ambiguous who received anti-HER2 therapy (91%) were either HER2 IHC 3+ or FISH ratio 2 or greater.



117 Inter-Observer Agreement among Pathologists for Semi-Quantitative Hormone Receptor Scoring in Breast Carcinoma

DA Cohen, DJ Dabbs, KL Cooper, M Amin, TE Jones, MW Jones, M Chivukula, GA Trucco, R Bhargava. Magee-Womens Hospital of University of Pittsburgh Medical Center (UPMC), Pittsburgh, PA; University of Pittsburgh Cancer Institute (UPCI) Biostatistics Facility, Pittsburgh, PA.

Background: Hormone receptor immunohistochemical (IHC) semi-quantitative score is more useful than mere positive or negative result in predicting benefit from hormonal therapies. The recently released ASCO/CAP guidelines recommend reporting of hormone receptor test results in a semi-quantitative manner. However, there is a dearth of studies evaluating inter-observer agreement for such semi-quantitative scoring methods. **Design:** 74 resected invasive breast cancer specimens (previously ER+ on core biopsy) were considered for this study. Hormone receptor testing was performed on 4 microns thick whole slide tissue sections using estrogen receptor (ER) clone SP1 (Ventana) and progesterone receptor clone 1E2 (Ventana). Hormone receptor immunohistochemical semi-quantitation was performed using the modified H-score. The score consists of the sum of the percent of tumor cells staining multiplied by an ordinal value corresponding to the intensity level (0=none, 1=weak, 2=moderate, and 3=strong). The score ranges from 0 (no staining in the tumor) to 300 (diffuse intense staining of the tumor). In accordance to ASCO/CAP guidelines, an H-score of ≥ 1 was considered a positive result for both ER and PR. Four Pathologists independently scored each slide and recorded the H-scores. Agreement between observers was analyzed via Fleiss kappa statistics on ER and PR categorical scores. Intraclass correlation coefficient (ICC) was used to estimate the inter-observer agreement for ER and PR H-scores on a continuous scale (0-300).

Results: There was 100% agreement for categorical ER results (kappa of 1) and 97% agreement (kappa of 0.823, $P < 0.001$) for categorical PR results. For quantitative H-scores on ER and PR, ICC-agreement (two-way random effects model measuring absolute agreement of values) and ICC-consistency (two-way random effects model measuring consistency of scores) are reported below.

	ICC (Agreement) Est (95% CI)	ICC (Consistent) Est (95% CI)
ER	0.85 (0.79, 0.90)	0.86 (0.80, 0.90)
PR	0.87 (0.82, 0.92)	0.89 (0.84, 0.92)

ER: estrogen receptor; PR: progesterone receptor; ICC: Intraclass Correlation Coefficient; CI: confidence intervals

Conclusions: There is excellent inter-observer agreement with respect to H-scores among pathologists. As the H-score method provides a wide dynamic range and a continuous measure of tumor hormone receptor content, we suggest universal adoption of this method for reporting hormone receptor test results.

118 Predictors of Local Recurrence (LR) in Patients with Ductal Carcinoma In Situ (DCIS) Treated by Breast Conserving Therapy (BCT): Value of the Memorial Sloan-Kettering (MSK) Nomogram

LC Collins, N Achacoso, Z Sharafali, R Haque, L Nekhlyudov, SW Fletcher, CP Quesenberry, LA Habel, SJ Schnitt. Beth Israel Deaconess Medical Center, Boston; Harvard Medical School, Boston; Kaiser Permanente, Northern CA, Oakland; Kaiser Permanente, Southern CA, Pasadena; Harvard Vanguard Medical Associates, Boston.

Background: Various patient, treatment and pathologic factors have been associated with an increased risk of LR following BCT for DCIS. However, the strength and importance of individual factors has varied and the extent to which combining factors may improve prediction of risk is undetermined. Our aim was to assess, in a large population-based cohort of DCIS patients treated with BCT and known outcome, the value of the recently published MSK nomogram which combines clinical and pathologic features to predict the risk of LR in patients with DCIS treated with BCT.

Design: We identified patients diagnosed with a first unilateral DCIS between 1990-2001 treated with BCT at 3 integrated health plans. Slides from the index DCIS of patients with recurrences (cases=190) and controls (N=305) were reviewed. Regression methods were used to estimate relative risks (RR) of LR associated with clinical and pathologic factors. The MSK DCIS nomogram was then applied to the study population to compare the nomogram-predicted and observed risks for LR at 5 yrs.

Results: Among the 495 patients in the case-control analysis, the only pathologic features associated with increased LR in univariate analysis were larger lesion size (RR=3.0 for ≥ 20 low power fields of DCIS; 95% CI 1.6-5.6) and involved (RR=2.9; 95% CI 1.6-5.3), or close (<1mm) (RR=2.4; 95% CI 1.6-3.8) margins. The risk estimates provided by the MSK nomogram showed approximately 90% correlation with the observed rates of LR and were stronger than those provided by evaluation of individual features.

RR of LR among women with DCIS in relation to MSK nomogram probability quartiles

MSK nomogram probability quartiles	5 yr Observed LR (%)	Nomogram Predicted RR	95% CI
Quartile 1 (2-<8)	4.8	1.0	Ref
Quartile 2 (8-<13)	8.5	1.8	1.0-3.4
Quartile 3 (13-<20)	20.9	5.2	2.6-10.3
Quartile 4 (20-53)	33.1	9.9	4.8-20.4

The associations between the nomogram-predicted and the observed LR rates were maintained when the analyses were restricted to patients treated with and without radiation therapy.

Conclusions: When applied to a population of patients with DCIS treated with BCT with known outcome, the MSK DCIS nomogram provided highly accurate prediction of the 5-year LR risk. This nomogram, therefore, may be a useful decision aid in selecting treatment for patients with DCIS.

119 Local Recurrence of Breast Cancer in Patients with DCIS Depending of the Margin Assessment

E Colon, J Carlson. Karolinska University Hospital, Stockholm, Sweden.

Background: Ductal carcinoma in situ is a clonal proliferation of cells growing within the basement membrane of the breast with not evidence of invasion. This study was designed to collect follow up data on breast cancer patients with DCIS with subsequently local recurrence or no depending of margin assessment.

Design: We aimed to assess the local recurrence of DCIS recently diagnosed as DCIS in our department (2009-2010, 149 cases) and to compare the results with those previously reported over a similar period of time (2006-2007, 138 cases) depending of the margin assessment as described in the Table 1. In addition sections were reviewed to assess the outcome of the different subtypes of DCIS in association with/without LCIS, FEA, CCC. Clinical follow up was obtained from our medical records. Data was statistically analyzed using Chi-square or Fisher's exact test.

Results:

Table 1		Table 1	
2006-2007	(% of total cases-138)	2009-2010	(% of total cases-149)
Characteristic		Characteristic	
Age (years)		Age (years)	
<45	16	<45	25
>45	84	>45	75
Mammographic size		Mammographic size	
0-10 mm	15	0-10 mm	22
11-25 mm	28	11-25 mm	45
>25	57	>25	33
Pathological type		Pathological type	
Low	9	Low	19
Intermediate	55	Intermediate	46
High	36	High	35
Pathological size		Pathological size	
0-10 mm	7	0-10 mm	15
11-25 mm	45	11-25 mm	47
>25 mm	48	>25 mm	38
Margins		Margins	
Positive or <1 mm	15	Positive or <1 mm	10
Negative with 5-10 mm	24	Negative with 5-10 mm	27
Negative with 11-25 mm	40	Negative with 11-25 mm	38
Negative >25 mm	21	Negative >25 mm	25
Local recurrence		Local recurrence	
Positive or <1 mm	39	Positive or <1 mm	41
Negative with 5-10 mm	25	Negative with 5-10 mm	24
Negative with 11-25 mm	28	Negative with 11-25 mm	23
Negative, >25 mm	8	Negative, >25 mm	2
Associated lesions	25	Associated lesions	39

Clinical and pathologic characteristics of evaluated cases (based on initial histological reports).

Conclusions: We conclude that the assessment of margins and the early radiographic detection improved the prediction of the amount of residual tumor. A marginal distance > 25 mm showed small number of local recurrences. In addition, population-based mammography screening with technical improvements has resulted in increased detection of lesions <10 mm.

120 NY-BR-1 Protein Expression in Metastatic Breast Carcinoma

AL Cota, Y Wu, L Haiping, M Sharimini, S Krishnamurthy. University of Texas MD Anderson Cancer Center, Houston, TX; Thermo Fisher Scientific, Fremont, CA.

Background: NY-BR-1 is a mammary differentiation antigen that is expressed in normal and neoplastic breast tissues. In addition to its role as a breast immunomarker for identifying the origin of primary and metastatic tumors, it is a potential target for cancer immunotherapy. The stability of NY-BR-1 expression in metastatic breast cancer and influence of chemotherapy on its expression are not known. Our primary objective was to evaluate the expression of NY-BR-1 in metastatic breast carcinomas from chemotherapy-naïve (CN) and chemotherapy-treated (CT) patients.

Design: We studied 150 axillary lymph nodes containing metastatic breast carcinoma obtained from 67 (45%) CN patients and 83 (55%) CT patients. Immunostaining was performed on formalin-fixed, paraffin-embedded tissue sections using a primary antibody (Thermo Fisher Scientific, CA) against NY-BR-1 with antigen retrieval (EDTA buffer). Cytoplasmic staining in tumor cells was scored semiquantitatively for proportion (0-100% of cells) and intensity (1-3) using the H score method (0-300). An H score of more than 10 was regarded as positive. The influences of chemotherapy and primary tumor positivity for ER/PR and HER2 on NY-BR-1 protein expression were determined using the chi-square test.

Results: Immunopositivity for NY-BR-1 was observed in 83% (125) of the specimens, with a mean and median H score of 147 and 160. NY-BR-1 was noted in 97% (65/67) of CN specimens but only in 72% (60/183) of CT specimens; the difference was

statistically significant ($p=0.0001$). The mean and median H scores were 498 and 200 in the CN group and 105 and 80 in the CT group. NY-BR-1 was noted in 98% (54/55) of metastases from ER/PR positive tumors in the CN group and 75% (48/64) of metastases from ER/PR positive tumors in the CT group. Expression of NY-BR-1 in metastases correlated significantly with ER/PR positivity of the primary breast carcinoma only in the CN group ($P=0.03$). There was no association between expression of NY-BR-1 in metastases and HER2 positivity of the primary tumor.

Conclusions: 1) NY-BR-1 was positive in 83% of metastatic breast carcinomas 2) Immunopositivity for NY-BR-1 was significantly higher in CN than in CT specimens of metastatic breast carcinoma. 3) Expression of NY-BR-1 correlated with positive ER/PR status only in CN patients. 4) Our findings suggest that NY-BR-1 may be useful as a marker of breast origin for metastatic tumors and as a target for immunotherapy in patients with metastatic breast carcinoma.

121 Pathologic Upgrade (PU) Rates on Subsequent Excisional Biopsy (EXBX) When Lobular Carcinoma In Situ (LCIS) Is Found in a Needle Core Biopsy (NCB) with Emphasis on Radiologic Correlation

TM D'Alfonso, K Wang, Y-L Chiu, SJ Shin. Weill Cornell Medical College, New York, NY; Cornell University, Ithaca, NY.

Background: Management of lobular carcinoma in situ (LCIS) on NCB is uncertain as studies report a wide range of PU (3-35%) in the EXBX. This range can be attributed to the design of individual studies [pre-selection bias, radiologic correlation, and characteristics of LCIS [classical vs. non-classical; nuclear grade; extent; calcifications (calcs), if applicable]. We set out to determine the PU rate when LCIS is found in NCB at our institution.

Design: NCB samples containing LCIS as the most significant lesion in patients (pts) who underwent subsequent EXBX were identified (2001-2011). Microscopic features including architecture (florid vs. non-florid vs. both), nuclear grade, percentage of cores involved by LCIS, concurrent columnar cell lesion (CCL), and the presence/absence of calcs within LCIS were recorded. The most significant lesion was recorded from each corresponding EXBX. PU was defined as the presence of invasive carcinoma, ductal carcinoma in situ (DCIS), and pleomorphic LCIS (in cases where only classical LCIS was present in NCB) in the EXBX.

Results: 62 pts with LCIS in NCB who underwent EXBX were identified. Analyzed as a single group, PU was 11% (7/62). The percentage of cores involved by LCIS was significantly associated with PU ($p=0.02$). Characteristics present in the NCB such as architectural type of LCIS, nuclear grade, presence of CCL, or presence of calcs within LCIS did not correlate with PU. The results were re-analyzed with radiologic correlation. Of 62 cases, 51 (82%) were targeted for calcs, where 11 (22%) had calcs only in LCIS. Of these 11 cases, 3 (27%) had a PU on EXBX (1-microinvasive carcinoma; 2-DCIS). In 26 cases (51%), targeted calcs were found in both LCIS and benign lesions; of these, 3 (12%) had a PU on EXBX (1-invasive ductal carcinoma, 1-invasive lobular carcinoma, 1-pleomorphic LCIS). Cases of purely incidental LCIS (24/62; 39%) showed a PU of 4% (1/24) (1-DCIS).

Conclusions: PU in EXBX is significant (27%) if the targeted lesion is calcs which are exclusively associated with LCIS. If targeted calcs are found in both a benign lesion as well as LCIS, PU in EXBX remains significant (12%). However, for purely incidental LCIS found in NCB, PU is much lower (4%) and thus, foregoing EXBX may be reasonable in these pts. Our study underscores the importance of radiologic correlation when determining the PU in EXBX for pts with LCIS on NCB.

122 MYB-NFIB Gene Fusion Is Present in Mammary Adenoid Cystic Carcinoma (ACC) and Cylindroma, Two Morphologically Similar Entities

TM D'Alfonso, J Padilla, SJ Shin. Weill Cornell Medical College, New York, NY.

Background: Mammary ACC is a rare type of breast carcinoma which despite having a triple-negative and basal-like phenotype, has a favorable prognosis. Salivary gland ACCs are characterized by a fusion gene involving MYB and NFIB, resulting from a t(6;9)(q22-23;p23-24) translocation. This translocation results in the overexpression of MYB, and activation of oncogenic genes. This genomic alteration has recently been detected in 6 cases of mammary ACC. In addition, this translocation has been identified in dermal cylindromas. Primary mammary cylindroma, although rare, morphologically resembles ACC, but behaves in a benign fashion. In this study, we aimed to determine the frequency of MYB-NFIB fusion in a large series of mammary ACCs, as well as confirm the presence of this fusion in dermal cylindromas, which we used as a surrogate for mammary cylindroma.

Design: 31 cases of mammary ACC and 7 cases of dermal cylindroma were identified. Slides were reviewed and the diagnoses were confirmed. Formalin-fixed, paraffin-embedded tissue was available for each case. All tumors were screened by RT-PCR for the most common MYB-NFIB fusions, including MYB exon 14 linked to NFIB exon 8c, exon 9, or exon 8a, as well as additional fusion transcript variants which have previously been described.

Results: MYB-NFIB fusion transcript(s) were detected in 21 of 31 (68%) cases of mammary ACC and 5 of 7 dermal cylindromas. The transcript involving MYB exon 14 linked to NFIB exon 8c was present in 19 cases of mammary ACC and all 5 cases of cylindroma. In 6 cases of mammary ACC, additional MYB-NFIB fusion transcripts were detected, whereas in all 5 dermal cylindromas, one fusion transcript was present. There was no correlation between MYB-NFIB fusion status and specific morphologic features of mammary ACC such as nuclear grade, solid pattern, or frequency of mitotic figures.

Conclusions: MYB-NFIB gene fusion is present in the majority of mammary ACC and dermal cylindromas, providing evidence that these morphologically similar tumors also share common molecular features, despite behaving different clinically. The overexpression of MYB protein may prove to be a therapeutic target in ACC, and immunohistochemical detection of MYB may serve as a useful diagnostic marker in distinguishing mammary ACC from other breast lesions.

123 Utility of Prostate-Specific Membrane Antigen (PSMA) Expression by Vascular Endothelial Cells in the Differential Diagnosis of Papillary Lesions of the Breast

TM D'Alfonso, BD Robinson. Weill Cornell Medical College, New York, NY.

Background: The classification of papillary lesions of the breast can be challenging, even with the use of myoepithelial markers, as some papillary carcinomas may show patchy positivity for myoepithelial cells while papillomas may focally lack staining. A definitive diagnosis of papillary carcinoma in needle core biopsy (NCB) can allow for preoperative planning of a sentinel lymph node biopsy and wider surgical margins, thus potentially sparing patients a second surgical procedure. Neovascular endothelium in a variety of malignancies has been documented to express PSMA protein by immunohistochemistry (IHC). In this study, we set out to determine whether neovasculature expression of PSMA may be useful in the classification of papillary lesions of the breast, with particular focus on atypical papillary lesions in NCB samples. **Design:** 50 papillary lesions of the breast consisting of 17 papillomas, 17 papillary carcinomas, and 16 tumors classified as atypical papillary lesions were identified. Cases included 20 NCB, 26 excisional biopsies, and 4 mastectomies. IHC staining with PSMA was performed on representative formalin-fixed paraffin-embedded tissue sections of each case. Lesional vasculature was examined for the extent and intensity of PSMA staining. Papillary lesions with $\geq 5\%$ of vessels staining or with 2-3+ intensity were considered positive for PSMA expression.

Results: Positive PSMA staining was seen in 5 of 19 (26%) papillomas, 5 of 10 (50%) atypical papillary lesions, and 14 of 21 (67%) papillary carcinomas ($p=0.006$). 12 cases were classified as atypical on NCB. Upon excision, 2 of these cases were classified as papilloma, 6 remained atypical, and 4 were diagnosed as papillary carcinoma. Neovasculature in 0 of 2 papillomas, 3 of 6 atypical papillary lesions, and 4 of 4 papillary carcinomas stained positive with PSMA on the NCB specimens. If atypical and malignant cases are grouped together, 0 of 2 benign cases stained with PSMA, whereas 7 of 10 atypical/malignant cases stained positive (specificity = 100%, sensitivity = 70%).

Conclusions: PSMA expression in neovasculature of papillary breast tumors is more frequently seen in atypical and malignant lesions compared to papillomas. Our findings suggest that PSMA may be a useful adjunct in classifying papillary breast lesions, particularly in those that are atypical on NCB. Investigation of PSMA expression in a larger series of such cases is ongoing.

124 Radial Scar at Image-Guided Needle Biopsy: Is Follow-Up Excision Always Necessary?

C D'Arcy, L Liberman, T Nehhozina, E Brogi, AD Corben. Memorial Sloan Kettering Cancer Center, New York, NY.

Background: The need to excise breast lesions yielding radial scar (RS) at percutaneous image-guided core biopsy (CNB) remains controversial. This study was performed to determine the rate of cancer at surgical excision (EXC) in lesions yielding RS at CNB. **Design:** With IRB approval, we performed a retrospective review of CNBs with a benign diagnosis obtained at our center from 1996 to 2011. We identified 55 cases in which CNB yielded a diagnosis of RS with no other associated high risk lesion (ie, ductal or lobular atypia). Biopsy guidance was ultrasound in 27 cases, stereotactic in 20, and MRI in 8. Biopsy device was 14 gauge (G) automated needle in 25 cases, 11G vacuum-assisted probe in 20, 9G vacuum assisted probe in 7 and other in 3. Imaging and pathology findings were reviewed. The RS was considered incidental if (a) target lesion was calcification (Ca2+) and RS contained $\leq 10\%$ of the Ca2+ or (b) target lesion was mass/architectural distortion (AD)/MRI enhancement, RS was $\leq 1/3$ of the target image size and another benign lesion accounted for the imaging target. The 95% confidence intervals (CI) were calculated using Geigy scientific tables.

Results: The 55 CNBs with RS were in 56 women, median age 51 (range (R) 30-78) years. Imaging target was mass (18), Ca2+ (17), AD (9), MRI enhancement (8) and mass with Ca2+ (3). Median imaging target size was 0.8 (R 0.3-5.3) cm. RS was the imaging target in 37 (67%) and incidental in 18 (33%). Surgical excision of 52/55 (95%) lesions was performed at a median of 1 (range 0.1-78) months. Cancer was found in 4/52 (8%; 95% CI 2-19%) lesions, including 3 ductal carcinoma in situ (DCIS), and one multifocal invasive ductal carcinoma (largest focus 0.4 cm). Cancer was found at EXC in 3/16 (19%; 95% CI 4-46%) lesions evident as Ca2+, 1/3 (33%; 95% CI 1-91%) masses with Ca2+, 0/17 (0%; 95% CI 0-20%) masses, 0/9 (0%; 95% CI 0-34%) AD, and 0/7 (0%; 95% CI 0-41%) MRI enhancement lesions. Upgrade to carcinoma occurred in 4/37 (11%; 95% CI 3-25%) target vs 0/15 (0%; 95% CI 0-22%) incidental RS ($p=0.3$). Radiologic follow up of the 3 unexcised RS showed stability at a median of 57 (R 25-149) months.

Conclusions: Among lesions yielding RS as the highest risk lesion at CNB, surgery yielded cancer in 4/52 (8%; 95%CI 2-19%). Most cancers were DCIS and occurred in lesions evident as Ca2+. Our data support surgical excision of lesions yielding RS as the highest risk lesion at percutaneous image-guided needle biopsy.

125 Molecular Difference between Pure Invasive Ductal Carcinoma (IDC) and the IDC Components of the Tumors with Co-Existing Ductal Carcinoma In Situ

J Da, J Wang, H Chen, B Wei, DG Hicks, P Tang. University of Rochester Medical Center, Rochester, NY; RTI Health Solution, Research Triangle Park, NC.

Background: Although invasive ductal carcinoma (IDC) is frequently associated with co-existing ductal carcinoma in situ (DCIS), we often observed IDC presence without a DCIS component. Are these "pure" IDC molecularly similar to the IDC component with co-existing DCIS? Here we sought to compare a panel of biomarker expression to investigate if there are distinguishing molecular differences between these two groups. **Design:** We identified 118 cases of pure IDC between 1997 and 2008 from our departmental file; along with 380 IDC with co-existing DCIS. Tissue microarrays

(TMAs) were constructed for each group. Immunohistochemical (IHC) analyses were performed on these TMAs for ER, PR, HER2, Ki-67, EGFR, CK5/6, C35, IMP3, AR and p53. ER, PR and AR were recorded as Allred scores (3 and greater as positive); HER2 was scored as CAP 2007 guidelines (>30% of tumor cells with 3+ membrane staining as positive); Ki-67 was scored as positive with >15% of nuclear staining; EGFR was designated as positive if any tumor cells showed 1+ positive stain; a strong cytoplasmic stain was considered as positive for CK5/6, C35 and IMP3; and >10% strong cytoplasmic stain was considered as positive for p53.

Results: Among the cases we were able to obtain IHC data for above molecules; we compared their IHC expression patterns between pure IDC and the IDC component with co-existing IDC. We found that 1) the only molecule with significant different expression pattern between these two groups was CK5/6 (22% in pure IDC vs. 10% in IDC component, $p=0.0019$), which might due to the higher rate of triple tumors (16.1% vs. 9.7% in IDC component) in pure IDC group; 2) although no significant difference was noted, there were trend of expression difference with HER2 over-expression (2% in pure IDC and 7% in IDC component, $P=0.0757$); Ki-67 (25% in pure IDC vs. 16% in IDC component, $p=0.069$); C35 (45% in pure IDC vs. 56% in IDC component, $p=0.0752$) and p53 (55% in IDC vs. 66% in IDC component, $p=0.0747$); 3) no significant difference were noted with ER, PR, EGFR, IMP3 and AR between these two groups.

Conclusions: "Pure" IDC and the IDC component with co-existing DCIS share largely similar molecular alteration. Further studies are needed to investigate the molecular, biological and clinical difference between the two groups of the tumors.

126 Expression of CK14, CK8/18 and IMP3 in BRCA-Related Invasive Breast Carcinomas

F Dadmanesh, SK Mohanty, O Gordon, S Bose. Cedars-Sinai Medical Center, Los Angeles, CA.

Background: Certain immunohistochemical markers are shown to be useful in predicting BRCA mutation status in invasive breast carcinomas (IBC). Our study aims to evaluate expression of CK8/18 (luminal), CK14 (basal), and IMP3 (marker of aggressiveness and progression) to predict BRCA mutation status in IBC.

Design: Of 105 patients with BRCA germline mutation who underwent mastectomy, 30 IBC cases were identified. 73% (n=22) were BRCA1, 24% (n=7) BRCA2 and 3% (n=1) with dual BRCA1/BRCA2 mutation. All cases were invasive ductal carcinoma (IDC), except for one BRCA1 tumor with invasive lobular carcinoma in the contralateral breast. Our control group included 27 sporadic IBC. Immunostaining for CK14, CK8/18 and IMP3 were performed in all cases. Staining results were recorded in semiquantitative fashion as strong and diffuse cytoplasmic (CK14 and CK8/18) and/or membranous (IMP3) staining. Statistical analyses were performed using logistic regression and Fisher's exact test.

Results: Of BRCA1 carcinomas, 2 were Modified Bloom-Richardson grade I, 5 grade II and 15 grade III. Of BRCA2 carcinomas, 2 were grade II and 5 grade III. The dual BRCA1/BRCA2 carcinoma was grade II. Interestingly, 54% (n=12) of BRCA1 carcinomas had luminal A, 5% (n=1) luminal B, and 41% (n=9) basal-like phenotype. Of the BRCA2 carcinomas, 71% (n=5) had luminal A and 29% (n=2) basal-like phenotype. The dual BRCA1/BRCA2 carcinoma had luminal A phenotype. In the control group, 11% (n=3) were grade I, 48% (n=13) grade II, and 41% (n=11) grade III. 44% (n=12) of sporadic IBC had luminal A, 19% (n=5) luminal B, 4% (n=1) HER-2/neu, and 33% (n=9) basal-like phenotype. The IHC results are summarized in Table 1. CK8/18 expression in sporadic IBC was significantly higher than the BRCA carcinomas (Fisher's exact test, $p=0.015$). No significant differences were observed between the study and control group for IMP3 and/or CK14.

Table 1

IBC	IMP3 positive	CK14 positive	CK8/18 positive
BRCA1 (n=22)	7 (32%)	8 (36%)	15 (68%)
BRCA2 (n=7)	1 (14%)	1 (14%)	6 (86%)
BRCA1/BRCA2 (n=1)	0 (0%)	1 (100%)	1 (100%)
Sporadic (n=27)	4 (15%)	5 (19%)	27 (100%)

Conclusions: Our cohort included IBC with various grade and molecular subtypes. 59% of our BRCA1 carcinomas lacked basal-like phenotype in contrast to previously published data. When comparing BRCA carcinomas to sporadic IBC, regardless of mutation type, grade or molecular subtype, we observed that the absence of CK8/18 expression may predict BRCA mutation status. However, IMP3 and CK14 expression did not correlate with BRCA carrier status.

127 Concordance of Tumor Grade, ER and Her2+ER- Status with Gene-Expression-Based Profile Studies: Boosted Classification

LW Dalton. South Austin Hospital, Austin, TX.

Background: Development of sophisticated data mining algorithms has paralleled the advancements of molecular methodologies, although in the medical community the latter garners most of the attention. Data mining can discover patterns of variable association not obvious by traditional statistical measures. We wished to study if this might be the case in a widely referenced patient data set (Concordance of Gene-Expression-Based Predictors for Breast Cancer. NEJM 2006 355:560-9). In particular we wished to examine boosting classification (BC) which is a well known algorithm in the data mining community, but not in pathology.

Design: The data on each of 291 individual patients was obtained from supplementary online material of the NEJM paper. The patient population was of a younger group with age range 26-53 and median 45. Tumor grade (TG), ER status, and Her2+/ER-status(HR), were set as predictor variables with death of disease (DOD) as the target variable. Via BC (Statistica Data Miner, StatSoft, Tulsa,OK), these three predictors were combined into a binary "boosted grade" (BG) of high and low risk. BG was then compared with high vs low risk recurrence score (RS), activated or quiescent wound response profile (WR), and good vs poor seventy gene profile (SG).

Results: Boosted grade was concordant with the gene assays to include the subset of node neg. tumors. The NEJM paper stressed Cramer's V (V) statistic for comparing predictors in 2 way tables with >.36 regarded as substantial agreement and >.5 as strong. Thus, using R statistical project software V calculated for predictor pairs as: BG/RS .49; BG/SG .52; BG/WR .22; RS/SG .58; RS/WR .43; SG/WR .37-- all pairs had chi. sq. with $p < .05$. V of predictors paired with DOD showed: BG/DOD .38, SG/DOD .37, RS/DOD .32; WR/DOD .24. Further comparison of predictors with DOD showed likelihood ratios and diagnostic odds ratios respectively of BG/DOD 2.3 & 6.5; RS/DOD 1.6 & 7.6; SG/DOD 9.5 & 1.8; WR/DOD 1.3 & 5.8. All predictors showed $p < .05$ via chi.sq. and Pearson.

Conclusions: According to this data set of younger patients, gene assays have yet to be proven superior to TG, ER, HR when these latter variables have been "boosted." TG, ER, and HR are required on CAP tumor checklists-- the addition of gene profiling studies entails considerable added cost. It may very well be the math is more important than the molecules. And, it may be that a novel data mining algorithm can add the same or more value as can a novel tumor marker in stratifying patient risk. Study of a BG with other data sets is recommended.

128 Analysis of HER2 External Domain Epitopes in Breast and Gastric Cancers Expressing p95^{HER2}

L Daniele, D Recupero, G Viale, M Risio, AP Dei Tos, C Marchio, I Castellano, A Sapino. University of Turin, Turin, Italy; European Institute of Oncology, Milan, Italy; Institute for Cancer Research and Treatment (IRCC), Candiolo, Turin, Italy; General Hospital of Treviso, Treviso, Italy.

Background: A subgroup of HER2 overexpressing breast tumors coexpresses p95^{HER2}, a truncated HER2 receptor that retains a highly functional kinase domain but lacks the extracellular domain (ECD) and results in intrinsic trastuzumab resistance. In formalin-fixed paraffin-embedded tissues the expression of p95^{HER2} is supposed to reduce the expression of the ECD as detected by immunohistochemistry (IHC). Here we want to compare p95^{HER2} expression by western blot (WB) with HER2 expression by IHC (both intracellular (ICD) and trastuzumab-binding ECD).

Design: p95^{HER2} expression was evaluated by WB in a series of 99 breast carcinomas and 23 gastric cancers. The HER2 positive cell line BT474 was treated with pervanadate (a compound known to induce shedding of the HER2 ECD) and used as positive control for p95^{HER2} expression. p185^{HER2} was considered overexpressed (++) if the WB band was greater than or equal to p185^{HER2} level in BT474 cells. Lower levels of p185^{HER2} were classified as p185+. Specimens were scored as positive for p95^{HER2} (p95^{HER2}+) if a clear band was present at the same molecular weight of the p95 pervanadate-induced band in BT474 cell extracts.

IHC was performed using antibodies against both the ICD (polyclonal antibody A0485 by Dako and CB11 by Novocastra) and the ECD (TAB 250 by Zymed and BioHER, biotinylated trastuzumab, in-house created) of HER2. IHC was analyzed using an automated scanning system (Aperio ScanScope XT).

Results: The number of cases showing HER2 overexpression (score 3+) was higher in the p185+/+ p95^{HER2}+ cohort than in the p185+/+ p95^{HER2}- series, using both the anti-ICD and the anti-ECD antibodies. Automated analysis of IHC stained slides confirmed a significantly higher percentage of 3+ scored cells in p95^{HER2}+ cases as compared to the p95^{HER2}- cases. Conversely, the percentage of 2+ scored cells was higher in p95^{HER2}- cases. The percentage of cells scored 1+ did not significantly change between the two groups.

Conclusions: The presence of p95^{HER2} seems not to compromise trastuzumab binding, suggesting p95^{HER2} expression *per se* defines an aggressive subtype of HER2-positive cancers with distinct biological and clinical features resistant to trastuzumab. This is in contradiction with the assumption that the expression of p95^{HER2} or of other HER2 truncated forms could reduce the expression of the ECD which contains the trastuzumab-binding site.

129 Molecular Phenotype of Pregnancy Associated Breast Cancers (PABC) in a Large Cohort of Young Women

S Demski, S Gelber, J Marotti, K Cole, S Kerekoglow, K Ruddy, E Brachtel, L Schapira, S Come, V Borges, P Schedin, E Warner, E Winer, A Partridge, L Collins. Beth Israel Deaconess Medical Center, Boston; Dana Farber Cancer Institute, Boston; Dartmouth-Hitchcock Medical Center, Lebanon; Massachusetts General Hospital, Boston; University of Colorado Cancer Center, Denver; Sunnybrook Odette Cancer Centre, Toronto, Canada.

Background: The increase in breast cancer risk during pregnancy and post-partum is well known; however the molecular phenotype of PABCs has not been well studied. A genomic signature specific to the pregnant breast, which remains present postmenopausally, has been identified. Given this, we investigated whether the time interval since pregnancy affects the phenotype of breast cancers in parous vs. nulliparous young women.

Design: We examined molecular phenotype, determined by histologic grade on central review and biomarker status by report, in relation to time since pregnancy in a prospective study (n=359) of young women (≤40yrs) with breast cancer. Parity was ascertained from study questionnaires. Using tumor grade and biomarker expression, cancers were categorized as luminal A or B, HER2-type and triple negative (TN).

Results: Overall, 67% of cancers were ER+ and 29% were HER2+. There were no differences in the distribution of molecular phenotype according to time interval since pregnancy.

Distribution of molecular phenotype by interval between last pregnancy and diagnosis

Molecular Phenotype	Nulliparous N=132 (37%)	≤2 years N=54 (15%)	>2-5 years N=74 (21%)	>5 years N=99 (28%)	Total patients N=359
Luminal A (ER/PR+, HER2-, grade 1 or 2)	54 (41)	17 (31)	18 (24)	34 (34)	123 (34)
Luminal B (ER/PR+, HER2+ or ER/PR+, HER2-, grade 3)	45 (34)	19 (35)	26 (35)	34 (34)	124 (35)
HER2 type (ER-, PR-, HER2+)	9 (7)	6 (11)	13 (18)	9 (9)	37 (10)
Triple negative (ER, PR, HER2-)	24 (18)	12 (22)	17 (23)	22 (22)	75 (21)

However, nulliparous young women were more likely to develop luminal A cancers compared to parous women (41% vs. 30%; unadjusted chi square $p=0.04$) and appeared less likely to develop HER2-type and TN cancers (7% vs. 12%, $p=0.10$; 18% vs. 22%, $p=0.34$).

Conclusions: The distribution of breast cancer molecular phenotype is similar among parous young women irrespective of time interval since parturition. Nulliparous young women appear more likely to develop luminal A cancers. Whether the difference in molecular phenotypes of PABCs vs. cancers in nulliparous women is due to genomic alterations in the parous breast remains unknown. Effects of a prior pregnancy appear consistent across a 5-year period.

130 Routine Excision Is Necessary for Lobular Neoplasia Detected on Breast Core Needle Biopsy: Experience from a Large Women's Health Center

MM Desouki, AV Florea, K Mohammed, X Li, D Dabbs, C Zhao. UPMC, Pittsburgh, PA. **Background:** Lobular neoplasia (LN) is regarded as a risk indicator for the development of breast carcinoma. The significance of these lesions in core biopsy with respect to the need for surgical re-excision is controversial. The specific aim of this study was to ascertain pathologic findings of surgical follow-up excision (FUE) on patients who had LN on core biopsy.

Design: Core biopsies of breast from 2006-2011 with a diagnosis of LN with or without ADH, with no h/o invasive carcinoma (IC) or DCIS were studied. Cases were divided into: group 1 (pure LN) and group 2 (LN+ADH). Each group was further sub-divided into ALH or LCIS. Cases were considered to be upstaged if FUE showed IC or DCIS. Radiologic images, BIRADS and time between biopsy and FUE were recorded from the data files.

Results: 807 cases of LN were identified out of 20260 breast core biopsies (4%). 240 cases were excluded due to history or synchronous IC or DCIS (29.7%). Among the remaining 567 cases, 466 (82.2%) with FUE were included in the study. Patients were divided into groups as follow: ALH (235; 50%), LCIS (125; 27%), ALH+ADH (80; 17%) and LCIS+ADH (26; 6%). LN was confirmed by E-cad/P120 dual stain (263/466; 56.4%) or E-cad (70; 15%). The radiological abnormalities were calcification (78.5%), mass (14.2%) or other in 7.3%. The BI-RADS for group 1 were: score 4 in 256/260 (98.5% only 1 case score 5), and scores 3&5 in 4 cases (1.5%). For group 2, the BIRADS were: 4 in 78/80 (97.5%) and score 3 in 2 cases (2.5%) with no significant difference in relation to upstaging. The time interval between the core biopsy and FUE range from 0.3-7 month (mean 1.4) with significant difference in relation to upstaging in group 2. 28/360 (7.8%) and 17/106 (16.0%) of group 1 and group 2 cases upstaged to IC or DCIS (Table 1).

Table (1) Upstaging of LN on surgical follow-up excision

	ALH (%)	LCIS (%)	ALH+ADH (%)	LCIS+ADH (%)	Total (%)
IC	5 (2.1)	8 (6.4)	6 (7.5)	5 (19.2)	24 (5.2)
DCIS	8 (3.4)	7 (5.6)	3 (3.8)	3 (11.5)	21 (4.5)
ADH	47 (20)	25 (20)	40 (50)	7 (26.9)	119 (25.5)
Not upstaged	175 (74.5)	85 (68)	31 (38.7)	11 (42.4)	302 (64.8)
Total	235	125	80	26	466

Chi square test, $P=0.0001$

Conclusions: 1. This is the largest study on patients with diagnosis of LN on core biopsy and FUE.

2. LN with or without ADH is a definite risk factor for upstaging to IC and/or DCIS.

3. The risk of upstaging on FUE for LCIS is more than that of ALH (15.2% vs. 7.0%) ($p=0.0001$).

4. Our data indicate that excision of the biopsy site is prudent for all patients with LN on core biopsy due to the significant percentage of cases which found to be upgraded to IC or DCIS.

131 Claudin-Low Breast Cancer; a Molecular Subtype Associated with Poor Prognosis

K Dias, S Parpia, G Pond, MN Levine, T Whelan, AL Bane. McMaster University, Hamilton, ON, Canada; McMaster University, Hamilton, ON, Canada.

Background: Molecular profiling of human breast cancers has defined 5 molecular subtypes; luminal A, luminal B, HER2 over-expressing, basal-like and claudin-low. The claudin-low subtype was identified in 2007 and is characterized by low expression of claudins 3, 4, & 7 and E-cadherin. This subtype has been reported to be associated with expression of mesenchymal and cancer stem cell (CSC) markers. Herein we describe the morphological characteristics of claudin-low breast cancers and their association with overall survival and CSC markers.

Design: 943 T1 and T2, lymph node negative, primary invasive breast cancers treated with breast conserving surgery (BCS) and adjuvant radiation had formalin fixed paraffin embedded (FFPE) tumor blocks available for tissue microarray (TMA) construction. On the basis of IHC expression of ER, PR, HER2, Ki67, EGFR, CK5/6, Claudins 3, 4 & 7 and E-cadherin the tumors were classified as luminal A, luminal B, HER2 over-expressing, basal-like or claudin-low. Kaplan-Meier methods were used to estimate

overall survival. Fisher's exact tests were used to compare the claudin-low with luminal A subtypes with respect to tumor characteristics and the expression of CSC markers (ALDH1, CD44^{hi}/CD24^{low}).

Results: A molecular subtype was assignable in 782 of 943 tumors (83.0%), of which 357 (46%) were luminal A, 222 (28%) were luminal B, 32 (4%) were HER2 over-expressing, 110 (14%) were basal-like and 61 (8%) were claudin-low. The overall survival for claudin-low tumors at a median follow-up of 12 years was 73.6% (95% confidence interval [CI]: 58.0% to 84.2%) similar to that of basal-like (74.1%) and HER2 (72.5%) over-expressing subtypes. Compared to luminal A type tumors the claudin-low subtype were statistically more likely to have circumscribed tumor margins (20% vs 9%, $p=0.022$). There was no statistically significant association between claudin-low subtype and the expression of CSC markers (ALDH1 $p=1.00$, CD44^{hi}/CD24^{low} $p=0.23$).

Conclusions: The claudin-low subtype represents a minority of invasive breast cancers (8%), this group is characterized by poor prognosis similar to that of HER2 over-expressing and basal-like tumors. No association with the breast CSC markers examined was demonstrable in this cohort.

132 Diabetic Mastopathy, a Clinicopathological Correlation of 32 Cases

O Dorokhova, S Fineberg, A Shapoval, T Koenigsberg, Y Wang. Montefiore Medical Center and Albert Einstein College of Medicine, Bronx, NY; St. Vincent's Medical Center, Bridgeport, CT.

Background: Diabetic mastopathy (DMP) is a fibrous disease of the breast considered to be of autoimmune pathogenesis. Pathologic features include dense stromal fibrosis, lobular atrophy, circumferential mature B cells around small vessels, lobules and ducts, and increased stromal spindle and epithelioid-like cells. Imaging studies are often inconclusive. We present this case series of DMP in order to better define the clinicopathological spectrum of this disease.

Design: Thirty-two patients with classical features of DMP were identified from the pathology files of Montefiore Medical Center from 1999 till 2011. All slides were independently reviewed by 2 breast pathologists and the relevant clinical information was collected.

Results: All 32 patients were female, 23 (76.7%) had documented diabetes mellitus (DM) (8 type 1, 11 type 2 and 4 DM of unknown type). One woman had Graves' disease. The remaining patients did not have documented autoimmune disorders. The mean age for patients with type 1 DM was 36, for women with type 2 and unknown type DM was 66 and 68, respectively. Clinically, 27 (84.4%) patients presented with palpable masses; 1 with nipple discharge; 3 were identified on mammogram and 1 on MRI. At the time of the initial presentation, 4 (12.5%) patients had multiple masses in the ipsilateral breast and 2 (6.3%) had bilateral lesions. Five patients (15.1%) developed additional masses (2 ipsilateral and 3 bilateral). DMP was described on mammography as heterogeneously dense parenchyma in 67.7% of the cases, as area of asymmetry in 12.9%, and as ill-defined mass in 16.1%. The most common finding on ultrasound was irregular hypoechoic lesion (36.7%); 26.7% showed area of heterogeneity, 3.3% were well-circumscribed solid masses, and 26.7% were negative on imaging. Interestingly, 86.1% of the DMP nodules occurred in the upper outer quadrant of either breast. Notably 11 patients (33.3%) had one biopsy, 21 (66.7%) had at least 2 procedures, among them 9 had more than 2 procedures. Six patients (18.7%) had recurrence. None of DMP nodules showed malignant transformation during follow up.

Conclusions: We outline the constellation of findings on clinical examination, medical history and imaging studies for DMP. The recognition of this benign entity is important because it might spare patients from repeated surgical procedures. A detailed pathological and radiological correlation and immunohistochemical study is underway.

133 Endoglin: An Adjunct Diagnostic Marker To Differentiate between Benign and Atypical Vascular Lesions/Proliferations Arising in the Breast Post-Radiation therapy

W Dubinski, D Ghazarian. University Health Network, Toronto, Canada.

Background: Vascular lesions that arise in the breast following lumpectomy and radiation for breast carcinoma range from benign (e.g. telangiectasias) to atypical vascular lesions/proliferations (AVLPs) to angiosarcomas. Differentiating benign vascular proliferations from AVLPs by morphology is challenging and highly significant, as some AVLPs may progress to angiosarcoma.

Endoglin (CD105) is a specific marker of neovascularisation and differs from traditional panendothelial markers (e.g. CD34, CD31) in that it distinguishes newly formed (e.g. neoplastic) blood vessels from established 'bystander' vessels. Endoglin expression has been reported to be prognostically significant in various tumor types. We present the first comparison of endoglin immunohistochemical expression in benign vascular proliferations, AVLPs, and post-radiation angiosarcomas and apply our findings to differentiate between these lesions.

Design: Patients treated at University Health Network from 2001-2011 with a diagnosis of AVLP (5 cases) or post-radiation angiosarcoma (16 cases) were entered into the study. Each tumor and adjacent normal skin (21 cases) underwent immunostaining for endoglin and D2-40 and an expression value (positive or negative) was determined for each case. Cases were considered positive if any intensity of endoglin staining was present. A selection of benign vascular proliferations (3 pyogenic granulomas, 2 hemangiomas) was stained for comparison.

Results: The full spectrum of tumors was present, including benign proliferations, AVLPs, and both low- and high-grade angiosarcomas. Endoglin highlighted the endothelial cells of all benign vascular proliferations (2/2 hemangiomas, 3/3 pyogenic granulomas, $p=0.001$). A complete lack of endoglin expression was observed in endothelial cells of all cases of AVLP and angiosarcoma (5/5 and 16/16 cases, respectively; $p=0.001$). There was no endoglin expression in normal non-tumor skin (21/21 cases, $p=0.001$). Endoglin did not highlight any lymphatic vessels in either tumor or normal skin.

Conclusions: Benign vascular proliferations retained endoglin expression whereas AVLPs and angiosarcomas showed a complete lack of endoglin expression in both the neoplastic vessels and tumor cells. Our data suggest that endoglin (CD 105) might be used as an adjunct diagnostic marker to differentiate between benign vascular proliferations and AVLPs and implies a new way to understand the contribution of endoglin in the pathogenesis of vascular proliferations.

134 Immunophenotypic and Genomic Characterisation of Papillary Carcinomas of the Breast

R Duprez, P Wilkerson, M Lacroix-Triki, MB Lambros, A Mackay, RA'Hern, A Gauthier, P-E Colombo, F Daley, R Natrajan, E Ward, G MacGrogan, F Arbion, P Michenet, B Weigelt, A Vincent-Salomon, JS Reis-Filho. The Institute of Cancer Research, London, United Kingdom; Institut Claudius Regaud, Toulouse, France; Institut Curie, Paris, France; Institut Bergonié, Bordeaux, France; Centre Hospitalier Universitaire, Tours, France; Centre Hospitalier Régional, Orléans, France; Cancer Research UK London Research Institute, London, United Kingdom.

Background: Papillary carcinomas (PCs) are a rare histological special subtype of breast cancer associated with a favourable outcome. The aims of this study were to characterise the immunohistochemical characteristics, gene copy number aberrations and mutational repertoire of PCs, and to determine whether they would constitute an entity distinct from histological grade- and oestrogen receptor (ER)-matched invasive ductal carcinomas of no special type (IDC-NSTs).

Design: Sixty-three formalin-fixed paraffin-embedded PCs (39 encapsulated, nine solid, 12 invasive and three mixed encapsulated/ solid PCs) and 63 grade- and ER-matched IDC-NSTs were subjected to immunohistochemical profiling using a panel of 18 antibodies. DNA of sufficient quality was extracted from 49 microdissected PCs and 49 microdissected grade- and ER-matched IDC-NSTs, and subjected to high-resolution microarray-based comparative genomic hybridisation (aCGH) and MassARRAY Sequenom sequencing analysis of 19 known oncogenes.

Results: PCs were predominantly of low histological grade, expressed immunohistochemical markers consistent with a luminal phenotype, and displayed a lower rate of lymph node metastasis and p53 expression than grade- and ER-matched IDC-NSTs. PCs displayed less genomic aberrations than grade- and ER-matched IDC-NSTs; however the patterns of gene copy number aberrations found in PCs were similar to those of ER- and grade-matched IDC-NSTs, including 16q losses. Furthermore, *PIK3CA* mutations were found in 43% and 29% of PCs and grade- and ER-matched IDC-NSTs, respectively. The genomic profiles and mutational repertoires of encapsulated, solid and invasive PCs were remarkably similar.

Conclusions: Our results demonstrate that PCs are a homogeneous histological special type of breast cancer. The similarities of the genomic profiles of papillary carcinomas and grade- and ER-matched IDC-NSTs suggest that PCs may be best positioned as part of the spectrum of ER-positive breast cancers rather than as a distinct entity. Furthermore, the good prognosis of PCs may stem from the low rates of lymph node metastasis and p53 expression, low number of gene copy number aberrations, and high prevalence of *PIK3CA* mutations.

135 Concordance between Tissue Microarray and Whole Section Estrogen Receptor Expression and Intratumoral Heterogeneity

L Dvorak, R Gamez, L Varghese, C Forster, HE Gulbahce. University of Minnesota Fairview, Minneapolis, MN; Mayo Clinic, Rochester, MN; Fairview Southdale Hospital, Edina, MN; BioNet, University of Minnesota Fairview, Minneapolis, MN; VA Medical Center, Minneapolis, MN.

Background: Hormone receptor status determination for breast cancer is an important part of pathologists' daily sign outs and many retrospective and prospective studies. We compared the estrogen receptor (ER) expression tested on tissue microarray (TMA) sections to those tested on whole sections (WS) to find out concordance and frequency of intratumoral heterogeneity (ITH).

Design: One mm TMA were constructed from breast cancer excision tissue which were originally tested for ER by IHC or ligand binding assay (LBA). Discrepancy in ER expression between WS and TMA was evaluated only on those originally tested with IHC. All cases (originally tested by both IHC and LBA) with large enough tumor available on the block to allow more than 1 core were used to determine ITH. Each core's ER status was independently determined according to the current CAP guidelines with $\geq 20\%$ staining recorded as positive. Staining intensity was not evaluated.

Results: 15 of 272 (5.5%) of the cases showed discrepant results between WS and TMA. Likelihood of finding discrepancy between TMA and WS decreased as more cores were available at TMA. Overall 5/66 (7.6%) of TMA ER negative cases and 10/206 (4.9%) of TMA ER positive cases showed discrepancy with WS ER results. Four of 279 (1.4%) cases with more than one core on TMA (three cases had 3 cores and one case had 4 cores on TMA) showed discrepancy amongst the cores.

Conclusions: There is good correlation between ER on WS IHC and TMA IHC. TMA, rather than WS, may be used for ER status determinations from old stored blocks which were originally tested with LBA or IHC but need to be retested with a different Ab. This also provides indirect evidence that in majority of the cases, ER results of breast core biopsies will be representative of the whole tumor which is important in patients undergoing neoadjuvant therapy with no residual invasive tumor to test or confirm biopsy ER results. Intratumoral ER expression heterogeneity within the same tumor block is a rare event within primary breast cancers. Since only four of the 279 (1.4%) cases which had more than 1 core available showed discrepancy amongst the cores, it is not possible to recommend the optimal number of cores for accurate classification of a case as ER negative.

136 Clinicopathologic and Genomic Characterization of Solid Papillary Breast Carcinoma (SPC)

C Eberle, M Magbanua, E Sosa, J Grenert, JT Rabban, C Zaloudek, Y-Y Chen. University of California, San Francisco, San Francisco, CA.

Background: SPC can be challenging to diagnose and manage because myoepithelial cells (MEC) may be absent in morphologically well-circumscribed tumors. In this study, we correlate the clinical features, biomarker profiles and genomic alterations of SPC, emphasizing cases that are difficult to classify.

Design: 56 SPC were identified from 2001-2011. The cases were classified based on growth pattern and MEC expression (Table). The clinical features were reviewed. Conventional carcinoma, when present, was noted. Biomarker expression was examined using immunostains for ER, PR, HER2, and neuroendocrine (NE) markers. Genome-wide alterations were analyzed by array-based comparative genomic hybridization (aCGH) on selected cases.

Results: 50/56 cases could be classified with certainty, but 6 had discrepant growth pattern versus MEC expression (group D). In follow-up (0.1-10.3 y), LN metastasis was not identified in the cases with indeterminate classification. Among the 56 SPC, 95% were low to intermediate histologic grade. 96% were ER/PR positive and none overexpressed HER2. aCGH evaluated on 4 SPC (2 in group B, 1 each in C, E) showed a similar genomic profile with recurrent changes (75-100%) including gains of 1q, 5q & 10q, and losses of 2p, 8q, 13q, 14q, 15q & 16q. 2 of 31 patients with LN sampling had metastasis, both in patients with an invasive SPC component; metastases displayed SPC morphology. One patient developed recurrence. No patient died from SPC.

Conclusions: We are unable to identify specific features to better classify the indeterminate SPC. Because no LN metastasis is observed in this group, the question remains whether these are invasive tumors or not. Preliminary aCGH study suggests characteristic genomic alterations in invasive SPC. Comparison of aCGH in group D to other groups may help further classify indeterminate cases and is in progress.

Characteristics of SPC Groups

	All patients (n=56)	A: in situ SPC only (n=5)	B: in situ + inv SPC (n=18)	C: in situ SPC + IDC (n=12)	D: Indeterminate SPC (n=6)	E: Invasive SPC (n=15)
Growth pattern*	3,4,1	4,3,2	4,3,1	2,1	3,4	-
MEC	+	+/-	+	-	-	-
Mean age	66	62	67	68	64	64
Bloody nipple discharge*	17%	50%	20%	30%	0%	0%
Palpable mass	26%	0%	33%	20%	20%	36%
Abnormal mammogram	52%	50%	47%	30%	80%	64%
Incidental finding	5%	0%	0%	20%	0%	0%
NE diff	70%	100%	67%	83%	33%	64%
Mucinous diff	30%	60%	33%	25%	17%	27%
LN met	6.5%	NA	10%	0%	0%	11%

*1: single nodule, smooth border; 2: single nodule, irregular border; 3: multinodular single mass; 4: multiple discrete nodules +: MEC positive in all nodules; -: negative in all nodules; +/-: positive in some nodules

137 The Impact of the Greatest Linear Extent of Invasive Mammary Carcinoma in Needle Biopsy Material on Final Pathological Size and Tumor Stage

HD Edwards, O Hameed. Vanderbilt University Medical Center, Nashville, TN.

Background: Pathologic tumor size (TS) is one of the most important prognostic factors in invasive mammary carcinoma (IMC) and is usually determined after definitive excision (Ex). To our knowledge there are no systematic studies that specifically evaluate the impact of TS in needle biopsy (NB) material on the final pathologic TS and pathologic tumor (pT) stage.

Design: Tumor size in NB material, determined by greatest linear extent (GLE), was compared to that on Ex and the relationship between them and with final pT stage was determined for 99 consecutive IMCs. Statistical analysis was also performed to evaluate any associations between clinicopathological features and finding a larger size on NB.

Results: The overall mean TS on NB was less than that of the corresponding resection (0.84 vs. 1.3 cm; $P < .0001$, paired t-test); however, the opposite was seen when only small tumors (≤ 5 mm) were considered (0.42 vs. 0.26 cm; $P = .066$). There were 19 cases in which TS on NB was greater than that on Ex, with the differences being statistically significant (Figure 1). Of these 19 cases, 12 resulted in a higher pT stage (Figure 2). A larger TS on NB compared to Ex was significantly associated with a lower final pT stage ($P = .007$, X^2) and neoadjuvant therapy prior to resection ($P = .01$), but not with patient age, histologic type, histologic grade, proliferation rate or the presence/absence of DCIS ($P = .19, .53, .7, .83$ and $.07$, respectively).

Conclusions: These findings show that the greatest linear extent on needle biopsy often contributed the largest tumor size and, in a significant proportion of cases, resulted in a higher overall pT than would have been obtained by measurement on the excision alone. Accordingly, it is recommended that greatest linear extent of invasive mammary carcinoma should be reported in needle biopsy material, particularly in the setting of small tumors.

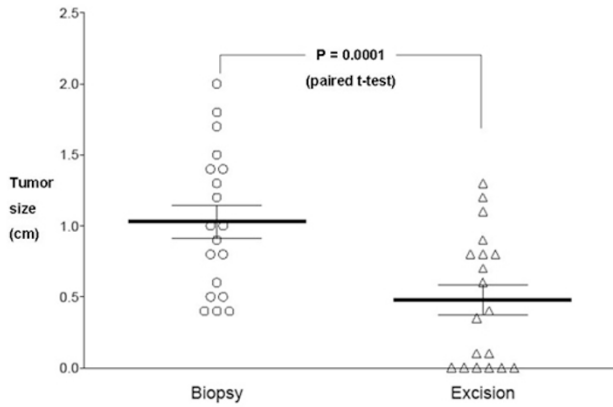


Figure 1. Comparison of 19 cases for which tumor size on needle biopsy exceeded that on excision (mean, 1.03 vs. 0.48 cm).

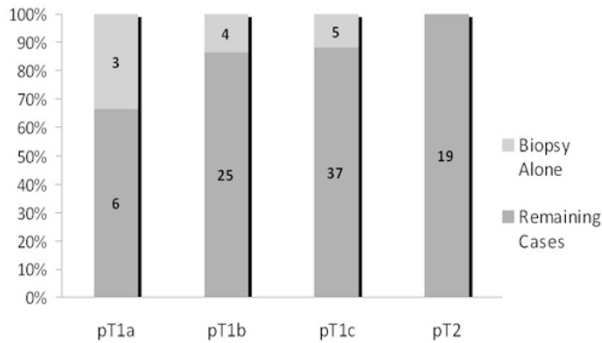


Figure 2. Relative proportion of cases in which needle biopsy alone was the determinant of final pathologic stage (pT).

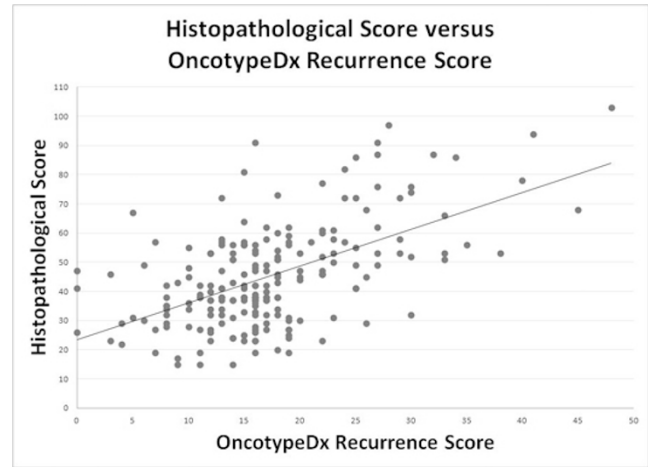
138 Do Combined Histopathological Features of ER Positive Breast Carcinoma Correlate with OncotypeDx Recurrence Score?

S Ehdavand, RA Simon, C Zhang, MR Quddus, JJ Ou, J Xiong, K Hansen, MM Lomme, W Shen, MM Steinhoff, WD Lawrence, CJ Sung. Brown University/Women & Infants Hospital, Providence, RI.

Background: Gene expression assays, such as OncotypeDx (ODx), show promise to predict recurrence and help guide treatment of the heterogeneous group of estrogen receptor (ER) positive breast carcinomas, including cases with metastatic disease in lymph nodes. However, this technology is relatively costly and patient selection criteria are subjective. Histopathological features, along with ER, progesterone receptor (PR), and HER2 status, are routinely reported and remain the current gold standard for predicting response to treatment and prognosis. This study aims to correlate routine histopathological features with ODx Recurrence Score (ODxRS) and seeks to determine if a subgroup of cases may not benefit from the added cost of ODx.

Design: The slides and charts of 206 patients who had ODx performed between July 2004 and July 2011 were examined. Ten histopathological parameters were evaluated and assigned value including tumor size, tubule formation, nuclear grade, mitotic count, lymphovascular invasion, lymph node status, quantitative ER and PR (using current CAP reporting standards), HER2 status, and extent of adjacent DCIS. A formula was developed to calculate a Histopathological Score (HS) combining nine weighted parameters (DCIS was excluded). The weight of each parameter was based on the strength of correlation with the reported ODxRS. The total HS for each case was compared to the ODxRS.

Results: Histopathological grade along with ER, PR, and HER2 status significantly correlated with ODxRS. Additionally, cases with a combined HS of ≤ 50 correlated with an ODx score of ≤ 30 ($n=141$, 69% of total cases). All resultant scores correlated with ODx scores with an $R=0.565$ (Figure 1). The extent of DCIS did not correlate with ODxRS. Nodal status, lymphovascular invasion, and tumor size did not independently correlate with the ODxRS.



Conclusions: Routinely obtained histopathological parameters can predict an ODxRS of ≤ 30 when the calculated HS is ≤ 50 (69% of our cases); therefore, it may not be necessary to perform ODx testing in these cases. Further studies are needed to validate the utility of combined HS in selecting cases for ODx testing.

139 Chromosome 17 Polysomy and Monosomy as Predictive Markers of Complete Pathological Response (pCR) in Women with Locally Advanced Breast Cancer (LABC)

L Elavathil, P Nirmalanantham, B Dhesy, G Gohla, O Boutross-Tadross, J Ramsay, T Aziz, A Bane, S Tang, A Lytwyn. Juravinski Hospital, Hamilton, ON, Canada; Juravinski Cancer Centre, Hamilton, ON, Canada.

Background: Fifteen to 22% of LABC patients achieve pCR after neoadjuvant therapy. Carcinomas that are negative for estrogen and progesterone receptor expression (ER-/PR-) and those that show HER-2/neu overexpression (HER-2/neu+) may achieve higher rates of pCR, but study results are not consistent. The HER-2/neu gene is present on chromosome 17 (Ch17). Polysomy or monosomy of Ch17 can occur, but the effect of these aberrations on response to treatment is not clear. We studied whether Ch17 polysomy/monosomy as detected by fluorescent *in situ* hybridization (FISH) on the pre-treatment breast needle core biopsy (NCB) can predict pCR in LABC patients. Additionally, we examined whether tissue expression of ER/PR and HER-2/neu was associated with pCR.

Design: LABC patients who were treated between 2007 and 2010 were identified. Immunohistochemistry (IHC) and FISH were performed on the NCB specimens to test for ER/PR expression and HER-2/neu expression, respectively. Ch17 polysomy was defined as present when the FISH Ch17 probe (CEP17) signal/nucleus was ≥ 3 , and monosomy when CEP17 signal/nucleus was < 2 . Two pathologists, who were blinded to all IHC and FISH results, reviewed the slides from each mastectomy case to assess pCR.

Results: A total of 65 LABC patients were identified. Of the 14 patients with polysomy, 4 (29%) achieved pCR compared to 6/46 (13%) with normal Ch17 expression ($p=0.172$). pCR was not seen in any of the 5 patients with monosomy. Of the 35 patients with ER- tumors, 9 (26%) achieved pCR, compared to 1/30 (3%) of ER+ patients ($P=0.013$). Ten of the 40 (25%) PR- patients achieved pCR, while none of the 25 PR+ patients showed pCR ($P=0.010$). pCR was seen in 6/14 (43%) of HER-2/neu+ patients, compared to 4/51 (8%) of HER-2/neu- patients ($P=0.001$).

Conclusions: Patients with monosomic tumors may display higher resistance to chemotherapy for histologic response. Polysomic tumors may have a higher rate of pCR compared to normal Ch17 expression, but the small sample size prevents definitive conclusion. Our findings agree with others that ER-/PR- and HER-2/neu+ tumours achieve higher frequency of pCR.

140 Multiplex Ligation-Dependent Probe Amplification (MLPA) Compared to Immunohistochemistry (IHC) and Fluorescence In Situ Hybridization (FISH) for Assessing HER2 Amplification in Invasive Breast Carcinoma

L Elavathil, A Manan, J Moreno, R Carter, L Connie, S Savola, A Lytwyn. Juravinski Hospital, Hamilton, Canada; McMaster University, Hamilton, Canada; Bay Area Genetics Laboratory, Hamilton, Canada; MRC Holland, Amsterdam, Netherlands.

Background: HER2 amplification status determines optimal treatment regimens for patients with invasive breast carcinoma. FISH is currently the definitive test for HER2 status, however it is costly, and in many centers is performed only if IHC testing shows indeterminate results. MLPA is a PCR-based technique which uses 4 probes for HER2 gene and can detect sequence dosage differences in a semi-quantitative manner. MLPA costs less than FISH. We compared MLPA testing to FISH and IHC in invasive breast cancer and report the concordance among these tests.

Design: Thirty (30) breast carcinoma from excisional biopsy specimens with known HER2 status by IHC (A0485) were studied. There were 13 negative (score 0 or 1), 10 indeterminate (score 2+) and 7 positive cases (score 3+ in $>30\%$ of cells). HER2 gene amplification status was determined by FISH (Vysis Pathvision) and by MLPA (MRC-Holland). FISH scores were defined as: negative (< 1.8), indeterminate (1.8-2.2) or positive (> 2.2). MLPA ratio of 0.7-1.3 was considered negative, while a ratio > 1.3 was positive for increased copy number. A ratio from 1.3 to 2 indicates low positive, while > 2 indicates high positive results. There is no indeterminate scoring category

in MLPA. Readers of one test were masked to the results of the other two tests, for example, those scoring MLPA did not know the results IHC or FISH.

Results: MLPA and FISH were concordant in 28 (93%) cases. Seven cases were positive for HER2 amplification by all 3 methods. Two cases scored as negative by both IHC and FISH were scored as low positive (1.44 and 1.35) by MLPA.

HER2 Amplification by MLPA Compared to IHC and FISH

IHC (n)	FISH		MLPA	
	Negative (n)	Positive (n)	Negative (n)	Positive (n)
Negative (13)	13	0	11	2
Indeterminate (10)	10	0	10	0
Positive (7)	0	7	0	7
Total (30)	23	7	21	9

Conclusions: These results suggest that MLPA could be used as an alternative method of testing for HER2 gene amplification status. MLPA identified additional 2 cases with HER2 amplification that were negative by both IHC and FISH. Further studies with a larger sample size are warranted to investigate whether MLPA improves correlation between gene amplification status and patient responsiveness to treatment.

141 Cytokeratin Immunohistochemical Profile of Breast Cancer: Do CK7 Negative Breast Carcinomas Exist?

E Elishaev, R Bhargava. Magee Women's Hospital of UPMC, Pittsburgh, PA.

Background: Often the first step in immunohistochemical (IHC) evaluation of a carcinoma of unknown origin is the tumor's CK7/CK20 profile. Breast cancers are categorized as tumors showing a CK7+/CK20- IHC profile. Any other profile will sway the investigator into a different direction.

Design: In order to identify other possible profiles, 186 consecutive primary breast carcinomas were investigated. The study was performed on tissue microarrays with 3 fold redundancy in order to mimic small core biopsies that are often the specimen a pathologist receive for analysis. A detailed IHC scoring using an H-score method (score ranges from 0 to 300) and also percentage of positive cells was utilized for evaluating CK7 (clone OVTL-30) and CK20 (clone 30S) stains. A biotin block was used during IHC procedure to block any non-specific staining.

Results: The most common IHC profile of breast carcinoma is CK7+/CK20- seen in 173/186 (93%) cases, followed by CK7-/CK20- profile identified in 12/186 (6.5%) cases. Only one case (0.5%) showed a CK7+/CK20+ profile, and none of the cases showed a CK7-/CK20+ profile. Most CK7+ cases were strongly and diffuse positive with a mean and median H-scores of 260 and 290 respectively with standard deviation of 67. The CK7 results with respect to percentage positive cells and receptor status is shown in table 1. In the only CK+/CK20+ case, CK20 reactivity was weak and was seen in 15% of the cells.

Percentage of CK7+ cells with respect to receptor status

	0% cells+	1-10%cells+	11-50%cells+	>50% cells+	Total
ER+/HER2-	11	1	2	116	130
ER+/HER2+	1	5	1	13	18
ER-/HER2+	0	0	0	8	8
ER-/HER2-	0	1	2	27	30
Total	12	5	5	164	186

Conclusions: Although majority of breast carcinomas are CK7+/CK20-, an unusual profile (i.e. CK7-/CK20-) is not uncommon and can create confusion in investigation of a carcinoma of unknown primary. Fortunately, many of the CK7 negative tumors are hormone receptor positive. The results of this study strongly support the use of IHC panels when investigating tumors of unknown primary origin.

142 Fascin Expression Associated with Triple Negative Breast Cancers and Unfavorable Prognosis in African-American Women

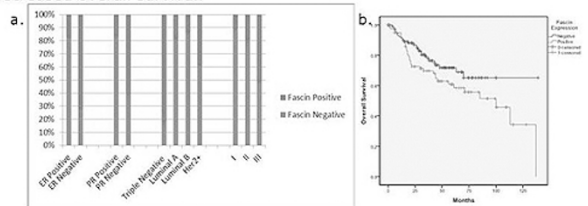
AK Esnakula, LJ Ricks-Santi, W Frederick, TJ Naab. Howard University Hospital, Washington, DC; Howard University Cancer Center, Washington, DC.

Background: Fascin, an actin-binding protein, induces parallel actin bundles in cell protrusions and promotes cell motility. Fascin overexpression has been associated with progression and unfavorable prognosis in hormone-receptor negative breast carcinomas. The objective of our study is to correlate the immunohistochemical expression of fascin in the four major subtypes of breast carcinoma (luminal A, luminal B, HER2 positive, and Triple Negative) and other clinicopathological factors including age, grade, tumor size, stage, regional node status, and overall survival in African American women.

Design: Tissue microarrays (TMAs) were constructed from optimally-fixed formalin-fixed, paraffin-embedded tumor blocks from primary breast carcinomas in 203 African-American females. Two separate 1mm cores represented each case. Five micrometer sections were stained with a primary monoclonal antibody against fascin (FCN01, Thermo, CA, USA). The sections were evaluated for the intensity of reactivity (0-3) and the percentage of reactive cells; and an H-score was derived from the product of these measurements. Cases were categorized as having negative/weak (score ≤ 100) or moderate/strong (score >100) fascin expression. Bivariate analysis was done via χ^2 analysis and survivability data was calculated via the generation of Kaplan-Meier curves (SPSS v19). Statistical significance was assumed if $P < 0.05$.

Results: Fascin expression was significantly linked to the Triple Negative subtype ($p < 0.0001$), ER negativity ($p < 0.0001$), PR negativity (0.0001), and Grade III differentiation ($p = 0.03$). There was a trend towards decreased overall survival ($p = 0.08$) and disease-free survival ($p = 0.05$). No correlation was seen with fascin expression and age, tumor size, node status, or stage.

Figure 1. a) Fascin expression correlates with ER negativity, PR negativity, Triple Negative Breast Cancer Subtype, Grade III differentiation, and **b)** decreased overall survival.



Conclusions: Our results indicate that fascin could be a potential marker of aggressive phenotype and a predictor of recurrence. Recent *in vitro* studies reveal that migrastatin analogs inhibit cell migration and metastasis by targeting fascin, making fascin a potential molecular target for cancer treatment in patients with Triple Negative breast carcinoma.

143 Metabolomic Transmethylation Profiling Reveals Differences in ER- Compared to ER+ Breast Cancer in African-American Women

AK Esnakula, TJ Naab, LJ Ricks-Santi, S Dasi, H Paul, RL DeWitty, W Frederick, E Gabrielson, YM Kannan. Howard University Hospital, Washington, DC; Johns Hopkins University, Baltimore, MD.

Background: Estrogen receptor negative (ER-) breast cancer, which is associated with poorer survival, is more common in younger African-American women when compared to other ethnic groups. The mechanisms, underlying these health disparities, remain largely unknown, especially in ER- breast cancer, which is often refractory to conventional therapy. Increased gene methylation frequency has been previously described in aggressive ER- breast cancer in African-American women. The goal of this study is to establish metabolomic transmethylation profiles in ER- and ER+ breast cancers from African-American women.

Design: Breast cancer tumor tissue methanol extracts from 15 ER- and 15 ER+ African-American women and several technical replicate samples from a homogenous pool containing a small amount of all study samples were analyzed using liquid/gas-chromatography coupled to mass spectrometry. Transmethylation pathway components were analyzed. Following log transformation and imputation with minimal observed values for each compound, Welch's two-sample t-test was used to identify metabolites that differed significantly between experimental groups.

Results: ER- breast cancer tumors showed significantly increased levels of methionine, S-adenosylhomocysteine and homocysteine when compared to ER+ tumors ($p \leq 0.05$), reflecting an increase in methionine accumulation and metabolism. Dimethylglycine and choline, intermediate metabolites, along with betaine, sarcosine and glycine were all collectively increased in the transmethylation pathway in the ER- cohort ($p \leq 0.05$). Two oncometabolites, sarcosine and 2-hydroxyglutamate were also elevated in ER- tumors ($0.05 < p < 0.1$). Hypermethylation in the ER- samples were further supported by increased concentrations of 4-methylglutamate, 2-methylbutyrylcarnitine, dimethylarginine, N1-methyladenosine, N1-methylguanosine, 5-methyluridine, N2,N2-dimethylguanosine, methyl-alpha-glucopyranoside, 5-methylthioadenosine and methylphosphate.

Conclusions: Our studies indicate that increased components of the transmethylation pathway observed in the ER- breast cancer samples could play an important role in the aggressiveness of ER- breast cancers. Metabolomics could help to identify novel therapeutic targets and biomarkers of diagnostic and prognostic significance.

144 Cytoplasmic Beta-Catenin Expression Associated with Triple Negative and HER2 Positive Breast Cancer Subtypes in African-American Women

AK Esnakula, LJ Ricks-Santi, YM Kannan, TJ Naab. Howard University Hospital, Washington, DC; Howard University Cancer Center, Washington, DC.

Background: Beta-catenin plays an essential role in cell adhesion via catenin-cadherin complexes and acts as a transcriptional regulator in the Wnt signaling pathway. With Wnt activation, beta-catenin is transferred from the membrane to the cytoplasm and the nucleus where it interacts with activators of transcription to modulate target genes, including c-MYC and cyclin D1, responsible for growth, invasion, and cellular transformation. The object of our study is to look for an association between beta-catenin expression and prognostic factors in four major subtypes of breast cancer (Luminal A, Luminal B, HER2 positive, Triple Negative) in 202 African-American women.

Design: Tissue microarrays (TMAs) were constructed from optimally-fixed formalin-fixed, paraffin-embedded tumor blocks from primary breast carcinomas in 202 African-American females. Two separate 1mm cores represented each case. Five micrometer sections were stained with a polyclonal antibody against beta-catenin (17C2, Thermo, CA, USA). The sections were evaluated for intensity of reactivity (0-3) and the percentage of reactive cells; an H-score was derived from the product of these measurements. Cases were categorized as having negative (score < 100) or positive (score ≥ 100) for membrane expression and negative (score = 0) or positive (score > 0) for cytoplasmic expression and nuclear expression. Bivariate analysis was done separately for the membrane expression and the cytoplasmic expression via χ^2 analysis and survivability data was calculated via the generation of Kaplan-Meier curves (SPSS v19). Statistical significance was assumed if $p < 0.05$.

Results: Cytoplasmic beta-catenin expression was associated with the HER2+ subtype ($p < 0.001$), ER negativity ($p < 0.001$), PR negativity ($p < 0.001$), the Triple Negative subtype ($p < 0.03$), and HER2 positivity ($p = 0.03$). No correlation was seen with cytoplasmic beta-catenin expression and age, tumor size, node status, stage, grade, or survival. No correlation was found with loss or retention of beta-catenin membrane

expression and any prognostic parameters. No nuclear stain was observed in any case. **Conclusions:** Our study found a significant association between the beta-catenin cytoplasmic expression and the breast cancer subtypes, *HER2+* and Triple Negative and hormone negative cancers. Collectively, these findings suggest that Wnt signalling pathway may play a role in the pathogenesis of unfavorable breast cancer subtypes in African-American females.

145 Differential Expression of Milk Fat Globule-EGF Factor 8 (MFG-E8) in Breast Cancers

Y Fang, Q Xie, H Wang, C Yang, AS Braverman, CA Axiotis. SUNY Downstate Medical Center/Kings County Hospital, Brooklyn, NY; BIDMC, Boston, MA; MGH, Boston, MA; SUNY Downstate Medical Center/Kings County Hospital, Brooklyn, NY.

Background: Levels of milk fat globule-EGF factor 8 (MFG-E8) mRNA, determined by microarray and *in situ* hybridization, are high in triple negative (ER/progesterone receptor/HER2/neu negative) breast cancer, but lower in estrogen receptor positive (ER+) breast tumors. Approximately 26% women who have breast cancer have p53 mutations. p53 mutation is most commonly associated with ER-/PR- tumors in premenopausal women. The patient with p53 mutations usually have poorer prognosis. Immunohistochemistry has been used to determine MFG-8 levels and its correlation with ER expression in breast biopsies, but their correlation with p53 and HER2/neu expression is not known.

Design: Benign breast lesions, and ER, HER2/neu and p53 positive and negative breast cancers were stained with an anti-MFG-E8 antibody.

Results: MFG-E8 was absent in 5 benign breast lesions (1 fibroadenoma, 2 intraductal papilloma, and 2 sclerosing adenosis). MFG-E8 was present in the plasma membrane and cytoplasm of 18 of 26 (69%) triple negative tumors. The presence of p53 mutations was known in all 26 triple negative tumors; 5 of the 9 tumors (56%) without p53 mutations, and 13 of 17 tumors (77%) with mutations were positive for MFG-E8. 3 out of 7 ER-, Her2/neu+ (43%) tumors showed positive staining for MFG-E8. Seven ER/HER2+ tumors and 7 ER+, HER2- tumors were negative for MFG-E8.

Conclusions: Immunohistochemical staining confirms the results of gene expression analysis of breast tumors for MFG-E8 mRNA. The protein product is absent in benign breast lesions and in ER+ tumors, whether HER2/neu+ or HER2/neu-, but present in most ER- tumors. MFG-E8 is expressed highest in triple negative, p53+ tumors. MFG-E8 protein may prove to be an independent marker for the latter tumors, and have implications for their histogenesis.

146 Biopsy Outcomes in Screen Detected Microcalcifications

G Farshid, T Sullivan, P Downey, G Gill, S Pieterse. BreastScreen SA, Wayville, SA, Australia; SA Pathology, Adelaide, SA, Australia; University of Adelaide, Adelaide, SA, Australia.

Background: The assessment of microcalcifications detected on screening mammograms has led to a substantial increase in the incidence of DCIS. At present DCIS comprises 1 in 5 screen detected malignancies. From a medical stance, the diagnosis of DCIS represents an important opportunity to prevent its progression to invasive cancer. However, to the extent that not all cases of DCIS will progress to invasive cancer in the woman's lifetime, some view the diagnosis of DCIS and its treatment as instances of over diagnosis and over treatment.

Recent genetic and transcriptomic studies of the various stages of breast cancer development have led to the emerging view that breast cancer evolves along two divergent molecular pathways and that these changes are evident early in the genesis of the disease, including its *in situ* phase.

We wished to evaluate the histologic features of malignancies diagnosed as a result of assessment of microcalcifications in the setting of population based breast cancer screening.

Design: Between Jan 1992–Dec 2007 cases biopsied in which microcalcifications were the only imaging abnormality were included. Patient demographics, imaging features and final histology were subjected to statistical analysis.

Results: Of 2545 lesions assessed, 1220 (47.9%) were malignant (809 DCIS only, 411 DCIS with invasive cancer) and 1325 (52.1%) were non-malignant, including 122 (4.8%) pre-malignant lesions (LCIS, ALH and ADH). The DCIS grade was high in 58.5%, intermediate in 9.5% and low in 30.9%. Special DCIS subtypes constituted 1.2% of cases. There was no correlation between the imaging and histologic grades. The invasive cancers were graded I in 21.2%, II in 43.8%, III in 14.1% and undetermined due to small size in 18.7%. Nodal metastases were detected in 15.6% of invasive cancers. On multivariate modelling imaging grade, mammographic extent >15mm, palpable mass and screening episode were independent predictors of malignancy. Radiologic grade had the largest effect with lesions of grade 4 and 5 being 2.2 and 3.3 times more likely to be malignant respectively than grade 3 lesions.

Conclusions: In addition to their strong association with DCIS, particularly of high grade, the assessment of appropriately selected screen detected microcalcifications enables detection of invasive breast cancers, including small invasive cancers. This is an important opportunity for altering the natural history of breast cancer and improving women's health outcomes.

147 Effect of Normal Gland Staining on Amplification Results by FISH in HER2/Neu 3+ Invasive Carcinoma of the Breast

FA Fedda, CG Farra, AN Tawil, A Tjajli, FI Boulos. American University of Beirut Medical Center, Beirut, Lebanon.

Background: Although epithelial cells of normal ducts do not have HER2 gene amplification and should show essentially no levels of membrane staining by HER2 immunohistochemistry (IHC), HER2 staining in benign breast epithelium is occasionally encountered. The significance of this occurrence has not yet been substantially studied

in the literature. It was however briefly addressed by the ASCO/CAP who recommended avoiding interpretation of IHC results in cancers with "strong staining of normal breast ducts". The ASCO/CAP guidelines did not however provide a clear definition for "strong staining", rendering it a largely subjective assessment. An alternative approach advocated by some authorities has been to subtract the amount of staining observed in normal breast epithelium from the score observed in breast cancer cells in the same section. The purpose of this study is to assess the correlation between HER2 IHC 3+ cases with normal gland staining (NGS) and their corresponding FISH results, to better understand the significance of such a finding on the final HER2 amplification status in carcinomas of the breast.

Design: 154 breast cancers cases with HER2 reported as positive (3+) between January 2005 and March 2011 were reviewed and HER2 status reconfirmed according to ASCO/CAP guidelines of 2007. NGS and other clinicopathologic characteristics were recorded. NGS was scored according to the same criteria used to score invasive cancer. Cases with 3+ HER2 status and NGS of at least 1+ were sent for FISH testing. Thirteen randomly selected positive controls without NGS were also sent for FISH confirmation.

Results: All patients were females with a median age at diagnosis of 55.5 years. Approximately 22% of cases (34/154) showed NGS for HER2. Twenty-four cases (70%) were grade 3, 9 (26%) were grade 2, and 1 (4%) was grade 1. FISH results were as follows: 67% (23/34) were confirmed as positive, 26% (9/34) were negative for amplification, and 6% (2/34) failed FISH testing. All 13 control cases tested positive by FISH. Of the 9 negative cases, four were grade 3, four grade 2, and one was grade 1.

Conclusions: Although based on a small cohort of samples, our study sheds light on an insufficiently studied phenomenon and highlights both its relatively high prevalence and association with significant discordance between IHC and FISH results. We therefore suggest careful assessment for NGS in all HER2 3+ cases, regardless of intensity and extent, and advocate a low threshold for FISH confirmation in such cases.

148 Distinguishing Luminal Breast Cancer Subtypes by Ki67 Index, PR Negativity or p53 Status Provides Prognostic Information?

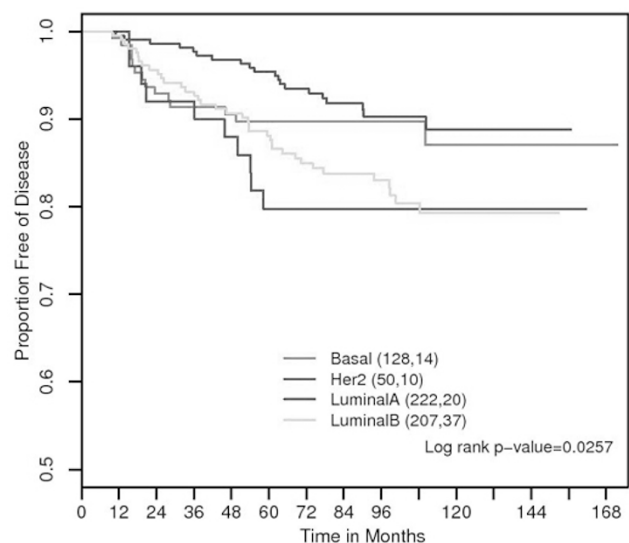
L Feeley, D Pinnaduwage, AM Mulligan, I Andriulis. Department of Pathology, Cork University Hospital, Cork, Ireland; Samuel Lunenfeld Research Institute, Toronto, Canada; Department of Pathology, St Michael's Hospital, Toronto, Canada.

Background: The principal objectives of this study were to determine the prognostic significance when subgrouping estrogen receptor positive breast tumors (i) into immunohistochemically defined luminal A and B categories using Ki67 and ii) according to p53 or PR status.

Design: The study group comprised of a consecutive series of 609 patients with node negative invasive breast carcinoma (median follow-up 107 months). 81 recurrences were observed. The luminal A subtype was defined as being ER and/or PR positive, HER-2 negative, and Ki67 low (<14%) and the luminal B subtype as being ER and/or PR positive, HER-2 negative, and Ki67 high ($\geq 14\%$) as proposed by Cheang et al. For this study, all HER-2 positive tumors were classified in the HER-2 group. ER negative, HER-2 negative, and CK5 positive tumors were classified as basal. Survival analysis was performed. In addition the luminal A and B subgroups were correlated with various clinical, pathological and molecular markers.

Results: Luminal A tumors had a significantly better disease free survival than their high proliferation luminal B counterparts. Furthermore the luminal B subtype was more prone to late relapse with consequent poorer long-term survival than the basal subtype which was at significantly higher risk of early relapse.

Luminals by ki67 (n=609)



When the luminal subgroups were compared pre-menopausal status, larger tumor size, higher tumor grade, presence of LVI, administration of chemotherapy, Bcl-2 negativity and p53 positivity were all significantly associated with luminal B tumors. Using p53 status or progesterone negativity instead of Ki67 to classify the ER+ luminal tumors further refined the luminal group and gave similar outcome results to that obtained using Ki67.

Conclusions: The Ki67 index can be used to segregate hormone receptor positive, HER-2 negative tumors into prognostically meaningful subgroups. Utilization of p53 status or PR negativity can also separate the ER+ luminal group into subgroups with different clinical outcomes. These IHC biomarkers offer a potential alternative to expensive molecular tests such as Oncotype Dx in guiding patient management.

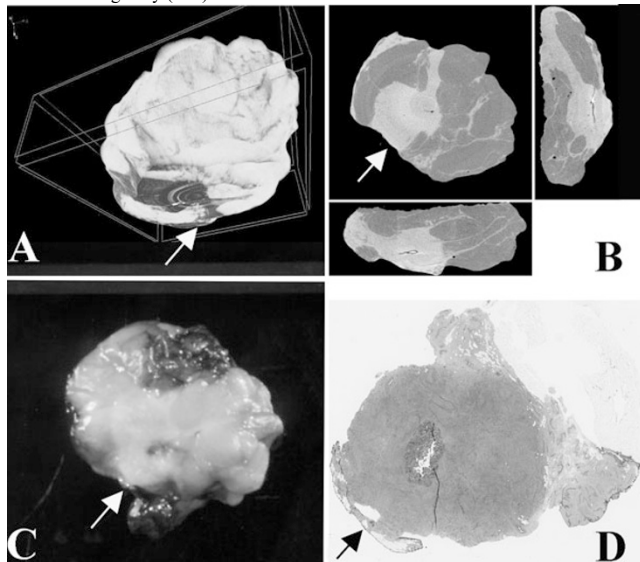
149 Breast Excision Specimens Evaluated by Micro-Computed Tomography (Micro-CT) with Histopathological Correlations

LJ Fernandez, JM Buckley, OP Afreth, R Tang, M Saksena, Y Yagi, JS Michaelson, FC Koerner, EF Brachtel, BL Smith. Massachusetts General Hospital, Boston.

Background: Breast conserving surgery is standard of care in the treatment of breast cancer. Re-excision is required in 25-40% to provide negative margins on permanent histopathological evaluation. Improved methods to intraoperatively determine margin involvement by carcinoma would be desirable. In this study, we explore a novel method of imaging excision specimens by micro-CT for rapid visualization of the removed mass and its relationship to the margins.

Design: Fourteen breast excision specimens for breast cancer from 13 consented female patients were evaluated with a table top micro-computed tomography scanner (micro-CT), Skyscan@1173 (Skyscan, Belgium). Scanning took <15 minutes, followed by routine histopathological processing and reporting. Micro-CT images of the excision specimens were evaluated for mass size and relation to margins. Whole slide images of the histologic slides were obtained by Nanozoomer 2.0-HT® (Hamamatsu LTD, Japan).

Results: Average mass size was 1.9cm by micro-CT (range 0.9-3.5cm) and 1.3cm on pathology (range 0-2.2cm). Margins were positive/ \leq 0.1cm in 86% (n=12) by micro-CT and 64% by histology (n=9). Margins were free (\geq 0.2 cm) in 7% by micro-CT (n=1) and 14% (n=2) by histopathology. Additional shaved margins (not evaluated by micro-CT) were negative in 71% (n=10). Tumors consisted of 12 invasive ductal carcinomas (IDC), 1 invasive lobular carcinoma and 1 healing biopsy site with mass-like appearance on micro-CT but no residual carcinoma. 57% showed ductal carcinoma in-situ histologically (n=8).



IDC with mass at margin (\rightarrow) by micro-CT (A,B), macroscopically (C) and histologically on whole slide image (D).

Conclusions: In this small pilot study, tumor size was slightly overestimated by micro-CT compared to pathology. Specimen margins were more often considered involved by tumor on micro-CT than confirmed histologically. Densely fibrous lesions, even if they do not contain tumor cells histologically, may be difficult to distinguish from tumor on micro-CT. Analysis of a larger cohort is necessary to determine predictive value of micro-CT assessment for breast excisions.

150 Breast Angiosarcoma: A Clinicopathologic Study

AV Florea, DJ Dabbs, S Beriwal, R Bhargava. Jewish General Hospital/McGill University, Montreal, Canada; Magee-Womens Hospital/University of Pittsburgh Medical Center, Pittsburgh.

Background: Angiosarcoma of the breast is a rare disease where histologic grade is considered prognostic. Angiosarcomas can be divided into primary (de novo) and secondary (secondary to radiation treatment for prior breast carcinoma). The objective was to determine clinicopathologic factors associated with primary and secondary breast angiosarcoma.

Design: All cases of breast angiosarcoma diagnosed at our institution from 1996 to 2011 were identified. Clinicopathologic factors were reviewed. Characteristics of primary and secondary angiosarcoma were compared.

Results: A total of 35 cases were identified. Seven were primary and 22 were secondary angiosarcoma. Six cases (all consults) could not be classified due to lack of clinical information. The median age of primary angiosarcoma patients was slightly lower than that of secondary angiosarcoma-60 years versus 71 years, but the difference was not statistically significant. Primary angiosarcomas were less often high grade compared to secondary angiosarcomas (43% versus 90%; $p=0.0239$). No statistical difference was noted in tumor size between primary and secondary angiosarcoma. Median time

from radiation to secondary angiosarcoma diagnosis was 7 years. One of 7 primary angiosarcoma patients received chemotherapy. Chemotherapy information was available on 18 secondary angiosarcoma cases of which only 2 received chemotherapy. The 2 secondary angiosarcoma patients that received chemotherapy still recurred within one year of diagnosis. Five-year disease free survival (DFS) for primary and secondary angiosarcoma was 43% and 56%, respectively ($p=0.6728$). Five year overall survival (OS) rate for primary and secondary angiosarcoma was 71% and 56%, respectively ($p=0.6592$). The five year DFS and OS was also not statistically significant between low grade and high grade angiosarcomas, regardless of the primary/secondary status.

Conclusions: Secondary angiosarcomas are more common than primary tumors. Secondary angiosarcoma cases are more often high grade compared to primary angiosarcoma but that does not seem to affect the DFS or OS. Oncologists infrequently use chemotherapy for angiosarcoma due to lack of effective regimens. Breast angiosarcoma is an aggressive disease for which novel therapeutic approaches are required.

151 Clinical and Pathological Characteristics of Her2 Positive Mucinous Carcinomas: The First Assessment of a Contradictory Lesion

C Flynn, FA Tavassoli, N Buza. Yale University School of Medicine, New Haven, CT.

Background: Mucinous carcinoma of the breast is considered a low-grade tumor with a favorable prognosis. A majority of the cases are positive for estrogen receptor (ER) and progesterone receptor (PR) immunostains, but negative for human epidermal growth factor receptor 2 (Her2). However, a small proportion of mucinous carcinomas may overexpress Her2 and manifest a more aggressive clinical course. This study was initiated to assess the prevalence and the clinicopathological significance of Her2 expression among mucinous breast carcinomas.

Design: All mucinous carcinomas (pure and mixed) of the breast diagnosed at our institution between January 2002 and August 2011 were included in the study. All available hematoxylin and eosin (H&E) stained and immunohistochemical slides were reviewed and the clinical information was obtained from the electronic medical records. The ER, PR, and Her2 status was evaluated according to the current CAP/ASCO guidelines.

Results: During this period, 168 mucinous breast carcinomas were available for study. Sixteen cases (9.5%) showed Her2 overexpression and/or amplification by immunohistochemistry or fluorescent in situ hybridization (FISH). The patients in the Her2 positive group were younger (mean age: 51; range 36-69) than those in the Her2 negative group (mean age 65; range 24-95). The average tumor size measured 3.9 cm in the Her2 positive group compared to 1.9 cm in the Her2 negative group. The majority of the Her2 positive tumors were moderately (60%) or poorly (33.3%) differentiated, whereas over 57% of the Her2 negative tumors fell in the well-differentiated category. Interestingly, 2% of well-differentiated mucinous breast carcinomas showed Her2 overexpression. Over two thirds of Her2 positive tumors also showed ER and PR expression (triple positives), while none of the Her2 negative cases were negative for both hormonal markers. Her2 positive tumors had a higher rate of axillary lymph node metastases (30%) than the Her2 negative tumors (21%).

Conclusions: Our data demonstrate that a significant subset of mucinous breast carcinomas shows Her2 overexpression/amplification. These tumors occur in a younger patient population, have a larger tumor size, higher histologic grade, and the majority of them are triple positive.

152 Comparison of HER-2 and Hormone Receptor (HR) Status between Primary Breast Cancer and Corresponding Distant Metastatic Sites with Double Check Assessment

I Frahm, S Sarancone, G Acosta Haab, V Caceres. Sanatorio Mater Dei, Buenos Aires, Argentina; Laboratorio Quantum, Rosario, Argentina; Instituto Maria Curie, Buenos Aires, Argentina; Productos Roche, Buenos Aires, Argentina.

Background: Although the vast majority of breast cancer carcinoma maintains the same biological features at relapse, recent studies suggested that some lesions may have a change in HER2 and HR status during tumor progression. As such, it may be advisable to biopsy metastatic disease for optimal treatment planning

Aim: to compare HER2 and HR status of metastatic breast cancer with those of the original tumor with simultaneously double check assessment to reduce analytical procedures errors.

Design: From December 2008 to September 2011, 137 patients with biopsy proven relapses were identified. HER-2 analysis was performed in both primary and metastasis material. Results were interpreted as ASCO/CAP guideline's. Discordant cases were evaluated by fluorescence *in situ* hybridization (FISH) too. ER and PR were also screened by IHC analyses.

Results: 137 primary breast cancer tumors and their corresponding distant metastasis were analyzed. Among paired primary/metastatic tumors, we found 18 discordant cases, 10 in ER or PR, and 7 in HER 2 showed discordance by IHC and FISH.

Results are summarized in Table 1.

Table 1: Discordant cases with double check assessment

Primary	ER	PR	HER2	Metastatic site	ER	PR	HER2
1	+	+	0	cervical node	+	-	0
2	+	+	0	pleura	+	-	0
3	+	+	0	lung	+	-	0
4	+	+	0	pleura	-	-	0
5	+	+	0	ovary	-	+	0
6	+	+	0	peritoneum	-	-	0
7	+	-	0	bone	+	+	0
8	+	+	0	skin	-	-	0
9	-	-	1	supraclavicular node	-	-	2
10	+	+	1	supraclavicular node	+	+	3
11	+	+	2	liver	+	+	0
12	+	-	0	liver	-	-	3
13	+	-	3	bone	-	-	0
14	+	+	1	liver	+	+	3
15	+	+	1	pleura	+	+	3
16	+	+	1	bone	-	-	1
17	+	+	1	bone	+	+	3
18	+	+	1	cervical node	+	-	1

Conclusions: 18/137 (13%) of relapsed tumors had changes in HER2 or ER/PR status, with double check evaluation. The tendency showed a lost in HR and a gain in HER 2 positivity. This study suggests that biopsies of relapsed/metastatic breast cancers should be performed, in concordance with largest series recommendations previously published.

153 The University of Kentucky Model for Selecting Breast Cancer Patients for Oncotype DX Testing

S Frame, M Burge, N Miller, Y Brill, R Matnani, P McGrath, M-L Fjallskog, LM Samayoa. University of Kentucky, Lexington, KY; VAMC, Lexington, KY; Uppsala University, Uppsala, Sweden.

Background: Currently, the decision on treatment of Estrogen Receptor (ER) (+), Her2-neu (-), N0-1a patients is largely supported by molecular tests such as Oncotype DX. While the benefits of this test are indisputable, the guidelines for ordering it are non-specific and may lead to over-utilization at a significant cost. This study presents a model for Oncotype DX testing, based on common morphologic (H&E) and Immunohistochemical (IHC) variables already established in our daily practices.

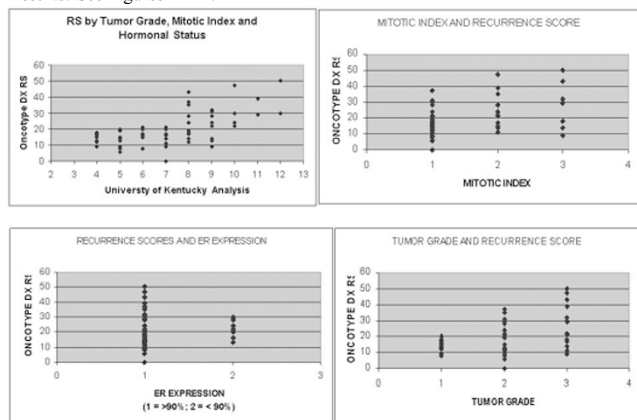
Design: Recurrence Scores (RS) from 72 randomly selected N0 patients were compared to levels (%) of ER, Progesterone Receptors (PR), Ki-67, Cyclin A, Mitotic Index (MI) and Tumor Grade (TG) using univariate regression analyses. Although no one variable showed a significant R value, the ones that correlated the most were selected and given a numerical score according to cut-off levels either previously described (MI and TG) or encountered while performing the analyses (ER and PR) (see table 1). Subsequently, all patients were scored accordingly and paired with their corresponding RS.

University of Kentucky Model for Oncotype DX testing

	1	2	3	4	5
ER expression % >90		<90			
PR expression % 90 - 100		70 - 90	30 - 70	1 - 30	0
Mitotic Index*	I	II	III		
Tumor Grade*	I	2	3		

Based on the modified combined Bloom Richardson Score

Results: See Figures 1A-D.



Conclusions: Although limited by the number of patients and depending on individual practices, results from this study suggest that only patients with scores of 8 and 9 will benefit from Oncotype DX. Patients with scores of 4-7 and > 10 will probably not benefit from the test since their RS are predictable to be low (< 21) and high (>25) respectively. In addition, RS of < 10 were not found in patients with tumors showing <90% ER (+), MI > 1 and in grade III tumors. These observations indicate that the model may be useful even after the results from the TAILOR X trial become available.

154 Significance of Src Activation Status in Trastuzumab Response in HER2-Positive Breast Carcinoma

A Gallardo, E Lerma, F Ortiz-Martinez, E Adrover, A Tibau, A Barnadas, D Giner, FI Aranda, FJ Gutierrez-Avino, G Peiro. Hospital de la Santa Creu i Sant Pau, Autonomous University of Barcelona, Barcelona, Spain; Hospital General Universitario, Alicante, Spain.

Background: Src kinase plays an important role in cell growth and differentiation. Recently, its phosphorylation has been suggested being related with the HER2 family receptors. Little is known about the correlation between the degree of this kinase activation and the response to Trastuzumab. Therefore, we investigated the activation status of Src kinase and its correlation with several biomarkers in a cohort of HER2-positive breast carcinoma (BC) patients treated with Trastuzumab.

Design: From a series of 155 BC patients treated with Trastuzumab, we selected 95 patients: 36 with this drug in the initial treatment, 51 in the metastatic disease and 8 patients where this was not precised. Patients. We examined immunohistochemically the phosphorylation status of Src (Tyr416) and p44/42 MAPK (Thr202/Tyr204), ER, PR, HER2, IGF1R (alpha), and p27 on paraffin-embedded tissue microarrays. Markers expression was assessed combining intensity and percentage of positive cells (score 0-300): for pSrc-416 and pMAPK (positive cut-off ≥150), IGF1R (cut-off ≥220) or in the nuclei for p27 (cut-off =20%). Correlations between IHC results, clinicopathological factors and prognosis were analyzed.

Results: Active pSrc-416 was seen in 28% (27/95) tumors in association with positive lymph node status (83%; p=0.041) and metastasis to the central nervous system (33%; p=0.12), but no correlation with other clinical-pathological data was found. Further, a positive correlation was observed between pSrc with pMAPK activation (35%; p=0.036), p27 (70%; p=0.013) or IGF1R overexpression (22%; p=0.13), and no association was seen for ER/PR (21%; p=ns). Survival analysis (Kaplan-Meier) showed only in the group of patients with first line Trastuzumab treatment, that increased active pSrc-416 was associated with poor overall survival (25% vs. 4%; p=0.02); and a trend toward shorter disease free survival (25% vs 7%; p=0.074).

Conclusions: Our results suggest that increased Src kinase activity is involved in promoting Trastuzumab resistance in combination with MAPK and IGF1R, in a subset of primary HER2-positive BC. Therefore, blocking this axis may prevent the development of Trastuzumab resistance in those patients.

155 Clinical Outcome of Intracystic and Solid Papillary Carcinomas of the Breast

RG Gamez, S Narendra, A Nassar. Mayo Clinic, Rochester, MN.

Background: Papillary carcinoma (PC) of the breast accounts for 0.5 to 1% of breast cancer. The localized form of PC encompasses both the intracystic/encysted (IPC) and solid (SPC) variants, which are typically circumscribed and often encapsulated (separated from the surrounding mammary stroma by a fibrous capsule) and lack myoepithelial layer at their periphery. Hence the term encapsulated PC (EPC) has been introduced. IPC is usually confined to a dilated cystic space and is surrounded by a fibrous capsule. Compared to IPC, SPC is typically solid, characterized by mucin production and neuroendocrine features, and is more often multinodular. IPC and SPD have long been regarded as a form of in-situ carcinoma but the observation of the absence of a myoepithelial cells at the tumor stromal interface has led to the proposal that these lesions are, in fact, invasive carcinomas with an expansile growth pattern. This concept is supported by the results of some studies which reported cases of axillary nodal or distant metastases. The purpose of our study is to assess the clinical features, behavior and outcome of IPC and SPC in our population in regards to its clinical outcome in order to better understand the pathophysiology of these lesions.

Design: All cases of IPC and SPC were retrieved using SnoMed search from 1994 to 2011. The clinical-pathologic features including post-surgical treatment and outcome (recurrence, metastasis and death) were investigated and recorded. Descriptive and inferential analysis was performed.

Results: See Table 1.

Variables	IPC (21)	SPC (12)
Median age (mean)	68.7 (70.3)	72.2 (69.9)
Histologic grade	100 % low grade	91.7% low grade, 8.3% immediate grade
Mean tumor size (range)	1.4 cm (0.5- 2.5 cm)	1.8 cm (0.6 - 4.3)
Associated DCIS	38.1% (8/21)	25%(3/12)
Invasive ductal carcinoma IDC	33.3% (7/21)	50.0% (6/12)
Lymph node (LN) status (positive)	0.09% (1/11)	0.12% (1/8)
Recurrence	0.05% (1/21)	0
Mean folow up time (years)	4.2 (0-11)	1.5 (0.1-5.4)
Metastasis or death of disease	None	None

Conclusions: These lesions tend to occur in older women. Almost one third of the cases were accompanied by DCIS or IDC. Only patients with invasive disease developed LN metastasis, however recurrence is very rare and so its distant metastasis. As previously reported, these patients had excellent survival.

156 Sonic Hedgehog (Shh) and Patched-1 (PTCH1) Protein Expression in Invasive Mammary Carcinoma; (PTCH1) Protein Expression Independently Predicts Outcome

J Garbaini, K-A Kim, C Sheehan, A Boguniewicz, J Ross. Albany Medical College, Albany, NY.

Background: Shh signaling regulates PTCH1 expression in the organization of embryonic development and may play a critical role in mammary gland morphogenesis and cancer development. Aberrant expression of Shh and PTCH1 result in abnormal growth of mammary ducts, but have not been linked to clinical outcome in invasive mammary cancer.

Design: Formalin-fixed, paraffin-embedded tissue sections of 175 invasive mammary carcinomas, including 125 ductal carcinomas (IDC) and 50 lobular carcinomas (ILC), were immunostained by automated methods (Ventana Medical Systems Inc., Tucson, AZ) using goat polyclonal Shh (sc-1194) and rabbit polyclonal PTCH1 (sc-9016) (Santa Cruz Biotech, Santa Cruz, CA) antibodies. Cytoplasmic immunoreactivity was semiquantitatively scored based on staining intensity and distribution and the results were correlated with morphologic and prognostic variables.

Results: Cytoplasmic Shh overexpression was observed in 94/175 (54%) of invasive carcinomas. Shh overexpression correlated with high tumor grade [70% grade III vs 45% grade II vs 48% grade I, $p=0.035$], advanced stage (65% advanced vs 46% early, $p=0.02$), positive lymph node status (60% node positive vs 44% node negative, $p=0.047$), and disease recurrence (67% recurrent vs 50% non-recurrent, $p=0.045$). Cytoplasmic PTCH1 overexpression was observed in 138/175 (79%) of invasive carcinomas. PTCH1 overexpression correlated with high tumor grade [95% grade III vs 76% grade II vs 78% grade I, $p=0.033$] and disease free survival (90% recurrent vs 75% non-recurrent, $p=0.036$). On multivariate analysis, advanced stage ($p=0.000$), ER negative status ($p=0.004$), and PTCH1 overexpression ($p=0.021$) were independent predictors of disease-free survival; while advanced stage was an independent predictor of overall survival ($p<0.0001$).

Conclusions: Shh and PTCH1 expression are associated with adverse clinicopathologic parameters in invasive mammary cancer with PTCH1 expression found to be an independent predictor of disease-free survival. Further study of the hedgehog pathway in breast cancer appears warranted.

157 Molecular Evidence in Support of the Neoplastic and Precursor Nature of Microglandular Adenosis

FC Geyer, M Lacroix-Triki, P-E Colombo, N Patani, A Gauthier, R Natrajan, MB Lambros, I Khalifeh, C Albarracin, S Orru, C Marchio, A Sapino, A Mackay, B Weigelt, FC Schmitt, J Wesseling, N Sneige, JS Reis-Filho. Hospital Israelita Albert Einstein, Sao Paulo, Brazil; Institut Claudius Regaud, Toulouse, France; CRCL Val d'Aurelle, Montpellier, France; The Institute of Cancer Research, London, United Kingdom; Institut Curie, Paris, France; The American University of Beirut Medical Center, Beirut, Lebanon; The University of Texas MD Anderson Cancer Centre, Houston; Ospedale A. Busino, Cagliari, Italy; University of Turin, Turin, Italy; Cancer Research UK London Research Institute, London, United Kingdom; Institute of Molecular Pathology and Immunology (IPATIMUP), Oporto, Portugal; Netherlands Cancer Institute, Amsterdam, Netherlands.

Background: Microglandular adenosis (MGA) is a proliferative breast lesion associated with hormone receptor- and human epidermal growth factor receptor 2- (HER2) negative (i.e. triple-negative phenotype) invasive carcinomas. Previous studies have demonstrated that MGA may be a clonal proliferation and precursor of triple-negative breast cancers. The aim of this study was to determine whether MGAs harbour genetic alterations similar to those found in matched invasive carcinomas.

Design: A series of 12 cases composed of MGA and/ or atypical MGA (AMGA), ten associated with invasive carcinoma, was retrieved. Expression of oestrogen (ER) and progesterone (PR) receptors, HER2, S100, cytokeratin (CK) 8/18, high molecular weight CKs and EGFR was investigated using immunohistochemistry. The morphologically distinct components of each case (MGA, AMGA and/ or invasive carcinoma) were microdissected and subjected to high-resolution microarray-based comparative genomic hybridisation.

Results: Immunohistochemical profiling revealed that all invasive carcinomas were of triple-negative phenotype and expressed S100, cytokeratins 8/18 and 'basal' markers. Apart from three typical MGAs, including one not associated with breast cancer, all samples analysed were found to harbour gene copy number aberrations, demonstrating the clonal nature of the majority of MGAs. Copy number changes were detected on average in 20.3% (median 15.0%, range 0.5-61.9%) of the genome, indicating varying levels of genetic instability. In three cases, MGA/AMGA displayed copy number aberrations similar to those found in matched invasive components (Pearson $r \geq 0.67$, $p < 0.05$).

Conclusions: Our results provide circumstantial evidence that MGA was the substrate for invasive carcinoma development and support the contention that MGA can be a clonal lesion and a non-obligate precursor of triple-negative breast cancer.

158 Histological Evaluation of the Papillary Lesions of the Breast from Needle Biopsy to the Excised Specimen: A Single Institutional Experience

SM Gilani, RS Tashjian, PJ Kowalski. St. John Hospital & Medical Center, Detroit, MI.

Background: The assessment and categorization of papillary lesions remains one of the most challenging areas in breast pathology. In this review, we evaluated the histological follow up of papillary lesions of the breast starting from the needle core biopsy until the final excision. The main focus of this study was to determine that papillary lesions of the breast warrant strong consideration for excision, regardless whether a benign, atypical, or malignant diagnosis is made on biopsy.

Design: After IRB approval, we reviewed the reports of patients diagnosed as papillary lesion on needle core biopsy from January 2001 to June 2011. A total of 91 cases were diagnosed as "papillary lesion" including benign, atypical and malignant on the needle core biopsy.

Results: A total of 29 cases (females mean age of 54.93 ± 12.5 SD) of breast needle core biopsies with the diagnosis of benign papillary lesion were viewed. Of these 29 cases, 19 (65.5%) cases were diagnosed as a benign on final excision, 3 (10.3%) cases were diagnosed as malignant, and the remaining 7 cases did not proceed to excision. The three malignant cases included two cases of ductal carcinoma ins-situ with micropapillary features and one lobular carcinoma ins-situ.

Of these 91 cases, 45 cases were diagnosed as malignant, with 44 cases (97.6%) malignant and 1 case ADH. The diagnosis of atypical papillary lesion was determined in

17 cases: 10 malignant, 5 atypical ductal hyperplasia, and 2 benign on the final excision. When comparing the combination of all atypical and malignant cases with both needle core biopsy and excisional biopsy (other than those having benign diagnosis) to the initial needle core biopsy findings, the differences were more striking ($p=0.019$). Of these 62 cases (mean age of 61.98 ± 15.20 SD), only 2 cases were diagnosed benign on final excision. Overall for the 91 cases, 21 (23.1%) were benign and 62 cases (68.1%) were atypical or malignant on the final excision.

Conclusions: We concluded that if benign papillary lesion is present on needle core biopsy then the chances of malignancy are high (10.3%, p -value < 0.0005) on the final excision, therefore we suggest excision of all papillary lesions. Similarly, malignant papillary lesions on needle core biopsy should always be excised due to the likelihood of (98%) malignancy on final excision. Based on our study we suggest removal of any type of papillary lesion diagnosed on needle core biopsy.

159 GATA-3 Expression in Male and Female Breast Cancers: Comparison of Clinicopathologic Parameters and Outcome

RS Gonzalez, J Wang, H Sullivan, A Adams, C Cohen. Emory University, Atlanta, GA.

Background: GATA-3 is a transcription factor that regulates lineage determination in breast epithelium. Its expression in female breast cancers has been linked to the expression of estrogen receptor (ER) and in turn to improved outcomes. However, GATA-3 has not been studied in male breast cancers.

Design: Nineteen male breast carcinomas (average age: 63 years) and 164 female breast carcinomas (average age: 57 years) were immunostained for GATA-3. Results were compared to age, tumor size, nodal and distant metastases, and positivity for ER, progesterone receptor (PR), and HER2. Nuclear staining for GATA-3 in 10% of cells was considered positive. Follow-up was obtained.

Results: Male cancers expressed GATA-3 less often than female cancers (32% vs. 82%, $p < 0.001$). Men with GATA-3-positive cancer were older than men with GATA-3-negative cancer (Table 1) and women with GATA-3-positive cancer (70 years vs. 57 years, $p=0.005$). Female grade 1 and 2 cancers were almost all GATA-3 positive, but only 52% of grade 3 cancers were positive ($p < 0.001$); no such correlation was seen in men. Unlike female cancers, male cancers showed no correlation between GATA-3 positivity and ER positivity, PR positivity, or distant metastases. While rates of metastasis and ER/PR positivity were similar in male and female GATA-3-positive cancers, male GATA-3-positive cancers were more often HER2-positive (33% vs. 4%, $p=0.029$) and larger (2.9 cm vs. 1.6 cm, $p=0.004$). Seventeen (89%) men were alive at follow-up (average: 61 months); only one, a 58-year-old with GATA-3-negative cancer, died of disease.

Characteristics of GATA-3-positive vs. GATA-3-negative Cancers

	GATA-3+	GATA-3-	p-value
M, avg. age	70 years	60 years	0.038
F, avg. age	57 years	58 years	0.821
M, avg. size	2.9 cm	2.0 cm	0.068
F, avg. size	1.6 cm	1.9 cm	0.250
M, grade 1/2/3	50%/17%/33%	9%/27%/64%	0.182
F, grade 1/2/3	30%/52%/18%	3%/21%/76%	<0.001
M, node mets	1/6 (17%)	6/11 (55%)	0.304
F, node mets	20/129 (16%)	8/28 (29%)	0.160
M, distant mets	0/5 (0%)	5/11 (45%)	0.119
F, distant mets	2/133 (2%)	5/21 (24%)	0.001
M, ER+	6/6 (100%)	12/13 (92%)	1.000
F, ER+	125/134 (93%)	2/29 (7%)	<0.001
M, PR+	4/6 (67%)	9/13 (69%)	1.000
F, PR+	109/133 (82%)	2/29 (7%)	<0.001
M, HER2+	2/6 (33%)	5/13 (38%)	1.000
F, HER2+	5/135 (4%)	1/29 (3%)	1.000

Conclusions: GATA-3 is expressed less often in male than female breast cancers and is seen in older patients. Male cancers show no correlation between GATA-3 positivity and ER positivity, PR positivity, or distant metastases. There may be no link between GATA-3 positivity and survival in men, whereas in women, GATA-3-positive tumors are typically lower-grade with a reportedly better prognosis.

160 Reduced or Loss of ER and PR Receptor Expression in Metastatic Breast Cancer

R Gupta, C Tornos, M Singh, B O'Hea, J Liu. Stony Brook University Medical Center, Stony Brook, NY.

Background: ER and PR expression in metastatic/recurrent breast cancer can be used to confirm the origin of the tumor and determine the use of hormonal therapy.

Design: A computer search for metastatic breast cancer cases was performed from January 1998 to September 2011. The ER and PR profile of these metastases was compared to the profile of the primary breast tumor. Sixty two metastases had available ER and PR status information in both the primary tumor and the metastases. We selected the cases that have differences of 50% or more with regard to either ER or PR expression between the primary and metastatic tumors, and the cases where the ER or PR expression in the metastatic tumors decreased to 0% from any level of expression in the primary tumors. Seven cases meet the criteria.

Results: In 55 of the 62 cases (88.7%), the ER and PR profiles have differences of less than 50% or no differences at all. In seven of the 62 cases (11.2%), the differences are significant ($>50%$). ER expression is reduced in 3 cases; PR expression is reduced in 4 cases (Table).

Differential ER and PR expression in Metastatic Breast Cancer

Metastatic Foci	ER (%) of Metastasis	PR (%) of Metastasis	Time between Primary and Met	Primary ER (%)	Primary PR (%)	Difference in ER (%)	Difference in PR (%)
Liver	95	0	7 yrs	90	80	+5%	-80%
Femoral reamings	46	8	2 yrs	80	90	-34%	-82%
Rectum	20	0	1 yr	90	0	-70%	0%
Liver	0	0	1 yr	1	80	-1%	-80%
Upper eyelid and orbicularis muscle	30	0	2 yrs	90	5-30	-60%	-5-30%
Femoral condyle	0	0	8 yrs	90	10	-90%	-10%
Liver	Positive	4	5 yrs	80	80		-76%

Conclusions: The ER and PR expression in distant metastatic sites significantly changes in 11% of our cases, showing decreased expression of one or both of the receptors. Before using hormonal therapy to treat distant metastases, ER and PR receptor profiles should be quantitatively reassessed in the metastases and compared to the primary breast cancer. Furthermore, the differences in receptor profiles could affect the histologic identification of metastatic tumors and the response to additional hormonal therapy. Although the mechanism is still unknown, the differences between the hormone receptor expression profiles of the metastases and primary breast cancers may be due to a wide spectrum of possibilities, ranging from the intrinsic biological properties of the cancer cells to the secondary effects of treatment (cell selection versus down-regulation).

161 High Grade Lobular Carcinoma In Situ in Breast Excision: Potential for Misdiagnosis as Solid Type DCIS or Classical LCIS

F Habib, S Syriac, D Wang, S Liu, R Karabakhstian, D Tan, T Khoury. Roswell Park Cancer Institute, Buffalo, NY; University of Kentucky, Lexington, KY; MD Anderson Cancer Center, Houston, TX.

Background: Differentiating ductal carcinoma in situ (DCIS) and classical lobular carcinoma in situ (C-LCIS) from high grade lobular carcinoma in situ (HG-LCIS) on excisional biopsy has important clinical implications. The purpose of this study was to determine the frequency of misdiagnosing HG-LCIS as DCIS or C-LCIS, and compare the difference in risk of mammary or non-mammary cancer between HG-LCIS and C-LCIS.

Design: All mammary carcinoma in-situ (MCIS) cases (from 1995 to 2010) reported as solid type DCIS (n=69), HG-LCIS (n=4) and C-LCIS (n=37) were reviewed and reclassified according to WHO classification. LCIS was graded using 2-tier grading system, as classical (grade 1 and 2) or high grade (pleomorphic, signet ring, necrotic, macro-acinar and mixed). E-cadherin immunostain was performed on all cases. The staining was graded from 0+ to 3+. Complete negative staining in addition to lobular carcinoma (LC) morphology was considered for the designation of LCIS phenotype. Equivocal staining (1+) was considered for the designation of undetermined MCIS. Cases with LC cells involving DCIS were designated as mixed MCIS. Key clinicopathological data were abstracted for all LCIS cases. Fisher's exact test was used for statistical analysis.

Results: Pure solid type DCIS was seen in 36 cases. There were a total of 13 HG-LCIS cases, 9 (69.2%) of which were misdiagnosed [3 of 39 (7.7%) reported C-LCIS and 6 of 36 (16.7%) reported pure solid type DCIS]. There were 2 cases of mixed MCIS and 2 undetermined MCIS. The median age of patients with HG-LCIS and C-LCIS was 56 (range 40-80) and 51 (range 42-79) years, respectively. HG-LCIS carries higher risk for non-mammary cancer than C-LCIS [4 of 12 (33.3%) vs. 1 of 32 (3.1%) respectively, p=0.02], while both processes have similar risk for mammary cancer. No statistically significant difference was seen between these groups with relation to menopausal status, race, or family history.

Conclusions: 1) Misdiagnosing HG-LCIS as C-LCIS or DCIS is not uncommon. 2) E-cadherin should be performed on any solid type MCIS to accurately differentiate between LCIS and DCIS. 3) In addition, proper grading for LCIS is important, as the HG type carries higher risk for developing non-mammary cancer compared to the classical type.

162 Glycolytic Phenotype is Correlated with Aggressiveness and Worse Prognosis in Invasive Ductal Carcinomas

H Han, SM Jang, K-S Jang, YJ Jun, YN Oh, MS Chung, SS Paik. College of Medicine, Hanyang University, Seoul, Korea.

Background: Glucose uptake and glycolytic metabolism are enhanced in cancer cells and increased expression of GLUT1 has been reported in human malignancies. The aim of this study was to investigate GLUT1 expression in human breast tissues and its correlation with various clinicopathological parameters, as well as its effect on patient survival in invasive ductal carcinomas.

Design: We used tissue microarrays consisting of normal breast tissue (18 cases), ductal hyperplasia (14 cases), ductal carcinoma in situ (55 cases), invasive ductal carcinoma (276 cases), and lymph node metastasis (58 cases). Immunohistochemistry was used and review of medical records and clinicopathological analysis were performed.

Results: Membranous GLUT1 expression was observed in normal and tumor cells. GLUT1 expression was markedly increased in ductal carcinoma in situ, invasive ductal carcinoma, and lymph node metastasis than normal and ductal hyperplasia. In invasive ductal carcinomas, 106 (38.4%) of 276 cases showed GLUT1 expression. GLUT1 expression was correlated with higher histologic grade (p<0.001), larger tumor size (p=0.025), absence of estrogen receptor (p<0.001), absence of progesterone receptor (p<0.001), and triple-negative phenotype (p<0.001). In univariate survival analysis, patients with GLUT1 expression revealed poorer overall survival and disease-free survival (p=0.017 and p=0.021, respectively, log-rank test). In multivariate survival analysis with the Cox proportional hazards model, GLUT1 expression was an independent prognostic factor of overall survival and disease-free survival (p=0.017 and p=0.019, respectively).

Conclusions: Our results demonstrated that GLUT1 expression may play an important role in the malignant transformation and a glycolytic phenotype can be a marker of aggressive biologic behavior and a worse prognostic factor in invasive ductal carcinomas.

163 Dietary Stearate Is an Effective Complementary Agent to Paclitaxel in Reducing the Incidence and Tumor Burden of Breast Cancer Lung Metastasis

RW Hardy, G Rezonzew, X Zhao, R Desmond, GP Siegal. University of Alabama at Birmingham, Birmingham, AL.

Background: Stearate is an 18-carbon saturated fatty acid found in meat and chocolate that has been shown to have anti-breast cancer properties in terms of preventing carcinogenesis and reducing tumor burdens. However dietary stearate per se does not reduce the incidence of metastasis. Paclitaxel (PTX) is a chemotherapeutic agent commonly used to treat breast cancer which has a mechanism of action that is different from that of stearate. Our hypothesis is that dietary stearate when combined with PTX will work additively or synergistically to reduce the incidence of breast cancer metastasis in a mouse model.

Design: Four diets were used in our experimental design: control (low fat) diet (5% corn oil), safflower diet (20% safflower oil), corn oil diet (17% corn oil/3% safflower oil) and stearate diet (17% stearate/3% safflower oil), n=25-30 mice per group. Diets were initiated 3 weeks prior to the injection of breast cancer cells. Female athymic nude mice were injected with 1x10⁶ MDA-MB-435 human breast cancer cells in their mammary fat pad. The primary tumor grew to 1cm³, were removed and the mice were treated paclitaxel (20 mg/kg, IP) weekly for 3 weeks at which time the mice were sacrificed and lung tumors assessed.

Results: PTX alone decreased the incidence of lung metastasis by 50% when combined with the control diet. However dietary stearate combined with PTX significantly reduced lung metastasis another 28% (p<0.05) compared to both the control and corn oil diets. Thus the combination of dietary stearate plus PTX reduced the incidence of lung metastasis to 22% in a mouse model that has virtually a 100% incidence of lung metastasis when untreated. In addition dietary stearate reduced lung metastasis tumor burden in those mice that did develop lung metastasis (p<0.01) compared to the control diet.

Conclusions: Dietary stearate increased the effectiveness of PTX chemotherapy to prevent the incidence of lung metastasis and reduce metastasis tumor burden. Future studies will test whether using dietary stearate with chemotherapy can reduce the effective dose of PTX and thereby potentially reduce the serious side effects associated with taxanes.

164 Detection of Short Forms of HER2 in FFPE Specimens in Breast Cancer: Biological Significance and Impact on Patient Care

J Huang. Medical College of Wisconsin, Milwaukee, WI.

Background: Studies from others have demonstrated that short forms of HER2 are strongly associated with poor outcome and trastuzumab resistance in breast cancer. However, the detection of such short forms of HER2 in formalin-fixed, paraffin-embedded (FFPE) specimens has not yet been established in routine clinical practice. In this study we evaluated the expression levels of HER2 in breast cancer and then explored whether the short forms of HER2 could be detected by IHC. Finally, we explored whether the short forms of HER2 could potentially activate Akt and MAPK signaling pathways and promote tumor cell proliferation in breast cancer.

Design: A TMA made up of 284 FFPE specimens with invasive breast carcinomas was utilized in this study. HER2 was examined by IHC with antibodies to A0485, SP3, CB11 and 4B5. HER2 gene amplification was analyzed with chromogenic in situ hybridization (CISH) in all cases. The expressions of short forms of HER2 were confirmed by western blot (WB). The expression of P-Akt, P-MAPK and Ki67 were also examined by IHC.

Results: Of 284 cases examined by IHC, 49 (17%), 54 (19%), 89 (31%) and 114 (40%) were HER2-positive with SP3, 4B5, CB11 and A0485, respectively. 68 of 284 cases (24%) evaluated by CISH showed HER2 gene amplification. The concordance between CISH and IHC was 47 (96%), 52(96%), 58(65%) and 65(57%) with antibodies for SP3, 4B5, CB11 and A0485, respectively. Short forms of HER2 ranging from 95 to 110 KD were detected by WB with A0485 in 58 of 65 cases (89%), which were both HER2-positive with A0485 and HER2-negative with SP3 by IHC. P-Akt and P-MAPK were strongly increased in the cases with short forms of HER2 compared with the ones without short forms of HER2 (P<0.001). The proliferation index (Ki67) was higher in the cases with short forms of HER2 than those without the short forms of HER2 (P<0.01).

Conclusions: The data indicates that the expression of HER2 examined by IHC with different anti-HER2 antibodies is variable in breast cancer. The short forms of HER2 were detected by IHC with A0485 and confirmed by WB. These short forms might activate intercellular signaling pathways, such as Akt and MAPK which might promote tumor cell proliferation in breast cancer. The data suggests that a combination of anti-HER2 antibodies that includes A0485 should be utilized in routine clinical practice for assessment of the short forms.

165 EGFR Gene Amplification and Protein Expression in Invasive Ductal Carcinoma of Breast

W Hwangbo, S Ahn, J Lee, S Kim, C Kim, I Kim. Korea University Anam Hospital, Seoul, Korea.

Background: The expression of epidermal growth factor receptor (EGFR) is used as marker for basal-like breast cancer, but it has been recently suggested that EGFR can be a target of breast cancer treatment.

Design: Between September 2005 and July 2011, 691 invasive ductal carcinomas of breast were diagnosed and immunophenotyped according to the expression of ER, PR,

Her-2, EGFR, c-kit and CK5/6. The expression of EGFR was scored using same criteria as for Her-2 expression. Eighty-two cases (13 1+ expression, 42 2+ expression and 27 3+ expression) were studied for gene expression using FISH technique.

Results: EGFR expression. Results: EGFR expression 2+ and 3+ was found in 76 of 691 cases (11%), and 18 cases co-expressed Her-2, 47 cases with other basal markers, and 11 cases expressed only EGFR. In amplification study, one of 13 EGFR 1+ cases (8%), 5 of 42 EGFR 2+ cases (12%), and 7 of 27 EGFR 3+ cases (26%). The EGFR gene amplification was seen in 5 of 16 (31%) Her-2-co-expression group, 2 of 12 (17%), EGFR only expression group and 6 of 54 (11%) basal-like group.

Conclusions: This study showed EGFR expression was associated with gene amplification in certain proportion of the breast cancers. Further study should be followed to determine the benefit of EGFR-directed therapy as well as to evaluate the clinical outcome of Her-2 and EGFR co-expressing patients.

166 Role of Beta-Catenin as a Mediator in the sFRP1-Induced Wnt Signaling and Epithelial-to-Mesenchymal Transition in Triple Negative Breast Cancer

J Iqbal, AA Thike, PH Tan, MM Thu. Singapore General Hospital, Singapore.

Background: Triple negative breast cancers (TNBC) are defined by the absence of estrogen receptor (ER), progesterone receptor (PR) and C-erbB2 expression. Oncologic managements options are limited in this group of patients. The Wnt/beta-catenin pathway has been implicated in epithelial-to-mesenchymal transition (EMT); inappropriate activation of the Wnt/beta-catenin signaling leads to the development of several human cancers, including breast cancer. Secreted frizzled-related protein 1 (sFRP1) which antagonizes this pathway is frequently lost in breast tumors. Beta-catenin has been implicated in the sustainment of EMT-associated stem-cell like traits. The goal of this study was to investigate possible interactions of the Wnt signaling pathway and EMT in TNBC.

Design: Immunohistochemistry was performed on paraffin-embedded tumor tissue of a consecutive cohort of 115 female patients with TNBC diagnosed between 2005 to 2007. Antibodies to sFRP1, beta-catenin, cyclin D1, E-cadherin and vimentin were applied to sections cut from tissue microarray blocks, using the streptavidin-biotin method. Intensity and proportion of tumor cells stained were assessed. Follow-up information was obtained from case notes. Disease free survival (DFS) and overall survival (OS) were defined as time from diagnosis to recurrence or death respectively. Associations between sFRP1, beta-catenin, cyclin D1, E-cadherin and vimentin expression with clinicopathological parameters, DFS and OS were evaluated using H-score. A p value of <0.05 defined statistical significance.

Results: Loss of E-cadherin (61%) and sFRP1 (65%) was seen in majority of cases with increased expression of vimentin (28%) and cyclin D1 (81%) associated with aberrant (cytoplasmic) expression of beta-catenin (82%). Both sFRP1 and E-cadherin loss was correlated with aberrant beta-catenin expression (p=0.001). Significantly, beta-catenin loss was associated with poor DFS. E-cadherin and sFRP1 deficient cases showed poor OS. Similarly, poor OS was seen in cases with vimentin upregulation.

Conclusions: These results show that in TNBC, (1) sFRP1 suppression leads to oncogenic activation of WNT pathway via cytoplasmic accumulation of beta-catenin (2) Beta-catenin is important in the cross-talk between canonical wnt signalling and EMT pathway indicating that loss of sFRP1 modulates EMT pathway, mediated by E-cadherin loss and/or vimentin acquisition. (3) E-cadherin down-regulation appears to be associated with Wnt activation via beta-catenin and may be used as a prognostic marker to predict poor survival in a subgroup of TNBC.

167 Axillary Recurrence of Breast Carcinoma

S Jaffer, C Nagi, A Nayak, R Guarino, IJ Bleiweiss. The Mount Sinai Medical Center, New York, NY.

Background: Recent trials suggest that sentinel lymph node (SLN) alone provides staging information and adequate locoregional control in early stage breast cancer, with a low risk of axillary recurrence. To evaluate this, we retrospectively examined all our axillary recurrences to examine the incidence and predisposing factors.

Design: Using the pathology computerized data base (2001-2011), out of 2670 breast cancers, we identified 13 axillary recurrences. We reviewed the clinical and pathologic information on all cases.

Results: The age of the patients ranges from 35 to 86 years (average = 57.5 years). All patients underwent mastectomy, with the exception of 2 lumpectomies. Ten patients received chemotherapy, neoadjuvant in 2. The carcinomas ranged in size from 0.9cm to 3cm (average = 2.2cm) and were multifocal in 3. By morphology they were ductal (8), lobular (1) or mixed (4). Of the ductal carcinomas, 4 were micropapillary, 2 were mucinous, and 1 anaplastic. All the lobular carcinomas were pleomorphic type. Nine cases were hormone receptor positive; of the remaining 4, 3 were Her2 positive. All cases had associated high grade DCIS, (extensive in 3 cases) and lymphatic invasion. Some of the data predated the SLN era, such that this practice was observed in only 6 cases. In the remaining 7 cases, 1-20 (ave = 9) axillary lymph nodes were excised showing complete replacement with extranodal extension in 2 cases. Of the 6 SLN biopsies, 4 were replaced by metastatic carcinoma, 2 of which also had replaced axillary lymph nodes. The 2 cases with negative SLN also had negative axillary lymph nodes. Both cases were mixed type measuring 3.5 and 2.3cm. The larger one was also multifocal and the patient was not treated with chemotherapy. In the 2nd case, the patient initially declined chemotherapy for a period of 12mos. In all cases, the recurrences ranged from 2 to 7 years (average = 4 years) after the primary, all of which showed bulky disease in the axilla with extranodal disease.

Conclusions: Axillary recurrence is a rare phenomenon (0.4%), directly influenced by previous disease burden in the axilla as seen in 11 out of 13 of our cases with bulky disease. It is even more rare in patients with no evidence of disease in the axilla as seen in 2 cases with both negative SLN and axillary lymph nodes. These 2 cases probably

recurred due to delayed and absent chemotherapy. Given these low recurrence rates, we would agree with the current recommendation of not excising axillary lymph nodes in patients with negative SLN and possibly with limited metastatic disease as well.

168 Cytokeratin Positive Cells in Sentinel Lymph Nodes of pT1a Breast Cancers

S Jaffer, C Nagi, A Nayak, R Guarino, IJ Bleiweiss. The Mount Sinai Medical Center, New York, NY.

Background: It is known that in the setting of intraductal carcinoma (DCIS), particularly involved by intraductal papilloma, one must be cautious in interpreting cytokeratin positive (CK+) cells in the sentinel lymph node (SLN) since they may represent displaced epithelial cells rather than true metastases. Given the low rates of metastases in pT1a invasive carcinomas, we evaluated the effect of this phenomenon on staging.

Design: Using the computerized pathology database, we identified and reviewed the morphology and serially performed immunohistochemistry (ihc) in 35 pT1a breast carcinomas with SLN containing single and clustered CK+ cells.

Results: The CK+ cells were present as single cells and or clusters present in the subcapsular sinuses. We were able to classify the SLN findings as positive = 11 cases, negative = 11 and undetermined significance = 13. In the negative cases, in comparison to the primary, all the CK+ cells were uniform and lacked atypia, appeared papillary (2), and was accompanied by reactive changes such as giant cells (3). In the corresponding breast tissue, there was either displacement (10) and or an intraductal papilloma (11). All the primaries except 1 were estrogen receptor (ER) positive, in contrast to the CK+ cells which were ER negative. The ER negative tumor was Her2 positive but the CK+ cells were Her2 negative. In 1 invasive lobular case, we also took advantage of the E-cadherin stain which was negative in the primary but positive in the CK+ cohesive cells. In the positive cases, the CK+ cells showed similar atypical features with the primary. Only 1 case showed displacement, and 3 showed lymphatic invasion. It was utilized in 2 cases showing similar ER positivity in both the primary and the CK+ cells. In the undetermined cases, the problem lay in the small number of single cells for comparison with the primary and further ihc study. In 1 case the primary showed heterogenous ER positivity which made interpretation of the ER negative cells in the SLN difficult. In another case the primary was ER positive but the CK+ cells although negative, appeared morphologically highly atypical.

Conclusions: Given the low rates of metastases in pT1a breast carcinomas, the identification of CK+ single and clustered cells in SLN should be resolved by morphology and or ihc whenever possible to prevent upstaging. Factors predictive of SLN positivity included multifocality and lymphatic invasion, and for negativity, the presence of displacement and or intraductal papilloma, while tumor size was not relevant.

169 Internal Impact of ACOSOG Z0011 at a Tertiary Academic Center

D Jaggessar Singh, B Harmon, B O'Hea, P Farrelly, R Christine, T Carmen, M Singh. Stony Brook University Medical Center, Stony Brook, NY.

Background: The ACOSOG Z011 trial in women with T1/T2 breast cancer with up to 3 positive sentinel nodes treated with lumpectomy followed by systemic therapy found no significant loco-regional, overall or disease free survival differences when patients underwent SLNB alone vs. SLNB and complete axillary node dissection (ALND). One conclusion of the study was that in this selected patient group frozen section is unnecessary since they will not undergo immediate ALND. Our study aimed to determine the impact of this trial on the practice of 4 sub-specialized breast surgeons at our institution, a Tertiary Academic Center.

Design: Our computer database found all breast surgery cases with SLNB done at our institution in the 6 months prior to publication of the trial results (9/1/10-2/28/11) and the 6 months after (3/1/11-9/1/11). The number of cases, number of SLNs sent as non-frozen vs. frozen specimens, and surgeons who performed each case were analyzed for both periods. Cases were stratified by surgeon to analyze whether the differences in surgical practice were surgeon dependent.

Results: There were 102 cases performed before the publication which included 279 SLNs, and 106 cases done after which included 339 SLNs. The proportion of lymph nodes sent non-frozen vs. frozen was greater in the 6 months after the publication: 1.4% vs 17.7% (p value of <0.0001). SLNBs were sent more frequently as non-frozen specimens by 2 out of 4 surgeons post trial. Prior to the publication, these two surgeons submitted 3 out of 150 (2%) SLNs as non-frozen while afterwards they submitted 60 out of 179 (33.5%) (p value of <0.0001). The remaining 2 surgeons showed no alteration in practice submitting 1 out of 129 (<1%) non-frozen SLNs pre-trial and 0 out of 160 (0%) non-frozen SLNs post-trial.

Conclusions:

Table 1: # of SLNs sent non-frozen v. frozen before ACOSOG Z011 data by individual surgeons

	Surgeon 1	Surgeon 2	Surgeon 3	Surgeon 4	Total
Non-Frozen SLN	3	0	1	0	4 (1.4%)
Frozen SLN	117	30	76	52	275 (98.6%)
Total	120	30	77	52	279

Table 2: # of SLNs sent non-frozen v. frozen after ACOSOG Z011 data by individual surgeons

	Surgeon 1	Surgeon 2	Surgeon 3	Surgeon 4	Total
Non-Frozen SLN	50	10	0	0	60 (17.7%)
Frozen SLN	88	31	77	83	279 (82.3%)
Total	138	41	77	83	339

The ACOSOG Z011 trial has impacted the surgical practice and treatment of breast cancer patients in some academic institutions. At our institution there has been a dramatic increase and trend towards non-frozen rather than frozen SLNBs, although there still remains individual variability among surgeons.

170 Androgen Receptor Expression in Vascular Neoplasms of the Breast

R Jain, P Bitterman, i Lamzabi, VB Reddy, p Gattuso. Rush University Medical Center, Chicago, IL.

Background: Androgen receptors (AR) have been reported to be present in normal breast tissue and breast carcinomas. However, there is no literature regarding expression of AR in vascular breast neoplasms. The following study is undertaken to assess the expression of AR in a subgroup of vascular neoplasms of the breast.

Design: All patients with histologically diagnosed hemangioma, angiolipoma and angiosarcoma of the breast were retrieved from the clinical and pathology database at our institution. The H & E slides were reviewed and immunohistochemical stain for AR (Dako, clone AR441) was performed on paraffin embedded tissue. Any amount of nuclear staining was considered positive. The intensity of staining was graded from 1+ to 3+; 3+ being brightness comparable to positive control. An estimate of the percent of lesional cells staining was made.

Results: There were a total of 32 cases: 10 hemangiomas, 20 angiolipomas and 2 angiosarcomas. Male to female ratio was 1:3.5. The average age at presentation for men was 45 years and for women 56.9 years. AR expression was present in stromal and fat cell nuclei of the angiolipomas, and stromal cells of hemangiomas and angiosarcomas. Interestingly, normal duct epithelium of the breast was positive in 7 out of 24 females and none in males. The pathologic, clinical and immunohistochemical data are summarized in Table 1.

Table 1: Summary of clinic-pathologic and immunohistochemical data

	Positive	1+	2+	3+	% cells staining	Size range / Average size (cm)	Negative
Hemangioma	5/8 (62.5%)	3/8 (37.5%)	2/8 (25%)	0	5-20	0.1-0.9 / F: 0.4; M: 0.7	3/8 (37.5%)
Angiolipoma	11/20 (55%)	8/20 (40%)	2/20 (10%)	1/20 (5%)	5-20	F: 0.2-2.2; M: 0.8-2.7 / F: 1.1; M: 1.7	9/20 (45%)
Angiosarcoma	2/2 (100%)	2/2 (100%)	0	0	5-30	9 and 1.2	0

Conclusions: 1. Androgen expression was present in 62.5% of hemangiomas, 55% of angiolipomas and 100% of angiosarcomas.

2. The majority of the tumors showed a low intensity nuclear expression of androgens, 1+ intensity in 13 cases, with 2+ intensity seen in 2 cases and only one case of angiolipoma showed 3+ expression.

3. All positive cases of angiolipoma (55%) showed AR in adipocytes and stromal cells.

4. Since AR have been reported to be present in human adipocytes and preadipocytes, it is possible that the cell of origin of angiolipoma is a preadipocyte.

5. The expression of AR in hemangioma and angiosarcoma of the breast needs to be further investigated.

171 ZNF217 and FGFR1 Amplification in the Progression of In Situ to Invasive Breast Carcinoma

M Jang, EJ Kim, Y Choi, HE Lee, SY Park. Seoul National University College of Medicine, Seoul, Republic of Korea; Seoul National University Hospital, Seoul, Republic of Korea; Seoul National University Bundang Hospital, Seongnam, Republic of Korea.

Background: Gene amplification is an important mechanism for activation of oncogene in malignant tumors. Although amplification of HER2, C-MYC, CCND1, FGFR1 and ZNF217 has been described in breast cancers, their role in the progression of in situ to invasive breast carcinoma has been rarely studied. To investigate their role in the progression of breast cancer, we compared the amplification frequency of these genes in pure ductal carcinoma in situ (DCIS), DCIS associated with invasive carcinoma and invasive carcinoma.

Design: We performed fluorescence in situ hybridization of the selected genes on tissue microarrays composed of 175 pure DCIS and 208 DCIS associated with invasive carcinoma and 427 invasive carcinomas. For the cases of DCIS associated with invasive carcinoma, we compared gene amplification status of intraductal and invasive components in the individual patients.

Results: Amplification rate of ZNF217 and FGFR1 was significantly higher in invasive carcinoma than in pure DCIS (ZNF217, 9.4% vs. 3.5%, $p=0.015$; FGFR1, 11.8% vs. 6.0%, $p=0.035$). On the contrary, HER2 gene amplification was more frequently found in pure DCIS compared to invasive carcinoma (20.0% vs. 31.4%, $p=0.002$). ZNF217 amplification rate was also significantly higher in DCIS associated with invasive carcinoma than in pure DCIS (ZNF217, 11.9% vs. 3.5%, $p=0.003$). Overall, gene amplification frequency of all genes in invasive carcinoma and DCIS associated with invasive carcinoma did not differ significantly. Comparing matched invasive and DCIS components in 208 cases, HER2, C-MYC, CCND1, and ZNF217 amplification status was concordant in most cases. However, FGFR1 amplification was increased in the invasive component ($p=0.031$). In survival analyses, FGFR1 amplification was associated with decreased disease free survival in the patients with invasive carcinoma ($p=0.003$).

Conclusions: Our study revealed that DCIS associated with invasive carcinoma is similar to invasive carcinoma in terms of gene amplification of analyzed genes. However, our data also showed significant difference of ZNF217 and FGFR1 amplification between pure DCIS and invasive carcinoma and FGFR1 amplification between invasive and DCIS components of the same tumor, and the association of FGFR1 amplification with patients' prognosis, suggesting the role of ZNF217 and FGFR1 amplification in the breast cancer progression including tumor invasion.

172 Toluidine Blue – Formalin Mixture: A Useful Tool To Enhance Detection of Benign and Malignant Breast Lesions for Gross Submission of Breast Specimens

Z Jlayer, Y-A Tseng, E Selbs, GK Turi. Winthrop University Hospital, Mineola, NY.

Background: Submission of breast tissue for pathologic evaluation currently relies on both visual and palpation findings and radiographic images without knowledge of where mammary epithelium lies in the breast. A more optimal method for detection of breast epithelial lesions could utilize a supravital stain applied to breast specimens that identifies where terminal duct lobular units (TDLU) and their pathologic alterations are within breast tissue. We studied the utility of a toluidine blue – formalin mixture (TB-FM) for enhanced identification of pathologic breast lesions.

Design: 115 cases were studied, most of which were excisional biopsies. Fresh breast specimens were serially sliced at 3 – 5 mm thickness, and fixed at room temperature for 3 hours in TB-FM. TB-FM was prepared fresh for each case, by using 1 cc of 1% toluidine blue per 200 cc of neutral buffered formalin (NBF). After 3 hours fixation in TB-FM, breast specimen slices were photographed. The entire breast specimen was submitted for histologic evaluation for all cases. TB-FM stained breasts show dark blue dots which highlight mammary epithelium and proliferative lesions against white to light blue stroma. Blue dots from TB-FM specimen photographs were correlated with H & E stained sections for each blue stained area.

Results: TB-FM identified all benign epithelial proliferations, regardless of their nature, and all DCIS and LCIS lesions greater than 1mm. The size of the TB-FM stained areas correlated well in proportion to lesion size and cellularity. There were 70 benign lesions, 18 carcinoma in situ (9 DCIS, 9 LCIS), 25 invasive ductal carcinomas, 1 invasive lobular carcinoma, and 1 atypical ductal hyperplasia. The size ranges of epithelial proliferations identified by TB-FM staining were as follows: benign proliferations including fibroadenoma (0.1- 3.1 cm), carcinoma in situ, mostly DCIS (0.1-10 cm), and invasive carcinoma (0.1-5.5 cm).

Conclusions: TB-FM non-specifically stains all foci in the breast where increased cells per unit area occur. TB-FM identifies normal breast epithelium, ductal and lobular proliferations greater than 1 mm, and all invasive carcinomas, including pT1a and pT1b stages. This novel technique, although non-specific, is a highly sensitive method which enhances the gross detection of important breast pathologic alterations.

173 A Panel of Cytokeratin (CK) 5/6, p63 and Smooth Muscle Myosin (SMMS) Immunostain Improves Diagnostic Accuracy of Papillary Lesions of the Breast Diagnosed on Core Needle Biopsy (CNB)

S Kandukuri, K Astvatsaturyan, S Bose. Cedars-Sinai Medical Center, Los Angeles, CA.

Background: Histopathologic evaluation of papillary lesions (PL) of the breast on CNB is challenging with greater than 20% rate of under diagnosis of atypia or malignancy. Thus complete excision is the standard of care. An accurate core biopsy diagnosis of the final pathology would allow appropriate management of patients. Various immunostains are being tested as surrogate markers to improve diagnostic concordance. Our study evaluates the diagnostic accuracy of a panel of three immunostains in PL of the breast.

Design: From 1998 to 2011, all departmental cases diagnosed as PL of the breast on CNB with follow up excisions were reviewed. CNB's containing only pure papillary lesions were included. Immunostaining (IHC) was performed using a dual cocktail of p63 (brown nuclear reaction product) and SMMS (red cytoplasmic stain) and CK5/6 on consecutive sections of selected blocks. IHC were evaluated without knowledge of original and final diagnoses. PLs showing uniform, diffuse positivity with all three markers were diagnosed as benign; those with diffuse negative staining were diagnosed as malignant while those showing patchy staining with focal areas of negativity were diagnosed as atypical.

Results: The study included 34 cases, 11 of which were benign, 4 atypical and 19 malignant on excision. The original CNB diagnoses were benign in 19, atypical in 9 and malignant in 6. Four of the malignant cases were interpreted as benign and 9 as atypical on CNB. Additionally the 4 cases with atypical final diagnosis were interpreted as benign on CNB. Concordance was observed in 17 of 34 cases (50%). After IHC, the predicted diagnoses were 15 benign, 9 atypical and 10 malignant. The remaining 9 cases with malignant final diagnosis were diagnosed as atypical (n=8) and benign (n=1). The four atypical cases were interpreted as atypical (n=1) and benign (n=3). The overall concordance after immunostaining improved to 65%. Of the 19 malignant PL, 10 were diagnosed as malignant after IHC and 8 as atypical. There was one false negative case.

Conclusions: - Immunostaining of CNB of breast with PLs improves concordance with excision diagnosis.

- PL diagnosed as atypical after IHC require excision.

- PL diagnosed as benign after IHC may be followed up after careful consideration of clinical features.

174 Occult Involvement of Nipple by Malignancy Occurs in 14% of Therapeutic Nipple-Sparing Mastectomies

RE Kaplan, SA Hoda. New York Presbyterian Hospital/Weill Cornell Medical College, New York, NY.

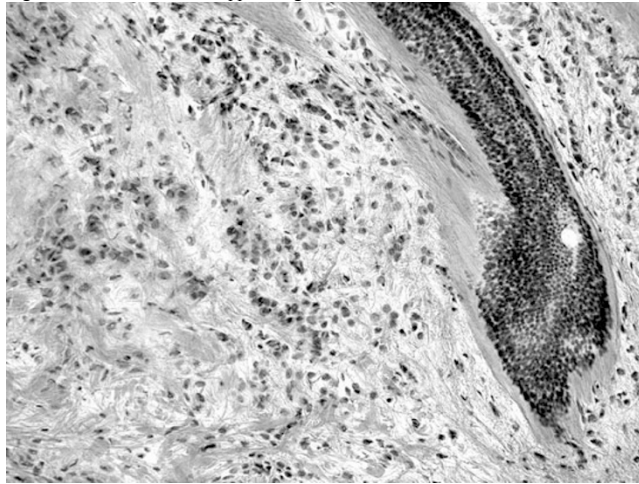
Background: Nipple-Sparing Mastectomy (NSM) is an increasingly utilized surgical option in managing breast carcinoma (ca); however, data on malignant involvement of nipple margin, a finding of obvious surgical and clinical significance, are scant.

Design: Consecutive NSM specimens, including those performed for therapeutic (Th-NSM) and prophylactic (Pr-NSM) purposes, over a 4-year period (2007-to date), were studied. A separately submitted retro-areolar cross-sectional "true" nipple margin (NM) was evaluated via frozen section examination (FSE) whenever requested, and by permanent H&E-stained preparations.

Results: 325 consecutive NSM specimens, including 208 (64%) Th-NSM and 117 (36%) Pr-NSM, were studied. All nipples were clinically unremarkable. 86% (179/208) of NM

from Th-NSM, and 100% (117/117) of NM from Pr-NSM showed no histopathological abnormality. 14% (29/208) of NM in Th-NSM and 0% (0/117) of NM in Pr-NSM showed malignancy. NM in Th-NSM showed ductal ca in situ (DCIS) in 16/208 (8%) cases, lobular ca in situ (LCIS) in 5/208 (2%), invasive ductal ca in 4/208 (2%), invasive lobular ca (Figure 1) in 4/208 (2%). FSE was requested in 187 of 325 TNM (58%) with a sensitivity of 64% and specificity of 99% (false-negative: 9, false-positive: 1). Tumor size, grade, estrogen receptor status, HER2 status, lymphovascular involvement, and lymph node involvement were not associated with malignancy in NM ($p > 0.05$). Complete nipple resection (CNR), status-post NSM, was performed in 69% (20/29) of positive NM cases. 5 cases with LCIS in NM, status-post NSM, did not have CNR. Residual malignancy in CNR was found in 55% (11/20, including 3 cases of invasive ca). **Conclusions:** In this series, 14% (29/208) of nipples from Th-NSM specimens showed occult malignancy, and the most common malignancy in nipple margin was DCIS (8%). No nipple from Pr-NSM (0/117) showed malignancy. FSE of nipple (a test with high specificity and low sensitivity) is important, since no routine pathological parameter is predictive of nipple margin involvement.

Figure 1: Frozen section of nipple margin with invasive lobular carcinoma.



175 Systematic Identification of Prognostic Biological Pathways in Breast Cancer Molecular Subtypes

J Kaplan, S Schmitt, D Koller, AH Beck. Beth Israel Deaconess Medical Center, Boston; Stanford University, Palo Alto.

Background: Breast cancer is a heterogeneous disease with distinct molecular subtypes including luminal A, luminal B, HER2, and basal-like types. Biological pathways driving breast cancer progression within molecular subtypes are incompletely understood. An improved understanding of subtype-specific pathways will facilitate the identification of new prognostic biomarkers and specific therapeutic targets.

Design: We analyzed eleven publically available breast cancer genome-wide expression profiling datasets with associated recurrence/disease free survival data (total samples = 2123) to identify prognostic biologic pathways within breast cancer molecular subtypes. For each dataset, we assigned each sample to a molecular subtype using the PAM50 subtype predictor. We then rank-normalized the expression value of each gene across patients of each molecular subtype for each data set. We pooled the rank-normalized expression values for patients of a subtype across the eleven data sets to create four new meta-data sets containing rank-normalized values for patients from one of the four molecular subtypes. These values were used to compute every gene's univariate association with survival separately within the four subtypes. After performing univariate survival analyses, we performed gene set enrichment analysis (GSEA) separately on the four lists of gene survival statistics to identify biologic pathways significantly associated with prognosis in the molecular subtypes.

Results: Proliferation-associated pathways were most strongly associated with poor survival in ER+ breast cancer (in both luminal A and luminal B subtypes). Conversely, proliferation-associated pathways were associated with improved prognosis in the molecular HER2 type. Extracellular-matrix remodeling-associated pathways were significantly associated with poor prognosis in ER- breast cancer (both HER2 and basal-like groups). In luminal B, HER2, and basal-like subtypes, inflammation-related pathways were associated with improved survival (all FWER $p < 0.05$).

Conclusions: The results of this study show that diverse biological pathways are associated with prognosis in breast cancer molecular subtypes. These results provide new insights into the pathways that drive tumor progression within molecular breast cancer subtypes and this, in turn, may lead to the development of novel subtype-specific prognostic markers and therapeutic targets. Future studies will evaluate the relationship of these subtype-specific pathways with chemotherapy response.

176 Imaging and Pathology Discrepancies in Lymph Node Evaluation of Mammary Carcinoma

M Kasami, T Uematsu, T Oichi, M Abe. Shizuoka Cancer Center, Nagaizumi, Shizuoka, Japan.

Background: Rapid advances in imaging and molecular diagnosis have raised questions about the value of TNM staging, especially in mammary carcinoma. However, as one of the important prognostic factors and as determining factors for systemic adjuvant therapy, pathologic examination of lymph nodes is recommended.

Design: From 2002 to 2007, 649 cases of mammary invasive carcinoma were classified as N0 (Clinically negative lymph nodes) by using MRI and/or CT in our hospital. We compared 151 cases with pathologically positive lymph nodes (fN0) in N0 and 498 cases with pathologically negative lymph nodes (pN0) in N0, regarding the size of primary invasive carcinoma, histologic grade, ER, Her-2, fibrosis, multiplicity and extensive intraductal component (EIC, defined more than 50mm in the greatest extent). **Results:** The average patient age was 56 years in both groups. Invasive lobular carcinoma was diagnosed in 9 patients (6% of fN0 patients and in 24 of pN0 patients. The histologic grade 3 was diagnosed in 37 of fN0 patients and in 120 of pN0 patients. The size of metastases was averaged 4.2mm (range 0.3-12.0mm) in fN0 which was subdivided in pNmi(n=47cases), pN1a(n=93), pN1b(n=1), pN2(n=7) and pN3(n=3). There were 9 deaths in pN0 cases and 2 of fN0 cases (median follow up period: 75 months) and 10 cases were died of hematogenous metastases. No significant survival differences were detected between pN0 and fN0 cases by Kaplan Meier Method. Table 1 shows the results.

Table 1. Comparison of fN0 and pN0 cases

case and control	multiplicity	size(ave) ♦	≥ T2	fibrosis	ER+	Her-2:3+	EIC
fN0	35.8 %	19.2 mm	34.3 %	44.4 %	90.1 %	8.6 %	15.9 %
pN0	22.3 %	15.9mm	21.7 %	23.6 %	81.1 %	11.4 %	17.3 %
p value	<0.001	0.0001	0.0001	<0.0001	0.01	0.325	0.693

PearsonX² but Mann-Whitney ♦, fN0:false positive N0, ave:average

Conclusions: Multiplicity, large size, ER positivity and fibrosis were related in positive lymph nodes. However, microscopic disease in the lymph nodes of mammary carcinoma could not be considered a prognostic factor in comparison with imaging diagnosis in this study. For long term survival analysis, further studies are required.

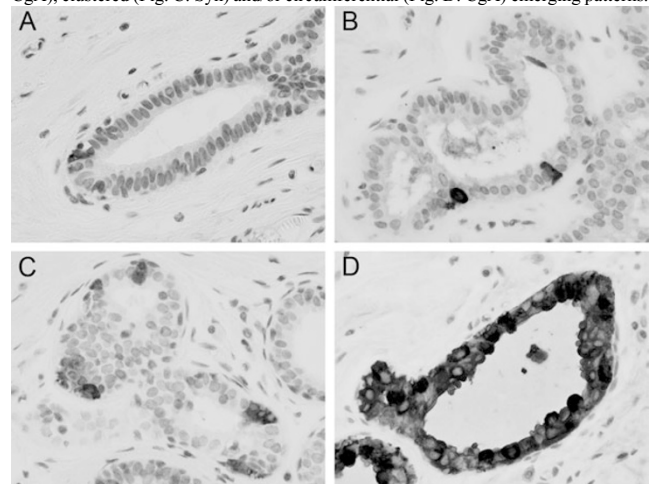
177 Neuroendocrine Cell Hyperplasia of the Breast – Potential Precancerous Lesion of Mammary Neuroendocrine Carcinoma

T Kawasaki, K Mochizuki, T Kondo, H Yamauchi, S Inoue, M Inoue, N Oishi, T Yamane, T Nakazawa, D Niu, K Nakazawa, Y Ishii, T Yuminamochi, H Yagata, H Tsunoda, H Onishi, H Fujii, R Katoh. University of Yamanashi, Yamanashi, Japan; St. Luke's International Hospital, Tokyo, Japan.

Background: The World Health Organization (WHO) classifies breast neuroendocrine carcinoma (B-NEC), defined as >50% neoplastic cells expressing specific NE markers, as a special tumor entity representing only about 2-5% of mammary cancers. However, the natural history of B-NEC and the mechanisms underlying its development have yet to be sufficiently analyzed and established.

Design: To clarify the presence of a precursor lesion of B-NEC, we investigated 32 totally-resected mammary tissues with a B-NEC using an immunohistochemical technique with primary antibodies against chromogranin A (CgA) and synaptophysin (Syn). Thirty-two mastectomy specimens harboring a mammary non-NE carcinoma were also examined in the same fashion.

Results: The 32 B-NECs were histologically subclassified into NE ductal carcinoma *in situ* (NE-DCIS) (7 cases, 22%), solid NEC (16 cases, 50%), mucinous NEC (3 cases, 9%), small cell NEC (1 case, 3%) and large cell NEC (5 cases, 16%). NE cell hyperplasia, demonstrated by immunohistochemistry for CgA and/or Syn, was widely identified in background mammary ducts and lobules of the 7 B-NECs (22%): 3 NE-DCISs and 4 solid NECs. NE cell hyperplasia showed isolated (Fig. A: Syn), scattered (Fig. B: CgA), clustered (Fig. C: Syn) and/or circumferential (Fig. D: CgA) emerging patterns.



These NE cells were morphologically polygonal, ovoid or columnar with faintly fine-granular cytoplasm and round-to-oval nuclei without atypism. With the exception of a clustered pattern, NE cells were not readily recognizable by hematoxylin and eosin staining. Furthermore, 4 of 7 cases with NE cell hyperplasia had multifocal B-NEC. In contrast, 32 non-NE carcinomas had no NE cells in the cancer lesion background.

Conclusions: This report is the first to describe NE cell hyperplasia which could be regarded as a precancerous lesion closely related to the malignant progression of B-NEC. A background of extensive NE cell hyperplasia should be taken into consideration when treating B-NEC.

178 Neuroendocrine Carcinoma (NEC) of the Breast – Clinicopathological Study of 90 NEC Cases in Conjunction with 1505 Non-NEC Cases

T Kawasaki, K Mochizuki, T Kondo, H Yamauchi, S Inoue, M Inoue, N Oishi, T Yamane, T Nakazawa, D Niu, H Yagata, H Tsunoda, H Onishi, H Fujii, R Katoh. University of Yamanashi, Yamanashi, Japan; St. Luke's International Hospital, Tokyo, Japan.

Background: The World Health Organization (WHO) classifies mammary neuroendocrine carcinoma (NEC), defined as >50% neoplastic cells expressing specific NE markers (i.e. chromogranin A and/or synaptophysin), as a special tumor entity representing only about 2-5% of breast cancers. However, its biological behavior and prognosis are still controversial.

Design: To clarify clinical significance and biological characteristics, 90 NECs of the breast were investigated and the clinicopathological findings compared with those of 1505 non-NECs.

Results: NECs accounted for 5.6% of all breast carcinomas in our study, and the mean patient age was 53.9 years. Pathological features of NECs included low nuclear grade (71%), earlier disease stage, absence of lymphatic permeation (70%), absence of coagulation necrosis (76%), absence of calcification (51%), weak inflammatory reaction (82%), estrogen receptor positivity (97%), progesterone receptor positivity (88%) and low HER2 score ($P < 0.05$). The characteristic histological architecture of NECs was a predominantly solid growth of cancer cells ($P < 0.05$) and a highly-vascular fibrovascular stroma. Cancer cells were polygonal or occasionally spindle-shaped with relatively well-developed, fine-granular cytoplasm and round to ovoid nuclei with fine and/or granular chromatin. Mucin production was occasionally seen. Ten cases (11%) had NEC recurrences and 6 (7%) died due to the tumor (mean 72 months post surgery). The recurrent NECs in these 10 cases were characterized pathologically by high nuclear grade (70%), pT2-4 (90%), axillary lymph node metastasis (80%) and lymphatic involvement (80%). Distant metastases of NECs usually affected the liver and bone (70%). The main cause of death was liver failure (83%) due to liver metastasis. Preoperative neoadjuvant chemotherapy was performed in six NEC cases; a mild therapeutic effect was obtained in five cases and no effect in one.

Conclusions: NECs of the breast had distinctive clinicopathological features, with most constituting a low-grade tumor group. However, recurrence and/or distant metastasis were more common in cases with high-grade breast NECs and this tumor group would, therefore, need more aggressive and/or novel therapeutic approaches.

179 Breast Pathology Second Review Identifies Clinically Significant Discrepancies in 10% of Cases

L Khazai, LP Middleton, N Goktepe, BT Liu, AA Sahin. MD Anderson Cancer Center, Houston, TX.

Background: It has been common practice at our tertiary care referral center to review the pathology materials of referred patients. To assess the relevance of this process in this era of cost containment, we compared the original pathology reports with the second-review reports issued at our institution. Our secondary objective was to assess compliance with College of American Pathologists (CAP) recommendations regarding inclusion of scientifically validated data elements (SVDE) in pathology reports.

Design: We performed a retrospective study of all 1970 consecutive breast pathology referrals cases during the calendar year 2010. The variables studied were histologic classification, tumor grade, necrosis, size, margin status, lymphatic/vascular invasion, dermal involvement, and immunohistochemical (IHC) profile (ER, PR and Her-2). Each variable was rated as agree, disagree, missing information or not applicable.

Results: A significant discrepancy, defined as a disagreement that affected patient care, was found in 200 cases (10%). In 336 cases (17%) some CAP-required information was missing. The most common areas of discrepancy were clinically significant histologic categorization (67 cases; 33%) and biomarker reporting (50 cases; 25%). In the histologic category, diagnoses were up-graded in 33 cases (20 in-situ lesions, 3 carcinomas misinterpreted as benign, and 2 missed lymph node metastases resulting in a change in tumor stage). The most problematic diagnostic categories included intraductal lesions, lobular carcinoma, metaplastic carcinomas and phyllodes tumors. Most disagreements in the IHC-profile category were interpretive. In addition, in 20% of discrepant cases, findings were confirmed by repeat IHC analysis performed at our institution. Fluorescent In-Situ Hybridization (FISH) studies performed at our institution supported the changes in interpretation in 2 of 4 cases.

Conclusions: Our results confirm the value and utility of obtaining a second opinion in a referral center setting in order to provide optimal patient care, and highlight the challenging nature of certain diagnostic categories in breast pathology and the need to obtain second opinions in such cases. Our results also support the use of second review to ensure inclusion of CAP-required SVDEs in pathology reports.

180 Distinguishing Metastatic Neuroendocrine Tumors to the Breast from Primary Invasive Mammary Carcinomas with Neuroendocrine Differentiation

S Kim, SK Mohanty, RB Mertens, S Bose, LJ Jih, D Dhall. Cedars-Sinai Medicine, Los Angeles, CA.

Background: Metastatic neuroendocrine tumors (MNETs) to the breast can show histologic overlap with invasive mammary carcinoma (IMC) and may be misdiagnosed as such, with undesirable consequences, since the management of the two conditions is completely different. This study was undertaken to characterize the histologic features and immunohistochemical (IHC) profile of MNETs to the breast and primary IMC with neuroendocrine differentiation (NED) and to determine whether IHC is helpful in distinguishing these two diagnostic entities.

Design: The anatomic pathology database of our institution was searched from January 2005 to July 2011 for MNETs to the breast and primary IMCs with NED. The histopathologic features, IHC profile (ER, PR, Her-2/neu, and Ki-67), and Her-2/neu overexpression by FISH were studied.

Results: Ten cases of MNET to the breast (median age=64 years; 10 females) and 14 cases of IMC with NED (median age=64 years; female:male=13:1) were identified. The metastatic tumors originated in the lung (n=4), gastrointestinal tract (n=4), ovary (n=1) and pancreas (n=1). With the exception of one case, all MNETs were unilateral. They were comprised of uniform tumor cells exhibiting predominantly nested and trabecular architecture, with characteristic salt and pepper-like nuclear chromatin. Most MNETs were intermediate grade. Cases of IMC with NED exhibited Modified Bloom-Richardson grade of II or III, with grade 2 nuclei and a tubule score of 3 in most cases. Coexistent DCIS was identified in more than half (8/14) of IMC with NED, whereas DCIS was not identified in any cases of MNET. A comparison of the demographic and IHC characteristics of the two groups is illustrated in Table 1.

Table 1

Tumor type (n)	ER positive	PR positive	Her-2/neu amplification (FISH + & IHC 3+)	Synaptophysin positive	Chromogranin positive	Ki-67 proliferative index (mean & range)
MNET (10)	2/9 (22%) (weak to moderate)	1/9 (11%) (weak)	0/3 (0%)	9/9 (100%) (strong & diffuse)	10/10 (100%) (strong & diffuse)	9 (2-19%)
IMC with NED (14)	12/14 (86%)	9/14 (64%)	2/12 (17%)	11/14 (79%) (variable staining)	14/14 (100%) (variable staining)	33 (11-86%)

Conclusions: - In comparison to IMC with NED, metastatic NETs are generally of lower grade, are not associated with DCIS, have a lower proliferation rate, and are usually negative for ER.

- A low grade, ER-negative, invasive tumor in the breast with IHC evidence of neuroendocrine differentiation should raise the possibility of a metastatic NET.

181 Comparison of Immunohistochemical Stains for Myoepithelial Cells Versus Collagen Type IV in Invasive Ductal Carcinomas and Ductal Carcinoma In Situ of the Breast

JM Kitayama, RB West, KC Jensen. Stanford University Medical Center, Stanford, CA; Veterans Affairs Palo Alto Healthcare System, Palo Alto, CA.

Background: The differentiation between invasive ductal carcinoma and ductal carcinoma in situ is defined by the absence of myoepithelial cells and disruption of the basement membrane. There are a number of stains that can be used to evaluate for the presence of myoepithelial cells. Few comparative studies of the most commonly used antibodies with significant numbers of cases of ductal carcinoma in situ with (DCIS/IDC) and without (DCIS) invasive ductal carcinoma (IDC) have been performed. We investigated the sensitivity and specificity of five antibodies by staining 319 cases of normal breast, DCIS, IDC and DCIS/IDC on a tissue microarray.

Design: A tissue microarray comprised of normal breast, DCIS, DCIS/IDC and IDC was constructed from cases obtained for the surgical pathology files. Immunohistochemistry was performed using p75 (Santa Cruz Biotech), p63 (Cell Marque), calponin (Dako Cytomation), and smooth muscle myosin heavy chain (SMMS) (Dako Cytomation) and collagen Type IV (Dako Cytomation).

Results: As a whole, all the myoepithelial cell markers had a similar rate of detection for myoepithelial cells in normal breast, DCIS, and combined DCIS/IDC. These rates ranged from 66-85% for DCIS, 53-78% for DCIS/IDC, and 51-67% of normal breast. With invasive carcinoma, there was a wide range of staining ranging from 14% to 100%.

Myoepithelial and Collagen Type IV Positive Cases

Cases	Carcinoma	DCIS	DCIS/IDC	Normal
p63	11/7 (14%)	96/137 (70%)	78/126 (62%)	25/49 (51%)
SMMS	2/7 (29%)	90/137 (66%)	67/126 (53%)	32/49 (65%)
Calponin	4/7 (57%)	106/137 (77%)	99/126 (79%)	33/49 (67%)
p75	1/7 (14%)	116/137 (85%)	92/126 (73%)	33/49 (67%)
Collagen Type IV	7/7 (100%)	110/137 (80%)	98/126 (78%)	30/49 (61%)

Conclusions: In our series, the four myoepithelial antibodies had comparable sensitivity in the detection of myoepithelial cells in normal breast tissue, DCIS, and DCIS/IDC. Those stains with higher sensitivity such as calponin and collagen type IV had lower specificity in comparison to p63. Stains such as calponin and SMMS are easy to visualize but are not as specific as p63. Surprisingly, collagen type IV also showed poor specificity as it stained 100% of invasive carcinomas. It is beneficial to use several myoepithelial stains concurrently when evaluating for invasion. Myoepithelial stains appear to be superior to collagen type IV in our experience.

182 Prediction of Oncotype DX Recurrence Score: Use of Equations Derived by Linear Regression Analysis

ME Klein, DJ Dabbs, Y Shuai, R Bhargava. University of Wisconsin, Madison, WI; Magee-Womens Hospital of UPMC, Pittsburgh, PA; University of Pittsburgh Cancer Institute, Pittsburgh, PA.

Background: Oncotype DX® is a quantitative reverse transcription polymerase chain reaction based assay, shown to have prognostic and predictive value in estrogen receptor (ER) positive breast cancers. The Oncotype DX® recurrence score (RS) ranges from 0-100, divided into low, intermediate or high risk categories (LR <18, IR 18-30, HR ≥31). Morpho-immunohistologic correlation studies have shown that RS is heavily influenced by ER and progesterone receptor (PR) H-scores, HER2 status, Ki-67 proliferation index, and tumor grade. Our pilot study of 42 cases (Mod Pathol. 2008;21:1255-1261) showed that RS can be predicted by the following (old Magee equation, oME): RS = 13.424 + 5.420*(nuclear grade) + 5.538*(mitotic count) - 0.045*(ER H-score) - 0.030*(PR H-score) + 9.486*(0 for HER2 negative, 1 for positive).

Design: We used a dataset of over 800 cases to formulate three new RS equations, then used each equation to calculate a RS for an independent set of 162 cases.

new Magee Equation 1 (nME1): RS = 15.31385 + Nottingham score*1.4055 + ER H-score*(-0.01924) + PR H-score*(-0.02925) + (0 for HER2 negative, 0.77681 for equivocal, 11.58134 for positive) + Tumor size*0.78677 + Ki-67*0.13269.

nME2: RS = 18.8042 + Nottingham score*2.34123 + ER H-score*(-0.03749) + PR

H-Score*(-0.03065) + (0 for HER2 negative, 1.82921 for equivocal, 11.51378 for positive) + Tumor size*0.04267.

nME3: RS = 24.30812+ ER H-Score*(-0.02177) + PR H-Score*(-0.02884) + (0 for HER2 negative, 1.46495 for equivocal, 12.75525 for positive) + Ki-67*0.18649.

Results: The concordance between RS category by Oncotype DX® and Magee equations was 54.6% (88/161), 55.7% (87/156), 59.7% (95/159), and 54% (86/159) for oME, nME1, nME2, and nME3 respectively. When the IR category was eliminated, the concordance increased to 95.4% (62/65), 100% (52/52), 98.1% (52/53), and 98.1% (53/54) for oME, nME1, nME2, and nME3 respectively. The mean (median) RS for Oncotype DX® was 20 (19), compared to 17.5 (16) for oME, 19.9 (18.8) for nME1, 19.8 (19.6) for nME2 and 19.3 (18.5) for nME3.

Conclusions: Any of the four equations may be used to calculate a RS, using reported pathologic findings. When the calculated RS is LR or HR, the concordance with the Oncotype DX® RS is very high, and Oncotype DX® testing may even be avoided. Conversely, pathologists should investigate any Oncotype DX® RS that is dramatically different than expected based on pathologic findings, to ensure accuracy of the Oncotype DX® result.

183 Can GP88 Expression Serve as an Additional Surrogate Marker for Oncotype DX Recurrence Score?

M Koka, LB Goicochea, G Serrero, K Tkaczuk, B Yue, K Tuttle, OB Ioffe. University of Maryland School of Medicine, Baltimore, MD; University of Maryland Greenebaum Cancer Center, Baltimore, MD; A&G Pharmaceutical Inc., Columbia, MD.

Background: GP88 (progranulin) is an autocrine growth factor involved in survival, angiogenesis and cell migration. In estrogen receptor-positive (ER+) cells, GP88 overexpression is associated with resistance to Tamoxifen and Letrozole. High levels of GP88 expression in ER+ breast carcinoma have been reported to be associated with a 4-fold decrease in disease-free survival and a 2-fold decrease in overall survival. In this study, we investigated the correlation of GP88 expression in ER+ breast cancers with Oncotype DX recurrence score and other prognostic factors.

Design: Sixty-eight women ages 37-77 with ER+ invasive mammary carcinoma were studied. GP88 immunostaining was compared to routine clinicopathologic factors, PR, HER2/neu and Ki67 (by image analysis) and Oncotype DX (Genomic Health).

Results: The GP88 expression correlated with Oncotype Dx Recurrence score qv well as with Ki-67 index, tumor grade and stage. Age, HER2/neu and PR status did not correlate with GP88 expression.

GP88 expression	Mean Ki-67 index (%)	Mean Oncotype DX® Recurrence Score®	pT1	pT2	Grade 1	Grade 3
0/1+, 33 cases	14.4	16	27 (81%)	6 (19%)	7 (21%)	4 (12%)
2+/3+, 25 cases	25.8	22	7 (28%)	18 (72%)	3 (12%)	6 (24%)
p value	0.03	0.03	0.001		0.05	

Conclusions: This is a first study to show that GP88, an important tumor aggressiveness marker, significantly correlates with Oncotype DX score and other tumor clinicopathologic parameters and prognostic markers. Further studies are underway to determine whether a combination of GP88 with other standard factors could be used instead of Oncotype DX Assay to predict outcome and determine management in ER+ breast cancers.

184 Tubulopapillary Carcinoma of Breast: A Distinct Entity?

F Konno, J Cangiarella, L Chiriboga, S Krauter, F Darvishian. NYU Langone Medical Center, New York, NY.

Background: Papillary breast carcinomas comprise 1-2% of all breast cancers. Traditionally, this subtype is categorized as an indolent cancer that carries a more favorable prognosis than the conventional invasive carcinoma. We encountered a group of invasive breast carcinomas with papillary and tubular features in primary and metastatic settings, which were noted to behave aggressively or demonstrate parameters known to be associated with aggressiveness. Our objective was to determine whether tubulopapillary carcinoma merits separate classification.

Design: Our pathology database was queried for primary invasive breast carcinoma with papillary features. The slides were reviewed for tubulopapillary features. The cases with features of ordinary papillary carcinoma were used as control. Biomarker status, ki-67 proliferation index, p53 status, lymphovascular invasion (LVI), mitotic count per 10 high power fields (HPF) and lymph node status were used as parameters associated with aggressive behavior. Only diffuse p53 labeling of more than 70% was considered positive. The biomarker status was classified as hormone receptor positive (HR+), her2 overexpressing (her2+) and triple negative (TN).

Results: We identified 11 breast carcinomas with tubulopapillary features as study group and 14 control cases. In general, the tubulopapillary carcinomas exhibited infiltrating gaping glands with intratubular and broad extratubular papillary growth with an invasive border.

	Study Group	Control Group
Mean age (y)	59	68
Invasive Border	11 (100%)	3 (21%)
Nuclear Grade	G3=6 (55%) G2=5 (45%)	G3=2 (14%) G2=9 (64%) G1=3 (21%)
Mean mitotic count/10 HPF	12	2
Lymphovascular invasion	5 (45%)	1 (7%)
Biomarker category	4 TN (36%), 4 her2+(36%), 3 HR+(27%)	14 HR+(100%)
Mean ki-67 (%)	25	8
p53	4 (36%)	0
Mean size (cm)	1.8	1.6
Positive nodes	4 (36%)	0

G (grade); TN (triple negative); HR+ (hormone receptor positive); her2+ (her2 overexpressing)

The study group showed higher mitotic count (12 vs 2 per 10 HPF); higher Ki-67 index (25% vs 8%); higher p53 overexpression (36% vs 0%); higher incidence of LVI (45% vs 7%); and higher incidence of positive lymph nodes (36% vs 0%). The control group had a more favorable biomarker status as all cases were HR+.

Conclusions: Overall, the breast carcinomas with tubulopapillary features more frequently demonstrated parameters associated with aggressive behavior compared to the control group, independent of size. These findings suggest the presence of a subgroup of papillary carcinomas of breast with tubulopapillary features, which unlike ordinary papillary carcinoma, may behave in an aggressive fashion.

185 Whole-Slide Digital Imaging Versus Optical Microscopy for Primary Diagnosis of Hematoxylin-and-Eosin-Stained Breast Tissue Sections

S Krishnamurthy, K Mathews, S McClure, M Murray, D Visscher. Md Anderson Cancer Center, Houston; Scripps Memorial Hospital, LaJolla; Presbyterian Hospital, Charlotte; Memorial Sloan Kettering Cancer Center, New York; University of Michigan, Ann Arbor.

Background: Whole slide imaging (WSI) is now used for educational purposes, archiving and quantitation of immunostains. However, WSI is not routinely used for primary diagnosis of hematoxylin and eosin (H&E)-stained tissue sections. We conducted a multi-institutional study to compare whole-slide digital images using the Aperio digital pathology system versus optical microscopy (OM) for primary diagnosis of H&E-stained tissue sections of breast lesions.

Design: The study was conducted at 3 clinical sites with 3 breast pathologists who interpreted 150 H&E slides, 3 times by WSI and 3 times by OM. For WSI, slides were scanned using the Aperio ScanScope® and interpreted on a computer monitor using Aperio ImageScope software and Aperio Spectrum™ data management software. Diagnoses were recorded using the College of American Pathologists breast checklist. WSI was compared with OM for accuracy, precision (interpathologist variation), and reproducibility (intrapathologist variation). Results were considered accurate only if the diagnosis matched exactly between the 2 platforms. The proportion of accurate results reported by each pathologist was expressed as a percentage for the comparison of WSI with OM.

Results: The accuracy of WSI with OM for classifying lesions as no carcinoma, noninvasive (ductal, lobular), or invasive (ductal, lobular, other) was 90.5%. Interpretations made using OM compared to themselves resulted in accuracy of 92.1%. The precision and reproducibility of WSI in diagnosis of the breast lesions in comparison to OM, obtained by performing pairwise comparisons, included 3 comparisons for each slide, resulting in 36 possible comparisons. Overall, 12,164/13,447 and 3174/3465 of the pairwise interpretations by WSI were the same, compared to 14,395/15,628 and 3703/3919 of the pairwise comparisons by OM, resulting in precision of 90.5% and 92.1%, respectively, and reproducibility of 91.6% and 94.5%, respectively.

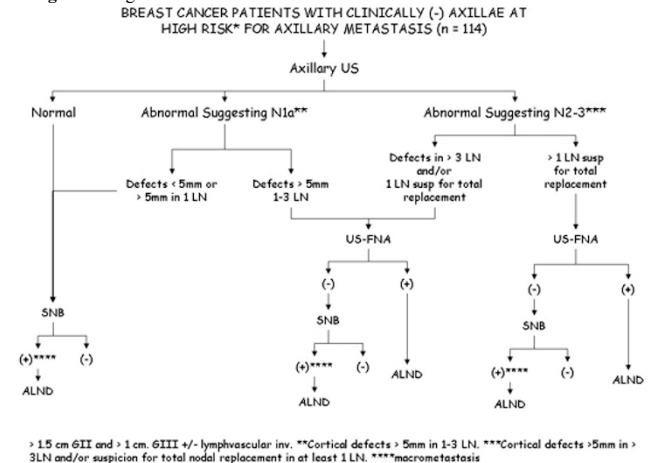
Conclusions: The study demonstrated substantial equivalence between WSI and OM with similar accuracy, precision, and reproducibility for making a primary diagnosis of H&E-stained breast tissue sections. 2. Prospective clinical studies using routine surgical pathology specimens can confirm equivalence between WSI and conventional OM and facilitate the incorporation of WSI for making primary histologic diagnosis.

186 Controversies Generated by Complete Axillary Dissections Prompted by (+) Ultrasound Guided Fine Needle Aspiration Biopsy in Clinically Node (-) Breast Cancer Patients

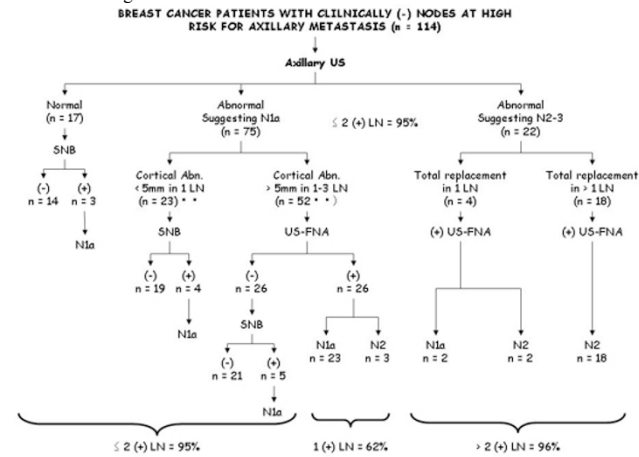
VV Krol, EA Pirruccello, JJ Krol, PC McGrath, RK Patel, RL Stewart, AL Szabunio, YM Brill, LM Samayoa. University of Kentucky, Lexington, KY; VAMC, Lexington, KY.

Background: Ultrasound Guided Fine Needle Aspiration (US-FNA) is being increasingly used for staging the axilla preoperatively. Overall this approach identifies 30 - 40 % of patients with occult metastasis. However, Complete Axillary Dissections (CAD) after a (+) US-FNA in patients with minimal disease may be considered overly aggressive. This study focuses in the selection of patients that will benefit the most from this procedure.

Design: See Figure 1.



Results: See Figure 2



Conclusions: To avoid overtreating the axilla, this study suggests: 1- That CAD should only be performed after a (+) US-FNA when the corresponding sonographic findings show strong evidence of N2-3 disease. 2- That patients with small (< 5mm) isolated, single node cortical abnormalities will not benefit from a US-FNA and 3 - That the extent of axillary surgery in patients with cortical abnormalities > 5mm in > 1 LN must be a limited one. In these patients either with a (+) US-FNA or a (+) SNB, the surgeon should be aware of the possible extent of disease and plan the dissection accordingly.

187 Morphologic & Immunohistochemical Heterogeneity in Mucinous Carcinoma of Breast (MC)

ON Kryvenko, J Yoon, J Arias-Stella, MW Lee, DA Chitale. Henry Ford Hospital, Detroit, MI.

Background: Pure MC (colloid), a special type of invasive ductal carcinoma (IDC), is associated with relatively favorable prognosis. However, reported incidence varies depending on histologic criteria used, so does the outcome. Our aim was to explore the morphologic & immunohistochemical spectrum of breast cancer with mucinous differentiation.

Design: From 2000 to 2011, we retrieved all the cases of breast cancer where the word 'mucinous' appeared in the final report. All the cases were reviewed & histologically classified based on cellularity & extracellular mucin content per published criteria as Type A MC (60-90% extracellular mucin in >90% of tumor & Type B-MC (<60% extracellular mucin in >90% of tumor). IDC-NOS with minor mucinous component were subtyped as mixed MC. Presence of intracytoplasmic mucin & morphologic features of neuroendocrine differentiation (NED) were recorded. 90 tumors were stained with antibodies against CD56, chromogranin, synaptophysin, estrogen & progesterone receptors, Her2neu, & Mib-1. Age, pathologic grade & stage were recorded. Chi-square & t-test were used for statistical analysis.

Results: There were 128 patients with 134 tumors. No statistical difference was observed between the subtypes in age (28-95 years; mean, 69.1) or pathologic stages (11 stage 1a, 39 - stage 1b, 34 stage 1c, 26 - stage 2, 3 - stage 3). Average tumor size increased with cellularity (0.1-7.5 cm; mean 1.6 cm, statistically not significant). Lymph nodes were dissected in 101 cases (number: 1-29; mean 4) & metastasis (LN+) were seen in 10 cases; all with larger primary tumor size (1.5cm vs 2.3cm, p=0.049), high Mib-1 index (16.2 vs 7.2, p=0.011), Mib (60 vs 30%) & type B or mixed MC patterns (8/10). CD56 was positive in 15 cases. All tumors were positive for ER, 7 negative for progesterone. Intracytoplasmic mucin was most frequently present in type B MC.

Total MC type	Mean size (cm)	Synaptophysin (%)	Chromogranin (%)	Her2neu(%)	Mib-1, mean	LN+(%)
TypeA (n=70)	1.4	25.5	22.9	3	4.5	3.8
TypeB (n=39)	1.7	43	36	8	11.3	14.7
mixedMC (n=19)	2.2	23	15	17	21	21

Conclusions: We observed gain of aggressive histological & immunophenotypic features directly proportional to increasing cellularity & decreasing extracellular mucin content. With increasing cellularity there was larger tumor size, higher nuclear grade & proliferation index, frequent NED, Her2/neu positivity & increase chance of nodal metastasis. Therefore it is imperative to stratify MC using strict histologic criteria due to different clinical outcomes and tumors with conventional IDC should primarily be called IDC with a note of focal mucinous differentiation.

188 Primary Mucinous Carcinoma (MC) of Breast - A Proposal of Precursor Lesion & Possible Tumor Progression

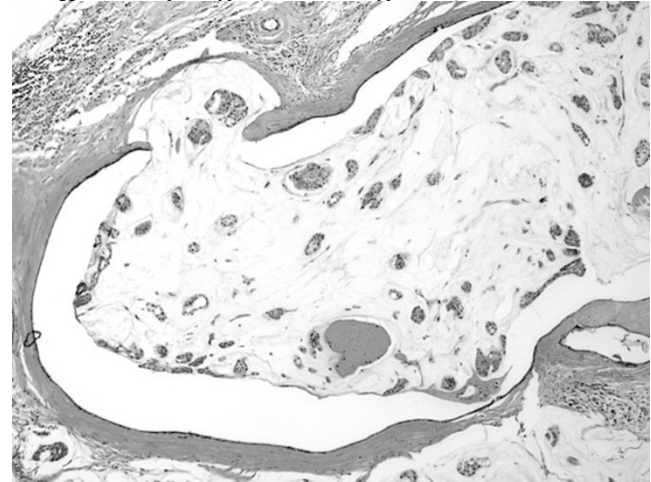
ON Kryvenko, DA Chitale, J Yoon, J Arias-Stella, MW Lee. Henry Ford Hospital, Detroit.

Background: MC is a rare primary tumor of the breast associated with a relative favorable outcome. Data in the literature are limited regarding the precursors of MC & tumor progression unlike invasive ductal carcinoma, NOS (IDC-NOS). In this study we sought to characterize association of mucinous ductal carcinoma in situ (DCIS) with MC as a precursor lesion.

Design: Study included 128 cases of MC over a 10 year period. Based on published criteria, tumors were further classified based on cellularity & extracellular mucin content: Type A MC (paucicellular, 60-90% extracellular mucin in >90% of tumor) & Type B-MC (cellular, <60% extracellular mucin in >90% of tumor). IDC-NOS with minor mucinous component were subtyped as mixed MC. All slides were reviewed

to identify DCIS, with focus on transitional pattern between the MC & DCIS. Immunohistochemistry (IHC) for p63 & calponin was done to assess presence of myoepithelial cells in the transitional areas.

Results: There were 70 Type A MC & 39 Type B MC & 19 cases of mixed MC. 15 specimens were needle core biopsy, the rest excisions. Associated DCIS was identified in 88 (69%) cases (5 biopsies & 83 excisions: Type A MC - 46; Type B MC - 29; mixed MC - 13) with 81 cases showing luminal expansion by mucin. 59 of 81 DCIS (73%) with luminal mucinous distention revealed transitional pattern between DCIS & MC. The predominant pattern of DCIS was cribriform & solid (65/81) with luminal mucinous distention, focal flattening & attenuation of the epithelium, disruption of the epithelium with mucocoele like extravasation of mucin with detached floating papillae. Detached papillae in the mucin pool were confirmed by presence of peripheral apocrine snouts & were negative for p63 & calponin. Gradual disappearance of myoepithelial cells in transition was confirmed by IHC in 21/43 stained cases. Solid DCIS was associated with aggressive MC phenotypes (mixed MC & Type B MC).



Conclusions: MC has distinct mucinous DCIS precursor with characteristic transition zone. Pathogenesis of MC may involve mucinous overdistention of ducts involved by DCIS with rupture & extravasation of malignant epithelium. We believe Type A MC & Type B MC represent spectrum of tumor progression as Type A MC gradually deplete extracellular mucin becoming Type B MC & ultimately non mucinous IDC.

189 K-ras Mutations in Triple Negative Breast Carcinomas

I Kulac, S Balci, K Altundag, A Baykal, G Guler Tezel, G Guler. Hacettepe University Faculty of Medicine, Ankara, Turkey; Yildirim Beyazit University Ankara Atatürk Research and Education Hospital, Ankara, Turkey.

Background: K-ras mutations are seen in 40% of colorectal cancers (CRC). Only CRCs with wild type K-ras respond to anti-EGFR treatments. Triple negative breast (TN) tumors show high incidence (around 60%) of EGFR expression and they are also good candidates for anti-EGFR treatments. One previous report showed no K-ras codon 12 and 13 mutations in TN tumors. So we aimed to search for K-ras mutations in our cohort.

Design: 47 primary breast carcinomas which are negative for ER, PR and HER2 are included. DNA was extracted from sections that constitute more than 75% invasive tumor tissue. K-ras mutations in codon 12, 13 and 61 were analyzed by pyrosequencing on the Qiagen PyroMark Q24. Only the mutation levels which were 3% more than the level of detection defined in the product manual were accepted as positive.

Results: Mean age of patients were 51.9±14.0 (min:25, max:85). Of the 47 TN tumors 41 (87.2%) were grade 3, 6 (12.8%) were grade 2 tumors.

2 (4.3%) cases had mutation in codon 12; 2 (4.3%) cases in codon 13; 8 (17.0%) cases in codon 61. Ten (21.3%) cases had mutation at least in one codon. One (2.1%) case had mutation in codon 12&61 and one other in codon 13&61 simultaneously. None of the cases had mutation in all three codons.

Mutations were GGT>GTT and GGT>GAT in codon 12; GGC>GAC in codon 13 and TTT>GTT in codon 61.

Conclusions: We found that K-ras mutations can be seen in TN tumors. In clinical trials with EGFR targeted agents, K-ras mutation detection may be beneficial to predict unresponsive patients.

190 Lipophyllodes of the Breast. A Clinicopathologic Study of 10 Cases Integrated by Molecular Pathology Insights

J Lamovec, P Cusati, S Pizzolitto, G De Maglio, G Falconieri. Institute of Oncology, Ljubljana, Slovenia; General University Hospital, Udine, Italy; General Hospital, Santiago do Cacem, Portugal.

Background: Lipophyllodes tumor (LPT) is a rare, special type of mammary fibroepithelial tumor showing basically the features of phyllodes tumor with a distinctive fatty component featuring mature adipocytes and lipoblasts. Available evidence suggests that most of LPT pursues a benign course, however confirmatory evidence from clinicopathologic investigations of large series integrated by molecular assays are apparently underreported. The aim of this study is to update our knowledge of LPT integrating traditional clinicopathologic assessment with molecular assay for MDM2 gene expression.

Design: We retrieved the archival material of 10 patients with breast LPT and available clinical follow-up. A standard panel of antibodies against cytokeratins, vimentin, actins,

S100 protein, desmin, epithelial membrane antigen, estrogen- and progesterone receptors was applied on paraffin sections. Evaluation for the amplification of the MDM2 gene expression was also performed by FISH on 7 cases.

Results: The patients were all women, 39 to 63 years old (median 52 years). Macroscopically the tumors were lobulated, from 4 to 4.5 cm. In one case however it measured 30 cm. Microscopically tissue sections showed an organoid, biphasic growth pattern featuring a pronounced lipomatous component either mature, lipoma-like type or with malignant appearing lipoblasts in a myxoid background simulating myxoid liposarcoma. In 2 cases there was evidence of diverging rhabdomyoblastic differentiation. Follow-up (from 4 to 11 years) is negative for tumor recurrence or metastases in 7 patients. The patient with a 30 cm LPT died of pulmonary metastasis 1 years after mastectomy. 2 patients developed local and isolated metastases and were successfully treated with mastectomy and metastasectomy, respectively. No case showed MDM2 gene amplification, including those with an unfavorable follow up.

Conclusions: LPT is clinically comparable with phyllodes tumor inasmuch as it occurs in adult-aged women and presents as a palpable, occasionally huge mass. In most cases, the stromal component features mature fat, however immature and pleomorphic adipocytes may be recognized. The clinical course is difficult to predict on a pathologic basis only; in contrast to common phyllodes tumor increased cellularity, cell pleomorphism and brisk mitotic activity were not associated with an adverse outcome. The absence of MDM2 gene amplification should be also viewed with caution about its prognostic value.

191 HER2/Neu Gene Amplification Heterogeneity: The Significance of Cells with a 3:1 HER2/CEP17 Ratio

L.J. Layfield, R. Schmidt. University of Utah School of Medicine, Salt Lake City, UT; ARUP Laboratories, Salt Lake City, UT.

Background: The CAP produced guidelines for HER2 amplification heterogeneity. Heterogeneous populations may behave differently than homogeneous populations. When 20 cells are counted to evaluate HER2/neu amplification, a single 3:1 HER2/CEP17 ratio cell characterizes the sample as heterogeneous non-amplified. Such heterogeneous cases may behave differently than heterogeneous non-amplified cases secondary to multiple cells with ratios >2.20 or cases with a single cell having a ratio >3:1. Heterogeneity may indicate biologically important characteristics.

Design: Fluorescence in situ hybridization was performed for each of 1547 cases and 20 cells of invasive carcinoma were analyzed for HER2/CEP17 ratio. Cases were assessed as non-amplified (ratio <1.8), borderline amplified (ratio of 1.8 to 2.2) or amplified (ratio >2.20). Heterogeneity was present when the percentage of cells with ratios above 2.20 was ≥5% but <50%. Individual cells were typed by probe ratios. The distribution of HER2/CEP17 ratio was determined with the number of 3:1 HER2/CEP17 cells plotted against the number of amplified cells. The probability of a heterogeneous population being present was plotted against the number of 3:1 cells in the sample.

Results: 3:1 HER2/CEP17 ratio cells occur with low frequency (2.2%) but are the determining factor for heterogeneity in 46% of heterogeneous cases. Thirty five percent of heterogeneous cases were due to a single 3:1 cell. A single 3:1 cell in a sample is a poor predictor of additional amplified cells. Among cases with a single 3:1 cell, only 30% contain an additional amplified cell. 3:1 ratio cells were responsible for 10% of the diagnoses of amplification. 3:1 cells were not associated with heterogeneity in amplified cases ($p < 0.36$) but were associated with heterogeneity in borderline cases ($p < 0.002$).

Conclusions: Our data suggests that inclusion of cells with a 3:1 HER2/CEP17 ratio in the definition of heterogeneity may be too broad as these cells are a determining factor in approximately one-third of diagnoses of heterogeneity but are not strongly associated with other measures of amplification. 3:1 ratio cells are a poor predictor for the presence of additional amplified cells in a sample. The lower cut point for heterogeneity is in a region sensitive to error. A small counting error may result in a diagnosis of heterogeneity. The importance of small numbers of 3:1 HER2/CEP17 ratio cells in a sample should be reassessed as they may not reflect a poor prognosis or the likelihood of amplified cells in metastases.

192 Differing Prognostic Associations of Tumor Stromal Macrophages in Different Molecular Subtypes of Breast Cancers

AF Lee, H Huwatt, S Leung, J Choo, TO Nielsen, C-H Lee. Univ. of British Columbia, Vancouver, BC, Canada; Vancouver Gen. Hosp., Vancouver, BC, Canada.

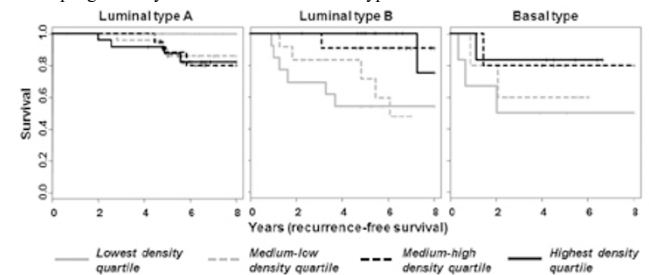
Background: Dense stromal macrophage infiltrates are associated with poor prognosis in breast cancer as a group overall. Experiments in some breast cancer models have implicated tumor-macrophage interactions in cancer progression. Although genetic differences between the different molecular subtypes of breast cancer is well established, the prognostic significance of tumor associated macrophages in the different subtypes remains poorly understood.

Design: We performed a study on a series of 166 breast cancers with clinical follow-up data. Individual cases were represented by duplicate tumor cores on a tissue microarray. These cases were immunohistochemically subtyped (Cheang et al. Journal of National Cancer Institute. 2009;101:736-50, and Clinical Cancer Research. 2008;14:1368-76) and a total of 93 luminal type A, 51 luminal type B, and 22 basal type cases were represented. The number of stromal macrophages highlighted by CD163 immunostaining (Novocastra) was manually quantified, without knowledge of subtype, and normalized to the tissue core area for determination of macrophage density. Kaplan-Meier survival and univariable Cox regression analyses (recurrence-free survival) were performed.

Results: We observed that the presence of increased stromal CD163+ macrophages is associated with poorer recurrence-free survival in luminal type A cancers (hazard ratio=1.47, $p=0.044$). In contrast, increased stromal CD163+ macrophages is associated with improved recurrence-free survival in luminal type B cancers (hazard ratio=0.702,

$p=0.047$) and basal type cancers (hazard ratio=0.656, $p=0.13$). Kaplan-Meier survival analyses, with the cases stratified into quartiles based on relative macrophage densities in each molecular subtype, are shown in Figure 1.

Figure 1: Kaplan-Meier survival analysis (recurrence-free survival) of stromal macrophage density in different molecular subtypes.



Conclusions: Our study demonstrated differing prognostic associations for increased stromal macrophages in the different molecular subtypes of breast cancers. We have currently extended the same analysis to a large validation series of 1722 breast cancers (subtyped by gene expression profiling and immunohistochemistry) and the results will be updated.

193 Targeted Overexpression of EZH2 to the Mammary Gland Accelerates ErbB2-Driven Tumorigenesis

X Li, ME Gonzalez, ML DuPrie, KA Toy, CG Kleer. University of Michigan, Ann Arbor.

Background: EZH2 protein is overexpressed in estrogen receptor negative invasive breast carcinomas with concomitant HER-2/neu overexpression and is a predictor of metastasis. We have demonstrated that mammary specific EZH2 overexpression causes intraductal hyperplasia but is not sufficient to induce invasive carcinomas. To address the biological impact of EZH2 overexpression in mammary tumorigenesis, we generated a novel mouse model of ErbB-2 and EZH2 overexpression in the mammary epithelium.

Design: Mammary specific EZH2 overexpressing transgenic mice were developed in our laboratory. MMTV-neu mice were purchased (Jackson laboratories, FVB/N-TgN(MMTVneu)202Mul/J). EZH2+;neu and EZH2 wt;neu mice were obtained by synchronized breeding of male heterozygous EZH2 transgenics and female MMTV-neu mice. Xenotransplants were carried out to determine the effect of EZH2 overexpression in the stem cell population. Flow cytometry, real-time PCR and immunoblots were performed in mouse mammary glands and cell lines. EZH2, Ki-67, Stat5, and Notch1 were determined by IHC.

Results: EZH2 overexpression enhanced tumor initiation in MMTV-neu mice. EZH2+neu mice (n=30) showed accelerated tumor development (median time to tumor initiation=234 days) compared to EZH2 wt;neu controls (n=25) (median time to tumor initiation=295 days) (Log-rank $p < 0.0001$). Despite no differences in tumor size or histology, flow cytometry revealed that EZH2+neu mice had an expansion of the luminal progenitors (CD24+CD29loCD61+) in the mammary glands at 8 weeks of age, preceding tumor development. Transplantation of mammary stem cells derived from 8-week old EZH2+neu and EZH2 wt;neu controls into FVB mice showed that EZH2 overexpression induced stem cell proliferation, intraductal hyperplasia and the formation of solid nests composed of primitive cells. The function of EZH2 in mammary stem cells was further validated in breast cell lines by showing that EZH2 overexpression increased the number of stem cells and mammospheres. EZH2 increased the levels of stem cell regulators NOTCH1 and STAT5a tested by RT-PCR and immunoblots.

Conclusions: EZH2 overexpression accelerates the initiation of ErbB2-induced mammary tumors in mice. EZH2 overexpressing mammary glands exhibited an increase in the progenitor cell population able to recapitulate the cellular heterogeneity of the mammary gland. EZH2 overexpression deregulated several stem cell pathways, including NOTCH1 and STAT5, which is under investigation. We provide first in vivo evidence that EZH2 cooperates with ErbB2 in breast cancer initiation and increases the stem cell population in the mammary gland.

194 Predictors of Response to Trastuzumab Containing Neoadjuvant Chemotherapy in HER2 Positive Breast Cancers

X Li, A Kanbour-Shakir, D Dabbs, R Bhargava. University of Pittsburgh Medical Center, Pittsburgh, PA.

Background: Trastuzumab-containing neoadjuvant chemotherapy (NACT) in patients with HER2-positive breast cancer is highly effective in reducing tumor volume and enables more patients to have breast conserving surgery. We have previously reported that tumor hormone receptor level significantly influences response to trastuzumab containing NACT (Mod Pathol. 2011;24:367-374). In this study, we comprehensively evaluated various morphologic features and proliferative activity in 50 invasive breast carcinomas treated with trastuzumab containing NACT to determine if any of these features have the same predictive value as tumor hormone receptor content.

Design: Following morphologic parameters were analyzed: Nottingham score, grade and individual grading components, absolute mitosis count/10 high power fields, and type of growth pattern (infiltrative versus pushing). The following features were considered present if identified in >10% of the tumor: sheet-like growth pattern, spindle cells, apocrine differentiation, intra-tumoral lymphocytic infiltrate, and geographic necrosis. Nucleoli were considered prominent if visible at 10X objective and substantial apoptosis was considered present if easily visible at 10X. Cell proliferative activity was assessed by Ki-67 labeling index LI. Complete pathologic response was defined as absence of

invasive carcinoma in the post-therapy resection specimen and within regional lymph nodes. Percentage tumor volume reduction was calculated based on pretherapy clinical tumor size and meticulous examination of the post-therapy resection specimen.

Results: Eighteen (36%) cases achieved pCR. Neither morphologic variables nor Ki-67 LI were predictive of pCR or >50% tumor volume reduction. Similar to our previous report, hormone receptor status and semi-quantitative H-scores for ER and PR were predictive of both pCR and >50% tumor volume reduction. The mean ER and PR H-scores for tumors that showed pCR were 44 and 10 respectively compared to 132 and 62 for cases that failed to achieve pCR (p value of 0.005 for ER and 0.018 for PR). **Conclusions:** Only steroid hormonal receptor (ER and PR) content of the tumor are predictive of pCR and significant tumor volume reduction in HER2 positive patients treated with trastuzumab-containing NACT. Neither morphologic features (including Nottingham grading) nor Ki-67 LI are predictive of response or >50% tumor volume reduction. Semi-quantitative scoring for hormone receptors should be universally adopted by pathologists for proper patient management.

195 Surgical Excision May Not Be Necessary for Benign Papillomas on Core Biopsy: A Large Retrospective Study in an Academic Women Center

X Li, M Desouki, D Dabbs, S Shyu, G Carter, L Wang, C Zhao. Magee-Womens Hospital, University of Pittsburgh Medical Center, Pittsburgh, PA.

Background: The clinical management of benign papillomas detected by needle core biopsy (NCB) remains controversial. There is great discrepancy of reported upstaging rate at excision, ranging from 0% to 25%.

Design: A computer based search was carried out on our database from January 2005 to December 2010, to identify the cases of papilloma and atypical papilloma diagnosed on NCB. The pathological findings in follow up excision (FUE), BI-RADS scores and time between biopsy and FUE were recorded and analyzed.

Results: Total 18361 cases of NCB were performed during the study period. 648 (3.5%) cases were interpreted as papilloma (IP) (n=576) or atypical papilloma (AP) (n=72). 106 cases were excluded due to prior history of or synchronous malignant breast lesions or ADH/ALH. Of the 542 cases of IP (482) or AP (60), 422 (78.0%) had FUE, including 369 cases of IP and 53 cases of AP. The mean interval between NCB and FUE was 2.0 months (0.2-15.5) for IP and 1.6 months (0.5-5.5) for AP. The BI-RADS scores for IP were: 1-3 in 14/323 (4.3%), 4 in 303/323 (93.8%), 5 in 6/323 (1.8%) of cases; for AP were: 2 in 2/43 (4.7%), 4 in 40/43 (93%), and 5 in 1/43 (2.3%) of cases. The discovery of significant lesions upon surgical excision of papilloma is shown in the [table 1]. The BI-RADS score was 4 for all 5 cases of DCIS and polymorphic LCIS in IP group. Score 5 in one case, which was papillary carcinoma and score 4 in 5/6 cases of DCIS and IC in AP group.

Table 1: Findings on Subsequent Breast Excision

	IP N=369	AP N=53	Total N=422
Invasive Carcinoma	0 (0%)	2 (3.8%)	2 (0.5%)
DCIS	5* (1.4%)	4 (7.6%)	9 (2.1%)
ADH	48** (13%)	19 (35.9%)	67 (15.9%)
LN	7 (1.9%)	0 (0%)	7 (1.7%)
ADH/LN	6 (1.6%)	1 (1.9%)	7 (1.7%)
Total	66 (17.9%)	26 (49%)	92 (21.8%)

* includes one polymorphic LCIS; ** includes 8 atypical papilloma; LN includes ALH and LCIS

Conclusions: Of 369 patients with diagnosis of benign papillomas on CNB, 5 (1.4%) cases were upstaged to DCIS or pleomorphic LCIS on FUE compared with 11.4% of DCIS or IC in AP group (p<0.01).

Our results suggest that FUE may not be required for benign papilloma diagnosed on CNB in patients without any associated other risk factors while FUE is recommended for all AP cases.

196 Development of New Rabbit Monoclonal Antibody to Estrogen Receptor alpha (Clone EP1) and HER2/ERBB2 (Clone EP3) for Immunohistochemical Application

A Li, H Pan, N Jiang, Z Liu, Z Fang, M Frolkis, W Zhu, T Chen. Epitomics, Inc., Burlingame, CA.

Background: Rabbit monoclonal antibodies (RabMAbs) are known for their superior sensitivity and specificity in the immunohistochemical (IHC) detection of antigens in formalin-fixed paraffin-embedded (FFPE) tissue compared to mouse monoclonal and rabbit polyclonal antibodies. A RabMAb against ER alpha (ER) or HER2 has been shown to improve the IHC test quality in breast cancer diagnosis. However, the cross reactivity of ER with lung adenocarcinomas or ER beta protein is still a concern. The cross reactivity of anti-HER2 with HER4 protein may lead to false positive HER2 testing results in breast cancer patients. As a resolution, we developed a new RabMAb ER alpha using an immunogen that resides on the N-terminal portion of the ER protein, which shows no reactivity with ER beta. We have also produced a new HER2 RabMAb without HER4 immunoreactivity.

Design: Rabbits were immunized with recombinant human ER protein or a HER2 peptide corresponding to residues in human HER2 protein. Initial antibody characterization was performed by ELISA, differential western blot (WB) and IHC. Antibodies suitable for IHC were further validated with specific target tissues as well as normal, tumor and breast cancer tissue arrays. For ER, the performance was further compared with current ER standard clone SP1. Positive and negative staining status was scored according to ASCO/CAP guideline. A tumor with positive staining was determined when 1% or more cells were stained. The specificity, sensitivity and concordance of EP1 versus SP1 were analyzed.

Results: For ER antibody, clone EP1, WB results show that EP1 has no cross reactivity with ER beta. IHC analysis shows that EP1 labels the nucleus of target cells in breast, cervix and uterus in normal tissue arrays. No staining was observed in other normal tissues. In a breast cancer array, there is a high concordance between EP1 and SP1:

the positive, negative and overall agreements are 95%, 96% and 98% respectively. For HER2 antibody, clone EP3, WB showed no reactivity with the HER4 protein. IHC testing shows that EP3 only labels the membrane of breast cancer and gastric cancer cells. No staining was observed in other tumor and normal tissues tested.

Conclusions: RabMAbs anti-ER alpha, clone EP1 and anti-HER2, clone EP3 are specific and sensitive in the detection of target proteins by IHC in FFPE tissues. EP1 is highly concordant with SP1. EP1 is useful in the immunohistochemical assessment of hormone receptor status in breast cancer. Compare to current HER2 antibodies, EP3 may be a potentially better tool for HER2 IHC testing.

197 The Effect of Prolonged Cold Ischemia Time on Estrogen Receptor Detection in Breast Cancer

X Li, MT Deavers, M Guo, LP Middleton, P Liu, L Huo. The University of Texas, MDACC, Houston.

Background: Recent guidelines provided by ASCO/CAP recommended that cold ischemia time (time from tumor removal to fixation) be limited to within 1hr in order to obtain accurate ER IHC results. While this is done routinely for core biopsy specimens, it may be difficult for resection specimens due to comprehensive intra-operative evaluations. Data is limited on the effect of prolonged cold ischemia time on ER IHC. In this study, we compare ER expression levels in resection specimens that have a cold ischemia time of >1hr to their corresponding biopsy specimens with the aim to guide our clinical practice.

Design: 78 resection specimens of invasive breast carcinoma with a cold ischemia time of >1hr identified between February and May 2011 in our department computer database were tested in this study. One section of the invasive carcinoma from each case was stained for ER (6F11, Novocastra Laboratories), then scored following ASCO/CAP guidelines and divided into 3 categories (10% and above, positive; 1-9%, low positive; less than 1%, negative). ER results from the corresponding core biopsy specimens were recorded from the pathology reports. Concordance was evaluated by weighted kappa statistics considering any change in category as an event. Any decrease in detected expression from biopsy to resection resulting in a categorical change or any decrease of more than 30% within the positive group in association with cold ischemia time was analyzed with Wilcoxon rank-sum test.

Results: The cold ischemia time ranged from 64 to 357 min (mean, 124). Based on the biopsy specimens, 70 tumors were ER positive, and 8 were ER negative. In the resection specimens, 2 of the 8 negative tumors on biopsy stained low positive, and 1 of the positive tumors stained low positive and 1 stained negative. The weighted kappa value was 0.83, indicating good concordance. Decreased expression resulting in a change in category (2 of 78 cases, 3.8%) was not associated with cold ischemia time (p=0.75). Within the group that was positive in both biopsy and resection specimens (68 cases), a lower expression level by over 30% in the resection was found in 4, and a higher expression level by over 30% in the resection was found in 5. This decrease in expression level was not associated with cold ischemia time (p=0.43).

Conclusions: In the majority of cases, cold ischemia time up to a few hours does not affect ER IHC. The decreased ER expression in the resection specimens in this study may not be due to prolonged cold ischemia time and warrants further investigation.

198 Evaluation of GATA3 Expression in Tumors from Various Organs

F Lin, J Shi, M Wilkerson, H Liu. Geisinger Medical Center, Danville, PA.

Background: GATA3 is a recently described immunohistochemical marker for urothelial carcinoma. Low GATA3 expression has also been suggested to correlate with poor prognosis in breast cancer. However, the published data on the GATA3 expression on tumors from other organs were limited. In this study, we investigated the expression of GATA3 in a large series of carcinomas from various organs using a single immunostaining system (Dako).

Design: Immunohistochemical evaluation of the expression of GATA3 (Santa Cruz Biotech Inc, Cat. No. GATA3 [HG3-31]:sc-268) on 1,110 cases of carcinomas from various organs using tissue microarray sections was performed. The staining intensity was graded as weak or strong. The distribution was recorded as negative (<5% of tumor cells stained), 1+ (5-25%), 2+ (26-50%), 3+ (51-75%), or 4+ (>75%).

Results: The positive staining results (%) and the total number of cases for each entity (N) are summarized in Table 1. Sixty-two of 72 urothelial CA (86%), 90 of 99 ductal CA (91%) and 48 of 48 lobular CA were positive for GATA3. Diffuse (3+ or 4+) and strong nuclear staining was noted with 65% of urothelial CA, 84% of ductal CA and 77% of lobular CA. Two of 96 endometrial carcinoma cases were positive for GATA3. All others cases in this study were negative for GATA3.

Table 1. Summary of immunostaining results

Tumor	GATA3 (positive cases and %)
Seminoma (N=30)	0
Embryonal CA (N=24)	0
Yolk sac tumor (N=12)	0
Lung neuroendocrine CA (N=61)	0
Lung ADC (N=61)	0
Lung SCC (N=49)	0
Papillary thyroid CA (N=47)	0
Follicular thyroid CA (N=37)	0
Medullary thyroid CA (N=10)	0
Anaplastic thyroid CA (N=5)	0
Clear cell RCC (N=82)	0
Papillary RCC (N=20)	0
Colonic ADC (N=43)	0
Esophageal ADC (N=30)	0
Gastric ADC (N=21)	0
Pancreatic ADC (N=50)	0
Urothelial CA (N=31)	62/72 (86%)
Prostatic ADC (N=136)	0
Cholangiocarcinoma (N=11)	0
Breast ductal CA (N=99)	90/99 (91%)
Breast lobular CA (N=48)	48/48 (100%)
Endocervical ADC (N=17)	0
Endometrial CA (N= 96)	2/96 (2%)
Ovarian serous CA (N=56)	0
Hepatocellular CA (N=18)	0
Pancreatic endocrine neoplasm (N=15)	0
Skin melanoma (N=100)	0

ADC—adenocarcinoma; CA—carcinoma; RCC—renal cell carcinoma

Conclusions: Our data demonstrate that GATA3 is a sensitive and specific marker for the diagnosis of urothelial carcinomas and breast carcinomas when working on a tumor of unknown origin. Caution should be taken in that rare cases of endometrial adenocarcinoma can be positive for GATA3 as well.

199 COX-2 (Cyclooxygenase-2) Expression Is Associated with Aggressive Disease in Invasive Mammary Carcinoma

K Linos, C Sheehan, J Ross. Memorial Sloan-Kettering Cancer Center, New York, NY; Albany Medical College, Albany, NY.

Background: COX-2 converts arachidonic acid to prostaglandin H2 and has been linked to aberrant cancer cell adhesion, proliferation, apoptosis, angiogenesis, and immune surveillance. COX-2 overexpression has been associated with adverse prognostic factors for breast cancer, but it has not been widely studied as a marker of clinical outcome for the disease.

Design: Formalin-fixed, paraffin-embedded tissue sections from 177 cases of invasive mammary carcinoma [127 ductal (IDC) and 50 lobular (ILC)] were immunostained by automated methods (Ventana Medical Systems Inc., Tucson, AZ) using mouse monoclonal COX-2 (clone CX-294, DAKO, Carpinteria, CA). Cytoplasmic immunoreactivity was semiquantitatively scored based on staining intensity and distribution and the results were correlated with morphologic and prognostic variables.

Results: COX-2 expression was variably identified in normal breast epithelium with accentuation of staining in micropapillary ductal epithelium. Cytoplasmic COX-2 overexpression was observed in 123/177 (70%) tumors; 89/127 (70%) IDC and 34/50 (68%) ILC. COX-2 overexpression correlated with tumor grade [83% grade 3 vs 67% grade 2 vs 56% grade 1, $p=0.046$], advanced stage [77% advanced stage vs 62% early stage, $p=0.042$], lymph node status [75% node positive vs 61% node negative, $p=0.049$], and disease-free survival [83% recurrent vs 65% non-recurrent, $p=0.016$]. Within the IDC subgroup COX-2 overexpression correlated with tumor grade [83% grade 3 vs 67% grade 2 vs 50% grade 1, $p=0.032$] and lymph node status [78% node positive vs 60% node negative, $p=0.032$]; while showing a trend for advanced stage [79% advanced stage vs 64% early stage, $p=0.074$]; while within the ILC subgroup, COX-2 overexpression correlated with disease-free survival [92% recurrent vs 59% non-recurrent, $p=0.028$] while showing a trend for association with ER negative tumors [91% ER negative vs 63% ER positive, $p=0.077$]. Within the ER negative subgroup, a trend with disease-free survival [91% recurrent vs 70% non-recurrent, $p=0.062$] was noted. On multivariate analysis, advanced stage and ER negative status were independent predictors of disease-free survival; while advanced stage was an independent predictor of shortened overall survival.

Conclusions: COX-2 overexpression is associated with adverse prognostic factors in breast cancer including high tumor grade, advanced tumor stage and disease recurrence after primary therapy. Further study of COX-2 expression in mammary carcinoma appears warranted.

200 Dual PTEN and RB Loss Predict Invasive Recurrence of DCIS

RL Lipinski, RW O'Neill, ES Knudsen, GF Schwartz, AK Witkiewicz. Thomas Jefferson University, Philadelphia, PA.

Background: Currently there is paucity of markers allowing to predict which DCIS lesions will recur as an invasive disease. The RB tumor suppressor pathway is an important regulator of cell proliferation that has been shown to become functionally lost in close to 30% of DCIS. Loss of RB is associated with increased risk of DCIS progression to invasive breast cancer. PTEN is a tumor suppressor gene that is frequently altered in advanced breast cancers. Loss of PTEN expression has been associated with breast cancer metastasis and death in previous studies but its role in DCIS progression has not been investigated. It has previously been shown that loss of PTEN may be related to RB pathway inactivation through its effects on cyclin D1.

The goal of this study was to elucidate the potential role of RB and PTEN as predictive biomarkers for recurring breast cancer disease.

Design: 230 DCIS patients treated with surgery and clinical follow up were included in the study. Expression of PTEN and RB was assessed by employing a standard immunoperoxidase method with primary PTEN antibody (Cell Signaling Technologies, Rabbit Monoclonal, 138G6, 1:100) and primary RB antibody. (ThermoScientific; catalog no. MS-107-B, 1:50). PTEN expression was scored semi-quantitatively as negative (cancer cells showed no staining while normal cells were positive), weak (staining intensity was less than adjacent normal cells), or strong (staining intensity was equal to adjacent normal cells). PTEN loss was defined as a score of either negative, or weak. RB expression was scored as negative or positive (any neoplastic cell staining). Association between markers expression and recurrence was assessed using Kaplan-Meier Survival Analysis.

Results: Of the 230 DCIS cases, 68 (29%) recurred (46 as DCIS and 22 as invasive carcinoma). There was a statistically significant association between loss of RB expression and invasive recurrence ($p=.0014$). However, its significance was increased when considered in combination with PTEN loss ($p<.0001$). An invasive recurrence was observed in 41% of patients with RB/PTEN loss, while 6% of patients with no recurrence showed RB/PTEN loss of expression.

Conclusions: Dual PTEN and RB expression loss in DCIS is associated with increased risk of invasive breast cancer recurrence. The combination of PTEN and RB may prove useful as predictive biomarkers for invasive breast cancer recurrence.

201 Identification of an Effective Immunohistochemical Panel in Distinction of Breast Carcinoma from Endometrial Adenocarcinoma

H Liu, J Prichard, F Lin. Geisinger Medical Center, Danville, PA.

Background: When working on a tumor of unknown origin, breast carcinoma (BCA) versus endometrial adenocarcinoma (EDAC) may present a diagnostic challenge because of the overlapping morphological features and immunostaining profile. In this study, we re-evaluate the expression of an extensive panel of biomarkers including recently described markers GATA3, Trefoil factor 1 (TFF1), Trefoil factor 3 (TFF3) and PAX8 using a single immunostaining system (Dako).

Design: We immunohistochemically evaluated the expression of 1) epithelial markers (AE1/3, CAM5.2, CK7, CK20, CK17, CK19, CK903, EMA); 2) mucin gene products (MUC1, MUC2, MUC4, MUC5AC, MUC6); 3) tumor suppressor genes and transcription factors (ER, PR, p53, beta-catenin, WT-1, CDX2, pVHL); and 4) tumor-associated proteins (TTF-1, napsin A, GATA3 [Santa Cruz; Sc-268], TFF1 [Epitomics; AC-0045], TFF3, FOXA1, ERG, HepPar1, glypican 3, SALL4, OCT4, PAX2, PAX8, RCC GCDFP-15, mammaglobin, S100P, IMP3, maspin, MOC31, CEA, CA19-9, CA125, CD10, CD15, villin, and P504S) on 146 cases of breast carcinoma (98 ductal carcinomas and 48 lobular carcinomas) and 58 cases of endometrial adenocarcinoma on tissue microarray sections. The staining intensity was graded as weak or strong. The distribution was recorded as negative (<5% of tumor cells stained), 1+ (5-25%), 2+ (26-50%), 3+ (51-75%), or 4+ (>75%).

Results: The positive staining results from selected antibodies, which demonstrated diagnostic value, are summarized in Table 1. When combining ductal and lobular carcinomas, the positive staining results for GATA3 and TFF1 were 95% and 77%, respectively, with a strong and diffuse staining (3+ or 4+) in 131 cases (90%) and 79 cases (56%), respectively. For endometrial adenocarcinoma, 50 cases (88%) were strongly and diffusely (3+ or 4+) positive for PAX 8, and 36 cases (69%) were strongly and diffusely (3+ or 4+) positive for vimentin.

Table 1. Summary of immunostaining results on selected antibodies

Antibody	Breast DCA	Breast LCA	EDAC
GATA3	90/98 (92%)	48/48 (100%)	2/58 (3%)
TFF1	68/95 (72%)	41/47 (87%)	4/58 (7%)
PAX8	0	0	58/58 (100%)
p16	14/98 (14%)	0	57/58 (98%)
Vimentin	3/97 (3%)	2/48 (4%)	52/58 (90%)

DCA—ductal carcinoma; LCA—lobular carcinoma; EDAC—endometrial adenocarcinoma

Conclusions: These data demonstrate that GATA3, TFF1, PAX8, p16 and vimentin are the most effective diagnostic panel for distinguishing breast carcinoma from endometrial adenocarcinoma.

202 Verification of Rabbit Monoclonal Antibody Progesterone Receptor Clone YR85 in Invasive Breast Cancers Using Clone Pgr636

H Liu, S Muralitharan. Thermo Fisher Scientific, Anatomical Pathology Division, Fremont.

Background: Clone YR85, a relatively new rabbit monoclonal anti-progesterone receptor antibody, demonstrated potential clinical usefulness by presenting distinct nuclear staining in a set of known PR positive breast cancer samples. To further characterize the antibody, a comparison study has been carried out between this clone and the well established clone Pgr636.

Design: Three breast cancer tissue microarrays consisting of a total of 210 cases were used to evaluate the concordance of the rabbit monoclonal antibody clone YR85 and clone Pgr636. Two normal tissue microarrays and one multi-tumor microarray were stained with both clones to survey the distribution in non-breast cancer cases and to investigate possible non-specific staining. A mini PR microarray served as the control. Normal breast tissue cores and benign breast lesions were also present in some of the microarrays serving as general control. All tissues were fixed within 30 minutes of removal in 10% NBF for 24 hrs. The IHC of the two clones was performed in parallel in an Autostainer and stained using UltraVision Quanto HRP detection system. The percentage of invasive tumor cells exhibiting nuclear staining and staining intensity was reported. A cutoff of a minimum of 1% of tumor cells positive for PR in samples was considered positive.

Results: A total of 197 invasive breast cancer cases were valid for data analysis. There was a good representation of cases with various expression levels in the cohort. The overall concordance between clone YR85 and the reference clone Pgr636 was 92.9%;

the concordance for PR positive category was 92.7% and for PR negative category was 93.0%. The Cohen's Kappa Coefficient was 0.854.

In the distribution survey, the two PR clones were stained on two normal tissue microarrays and a multi tumor microarray consisting of 35 normal tissue types and 40 tumors types covering most of the common benign, malignant and metastatic tumors. As expected, clone YR85 nuclear staining was also observed in the cells of other reproductive organs other than breast. Clone YR85 staining was not found in most non-reproductive organs, except one of the five normal pancreatic tissues tested. This is consistent with the performance of the clone PgR636 which also stained positive in the same pancreatic tissue core with the same staining pattern.

Conclusions: This verification study confirms that clone YR85 performs with high concordance to the reference clone PgR636 in detecting progesterone receptor in invasive breast cancers and other reproductive organs.

203 Breast Papillary Lesion on Needle Core Biopsy: Is Surgical Excision Necessary?

L Lopez, K Woolf, D Hicks, X Wang. University of Rochester, Rochester.

Background: The upgrade rate for breast papillary lesions in excisional specimens following the core biopsies has been reported as 0 to 25%. The necessity for surgical excision of a papillary lesion is still an ongoing debate.

Design: 48 breast core biopsies with central solitary papillary lesions were identified in departmental file from 2006 to 2011. All were followed up with surgical excisions. **Results:** 24/48 of the papillary lesions were diagnosed as intraductal papilloma with or without usual hyperplasia at the time of core biopsy. Whereas, 11 were diagnosed as complex sclerotic papillary lesion, 8 as atypical papilloma without further differentiation into ADH or DCIS, and 6 as papillary carcinoma not specifying invasive versus in situ. Majority of the diagnoses were based on the morphological criteria. Immunostain for myoepithelial markers was used to help the diagnosis only in 5 cases. In the follow up excisions, 19/24 of the intraductal papillomas remained the same, 3/24 with no remaining lesion, one upgraded as with focal atypia and only one with changed diagnosis as malignant adenomyoepithelioma involving papillary lesion. All 11 complex sclerotic papillary lesions remained same in excision. While 7/8 atypical papillomas were downgraded as benign papillomas in excision, 1/8 remained the same. In retro-review, at least 6/8 "atypical papillomas" were virtually papilloma with florid ductal hyperplasia. All papillary carcinomas remained the same as carcinoma in excision.

Conclusions: The upgrade rate of papillary lesions in excision specimen in our series is almost zero, other than the case with malignant adenomyoepithelioma in excision. It indicates that as long as we follow the diagnostic criterion, it is possible to differentiate benign versus malignant papillary lesions morphologically on core biopsy, and a surgical excision is not necessary for every papillary lesions.

Immunostain for myoepithelial markers is useful but not necessary for differentiation of papillary lesions.

The high rate for downgrading in the excisions for atypical papillomas indicates that pathologists are often over cautious for the papillary lesions and turn to over diagnose this kind of lesion.

204 HER2 Dual ISH Determination of HER2 Gene Status in Breast Cancer: Interobserver Reproducibility

AA Lott Limbach, EP Downs-Kelly, BG Papouchado, RR Tubbs, C Lanigan, CN Booth. Cleveland Clinic, Cleveland, OH.

Background: The HER2 status of breast carcinoma has prognostic and treatment implications. Current guidelines from the American Society of Clinical Oncology and College of American Pathologists include immunohistochemistry and fluorescence in situ hybridization (FISH) as HER2 status testing methods. Disadvantages of FISH include the laborious assay, need for fluorescent microscopy and fluorescent signal degradation over time. The INFORM HER2 DNA Probe Cocktail assay (Dual ISH) (Ventana Medical Systems Inc., Tucson, AZ) is fully automated, is performed on formalin-fixed paraffin-embedded tissue and uses HER2 and Chromosome 17 (CHR17) specific probes to qualitatively and quantitatively assess HER2 gene status using brightfield microscopy.

Design: Prior to scoring the study slides, 5 pathologists completed training in Dual ISH interpretation via review of e-learning and reference materials, an e-learning exam, and scoring of a 30-slide test set of various HER2 amplification states (provided by Ventana). Pathologists then independently scored 86 cases of invasive breast carcinoma, blinded to the historical FISH results. The average HER2 and CHR17 copy number were recorded using a Gestalt interpretation and the HER2/CHR17 ratio was recorded (as per the package insert FDA guidelines) as amplified if the HER2/CHR17 ratio ≥ 2.0 and as non-amplified if the HER2/CHR17 ratio < 2.0 . If the HER2/CHR17 ratio was 1.8 to 2.2 (inclusive), 20 additional nuclei were counted and a new ratio was recorded based on 40 nuclei. Interobserver agreement and concordance of each observer's Dual ISH score with historical FISH results were calculated using the kappa statistic. With a kappa value $> .80$, reproducibility has been inferred from published literature to be "excellent". **Results:** Overall agreement between conventional FISH and the average Dual ISH results was 96.3%. The average interscorer Dual ISH Kappa was 0.87 while the average Dual ISH versus FISH Kappa for all scorers was 0.92. The kappa results of the interobserver Dual ISH scores are summarized in Table 1.

Table 1 Interobserver kappa values and comparison with historical HER2 FISH results

	FISH	P2	P3	P4	P5
P1*	1	0.95	0.81	0.95	0.88
P2	0.95		0.76	0.90	0.90
P3	0.81			0.81	0.74
P4	0.95				0.93
P5	0.91				

P* denotes pathologist

Conclusions: Dual ISH represents a novel and fully automated brightfield HER2 assay that generates permanent slides and demonstrates excellent concordance with conventional FISH results. Excellent interobserver interpretative reproducibility facilitates implementation into daily work flow while producing consistent and accurate results.

205 Claudin Expression in Invasive Lobular Carcinoma with an Emphasis on Pleomorphic Lobular Carcinoma

S Lu, K Singh, S Mangray, R Tavares, R Monahan, J Li, M Resnick, E Yakirevich. The Warren Alpert Medical School of Brown University, Providence, RI.

Background: Claudins are involved in the formation of tight junctions in epithelial cells. The role of claudins in breast epithelial physiology is traditionally thought to be in maintaining cellular adhesion, polarity, and barrier function. Invasive lobular carcinomas of the breast are characterized by loss of cell adhesion. The goal of this study was to evaluate the expression patterns of claudins 1,3,4,7, and 8 in invasive lobular carcinoma (ILC) with an emphasis on pleomorphic lobular carcinoma (PLC).

Design: Fifty eight cases of invasive lobular carcinoma were retrieved from the archives of Rhode Island Hospital including 35 cases of classic ILC (CLC) and 23 cases of PLC. Paraffin embedded tissue microarrays were analyzed for IHC expression of E-cadherin and claudins 1,3,4,7, and 8. The immunoreactivity was assessed based on a combined score of the extent and intensity on a scale of 0-3+.

Results: Normal breast luminal cells exhibited membranous claudin staining for all of the claudins studied. In the carcinoma tissue the staining pattern was similar to that in the normal breast with a predominant membranous staining. Loss of E-cadherin immunoreactivity was detected in all cases in both groups. Negative to weak claudin 1 staining was detected in the vast majority (94%) of CLC and 96% of PLC. Loss of claudin 3 expression was similar in CLC and PLC (79% and 78%, respectively). In contrast to claudins 1 and 3, claudins 4, 7, and 8 were significantly overexpressed (2-3+) in CLC (100%, 61%, 97%, respectively), and PLC (100%, 67%, 94%, respectively). Strong (3+) claudin 4 expression was significantly more frequent in PLC as opposed to CLC (65% and 30%, respectively, $P=0.013$). Similar to claudin 4, strong claudin 8 expression was more frequently seen in PLC than in CLC (47% and 10%, respectively, $P=0.0031$). There was a trend between claudin 4 overexpression and poor patient survival ($P=0.2$).

Conclusions: This study is the first to examine expression of the claudin protein family in ILC. Low expression levels of claudins 1 and 3 are in keeping with loss of other adhesion proteins in ILC. Overexpression of claudins 4, 7, and 8 is an unexpected phenomenon in lobular carcinoma and suggests that these proteins may be involved in progression to more aggressive tumor type. In view of the results of this study, it is likely that the traditional view of adhesion proteins being lost in ILC will need to be revised in the case of claudins. ILC may be added to the group of solid tumors where claudin expression is paradoxically increased.

206 Intra-Operative Margin Evaluation of Breast Specimens: Value of Gross Evaluation

AR Mallon, DJ Dabbs, RR Johnson, GM Ahrendt, KP McGuire, M Bonaventura, R Bhargava. Magee-Womens Hospital of UPMC, Pittsburgh, PA.

Background: Intra-operative frozen section (FS) analysis of breast tissue is generally not recommended as it is difficult to freeze adipose tissue which results in sub-optimal sections and has the potential for erroneous diagnosis. Contrary to the general belief, a recent study (Jorns et al. Mod Pathol 2011;24(suppl 1):46A-Abstract 183) suggests that the benefits of intraoperative FS for margin evaluation are under-estimated (study showed reduction in re-excision rate from 55.3% without FS to 19.4% with FS). However, the study did not evaluate if gross intra-operative evaluation would provide the same information.

Design: A retrospective evaluation of all breast segmental resections for invasive carcinoma for the calendar year 2010 was performed. All surgeries were performed by breast surgeons with median experience of >10 years. Whether an intra-operative gross evaluation was requested by the surgeon was recorded. FS for margin evaluation on breast specimens are not performed at our institution. Several factors are considered by surgeons for re-excision, that not only includes margin width (i.e. < 2 mm) but also tumor histology, co-morbidities, margin type, extent of involvement and cosmetic outcome. The number of patients that underwent second surgery for margins was used to define the re-excision rate.

Results: A total of 365 invasive carcinomas were identified. Intra-operative gross evaluation was requested on 58 (16%) invasive carcinomas. The cases where intra-operative gross evaluation was not requested (i.e. 307 cases), surgeons themselves performed small re-excisions at the time of initial surgery if they felt "clinically close" (either by palpation or specimen radiograph) to the lesion in 94 (31%) cases. The re-excision rate (i.e. second surgery) for invasive carcinomas without gross intra-operative evaluation was 19% (58 of 307) and with gross intra-operative evaluation was 7% (4 of 58). This difference in re-excision rate between the 2 groups was statistically significant ($p=0.02$).

Conclusions: The re-excision rate at our institution is at the lower end of the spectrum likely due to the high volume and sub-specialty nature of the practice. However, gross intra-operative evaluation of the thinly sliced breast specimen further reduces the re-excision rate for positive or close margins. There is no need for frozen section analyses as the benefits derived will be minimal and will result in sub-optimal evaluation of margins on permanent sections.

207 Breast Micropapillary Carcinomas: RNA-Seq and Mutation Profiling

C Marchio, DN Rodrigues, P Wilkerson, MB Lambros, B Weigelt, A Sapino, A Mackay, C Maher, R Natrajan, JS Reis-Filho. University of Turin, Turin, Italy; The Institute of Cancer Research, London, United Kingdom; Cancer Research UK London Research Institute, London, United Kingdom; Washington University School of Medicine, St Louis.

Background: Micropapillary carcinomas (MPCs) are a rare special type of breast cancer, characterised by specific morphological features and an aggressive clinical behaviour. Genomics studies have demonstrated that MPCs harbour a constellation of gene copy number changes that are distinct from that of grade- and ER-matched invasive ductal carcinomas of the breast. The aims of this study were to investigate whether MPCs would harbour recurrent fusion genes and to characterise the repertoire of mutations affecting known oncogenes in MPCs.

Design: Twenty-two (15 pure and 7 mixed) MPCs of the breast were microdissected. RNA and DNA were extracted. Six pure MPCs were subjected to massively parallel RNA sequencing. cDNA libraries were prepared according to standard mRNA prep Illumina protocols and run on the Genome Analyser Ix sequencers. Data were aligned to the genome and transcriptome using Bowtie. Mate-pairs supporting novel chimaeric transcripts were identified using Chimerascan version 4.0. Fusion genes identified were validated using RT-PCR and Sanger sequencing. Somatic mutation profiling was performed in all 22 MPCs using the Sequenom OncoCarta Panel v1.0 covering hotspot mutations in 19 oncogenes. The results were validated using Sanger sequencing.

Results: Twelve high-confidence fusion genes were found in four MPCs. Three of the chimaeric transcripts (i.e. *SLC2A1-FAF1*, *ELMO2-RAE1*, *BCAS4-AURKA*) were present in a single tumour and mapped to regions of amplification. All chimaeric transcripts were confirmed using RT-PCR and Sanger sequencing. An independent series of 12 MPCs and other types of breast cancer (n=160) were screened for fusions by RT-PCR. No recurrent fusions were identified. Forced expression of two of the in-frame fusion genes (*SLC2A1-FAF1* and *ELMO2-RAE1*) and their partner genes in MCF7 cells resulted in increased proliferation, whilst forced expression of *BCAS4-AURKA* had no effect on cell growth and proliferation. Sequenom MassARRAY analysis led to the identification of a single mutation (i.e. *PIK3CA* H1047R) in one case, which was validated by Sanger sequencing.

Conclusions: A proportion of breast MPCs harbour intra-chromosomal fusion transcripts that appear to be private events, but may play a role in tumour proliferation. Neither recurrent fusion genes nor mutations in the genes assessed by OncoCarta v1.0 are likely to account for the characteristic morphological features and aggressive clinical behaviour of MPCs.

208 Effect of Not Bisecting Mastectomy and Lumpectomy Specimens Received from Remote Sites on ER/PR Results

M Marolt, S Tawfic. Fairview University Medical Center, Minneapolis, MN.

Background: The 2010 ASCO/CAP guideline recommendations for ER/PR testing include bisecting lumpectomy/mastectomy specimens through the tumor at remote sites prior to fixation. This has become a CAP requirement in 2011. Appropriate evaluation of surgical margins is also critical for management. The purpose of this study is to determine if not bisecting the specimen affects the percentage of tumor cells staining for ER/PR and/or the intensity of staining.

Design: Lumpectomy/mastectomy specimens with no previous documented biopsy or with negative ER/PR on the diagnostic biopsy were omitted from the study. Twenty specimens received from remote sites in 2010 met the criteria. All cases were not bisected prior to fixation and transport. The following data were collected: specimen size, tumor type and size, distance from margins, cold ischemia time, time until grossing and total fixation time. IHC for ER/PR was performed and interpreted blindly by two pathologists. The results were compared with those obtained on the prior needle core biopsies. HER2 amplification by FISH was performed as applicable.

Results: The study included 2 mastectomy and 18 lumpectomy specimens. The range of specimen and tumor size was 4.0-19.0 cm (mean 8.5 cm) and 0.45-8.0 cm (mean 2.0 cm), respectively. Three cases had a positive margin; otherwise the distance to the closest margin ranged from 0.1 to 2.0 cm (mean 0.4 cm). Three cases were ductal carcinoma in-situ; the rest were invasive carcinoma. The cold ischemia time was less than 1 hr. The fixation time until grossing ranged from 4 to 24 hrs in 19 cases (mean 18 hrs), and 66 hrs in one case. The total fixation time ranged from 6 to 72 hrs. The percentage and the intensity of ER/PR positive tumor cells in the excisional specimens matched those reported for the previous diagnostic biopsies in all cases. ER and PR positivity ranged from 75 to 100% and 0% to 100%, respectively with moderate to strong staining. The two cases with HER2 amplification by FISH on the diagnostic biopsies also showed amplification on the lumpectomy specimens.

Conclusions: There was no difference in percentage of tumor cells staining for ER and PR or staining intensity (as compared to the diagnostic biopsies) when lumpectomy and mastectomy specimens were not bisected at the remote sites. This was noted irrespective of specimen size, tumor size and distance from margin. The tumors in our series had relatively high ER/PR expression with moderate to strong staining, and a larger study with more variable ER/PR expression may be needed.

209 Predicting Non-Sentinel Lymph Node Status in Breast Cancer Patients with Metastases in Sentinel Lymph Nodes

AJ McCarthy, K O'Connor, F O'Connell, MW Bennett, TJ Browne. Cork University Hospital, Cork, Ireland.

Background: Current practice is to perform a completion axillary lymph node dissection (ALND) for breast cancer patients with positive sentinel lymph nodes (SLNs), although fewer than half will have non-sentinel lymph node (NSLN) metastasis.

Our aim was to assess morphologic features of the SLN metastasis to elucidate those features that might predict NSLN involvement, thereby isolating a subgroup of patients with SLN metastases in whom ALND is not necessary.

Design: Reports from all patients who underwent SLN biopsy (SLNB) over a 1 year period were analyzed for: type, grade and size of primary tumor, and lymphovascular space invasion (LVI).

The tumor deposits within the positive SLNs were reviewed for: location (subcapsular, parenchymal, combination of subcapsular and parenchymal, and extensive), size, percentage of SLN involved, necrosis, desmoplasia, overall Modified Bloom-Richardson grade, extranodal extension, extranodal LVI, mitotic count (number of mitoses per 300 cells) and proliferative index (Ki-67 count per 10 high power fields (hpf) and per 300 cells).

Statistical analysis was performed using a statistical software package (SPSS).

Results: 331 patients had a SLNB. 71 SLNs were positive (neo-adjuvant treated patients were excluded) and these proceeded to have ALND (21 ALNDs were positive). Having a positive SLN was statistically significantly associated with: type (P=0.002), grade (P<0.001), and size (P<0.001) of primary tumor, and LVI (P<0.001).

Tumor deposits within SLNs exhibiting a desmoplastic response were more likely to have positive ALND specimens (P=0.009).

Positive ALND was not statistically significantly associated with: size of deposit, percentage of SLN involved, necrosis, overall Modified Bloom-Richardson grade, extranodal extension, extranodal LVI, mitotic count and proliferative index.

Both subcapsular and extensive deposits were more likely to be associated with positive ALNDs (however, P=0.245).

Ki-67 and mitotic counts per 300 cells of deposit in SLN had no statistically significant difference across positive and negative ALND groups. The positive ALND group had a higher Ki-67 count per 10 hpf than the negative ALND group (however, P>0.05).

Conclusions: Similar to previous studies, patients with a low probability of having a positive SLN can be identified from known pathologic features of the primary tumor. Based on the statistical significance of desmoplasia, the presence of desmoplasia within the SLN deposit appears to predict NSLN involvement, thereby potentially isolating a subgroup of patients with SLN metastases in whom ALND is indeed necessary.

210 Loss of Retinoblastoma (RB) Tumor Suppressor Expression in Breast Cancer Correlates with Better Response to Neoadjuvant Chemotherapy

JM McFalls, J Kline, GF Schwartz, AK Witkiewicz. Thomas Jefferson University, Philadelphia, PA.

Background: Neoadjuvant chemotherapy followed by surgery is standard of care for locally advanced breast cancer. However, breast cancers show a wide variation in response to neoadjuvant chemotherapy, with some achieving complete pathologic remission while others continue to progress unabated. The aim of this study was to investigate whether expression of the retinoblastoma tumor suppressor (RB), p16, estrogen receptor (ER), progesterone receptor (PR), and HER2, in pre-treatment breast cancers predicts their response to neoadjuvant chemotherapy.

Design: We retrospectively reviewed the medical records and pathology of 130 patients with breast cancer who were treated with neoadjuvant chemotherapy followed by surgical excision at our institution from 1982 to 2010. Patients for whom no tissue was available prior to neoadjuvant treatment were excluded (33 patients). Pretreatment tissue was stained with antibodies against ER, PR, Her2, RB, and p16. Medical records were reviewed for pre-treatment tumor size and stage. Post-surgical excision pathology slides were reviewed and response to neoadjuvant therapy was graded using complete pathologic remission (cPR), modified Miller-Payne score, and clinical-pathologic stage (CPS) scoring systems.

Results: RB loss was seen in 16.6% of ER positive and in 60% of triple negative breast cancers. Loss of RB significantly predicted an improved response to neoadjuvant chemotherapy, as measured by complete pathologic remission, modified Miller-Payne score, and CPS score (p value < 0.01 for all three measures).

Conclusions: Loss of RB tumor suppressor staining in pre-treatment breast cancer biopsies can be used prior to initiation of neoadjuvant chemotherapy to predict good tumor response. Patients whose tumors express RB may benefit from proceeding directly to surgical excision.

211 Insulin-Like Growth Factor Receptor in Breast Cancer

LA McLendon, C Cohen, S Patel, R Diaz, S Schmechel, A Adams, GM Oprea-Ilie. Emory University, Atlanta, GA; University of Minnesota, Minneapolis, MN.

Background: Insulin-like Growth Factor Receptor (IGFR) plays a fundamental role in cell growth and malignant transformation and is an important inhibitor of apoptosis. While cells lacking IGFR have prolonged cell cycle kinetics, cells overexpressing this tumor marker demonstrate a decreased susceptibility to apoptosis in vitro. IGFR is a membrane-bound heterotetramer with intrinsic tyrosine kinase activity and multiple downstream targets including Ras and Raf. Prior studies have shown that IGFR plays a role in proliferation of breast tissue and is over-expressed in some breast cancers (BC). We studied the expression of IGFR in BC by immunohistochemical (IHC) methods in a large series of hormone receptor positive and triple negative tumors (TNT). IGFR may be of interest in BC as a target for additional adjuvant treatment.

Design: Invasive mammary carcinomas (IMC) diagnosed during a 7-year period were reviewed. The IMC markers ER, PR, and Her-2 scored by the new CAP standards were included. The tumors were studied as Her-2 positive, TNT, and hormone receptor positive, which includes ER and PR positive cancers. Tissue microarrays (TMAs) were constructed with two 1 mm representative cores from each IMC and were stained with IGFR monoclonal antibody. The scoring of the IHC results was semiquantitative, using 0-3 for intensity and a percentage of tumor cells staining. Tumors that scored 2-3 for intensity with ≥10% of tumor cells staining were considered positive.

Results: Of the 350 IMC tumors stained for IGFR, 327 are positive (93.4%). The age at diagnosis varies from 24-90 years, and the relationship between IGFR positivity and age is not significant. IGFR positivity is lower in TNT than non-TNT (92.2% vs 94.2%; $p = 0.01$). IGFR positivity was more prevalent in hormone receptor positive IMC than in hormone receptor negative tumors (97.4% vs 88.5%; $p < 0.001$). Positivity of IGFR in Her-2 positive/hormone receptor negative IMC is significantly lower than in combined TNT and hormone receptor positive tumors (60.0% vs 93.9%; $p = 0.01$). Of African American patients, 198 of 218 (90.8%) were positive for IGFR, while Caucasian patients had IGFR positive tumors in 107 of 109 (98.2%) with $p < 0.001$.

Conclusions: 1. There is differential expression of IGFR among breast cancers, and this expression is related to the tumor markers: ER, PR, and Her-2.

2. IGFR positivity is related to patient race.

3. There is no correlation between the age of diagnosis of IMC and IGFR positivity.

4. IGFR positive breast tumors could be amenable to specific anti-tyrosine kinase type drugs.

212 Polycomb Genes and Large Non Coding RNAs Expressions in Invasive Breast Carcinomas: New Clues for Epigenetic Targeted Therapies

D Meseure, K Drak Alsibai, M Trassard, R Lidereau, I Bieche. Institut Curie, St Cloud, France.

Background: Epigenetic deregulation and carcinogenesis are intimately connected and gene silencing is a major consequence of epigenetic modifications in cancer cells. Polycomb group proteins (PcG) play important roles by inhibiting chromatin remodeling and transcription, silencing tumor suppressor genes, regulating stem cells and interconnecting with Wnt/beta-catenin, TGF-beta and Sonic-Hedgehog pathways. There are at least two complexes: PRC1 (CBX7/8, HPC, Bmi1, RING) and PRC2 (EZH2, EED, SUZ12, Jarid). Histone methyltransferase EZH2 and CBX7 act as transcriptional repressors of many genes and are particularly implicated in silencing of the INK4b/ARF/INK4a locus.

Design: By using real time RT-PCR in a series of 80 IBCs, we quantified mRNA expression levels of *ANRIL*, *HOTAIR*, *EZH2*, *SUZ12*, *CBX7*, *Bmi1*, *HMGAI*, *RUNX3*, *HDAC2*, *TWIST1*, *VIM*, *P16*, *P15* and *P14/ARF* genes. Immunohistochemistry (IHC) in a series of 70 IBCs and a retrospective RNA series of 453 well-characterized tumors were used to confirm results and establish statistical correlations.

Results: RT-PCR revealed high mRNA levels of *ANRIL*, *HOTAIR*, *EZH2*, *SUZ12* and *Bmi1* but an unexpected loss of expression of *CBX7*. Moreover, underexpression of *CBX7* was associated with overexpression of *HMGAI*, *MiR181b*, *P16*, *P15*, *P14/ARF*, *HDAC2*, *VIM* and *TWIST1*. IHC showed intense nuclear positivity with anti EZH2 and HMGAI Abs, variable nuclear and cytoplasmic staining with anti P15 and P16 Abs and no staining with anti CBX7 Abs. Mutual positive correlations were observed between (i) *ANRIL*, *EZH2*, *SUZ12*, *P14/ARF*, *P15*, *P16* and (ii) *CBX7*, *CDHI*, *VIM*, *TWIST1*. No correlation was observed between *Bmi1*, *TWIST1* and *HOTAIR*.

Conclusions: Polycomb *EZH2/SUZ12/Bmi1* and the Large non Coding RNAs *ANRIL* and *HOTAIR* are overexpressed in invasive breast carcinomas. Loss of expression of *CBX7* might be explained by *HMGAI/MiR181b* overexpression, is associated with *P14/ARF*, *P15* and *P16* overexpressions. *CBX7* seems to have oncosuppressive properties in IBCs and its underexpression is correlated with a more aggressive phenotype, partially via down-regulation of E-cadherin expression.

213 Breast Implant Capsule-Associated Anaplastic Large Cell Lymphoma (BIC-ALCL)

C Mies, A Goyal, A Bagg, DM Frank, FG Barr, AL Dara, DB Roy, S Jaffer. Hospital of the University of Pennsylvania, Philadelphia, PA; Mount Sinai Medical Center, New York, NY.

Background: The US-FDA recently issued preliminary findings of an analysis to assess a possible association between anaplastic large cell lymphoma (ALCL) and breast implants. The analysis was prompted by a small (~30), but growing, number of cases of a rare form of lymphoma in women with breast implants, typically arising within the capsule and causing a clinically-evident peri-implant fluid accumulation. We describe 3 new cases of breast implant-associated anaplastic large cell lymphoma (BIC-ALCL) that highlight its characteristic clinical and pathologic features.

Design: We studied the histopathologic characteristics, molecular pathology and clinical course of 3 cases of BIC-ALCL.

Results: The patients were 46, 67 and 67 years old, respectively, and all had breast implant reconstruction following mastectomy for cancer. All 3 presented with peri-implant fluid accumulation occurring 5 to 13 years after reconstruction. Gross exam showed the affected peri-implant capsules were thickened. Microscopy showed non-cohesive, enlarged, atypical-appearing cells, some with reniform or horseshoe-shaped nuclei, in eosinophilic material adherent to the inner capsule surface; the atypical cells also infiltrated the inner capsule layers. In all 3 cases, the ALCL cells were ALK-negative and positive for CD30 and EMA; CD3 and CD4 were positive in 1 case each and both of these showed a monoclonally rearranged T-cell receptor γ -chain gene (*TRG@*). Flow cytometry analysis of peri-implant fluid from the third case detected a predominance of T cells, but molecular studies on the fluid did not detect a *TRG@* gene rearrangement. All 3 had stage I lymphoma, confined to the breast. Two patients were treated with chemotherapy; one also had a stem cell transplant. All 3 are alive with neither breast cancer- nor lymphoma recurrence 36, 12 and 7 months after diagnosis of BIC-ALCL.

Conclusions: Breast implant exchange with capsule resection prompted by peri-implant fluid accumulation should be carefully examined for BIC-ALCL. Clues to diagnosis are the unusual clinical presentation, a thickened scar capsule and histologic sections showing an atypical cellular infiltrate. These findings should prompt appropriate immunohistochemical stains and molecular analysis, where feasible.

214 Role of HER4 in Trastuzumab Therapy Effectiveness for Metastatic Breast Cancer

EC Minca, BP Portier, Z Wang, C Lanigan, E Downs-Kelly, RR Tubbs. Cleveland Clinic Foundation, Cleveland, OH.

Background: HER2 amplification and overexpression in metastatic breast carcinoma is an indication for targeted therapy with Trastuzumab. Despite improving overall survival, Trastuzumab treatment has a highly variable responsiveness in individual patients. Identification and accurate detection of molecular markers that are predictive of therapy outcome are clinically relevant. Recently, a less characterized member in the ERBB family, HER4, has been hypothesized to promote pro-apoptotic signaling, thus possibly sensitizing tumor cells to anticancer agents. In this study we sought to determine whether knowledge of HER4 and HER2 expression status can be utilized to predict effectiveness of Trastuzumab-based therapy in cases of metastatic breast cancer.

Design: Study cases included 30 excisional samples and 3 core biopsies from 33 patients that subsequently received Trastuzumab-based therapy for metastatic breast cancer. All samples were analyzed for HER4 and HER2 by IHC (E200 and 4B5 respectively) and Quantitative-Real Time-PCR (Q-RT-PCR). An immunostaining scoring system for HER4 was developed based on intensity and percentage of positive cells. IHC for HER2 was performed following ASCO/CAP guidelines. IHC scores were correlated with mRNA quantification by Q-RT-PCR for both HER4 and HER2. Electronic medical records were reviewed to determine the clinical outcome as time to progression (TTP). Statistical analysis was performed using log-rank test.

Results: The study population had a median TTP of 7 month. IHC and Q-RT-PCR showed a good correlation for both HER4 and HER2 expression ($R^2=0.6$) and segregated the patient population into four groups: HER4/HER2 double positive (11), HER4-positive/HER2-negative (5), HER4-negative/HER2-positive (13) and HER4/HER2 double negative (4). Of these, the double positive group had the longest median TTP (12 months compared to 5, 7 and 7.5 respectively) and a distinct Kaplan Meier distribution. The higher TTP for the double positive group approached statistical significance (small sample size) when compared to other HER4/HER2 combinations ($p=0.09$).

Conclusions: HER4 expression is variable in HER2 positive breast tumors. Patients with tumors co-expressing HER4 and HER2 might benefit from longer TTP with trastuzumab-based treatment for metastatic disease. This finding suggests a potential role for utilizing HER4 status as a predictor for therapy effectiveness. Therefore, further investigation of combined HER4 and HER2 testing in a larger patient cohort is warranted.

215 DCIS Heterogeneity: An Integrated RNA-miRNA Analysis

JC Moreno, R Nair, NA Miller, BJ Youngson, V Jakovlev, D McCready, SJ Done. Campbell Family Institute for Breast Cancer Research, Toronto, ON, Canada; University Health Network, Toronto, ON, Canada; University of Toronto, Toronto, ON, Canada; St. Michael's Hospital, Toronto, ON, Canada.

Background: Ductal carcinoma in situ (DCIS) is a heterogeneous, pre-invasive malignancy that can be a precursor to invasive breast cancer, however not all lesions progress. Limited ability to prognosticate progression leads to over treatment of a significant number of patients. Mapping RNA and miRNA molecular changes simultaneously may provide a better understanding of DCIS heterogeneity and help us predict its clinical behavior.

Design: Five cases of extensive DCIS were selected. From each case six areas (5 DCIS, 1 normal) were microdissected. The epithelium and the peri-lesional stroma were microdissected separately. RNA and miRNA were extracted and microarray analysis performed.

Results: An epithelial RNA signature of 317 probes clusters samples into two groups, one overexpressing genes involved in cell proliferation and the other overexpressing genes involved in nuclear translocation of proteins, protein folding and NF- κ B signalling. Three cases (60%) had samples belonging to both groups. A stromal RNA signature clusters samples into two groups, one enriched for positive regulators of transcription, gene expression and STAT3 phosphorylation, the other overexpressing genes involved in cell junction organization and assembly. Four cases (80%) had samples belonging to both groups. A signature of 63 miRNAs separate epithelial samples into three distinct groups, and a signature of 42 miRNAs cluster stromal samples into 4 groups. In epithelial samples, 50% (15/30) of the overexpressed miRNAs control 30 (9%) of the over/underexpressed genes in the RNA signature. In stromal samples 26 out of 45 miRNAs control 125 (13%) genes in the stromal signature.

Conclusions: We analyzed RNA and miRNA simultaneously on the same samples. Results show that DCIS and adjacent stroma with different signatures coexist within the same breast. Signatures include several genes known to be altered in breast cancer. Interestingly even apparently normal stromal samples have signatures that cluster them into groups with proliferating or protective genes. RNA signatures that support proliferation in both the epithelium and the stroma are seen in 43% (7/16) of samples. These studies add to our understanding of the biology of DCIS and may result in genetic signatures which if present can predict for progression to invasive breast cancer.

216 Comparison of Tumor Biomarkers in Primary Breast Carcinoma and Paired Metastases

G Moses, Y Peng, Y Fang, S Sahoo, V Sarode. UT Southwestern Medical Center, Dallas, TX.

Background: Tumor biomarkers such as ER and HER2 may change between primary breast cancer and subsequent distant metastases. This change may have therapeutic implications. Loss of ER is an established predictor of poor response to endocrine therapy. The aim of this study is to determine changes in ER, PR, HER2, Ki-67 and p53 between primary breast cancer and metastases.

Design: Forty-six female patients with paired primary breast carcinomas and distant metastases were identified from the UT Southwestern Medical Center pathology files

and analyzed retrospectively. Tumor biomarkers (ER, PR, HER2, Ki-67, and p53) were performed prospectively at the time of diagnosis using routine immunohistochemistry and image analysis. All IHC positive HER2 was confirmed by FISH. Biomarker expression was compared on primary and metastatic tumor pairs.

Results: In the primary tumors, luminal B subtype was most common, 25 of 46 (54.3%), followed by triple-negative (17.4%), luminal-HER2 (15.2%), HER2 (10.9%), and luminal A (2.2%). Sites of metastasis were skin (13), bone (11), distant lymph nodes (10), serous cavities (8), lung (5), liver (3), gynecologic tract (3), and brain (2). Comparison of tumor markers between paired primary tumors and metastases are shown in the table.

Biomarker Changes in Paired Tumors

Variable	Primary	Metastasis	Change	P Value
ER+ (>1%)	33	25	-8	0.0455
ER-	13	22	+9	
PR+ (>1%)	19	9	-10	0.0433
PR-	26	24	-2	
HER2+	12	12	0	0.4795
HER2-	33	31	-2	
Ki-67 >14%	43	36	-7	0.0771
Ki-67 <14%	1	0	-1	
p53 >10%	22	15	-7	0.3428
p53 <10%	22	19	-3	

Conclusions: Our results indicate that a significant number of metastases either gain or lose ER and/or PR compared to the primary tumor. There is no change in HER2 status, Ki-67, or p53 in metastatic sites. Biomarkers performed on metastatic tumors are important in making treatment decisions.

217 Type 2 3a/Type 5 17β-HSD (AKR1C3) Is a Negative Regulator of Breast Cancer Proliferation: An Immunohistochemical and In Vitro Study

P Murugan, H-K Lin, W Wu, V Miller, Q Yang, K-M Fung. University of Oklahoma Health Sciences Center, Oklahoma City.

Background: Hormone dependent malignancies require local (paracrine and intracrine) concentrations of steroid hormones that can be regulated by hydroxysteroid dehydrogenases (HSDs) in the target tissue. HSDs, members of the aldo-keto reductase superfamily (AKR1), convert potent steroid hormones into cognate inactive metabolites and vice versa. AKR1C3, or type 2 3a/type 5 17β-HSD, is an isoenzyme that can alter the local concentration of androgens and estrogens. Its role may be particularly important in hormone dependent malignancies of the aging populace where the gonadal-pituitary axis is compromised. We investigated the expression of AKR1C3 in normal and neoplastic breast tissue.

Design: Immunohistochemistry for AKR1C3 was performed on formalin-fixed, paraffin embedded sections [47 breast specimens including 35 with normal lobules, 38 with normal ducts, 9 lactating adenomas, 19 ductal carcinomas in-situ (DCIS) and 18 infiltrating ductal carcinomas (IDC)]. Immunoreactivity was scored as negative (<5%), 1+ (6-25%), 2+ (26-75%) and 3+ (76-100%). In addition, stable transfection for expression of AKR1C3 was performed on T47D ductal breast carcinoma cells with a pLNCX-AKR1C3 expression construct and cell growth was quantified using a colorimetric XTT cell proliferation assay kit. Appropriate controls were employed.

Results: We demonstrated a uniform, diffuse, and strong expression of AKR1C3 in lactating adenomas. In general, other breast tissue demonstrated focal, but definite, immunoreactivity. The majority of normal ducts showed positive staining (92.1%, 35/38). Normal lobular staining (97.1%, 34/35) was more prominent than ductal expression. In contrast, the expression of AKR1C3 was reduced in DCIS (52.6%, 10/19) and more so in IDC (16.6%, 3/18). In addition, the T47D-AKR1C3 transfectants exhibited significantly suppressed cell growth (8-10 folds) as compared to T47D-mock transfectants.

Conclusions: These findings suggest that AKR1C3 may play an important role in the physiology and pathology of mammary epithelium. Suppressed AKR1C3 expression may represent one of the features that promotes tumorigenesis. The mechanism is unclear but may be influenced by loss of androgen mediated inhibitory effect on breast cancer cells as a result of AKR1C3 deprivation. The influence of AKR1C3 on mammary epithelium requires further investigation.

218 CD105 (Endoglin) Expression in Tumor Cells Associated with HER2 Positive Breast Cancers and Decreased Disease-Free Survival in African American Women

TJ Naab, LJ Ricks-Santi, YM Kannan, AK Esnakula. Howard University Hospital, Washington, DC; Howard University Cancer Center, Washington, DC.

Background: CD105(Endoglin) is a membrane glycoprotein and functions as a component of the transforming growth factor-β receptor complex. Its expression is selectively upregulated in small, immature tumor vessels in malignant tumors. High grade malignant tumors, e.g., melanoma cells and ovarian serous carcinoma cells, have shown cytoplasmic CD105 expression. The significance of CD105 cytoplasmic expression in human breast cancer has not been established. The object of our study is to evaluate the association of CD105 cytoplasmic expression in tumor cells in the four major subtypes (Luminal A, Lumina B, HER2 positive, Triple Negative) and other clinicopathological factors including age, grade, tumor size, stage, regional node status, and disease-free survival in African American women.

Design: Tissue microarrays were constructed from optimally-fixed formalin-fixed, paraffin-embedded tumor blocks from primary breast carcinomas in 202 African-American females. Two separate 1mm cores represented each case. Five micrometer sections were stained with a mouse monoclonal antibody against CD105 (4G11, Leica, IL, USA). The sections were evaluated for the intensity of reactivity (0-3) and the percentage of reactive cells; an H-score was derived from the product of these measurements. Cases were categorized as having negative (score=0) or positive (score>0) cytoplasmic expression in tumor cells. Bivariate analysis was done via χ² analysis and survivability data was calculated via the generation of Kaplan-Meier curves (SPSS v19). Statistical significance was assumed if $p < 0.05$.

Results: CD105 cytoplasmic tumor cell expression significantly correlated with HER2+ subtype ($p < 0.0001$), Luminal B subtype ($p < 0.01$), tumor Size ($p < 0.01$), HER2 positivity ($p < 0.0001$) and decreased disease-free survival ($p = 0.038$). No correlation was seen with tumor cell CD105 cytoplasmic expression and other prognostic parameters.

Conclusions: Our results show a significant correlation of CD105 cytoplasmic expression with HER2+ subtypes and decreased disease-free survival. In animal models and in vitro studies, anti-CD105 monoclonal antibodies induced regression of preformed tumors and inhibited formation of new tumors. In women with HER2+ breast cancers, targeted therapy with anti-CD105 mAbs could potentially attack not only tumors with high microvessel density but also the breast cancer cells as well.

219 Distribution Patterns of Micrometastases and Isolated Tumor Cell Clusters (ITC) in Sentinel Lymph Nodes from the NSABP B-32 Trial

SR Nankoe, JM Skelly, T Ashikaga, SP Harlow, DN Krag, DL Weaver. University of Vermont College of Medicine, Burlington, VT.

Background: ITCs and micrometastases in sentinel nodes were independent prognostic variables in the analysis of NSABP B-32 data; however, differences in overall survival were minimal: 0.6% and 2.4%, respectively (NEJM 2011;364:412-421). Other factors associated with metastases may have predictive value.

Design: 174 of 616 (28%) occult metastasis positive cases from B-32 were reviewed to discover and quantify potential prognostic variables including: ITC pattern (P1, single afferent; P2, two afferents; P3, >2 afferents or subcapsular clusters >5 linear mm or >33% circumference); micrometastasis pattern (P5, one subcapsular; P6, one parenchymal; P7, two subcapsular; P8, one subcapsular and one parenchymal; P9, two parenchymal; P10, >2 foci); area of involvement of close clusters (A0, n/a; A1, up to 1mm; A2, >1 up to 2mm; A3, >2 up to 3mm); maximum depth from capsule (mm); and ITC total cell count. For pattern (P) assessment, at least 2.2 mm of uninvolved nodal parenchyma was required between cluster groups to be considered separate afferents. Micrometastasis patterns with single cells surrounding a larger cluster (eg P5s) were noted.

Results: 106 of 143 (74%) ITCs were single afferent (P1) pattern and 24 of 31 (77%) micrometastases were single subcapsular (P5) pattern. For tightly clustered groups, area of involvement was up to 1mm (n=10), >1 up to 2mm (n=2), >2 up to 3mm (n=2) or not relevant (n=160). Depth from capsule was <0.1mm (n=40; 23%), 0.1-0.5mm (n=93; 53%), 0.6-1.0mm (n=19; 11%), 1.1-2.0mm (n=17; 10%), and >2.0mm (n=5; 3%). Maximum total cell counts for ITCs in a single node cross section were <100 cells (n=121), 100-200 cells (n=17), >200 cells (n=5).

Conclusions: ITCs are most likely to be associated with a single afferent lymphatic while micrometastases are most likely to be a single subcapsular focus; other patterns identified may indicate higher prognostic risk. Depth from capsule was widely distributed and may represent a prognostic variable worth further investigation. Tightly grouped ITC clusters with an area of involvement in the micrometastasis range are infrequent (8%) and unlikely to assist in N-classification. Similarly, ITC cases with >200 cells in a single node cross section were infrequent.

Patterns of ITCs and Micrometastases

Pattern	Number of Cases	Percent	Percent of ITCs	Percent of Micromets
P1	106	60.9	74.1	-
P2	17	9.8	11.9	-
P3	20	11.5	14.0	-
P5	14	8.1	-	45.2
P5s	10	5.8	-	32.3
P6	3	1.7	-	9.7
P6s	1	0.6	-	3.2
P7s	1	0.6	-	3.2
P10	2	1.2	-	6.5

220 Clinical Outcome in Pleomorphic Lobular Carcinoma

S Narendra, SM Jenkins, RG Gamez, A Nassar. Mayo Clinic, Rochester, MN.

Background: Pleomorphic lobular carcinoma (PLC) was first described by Dixon et al. in 1982 as a variant of infiltrating lobular carcinoma (ILC). It has a typical architectural pattern of ILC; however, the neoplastic cells show marked nuclear atypia and pleomorphism. This variant is known to be multicentric and bilateral. Multiple studies have been performed that have shown a decrease in overall survival when compared to classic ILC. This study was undertaken to assess the overall outcome of patients with diagnosis of PLC and to assess the treatment modalities offered to patients with PLC.

Design: 39 cases of PLC were retrieved from the pathology files between 1985-2010. The H&E slides were reviewed and E-cadherin performed on all cases for confirmation. Clinical data was assessed and analyzed for patient age, time of diagnosis, type of surgical treatment, lymph node status, post-surgical treatment including radiation, hormonal and chemotherapy, recurrence and metastases, ER, PR and HER2 receptor status.

Results: Median age at the time of diagnosis was 61 years (range from 35.0 to 86.0). Of the 39 cases, 66.7% (26 patients) underwent mastectomy and 35.9% (14) had wide local excision. One patient underwent both mastectomy and wide local excision (WLE). The mean tumor size was 3.0 cm (range from 0.3 to 17.5 cm). Lymph node status was available for 38 patients. Most patients (52.6%, n=20) did not have any positive nodes, 21.1% (n=8) had 1-3 positive nodes, and 26.3% (n=10) had more than 3 positive nodes. In-situ component was present in 89.5% (34 of 38 patients for which data were available). Hormonal treatment was given to 48.7% (19 patients), chemotherapy to 41% (16) and radiation to 56.4% (22). The receptor status was available on 38 patients and 92.1% were ER positive, 71.1% were PR positive and 9.7% were HER2 positive. Almost one-third cases (33.3%) had recurrence or metastases. After a follow-up ranging from 208 days to 32 years, 7.7% are alive with disease, 79.5% are alive with no disease and 12.8% died of disease.

Conclusions: Our study showed that there was significantly higher risk of recurrence/metastases for stage N3 ($p = 0.02$), WLE ($p = 0.03$), more positive lymph nodes ($p = 0.003$), and older age ($p = 0.03$). The estimated median time-to-recurrence/metastasis (Kaplan-Meier) was 12.4 years (95% CI: 6.9 to 23.6).

221 Cytokeratin 5/6 Negative Atypical Ductal Hyperplasia Predicts Disease Progression in Subsequent Breast Biopsies

JC Nguyen, F Hasteh, GY Lin, N Weidner. The University of California San Diego, San Diego, CA; Clarient, Inc., Aliso Viejo, CA.

Background: Management of atypical duct hyperplasia (ADH) of the breast remains problematic. Cytokeratin 5/6 (CK 5/6) is expressed in benign intraductal lesions, but absent in ADH, ductal carcinoma in situ (DCIS), and invasive carcinoma. Thus, absence of CK 5/6 immunoreactivity in ADH found in core biopsies may predict disease progression within follow-up specimens.

Design: To study this hypothesis, we examined one hundred and five (105) consecutive breast core biopsies with ADH. CK 5/6 immunostaining was performed and correlated with follow-up findings.

Results: Of the 105 core biopsies, twenty (20) showed positive CK 5/6 staining within the ADH and seventy-six (76) showed negative CK 5/6 staining. The remainder had the ADH exhausted upon recuts.

Of the twenty cases with CK 5/6 positive ADH, thirteen had a subsequent follow-up breast biopsy or excision. None showed disease progression, that is, none had DCIS or invasive carcinoma. More specifically, nine (69%) had no evidence of ADH, DCIS, or invasive carcinoma. However, four (31%) had persistence of ADH.

Of the seventy-six cases with CK 5/6 negative ADH, sixty-four (64) had a subsequent follow-up breast specimen. Nineteen (30%) had no evidence of ADH, DCIS, or invasive carcinoma. Twenty-one (33%) had persistent ADH, nineteen (30%) had progression to DCIS, and five (8%) had progression to invasive carcinoma.

Conclusions: We demonstrate that CK 5/6 expression is useful in predicting disease progression in a subsequent breast biopsy or excision. A majority (69%) that showed positive CK 5/6 staining of ADH did not have evidence of ADH, DCIS, or invasive malignancy in subsequent specimens. However, when CK 5/6 was negative within ADH, the subsequent specimens showed either persistent ADH or disease progress in 70%. Moreover, of the latter group thirty-eight (38%) of the subsequent specimens showed disease progression to DCIS or invasive carcinoma. Thus, there is utility of determining CK 5/6 status of the ADH in core breast biopsies. If the ADH is CK 5/6 positive, close clinical follow-up may be adequate, instead of immediate surgical management. In contrast, patients with CK 5/6 negative ADH would likely benefit from immediate excisional surgery.

222 Conservative Surgery for Breast Cancer: Comparison of Two Surgical Techniques To Obtain Negative Margins

J Niakan, S Fineberg. Montefiore Medical Center, Bronx, NY.

Background: Margin status is the most important determinant of local recurrence after breast conservative surgery for breast cancer (BC). Literature suggests that lumpectomy with separate cavity margins (CM technique) reduces positive margin rate (mr) compared to lumpectomy alone. Another technique, which includes intraoperative inking and gross margin assessment of a lumpectomy with the addition of intraoperative excision of grossly close margins (LM technique) also reduces the positive mr compared to lumpectomy alone. We compare these two methods (CM vs LM) for margin status, volume of tissue and slide production.

Design: We searched pathology data from the Medical Center from 2010 to July 2011 for cases of BC removed using the CM or the LM techniques. In the CM technique a unoriented lumpectomy is received along with 4 separate margins designated medial, lateral, inferior and superior. Anterior and deep margins are received in some cases. In the LM technique a oriented lumpectomy specimen is inked and sectioned intraoperatively by the pathologist alongside the surgeon. Additional margins are taken if a grossly close margin is identified. We identified 161 cases with 82 cases included in the CM technique (49 invasive and 33 DCIS) and 79 cases in the LM technique (49 invasive and 30 DCIS). We compared margin status, volume of tissue and slide production. A positive margin was defined as less than 2mm. Anterior and deep margins were not considered in the analysis.

Results: In the CM group, a positive margin was present in 20 of 82 cases (24%). In the LM group a positive margin was present in 15 of 79 cases (19%) (p=0.44). The positive mr for invasive BC was 16% for LM technique and 18% for CM technique. The positive mr for DCIS was 23% for the LM technique and 33% for the CM technique. Gross intraoperative examination of margins in LM cases resulted in additional separate margins being obtained intraoperatively in 17 of 79 cases. The average volume of tissue excised for CM was 100 cm³ and for LM was 111 cm³. The number of glass slides per case was 37 for CM and 18 for LM.

Conclusions: CM and LM techniques both provide excellent and comparable negative margin rates for breast conservative surgery for invasive BC. Our data suggest that negative margin rates may be better for LM technique than CM technique in cases of DCIS as a continuous piece may best reflect the ductal anatomy. This however requires confirmation with a larger data set. The volume of tissue removed in both techniques is similar however glass slide production is more than double for CM over LM.

223 Applying the American College of Surgeons Oncology Group Z0011 Trial; Can Histological Parameters Predict Axillary Nodal Understaging in Breast Carcinomas ?

KM O'Connor, AJ McCarthy, F O'Connell, TJ Browne, MW Bennett. Cork University Hospital, Cork City, Ireland.

Background: The American College of Surgeons Oncology Group Z0011 trial demonstrated that T1-T2 breast carcinoma patients with one or two positive sentinel lymph nodes, treated with whole-breast irradiation and systemic chemotherapy who do not proceed to axillary dissection do not have inferior survival, compared to those who do have axillary dissection. The implication is that such patients no longer require axillary lymph node dissection (ALND). The aim of this study is to determine whether

application of the Z0011 trial would understage a proportion of patients and potentially lead to their undertreatment. We further aimed to investigate whether primary tumour and sentinel nodal metastasis characteristics could aid identification of understaged tumours.

Design: 331 consecutive breast carcinoma cases were analysed of whom 68 patients with T1-T2 tumours underwent sentinel lymph node (SLN) biopsy and axillary clearance. Main tumour characteristics analysed included grade, size, lymphovascular invasion and hormone status. Nodal metastasis characteristics analysed included grade of metastasis, nuclear grade, mitotic count / 300 cells, Ki-67/10HPF and Ki-67 per 300 cells.

Results: 59 patients (87%) had 1 or 2 positive SLNs and 17 (29%) of these had further positive nodes on axillary dissection. Of these 17 patients 7 (12%) were upstaged. Of these patients the average tumour size was larger in those who were upstaged by their axillary dissection compared to those who remained at the same stage (3.4cm vs. 2.4cm). Tumour grade, lymphovascular invasion, receptor status, SLN metastasis grade, Ki-67/10HPF and per 300 cells on the SLN metastasis and mitotic count /300cells on the SLN metastasis were not associated with nodal upstaging at subsequent axillary dissection (p > 0.05).

Conclusions: If the results of the Z0011 trial are applied as currently suggested a significant number of patients will be understaged by omission of axillary clearance (12%). Tumour size is larger in these understaged patients, suggesting further analysis of this parameter in predicting non sentinel lymph node metastasis in T1- T2 tumours with one or two positive sentinel lymph nodes is warranted.

224 The Relation between Melatonin MT1 Receptor and Oncotype Recurrence Score in HER 2- Positive and Negative Breast Cancers

GM Oprea-Ilie, E Haus, LA McLendon, LL Sackett-Lundeen, R Busch, A Adams, C Cohen. Emory University, Atlanta, GA; University of Minnesota, Minneapolis, MN; Health Partners, St. Paul, MN.

Background: Melatonin, the main secretory product of the pineal gland regulates cell proliferation via the melatonin receptor MT1 (MT1R). Anti-proliferative actions of melatonin on human and animal cell lines have been reported in breast cancer (BC). These oncostatic actions of melatonin are enhanced by MT1R overexpression and by melatonin receptor agonists, and they are inhibited by luzindole, an MT1 inhibitor.

At physiologic concentrations, melatonin suppresses the growth of human BC cell lines that are estrogen receptor alpha (ER α) positive and some that are ER α negative in vitro and in in xenograft models. Most BC express MT1R. The relationship between MT1 expression and genetic factors determining the behavior of breast cancer is unknown. In tumor cells, melatonin interacts with hormonal and other factors, including the epidermal growth factors. We aim to investigate the presence of melatonin MT1 receptors in relation to breast cancer markers (ER, PR, HER2/neu) and to the Oncotype recurrence score (ORS).

Design: 130 invasive mammary carcinomas (IMC) were included. Tissue microarrays constructed with two 1 mm cores from each BC were stained with a polyclonal antibody to MT1 (Chemica International 1/40). The product of staining intensity (1-3) and % of positive cells gave the numerical score (NS). BC markers: ER, PR and Her2/neu (HER) were studied by immunohistochemistry (IHC) with HER confirmed by FISH when equivocal. ORS on ER-positive, lymph node-negative BC was performed by Genomic Health, Redwood City California.

Results: 130 BC were studied. The correlation of NS of MT1R correlates negatively with the ORS (Table 1).

MT1R and Oncogene Recurrence Score

df	F-Test	p Value	No	IR	Y Intercept	Slope
1	4.089	0.0453	126	-0.17867	21.541	-0.019

Higher ORS, with worse prognosis and tendency for progression, is associated with lower MT1 receptor expression.

The MT1 receptor score is not statistically different between HER2 positive and negative, hormone positive and negative BC. (Table 2)

MT1 Receptor and BC Phenotype:

Phenotype	Number Positive/Negative	% Positive
HER2	13/75	15
ER	58/30	66
PR	47/41	53

ANOVA: NS

Conclusions: 1. In animal studies the MT1R relates to tumor inhibition and better prognosis. In our study, in human breast carcinomas the higher the Oncotype recurrence score, indicating unfavorable course, the lower MT1R.

2. A possible relation of genetic determinants of tumor behavior with MT1R expression is of interest in breast oncogenesis.

225 Chromosome 17 Polysomy: Correlation with Histological Parameters and HER2/Neu Gene Amplification

M Orsaria, S Kheifja, N Buza, A Kamath, P Hui. Yale University, New Haven, CT; Azienda Ospedaliero-Universitaria S. Maria della Misericordia, Udine, Italy.

Background: HER2 gene amplification is present in the majority of invasive breast carcinomas that have HER2 protein overexpression. A subset of breast cancers harbor an increased chromosome 17 copy number (polysomy 17), frequently associated with comparable HER2 copy number increase. We investigated the clinicopathologic significance of polysomy 17 in correlation with various histological parameters and HER2 gene amplification.

Design: Surgical specimens of 266 consecutive cases of primary invasive breast carcinomas were selected from a single tertiary medical center. HER2 gene status and chromosome 17 copy numbers were assessed by dual-color fluorescent in situ hybridization (FISH). Chromosome 17 polysomy was determined by the presence of ≥ 3 average CEP17 signals per average nucleus of 30 invasive tumor cells.

Results: Overall 63 tumors (23.7%, 63/266) harbored polysomy 17. Carcinomas

with polysomy 17 were associated with adverse histological indicators including high histological grade, high nuclear grade, poor Nottingham Prognostic Index, advanced local tumor extent (pT4) and progesterone receptor negativity. Polysomy 17 was more frequently observed in HER2 unamplified (71.4%) than in HER2 amplified cases (23.8%). However, polysomy cases were more often HER2 3+ by immunohistochemistry (17.5%, 11/63) than the nonpolysomy cases (5.9%, 12/203). Five cases (2%, 5/266) had HER2 protein overexpression (3+ by immunohistochemistry) but failed to demonstrate the HER2 gene amplification by FISH, none of which had more than 6 CEP17 signals per average nucleus.

Conclusions: In conclusion, polysomy 17 is significantly correlated with several adverse histological parameters including high histological grade, high nuclear grade, poor Nottingham prognostic index, advanced local tumor extent and PR negativity. Polysomy 17 is common to both HER2 amplified and unamplified tumors. In the absence of the gene amplification, HER2 protein overexpression may be explained by other mechanisms including the transcription upregulation and polysomy 17.

226 Clinical Role of Total Osteopontin and Osteopontin-c mRNA in Subtypes of Breast Carcinoma

F Ortiz-Martinez, FJ Gutierrez-Avino, D Giner, D Ciprian, L Andres, E Adrover, FI Aranda, E Lerma, G Peiro. Hospital General Universitari, Alacant, Spain; Hospital de Cruces, Barakaldo, Spain; Hospital de la Santa Creu i Sant Pau, Barcelona, Spain.

Background: Osteopontin (OPN), a secreted phosphorylated glycoprotein, promotes cell tumor progression binding to integrins and CD44 cell receptors, then regulating multiple signaling pathways like Wnt/B-catenin/Tcf4, PI3K/Akt or JAK2/STAT3. OPN overexpression has been correlated with metastasis and adverse outcome in several neoplasms. In breast carcinoma (BC) the expression of total OPN (OPN-t) mRNA and its splicing variant c (OPN-c) (a suggested marker for transformed cells) as well as their clinical role have not been extensively evaluated.

Design: 305 BC samples were first classified immunohistochemically into Luminal A and B, HER2 or triple negative (TN)/basal-like phenotypes. Total mRNA was extracted from preselected tumor areas of paraffin-embedded tissue and retrotranscribed to cDNA. Quantitative real-time PCR was performed to analyze OPN-t and OPN-c levels using TaqMan® Gene Expression Assays. A mix of 10 normal mammary tissue mRNA was used as a calibrator, and *PUM1* as reference gene to normalize OPN-t and OPN-c expression. Relative mRNA levels were determined using the $\Delta\Delta C_T$ method. Correlations between OPN-t and OPN-c results with clinico-pathological factors and outcome were evaluated.

Results: Median patients' age was 57 years (range 23-89) and the median follow-up 83 months (range 6-281). OPN-t mRNA overexpression (fold change ≥ 5) was detected in 74% samples (226/305). Among them, tumors were more frequently HER2 (43%) and TN/basal-like (33%) subtypes ($p=0.004$), with positive lymph-node status (40%; $p=0.025$), presenting in patients >50 years (70%, $p=0.046$), and a trend toward grade 3 (66%; $p=0.07$) and presence of necrosis (50%, $p=0.15$). OPN-c was overexpressed (≥ 2 fold change) in 53% samples (108/203) associated with TN/basal-like subtype (46%; $p=0.002$). Patients with increased OPN-t mRNA tumor levels had shorter overall survival (74% vs 84%; $p=0.006$), especially those with TN/basal-like (65% vs 82%; $p=0.052$) (Kaplan-Meier; log rank).

Conclusions: In our series of BC, increased OPN-t mRNA was associated with poor prognostic factors, HER2 and TN/basal-like subtypes and shorter survival. Moreover, OPN-c was specifically related with TN/basal-like. Therefore, novel therapeutic strategies against OPN might be a valid approach for treatment of aggressive BC phenotypes.

Supported by Grants FCVI-HGUA (PI-C/2008/02), ACOMP/2009/195 and GE-018/09

227 Prediction of Prognosis in Breast Cancer by Using CD34 Immunostain and Quantitative Image Analysis

U Ozerdem, EM Wojcik, GA Barkan, X Duan, C Ersahin. Loyola University Medical Center, Chicago, IL.

Background: Breast cancer is the most common cancer diagnosed in women. It is therefore imperative to establish new prognostic markers that can be easily utilized in breast pathology practice to stratify the patients. CD34 is expressed by both blood vessel endothelial cells and nascent (activated) lymphatic endothelial cells in tumors. CD34 immunostain is therefore in a unique position to identify angiogenesis and lymphangiogenesis simultaneously in a given tumor tissue. This investigation aims at establishing a quantitative analysis of CD34 expression in different stages of breast cancer tissues as a tangible prognostic tool in breast pathology.

Design: We used a tissue microarray, which contained 40 cores with stage IIA, IIB, IIIA, IIIB, and IIIC breast cancer, and 10 non-cancer breast cores. Tissue microarray slides were immunostained with CD34 for identification of blood vessel and nascent lymphatic endothelial cells. Immunostained slides were imaged with a high resolution digital camera. Digital images were analyzed using NIH ImageJ1.44 image analysis software. A CD34 score was quantified for each patient as a percentage of the CD34-positive microvessel area to the area of the microarray spot (CD34 area/area of entire tissue core). Statistical analyses were performed using Graphpad Prism Software. The scores in each position of tissue microarray were compared across each prognostic group. Bonferroni's multiple comparison test was used to compare prognostic groups in pairs.

Results: The mean CD34 score was 0.24%, 0.40%, 1.30%, 2.33%, 2.64%, and 3.44% for normal patients, patients with stage IIA, IIB, IIIA, IIIB, and IIIC breast cancer groups, respectively ($p<0.0001$). The mean CD34 score was 0.70% and 2.21% for lymph node-negative and lymph node-positive breast cancer groups, respectively ($p<0.0001$).

Conclusions: CD34 score of breast cancer, quantified by using CD34 immunostain and NIH ImageJ1.44 image analysis software, can predict prognosis. This method can be utilized as a practical and cost-effective alternative method to stratify breast cancer patients. Potentially, CD34 score can also be used to identify the patients who would benefit from targeted anti-blood vessel endothelial cell and anti-lymphatic endothelial cell therapies. Further studies are warranted.

Supported by a research grant from Loyola University Medical Center.

228 Impact of ACOSOG Trial Results in the Practice of Breast Cancer Surgery in Long Island: Survey of 19 Hospitals

D Pandya, J Liu, M Singh, P Kane, C Tornos. Stony Brook University Medical Center, Stony Brook, NY.

Background: The ACOSOG Z011 trial in women with T1 or T2 breast cancer with up to 3 positive sentinel nodes treated with lumpectomy followed by systemic therapy found no significant differences in loco-regional recurrence, overall survival or disease free survival when patients underwent sentinel lymph node biopsy (SLNB) alone versus SLNB and complete axillary node dissection (ALND). The study implied that frozen section (FS) in selected patients is not necessary since they will not undergo immediate ALND. Our study was aimed to determine the impact of this trial on the daily practice of breast cancer surgery in Long Island.

Design: A telephone survey was done with pathologists from all Long Island Hospitals covering two counties. The survey included: number of surgeons providing breast cancer care specifying general surgeons vs breast surgeons, existence of a breast or general tumor board, routine practice of SLNB by surgeons including frozen sections, routine pathology done on SLN, discussion of ACOSOG results between pathologists and surgeons, changes observed after ACOSOG results were published regarding number of FS requested, and pathology work done on SLN.

Results: A total of 19 hospitals were surveyed including 1 academic center, and 18 community hospitals. 8 hospitals had general surgeons doing all the cases, 9 had both general and breast surgeons and 2 hospitals had breast surgeons. 18 hospitals had all surgeons routinely performing SLNB. In one hospital, one of the two surgeons did not routinely do SLNB. All hospitals but one routinely do immunostains in SLN, and all but one do also levels. 14 hospitals had tumor boards with discussion of breast cases. 5 hospitals had discussed ACOSOG results between pathologists and surgeons. Only one surgeon in a community hospital stopped requesting frozen section on sentinel lymph node and also stopped performing axillary lymph node dissection as per ACOSOG recommendations. One surgeon in another hospital made the request of no immunostain on sentinel nodes but the hospital pathologists did not change the practice. No hospital has changed the pathology work up of SLN after this publication.

Conclusions: Long Island hospitals treat approximately 2,400 new cases a year. Despite these numbers, and despite the presence of one academic institution in the survey, only one surgeon in one community hospital has made changes in the daily practice of SLNB. Pathology work up of SLN in all hospitals remains unchanged.

229 Invasive Breast Carcinomas in Ghana: Higher Frequency of High Grade Tumors with Squamous Differentiation, Triple Negative Status, and EZH2 Expression

J Pang, K Toy, K Griffith, L Newman, C Kleer. University of Michigan, Ann Arbor, MI.

Background: Breast cancer in African American women is frequently ER negative, high grade, and more aggressive than in Caucasian women. The ancestors of most African American women come from West Africa, including Ghana. The Polycomb group protein enhancer of zeste homologue 2 (EZH2) is a marker of poor outcome in Caucasian breast cancers. This study investigates the histologic features, expression of ER, PR, HER-2/neu, and EZH2 in Ghanaian breast cancers.

Design: Benign and malignant breast tissue from women treated at Komfo Anoyke Teaching Hospital between 2006 and 2011 were obtained for histologic classification. Immunostains for ER, PR, and HER-2/neu were performed previously. EZH2 immunostain was performed following the manufacturer's protocol. EZH2 nuclear expression was scored on a 0-3 scale: no staining (0), staining in $<50\%$ of cells (1), moderate staining in $>50\%$ (2), and strong staining in $>50\%$ (3). Cytoplasmic staining was noted as present or absent.

Results: 100 invasive carcinomas and 69 benign biopsies were studied. Of the invasive carcinomas, 89 were ductal, 2 were lobular, and 9 were metaplastic. Squamous differentiation was seen in 11% (6 metaplastics and 5 ductals with squamous features). The majority of carcinomas were grade 3 (52%), 41% were grade 2, and 7% were grade 1. Most were negative for ER (76%), PR (77%), and HER-2/neu (87%). 62% were negative for all three. EZH2 was significantly expressed in malignant compared with benign breast ($p<0.0001$). EZH2 expression was significantly associated with high histologic grade ($p<0.05$). Greater EZH2 expression was seen in ER negative (26%) than ER positive tumors (4%), although not statistically significant. 16% of invasive carcinomas showed cytoplasmic staining which was significantly associated with ER negative and triple negative status ($p<0.05$).

Conclusions: Invasive carcinomas in Ghanaian women are frequently poorly differentiated with squamous features. Invasive lobular carcinomas are rare. Most invasive carcinomas are triple negative. Similar to Caucasian tumors, EZH2 expression is associated with high histologic grade. In a subset of invasive carcinomas, EZH2 is localized to the cytoplasm, which has not been previously reported and warrants further investigation. Our data provide first histologic and biomarker characterization of Ghanaian breast cancers which is necessary to develop more efficacious treatments and useful prognosticators.

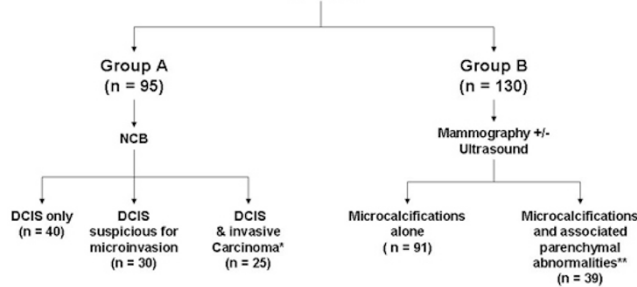
230 Lumpectomies for DCIS without Sentinel Node Biopsy – Patient Selection and 5 Year Follow-Up

RK Patel, ML Cibull, PC McGrath, WR Heather, EA Pirruccello, VV Krol, YM Brill, LM Samayoa. University of Kentucky, Lexington, KY.

Background: The role of Sentinel Node Biopsy (SNB) in patients with Ductal Carcinoma In-Situ (DCIS) is largely based on data showing up to 20% incidence of axillary metastasis. While accurate at the time, these studies could not have taken into account the radiographic capabilities currently available for the diagnosis of the disease. Based on their initial radiologic findings, this study focuses on the selection of DCIS patients not needing SNB at the time of lumpectomy and presents 5 year follow up data on patients treated with lumpectomy + radiation alone.

Design: The incidence of invasive (inv.) and metastatic carcinoma (ca) in 225 patients with radiographic and/or histologic diagnosis of DCIS see Figure 1, was correlated with the following: extent of microcalcifications (m-Ca++) up to 50 mm; characteristics of the m-Ca++ (linear, segmental, clustered, pleomorphic, amorphous and casting); m-Ca++ alone vs m-Ca++ with associated parenchymal changes; uniceentric vs multicentric disease; lumpectomies vs mastectomies specimens; and extent of axillary and inv. ca.

Figure 1. Patients with DCIS (n = 225)



*DCIS representing at least 75% of the NCB

**Well defined associated masses excluded

All patients had at least GII DCIS on their initial NCB. In group A SNB were performed in all patients. In group B, SNB was only done in patients having mastectomies and in patients with microinvasive or inv. ca. Parenchymal changes included: ill-defined masses, increased density and parenchymal asymmetry. DCIS patients having lumpectomy + radiation alone have ≥ 5 years of follow up (n = 63).

Results: See Table 1.

Table 1. Extent and incidence of invasive and metastatic carcinoma in DCIS

Radiographic characteristics	Incidence of Invasive Carcinoma		Size of invasive carcinoma				Incidence of Metastatic Carcinoma		Axillary Stage			# of (+) nodes	
	%	%	T1mic	T1a	T1b	T1c*	%	ITC	Nmic	Nia	1	2	
Calcifications only (n=145)	8	5.5%	7	-	-	1	0%	-	-	-	-	-	-
Calcifications & parenchymal abnormalities (n = 61)	40	65%	3	6	10	21	8	13%	1	3	4	7	1
Calcifications & well defined suspicious masses (n = 19)	12	63%	-	2	3	7	6	32%	-	2	4	4	2

*All tumors ≤ 1.5 cm.

Data independent of unifocal versus multifocal disease, mastectomy versus lumpectomy and mammographic microcalcifications extent and morphology.

No incidence of metastatic carcinoma reported in >67 months follow up in patients treated w/o SN biopsy

Conclusions: See Table 2

Table 2. Indications for SNB in DCIS patients undergoing lumpectomy

Patients' Radiographic Characteristics and NCB diagnoses	Incidence of metastatic carcinoma at the time of primary surgery	SNB at the time of Lumpectomy	No SNB at the time of Lumpectomy	SNB as a second procedure
Micro-Calcifications alone & NCB Dx of DCIS	0%		xxxxx	At surgeon's discretion, depending on size of the invasive carcinoma if present
Micro-Calcifications alone & NCB DX of DCIS + microinvasive ca	0%		xxxxx	At surgeon's discretion, depending on size of the invasive carcinoma if present
Micro-Calcifications with associated parenchymal abnormalities & NCB Dx of DCIS alone or with microinvasive or invasive ca	13%	xxxxx		
Micro-Calcifications with associated well defined masses (mammographic and sonographic) & NCB Dx of DCIS alone or DCIS + microinvasive ca or inv carcinoma	32%	xxxxx		

231 Differential Expression of Syndecan-1/CD138 in Triple Negative Breast Carcinoma and Hormone Receptor Positive Breast Carcinoma

S Patel, C Cohen, LA McLendon, A Husman, S Schmechel, R Busch, K Stevens, A Adams, GM Oprea. Emory University, Atlanta, GA; University of Minnesota, Minneapolis, MN.

Background: Syndecan-1 (CD138) is a member of the family transmembrane heparan sulfate proteoglycans, which are involved in cell-to-cell adhesion and the interaction of cells with the extracellular matrix, cell migration and angiogenesis. Altered syndecan-1 expression has been described in carcinogenesis of various tumors in which it correlates with gain of malignant characteristics and adverse outcome. In the breast, syndecan-1 has additionally been correlated with Her2 amplification and hormone receptor negative status. Syndecan-1 expression has not been studied in a large triple-negative breast carcinoma series in comparison with non-triple negative phenotype.

Design: Breast carcinomas over a 7-year period were reviewed. Tissue microarrays were constructed from 263 invasive breast carcinomas. IHC for hormone markers ER, PR, and Her-2 were scored per CAP standards. Her2 was confirmed by reflex FISH for 2+ IHC. The carcinomas were classified as hormone receptor (ER and/or PR)-positive, Her-positive (ER/PR-negative), and triple-negative. IHC for syndecan-1 was performed. Membranous epithelial staining was scored, with 2-3+ in greater than 5% of tumor cells considered positive. Preliminary statistical analysis was performed by Chi-square analysis.

Results: Patient age ranged from 24 to 90 years. 187 triple-negative (TNC), 67 hormone receptor positive, and 8 Her-positive carcinomas were identified. Syndecan-1 IHC results were able to be assessed in 209 cases. 112 of 144 (78%) of triple-negative carcinomas (TNC) were positive for syndecan-1 as compared to 17 of 65 (26%) of the non-TNC (p<0.001). Fewer (13/58, 22%) hormone receptor positive carcinomas were positive for syndecan-1 as compared with the remaining tumors (116/151, 77%). Syndecan-1 expression did not correlate with age, race, and Her2-positivity.

Conclusions: Syndecan-1 expression appears to be high in triple-negative breast cancers, potentially offering a therapeutic target for targeted therapy against these aggressive neoplasms. Syndecan-1 was frequently negative in hormone receptor positive carcinomas, confirming previous reports.

232 Prognostic Role of Tumor-Infiltrating FOXP3+ Tregs, SKP2, p21 and p27 in Immunophenotypes of Breast Carcinoma

G Peiro, F Ortiz-Martinez, D Giner, FJ Gutierrez-Avino, FI Aranda, E Lerma, E Adrover, J Sanchez-Paya, JM Sempere-Ortells. Hospital General Universitari, Alacant, Spain; Hospital de La Santa Creu i Sant Pau, Barcelona, Spain; Universitat d'Alacant, Alacant, Spain.

Background: The X-linked gene *FOXP3* (Xp11.23) is a member of the forkhead family of transcription factors that plays a key role in the immune suppressive function of regulatory T-cells (Tregs). Recently, it has been identified as a tumor suppressor that regulates the transcription activity of oncogenes and tumor suppressor genes. The aim of our study was to evaluate the presence of FOXP3+ Tregs in tumor microenvironment of breast carcinoma (BC) and to correlate the results with the tumor expression of SKP2, p21 and p27; and patient's outcome.

Design: We performed an immunohistochemical (IHC) study of FOXP3, SKP2, p21 and p27 on paraffin-embedded tissue microarrays (1mm diameter cores) containing 372 BC, stratified by immunophenotypes: 24% Luminal A and B (ER/PR+, HER2-), 42% HER2+ (≥30% cells 3+ by IHC and/or FISH/CISH amplification), and 34% TN/basal-like (ER/PR/HER2- +/-CK5/6+/-EGFR). FOXP3+ cells within the tumor and/or immediately adjacent stroma were counted in 3 high power fields (HPF) (x400). Further, the average of positive tumor nuclei (SKP2, p21 and p27) was recorded. The correlations between IHC results, clinicopathological factors and outcome were analyzed.

Results: Median patients' age was 56 years (range 23-89 years) with a median follow-up of 93 months (range 6-371 months). There was a significant correlation between the high number of Tregs (median threshold ≥15 FOXP3+ cells) (27%) and tumors of TN/basal-like phenotype (36%), grade 3 (37%), with necrosis (40%), positive lymph-node status (34%), SKP2 overexpression (45%), and loss of p21 (29%) and p27 (36%) (all p≤0.046). Neither Tregs content nor nuclear p21 and p27 expression showed prognostic significance (all p=ns), whereas SKP2 oncogene overexpression correlated with shorter overall survival (79% vs 69%; p=0.044) (Kaplan-Meier; log rank test).

Conclusions: Our study suggests that FOXP3+ Tregs are markers of aggressive BC, and that might be important for the design of immunotherapy based clinical protocols. The role of *FOXP3* as a tumor suppressor is supported by the loss of p21 and p27 and the increased SKP2 oncogene expression in tumor cells, the latter being related with poor prognosis.

Supported by Grants FIS 10/00082, AP-172/10, FCVI-HGUA (2010/PC-04 and 2011/PC-03)

233 FGFR1 Amplification in Breast Cancers with Unfavorable Features

K Pfaltz, S Schneider, S Eppenberger-Castori, C Tapia. University Bern, Bern, Switzerland; University Hospital Basel, Basel, Switzerland.

Background: The fibroblast growth factor receptor 1 (FGFR1) gene, located at chromosome 8p12, encodes a tyrosine kinase. FGFR1 is involved in cell proliferation, survival, migration, and differentiation. FGFR1 can be targeted by a small molecule (FGFR inhibitor) leading to significant tumor shrinkage. FGFR1 amplified tumors seem to be targetable/responsive to FGFR inhibitors. Therefore, we validated FGFR1 gene status in a large cohort of breast cancers to evaluate FGFR inhibitors as a possible therapeutic option in this disease.

Design: We hybridized tissue micro-arrays (TMA) with 907 breast cancers using a commercially available fluorescent in-situ hybridization probe (FGFR1/CEN8; ZytoVision®). Normal gene status was considered as a ratio (FGFR1/CEN8): 0.8-1.9, amplification was defined as ratio ≥2.0, polysomy was defined as >4 FGFR1 and CEN8 signals.

Results: FGFR1 amplification was observed in 8.9% (n=81), a normal gene status was found in 80.7% (n=732), and a polysomy was detected in 10.2% (n=93) of all tumors. FGFR1 amplified breast cancers showed the following features: 72.8% (59/81) ductal, 45.5% (35/77) high grade (G3), 16% (12/75) HER2 of 2+/3+, 55.5% (35/63) positive lymph nodes, and 18% (13/72) recurrence. Comparing T-categories (T1, T2, T3) FGFR1 amplified breast cancers and non-amplified tumors showed the following results: T1: 25% vs. 34%, T2: 56% vs. 48%, T3: 9% vs. 6%.

Conclusions: FGFR1 amplification is especially prevalent in breast cancers with unfavorable/aggressive features such as a high tumor grade (45.5%), large tumor diameter, and metastasis (55.5%). These patients are a clinically relevant group since they require aggressive adjuvant treatment. The detection of FGFR1 amplification could help in the identification of some patients already at higher risk which might benefit from a new therapeutic option with FGFR1 inhibitors.

234 TOP2A Status in Chemotherapy-Treated Breast Cancer Patients Using FISH in Cytokeratin-Positive Cells

WE Pierceall, J Bartek, J Bartkova, H Nevanlinna, C Blomqvist. On-Q-ity, Inc, Waltham, MA; Danish Cancer Society, Copenhagen, Denmark; Helsinki University Central Hospital, Helsinki, Finland.

Background: Tumor biomarker analysis increasingly provides information for predicting outcomes with specific chemotherapeutic regimens (personalized medicine). TOP2A is a DNA helicase that is targeted by anthracyclines, cytotoxic therapeutics commonly used as both adjuvant and palliative treatment of breast cancer. Several large studies have shown that TOP2A copy number variations (CNV) are predictive to response and outcome after anthracycline based chemotherapy.

Design: We have developed an approach for analyzing FFPE breast tumors on tissue microarrays with TOP2A fluorescence in situ hybridization (FISH) coupled with cytokeratin immunofluorescence (IF) to specifically identify tumor cells. Stained tissue from breast cancer patient specimens was imaged and analyzed using Metafer/Metacyte (Metasystems) by a customized image classifier and high throughput analysis.

Results: TOP2A:CEN17 ratios ≥ 2.0 (amplified) and ≤ 0.8 (deleted) were observed for 10.0% and 6.1% of the patients, respectively, and established as cut-offs for statistical tests. Patient subgroup outcomes for adjuvant chemotherapy (CEF, CMF, No Chemotherapy [CT]) were evaluated. No statistically significant differences were observed in clinical endpoints for TOP2A status in anthracycline-treated patients. However, patients with TOP2A aberrations receiving methotrexate-based therapy exhibited significant decrease in 5yr Distant Disease-Free Survival (5yrDDFS) and Breast Cancer-Specific Overall Survival (BCSOS), especially for the group with TOP2A deletions (DFS HR=5.31, p=0.001 and BCSOS HR=6.45, p<0.001). No significant differences were seen in the No CT treatment group. Topo2A protein levels by immunohistochemistry were assessed with no correlative statistical relevance to IF/FISH-based prognosis for CEF or CMF groups. Interestingly, aberrant (under)expressing No CT patients exhibited better 5yrDDFS [HR=0.39, p=0.004] and trended toward more favorable BCSOS (HR=0.61, p=0.11).

Conclusions: Our results indicate a strategy by which targeted scoring of FISH signals to cytokeratin-positive staining tumor cells may provide a tool for added precision and efficiency in the evaluation of the TOP2A from tumor tissue.

235 Combined Approach for Staging the Axilla Versus Sentinel Lymph Node Alone – A Cost Effective Approach Limiting the Extent of Axillary Dissections in Breast Cancer Patients

EA Pirruccello, PC McGrath, VV Krol, RK Patel, RL Stewart, YM Brill, AL Szabunio, LM Samayoa. University of Kentucky, Lexington, KY; VAMC, Lexington, KY.

Background: Local control and prognostic information for managing the majority of clinically node (-) breast cancer patients can be achieved by sentinel node biopsy (SNB) alone, or axillary dissections limited to 1-3 Lymph Nodes (LN). Currently, 20 - 30% of clinically node (-) patients have additional surgery at a significant risk and without clear benefit for survival. This study compares the results from staging the axilla using the current methodology (SNB alone) versus the results from using a combined, multidisciplinary and cost effective approach shown below.

Design: Primary tumor histologic characteristics, axillary ultrasound (US) +/- Fine Needle Aspiration (FNA), SNB and Axillary Lymph Node Dissection (ALND) data from 176 patients, grouped into the following categories: 1) Patients at Low Risk (LR) for axillary metastasis; 2) Patients at High Risk (HR) with normal axillary US; 3) HR patients with US suggesting N1a disease and 4) HR patients with US suggesting N2-3 disease; were analyzed according to: a) Sentinel Node (SN) and Non-Sentinel Node (NSN) status and b) Final number of (+) LN in ALND after a (+) SNB or (+) US-FNA. Patients at HR for axillary metastasis were defined as those having grade II tumors ≥ 1.5 cm and grade III tumors > 1.0 cm. Sonographic abnormalities in the axilla: suggestion of Minimal N1a disease was defined as cortical defects < 5 mm in 1-3 LN, suggestion of N1a as cortical defects > 5 mm in 1-3 LN, and suggestion of N2-3 disease as complete nodal replacement in 1 LN.

Results: See Table 1.

Table 1 Extent of Axillary Disease from Axillary Dissections after SN biopsy or Positive US-FNA

Breast Cancer patients histologic and sonographic characteristics	RESULTS FROM SN MAPPING										RESULTS FROM US-FNA					OVERALL NODE STAGE		
	(+)	(-)	SN (+) N2/3 (-)	SN (+) N2/3 (+)	# (+) SN			# (+) LN			Total # (+) LN	(+)	# (+) LN			N1	N2-3	
					1	2	3	1	2	3			1	2	>3			
Low Risk no US	6	56	6	0	5	1	0	5	1	0	-	-	-	-	-	-	6	0
High Risk normal US	3	14	3	0	2	1	0	2	1	0	-	-	-	-	-	-	3	0
HR with LN cortical defects < 5 mm in 1 or more LN	4	19	3	0	3	1	0	3	1	0	-	-	-	-	-	-	4	0
HR with LN cortical defects ≥ 5 mm in 1 -3 nodes	5	21	5	1	2	1	0	2	1	1	26	16	5	4	3	2	28	2
HR with total replacement in 1 LN	-	-	-	-	-	-	-	-	-	-	4	-	-	1	1	2	2	2
HR with total replacement in > 1 LN	-	-	-	-	-	-	-	-	-	-	10	-	-	-	-	10	-	10
totals	19	110	17	1	13	4	1	13	4	1	40	16	5	4	23	43	23	23

Conclusions:

Table 2 Extent of Axillary Surgical Procedures According to Combined Approach

Patient Characteristics	TYPE OF AXILLARY SURGERY		
	SNB only	Limited Axillary Dissection	Complete Axillary Dissection
Low Risk	xxxx		
High Risk with Normal Axillary US	xxxx		
High Risk with Minimal Axillary Disease by US	xxxx		
High Risk with N1a disease by US and (-) FNA	xxxx		
High Risk with N1a disease by US and (+) FNA		xxxx	
High Risk with N2-3 disease by US and (+) FNA			xxxx

This approach would result in a 38% (48/176) reduction in the number of SNB and a 30% (22/66) reduction in the number of ALND. This translates in to \$200,000 (30 - 40%) in procedure-associated savings in our study group.

236 Predictive Benefit of HER4 Testing in Invasive Breast Carcinoma Patients Receiving Preoperative Trastuzumab-Based Therapy in the Neoadjuvant Setting

BP Portier, Z Wang, E Mincae, E Downs-Kelly, C Lanigan, J Jay, D Tast, J Renger-Moore, E Walk, R Tubbs. Cleveland Clinic, Cleveland, OH; Ventana Medical Systems Inc., Tucson, AZ.

Background: Common prognostic/predictive markers utilized in breast cancer testing include ER, PR, Ki67, and HER2. Positivity for HER2 by IHC or FISH serves as eligibility for anti-HER2 based Trastuzumab (Genentech, USA) therapy. Response to Trastuzumab in HER2 positive patients is variable, suggesting that additional markers could add predictive value. Recent evidence has implicated a role for HER4 in predicting response to Trastuzumab therapy. In this study, we retrospectively examined the amplification and expression status of both HER4 and HER2 in a cohort of breast carcinomas receiving preoperative Trastuzumab in the neoadjuvant setting to elucidate if combination testing added predictive or prognostic value.

Design: All patients (pts) that received Trastuzumab at the Cleveland Clinic from 1/2008 to 12/2010 were reviewed for study inclusion (234 patients); 47 pts met inclusion criteria which included a diagnosis of primary invasive breast cancer, neoadjuvant Trastuzumab therapy, and a pre-treatment biopsy performed at the Cleveland Clinic. These biopsy specimens were analyzed for HER2 via IHC (4B5), FISH (PathVysion), Dual ISH, and Q-RT-PCR; HER4 via IHC (E200) and Q-RT-PCR. Electronic medical records were reviewed for outcome measures including metastasis free survival, overall survival (OS), and complete pathologic response (CpR).

Results: Utilizing IHC and molecular methods, four individual patient populations were segregated: 1) HER4-pos/HER2-pos (12 pts), 2) HER4-neg/HER2-pos (24 pts), 3) HER4-pos/HER2-neg (6 pts), and 4) HER4-neg/HER2-neg (5 pts). Investigation of all four combinations revealed that one population (HER4-pos/HER2-pos), demonstrated statistically significant metastasis free survival compared to the other HER4/HER2 combinations. No significant difference was observed for OS or CpR.

Conclusions: Determination of HER4 amplification/expression in combination with HER2 predicted metastasis free survival in patients treated with Trastuzumab. This finding supports the previously reported protective role of HER4 in Trastuzumab treated breast cancer, and demonstrates the potential prognostic value of dual testing for HER2 and HER4. This data also supports further investigation of HER2 & HER4 testing in a large, well characterized breast cancer cohort to further elucidate the prognostic strength of dual marker testing.

237 Utilization of Dual ISH and RT-PCR Enhances Resolution of IHC and FISH Double Equivocal Testing Results in Breast Carcinoma

BP Portier, Z Wang, E Mincae, C Lanigan, E Downs-Kelly, R Tubbs. Cleveland Clinic, Cleveland, OH.

Background: Cases classified as equivocal by both IHC and FISH testing for HER2 represent a deficiency in laboratory medicine. Currently, per ASCO/CAP guidelines,

cases called equivocal by one methodology are reflex tested by a second methodology (FISH/IHC or IHC/FISH). However, reflex testing fails to resolve HER2 status in all cases. Cases that are equivocal by both FISH and IHC are categorized as "Double Equivocal". In this study, we examined the utility of using the newly FDA approved Dual ISH HER2 detection system and a Quantitative-Real Time-PCR (Q-RT-PCR) assay to determine the amplification status of *HER2* in patients that could not be resolved by standard IHC and FISH testing.

Design: Cases were identified from the Cleveland Clinic electronic records from 1/2008 to 12/2010. Q-RT-PCR was performed on FISH/IHC amplified, equivocal, and non-amplified cases following RNA extraction of macro-dissected tissue utilizing a LightCycler 480 II (Roche Applied Biosciences, Penzberg, Germany). Q-RT-PCR results were expressed as the ratio of HER2 to two reference genes (B2B and GAPDH). Dual ISH (HER2 Inform, Ventana, Tucson, AZ) was performed and scored per manufacturer's instructions.

Results: Q-RT-PCR assay was validated utilizing control IHC/FISH amplified and non-amplified cases. ROC curve analysis of Q-RT-PCR validation assays showed 100% sensitivity and specificity with a cut off score of 7.0 and above identifying HER2 mRNA over-expression. In the IHC/FISH double equivocal population, Q-RT-PCR identified 15 (30%) cases as amplified. Dual ISH applied to the double equivocal cohort identified 13 (26%) cases as amplified. Overall agreement between Q-RT-PCR and DISH for all cases was 90%.

Conclusions: Utilization of Dual ISH, a new FDA approved bright-field *HER2* detection system, and a molecular based approach using Q-RT-PCR both showed superior resolution of HER2 status compared to standard IHC and FISH testing methods. This study shows the utility and added sensitivity of adding Dual ISH as a first line HER2 test and adding Q-RT-PCR as a downstream assay, in cases that fail primary screening. Utilization of these two techniques would decrease first round equivocal calls (Dual ISH) and would offer a definitive follow up reflex test (Q-RT-PCR). Both methods are morphology based and are readily incorporable into standard laboratory work flows. Dual ISH has the added benefit of being FDA approved, in addition, since *HER2* detection is bright-field based, this opens this procedure to practices that currently lack a FISH laboratory.

238 Utilization of Oligo-Array CGH To Determine *HER2* Amplification Status, Amplicon Genomic Span, and Co-Amplification Signatures: Potential Complementary Role to *HER2* FISH Testing

BP Portier, Z Wang, C Lanigan, G Batiouchko, E Downs-Kelly, T Richmond, D Gerhardt, K Munn, W Haagmans, R Tubbs. Cleveland Clinic, Cleveland, OH; Roche NimbleGen, Inc., Madison, WI.

Background: Utilization of array-based comparative genomic hybridization (aCGH) for determination of HER2 copy number is a relatively new tool for HER2 status determination. A clear advantage of aCGH over FISH testing has been reported in cases with aneusomy of chromosome 17. FISH testing, which relies on a ratio of HER2 to Centromere 17 (HER2/CEP17) can result in inaccurate HER2 determination in cases with apparent aneusomy attributable to gain at the alphacentromeric reference locus. In this study, we utilized aCGH to determine accurate amplicon size/genomic span, intra-HER2 gene amplification variability, and to compare aCGH/FISH assay concordance.

Design: DNA was extracted from formalin fixed paraffin embedded tissue (Qiagen, Valencia, CA) from invasive breast carcinomas following macrodissection. Samples utilized in this study segregated into three groups: 1) Aneusomy 2) Monosomy, and 3) Eusomic cases as determined by FISH utilizing a centromere 17 probe (PathVysion; Abbott Molecular). A custom 720k oligo-array CGH was utilized (Roche Nimblegen, Wisconsin) that tiled chromosome 17 (probe density varied from 100bp to 7,500bp; highest density in exons). Analysis of aCGH was performed using DEVA software suite (Roche-Nimblegen, Madison, WI).

Results: Detection of HER2 amplification by aCGH was visualized and quantified by HER2 Log value. Correlation between FISH HER2 score and aCGH Log HER2 value was strong ($R^2=0.97$). The amplicon size in the region surrounding HER2 was highly variable among cases and did not correlate with level of HER2 amplification identified by FISH. Furthermore, aCGH demonstrated intra-HER2 gene amplification variability in the majority of cases.

Conclusions: While aCGH HER2 results strongly correlated with FISH HER2 scores, variability within the HER2 gene was only identifiable by aCGH. This variable level of intra-HER2 gene amplification cannot be elucidated by FISH testing and could partially account for the variability in patient response to Trastuzumab therapy. aCGH detects the exact amplicon size/genomic span and enables generation of a molecular profile of all co-amplified or deleted genes on chromosome 17. Generation of this molecular signature could result in improved stratification and a more informative personalized medicine approach to selecting patients for Trastuzumab based therapy. Further testing in a larger, well characterized population with clinical outcome data is warranted.

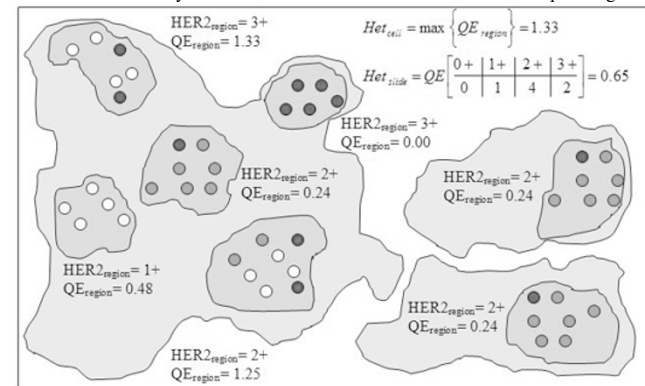
239 The Use of Tumor Heterogeneity Scoring in Determining the Amount of Tissue Required for HER2 Diagnosis in Breast Cancer

SJ Potts, H Lange, DG Young, N Landis, DA Eberhard. Flagship Biosciences, Flagstaff, AZ; University of North Carolina, Chapel Hill, NC.

Background: Effective clinical approaches to measuring tumor heterogeneity would be useful in both evaluating patient therapeutic response as well as determining the amount of tissue required for diagnosis. Combining methodology based on current clinical anatomic practice with ecological diversity statistics, we created a new scoring system that combines tumor and cell level heterogeneity called the HetMap, that allows visualization of the heterogeneity of a subject in the context of an entire patient population.

Design: We evaluated the approach on HER2 immunohistochemistry stained breast cancer samples, using 200 specimens across two different laboratories, with three

pathologists at each laboratory outlining ten to twenty regions of tumor for scoring. by automatic cell-based image analysis. HetMap was evaluated using three different scoring schemes: HER2 scoring according to ASCO/CAP guidelines, H-Score and a new continuous HER2 score ($HER2_{cont}$). We determined the extent to which heterogeneity and the area of tissue analyzed contributes to discordance rates between pathologists.



Results: Two definitions of heterogeneity, cell-level and tumor-level, provided useful independent measures of heterogeneity. Cases with higher discordance rates showed a statistically significant correlation with higher tumor heterogeneity. As the area analyzed increased, the discordance rates decreased.

Conclusions: HetMap is a general approach that can be applied to any marker and was here evaluated using the IHC HER2 maker for breast cancer tissue. The results suggest that HetMap could be a useful means to identify tumors with higher degrees of heterogeneity, or to highlight slides that should be rechecked for QC issues.

240 Outcomes Study of Atypical Ductal Hyperplasia and Ductal Carcinoma In Situ Treated with Excision

J Qian, A Rizki, J Chong, J Richey, J Ticar, L Shan, M Idowu. Virginia Commonwealth University, Richmond, VA.

Background: The natural history of low grade ductal carcinoma in situ (DCIS) suggests that the majority of the patients do not progress to invasive carcinoma. While there may be some practice variation, many treat DCIS with excision and radiation. Atypical ductal hyperplasia (ADH) on the other hand is treated with excision without radiation. We evaluated 1) the time to recurrence, 2) the recurrence diagnoses and we compared the frequency of recurrence of ADH and DCIS.

Design: Women with ADH and DCIS treated with excisional biopsy from 1988 to 2006 at the VCUHS Breast Disease Cohort were identified through pathology review. All specimens had negative surgical margins. Only cases with at least 5 year follow-up information are included. Cases with total mastectomy and positive margins are excluded. Subsequent recurrences and/or subsequent development of infiltrating carcinoma on the same side were identified. We determined the prognostic significance of several histopathological characteristics of ADH and DCIS on initial diagnosis including size, and DCIS grade.

Results: There were 220 patients with a mean age of 55 years and a mean follow-up of 81 months (maximum follow-up, 266 months). 112 (51%) were ADH, of which 18/112 (16%) recurred (7ADH, 3 DCIS, 6 infiltrating ductal and 2 infiltrating lobular) with a mean time to recurrence of 45 months. 108 (49%) were DCIS (all grades) of which 23 (22%) recurred (7 ADH, 9 DCIS, 3 IDC, 3 ILC) with a mean time to recurrence of 57 months. The mean initial size of ADH was smaller than DCIS (1.56 vs. 2.17 cm², $P=0.01$), but there was no significant difference in age at diagnosis (54 vs. 56 months), recurrent rate (16% vs. 22%), time to recurrence (45 vs. 57 months), and recurrent diagnosis (for each pair, $p>0.05$). Among DCIS, 62% were high-grade and 38% were low-grade. There was no significant in recurrence rates between low grade and high-grade DCIS (16% vs. 24%), $P>0.05$. Surprisingly, ADH and low-grade DCIS had an identical (16%) recurrence rate and the size was similar (1.56 vs. 1.71).

Conclusions: In this study, we found that the initial size for DCIS was large than ADH, and low-grade DCIS and ADH had an identical prediction value for the recurrence of atypia and malignancy in the breast. These findings suggest that the management options for ADH and low-grade DCIS should be evaluated carefully.

241 Development and Validation of a Novel Gene Expression-Based Macrophage-Associated Marker Prognostic Score

LM Quintana, AH Beck. Beth Israel Deaconess Medical Center, Boston, MA.

Background: Tumor associated macrophages are involved in breast carcinogenesis; however, few macrophage-associated prognostic biomarkers have been identified. We sought to identify prognostic macrophage-associated markers and to develop a macrophage-associated marker prognostic score (MAMPS).

Design: We identified a list of 638 macrophage-associated markers using Ingenuity Pathway Analysis. We previously performed a meta-analysis across 11 microarray data sets (total of 20,827 genes and 2,123 patients) to estimate the association of each gene with survival in each of the four breast cancer molecular subtypes (Luminal A, Luminal B, Basal, Her2). In the current study, we focused our analysis on macrophage-associated markers showing a strong prognostic association (absolute value of Z statistic ≥ 3) in at least one breast cancer molecular subtype. Based on the genes identified, we computed a prognostic score (MAMPS) as the sum of the expression levels of the macrophage-related markers associated with decreased survival minus the sum of the expression

levels of the macrophage-related markers associated with improved survival. We then evaluated the prognostic association of the MAMPS in patients from three independent validation data sets (n = 780).

Results: No macrophage-associated markers were identified at the significance threshold in Luminal A. In Luminal B, Her2 and Basal, we identified a total of 12 markers (11 associated with improved prognosis and 1 associated with poorer prognosis). These 12 markers were used to compute the MAMPS. In patients from the validation data sets, the MAMPS was significantly associated with recurrence free survival in Luminal B ($Z=3.5$, $p = 0.0005$), Basal ($Z=3.3$, $p = 0.0009$), and molecular Her2 ($Z=2.1$, $p = 0.03$) breast cancer cases, with no association in Luminal A ($p>0.6$). In a multivariate model including MAMPS and molecular subtype, MAMPS was a significant prognostic factor ($Z=5.1$, $p = 3.0e-7$), independent of molecular subtype.

Conclusions: The MAMPS is strongly associated with prognosis in Luminal B and Basal breast cancer with a weaker association in Her2 and no significant association in Luminal A. These findings provide new insights into tumor-associated macrophages in breast cancer and will facilitate the development of diagnostic and therapeutic strategies targeting macrophages in breast cancer.

242 Comparison of Prognostic Receptors in Primary Breast Cancer and Nodal Metastases

SK Rathke, Z Basir, AC MacKinnon. Medical College of Wisconsin, Milwaukee, WI.

Background: Breast cancer treatment is guided by assessment of estrogen receptors (ER), progesterone receptors (PR), and human epidermal growth factor receptor 2 (HER2). There is limited research on comparison of these receptors in primary tumors versus their lymph node metastases. If receptor expression were different, it could guide changes in therapy. Our aim is to determine if there is a significant change in receptor expression in lymph node metastases compared to primary tumors.

Design: All patients having breast cancer with lymph node metastases at our institution between January 2008 and June 2011 were identified. Tissue microarrays (TMAs) were constructed when possible and remaining cases were stained individually. Immunohistochemistry (IHC) for ER, PR and HER2, and FISH for HER2 were performed on lymph node metastases. HER2 IHC was scored from 0 to 3+. HER2 FISH was positive if the ratio was >2.2 . Results were compared with those of the primary tumors.

Results:

Prognostic Receptors in Primary Tumor and Lymph Node Metastasis

Primary Tumor Receptors	Lymph Node Metastasis Receptors	
	Discordant with primary tumor % (n)	Concordant with primary tumor % (n)
ER pos, n=99	ER neg 5 (5)	ER pos 95 (94)
ER neg, n=23	ER pos 4 (1)	ER neg 96 (22)
ER total, n=122	5 (6)	95 (116)
PR pos, n=87	PR neg 18 (16)	PR pos 82 (71)
PR neg, n=35	PR pos 11 (4)	PR neg 89 (31)
PR total, n=122	16 (20)	84 (102)
HER2 neg, n=96	HER2 pos 0 (0); HER2 equivocal 6 (6)	HER2 neg 94 (90)
HER2 pos, n=19	HER2 neg 5 (1); HER2 equivocal 0 (0)	HER2 pos 95 (18)
HER2 equivocal, n=3	HER2 neg 67 (2); HER2 pos 33 (1)	HER2 equivocal 0 (0)
HER2 total n=118*	8 (10)	92 (108)

*3 cases were excluded from HER2 evaluation because there was no HER2 results on the primary tumor. 1 case showed 3+ HER2 IHC on primary tumor and metastasis but had non-amplified FISH on metastasis.

122 cases of breast cancer with lymph node metastases were obtained; 30 cases (25%) showed receptor changes. 4 cases (3.3%) showed expression changes in more than one receptor, 2 with PR and HER2 changes and 2 with ER and PR changes.

Conclusions: Changes in receptor expression in lymph node metastases when compared to the primary tumors do occur. The percentage of cases with changes in prognostic receptor expression warrants attention. This phenomenon may indicate that repeat testing for ER, PR and HER2 on lymph node metastases is indicated to guide treatment and to explain therapy failure in patients with metastatic disease.

243 Can Tumor Cellularity Predict Outcomes in Primary Non-Treated Breast Carcinoma?

ES Reisenbichler, O Hameed. Brigham and Women's Hospital, Boston, MA; Vanderbilt University, Nashville, TN.

Background: Tumor cellularity (TC) is used to calculate residual cancer burden in breast carcinoma (BC) following neoadjuvant therapy, with the latter being shown to predict distant relapse-free survival (RFS). It is not clear however, whether TC can help predict outcomes in non-treated BC. The goal of this study was to evaluate the prognostic value of TC in this particular setting.

Design: Following a detailed histologic review and after excluding foci of necrosis and in-situ carcinoma, TC (%) was evaluated in the primary excision of 366 cases of BC. Tumor size (TS), histological type and grade, lymph node status, RFS and overall survival (OS) were also recorded. The TC was then multiplied by size (mm) to derive the primary tumor burden (PTB). A receiver operating curve (ROC) was then used to determine the best PTB cutoff point to segregate the cohort into 2 groups for survival analysis.

Results: Mean patient age was 58 yr (range, 21-91) and median follow-up was 87 mo (range, 0.7-165). Invasive ductal carcinoma of no special type constituted 80% of cases, invasive lobular carcinoma 10%, and other special types of carcinoma, 10%. Nottingham grades I, II and III, represented 25%, 41% and 32% of the cases, respectively (unknown in 4). TC ranged from 2-99% (mean 47.6%) and PTB from 1-64 (mean, 10). A PTB cutoff of 16.9 (determined by receiver operative curve analysis)

was able to stratify patients into high and low risk groups with significantly different RFS (Fig 1) and OS (Fig 2) rates. Additionally, a high PTB was predictive of a worse outcome (hazard ratio, 5.5; 95% confidence interval, 2.2-13.7) in patients with lymph node negative disease ($P=0.0002$).

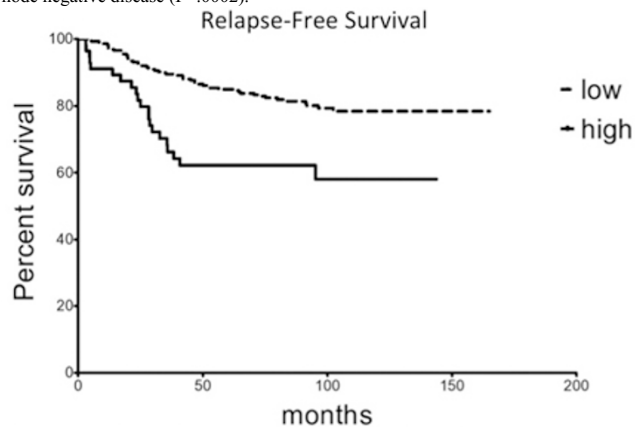


Fig 1. Hazard ratio high vs. low risk, 3.5 (95% CI, 1.8 – 6.9); $P=0.0002$

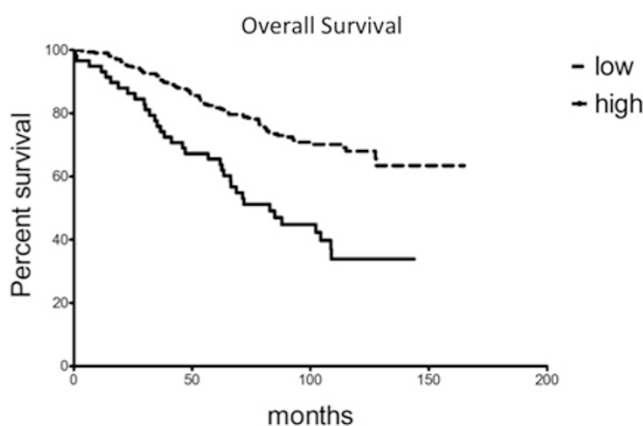


Fig 2. Hazard ratio high vs. low risk, 3.6 (95% CI, 2.2 – 6.1); $P<0.0001$

Conclusions: Tumor cellularity appears to be a prognostic marker in primary breast carcinoma. Additional statistical analysis is being performed to determine whether incorporating this along with other established markers can better define outcomes.

244 Identification of Fusion Genes in Papillary Carcinomas of the Breast

JS Reis-Filho, A Mackay, PM Wilkerson, MB Lambros, A Gauthier, O Mariani, R Duprez, DN Rodrigues, M Mandour, C Maher, B Weigelt, R Natrajan, A Vincent-Salomon. The Institute of Cancer Research, London, United Kingdom; Institut Curie, Paris, France; Washington University in St Louis, St Louis; Cancer Research UK London Research Institute, London, United Kingdom.

Background: Papillary carcinoma is a histological special type of breast cancer accounting for approximately 1% of all invasive breast cancers. Papillary carcinomas constitute a group of tumours that are part of the spectrum of oestrogen receptor (ER)-positive 'luminal' breast cancers. Three variants of papillary carcinomas are currently recognised: encapsulated (EPC), solid (SPC) and invasive (IPC) papillary carcinomas. The aim of this study was to investigate whether papillary carcinomas of the breast are underpinned by novel expressed fusion genes/ chimaeric transcripts.

Design: Eight frozen papillary carcinomas (three EPCs, three IPCs, and two SPCs) were subjected to paired-end massively parallel RNA sequencing. cDNA libraries were prepared according to a modified Illumina mRNA protocol and run on the Genome Analyzer II sequencers (read length of each mate pair = 72bp; two lanes per sample). Data were aligned to the genome and transcriptome using Bowtie and mate-pairs supporting novel chimaeric transcripts identified using Chimerascan version 4.0. High confidence nominated fusion genes were validated using reverse transcription (RT)-PCR.

Results: Analysis of papillary carcinomas led to the identification of high confidence chimaeric transcripts in seven samples. One EPC did not harbour any high confidence chimaeric transcripts. Using validated approaches, 22 high confidence novel expressed chimaeric transcripts were found, of which 17 were intra-chromosomal and five were inter-chromosomal chimaeric transcripts. Seven of these chimaeric transcripts were predicted to produce in-frame fusion proteins, and these included a reciprocal inter-chromosomal translocation $t(1;12)(q23.3;q23.1)$ fusing exon 7 of *USF1* to exon 14 of *CCDC38*. We also observed an out-of frame chimaeric transcript involving *ZNF57* and *TMPRSS9* that was recurrent in two of the samples analysed (one EPC and one IPC). This out-of-frame chimaeric transcript may lead to loss of function of both genes. Out of the in-frame chimaeric transcripts identified, one of the 5' gene partners contained an oestrogen-responsive element.

Conclusions: Unlike other special histological types of breast cancer, which are underpinned by specific recurrent fusion genes (e.g. secretory and adenoid cystic carcinomas), papillary carcinomas are unlikely to be characterised by the presence of a highly recurrent fusion gene.

245 Progesterone Receptor and HER2 Status Are Significant Prognostic Factors in Advanced Breast Cancer

Z Ren, O Hameed, Y Li, GP Siegal, S Wei. University of Alabama at Birmingham, Birmingham.

Background: About 90% of breast cancer (BC) mortality is due to distant metastases that are resistant to adjuvant therapies. Thus, assessment of factors associated with clinical outcomes in patients with advanced BC is of significant importance. We have previously found that PR and HER2 status are significant prognostic markers for post-metastasis survival in a small patient cohort. In this study, we sought to determine significant clinicopathological factors in predicting overall survival (OS) in a larger patient population.

Design: The tumor registry of the authors' institution was searched to identify BC cases with associated distant (bone, visceral organ, brain) metastasis. The clinicopathological characteristics of BCs were examined, including age, race, tumor size, tumor type, histologic grade, number of positive lymph nodes, ER, PR and HER2 status, to identify factors significant for OS.

Results: Of all BC patients diagnosed from 1997 to 2010, 552 had distant metastases either at the time of diagnosis (n=206) or subsequently (n=346). By univariate analysis, race, histologic grade, ER, PR and HER2 status were significantly associated with OS. However, applying a multivariate Cox regression model showed that only PR and HER2 were independent factors for OS. Patients with PR+ BCs had significantly better survival [hazard ratio (HR)=0.6 (0.5-0.8); p=0.013]. Interestingly, HER2 overexpression/amplification was associated with a favorable clinical outcome [HR=0.6 (0.4-0.7); p=0.0001]. However, HER2-targeted therapy with Trastuzumab did not add significant survival benefit in the subset patients with HER2+ BCs.

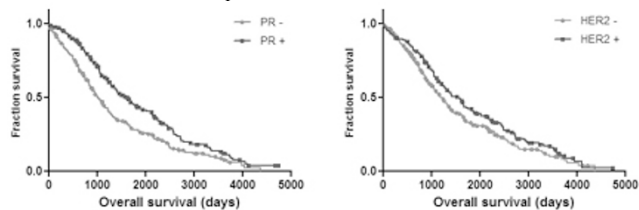


Figure 1. Kaplan-Meier curves of OS by PR and HER2 expression

Conclusions: A number of prognostic factors have been established in early stage BCs, including age, race, tumor size, nodal status, histologic grade, ER, PR and HER2 status. However, our data suggest that such findings may not entirely apply to advanced BCs. We found that PR overexpression was associated with prolonged OS, thus providing significant prognostic value beyond ER alone. In contrast to its negative impact on OS in early BC, HER2 overexpression/amplification was associated with a favorable OS in patients with metastatic BCs. The mechanism by which HER2-targeted therapy did not provide survival benefit in this subset of patients remains to be determined.

246 Expression of Androgen Receptor and Its Active (Phosphorylated) Forms in Breast Cancer Progression

Q Ren, S Jain, R Ruoff, L Zhang, V Reuter, J Melamed, M Garabedian, P Lee, S Logan. New York University School of Medicine, New York, NY; Memorial Sloan Kettering Cancer Center, New York, NY.

Background: Androgen receptor (AR) expression is reported in ~70% of breast cancers. We studied the expression of AR and its phosphorylated forms at Ser-213 and Ser-650, which modulate its activity, in breast cancer and its clinicopathological correlation.

Design: Immunohistochemistry was performed using specific antibodies against AR, ARSer(P)-213 and ARSer(P)-650 in localized (n=68) and metastatic (n=32) breast cancers as well as benign controls (n=34) using tissue microarrays. Intensity levels [0 (negative) - 3 (strong)] for cytoplasmic and nuclear expression were scored, and combined with percentage of positive cells to generate a histoscore for statistical analysis with an unpaired t-test.

Results: Nuclear staining of AR is seen in all benign tissue (100%) and 64 of 96 cancers (67%). The mean expression of nuclear AR is decreased 1.9-fold in cancers compared to controls (p<0.0001) (see table). Distinct patterns of expression of ARSer(P)-213 and ARSer(P)-650 were observed in breast cancer. The nuclear staining of ARSer(P)-213 is increased in breast cancers by 1.9-fold (p=0.003), while the nuclear and cytoplasmic ARSer(P)-650 expressions are both significantly decreased in tumors (p<0.0001). Cytoplasmic ARSer(P)-650 expression is lower in high stage cancers or those with lymph node involvement (p<0.005), while cancers with distant metastasis show a higher nuclear ARSer(P)-650 expression (p<0.05). ER negative cancers show an increase in cytoplasmic ARSer(P)-213 and ARSer(P)-650 expression (p< 0.05). Compared to invasive lobular carcinoma, invasive ductal carcinoma (IDC) shows increased cytoplasmic ARSer(P)-213 and ARSer(P)-650 expression (p<0.0005).

Ratio of expression levels of AR/phosphorylated forms in clinical subgroups [statistical significance values only(p<0.05). N: nuclear; C: cytoplasmic].

	Cancer / Benign	ER- /ER+	Ductal / Lobular	High / Low Stage	Positive / Negative Node	Metastasis / Localized
AR-N	0.5	0.4	-	-	-	-
ARSer(P)-213-N	1.9	-	-	-	-	-
ARSer(P)-213-C	-	2.5	24.1	-	-	-
ARSer(P)-650-N	0.5	0.6	-	-	-	1.7
ARSer(P)-650-C	0.6	1.4	3.0	0.6	0.6	-

Conclusions: We demonstrate up-regulation of ARSer (P)-213 expression (nuclear) and down-regulation of ARSer(P)-650 (nuclear and cytoplasmic) in breast cancer. The cytoplasmic up-regulation of both correlates with breast cancer with poor prognosis (ER negative and IDC). Up-regulation of nuclear ARSer(P)-650 expression in metastatic breast cancer suggests the phosphorylation of AR at Ser-650 may play a role in cancer progression.

247 Breast Cancer Subtypes and Epigenetic Characterization of in Women from Senegal, West Africa

M Rendi, KH Allison, J Stern, S Hawes, Q Feng, N Kiviat. University of Washington, Seattle.

Background: We have previously described the frequency of pre/postmenopausal breast cancer as well as risk factors in a large cohort of women from Senegal, West Africa. In this study, our aims were to further characterize these cancers and to determine the histology, immunohistochemical profile, and methylation status of pre- and postmenopausal breast CA in West Africans.

Design: As previously reported, 522 consecutive women presenting to the Dakar Tumor Institute, Senegal, West Africa with a breast mass were enrolled and underwent a physical examination and medical history. Needle core biopsy of the mass was performed with subsequent histologic and immunohistochemical analysis with HER2 gene amplification status in equivocal cases. Immunohistochemical results were used as a surrogate to determine the breast cancer subtypes. Additionally, the epigenetic profile of these tumors was assessed by examining the methylation status of 32 genes known to be involved in breast and other epithelial cancers.

Results: Of the 522 women enrolled, the presence of cancer was confirmed in 197, 57% of which were premenopausal, 43%, postmenopausal. 96% of cases were invasive ductal carcinoma, with cases of invasive lobular carcinoma (2%) and mixed ductal and lobular features (2%) comprising the remainder. 75% of the cancers were Grade 3, 21% were Grade 2, and 4% were Grade 1. The IHC status is as follows:

Immunohistochemical Characterization of Senegalese Breast Cancer

	ER+/PR+/HER2-	ER-/PR-/HER+	TN (% of TN cases also CK 5/6+)
Premenopausal	40%	19%	41% (53% CK 5/6+)
Postmenopausal	42%	13%	45% (47% CK 5/6+)
Total of all cases	43%	15%	42% (67% CK 5/6+)

TN = Triple Negative

Of the 32 genes evaluated for methylation status, 5 genes, GSTP1, RASSF1, APC, HS3ST2, and SCGB3a1 were found to be hypermethylated in cancer compared with controls. Interestingly, these genes were only hypermethylated in the cancers that were positive for ER, PR, and/or Her2/neu expression whereas the triple negative cancers were found to be hypomethylated compared with controls.

Conclusions: Breast CA, in this population, was most commonly high grade, invasive ductal carcinoma with a high percentage of triple negative, CK 5/6+ cancers in both premenopausal and postmenopausal women. 5 genes were significantly hypermethylated in cancers that expressed ER, PR, and/or HER2 but interestingly were found to be hypomethylated in the triple negative cancers compared with controls. These data have important implications for the understanding of the molecular basis of both premenopausal and postmenopausal breast CA in West African and potentially African American women.

248 Sphingosine Kinase Type 1 (SPHK-1) and Sphingosine-1-Phosphate Receptor 1 (S1PR1/EDG1) Positive Breast Carcinomas Are Associated with Increased Incidence of Distant Metastases

HT Richard, JP Bergeron, JA Almenara, MO Idowu. Virginia Commonwealth University, Richmond, VA.

Background: Sphingosine Kinase Type 1 (SPHK-1) and its metabolite, sphingosine-1-phosphate receptor 1 (S1P/EDG-1), have been implicated in cell growth, apoptosis suppression, and angiogenesis. Overexpression of SPHK-1 with concomitant increase in EDG-1 induces an anti-apoptotic effect, and recent studies suggest a relationship with poor outcome in breast carcinoma patients in this setting. We evaluated the relationship between SPHK-1/EDG-1 expression and distant mets along with other clinicopathologic parameters including Ki-67, local recurrence, triple negative hormone receptor (HR) status, and lymph node (LN) status.

Design: Clinical outcome and pathologic characteristics of breast cancer cases from 1992 to 2008 were reviewed. A minimum of 60 mos of follow-up was required for inclusion of cases without recurrence or metastases. Tissue microarrays (TMA) were created by obtaining 1 mm cores in triplicate from different areas of the tumor using an automated TMA system (Beecher ATA-27). Specimens were stained with rabbit polyclonal antibodies to SPHK-1 and EDG-1 (Abcam, Ma USA). For EDG-1, moderate to intense membranous staining was positive; for SPHK-1 moderate to intense cytoplasmic and/or nuclear membrane staining was pos. Cases were independently scored by two pathologists. Statistical significance was determined by a Chi-squared test.

Results: 278 SPHK-1 cases and 255 EDG-1 cases were scorable. Median follow-up for all cases was 72 mos, ranging from 12 to 228 mos. 85 SPHK-1 cases and 79 EDG-1 cases having distant mets and/or loco-regional recurrence were identified. A higher fraction of cases with distant mets was associated with SPHK-1 and EDG-1 positivity

(51 vs 34, $p=0.009$ and 60 vs 19, $p=0.05$), respectively. Additionally, EDG-1 positivity was associated with high Ki-67 ($>30\%$) ($p=0.016$), whereas SPHK-1 positivity was associated with triple negative HR status ($p=0.007$) and axillary LN positivity ($p=0.03$).

SPHK1/EDG1	SPHK1 pos	SPHK1 neg	EDG1 pos	EDG1 neg
% dist mets (n=85/79)	60% (51)	40% (34)	76% (60)	24% (19)
% loc recur (n=32/27)	63% (20)	37% (12)	74% (20)	26% (7)
% grade III (n=108/98)	63% (68)	37% (40)	69% (68)	34% (30)
% high Ki67 (n=93/89)	68% (63)	32% (30)	74% (66)	26% (23)
% triple neg (n=73/66)	55% (40)	45% (33)	68% (45)	32% (21)
% LN pos (n=115/104)	72% (83)	28% (32)	71% (74)	29% (30)

Conclusions: The association of SPHK-1 and EDG-1 pos tumors with an increased rate of distant mets suggests they play an important role in tumor progression and may be a target for novel therapeutics.

249 Androgen Receptor Positive Breast Cancers Are Associated with Better Prognosis Compared with Androgen Receptor Negative Cancers

HT Richard, JP Bergeron, JA Almenara, MO Idowu. Virginia Commonwealth University, Richmond, VA.

Background: Androgen receptor (AR) status has been suggested to be of potential prognostic as well as therapeutic importance in post-menopausal breast carcinoma patients. However, few studies have examined the association of AR with triple negative breast cancer, distant metastasis, and loco-regional recurrence. This study evaluated the relationship between AR status and the rate of distant metastasis, triple negative breast cancers, loco-regional recurrence, ER status, and axillary lymph node status.

Design: The clinical outcomes and pathologic characteristics of breast carcinoma cases from 1992 to 2008 were reviewed. A minimum of 5 years of follow-up was required for inclusion of cases without recurrence or metastases. For each case, tissue microarrays (TMA) were created by obtaining 1 mm cores in triplicate from different areas of the tumor using an automated TMA system (Beecher ATA-27). The specimens were stained with a mouse monoclonal antibody to androgen receptor (Dako, USA). Each case was reviewed independently by two pathologists, and cases with moderate to intense nuclear staining were considered positive. Statistical significance was determined using a Chi-squared test.

Results: Of 279 cases, 82 were found to have distant metastases and 30 had loco-regional recurrence. The median follow-up period for all cases was 72 months, and ranged from 12 to 228 months. AR positive cases were associated with a decreased incidence of distant metastases when compared to AR negative tumors (48 vs 34, $p=3.3 \times 10^{-6}$). Additionally, AR negativity was associated with high Ki67 ($>30\%$), triple negative hormone receptor status, and high histologic grade. Interestingly, a greater percentage of AR positive tumors were more likely to have lymph node metastases at the time of diagnosis (76 vs 37, $p=0.16$), although it was not statistically significant. No significant difference in the effect of AR status was noted between patients greater than or less than 55 years of age.

	AR pos	AR neg
% distant mets (n=82)	41% (34)	59% (48)
% local recur (n=30)	43% (13)	57% (17)
% grade III (n=104)	33% (34)	67% (70)
% high Ki67 (n=94)	30% (28)	70% (66)
% triple neg (n=73)	16% (12)	84% (61)
% ER pos (n=181)	85% (153)	15% (28)
% LN pos (n=113)	67% (76)	33% (37)

Conclusions: Androgen receptor positive tumors are associated with decreased incidence of metastases and loco-regional recurrence, irrespective of age. Therefore, AR may be a useful marker for prognosis as well as a potential target for novel therapeutics.

250 Meta-Analysis of Gene Expression Profiling Datasets To Uncover Biological Pathways and Candidate Biomarkers Associated with Progression in DCIS

JN Robens, SJ Schmitt, AH Beck. Beth Israel Deaconess Medical Center, Boston.

Background: The frequency with which DCIS is encountered in clinical practice has dramatically increased in recent years. Factors associated with progression of DCIS to invasive cancer remain poorly understood. Prior genome-wide studies to identify markers associated with risk of progression in DCIS have been limited by small sample size. We undertook a meta-analysis of breast cancer progression-associated gene expression profiling data sets to discover biological pathways and candidate biomarkers of progression in DCIS.

Design: We searched the NCBI's Gene Expression Omnibus to identify gene expression profiling datasets containing samples from DCIS and/or normal breast and/or invasive ductal carcinoma (IDC) with at least 5 samples in each category. We identified a total of 5 data-sets. Within each dataset, we performed 2-class Significance Analysis of Microarrays (SAM) to identify genes differentially expressed between normal and DCIS, normal and IDC, and DCIS and IDC at a false discovery rate (FDR) $\leq 10\%$. We performed a total of 13 SAM analyses over 12,755 genes.

Results: Overall, the largest changes in gene expression in both the epithelium and stroma occur during progression from normal to DCIS with fewer altered genes during progression from DCIS to IDC. When analyzing all comparisons together, we identified a core set of 44 genes differentially expressed in $\geq 60\%$ of the analyses. This gene list is highly enriched for genes related to the extra-cellular matrix (Bonferroni $p=3.5e-7$) and genes regulating angiogenesis (Bonferroni $p=0.002$). Top genes identified in our analysis as most consistently showing altered expression during progression (including progression from DCIS to IDC) include: CALD1 (caldesmon), POSTN (periostin), LHFP (lipoma HMGIC [high mobility group protein isoform I-C] fusion partner, LMO2 (LIM only domain 2), COL1A2 (collagen alpha 2-1), INHBA (inhibin beta-A), COL10A1 (collagen, type X, alpha-1), KRT14 (keratin 14).

Conclusions: In this meta-analysis of gene expression profiling data sets, we identified biological pathways and a core set of genes consistently showing altered expression during breast cancer progression. The most dramatic changes in gene expression occur in the transition from normal to DCIS. The top genes associated with the transition from DCIS to IDC are stromal-related rather than epithelial-related. These data provide insight into the biology of breast cancer progression, and core genes identified in our analysis represent candidate prognostic biomarkers for DCIS.

251 Integrative Analysis of Papillary Carcinomas of the Breast

DN Rodrigues, P Wilkerson, R Duprez, A Mackay, MB Lambros, A Gauthier, O Mariani, M Mansour, R Natrajan, B Weigelt, A Vincent-Salomon, JS Reis-Filho. The Institute of Cancer Research, London, United Kingdom; Institut Curie, Paris, France; Cancer Research UK London Research Institute, London, United Kingdom.

Background: Papillary carcinoma (PC) is a rare histological special type of breast cancer associated with a relatively good prognosis. Three morphological variants of PC (encapsulated (EPC), solid (SPC), and invasive (IPC)) are currently recognised. Few studies to date have investigated the repertoire of genomic alterations of papillary carcinomas. The aims of this study were (i) to identify recurrent copy number aberrations in PCs, (ii) to identify genes that are consistently overexpressed when amplified in PCs, and (iii) to determine whether the three morphological subtypes of PC are characterised by distinct copy number or gene expression profiles.

Design: Twenty-two frozen PCs of the breast (10 EPCs, 6 IPCs, 5 SPCs, and 1 mixed EPC-SPC) were subjected to Affymetrix SNP6 genotyping and gene expression profiling using the Illumina HT12 platform. Hierarchical clustering was performed using categorical copy number states and gene expression data to identify subgroups of PCs. Supervised analysis of the different histological variants of papillary carcinomas was performed. SNP6 copy number and gene expression data were overlaid to determine genes whose expression is regulated by gene copy number aberrations.

Results: PCs displayed the genomic aberrations found in oestrogen receptor (ER)-positive breast cancers of low histological grade, including gains of 1q, 8q, 16p, and 20q, and losses of 8p, 11q and 16q. Recurrent amplifications mapping to 8p12-p11, 11q13, and 20q13 were observed. Hierarchical cluster analysis of the gene expression data revealed a cluster significantly enriched for EPCs. Significance analysis of microarrays identified seven genes significantly differentially expressed between EPCs and non-EPCs (i.e. *NFKBIZ*, *ERP27*, *H2AFY2*, *ARHGDI3*, *YPEL2*, *INADL* and *GBP3*). Overlay of SNP6 copy number and gene expression data identified 3899 genes whose expression was copy number regulated. Functional annotation of these genes revealed a significant enrichment for genes playing a role in the PI3K/AKT/mTOR and oestrogen receptor signalling pathways. Furthermore, 6 genes were found to be overexpressed when amplified, all mapping to the 11q13 amplicon (i.e. *CCND1*, *ORAOV1*, *FADD*, *PPF1A1*, *CTTN* and *SHANK2*).

Conclusions: Papillary breast carcinomas have genomic aberrations consistent with those reported for ER-positive invasive ductal carcinomas of no special type. Integration of gene copy number and gene expression data revealed that activation of the PI3K/AKT/mTOR pathway may be driven by genomic aberrations in these cancers.

252 Selection of Breast Core Biopsy Specimens for Tissue Biorepository

DG Rosen, LP Middleton, WT Yang, AA Sahin. Baylor College of Medicine, Houston, TX; MD Anderson Cancer Center, Houston, TX.

Background: Neoadjuvant therapy has been widely adopted in breast cancer patients. With the advent and success rate of such practice the amount of tissue that is available for further testing in subsequent resection specimens can be scant. Furthermore, the tumor morphology and biomarker expression may be altered due to the previous exposure of such therapy agents. Hence, some institutions are considering the acquisition of an additional core needle biopsy at the time of the procedure. This additional fragment of tissue may be used for future marker testing if the patient is enrolled in a research protocol not affecting the diagnostic material. Tissue bio-repositories represent an invaluable resource for research studies and provide a tissue reservoir for future tests. Therefore, tissue samples collected and stored during the initial diagnostic procedure has been suggested. The aim of this study is to determine the impact of selecting random tissue cores for breast cancer bio-repository.

Design: A total 988 ultrasound guided core biopsies from 242 specimens corresponding to 224 patients between 2008 and 2009 were examined. Each core was examined percentage of tumor present and diagnostic adequacy. Only specimens with presence of invasive carcinoma were included for this analysis. Cores with $< 10\%$ of tumor were considered as low cellularity for bio-repository.

Results: The average number of cores per specimen was 4 (range 2 to 8) with an average core size length of 0.95 cm (range 0.1 cm to 3.5 cm). In addition, 3 of the 242 specimens showed fragmented core pieces ranging from 0.1 to 0.9 cm in aggregate. Needle size ranged from 21 to 12 gauge. In 66 specimens (41%) there was at least 1 core with $< 10\%$ tumor cellularity. In 95 specimens (59%) all cores had $> 10\%$ of tumor cellularity and in 12 specimens all cores showed $< 10\%$ tumor cellularity. A total of 789 cores (80%) were considered of good diagnostic quality, 185 cores (19%) adequate with minor diagnostic artifacts, and 14 cores (1%) insufficient for diagnosis. The later were considered as insufficient for diagnosis due to scant tumor present on 3 cases.

Conclusions: If extra core biopsy will be used for future studies a quality control of tissue such as touch imprint, frozen sections, or other innovative techniques should be utilized in order to increase the chance of obtaining tissue with adequate tumor. At the present time, laboratory techniques that use paraffin embedded tissue for testing may be a better alternative until these issues are resolved. Future studies are guaranteed.

253 Comprehensive Genomic Profiling of Breast Cancer by Massively Parallel Sequencing Reveals New Routes to Targeted Therapies

J Ross, C Sheehan, A Parker, M Jarosz, S Downing, R Yelensky, D Lipson, P Stephens, G Palmer, M Cronin. Albany Medical College, Albany, NY; Foundation Medicine Inc., Cambridge, MA.

Background: The recent introduction of massively parallel (next-generation) DNA sequencing to clinical samples has enabled the discovery of novel and unanticipated genomic-derived drug targets of therapy for patients with refractory metastatic breast cancer.

Design: After DNA was extracted from 4 formalin-fixed paraffin embedded sections cut at 10 microns from 15 cases of primary invasive breast carcinomas, the exons of 145 cancer-related genes were fully sequenced by next-generation technology using the Illumina HiSeq 2000 (Illumina Inc. San Diego, CA) to an average sequencing depth of 253X. Tumoral DNA was evaluated for point mutations, insertions, deletions, copy number alterations and translocations.

Results: 15/16 (94%) of the tumors revealed 33 total somatic genomic alterations (mean 2.2 alterations per tumor) with a range of 0 to 4 alterations per sample. Standard of care alterations consisted of 3(19%) tumors with *HER2* copy number increases. The NGS *HER2* copy number measurements by NGS in the *HER2* amplified cases averaged 80% of the counted *HER2* copies on FISH assessment of the same tumor block. Genes co-amplified with *HER2* included *RARA*. 10/16 (63%) of tumors harbored at least one alteration that potentially could have led to clinical trials of novel targeted therapies including copy number increases for *IGF-1R* in 2 (13%) tumors [IGF-1R inhibitors], *MDM2* in 1 (6%) tumor [nutlins], *CCND1* in 3 (19%) tumors [CDK inhibitors], *CCNE1* in 1 (6%) tumor [CDK inhibitors] *CDK4* in 1 (6%) tumor (CDK inhibitors), and *FGFR1* in 1 (6%) tumor (FGFR1 inhibitors). 5 (31%) of tumors had 1 or more *PIK3CA* mutations [PIK3CA and mTOR inhibitors]. 6/16 (38%) of tumors had alterations classically associated with adverse clinical outcome including *TP53* and *PTEN* mutations and *HER2* copy number increases.

Conclusions: Deep massively parallel DNA sequencing of clinical breast cancer samples uncovers an unexpectedly high frequency of genomic alterations that could influence therapy selection for the disease. Deep sequencing of genomic DNA can provide a broad cancer-related gene survey at a depth of coverage that provides sensitive detection for all classes of genomic alterations, and when applied to breast cancer patients can reveal actionable genomic abnormalities that inform treatment decisions.

254 Fibroepithelial Lesions in the Breast of Adolescent Females: A Clinicopathological Profile of 35 Cases

DS Ross, DD Giri, MM Akram, J Catalano, KJ Van Zee, E Brogi. Memorial Sloan-Kettering Cancer Center, New York.

Background: Fibroepithelial lesions (FELs) are the most frequent breast abnormality in females 18 years-old or younger (F≤18). Hormonal changes could impact the diagnosis and clinical course of FELs in this age group. We investigated morphology and clinical behavior of FELs in adolescent females.

Design: We searched the 2000-2011 pathology database for breast FELs in F≤18. FELs in the same age group from a published series (Barrio A, Ann Surg Oncol, 2007) were also included. Two pathologists reviewed all available slides and assessed smooth muscle actin (aSMA) staining (1A4, DAKO) on available lesional tissue. Patient information (INFO) and clinical follow-up (F/U) were obtained from e-medical records.

Results: The study cases are 35 FELs from 30 F≤18; 3 patients (pts) had multiple unilateral FELs, 3 others had bilateral FELs. The median age at diagnosis was 16 y (range 10-18). Race INFO was available for 18 pts: 12 were Caucasian, 4 African-American, and 2 Hispanic. Median age at menarche was 12 y (range 11-14) for 13 pts with available INFO; 12/13 had a FEL at a median of 48 months (mo) (range 0-72) after menarche, 1/13 had a FEL 12 mo prior to menarche. All pts underwent excision; 1 pt subsequently underwent mastectomy. Clinical presentation INFO was available for 26 FELs: 25/26 (96%) were palpable (palp) [22/25 (88%) were also detected on ultrasound (US)]; the non-palp FEL was found at US because of a palp ipsilateral FEL. The FELs were 20 fibroadenomas (FAs) and 15 phyllodes tumors. Table 1 summarizes morphology and F/U INFO.

Short fascicles admixed with collagen occurred in 100% of juvenile FAs (JFAs). Stromal expansion with pericanalicular pattern typified all 3 variant JFAs. All JFAs, variant included, were strongly aSMA positive.

FEL Characteristics

	N	Mean Age, Years (range)	Gross Size (cm)	Mitoses/10 HPF	Recurrent Cases	Months to Recurrence	Follow-Up (months)
Fibroadenoma	20	15.4 (11-18)	2.9 (0.7-6)	1 (0-7)	0	-	47 (0-326)
Usual	5	16.8 (15-18)	2.2 (0.7-3.8)	1 (0-2)	0	-	9 (0-17)
Juvenile	12	15 (11-18)	3.1 (1.5-6)	2 (0-4)	0	-	61 (0-326)
Juvenile Variant	3	14.7 (11-17)	3.3 (2.5-4)	3 (0-7)	0	-	58 (0-94)
Phyllodes Tumor	15	14.9 (10-18)	5.8 (1-25)	6 (1-20)	2	Mean 14.5	45 (0-278)
Benign	11	15 (10-18)	3.3 (1-8.5)	3 (1-7)	1	18	17 (0-109)
Low Grade	1	15	-	10	1	11	118
Malignant	3	14.7 (13-16)	14.5 (4-25)	17 (12-20)	0	-	123 (0-278)

Conclusions: Mitoses are common in FELs from F≤18 y, and can be substantial even in FAs. This finding should not be over interpreted in FELs from this age group. Our results provide a useful reference to pathologists and clinicians treating adolescents with FELs.

255 Invasive Lobular Carcinoma and Oncotype Dx®: Impact of Pathology and Recurrence Score on Treatment Plan

DS Ross, LC Galman, J Catalano, LK Tan. Memorial Sloan-Kettering Cancer Center, New York.

Background: Oncotype Dx® Breast Cancer Assay is a 21-gene assay that predicts whether certain patients with ER-positive breast cancer will benefit from chemotherapy.

The goal of this project is to examine the impact of pathology and Oncotype Dx® Recurrence Score (RS) on the treatment plan for invasive lobular carcinoma (ILC).

Design: A search of the 2008-2011 pathology database was performed for cases of ILC submitted for Oncotype Dx® testing. The pathology, test results and treatment regimen for each patient was obtained. The histopathologic features of the tumors were recorded as were the results of their Oncotype Dx® RS. The latter was categorized into different risk categories based on the guidelines set forth by Oncotype Dx®: low risk (LR) <18, intermediate risk (IR) 18-30, high risk (HR) >30.

Results: A total of 1489 specimens were sent for Oncotype Dx® testing during the study period. Of these, 135 (9%) cases were classified as ILC. The age of the patients, tumor size and subtype, nodal status, Oncotype Dx® RS and treatment for the 3 risk groups are summarized in Table 1. The overall mean age was 58 years-old (range 34-79) and the overall mean tumor size was 1.6 cm (range 0.3-4.3 cm). The histology of the ILC was classical (n=108, 80%), pleomorphic (n=13, 10%), classical and pleomorphic (n=14, 10%). Twelve (9%) out of 133 patients that had axillary lymph node (LN) sampling had metastases (range 1-2 positive LN). All tumors were Her-2/neu negative by immunohistochemistry. The overall mean Oncotype Dx® RS was 16 (range 5-33), with the following distribution: LR 85 (63%), IR 48 (36%), HR 2 (1%). No patients with classical or mixed type ILC or with LN metastases were classified as HR. Two (15%) out of 13 pleomorphic ILC were in the HR category with scores of 31 and 33. Forty-two (31%) patients received chemotherapy (CT), 108 (80%) hormone therapy (HT) and 72 (53%) radiation therapy (RT).

ILC Characteristics

	LR (<18)	IR (18-30)	HR (>30)
N (total 135)	85	48	2
Age (yrs)	57 (34-79)	59 (45-77)	69 (61-76)
Tumor Size (cm)	1.7 (0.5-4.3)	1.4 (0.3-3.6)	1.8 (1.2-2.4)
Histology			
Classical	73	35	0
Pleomorphic	2	9	2
Classical & Pleomorphic	10	4	0
LN Metastasis	9	3	0
Recurrence Score	13 (5-17)	21 (18-29)	32 (31-33)
Treatment			
CT	15	25	2
HT	72	34	2
RT	42	29	1

Conclusions: 1) Regardless of subtype, 99% of ILC are in the LR/IR categories. 2) The clinical decision for administering CT in our study population was not based on Oncotype Dx® RS but determined by clinicopathologic variables. 3) Oncotype Dx testing does not provide additional predictive information for clinical management of patients with ILC.

256 Immunophenotype Profile of Breast Carcinoma Brain Metastases in Comparison to Their Breast Primaries

RS Saad, A El-sayed, A Shehata, M Mashhour, W Hanna. Sunnybrook Health Sciences Centre, Toronto, Canada.

Background: Brain metastases (BM) arising from breast cancer correlates with a poor prognosis. Identification of tumor characteristics associated with breast cancer brain metastases (BCBM) could help identify patients at risk. There is few information available on hormonal status in breast carcinoma metastatic to brain.

Design: Computer search identified patients with breast cancer (BC) brain metastases who were diagnosed between 2000 and 2010. Hormonal receptors and Her2/neu were performed on both primary and metastatic brain tumors. Survival and disease recurrence patterns were evaluated by age, hormonal and Her2/neu status using the Kaplan-Meier method and Cox regression analysis.

Results: Our study included 130 patients with BC brain metastases with mean age 47±9 years. The median age at diagnosis of primary breast carcinoma and brain metastasis was 43 and 47 years, respectively. The median interval between both diagnoses in this subgroup was 32 months. Metastatic tumor was located in cerebellum in 60/130 (46%), cerebrum in 57/130 (44%) and 13/130 (10%) in vertebral column. Primary breast carcinoma demonstrated high-grade in 87/130 (67%), intermediate grade in 39/130 (30%) and low grade 4/130 (3%). Primary breast carcinoma was ER positive in 56/130 (43%) (5 low positive and 51 strongly positive), PR positive in 46/130 (35%) (3 low positive and 43 strong positive), and Her2/neu was positive in 41/130 (32%). ER change from positive to negative in 7/130 (5%) cases and from negative to positive 4/130 (3%), PR status from positive to negative in 10/130 (8%) and negative to positive 2/130 (2%). None of our cases shows any change of Her2/neu status between primary and metastatic tumor. Tumor grade correlate negatively with ER, and PR status, but not with Her2/neu status. Her2/neu was correlated with age (younger age show positive results) (P<0.05). Only Her2/neu status shows significant correlation with patient survival.

Conclusions: Expression of antigens commonly associated with breast carcinoma does not differ significantly between the primary tumor and the corresponding brain metastases. No specific immunoprofile identifies breast carcinomas that develop brain metastases, although Her2/neu status was associated with poor survival.

257 Mammary Amyloidosis: A Series of 44 Cases from a Single Institution

SM Said, C Reynolds, RE Jimenez, B Chen, JA Vrana, JD Theis, A Dogan, SS Shah. Mayo Clinic, Rochester, MN.

Background: Amyloidosis is a disorder characterized by extracellular accumulation of Congo red positive fibrillar deposits resulting from abnormal folding of proteins. More than 20 precursor proteins of amyloid have been identified so far, with the most common types being immunoglobulin light-chain (AL) amyloidosis secondary to plasma cell dyscrasia and reactive secondary (AA) amyloidosis associated with chronic

inflammatory diseases. AL amyloidosis is usually systemic and commonly involves the heart, kidney, gastrointestinal tract, and tongue. Breast involvement by amyloidosis has rarely been reported.

Design: Forty-four cases of mammary amyloidosis diagnosed from 1995 to 2011 were identified at our institution. In 4 patients, the breast biopsies were performed at our medical center. In the remaining cases, the biopsies were performed at outside institutions and materials were sent to us for a second opinion or for amyloid typing by immunohistochemistry and/or mass spectrometry (MS).

Results: The study group included 43 women and 1 man with ages ranging from 36 to 85 yrs (mean 59 yrs). Clinical presentation was breast mass in 12 cases, calcifications in 6 cases and unknown in 26 cases. Amyloid deposition was in the right breast in 22 (50%), in the left breast in 19 (43%), and bilateral in 2 (5%) patients; the site was not indicated in 1 (2%) patient. The type of amyloidosis was AL in 24 cases (14 AL-kappa, 10 AL-lambda) and heavy and light chain (IgA-lambda) in one case. None of the cases showed AA amyloidosis. For the remaining 19 cases, typing was not performed or was inconclusive. MS established the type of amyloid in 16 of 17 (94%) cases tested. In addition to amyloidosis, the breast biopsy showed MALT lymphoma in 13 (30%) cases, plasma cell proliferative disorder in 6 (14%) cases, plasmacytoma in 1 (2%) case and CLL in 1 (2%) case. One patient had concurrent intraductal carcinoma, but none had invasive carcinoma. Of the 16 patients seen in our institution, 7 (44%) had amyloid deposition in one or more organ site (skin 3, lymph nodes 2, heart 2, soft tissue 2, lung/pleura 1, submandibular gland 1, and kidney 1).

Conclusions: Amyloidosis involving the breast is rare and when present is most commonly AL type. With the introduction of MS, the type of amyloid can be determined in the majority of cases. In our study, mammary amyloidosis is associated with concurrent hematologic malignancy in 48% of patients, of which 62% are MALT lymphoma. Involvement of additional organ sites is seen in over one third of our patients. Further work up to rule out hematologic malignancy and/or systemic amyloidosis is recommended.

258 Multicentric Comparative Study between One-Step Nucleic Acid Amplification (OSNA) Whole Node Assay and Standard Histology for Breast Sentinel Lymph Node: Molecular Assay Can Avoid Secondary Surgeries and Predict No Other Node Involvement

I Sansano, M Espinosa, C Iglesias, M Aizpurua, M Sancho, C Garcia, I Rubio, S Ramon y Cajal, V Peg. H. U. Vall d'Hebron, Barcelona, Spain; H. de Salamanca, Salamanca, Spain.

Background: Although the sentinel lymph node (SLN) biopsy is a common procedure in the management of early stage breast cancer, SLN examination has not been standardized. Recently, the OSNA is being considered as a potential standard method, providing a semi-quantitative result in a short period of time according to the amount of CK19 mRNA copy number. The aims of this study were, first, to compare SLN intraoperative assessment with OSNA assay using a whole lymph node versus routine H&E frozen section (FS) and final histological diagnosis with a 2 mm-sectioned lymph node and second, to evaluate the ability of the molecular assay to predict non-SLN involvement.

Design: A cohort of 609 consecutive patients diagnosed between 2010 and 2011 with early breast cancer in two centers (H. de Salamanca, H.U. Vall d'Hebron, Barcelona) were analyzed. FS was performed intraoperatively in 303 patients and OSNA assay in 306 patients. Patients' characteristics were evaluated in both groups and rates of metastasis detected by both methods were compared. A lymphadenectomy was performed in all cases with SLN involvement detected either by OSNA or histology and non-SLN were only analyzed with H&E (1mm section).

Results: SLN metastasis was found in 80 cases (26.4%) by conventional H&E analysis and in 108 (35.3 %) by OSNA ($p=0.068$). 32 of the 80 positive cases (40%) from the FS group were only found after final histological evaluation (formalin fixed paraffin embedded blocks). 30 lymphadenectomies performed in the OSNA group showed non-SLN involvement (27.8%). Considering the amount of mRNA CK19 copies number in all positive SLNs per patient (total tumoral load (TTL)), 150000 copies cut-off was able to predict negative axillary dissections (negative predictive value=0.79, specificity=0.85, sensibility=0.43, $p=0.02$).

Conclusions: First, with the OSNA method there was a higher sensitivity in detecting metastasis than with conventional H&E. Despite this difference was not statistically significant ($p=0.068$), the molecular assay would have avoided second-time axillary dissection in 40% of positive cases from the FS group. Second, total amount of CK19 mRNA copies number was a good predictor of no further nodal involvement. However, real clinical value of TTL remains unknown. A recent multicentric study (B-CLOSER II) has just started, to try to answer this question.

259 Mitotic Figure Counts Are Significantly Higher in Breast Cancer Tumorectomy Specimen Than to Needle Biopsies

C Schaper, C Roehat, A Nobile, E Obermann, H-A Lehr. Breast Center Südbaden, Freiburg, Germany; CHUV, Lausanne, Switzerland; University Hospital, Basel, Switzerland.

Background: We tend to rather up- than down-grade breast cancers in tumorectomy specimen when compared to biopsy material and we had the vague impression that the effect is largely due to increased mitotic figure counts in tumorectomy specimen.

Design: We performed mitotic and apoptotic figure counts and immunohistochemical detection of cell cycle specific antigens (Ki-67, histone H3) in paired needle biopsy and tumorectomy specimen in two independent cohorts in Germany ($n=170$) and Switzerland ($n=52$). To exclude observer bias, counts were verified on virtual TMNs (blinded as to whether the scanned high power fields were from biopsies or from tumorectomies).

Results: The numbers of mitotic figures were significantly increased by a factor of 2.2 and 1.9 in the German and the Swiss cohorts, respectively. In contrast, the Ki-67

labeling index was comparable in biopsies and tumorectomy specimen in both cohorts. The spectrum of mitotic figures (from prophase to telophase) was significantly broader in biopsies than in tumorectomy specimen, where most mitotic figures were in pro-metaphase or in metaphase. The numbers of apoptotic figures were also increased in tumorectomy specimen when compared to biopsies.

Conclusions: We speculate that the increased numbers of mitotic figures in tumorectomy specimen reflects continued cell cycle progression into metaphase. Small biopsies are rapidly fixed (30min-1hr) while formalin only slowly penetrates larger tumorectomy specimen. As a consequence, biological processes, including passage through a committed cell cycle, may continue for quite some time in the tumorectomy specimen, resulting in higher numbers of mitotic figures.

260 Association of p27kip1 Expression and BRCA Status among Women with Breast Cancer: A Single Institution Study

M Schneider, C Albarracin, B Arun, AM Gutierrez Barrera, R Bassett, S Dawood, D Saab, L Gao, I Bedrosian, D Rosen. Baylor College of Medicine, Houston; The University of Texas MD Anderson Cancer Center, Houston; Dubai Hospital, Dubai, United Arab Emirates.

Background: p27kip1, a cyclin dependent kinase inhibitor that is transactivated by normally functioning BRCA1, acts as a potent tumor suppressor protein in many malignancies including breast cancer. Decreased p27kip1 expression has been associated with poor prognostic outcome among various groups of breast cancer patients, including BRCA mutation carriers. The objective of this study was to correlate p27kip1 expression in patients with known BRCA mutation status with clinico-pathological characteristics, hormonal receptor status and expression of human epidermal growth factor receptor 2 (HER2).

Design: Samples from 94 patients with known BRCA mutation status (age range 31-82 years) were assessed for p27kip1 expression using a tissue microarray (TMA). This TMA included the following subgroups: BRCA non-carrier ($n=15$), BRCA1 mutation carrier ($n=19$), BRCA2 mutation carrier ($n=21$), and sporadic breast cancer ($n=39$). Expression of p27kip1, estrogen receptor (ER), progesterone receptor (PR), and HER2 was evaluated by digital image analysis. Mean nuclear p27kip1 expression was defined as the average percent of positively stained tumor nuclei in a patient subgroup.

Results: The mean nuclear p27kip1 expression was observed in BRCA non-carriers, BRCA1 and 2 mutation carriers and sporadic patient populations at 95.6% (SD), 76.3% (SD), 94.3% (SD), and 91.2% (SD) respectively. Lower p27kip1 expression was significantly associated with BRCA1 mutation carriers ($p=0.0007$), grade III tumors ($p=0.0047$), ER negative tumors ($p<0.0001$), and PR negative tumors ($p=0.0187$). HER2 expression was not associated with p27kip1 expression ($p=0.8702$).

Conclusions: The results of this single institution study indicate that p27kip1 expression is decreased among BRCA1 mutation carriers, which supports a role for altered p27kip1 expression in BRCA1-associated breast cancer. Decreased nuclear p27kip1 is also associated with higher grade and hormone receptor negative tumors; all factors that are associated with a poor prognostic outcome. Further studies are warranted to analyze the prognostic and predictive significance of these findings. In particular, to determine if p27kip1 plays a unique role in clinical outcome.

261 VEGFA Amplification/Deletion in Human Breast Tumors

BP Schneider, M Radovich, B Hancock, N Kassem, G Sledge, K Vang Nielsen, S Muller, M Thorat, R Mehta, S Badve. Indiana University School of Medicine, Indianapolis, IN; Dako A/S, Glostrup, Denmark.

Background: The anti-VEGF antibody, bevacizumab, has been FDA approved for the treatment of breast cancer. While germline variability (ie, single nucleotide polymorphisms) may serve as a predictive marker for anti-VEGF therapy, to date tumor-specific variability has not. More specifically, amplification or deletion of the VEGFA gene has not been studied or evaluated as a predictive or prognostic biomarker for breast cancer.

Design: A VEGFA/centromere enumeration-6 (CEN-6) probe was created and validated using DNA clones and restriction enzyme fragment measurements. The final product contained a RP11-710-L16 probe covering 183 KB including the VEGFA gene and flanking regions. The CEN-6 probe was developed with fluorescein isothiocyanate labeled peptide nucleic acid oligonucleotides. VEGFA and CEN-6 probes were tested on metaphase spreads to exclude cross-hybridization to other chromosomes.

A tissue microarray containing 93 breast cancers was analyzed for the presence of VEGFA gene amplification and/or deletion using a FISH protocol similar to the TOP2A FISH pharmDx™ Kit. VEGFA/CEN-6 signal ratio in cancer cells was recorded. Normal cells in the tissue sections served as an internal positive control of pretreatment and hybridization efficiency. A ratio of <0.8 was considered deleted, $\geq 1.5-1.99$ was considered borderline amplified, whereas a ratio of ≥ 2.0 was considered amplified.

Results: Of the 93 core tissue specimens, FISH analysis was successful in 80 cases (86%) of the cases. Of these, 11% were found to demonstrate VEGFA deletions, 9% were borderline amplified, and 5% were amplified. Thus, 25% in total had genetic aberrations of this gene. The aberrations did not correlate with ER or HER2 expression.

Results	n=80	%
Deletion (<0.8)	9	11
Normal (0.8-1.49)	60	75
Borderline (1.5-1.99)	7	9
Amplified (≥ 2.0)	4	5

Conclusions: VEGFA gene aberrations are relatively common in primary breast cancers. Their role as predictors of response to anti-VEGF therapies remains to be studied.

262 Background Microenvironmental Changes in Atypical Hyperplasia of the Breast

JK Schoolmeester, LC Hartmann, MH Frost, DW Visscher. Mayo Clinic, Rochester, MN.

Background: Benign breast disease (BBD), encompassing nonproliferative changes, proliferative disease without atypia, and atypical hyperplasia (AH), has been proven an important risk factor for subsequent development of breast cancer. The comprehensive identification of these background microenvironmental changes in AH and whether they collectively represent a precursor state, contribute to or create the conditions necessary for development of epithelial atypia has not been previously studied.

Design: Background microenvironmental changes were assessed in 47 randomly selected biopsies with AH (25 atypical lobular hyperplasia, 22 atypical ductal hyperplasia) from women enrolled in our BBD cohort. This cohort consists of 9087 women, aged 18-85, who had a benign breast biopsy between 1967-1991. Each biopsy was evaluated for nonproliferative changes, proliferative disease without atypia, AH, and the presence of calcifications in benign or atypical ducts in a single slide.

Results:

Background Microenvironmental Changes	ALH, n=25	ADH, n=22
Nonproliferative Changes	22	17
Columnar Cell Lesions	20 (7 CC, 9 CH, 4 FEA)	19 (2 CC, 6 CH, 11 FEA)
Sclerosing Adenosis	11	11
Moderate-Florid Usual Ductal Hyperplasia	6	5
Radial Scar and/or Papilloma	5	10
Two Proliferative Lesions	11	13
Three Proliferative Lesions	1	1
Greater than Three Proliferative Lesions	2	3
Calcifications Associated with Benign Ducts	9	8
Calcifications Associated with Atypical Ducts	6	11

CC=Columnar Change, CH=Columnar Hyperplasia, FEA=Flat Epithelial Atypia

Conclusions: 1. Columnar cell lesions and sclerosing adenosis are the most common background alterations in the setting of AH.

- The frequency and quantity with which AH is associated with proliferative lesions are essentially equal.
- FEA is more frequent in the setting of ADH than ALH.
- In comparison to ALH, calcifications associated with atypical ducts are more common in ADH.
- The frequency of sclerosing adenosis and columnar cell lesions, particularly FEA, in AH, implies their pathogenesis is non-random and develops out of a limited set of precursors.

263 Cellular Spindled Histiocytic Pseudotumor Complicating Mammary Fat Necrosis: A Potential Diagnostic Pitfall

AP Sciallis, B Chen, AL Folpe. Mayo Clinic, Rochester, MN.

Background: Fat necrosis (FN) of the breast is a relatively common reactive/repairative process that may be either primary, often following trauma, or secondary to prior surgery or therapeutic irradiation. Primary mammary FN may closely mimic breast neoplasia, both clinically and radiographically, and is thus frequently biopsied. Recently, in consultation, we have seen a number of cases of mammary FN complicated by a cellular, spindled proliferation of macrophages, mimicking various spindle cell neoplasms of the breast. Herein we report our experience with these distinctive pseudotumors.

Design: Our institutional and consultation archives for the period 1994-2011 were searched for cases of mammary FN, yielding a total of 161 cases. For consultation cases, only those in which the submitting pathologist's differential diagnosis included a spindle cell neoplasm were included. For institutional cases, only those presenting as a mass lesion and showing a cellular spindle cell histiocytic proliferation were included. Nineteen cases met these criteria and comprised the final study group. All available routinely stained and immunohistochemical slides were re-reviewed.

Results: For consultation cases, suggested diagnoses included spindle cell metaplastic carcinoma, cellular fibroepithelial lesion with stromal overgrowth, desmoid-type fibromatosis, angiosarcoma and "atypical spindle cell proliferation". The morphologic features of all cases were similar, showing a moderately cellular, fascicular proliferation of mitotically active, normochromatic spindled cells, surrounded by more typical features of FN, including non-spindled, lipid-laden macrophages, inflammatory cells, degenerating adipocytes, calcification, and myofibroblastic and capillary proliferation. When performed, immunohistochemical studies showed the spindled cells to have a histiocytic phenotype, with expression of CD163 and CD68, and absent expression of various cytokeratins, S100 protein, p63, and beta-catenin.

Conclusions: We have presented 19 cases of a distinctive cellular proliferation of spindled histiocytes, arising in the setting of mammary FN. This presumably represents an exaggerated, unusual morphological manifestation of the normal response to FN in the breast. Awareness of this distinctive pseudotumor should help to prevent its misdiagnosis as various other spindle cell neoplasms that may involve the breast.

264 Upgrade Rates on Surgical Excision for Targeted vs. Incidental Radial Scars/Complex Sclerosing Lesions (RS/CSLs) Identified on Core Needle Biopsy (CNB)

M Shabani, TS Mehta, C Wells, JA Kraus, H Gilmore, SJ Schnitt, LC Collins. Beth Israel Deaconess Medical Center and Harvard Medical School, Boston, MA; Massachusetts General Hospital, Boston, MA; Case Western Reserve University, Cleveland, OH.

Background: Prior studies have suggested that a histologic diagnosis of RS/CSL warrants surgical excision because of its association with malignancy. Recent advances in imaging techniques and larger tissue sampling have resulted in increasing diagnoses of incidental RSs. While many studies have looked at upgrade rates on excision for RS/CSLs diagnosed on CNB, to our knowledge none have specifically compared upgrade rates in targeted versus incidental RS/CSLs.

Design: We retrospectively searched breast pathology tissue diagnoses and identified 74 cases of RS/CSLs reported on CNB over a 5-year period (2004-2009). Only those cases without associated atypia or carcinoma on CNB were included. A breast pathologist reviewed each case to confirm the diagnosis. Blinded to excision diagnoses, radiologic-pathologic correlation was performed to ascertain whether the RS/CSL on CNB was the target lesion or an incidental finding. Upgrade rates on excision were then determined for both groups.

Results: Of the 74 cases, 11 were excluded after initial pathology review (5 due to atypia and 6 with no RS/CSL). Twenty-four lesions were reclassified as sclerosing and/or intraductal papillary lesions, and 12 did not undergo excision, leaving a total of 27 cases with RS/CSLs on CNB and follow-up surgical excision. 21 RS/CSLs were targeted, and 6 were incidental to other targeted lesions (e.g. fibroadenoma, duct ectasia). Of the 21 targeted RS/CSLs, 6 (29%) were upgraded on excision (all atypical hyperplasias unassociated with the RS/CSL). Of note, among the 6 incidental RS/CSLs 3 (50%) were upgraded to atypical hyperplasia on excision.

Outcome of Targeted vs. Incidental RS/CSLs

RS/CSLs: 39	
27 Excised	
21 Targeted	6 Incidental
6 Upgraded (6 atypical hyperplasias)	3 Upgraded (3 atypical hyperplasias)
Upgrade Rate: 29%	Upgrade Rate: 50%

Conclusions: The upgrade rate for targeted radiologically concordant RS/CSLs remains unacceptably high to consider surveillance over excision. Even incidental RSs were associated with a high upgrade rate, though the sample size in this subset was small. Of note, however, none of the upgrades included DCIS or invasive carcinoma, and all of the atypical hyperplasias were remote from the RS/CSL in the excisions. Larger studies are still required before definitive recommendations can be made; currently, we continue to excise all radial scars diagnosed on core needle biopsy at our institution.

265 Axillary Recurrence after Negative Sentinel Lymph Node Dissection in Three Elderly Triple Negative Breast Cancer Patients

M Sharma, KA Skinner, DG Hicks, P Tang. University of Rochester Medical Center, Rochester, NY.

Background: Sentinel lymph node dissection (SLND) is now a standard of care for breast cancer patients with clinically negative axillary nodes. The rates for axillary recurrence in SLN negative patients are negligible. Here we sought to investigate the clinicopathological features associated with axillary recurrence.

Design: Among approximately 1000 breast cancer patients treated in our institution with negative SLND in last 5 years, 3 cases had axillary recurrence. The SLN received 1) original evaluation - each node was evaluated by 2 levels of frozen sections and 2 levels of permanent HE sections and 1 level of IHC-CK. The interval between each level was 50µm; and 2) Re-evaluation: we reviewed all original slides of frozen, permanent H&E, and IHC-CK sections. We then serially sectioned the entire remaining SLN with H&E and 2 levels of IHC-CK staining (ranging 27-150 levels per SLN). We reviewed the chart to document the treatment and follow up information of each patient.

Results: The ages of the patients were between 63-80 years. The intervals between the diagnosis of the primary tumor and the axillary recurrence were 17-20 months. All the 3 patients had infiltrating ductal carcinoma (IDC) of high nuclear grade, ranged 1-2.3 cm in size, and were ER, PR and HER2 negative. One patient with mastectomy received no radiation and chemotherapy. Two patients treated with BCT also received whole breast radiation (but axilla recurrences were outside of the radiation field). In one patient, the radiation field was suboptimal due to the presence of the pacemaker; this patient did receive chemotherapy. In the other patient, axilla did not receive radiation due to significant ptosis; this patient declined chemo therapy due to advance age. All 3 patients were on a 3 month follow up schedule. All three recurrences were detected by palpation. ALND were performed in all three cases, with metastatic tumor size ranging 1.9-4 cm and positive nodes at 6/16, 1/9, 3/16, respectively. We failed to identify any tumor cells in original frozen, H&E, IHC sections of the SLN. We also failed to identify any tumor cells in the remaining SLN after examining both the H&E and IHC-CK sections of the entire nodal tissue.

Conclusions: Axillary recurrence is a rare event. All cases in our study occurred in post-menopausal patients and received suboptimal therapy. Patients with aggressive features as such TN tumors, who are not receiving optimal treatment due to personal condition should be followed closely even in the setting of negative SLN.

266 Dichotomy Effects of Akt Signal on Breast Epithelia by Inhibiting Epithelial-Mesenchymal Transition, Motility, and Stem Cell, but Sustaining Survival

R Shen, Z Peng, W Zhou, JR Scott, JR Chao, K-Y Teng, MWY Chan, H-JL Lin. The Ohio State University, Columbus, OH; University of Arizona, Phoenix, AZ; National Chung Cheng University, Min-Hsiung, Chia-Yi, Taiwan.

Background: The oncogenic roles of Akt remain controversial, but are indicated to be modulated by an interplay and net balance between various isoforms.

Design: To decipher effects of different Akt isoforms on epithelial-mesenchymal transition (EMT), MCF10A and human mammary epithelial cells (HMECs) were transduced with constitutively active Akt isoforms via retroviruses, followed by RT-qPCR analysis for a panel of known EMT-associated transcripts. In addition, same experiments were performed in MCF10A cells undergoing EMT either by TGFβ treatment or overexpressing IGF-1R. Effect of activated Akt on cell migration was appraised by transwell migration and wound-healing assays. Likewise, effect of Akt on the formation of stem/progenitor cells was evaluated by the formation of mammospheres along with the % of ALDEFLUOR-positive cells. To determine if such effects of Akt will change with malignancy states, a series of isogenic cell lines displaying

progressively increasing metastatic features (namely MI, MII and MIII) were subjected to the aforementioned assays. Finally, effect of Akt signaling on cell death rendered by chemotherapeutic agents, was assessed by MTT assay.

Results: We demonstrated that overly activated Akt signaling resulted in inhibitory effects on EMT, cell motility and stem/progenitor cell expansion, in both nonmalignant MCF10A and HMEC cells. Importantly, this action mode is largely redundant and independent of isoform types. Interestingly enough, the aforementioned “neoplasm-unfavorable” effects can be partly rescued in epithelial cells gaining advanced malignancy. In contrast to the unfavorable oncogenic behavior, activated Akt signaling in MCF10A cells remarkably rescued cell viability loss caused by cytotoxic agents, which is regarded as tumor-promoting.

Conclusions: Despite sustaining cell survival, Akt signaling plays an inhibitory effect on EMT, motility and stem cell expansion of breast epithelia, which is partly impaired by increased malignancy.

267 Is Routine Testing for Hormone Receptors Necessary in the Clinical Management of Grade 1 Breast Carcinomas?

WA Shen, CJ Sung, C Zhang, MM Steinhoff, M Lomme, RA Simon, S Ehdavand, WD Lawrence, MR Quddus. Brown University/Women & Infants Hospital, Providence, RI; Chi Mei Hospital, Liouying, Tainan, Taiwan.

Background: Assessment of hormone receptors (HR) status (estrogen receptor [ER] and progesterone receptor [PR]) of breast cancers (BRCA) and HER2 status has been routine clinical practice and these prognostic/predictive biomarkers are considered integral to breast cancer management. It is generally believed that low grade tumors are typically HR positive and high grade tumors are more likely to be HR negative. However, the frequency of HR expression in low grade invasive BRCA and ductal carcinomas *in situ* (DCIS) has not been reported. The correlation of nuclear grade (NG) and HR status in low grade BRCA is also unknown. We investigated the frequency of HR expression in low grade BRCA and whether such HR status correlates with NG, and advanced stage, with the aim to propose the possibility of elimination of routine HR testing in this group.

Design: All invasive and *in situ* BRCA diagnosed between 2004-2008 were retrieved, and grade 1 tumors (including all histologic types) were evaluated for HR status. All invasive BRCA were graded utilizing the Nottingham histologic score and low grade DCIS was defined as having NG 1.

Results: A total of 1505 cases of BRCA were identified, of which 149 (9.9%) cases were grade 1 (136 invasive carcinomas and 13 DCIS), from patients ranging in age from 37 to 86 years (median 55 years). The invasive BRCA included: 110 (80.9%) infiltrating ductal carcinomas, 9 (6.6%) mucinous carcinomas, 9 (6.6%) invasive tubular carcinomas, 6 (4.4%) infiltrating lobular carcinomas, 1 (0.7%) infiltrating cribriform carcinoma, and 1 (0.7%) invasive micropapillary carcinoma. The mean tumor size was 1.12 cm (range: 0.1-7.2 cm; median: 1.0 cm.). All 149 (100%) low grade invasive BRCA and DCIS expressed ER regardless of lymph node status or presence of lymphovascular invasion (LVI). When invasive BRCA were stratified by NG, all 48 grade 1 and all 87 grade 2 expressed ER. Of 136 invasive BRCA, 125 (91.9%) expressed PR. PR was positive in 41 (85.4%) NG1 cases and in 83 (95.4%) NG2 cases. The one case of invasive BRCA with NG3 was positive for both ER and PR.

Conclusions: Our findings suggest that 100% of grade 1 invasive BRCA express ER and 91.9% express PR regardless of NG, histologic type, lymph node status, or LVI. Therefore, routine evaluation of HR status (particularly ER) may not be necessary in the clinical management of grade 1 BRCA. A multi-institutional study with a larger number of cases may be necessary to further validate these findings.

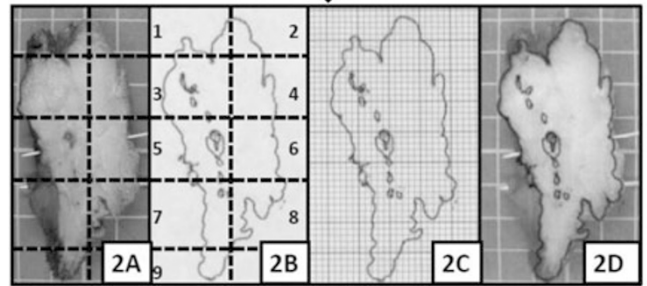
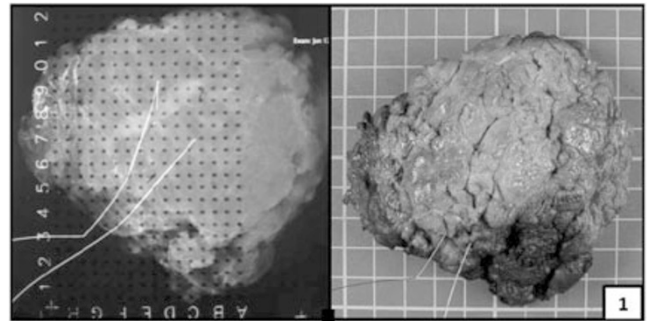
268 A Proposed Technique for Topographical Mapping of Cancer Burden in Breast Resection Specimens

N Shillingford, E Yakirevich, D Treaba, S Chen, M Mainiero, R Sams, M Chung, RA DeLellis, S Mangray. Rhode Island Hospital, Providence, RI.

Background: In the era of conservative breast surgery, cancer burden and resection margin status are key factors in the management of breast cancer patients. Yet major challenges exist in delineating and reporting the cancer burden such that the distribution of ductal carcinoma *in-situ* or invasive mammary carcinoma can easily be gleaned from the report by treating physicians. Herein, we describe a technique for topographical mapping using conventional histologic sections as an alternative to whole mount sections.

Design: On receipt of previously inked and needle localized, the specimen is oriented in the same manner as the accompanying x-ray (Fig. 1). Based on localization and/or bracketing of the tumor, the specimen is sectioned in a plane perpendicular to the closest apparent margin. Sections are done optimally at 4-6 mm intervals. After sectioning the full slices are photographed (Fig. 2A) prior to overnight fixation in formalin. Whole slices are submitted for histologic examination and a map is made on the photographed slices. Small specimens are entirely submitted while bracketed areas are entirely submitted as full slices along with alternate slices beyond those areas in larger specimens. On examination of the hematoxylin and eosin sections, tumor is mapped on individual glass slides with a marking pen. Biopsy site and calcifications are also noted. Each section is then traced onto a plastic transparency reconstructing the whole slices from the mapped sections (Fig. 2A & Fig. 2B).

Results: By this method a whole mount representation is obtained of individual slices from conventional histologic sections (Fig. 2B).



Conclusions: These images can be incorporated into pathology reports with appropriate annotation giving span of tumor and involved margins. In cases of neoadjuvant chemotherapy the percentage of residual tumor in the original tumor bed can be estimated with the use of 1 or 2 mm grids (Fig. 2C), or by digital image analysis, for assessing residual cancer burden. Transparency maps can be superimposed on the original photographs for reporting (Fig. 2D). This technique also has potential for three dimensional reconstruction as is done with CT scans or to enhance breast MRI interpretation by correlative studies.

269 Adenoid Cystic Carcinoma of the Breast – A Morphologic Study of 41 Cases

EA Slodkowska, S Sahoo, M Akram, J Catalano, D Giri. Memorial Sloan Kettering Cancer Center, New York, NY; UT Southwestern Medical Center, Dallas.

Background: ACC accounts for <1% of breast cancer and is regarded as one of the triple negative (TN) cancers with favorable behavior. Due to its rarity only few case series with a substantial number of cases have been previously reported.

Design: An IRB-approved search yielded a total of 41 cases of mammary ACC between 1980 and 2011. The histopathology of the cases was reviewed by 2 pathologists. Immunohistochemistry (IHC) for Ki-67, p53, p63, CD117, CK5/6, CK7, & C-Myb was performed on 22 cases. ER, PR & HER-2 status was available for 27 tumors.

Results: There were 39 females and 2 males. Median age was 57 (range 29-81). Median tumor size was 1.7 cm (range 0.5-6.5 cm). 9 tumors (21%) had pure basaloid morphology (BM). 60% tumors showed widely infiltrative (WI) growth & the remaining were focally infiltrative. Perineural invasion (PI) was seen in 6 cases, 3 of these had BM and 2 had local recurrence (LR). Tumor necrosis was seen in 2 cases (1 with LR & 1 with BM). The average mitotic index (MI) per 10 hpf for all tumors was 6, vs. 16 for tumors with BM; for tumors with LR and/or DM it was 10. 1/38 pt had axillary lymph node (LN) metastases. All 22 cases subjected to IHC showed at least focal staining with CD117, CK5/6, CK7 & p63. P53 staining ranged from 0-10% (mean: 4%). In 20/22 tumors C-Myb staining (nuclear) was present in 5 to 90% cells; in 2 cases only rare cells stained. C-Myb staining was typically more pronounced at the tumor periphery. For tumors with BM the average Ki-67 index was 22% (range 3-60) & for the rest it was 9% (range 1-40). 27/27 tumors with available data were TN. Follow up data were available for 38 pt (median 69 months (m), range 1-293). 4 pt (10%) had LR & 3 (7%) additional pt developed distant metastases (DM). All pt with DM had tumors with WI growth. The median size was higher at 2.8cm for the 7 pt with LR and/or DM. 2/9 (22%) pt with BM had either LR or LN metastases. None of the patients died of disease; 2 pt with lung metastases were alive with disease at 71 & 84 m.

Conclusions: Although LR occurred in 10% and DM in 7% of cases, the overall prognosis in pt with mammary ACC in this study was excellent (0 deaths due to disease). Widely infiltrative growth, size, high MI, high Ki67, BM, tumor necrosis and PI may be factors adversely affecting the outcome. Although C-Myb is expressed in over 90% of ACC cases, its diagnostic value is subject to its testing across the spectrum of breast cancer.

270 Pure Mucinous Carcinoma in Women 40 Years Old or Younger: Clinico-Pathological and Follow-Up Study

EA Slodkowska, AD Corben, J Catalano, E Brogi. Memorial Sloan Kettering Cancer Center, New York, NY.

Background: Breast carcinoma in young women is usually aggressive. Pure mucinous carcinoma (PMC) of the breast typically occurs in postmenopausal women and has indolent course. The clinical course of PMC in young women has not been investigated. Our study aims to define the clinico-pathological characteristics and behavior of PMC in women up to 40 years of age (W≤40y).

Design: We searched the 1992-2011 pathology database for carcinomas with associated mucin diagnosed in W≤40 y. Two pathologists reviewed all available slides and identified cases of PMC, defined as having 100% mucinous morphology. Carcinomas with a non-mucinous component or post neoadjuvant treatment were excluded from the study. Morphologic features, including micropapillary morphology, as well as ER and HER2 status of PMCs were recorded. Clinical and follow-up (F/U) information was retrieved from the e-medical records.

Results: We identified 24 PMCs from 21 W≤40y. Nineteen patients (pts) had one PMC, one had 2, one had 3. No pt was pregnant/nursing for at least 22 months (m) prior to diagnosis. Clinical symptoms included a palpable mass (14), nipple discharge (4), mammographic mass (2) or Ca2+ (2). DCIS was present in 19/24 (80%) cases, and was mucin producing in 18/19 (94%). All 21/21 PMCs tested were positive for ER, negative for HER2. Table 1 details morphology and clinical data.

Pure Mucinous Carcinoma (PMC): Morphology and Clinical Features

	PMC without MPF (n=5)	PMC with MPF (n=13)	PMC pure MP (n=6)	All PMC cases (n=24)
Age (median, yrs)	33	36	35	36
Size (median, cm)	1.6	0.6	2.4	1.2
NG	low 1, int 2, high 2	int 12, high 1	low 1, int 5	low 2, int 19, high 3
Mitoses/10hpf	4	1	2	2
Ca2+	0	3 (1P)	3P	6
LVI	1	1	2	4
Treatment	E1, M4, R1, C3	E3, M10, R4, C3	E2, M4, R5, C3	E6, M18, R10, C9
Patients with LN mets	1 of 5	2 of 10	1 of 6	4 of 21
Median FU (m)	25	37	69	37 (range 8-175)
Local recurrence	0	2 (20m, 52m)	3 (39m, 39m, 69m)	5
Distant metastases	0	0	1 (93m, lung; NED 7 yrs after lung surgery)	1
Patient status	5 NED	12 NED, 1 LFU	6 NED	21 NED

MPF-micropapillary features, MP-micropapillary, NG-nuclear grade, int-intermediate, P-psammomatous, E-excision, M-mastectomy, R-radiotherapy, C-chemotherapy, LFU-lost to follow up

Conclusions: To the best of our knowledge, ours is the largest series of PMC in women ≤40 years. Pure mucinous/micropapillary carcinomas constituted about a fourth of PMCs in this age group and our data suggest they might have a more aggressive course. Nonetheless, our results indicate that the clinical behaviour of PMC in young women is relatively indolent, in keeping with its known biology in other age groups.

271 Progesterone Receptor and Ki-67 Immunohistochemistry Predict Oncotype Dx® Recurrence Score in Lymph Node Negative and Positive Breast Cancers

LS Spruill, JR McEvoy. Medical University of South Carolina, Charleston, SC; Roper St. Francis Healthcare, Charleston, SC.

Background: Oncotype Dx® is a proprietary molecular assay that detects the expression level of RNA associated with behavior of invasive breast cancer. Results are reported as a Recurrence Score (RS) and stratified into low, intermediate, and high risk groups which theoretically correlate with risk of recurrence at 10 years after surgical treatment only. RS may be used by oncologists as a tool to guide initiation of chemotherapy. The ongoing prospective TAILORx trial utilizes a modification of the standard RS risk stratification values which expands the number of patients in the intermediate group.

Design: Our objective was twofold: 1) to test whether routinely performed histology and immunohistochemical studies could be used to predict the RS in a cohort of lymph node negative and lymph node positive patients, and 2) to assess the prediction of recurrence using both the standard RS and the modified TAILORx RS. H&E stained slides were used to assess morphology including the components of the Nottingham combined histologic grade. Immunohistochemistry was used to assess hormone receptor expression, Ki-67 positivity, and Her-2/neu expression.

Results: The most recent 92 cases with invasive carcinoma and Oncotype DX® results were evaluated. Of those, 69 cases were node negative and 23 were node positive. Using the standard RS, 56 cases were low risk, 26 were intermediate risk, and 10 were high risk. Using the modified TAILORx stratification, 19 cases were low risk, 57 were intermediate risk, and 16 were high risk. Bivariate analysis demonstrated that PR status, Nottingham grade, nuclear score, mitotic rate, and Ki-67% were significantly associated with RS using both the standard and modified TAILORx risk stratifications. However, multivariate logistic regression analysis demonstrated that only a positive PR status and low Ki-67% were predictive of a low RS using the standard risk stratification. None of the variables remained predictive of RS when the modified TAILORx values were applied.

Conclusions: Our study demonstrates that PR status and Ki-67% are predictive of Oncotype DX® RS values using the currently clinically applicable standard risk stratification in a cohort of lymph node negative and lymph node positive patients.

272 The Spectrum of Osteosarcomatous and Chondrosarcomatous Differentiation in Malignant Breast Lesions

CL Stephenson, JF Simpson, DL Page, ME Sanders. Vanderbilt University Medical Center, Nashville, TN.

Background: Osteosarcomatous (OSD) and chondrosarcomatous differentiation (CSD) in malignant breast lesions is rarely encountered. These heterologous sarcomatous elements have an identical histologic appearance as their extramammary counterparts. However, limited cytogenetic and molecular studies suggest that they do not share the same changes which may explain their usually less aggressive behavior in the breast.

Design: We reviewed the histopathology of malignant breast neoplasms with OSD and/or CSD received by the Vanderbilt Breast Consultation Service from July 1997 to

September 2011 to identify features useful for their correct classification. Available slides and reports were reviewed and diagnostic features were recorded. Immunohistochemical (IHC) studies had been performed on select cases.

Results: Eighty-seven cases with OSD and/or CSD were identified and had been diagnosed as follows: metaplastic carcinoma (n=51), malignant phyllodes tumor (n=17), and sarcoma only (n=19). Patients with sarcomas were slightly older (average 69 vs. 60 yrs) than patients with metaplastic carcinomas and phyllodes tumors, but there was no size difference among the 3 groups. Within the metaplastic carcinomas, 25 showed OSD, 18 had CSD and 8 were mixed. In addition, 15 metaplastic carcinomas contained no special type carcinoma components (one of which had 2 positive lymph nodes) and 6 had associated ductal carcinoma in situ (DCIS). Ten phyllodes tumors contained osteosarcoma (OS), 2 contained chondrosarcoma (CS) and 2 were mixed. One phyllodes tumor also contained a no special type carcinoma component and one had associated DCIS. There were 15 pure OS or CS, and 2 mixed sarcomas (OS with CS or fibrosarcoma). No cases of sarcoma or phyllodes tumor had involved lymph nodes. IHC studies performed on 29 metaplastic carcinomas showed expression of keratin and p63. None of the 12 pure sarcomas studied by IHC showed any cytokeratin expression.

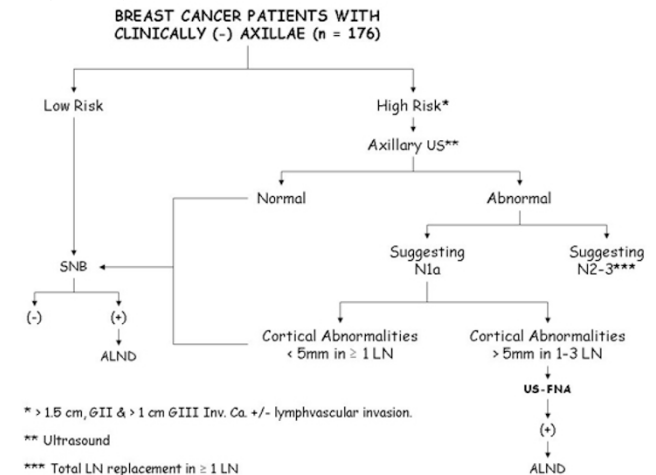
Conclusions: In the breast, OSD and CSD arise in 3 settings: a heterologous component of a metaplastic carcinoma, part of a malignant phyllodes tumor, or as pure sarcoma. IHC using antibodies to keratin and p63, as well as the presence of DCIS in adjacent ducts, assist in the recognition of metaplastic carcinoma. Phyllodes tumors with dominant sarcoma components are recognized by focal residual epithelial elements. Lymph node sampling is only useful in cases with no special type carcinoma components.

273 Preoperative Identification of N1a Disease in Clinically Node Negative Breast Cancer Patients

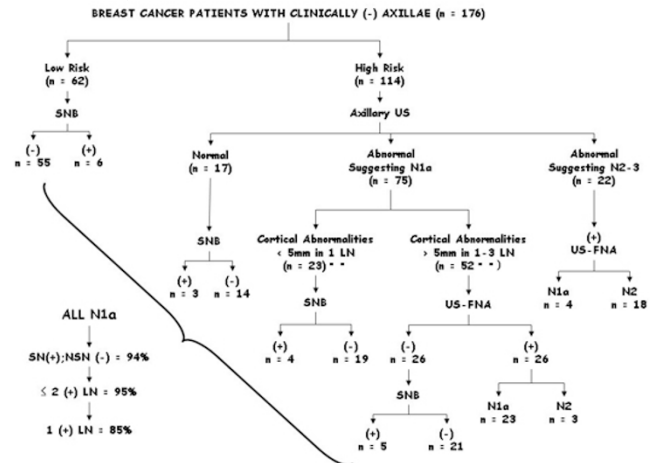
RL Stewart, PC McGrath, H Wright, AL Szabunio, EA Pirruccello, YM Brill, VV Krol, RK Patel, LM Samayoa. University of Kentucky, Lexington, KY; Lexington VA Medical Center, Lexington, KY.

Background: Between 20 to 30% of patients undergoing Sentinel Node Biopsy (SNB) will have N1a disease. Results from the ACOSOG – 0011 trial strongly suggest that when treated appropriately, axillary lymph node dissections (ALND) are probably not needed in N1a patients with 1-2 (+) Lymph Nodes (LN). This study focuses in how to select these patients preoperatively and evaluates the need for Sentinel Node (SN) Intraoperative Consults (IOC) using a combined multidisciplinary approach.

Design: See figure 1.



Results: See figure 2



Conclusions: In all likelihood, clinically node (-) patients with normal or without significant sonographic LN abnormalities (cortical defects < 5mm in ≥ 1 LN) require SNB only for their axillary staging. SN IOC may be safely bypassed in these patients

since its result are unlikely to impact the extent of their ALND. Unless the mapping fails and/or small suspicious LN (not detected by US +/- FNA) are identified at the time of surgery, IOC could be left at the surgeon's discretion alone.

274 HER2 Heterogeneity by FISH in Breast Cancers and Matched Lymph Node Metastases: A Pilot Study

CJ Suarez, SM Dintzis, RA Schmidt, KH Allison. University of Washington, Seattle.
Background: In 2009, recommendations for reporting minor populations (5-50%) of cells with HER2 amplification by fluorescence in situ hybridization (FISH) were published ("HER2 heterogeneous cases"). However, there is little data available about the significance of these minor HER2 positive populations. We examined the percentage of HER2 amplified cells by FISH in primary breast cancers and their lymph node metastases.

Design: As a pilot study, FISH for HER2 was performed on 32 cases: 16 primary breast cancers and their matched untreated lymph node metastases. The percent cells with HER2 gene amplification by both HER2:CEP17 ratio and absolute HER2 signals/cell in the primaries was compared to the percent in the LN metastasis.

Results: By the CAP recommended criteria using HER2:CEP17 ratios, 25% (4/16) of primaries and 13% (2/16) of LN metastases had HER2 heterogeneity. By the absolute HER2 signals/cell criteria, 19% (3/16) of cases had heterogeneity in the primary and 0% (0/16) in the matched LN metastases. One case had 0% amplified cells, and no heterogeneity in the primary, but demonstrated HER2 amplification in > 80% of cells in the LN metastasis.

Cases with HER2 Heterogeneity

	Heterogeneity by HER2:CEP17 Ratio Criteria		Heterogeneity by absolute HER2 signals/cell criteria	
	Primary	LN Metastasis	Primary	LN Metastasis
Overall (N=16)	25% (4)	13% (2)	19% (3)	0% (0)
Heterogeneous cases: % cells with ratio > 2.2				
1	18%	0%	16%	4%
2	22%	8%	45%	52%
3	32%	0%	20%	0
4	13%	0%		

LN = lymph node

Conclusions: Based on results of this pilot study, the percent of HER2 amplified cells by FISH can change from primary to LN metastasis. Although our data shows predominantly decreases in minor populations of amplified cells in metastatic progression, increases can also occur. We plan to expand this study to include larger numbers to determine if these trends continue.

275 Low Androgen Receptor Expression Is Associated with Distant Metastases in Patients with Androgen Receptor Expressing Triple-Negative Breast Carcinoma

L Sutton, KE Torgbe, D Cao, V Sarode, K Molberg, B Haley, Y Peng. UT Southwestern, Dallas, TX; Washington University School of Medicine, St Louis, MO.

Background: High androgen receptor (AR) expression in breast cancer has been correlated with a decreased risk of recurrence and death, and significant differences in AR expression have been identified in different subtypes of breast cancer. Triple-negative (TN) breast carcinoma, characterized by negativity of estrogen receptor, progesterone receptor, and Her2, is a group of aggressive tumors that characteristically have a low AR expression. Further characterization of AR expression in TN tumors may help elucidate prognosis and treatment options.

Design: 91 patients were identified with TN breast tumors, 87 of which were basal-like with positivity of CK5/6 and/or EGFR. Of these patients, 32 had distant metastatic disease (pM1) and 59 had local disease only (pM0). Immunohistochemical staining for AR, Ki67 and p53 was performed. The frequency and percent of intratumoral expression of AR was compared between the pM1 and pM0 groups to explore an association of AR expression with metastatic disease in TN tumors. Also, AR expression levels were correlated with Ki67 expression, p53 expression and tumor size.

Results: The frequency of AR positivity was similar between the two groups with 34.38% positive pM1 cases and 35.59% positive pM0 cases. Among AR positive cases, intratumoral expression was significantly higher in the pM0 group (57.24% ±7.74) compared to the pM1 group (29.18% ±11.69; p=0.04). The expression of AR also showed a significant negative correlation with Ki67 expression (r=-0.51, p<0.001). No correlation was found with p53 expression or tumor size.

Conclusions: Our results reveal that among AR positive TN breast tumors, distant metastases (pM1) are significantly associated with a lower intratumoral expression of AR as compared to cases with only local disease (pM0). The results suggest TN tumors with a higher expression of AR may be less likely to develop metastatic disease. High Ki67 expression has been previously associated with a worse prognosis in TN tumors. The significant negative correlation of AR expression with Ki67 provides further support that high AR levels may be associated with a better prognosis in TN tumors, which might be related to the antiproliferative effect of AR stimulation. AR expression levels may have potential prognostic value in AR expressing TN tumors. Targeting the AR pathway may be a novel therapeutic approach for the treatment of TN tumors.

276 A Detailed Histologic Analysis of Flat Epithelial Atypia Diagnosed on Core Biopsy

BJ Sutton, KP Siziopikou, ME Sullivan. Northwestern University, Chicago, IL.

Background: Flat epithelial atypia (FEA) remains a somewhat controversial diagnosis within breast pathology. The WHO established a definition in 2003, but interpretations and diagnostic thresholds vary between pathologists, and the features described in the literature are numerous and often subjective. In this study, we reviewed breast needle core biopsies (NCB) with FEA as the most significant diagnosis and scored each NCB for 15 different histologic features to determine if 1) different patterns of histologic features

become evident and if 2) any specific pattern is more associated with upgrade at excision.

Design: After IRB approval, the pathology database was reviewed for NCB diagnosed as FEA between 1/1/03 and 12/31/10. Patients with atypical ductal hyperplasia (ADH) or cancer were excluded. 85 NCB were reviewed by MS & BS blinded to the excision findings and scored on the following features: dilation of TDLU, intralobular stroma, secretions, calcifications, basophilia, nuclear shape, size & distribution, nucleoli, cytoplasm, mitoses, myoepithelial cell prominence and presence of lobular neoplasia (LN). Relevant patient and excision data was also obtained.

Results: Using Ward's Method, the FEANCB separated into 3 clusters. Nine histologic criteria were statistically significant in separating the clusters (p<0.0001, see table).

Feature	Cluster 1 (N=34)	Cluster 2 (N=16)	Cluster 3 (N=35)
	"Intermediate"	"Classic FEA"	"HP-like"
Microcyst-like dilation	16%	79%	5%
Expanded interlobular stroma	76%	1%	60%
Overlapping nuclei	4%	2%	19%
Loss of nuclear polarity	9%	19%	0%
Eosinophilic cytoplasm	26%	14%	0%
Prominent apical snouts	14%	24%	6%
Nucleoli	7%	12%	2%
Prominent myoepithelial cells	1%	0%	13%
Calcifications	38%	36%	26%

The remaining histologic features showed no significant difference between the clusters. LN was twice as common in clusters 1 and 2. Excision pathology was available for 67/85. Two patients were upgraded to grade 1 DCIS, both from cluster 2 (2/16 or 12.5%). No patients from clusters 1 or 3 had cancer in their excision. ADH was present in excisions from each cluster with 12%, 6.7% and 3.7% upgrade rates for clusters 1-3, respectively. **Conclusions:** The term FEA is used to encompass NCB findings with subtle but seemingly distinct morphologies. The "classic FEA" NCB with microcyst-like dilation of the TDLU, loss of nuclear polarity, nucleoli and cytoplasmic snouts, without expanded intralobular stroma, carried the highest risk of upgrade to cancer at excision (12.5%). FEA NCB with more hyperplastic features were less associated with LN and only had a 3.7% upgrade rate to ADH on excision.

277 Comparative Expression Profiles of E-Cadherin and Vimentin in Triple Negative and Estrogen Receptor-Positive Breast Carcinoma

MJ Swadley, C Cohen, HC Sullivan, DJ Williams, LD Taliaferro-Smith, GM Oprea, AL Adams. Emory University, Atlanta, GA.

Background: Breast cancer is increasingly recognized as a diverse disease process with a variety of molecular backgrounds which dictate prognosis, behavior, and treatment. Triple negative (TN) breast cancer is particularly notable for its poor prognosis and difficulty in treatment due in part to its lack of receptor targets. Recent in vitro studies of TN cancers demonstrate changes in histologic appearance (epithelial to mesenchymal and vice versa) upon silencing of IGF-1R, as noted via an inverse relationship between expression of E-cadherin and vimentin by immunohistochemistry (IHC). Our goal is to investigate an in vivo relationship between E-cadherin and vimentin expression in TN cancers compared to estrogen receptor-positive (ERP) breast carcinomas.

Design: Tissue microarrays of breast carcinoma from 216 patients (100 TN, 116 ERP) were retrospectively examined for expression of E-cadherin and vimentin via IHC. Stain results in the TN group were compared to those in the ERP group using a Chi-square test. Pearson correlations were used to explore relationships between TN status, patient age, tumor size, grade, lymph node (LN) status, angiolymphatic invasion (ALI), and E-cadherin and vimentin expression.

Results: TN carcinomas showed decreased expression of E-cadherin (p=.002) and increased expression of vimentin (p <.001) compared with ERP carcinomas.

Immunophenotype of Studied Groups

	TN		ERP		P value
	Positive/Total	%	Positive/Total	%	
E-cadherin	63/100	63	95/116	82	p=.002
Vimentin	79/100	79	13/116	11	p<.001

TN tumors exhibited significant correlations with increased tumor size, higher grade, LN metastasis, decreased E-cadherin and increased vimentin expression, compared to ERP tumors, but not with age or ALI. When tumor size, grade, and LN status are controlled, a significant relationship between TN status and e-cadherin negativity (r=-.226, p<.001), and vimentin positivity (r=.532, p<.001) remains. No significant correlation between E-cadherin and vimentin expression was identified within either the TN or ERP group. A weaker but significant correlation between increasing tumor grade and vimentin positivity was identified (r=.145, p=.034), independent of TN status. **Conclusions:** Controlled correlations provide evidence that TN breast carcinoma displays increased vimentin and decreased E-cadherin expression, compared to ERP cancers, independent of tumor size, grade, and LN status. These expression patterns provide further support for the unique molecular makeup of breast carcinoma subtypes. A direct in vivo relationship between E-cadherin and vimentin expression is not identified.

278 Use of Gene Expression Markers To Screen for BRCA-1 Germline Mutations in Triple Negative Breast Cancer

EA Swanson, X Li, PS Sullivan, NA Moatamed, SK Apple. University of California, Los Angeles, Los Angeles, CA.

Background: Breast tumors from women who harbor germline *BRCA1* mutations are commonly triple-negative breast cancers (TNBC). Identifying *BRCA1* germline mutations in patients with TNBC has significant clinical implications including the consideration of risk-reducing bilateral salpingo-oophorectomy and bilateral prophylactic mastectomy for the patient, as well as consideration of *BRCA1* testing for blood-relatives. The gold standard for assessment of *BRCA1* status is costly and involves full-sequencing and analysis of the gene. A faster, more cost effective screening test would be helpful in selecting a subpopulation of TNBC patients that should undergo

full-sequencing. We sought to determine whether TNBCs from BRCA-1 positive and negative patients have a unique gene expression profile with the goal of developing a PCR-based screening test for the BRCA1 germline mutation.

Design: TNBC specimens from five confirmed *BRCA1*-positive and four negative patients were obtained in formalin fixed paraffin embedded blocks. Tumor cells were dissected from the blocks using a dissection microscope. Total RNA was isolated using the Ambion Recover ALL Kit, amplified using the Nu-GEN WT-Ovation® FFPE RNA Amplification System, labeled with the FL-Ovation® cDNA Biotin Module V2, and hybridized to the Affymetrix Gene Chip® Human U133 Plus 2.0 Array. Raw data was analyzed using the Partek® Genomics Suite Version 6.4. Differentially expressed genes were selected at ≥ 1.5 fold and $p < 0.05$.

Results: 119 differentially expressed genes were identified between BRCA1-positive and BRCA1-negative tumors. Of those, 18 are cellular function and maintenance-related genes ($p = 2.69E-03$ - $4.59E-02$), 16 are cell cycle-related genes ($p = 3.02E-03$ - $4.59E-02$) and 12 are cell-cell signaling & interaction-related genes ($p = 1.45E-03$ - $4.87E-02$). The ERK/MAPK signaling pathway was significantly enriched, with MAPKSP and ATF1 over-expressed in the BRCA1-positive tumors, and RAP1A under-expressed. Both ERBB3 and SOS2 were overexpressed in the BRCA1 group, which belong to the Her2 signaling pathway in breast cancer. Using a gene signature profile, we developed a regression index which is predictive for BRCA1 positivity.

Conclusions: This study demonstrates that TNBC from *BRCA1*-positive patients have a unique gene expression profile compared with tumors from *BRCA1*-negative patients. BRCA1 positive TNBCs showed increased expression of genes involved in cell growth & proliferation. Our data demonstrate a rapid and cost-effective screening test that can identify TNBC patients with BRCA1 germline mutations.

279 Follow-Up Analysis of Benign Papillomas Diagnosed on Breast Core Needle Biopsy

RE Swapp, HM Brands, KN Jones, KN Glazebrook, TJ Hieken, DW Visscher, C Reynolds. Mayo Clinic, Rochester, MN.

Background: The aim of this study is to determine whether core biopsy (CB) proven benign papilloma with concordant imaging needs to be surgically excised.

Design: A text search of our institution's database for papillary lesions diagnosed by CB was performed between January 2003 and June 2010. Two pathologists evaluated all histologic materials without knowledge of the original diagnosis or patient outcome. The papillary lesions were designated as benign, atypical, or malignant. Any discrepant case between the initial diagnosis and second review was reviewed by a third "tiebreaker" pathologist. Three radiologists reviewed all cases for concordance. Details regarding pathologic results and follow-up imaging were recorded.

Results: Two hundred sixty papillary lesions diagnosed on CB with concordant imaging were identified. Of these, 207 (80%) were classified as benign, 40 (15%) atypical, and 13 (5%) malignant. Fifteen (7%) benign papillomas were excluded due to an associated high risk lesion adjacent to the papilloma or concurrent malignancy in the same quadrant of the breast. Fifty-four (26%) women underwent immediate excision. Surgical excision resulted in 47 (87%) benign papillomas, 1 (2%) atypical papilloma, and 4 (7%) with no residual papilloma. Two (4%) women underwent mastectomy for an invasive carcinoma in a different quadrant of the same breast and the papilloma biopsy site was not sampled. Fourteen (10%) women underwent delayed excision (8.7 to 74.4 mo., mean 26.1 mo.), 12 of which were at the prior CB site. Ten (83%) showed benign papilloma and 2 (17%) were atypical. Of the remaining 124 benign papillomas on CB, 83 were stable at last follow-up (13.6 to 93.8 mo., mean 35.8 mo.) and 41 women were lost to follow-up. Overall, in the immediate and delayed excisions, only 3 (4.5%) cases were upgraded to atypia with no malignant upgrades.

Conclusions: The likelihood of finding undetected atypia or malignancy in excision of a CB proven benign papilloma is extremely low when imaging is concordant. In our cohort, only 4.5% of benign papillomas diagnosed on CB were upgraded to atypia. These data support clinical follow up, rather than mandated surgical excision, for patients diagnosed with a benign papilloma on CB when imaging findings are concordant and in the absence of associated high-risk lesion or concurrent malignancy.

280 Immunohistochemical Expression of ID4 in Triple Negative Breast Cancer Correlates with Basal Phenotype and Poorer Disease Free Survival

PH Tan, AA Thike, MMM Thu, M Daniels, PY Cheok. Singapore General Hospital, Singapore.

Background: Triple negative (TN) breast cancers are defined by the absence of estrogen receptor (ER), progesterone receptor (PR) and c-erbB2 expression. Oncologic management options for this group of aggressive tumors are limited. ID4, inhibitor of differentiation 4, is involved in cell proliferation and growth via negative regulation of helix-loop-helix transcription factors. ID4 has been reported to be upregulated in basal-like breast cancer. In this study, we evaluate the relationship of protein expression of ID4 with the basal-like phenotype and clinical outcome of TN breast cancer.

Design: The cohort comprised 699 TN breast cancers diagnosed between 1994 to 2010, to which antibodies to basal markers (CK14, 34βE12, EGFR) and ID4 were applied to sections cut from tissue microarray blocks, using the streptavidin-biotin method. Positive ID4 was defined as staining of 1% or more of tumor cell nuclei. Follow-up was obtained from casenotes. DFS (disease free survival) and OS (overall survival) were defined as time from diagnosis to recurrence or death respectively, and correlated with protein immunohistochemical expression. A p value < 0.05 defined statistical significance.

Results: Median age was 52 years. Majority (83%) were Chinese, 8% Malay, 5% Indian, and 4% of other ethnic origins. Tumor size ranged from 0.9 to 20 cm (mean 3.6 cm, median 3 cm). Infiltrative ductal carcinoma was the commonest subtype (92%). Histologic grade 3 tumors predominated (77%). Node positivity occurred in 40%. CK14, 34βE12 and EGFR confirmed 85% to be basal-like. ID4 was expressed in 95% of cases. There was a statistically significant association of ID4 with histologic

grade ($p < 0.001$) and basal-like expression ($p < 0.001$). Mean and median follow-up was 101 and 97 months respectively. Recurrences occurred in 29% and deaths in 24% of women. DFS was significantly reduced in ID4 positive TN breast cancer ($p = 0.046$). There was no impact on OS.

Conclusions: ID4 appears to have a role in basal-like TN breast cancer, including a negative impact on DFS. Its mode of action likely involves transcription factors relating to cellular proliferation and growth. Investigating its relationship with other biological markers like p53 and BRCA which tend to disclose abnormal expression in TN breast cancer can lend additional insight into this group of challenging tumors. Its potential as another possible therapeutic target remains to be further elucidated.

281 Droplet Digital PCR™: Comparison of a Novel Method of HER2 Testing to Immunohistochemistry and Fluorescence In Situ Hybridization

SC Tanner, J Monaco, P Belgrader, J Regan, R Koehler, AS Brown. The University of Mississippi Medical Center, Jackson, MS; Bio-Rad Laboratories, Hercules, CA.

Background: Recently, laboratories have begun offering HER2 testing using conventional quantitative PCR (qPCR). Although sensitive, qPCR has limitations in distinguishing and accurately measuring small changes in template copy number. In this feasibility study, we examined detection and quantification of HER2 DNA amplification by droplet digital PCR (ddPCR), a highly precise method for absolute DNA quantitation.

Design: The surgical pathology archives at our institution were searched for 50 cases of invasive breast carcinoma that had IHC and/or FISH results, available formalin-fixed paraffin-embedded (FFPE) tissue, and at least 5 mm of invasive tumor. For each case, DNA was extracted from FFPE tissue and a PCR reaction mixture was produced. Each PCR reaction mixture was divided into an emulsion of ~20,000 1 nL mono-sized droplets. Each droplet served as an independent PCR reaction and contained either one or zero molecules of template. Droplets were thermal cycled and analyzed using an automated reader. Software counted the fraction of positive droplets for each sample, then calculated the concentration of HER2 and CEP17 genes in each sample. The copy number ratio of HER2 to CEP17 was used to determine whether the sample was positive or negative for HER2. We compared these data with HER2 status previously defined by IHC (27 cases), FISH (3 cases) and IHC and FISH (20 cases).

Results: Initial HER2 status was negative or positive with the following frequencies: IHC only 19(38%), 7(14%); FISH only 2(4%), 1(2%); combined IHC and FISH 19(38%), 2(4%). For ddPCR, results were negative in 41(82%), positive in 9(18%), showing 100% concordance with IHC and FISH results. Of the 11 cases that were equivocal by IHC, ddPCR converted HER2 status to positive in 9 and negative in 2. There was no change in HER2 status with ddPCR for patients evaluated by FISH or by both IHC and FISH.

Conclusions: ddPCR detected HER2 amplification in all cases having previous positive results while all negative cases were correctly assigned as negative (100% concordance). In eleven cases with equivocal IHC, ddPCR was able to detect presence or absence of HER2 amplification when compared to FISH. In conclusion, ddPCR is a highly precise method for measuring DNA copy number and these preliminary results demonstrate the feasibility of measuring HER2 amplification in breast carcinoma.

282 Predictive Marker (PM) Discordance between Primary and Metastatic Breast Cancer: The Role of Decalcification and Targeted Therapy

G Tozbikian, A Ziober, P Zhang. Hospital of the University of Pennsylvania, Philadelphia, PA.

Background: Discordance in PM between primary (PBC) and metastatic breast cancer (MBC) is well documented and impacts clinical management and survival. Clonal selection due to targeted therapy (TT), sample size, fixation, decalcification and low PM status are possible causes. In this study we evaluated these potential causes for PM discordance in MBC.

Design: A 3 year retrospective evaluation of MBC identified 80 patients with 88 MBC with PM available for comparison with that of the PBC. History of TT treatment, sample size (biopsy vs. excision), decalcification or not and MBC site were collected. All HR and HER2 tests were performed using DAKO PharmDx kits and pairwise comparison made between PBC and MBC. Discordance was defined by gain or loss of HR (Allred score 3-8 to 0-2) or HER2 (3+ to 0-1+), and alteration of HR defined by (6-8 to 3-5) and HER2 (3+ or 1+ to 2+).

Results: Of 80 PBC, 56% (46) were HR+, 16% (13) HER2+, and 26% (21) triple negative. MBC sites included lung (24), bone (21), liver (18), brain (8), and others (17). 13% (12) of MBC had discordance including loss of ER (10), HER2 (1) and gain of ER (1); and 24% (21) had alteration in ER (8), HER2 (12), and both (1). 17 of the bone MBC were decalcified, 24% (4) of which were discordant and 47% (8) altered. Decalcification was significantly correlated with loss or decline of ER ($P = 0.002$) but not HER2. 55 patients had hormone therapy (HRT) and 14 trastuzumab. Trastuzumab was not correlated with discordance or alteration of HER2 ($P = 0.157$). HRT was significantly correlated with loss or decline of ER ($P = 0.027$) but not when decalcified cases were excluded ($P = 0.13$). Discordance was not correlated with sample type/size ($P = 0.44$). Low ER positivity was seen in 14% of PBC and not significantly correlated with HR discordance or alteration in MBC ($P = 0.08$, $P = 0.29$).

Conclusions: 13% of MBC had discordant PM, mostly as loss of ER. Decalcification is significantly associated with discordance or decline in HR status on MBC, but not with HER2 status. HRT has a significant correlation with HR decline, but not when effect of decalcification/bone MBC were eliminated in the analysis. This finding concurs with prior studies comparing HR in decalcified and non-decalcified tissue of the same tumor and further emphasizes the adverse effect of decalcification in HR tests in MBC. Our study also showed sample size and low level PM status were not significantly correlated with discordance. The role of TT in discordant or altered HR and HER2 expression in MBC needs to be further studied in larger series.

283 Peptide Receptors as Targets for PET/SPECT Radiopharmaceuticals: A Breast Cancer Tissue Microarray Study

G Turashvili, O Goktepe, S McKinney, S Aparicio, B Guerin, F Benard. BC Cancer Research Centre, Vancouver, BC, Canada; Queen's University and Kingston General Hospital, Kingston, ON, Canada; Université de Sherbrooke, Sherbrooke, QC, Canada.

Background: Peptides are short polymers of amino acids linked by peptide bonds. Peptide receptors have been shown to be overexpressed in breast cancer, and may represent targets for imaging and therapy with radiolabeled peptides. We set out to assess the frequency of peptide receptor overexpression in breast cancer, and associations with clinical and other biomarker variables.

Design: A tissue microarray was constructed from 406 cases of breast cancer, and expression of peptide receptors (BDKRB1, GRPR, NPY1R, SSTR2) was evaluated using immunohistochemistry. Median follow-up was 6.6 years. Outcome data was available in 335 cases. Clinical covariate and biomarker associations were assessed using contingency tables, and Pearson's χ^2 or Fisher's exact test. Survival associations were assessed using Kaplan-Meier plots, logrank and Breslow tests, and Cox proportional hazards regression analysis.

Results: BDKRB1 was expressed in 221/291 (76%), GRPR in 219/292 (75%), NPY1R in 80/313 (26%), and SSTR2 in 300/302 (99.3%) cases. SSTR2 had no prognostic value and showed no association with any of the clinical or biomarker variables. Univariable survival analysis showed that BDKRB1, GRPR and NPY1R-negative cases had poorer overall and disease-specific survival than positive cases. Multivariable models consisting of peptide receptor scores and clinical variables showed suggestive evidence of independent prognostic value for peptide receptors. BDKRB1 and NPY1R were positively associated with ER and Bcl-2, negatively associated with histologic grade and EGFR, and associated with systemic therapy. BDKRB1 and GRPR were negatively associated with EZH2, a biomarker of poor prognosis. BDKRB1 was positively associated with NPY1R and GRPR and negatively associated with clinical T stage and EZH2. NPY1R was associated with HER2. GRPR was negatively associated with lymphovascular invasion, node status, tumor size, clinical and pathological T stage, and associated with histologic type of tumor and pathological N stage. All three peptide receptors were negatively associated with Ki-67 and showed higher expression in the luminal subtype of breast cancer.

Conclusions: Peptide receptors are expressed in a high proportion of breast cancer cases and some have prognostic value. This suggests that radiolabeled peptides targeting these receptors could be valuable agents for breast cancer diagnosis and therapy.

284 Marked Atypical Duct Hyperplasia Which Borders Low Grade Ductal Carcinoma In Situ on Core Biopsy Should Be Managed Conservatively

CJ VandenBussche, E Sbaity, TN Tsangaris, N Khouri, R Vang, A Tatsas, A Cimino-Mathews, P Argani. The Johns Hopkins Medical Institutions, Baltimore, MD.

Background: On breast needle core biopsy (NCB), the diagnosis of markedly atypical intraductal proliferations for which the differential diagnosis is the high end of atypical duct hyperplasia (ADH) and the low end of ductal carcinoma in situ (DCIS) can be especially difficult, due in part to lesional fragmentation and inter-observer variability. However, this distinction has significant clinical consequences. While the diagnosis of ADH usually results in no more than an excisional biopsy (EB), the diagnosis of DCIS on NCB can commit the patient to adjuvant radiation therapy (XRT) even if the resulting EB is negative, or it can even prompt an anxious patient to opt for bilateral mastectomy. We have favored a conservative approach to such cases (i.e. diagnose as marked ADH (MADH) and treat by EB); however, we know of no formal outcome studies to support this approach.

Design: We searched our computerized hospital database from the period of January 1, 1998 to January 1, 2009 for all breast NCB with the diagnosis of MADH. Patients who had a subsequent NCB showing DCIS or invasive ductal carcinoma (IDC) before EB were excluded. The resulting EB specimens were reviewed, and clinical follow up data were obtained.

Results: We diagnosed 164 patients with MADH on NCB. Among consultation cases in this group, 79% patients had been diagnosed with DCIS at the submitting institution. 82 patients underwent EB at our institution, and slightly over half (n=46, 56%) proved to have DCIS or IDC in their EB. Of these cases, 70% were managed by breast conserving therapy (BCT). However, almost half of the 82 cases (n=36, 44%) did not have DCIS or IDC on EB; of these, 15 EBs were benign, 18 showed atypical hyperplasia, 2 showed further MADH, and 1 showed lobular carcinoma in situ. Of these 36 patients, none received XRT and 23 had follow-up for at least 3 years. Only one of these patients had a "recurrence" of DCIS in the same breast, though on review this likely represented residual incompletely excised MADH.

Conclusions: Almost half the patients with MADH on NCB do not have DCIS or IDC on EB. These patients have a favorable outcome on limited follow-up without receiving XRT. Patients with MADH on NCB who prove to have DCIS or IDC on EB usually have localized disease which can be managed by BCT. While these results favor conservative approach to NCB with MADH to avoid over treatment, longer follow up is needed to determine if simple EB without XRT is adequate when no cancer is found in the EB.

285 Significance of Tumor CD24 and Stromal CD10 Expression in Triple Negative Breast Cancer

S Varghese, N Lill, C Shapiro, WJ Zhao. Ohio State University Medical Center, Columbus, OH.

Background: Triple-negative breast cancer (TNBC), a subtype of breast cancer that is negative for ER, PR, and HER2, has a poor prognosis. Although a correlation between stromal CD10 and tumor cell CD24 expression and outcome has been demonstrated among different types of breast cancer, little is known about the significance of tumor CD24 and stromal CD10 expression levels in TNBC. The aim of this study was to

evaluate tumor CD24 and stromal CD10 expression in TNBC and to examine their correlations with well known prognostic indicators of poor outcome such as tumor grade and, lymph node (LN) and distant metastasis in TNBC.

Design: A total of 130 TNBC patients (mean age of 51.5 ± 13 years; range 21-84; median 50 years) were enrolled in this study. A tissue microarray was built and the expression of biomarkers including ER, PR, HER2, CD10, CD24, p42/44 MAPK, and pStat3 was assessed by immunohistochemistry. Associations between clinicopathological variables and biomarkers were performed by MedCalc software.

Results: The histopathological and clinical correlation studies demonstrated that LN involvement (P=0.001, HR=3.309, .95 CI: 1.735-6.313) and distant metastasis (P<0.0001; HR=5.592, .95 CI: 1.871-16.715) were independent prognostic factors for reduced survival in TNBC patients. CD24 was detected in 69% and stromal expression of CD10 in 39% of TNBC. The over expression of tumor CD24 was frequently seen in patients negative for LN or distant metastasis (P<0.001). In contrast, over expression of stromal CD10 correlated positively with distant metastasis (P=0.04) and less strongly with LN involvement (P=0.08). No correlation was observed between clinicopathologic parameters and tumor p42/44 MAPK or pStat3 expression.

Conclusions: In this study, we confirmed that local LN and remote metastasis were robust prognostic indicators of poor outcome in TNBC. The absence of CD24 expression in tumors was associated with local lymph node and remote metastasis (P<0.001). In contrast, stromal CD10 expression was associated directly with remote metastasis (P=0.04) but less significantly with positive lymph nodes (P=0.08). These findings suggest that the absence of tumor expression of CD24 and stromal expression of CD10 might be surrogate markers for lymph node involvement and distant metastasis in TNBC. If the results are confirmed in larger studies, CD24 and CD10 expression could be used as prognostic biomarkers.

286 Tissue Microarrays as a Validation Methodology for Quality Control of HER2 Analysis by Fluorescence In Situ Hybridization

LE Vasquez, D Canon, Y Abello, N Ospina, A Plata, MM Torres, RE Andrade. Hospital Universitario Fundación Santa Fe de Bogotá, Bogotá, Colombia; Universidad de los Andes, Bogotá, Colombia.

Background: HER2 amplification and overexpression are predictive for prognosis and treatment response to specific therapies in breast cancer patients. It is mandatory to provide accurate results, avoiding false negative and positive. Frequently, differences on results interpretations are related to tissue sample handling and the analytical interpretation. Technical validation methods and quality control of these tests are mandatory, but they represent an additional cost that precludes their implementation in routine laboratories. The objective of this project was to evaluate the usefulness of tissue microarrays (TMAs) as a cost-effective technique for the validation of routinely molecular studies performed on HER2 in patients with breast cancer.

Design: Tissues from 326 cases were organized into 5 TMAs. Each TMA was analyzed for the amplification of the oncogene HER2 by FISH, considered the gold standard technique. The concordance between the results reported for HER2 by FISH in each of the patients and the results obtained in the TMA was statistically calculated by the Kappa analysis.

Results: The agreement was 95.4% with a Kappa value of 0.84 (almost perfect) for both the positive and negative results. The agreement between two observers was 96.5% with a Kappa value of 0.88.

Conclusions: The TMA is a useful and cost effective technology that allows reliably analyze up to 100 consecutive cases in a single mounting, and it can be implemented as a method of quality control and validation in peripheral laboratories, especially for the screening of the HER2 gene status.

287 High Concordance between HercepTest IHC and HER2 FISH: An Analysis of Two Companion Diagnostic Tests before and after Implementation of ASCO/CAP 2007 Guidelines

ME Vergara-Lluri, NA Moatamed, SK Apple. David Geffen UCLA Medical Center, Los Angeles, CA.

Background: Human epidermal growth factor receptor 2 (HER2) is a critical predictive marker in patients with invasive breast cancer who can benefit from treatment with trastuzumab. It is thus imperative to ensure accuracy and precision in HER2 testing. In 2007, The American Society of Clinical Oncology/College of American Pathologists ASCO/CAP guidelines proposed new recommendations for HER2 testing for IHC and FISH scoring in an effort to improve accuracy and utility of these companion diagnostic tests as a predictive marker for patients with invasive breast cancer. The goal of the new guidelines was to improve the concordance rate between the diagnostic tests for HER2 and decrease the number of inconclusive cases.

Design: Both IHC and HER2 FISH were performed on all specimens from our facility from years 2003 through 2011 (n=1447). Cases from 2003 to 2007 (n=958) were scored by FDA guidelines prior to publication of ASCO/CAP guidelines, with IHC 3+ cases staining >10% of tumor cells and FISH amplification cutoff value of 2.0. The new ASCO/CAP guidelines were implemented and scored accordingly for cases from 2008 to 2011 (n=489), with IHC 3+ cases staining >30% of tumor cells and FISH amplification cutoff value of 2.2. We compared the concordance rates before and after ASCO/CAP guidelines to see if ASCO/CAP guidelines yielded improvement in concordance rate between IHC and FISH.

HER2 Immunohistochemical Status vs HER2 Gene Status by FISH				
2003-2007		2008-2011		
IHC	FISH -	FISH +	FISH -	FISH +
0	299	2	134	3
1	403	18	256	8
2	71	47	37	13
3	0	118	2	36
Total	773	185	429	60

Results: For the 2003-2007 study population, the concordance between the IHC and FISH HER2 assays was 93.3% with a kappa coefficient of 0.79. When the equivocal IHC 2+ cases were excluded from the analysis (n=118; 12% of cases), the agreement increased to 97.6% with a kappa coefficient of 0.91. For the 2008-2011 study population, the concordance between the two assays was 94.7% with a kappa coefficient of 0.71. When the equivocal immunohistochemical 2+ cases were excluded from the analysis (n=50; 10% of cases), the agreement increased to 97.0% with a kappa coefficient of 0.83. Comparison of kappa coefficients between cases scored in 2003-2007 versus 2008-2011, $k=0.91$ vs $k=0.83$, did not show a significant difference.

Conclusions: In our study, implementation of the new ASCO/CAP HER2 scoring guidelines did not show a significant difference in concordance rates and did not decrease the number of inconclusive cases in specimens.

288 Resolving Equivocal HER2 Status in Breast Cancer by Automated and Quantitative RNA Chromogenic *In Situ* Hybridization (CISH)

Z Wang, S Bui, H Wang, N Su, X-J Ma, Y Luo, RR Tubbs. Cleveland Clinic, Cleveland, OH; Advanced Cell Diagnostics, Hayward, CA.

Background: Fluorescence *in situ* hybridization (FISH) for *HER2* gene amplification and immunohistochemistry (IHC) for *HER2* protein overexpression both can generate "equivocal" *HER2* results (FISH *HER2*/CEP17 ratio 1.8-2.2 or IHC score 2+), and some cases generate equivocal results by both methods. This study explores the potential of a novel automated and quantitative *HER2* mRNA CISH assay based on the recently developed RNAscope technology for resolving equivocal *HER2* status.

Design: Formalin-fixed, paraffin-embedded (FFPE) breast cancer specimens from a non-consecutive series of 73 cases were analyzed for *HER2* mRNA using a fully automated RNAscope CISH assay. There were 30 negative and 22 positive cases based on the combined FISH and IHC results, and 21 cases were equivocal by both methods ("dual equivocal"). These cases were pre-allocated into a training set (n=38) and a validation set (n=35). Automated image analysis of *HER2* mRNA staining was used to count the number of punctate "dots" per cell, each dot corresponding to a single *HER2* RNA transcript, and correlated to *HER2* FISH, IHC and *HER2* mRNA RT-PCR. A probabilistic linear discriminant analysis model for *HER2* status based on the training set was built and applied to the validation set.

Results: Evaluable *HER2* mRNA CISH results were obtained for 67 cases (92%). *HER2* mRNA dots per cell correlated strongly to FISH (Spearman $r=0.81$) and RT-PCR ($r=0.86$) and definitively separated *HER2* positive and negative cases in the training set. A predictive model based on *HER2* mRNA dots/cell in the training set correctly identified 11/12 negative and 5/5 positive cases (concordance=94%) in the validation set. The only discrepant case was reviewed and found to have both amplified ductal carcinoma in situ (DCIS) and Non-amplified invasive components; the *HER2* RNA CISH results were from the DCIS. When analyzed on the invasive component only, this case was correctly classified as *HER2* negative. The model classified all 16 double equivocal cases in the validation set into positives (n=2) and negatives (n=14).

Conclusions: This quantitative *HER2* mRNA CISH assay was highly accurate in assessing *HER2* status and may provide an effective means to resolve FISH/IHC dual equivocal cases. The walk-away automation and image analysis-based quantification should minimize both analytical and post-analytical variability in *HER2* testing. Quantification of single RNA transcripts *in situ* in routine clinical specimens demonstrates great potential in predictive biomarker analysis.

289 Clinical Implications of Diagnosing Intraductal Papillary Lesions of the Breast by General Pathologists vs. Specialists in Breast Pathology

J Warrick, S Holley, C Appleton, B Monsees, DC Allred. Washington University, St. Louis, MO.

Background: There is considerable debate on the need for specialists in breast pathology. This study compared the accuracy and clinical implications of diagnosing intraductal papillary lesions on core needle biopsies (CNB) - a particularly challenging setting - between experienced general surgical pathologists (GPs) and a specialist in breast pathology. It also set out to determine the impact of providing specialized training to GPs.

Design: A breast specialist reviewed (blinded) a recent consecutive series (n=135) of intraductal papillomas (IDPs) diagnosed on CNBs by a group of GPs, as well as all follow-up excisional biopsies (FU EXBs; 78 cases = 59% of total). Diagnoses on CNBs by GPs included IDP (97%) and atypical IDP (3%). The primary study endpoints were concordance of diagnoses between GPs versus the specialist, and accuracy of CNB diagnoses made by GPs and the specialist for predicting EXB diagnosis (assuming the specialist's EXB diagnosis was correct).

Results: Diagnoses were concordant between GPs and the specialist in 87% of CNBs and 87% of EXBs. Relative to the specialist, GPs made 11% false-negative diagnoses on CNBs (IDP to DCIS), 3% false-negative diagnoses on EXBs (IDP to DCIS), and 10% false-positive diagnoses on EXBs (ADH/DCIS to IDP). The accuracy of CNB for predicting EXB diagnosis was 88% for GPs and 96% for the specialist (one IDP upgraded to DCIS on EXB). One GP (senior resident) who originally reviewed all cases with the specialist, is in the process of re-reviewing them alone in a blinded manner, and the impact of this training exercise is being evaluated.

Conclusions: Previous studies suggest that 10-15% of IDPs diagnosed on CNBs by general pathologists are up-graded to cancer (primarily DCIS) on FU EXBs (Cancer (2009)15:2837; Eur J Surg Oncol (2008)34:1304), which is upheld in this study. This study also shows that errors (primarily false-positives) of similar magnitude are being made by generalists on FU EXBs. All of these errors could lead to highly unfavorable clinical outcomes. Relying on specialists in breast pathology would largely eliminate these dangers, as well as dramatically reduce the need for FU EXBs. Giving GPs specialized training in the evaluation of papillary breast lesions could also potentially accomplish this goal.

290 Molecular Difference between the Components of the Ductal Carcinoma In Situ and the Invasive Ductal Carcinoma (IDC), and between the Components of the IDC and the Metastasis of the Same Breast Cancer Patients

B Wei, J Wang, J Da, H Chen, DG Hicks, P Tang. University of Rochester Medical Center, Rochester, NY; RTI Health Solution, Research Triangle Park, NC.

Background: The key molecules involving in the progression of breast cancer from ductal carcinoma in situ (DCIS) to invasive ductal carcinoma (IDC) and from IDC to metastasis are still large unknown. Here we sought to investigate the molecular difference by immunohistochemical (IHC) analysis of a panel of biomarker expression on each component for DCIS, IDC, and metastasis of the same tumor.

Design: We identified 380 infiltrating ductal carcinomas between 1997 and 2008 from our departmental file; among them, 212 cases had co-existing DCIS, and 54 cases had co-existing lymph node (LN) metastasis. Tissue microarrays (TMAs) were constructed for each components of IDC, DCIS and LN metastasis from each case. IHC analyses were performed for ER, PR, *HER2*, Ki-67, EGFR, CK5/6, C35, IMP3, AR and p53. ER, PR and AR were recorded as Allred scores (3 and greater as positive); *HER2* was scored as CAP 2007 guidelines (>30% of tumor cells with 3+ membrane staining as positive); Ki-67 was scored as positive with >15% of nuclear staining; EGFR was designated as positive if any tumor cells showed 1+ positive stain; a strong cytoplasmic stain was considered as positive for CK5/6, C35 and IMP3; and >10% strong cytoplasmic stain was considered as positive for p53.

Results: Among the cases we were able to obtain IHC data for above molecules; we compared the IHC expression patterns between the DCIS and IDC components of the same case, and the IHC expression patterns between the IDC and LN metastatic components of the same case. We found 1) there were significant difference of expression levels for EGFR ($P=0.0278$), CK5/6 ($P<0.0001$), IMP3 ($P=0.0186$), AR ($P=0.0348$), and p53 ($P<0.0001$) between the DCIS and IDC components of the same tumor; 2) there was no significant difference on expression of above biomarkers between their IDC and LN metastatic components with an exception of C35 ($P=0.0067$).

Conclusions: During the progression of breast cancer, the accumulation of molecular alteration mostly occurs in the step from DCIS to IDC, but not in step from IDC and nodal metastasis.

291 "Incidental" Intraductal Papillomas: Is Excision Necessary?

PS Weisman, BJ Sutton, KP Sziopikou, J Franz, SM Rohan, ME Sullivan. Northwestern University, Chicago, IL.

Background: Intraductal papillomas (IDP) have classically become clinically apparent either due to patient symptoms or through discovery of a mass on imaging. Once diagnosed on needle core biopsy (NCB), excision is the standard of care due to the known association with higher grade lesions including cancer. However, as imaging has improved, asymptomatic IDPs that are not mass associated are being diagnosed: the "incidental" IDP. In this context, the appropriate next clinical step is unclear. In this study we retrospectively review all NCB with IDP over a 5 year period and correlate with imaging findings to determine the risk of upgrade for incidental IDPs.

Design: After IRB approval, the pathology database was reviewed for NCB with a diagnosis of IDP between 1/03 and 12/07. All available NCB slides were reviewed blinded to the specific original diagnosis (DX). Cases in which the reviewed DX conflicted with the original DX were re-reviewed by a second pathologist to establish consensus. Imaging was reviewed and mass associated IDPs were excluded. Incidental IDPs were categorized as either microscopic (MicIDP - in a single core) or multiple (MultiIDP - fragmented or in multiple cores). Atypia in the NCB was noted. Excision pathology was recorded; for this study an upgrade is defined as a patient who had no known ipsilateral cancer pre-excision & whose final pathology showed ductal carcinoma in situ (DCIS) or invasive carcinoma.

Results: Out of 12353 NCB performed in the date range, 224 were IDP (2%). Slides from 207 were available for review, 45 of which were not associated with a mass on imaging and were included in the study. 89% were stereotactic NCB targeting calcifications and 11% were MRI NCB targeting non mass like enhancement. The maximum microscopic size in a single core ranged from <0.1-0.4 cm for MicIDP and from 0.2-0.9cm for MultiIDP. Excision pathology was available in 24/45 (53%). The only upgrades were associated with cores showing atypia (2/5; 40%). No incidental IDPs without atypia on NCB were upgraded at excision (0/14). In the 21 patients with incidental IDPs that did not undergo excision, 1 went on to develop ipsilateral grade 1 DCIS (average FU = 55 mo; range 29-89).

Conclusions: Surgical excision is necessary when atypia is associated with an incidental IDP, as there is a significant risk of upgrade. However, incidental IDPs without atypia showed no upgrades at excision regardless of microscopic size. Of the non-excised IDPs, only 1 patient developed subsequent DCIS (interval=22 mo). With careful pathology-radiology correlation, incidental IDPs without atypia likely do not require surgical excision.

292 DNA Mismatch Repair Deficiency in Breast Carcinoma: A Pilot Study on Frequency and Clinicopathological Characteristics in Triple Negative and Non-Triple Negative Tumors

YH Wen, E Brogi, M Akram, Z Zeng, J Catalano, P Patsy, L Norton, J Shia. Memorial Sloan-Kettering Cancer Center, New York, NY.

Background: DNA mismatch repair (MMR) deficiency has been described in breast cancer; however, data are limited and the characteristics of such tumors are not defined. Triple negative breast carcinomas (TNBCs) often show solid growth and prominent lymphocytic infiltrate, which are morphologic features commonly seen in

MMR-deficient tumors. The aim of this pilot study was to analyze the frequency and clinicopathological characteristics of MMR deficiency in breast cancer, utilizing case series of both TNBCs and non-TNBCs.

Design: Study cases consisted of 227 TNBCs and 90 non-TNBCs. Tissue microarrays (TMAs) were utilized. MMR deficiency was evaluated by immunohistochemistry (IHC) for MLH1, PMS2, MSH2, and MSH6. Tumors with positive reactivity on the TMAs were classified as "normal stain"; any negative or equivocal stain on the TMAs was repeated on whole tissue sections and the latter results were used for final analysis. "Abnormal stain" was defined as no nuclear reactivity in a carcinoma evaluated on whole sections. All tumors with abnormal stain and available tissue were further evaluated for microsatellite instability (MSI) by PCR using a 3-marker panel (BAT-26, BAT-25, D2S123).

Results: All 90 non-TNBCs showed "normal stain" for all 4 antibodies tested. Of the 227 TNBCs, 3 (cases 1-3, Table 1) showed loss of both MLH1 and PMS2, whereas 1 case (case 4, Table 1) showed loss of both MSH2 and MSH6. Cases 1-3 had tissue for MSI testing. Case 1 showed instable BAT-26 and case 3 showed instability on all 3 markers. All 4 tumors were invasive ductal carcinoma, with histologic and nuclear grade 3/3. None of the 4 patients met the Amsterdam criteria for Lynch syndrome clinically. Table 1 summarizes additional tumor and patient characteristics, and clinical followup information.

Table 1.

	Case 1	Case 2	Case 3	Case 4
Age, year	59	65	51	56
Size, cm	1.2	2.3	4	28
Mitoses/10 hpf	8	69	30	83
Tumor lymphocytic infiltrate	Moderate	Minimal	Extensive	Minimal
Nodal stage	N0	N1	N1	N2
Followup (F/U), month	82	48	65	21
Distant metastasis (time after diagnosis)	None	Lung (34 months)	None	None
Status as last F/U	NED	DOD	NED	DOD

NED: no evidence of disease; DOD: died of disease

Conclusions: Our results document MMR-deficiency in 4 (1.8%) of 227 TNBCs, in contrast to none of 90 non-TNBCs. The biologic significance of MMR-deficiency in TNBC awaits further investigation.

293 Overexpression of EGFR and c-MET in Triple Negative Breast Cancer Is Associated with Poor Prognosis

AK Witkiewicz, RL Lipinski, C Solomides, S Peiper. Thomas Jefferson University, Philadelphia, PA.

Background: Triple negative breast cancer (TNBC) accounts for 10-20% of all breast cancers and is one of the subtypes associated with a poor prognosis. Epidermal growth factor receptor (EGFR), a tyrosine kinase receptor that plays a role in cell proliferation and migration, is expressed in 40-60% of TNBC. C-MET is a proto-oncogene that is associated with tumor growth and metastasis and has been shown to correlate with EGFR expression in breast cancer cell lines. Recently it has been postulated that c-MET may play a key role in the resistance to EGFR tyrosine kinase inhibitors. The goal of this study was to analyze the expression and prognostic significance of EGFR and c-MET in patients with TNBC.

Design: Tissue microarrays with 186 triple negative breast cancers were used in the study. EGFR and c-MET expression was evaluated by immunohistochemistry. EGFR and c-MET were scored as 0 (no staining seen, or staining in <10% of tumor cells), 1+ (weak and incomplete staining in >10% of tumor cells), 2+ (weak to moderate complete membrane staining seen in >10%), or 3+ (moderate to strong complete membrane staining in >10%). Positive score was defined as 2+ or 3+. Overall survival was assessed using Kaplan-Meier analysis.

Results: Staining for both markers could be evaluated for 169 cases. Of these samples, 80 (47%) were negative and 89 (53%) positive for EGFR. 127 (75%) samples were c-MET negative and 42 (25%) were c-MET positive. When analyzed in combination, 27 (16%) samples were EGFR+c-MET+, 65 (39%) EGFR- c-MET-, 62 (37%) EGFR+ c-MET-, and 15 (8%) were EGFR- c-MET+. Combined expression of EGFR and c-MET was associated with a decreased survival (p=.0162).

Conclusions: Combined EGFR and c-MET overexpression is associated with decreased survival time in triple negative breast cancer patients.

294 Number of Positive Sentinel Nodes after Pre-Screening with Axillary Ultrasound Is Predictive of Overall Axillary Tumor Burden in Breast Carcinoma

RJ Wolsky, CB Bills, H Sattar. University of Chicago, Chicago, IL.

Background: Axillary lymph node status is the most useful prognostic factor in patients with breast cancer. The current standard of care for screening the axilla is sentinel lymph node biopsy (SLNB). More recently, axillary ultrasound (AUS) with biopsy has become an important pre-screening modality. This study aims to determine the relationship of the number of positive sentinel nodes with final nodal stage in patients who have been pre-screened with AUS. Such information is useful as recent studies suggest complete axillary lymph node dissection does not confer added survival benefit over SLNB alone in patients with limited axillary disease.

Design: Surgical pathology reports and slides were reviewed from 461 consecutive breast cancer patients (University of Chicago Archive, 2004-2008) who had undergone pre-screening with axillary ultrasound. Of these, 348 cases that were deemed node-negative then underwent SLNB to confirm the AUS findings. 67 cases (19.3%) proved to be false negative, revealing metastatic carcinoma on sentinel lymph node biopsy. These cases were further reviewed to determine whether the number of positive sentinel nodes was predictive of final number of nodes involved.

Results: Of the 67 cases with a negative axillary ultrasound in which SLNB revealed metastatic carcinoma, an average of 3 sentinel nodes were removed (range 1-6). The relationship of the number of positive sentinel nodes to the final number of positive nodes is shown in Table 1.

Table 1: Relationship of Final Nodal Status to Number of Positive Sentinel Nodes

Number of Positive Sentinel Nodes	Average Total Number of Positive Nodes
1 (n=45)	1.67
2 (n=16)	4.94
3 or more (n=5)	11.2

Conclusions: After pre-screening with AUS, the number of positive sentinel nodes is predictive of the final number of positive axillary nodes (p < 0.0001) with fewer positive sentinel nodes corresponding to lower axillary tumor burden overall. Recent studies suggest that axillary lymph node dissection (ALND) does not offer a survival advantage in patients with limited axillary disease who are treated with breast-conserving surgery, whole-breast irradiation, and adjuvant systemic therapy. The use of a pre-screening modality such as AUS in combination with SLNB may be useful in identifying patients for whom ALND is not beneficial.

295 Efficacy of Axillary Ultrasound Pre-Screening in Relation to Pathologic Parameters of Breast Carcinoma

RJ Wolsky, CB Bills, H Sattar. University of Chicago, Chicago, IL.

Background: Axillary lymph node status is the most useful prognostic factor in patients with breast cancer. The current standard of care for screening the axilla is sentinel lymph node biopsy (SLNB). More recently, axillary ultrasound (AUS) with biopsy has become an important pre-screening modality. The purpose of this study is to correlate pathologic features of breast cancer with successful or unsuccessful AUS.

Design: Surgical pathology reports and slides were reviewed from 461 consecutive breast cancer patients (University of Chicago Archive, 2004-2008) who had undergone pre-screening with AUS. These cases were categorized into true positive, false positive, true negative, and false negative based on final nodal status as determined by subsequent SLNB. The cases were then further reviewed to identify pathologic characteristics that were predictive of true negative, false negative, and true positive status.

Results: Both the number of cases in each category along with the relationship to the pathologic parameters is present in Table 1.

Table 1: Relationship of Success of Axillary Ultrasound Pre-Screening to Pathologic Parameters

	True neg (n=282)	False neg (n=67)	True pos (n=57)	p value
Average Tumor size (cm)	1.64	2.55	3.56	<0.0001
Number of multifocal cases	45 (16%)	17 (25%)	17 (30%)	<0.05
Average number of positive lymph nodes	NA	3.15	5.82	<0.01
Average size of largest tumor in lymph node (cm)	NA	0.64	1.65	<0.0001

Conclusions: This study provides insight into the pathologic parameters that influence the efficacy of AUS. When features that are classically predictive of nodal involvement by breast carcinoma such as larger tumor size and multifocality are present, there is an increased likelihood of false negative AUS pre-screening over true negative. When present these features should increase the concern for nodal disease, despite negative AUS pre-screening. Furthermore, increased breast tumor size and greater nodal involvement (both by number and largest tumor deposit) are associated with a higher likelihood of true positive AUS pre-screening over false negative. Recent studies suggest that ALND in T1-T2 stage breast cancer does not improve survival in patients with limited nodal disease who are treated with breast-conserving surgery, whole-breast irradiation, and adjuvant systemic therapy. As more importance is, therefore, placed on SLNB and other newer screening techniques for metastatic disease, a better understanding of AUS in relation to pathologic parameters is critical.

296 Frequent PIK3CA Mutations in Radial Scars

K Wolters, D Ang, A Warrick, C Beadling, C Corless, M Troxell. Oregon Health & Science University, Portland, OR.

Background: Radial scars are breast lesions of uncertain pathogenesis that are associated with a two-fold increased risk of breast cancer compared to controls. Activating point mutations in *PIK3CA* are found in 25-30% of invasive breast cancers; however, they have not previously been investigated in most non-carcinomatous lesions. We sought to evaluate radial scars for known activating point mutations commonly seen in invasive breast cancer.

Design: Sixteen surgical cases containing 24 distinct lesions were identified from pathology archives (2002-2010). Radial scars were intimately associated with a spectrum of epithelial morphology; 18 had non-atypical hyperplasia or columnar cell change, five had atypical ductal hyperplasia (ADH) or ductal carcinoma in situ (DCIS), and one had invasive ductal carcinoma (IDC). We also tested metastatic IDC in a lymph node in a patient with an unknown primary who had three discrete radial scars associated with non-atypical epithelium. Lesional tissue was macro-dissected from unstained paraffin sections; genomic DNA was then extracted and screened for a panel of known hotspot mutations using PCR and mass-spectroscopy analysis. The mutation panel covers 643 mutations in 53 genes, including *AKT1/2/3*, *BRAF*, *CDK4*, *CTNBB1*, *EGFR*, *ERBB2*, *FBX4*, *FBXW7*, *FGFR1/2/3/4*, *GNAQ*, *HRAS*, *KIT*, *KRAS*, *MAP2K1/2/7*, *MET*, *NRAS*, *PDGFR*, *PIK3CA*, *RET*, *SOS1*, and *TP53*.

Results: Of the 24 lesions, 12 (50%) had *PIK3CA* mutations (11 with exon 20 H1047 mutations and one with an exon 9 E545K mutation). The remaining 12 lesions were wild-type for all of the screened genes. Of the radial scars without epithelial atypia, 9/18 (50%) had *PIK3CA* mutations; furthermore, 3/5 (60%) of radial scars with atypia had mutations detected. The IDC within a radial scar was wild-type. Interestingly, in the patient with three non-atypical radial scars and a positive lymph node, two of the

radial scars as well as the metastatic IDC exhibited the *PIK3CA* exon 20 H1047R mutation whereas the third radial scar was wild-type. No other mutations were found with the extensive screening panel.

Conclusions: In this study, 50% of radial scars showed mutations in *PIK3CA*, which is notably higher than the 25-30% mutation frequency of invasive breast cancer. This finding raises interesting questions as to the role of *PIK3CA* mutations in breast cancer development. Additional larger studies are indicated to confirm and extend these observations in understanding the pathogenesis of radial scars and their relationship to breast cancer.

297 How Many Tumor Cells in the Intraoperative Imprint Cytology of Sentinel Lymph Nodes Are Enough To Diagnose Metastatic Breast Carcinomas?

M-L Wu, S-C Yang, W-C Hsieh, H-T Wang, M-H Huang, S-L Ciou, A-Y Chuang. Koo Foundation Sun Yat-Sen Cancer Center, Taipei, Taiwan.

Background: Intraoperative imprint cytology examination (ICE) of sentinel lymph nodes (SLNs) is widely used in detecting metastatic breast carcinomas. Occasionally, few cases with tumor cells detected in the ICE have no or ≤ 0.2 mm isolated tumor cells on the H&E and/or IHC sections, which will be classified as no LN metastasis in the AJCC staging system.

Design: From 2007 to 2010, all ICE signed out as atypical cells, suspicious of malignancy or metastatic carcinomas were reviewed. On review, cases with crushed lymphocytes, histiocytes, and/or endothelium which were originally misdiagnosed as atypical cells were excluded. The numbers of the tumor clusters/single cells and the size of the largest tumor cluster were recorded. The aim of this study was to evaluate how many tumor cells in the ICE having >0.2 mm metastatic carcinomas on the permanent sections. To avoid false positive, 100% specificity is the goal.

Results: Three hundred and nine SLNs from 253 patients (IDC: 218, ILC: 10, mixed invasive ductal and lobular carcinomas: 16, tubular carcinoma: 1, invasive papillary carcinoma: 3, metaplastic carcinoma: 2, DCIS: 2, DCIS with microinvasion: 4) had tumor cells in the ICE. There were 217 SLNs having ≥ 30 tumor clusters/single cells. The numbers of tumor clusters/single cells in remaining 92 SLNs ranged from 1 to 28 (mean 9.4, median 7.5). The size of the largest tumor cluster in each SLN ranged from 0.02mm to 8mm (mean 0.75, median 0.4).

Among 22 SLNs with no or ≤ 0.2 mm isolated tumor cells on the H&E and/or IHC sections, the highest number of tumor clusters/single cells is 15 (range 1-15), and the size of largest tumor cluster is 0.28mm (range 0.03-0.28). Using the number of tumor clusters/single cells > 15 could achieve a sensitivity of 83.6% in predicting metastasis (specificity 100%). If using tumor cluster size ≥ 0.3 mm as an add-on criteria, we can increase the sensitivity to 84.7%.

Using the number of tumor clusters/single cells >10 could achieve a sensitivity of 86.8% in predicting metastasis (specificity 95.5%). If using tumor cluster size ≥ 0.3 mm as an add-on criteria, we can increase the sensitivity to 87.1%.

Conclusions: To predict metastasis in breast cancer patients using intraoperative imprint cytology of sentinel lymph nodes, the sensitivity is 83.6% when number of tumor clusters/single cells is >15 . Combining the size of the largest tumor cluster does not significantly increase the sensitivity of prediction metastasis.

298 Evaluation of Mesothelin and c-Met Expression in Triple Negative Breast Carcinomas Reveals Mesothelin as an Ideal, and Novel, Therapeutic Target

R Xian, J Tchou, A Ziober, R Vonderheide, B Selvan, C June, P J Zhang. Hospital of the University of Pennsylvania, Philadelphia, PA.

Background: Women with triple negative breast cancer (TNBC) derive no benefit from molecularly targeted treatments such as endocrine therapy or trastuzumab, thus a search for novel cell surface markers as potential therapeutic targets is highly desirable in TNBC. c-Met encodes for the tyrosine kinase receptor for hepatocyte growth factor (HGF). Over-expression/hyperactivation of c-MET/HGF occurs in various cancers. Small molecules and monoclonal antibodies against MET are now available for targeting MET-positive cancers. Mesothelin is a cell surface glycoprotein highly expressed in mesothelial cells and numerous malignancies. Mesothelin-specific antibodies and anti-mesothelin immunotoxins have been used to treat mesothelin-expressing carcinomas. Although c-MET expression has been reported in 25-60% of breast cancers (BRCA), mesothelin is generally considered not expressed by BRCA. Specifically, expression of these markers has not been extensively evaluated in TNBC.

Design: Expression of c-Met and mesothelin were evaluated in 98 BRCA (43 TNBC, 25 ER+/HER2- and 30 HER2+) by immunohistochemical (IHC) staining on formalin fixed paraffin sections. Anti-mesothelin (5B2, NeoMarker, 1:20) and anti-c-Met (S-10, R&D, 1:100) antibodies were used with standard IHC methods. Positive staining was scored as a product of staining extent (%) and intensity (1+, 2+, 3+) with a maximal score of 300. A score of 5 or greater was considered positive.

Results: Mesothelin is expressed in 67% of TNBCs (mean score of 59, range 5-225) as compared to 0% of ER+/HER2- cases, 3% (one case, score 200) of HER2+ cases and 0% of normal breast tissue. 42% of TNBCs showed staining scores of at least 25. Expression of c-Met in TNBCs and ER+/HER2- carcinomas was similar (67% vs 60%), with variable low level reactivity in normal mammary epithelium.

Conclusions: We report here, for the first time, that mesothelin is preferentially expressed in 2/3 of TNBCs but rarely in other BRCA (2%), and not at all in normal mammary tissue. Although its oncogenic role in TNBCs is unknown, it could be a potential therapeutic target in TNBCs for which there are few available treatment options. Studies are currently underway to evaluate T-cell mediated killing of mesothelin-expressing breast carcinoma *in vitro* with promising results. While the expression of c-Met is not specific to TNBC, it might still be a therapeutic target in TNBC when conventional drugs have been exhausted.

299 Comparison of Complete and Representative Frozen Section Sampling of Breast Cancer Sentinel Lymph Node

W Xu, K Kostroff, T Bhuiya. Hofstra North Shore-LIJ School of Medicine, Lake Success, NY; Hofstra North Shore-LIJ School of Medicine, New Hyde Park, NY.

Background: Intraoperative examination of sentinel lymph nodes (SLN) is critical in surgical management of breast cancer. Positive SLN usually leads to axillary lymph node dissection. Various methodologies are employed in handling SLN during frozen section. In this study, we compared the diagnostic outcomes between freezing the entire lymph node and freezing a representative section of the node.

Design: 958 breast cancer cases with 2211 SLN were collected from two tertiary hospitals from 01/01/2008 to 12/31/2010, including 325 cases with 956 SLN (2.9/case) from hospital 1 (H1), and 633 cases with 1255 SLN (2.0/case) from hospital 2 (H2). In H1, a lymph node was sliced at 2 mm and entirely frozen; while in H2, half of a small node or one slice of a large node cut at 2 mm intervals was frozen. Both hospitals performed H&E and AE1/3 immunohistochemistry examinations on 3 levels of permanent sections for frozen section negative cases as final SLN analysis. The results were statistically analyzed with Chi square test.

Results: For H1, 110 of 956 (11.5%) SLN were positive in final analysis, including 91 SLN with macrometastasis (macromet), 9 with micrometastasis (micromet) and 10 with isolated tumor cells (ITC); 87 of the 110 positive SLN (79.1%) were positive on frozen (80 macromet, 6 micromet, 1 ITC). For H2, 186 of 1255 (14.8%) SLN were positive in final analysis (125 macromet, 26 micromet, 35 ITC); 116 of the 186 positive SLN (62.4%) were positive on frozen (114 macromet, 1 micromet, 1 ITC). The sensitivity, specificity and negative predictive value of SLN frozen evaluation in H1 were (%): for macromet 94.5/100/99.4, micromet 66.7/100/99.7, and ITC 10.0/100/99.1; and in H2, for macromet 94.4/100/99.4, micromet 3.8/100/98.0, and ITC 2.9/100/97.3. Chi square statistical analysis showed a significant difference in detection of micromet in SLN between the two protocols ($p < 0.001$), but no significant difference for the detection of macromet ($p = 0.43$) and ITC ($p = 0.33$).

Conclusions: Frozen examination of the entire SLN detects significantly more SLN with micromet than representative sampling. Both methods are equally effective in detecting macromet, and inadequate in ITC detection. As the paradigm changes for the indications for an axillary dissection, the significance of a micromet found at frozen section will probably change. In the meantime, saving a patient a second surgery by complete evaluation of SLN at frozen section remains a desirable practice.

300 Evaluation of 2358 Breast Needle Biopsy Cases: Patients with Pure Atypical Flat Lesions Could Be Spared Surgical Excision

R Yamaguchi, M Tanaka, J Akiba, Y Naito, H Yano. Kurume University School of Medicine, Kurume, Japan; Social Insurance Kurume Daiichi Hospital, Kurume, Japan.

Background: The management of atypical flat lesions and other atypical ductal/lobular hyperplasia remains under discussion and the terminology used is confusing. In the present study, we focused on atypical flat lesions with other atypical lesions and low-grade ductal carcinoma *in situ* (DCIS).

Design: We examined the subsequent surgical results and follow-up data on borderline lesions and low-grade DCIS for 2358 needle biopsy cases.

Results: There were 17 cases (0.72%) with pure flat epithelial atypia (FEA), 44 (1.87%) with pure atypical ductal hyperplasia (ADH) and three (0.13%) with pure atypical lobular hyperplasia (ALH). In addition, there were 18 cases (0.76%) with ADH + FEA, three (0.13%) with ALH + FEA and one (0.04%) with ALH + FEA + ADH. The total number of cases with borderline lesions was 86 (3.65%). Subsequent surgical excision revealed the following incidences of malignancy: pure FEA (1/8) vs. pure ADH (17/31) ($p = 0.0489$); pure FEA (1/8) vs. FEA + ADH (7/10) ($p = 0.0248$); pure FEA (1/8) vs. pure FEA + ALH (2/3) ($p = 0.152$); pure ADH (17/31) vs. FEA + ADH (7/10) ($p = 0.265$). Among the 2358 cases, 703 had cancer and 155 had DCIS. Pure clinging carcinoma, monomorphic type (; pure FEA) was not seen in the 78 cases (50.3%) with low-grade DCIS. None of the cases of low-grade DCIS recurred during a follow-up period of 925.6 ± 429.9 days.

Conclusions: The pure type of clinging (monomorphic) DCIS (pure FEA) was rarely seen, especially in surgical specimens. After diagnosis of pure FEA using needle biopsy, follow-up findings including imaging data indicated that its appearance did not change during the follow-up period. Thus, we concluded that patients with pure FEA could be spared surgical excision, and that FEA is a more appropriate term than clinging (monomorphic) carcinoma or flat type DCIS.

301 The Predictive Value of P53 Expression to Anthracycline-Based Neo-Adjuvant Therapy in Triple Negative Breast Cancer Patients

JT Yang, CZ Liu, W Dooley, R Squires, E Jett, J Parker. OUHSC, Oklahoma City, OK.

Background: Triple negative breast carcinoma (TNBC) is an aggressive tumor without expression of estrogen/progesterone receptors and Her2/Neu. Anthracycline-based neoadjuvant therapy (ABNT) is routinely used in high stage TNBC patients. It is effective in some patients but has serious toxicity. Previously we have found that the extent of response to ABNT in TNBC patients can be categorized into three groups. complete pathologic response (cPR), no response, and partial response. The aim of this study is to assess the predictive value of p53 expression in these distinct responding groups of TNBC patients. Predictive marker study would help for the patient selection for this regimen.

Design: Total 74 TNBC cases are included. 40 are no response/nearly no response cases (tumor reduced $<20\%$ of the original size and without marked treatment cytological changes) and 34 are cPR/nearly cPR cases (Microscopically scattered small tumor nests with marked therapeutic degenerative changes). Anti-p53(Bp53-11) immunohistochemical stain is performed using Ventana on formalin fixed paraffin-embedded tissues with appropriate positive and negative controls. The staining results

show essentially biphasic distribution and are categorized as positive (diffusely strong stain), negative (no stain or weak stain in less than 50% of tumor cells), and intermediate. The data were assessed by chi-square for statistical significance.

Results: In 40 no response/nearly no response cases, 27 are negative (67.5%) for p53 expression; 11 positive (27.5%); and 2 intermediate (5%). In 34 cPR/nearly cPR cases, 9 are negative (26.5%) for p53 expression, 24 positive (70.5%), and 1 intermediate (3%). For the predictive value of p53 expression to ABNT, the sensitivity is 72% and specificity 71%. The positive predictive value is 69% and negative predictive value 75%. Chi-Square $P = 0.0009$, <0.001 , extremely significant.

Conclusions: The results show that p53 expression is significantly associated with response to ABNT in TNBC patients. Positive p53 expression is in significantly higher numbers of cPR/nearly cPR patients and negative p53 expression is in significant higher numbers of no response/nearly no response patients. The data bank for the study will be expanded to get more statistical power and the mechanism of p53 expression to response to ABNT needs to be further investigated. Other predictive markers also need to be explored.

302 RNA Binding Protein IMP3 Is Helpful in Differentiating Borderline and Malignant Phyllodes Tumor of the Breast

X Yang, B Ustun, S Goodman, D Kandil, A Khan. UMassMemorial Medical Center, Worcester, MA.

Background: Phyllodes tumor (PT) is a rare fibroepithelial neoplasm of the breast, which at times poses a challenge to separate into prognostically reliable categories especially on needle core biopsy (NCB). Several classification schemes have been proposed to grade PT; some using a two-tier scheme into benign and malignant, while others suggest dividing them into three categories: benign, low-grade malignant and high-grade malignant; or benign, borderline, and malignant. The latter grading scheme has been adopted by the WHO and employs histologic criteria such as stromal hypercellularity, pleomorphism, tumor margins and mitotic activity. Ki67 have been found useful in classification of PT but no standard threshold is established and there remains a need for additional biomarkers that may assist in the grading of PT. IMP3, an oncofetal protein, is a member of the insulin-like growth factor-II (IGF-II) mRNA-binding protein family. Its relevance as a biomarker in separating benign and malignant epithelial and mesenchymal tumors have been recently reported and therefore seems to be a good candidate for evaluation in PT.

Design: We retrieved all PTs resected at our institution over a 12-year (1999-2010) period. The slides were reviewed and PT classified according to the WHO criteria into benign, borderline and malignant category. IMP3 immunostaining was performed on all cases and Ki67 immunostaining on all borderline and malignant tumors. IMP3 immunostaining was considered positive if stromal tumor cells showed cytoplasmic and/or membranous staining. Ki67 index was calculated by counting percent of stromal cells showing nuclear immunoreactivity. IMP3 expression was correlated with tumor grade, tumor size and Ki67 index. Statistical analysis was performed using the Student's T-test (2-tailed).

Results: Fifty-one PTs cases on which blocks and slides were available included benign ($n=33$), borderline ($n=13$) and malignant ($n=5$). The median age at resection was 41, 49, and 65 years for benign, borderline, and malignant PTs, respectively. All 33 benign and 13 borderline PTs were IMP3 negative, while all 5 malignant PTs showed varying degrees of IMP3 immunostaining ($p=0.004$). Mean Ki67 index was significantly higher (10.6%) in IMP3 positive (malignant) compared to (3.35%) in IMP3 negative (borderline) tumors ($p=0.02$). There was no correlation between IMP3 expression and tumor size ($p=0.43$).

Conclusions: IMP3 is preferentially expressed in malignant PT. Immunostaining for IMP3-oncofetal protein can be a helpful tool in classifying PTs in challenging cases, especially in NCB.

303 The Effect of 96-Hour Formalin Fixation on the Immunohistochemical Evaluation of Estrogen Receptor (ER), Progesterone Receptor (PR), and HER2 Expression in Invasive Breast Cancer

IZ Yildiz-Aktas, DJ Dabbs, M Chivukula, R Bhargava. University of Pittsburgh Medical Center, PA.

Background: Accurate ER, PR and HER2 results are essential for proper therapeutic decision making in breast cancer treatment. The ASCO/CAP guidelines recommend formalin fixation for up to 72 hours for ER/PR, and up to 48 hours for HER2. Our aim was to study the impact of 10% neutral-buffered formalin fixation of 96 hours on ER/PR and HER2 testing by immunohistochemistry by comparing core biopsies fixed under current ASCO/CAP guidelines to resection samples fixed for 96 hours.

Design: Tissues were collected prospectively and fixed in 10% neutral-buffered formalin for 96 hours. An attempt was made to include cases with weak to moderate receptor expression. Of the 47 cases, for ER, 6 were negative, 5 were weak, 9 were moderate, and 27 were strongly positive. For PR, 12 were negative, 11 were weak, 15 were moderate, and 9 cases were strongly positive. For HER2, 4 were scored 0, 12 were 1+, 24 were 2+, and 7 were 3+. All cases were run on the Benchmark XT, using antibody clones SP1 (ER), 1E2 (PR) and 4B5 (HER2). Scoring for ER/PR was performed using the semi-quantitative H-Score method, with an H-score of 1 considered positive. ASCO/CAP guideline scoring was used for HER2.

Results: Of the 47 cases, only one case (2%) showed a qualitative change in result. However, this change was a positive ER result (H-score of 1) on 96 hours resected sample compared to a negative ER result (H-score of 0) on core biopsy. ER H-scores remained the same on 19 cases (40%), was lower on 17 cases (36%) and higher on 11 cases (23%). PR H-score remained the same on 21 cases (45%), was lower on 15 cases (32%) and higher on 11 cases (23%). For HER2, the IHC score remained the same on 46 cases (98%) and changed from 0 to 1+ on one case (2%).

Conclusions: Our results indicate no clinically significant difference in qualitative assessment of ER, PR, and HER2 results due to formalin fixation for 96 hours. The results do show slight difference in quantitative H-scores for hormone receptors, but we favor tumor heterogeneity and/or intra-observer variability as the cause for this slight variation rather than prolonged fixation, as the variation occurred in both directions. ER, PR and HER2 immunohistochemical results should be considered valid for cases fixed for up to 96 hours.

304 Impact of Cold Ischemic Time on Estrogen Receptor, Progesterone Receptor, and HER2 Semi-Quantitative Immunohistochemical Scoring

IZ Yildiz-Aktas, DJ Dabbs, R Bhargava. University of Pittsburgh Medical Center.

Background: There is a dearth of data regarding the acceptable limits of cold ischemic time (CIT) for breast tumors subjected to immunohistochemical (IHC) analysis for ER/PR/HER2. ASCO/CAP guidelines currently recommend a CIT of <1 hour.

Design: Breast resection specimens were subjected to variable CIT periods (0.5, 1, 2, 3, 4, 24, and 48 hours) within the refrigerator and at room temperature. Hormone receptors were semi-quantitatively scored using H-score method. HER2 was scored using the ASCO/CAP guidelines. The results were compared to the core biopsy scores which have negligible CIT. Mild reduction in staining for hormone receptors was judged present if the H-score on the resection specimen was between one-half and three-fourth of the H-score at core biopsy. Significant reduction was judged present when the H-score on resection was less than one-half of the core biopsy H-score. Mild reduction in HER2 staining was judged present if there was one step discordance, and significant reduction was judged present if there was 2-step reduction in staining. A true reduction was judged present only when the reduction was consistently present for the increasing time interval. A focal reduction for a particular time sample was attributed to the heterogeneity of the tumor sample.

Results: The study included 26 cases, all of which had refrigerated samples. Non-refrigerated samples (samples at room temperature) were present on 24 cases. The reduction in staining for ER, PR, and HER2 is shown in table 1.

Table 1

	Mild reduction	Minimum time to mild reduction	Significant reduction	Minimum time to significant reduction
Refrigerated Sample ER	8/26 (31%)	4 hours (3 of 8 cases)	6/26 (23%)	4 hours (1 of 6 cases)
Non-refrigerated Sample ER	9/24 (38%)	2 hours (1 of 9 cases)	8/24 (33%)	2 hours (1 of 8 cases)
Refrigerated Sample PR	6/26 (23%)	0.5 hour (2 of 6 cases)	4/26 (15%)	4 hours (1 of 4 cases)
Non-refrigerated Sample PR	8/24 (33%)	0.5 hour (1 of 8 cases)	6/24 (25%)	2 hours (1 of 6 cases)
Refrigerated Sample HER2	2/26 (8%)	4 hours (2 of 2 cases)	0/26 (0%)	No significant reduction
Non-refrigerated Sample HER2	10/24 (42%)	3 hours (3 of 10 cases)	2/24 (8%)	24 hours (2 of 2 cases)

Conclusions: Non-refrigerated samples are affected more by prolonged CIT than refrigerated samples. CIT of as short as one-half hour may occasionally impact the IHC staining for PR. Significant reduction in IHC staining however; generally does not result until 4 hours for refrigerated samples and 2 hours for non-refrigerated samples. The ASCO/CAP guideline of CIT < 1 hour is a prudent guideline to follow.

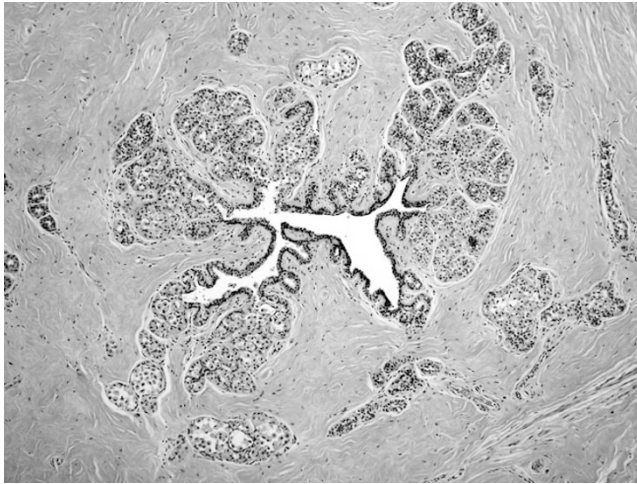
305 Terminal Duct Lobular Units (TDLU) in the Nipple: Implications for Nipple-Sparing Mastectomy (NSM)

JY Yoon, ON Kryvenko, D Chitale, MW Lee. Henry Ford Hospital, Detroit.

Background: Breast cancer treatment has been greatly evolved from radical mastectomy to breast conserving therapy (BCT). As part of BCT and aesthetic approach, NSM is increasingly done for both cancer treatment and risk reduction, but has raised the oncologic safety issue since recurrence data on NSM is limited. Ductal & lobular neoplasia (DLN) is thought to arise in the TDLU. Therefore, our aim was to assess frequency of TDLU in grossly unremarkable nipples and its involvement by DLN. We also assessed involvement of lactiferous ducts in these nipples by DLN.

Design: We prospectively collected grossly unremarkable nipples from 66 consecutive mastectomy specimens. Entire nipple was submitted. Nipples were transected at the base of nipple papilla: base-en face, papillae-vertically serially sectioned. Presence of TDLU & any epithelial proliferations were recorded.

Results: The indications for mastectomy were: 42 invasive ductal carcinoma (IDC), 6 ductal carcinoma in situ, 8 invasive lobular carcinoma, 1 lobular carcinoma in situ (LCIS), 9 prophylactic. TDLU was seen in 17 (25.8%) nipples; 6 at the en face base section, 6 in the perpendicular section of the papillae and 5 in both. Epithelial proliferations identified in TDLU were: 1 LCIS (case of IDC) and 1 columnar cell change (case of IDC).



No pathologic changes were found in nipples from prophylactic mastectomies. Occult ductal lesions without TDLU were: 3pagetoid extensions along lactiferous ducts(case of IDC), 1intraductal papilloma(case of IDC), 1direct extension by IDC, and 1dermal lymphatic involvement(case of IDC).

Conclusions: In our cohort, the frequency of TDLU was higher(25.8%) than previously reported two studies(9.4% & 17%) which would therefore make the development of a primary cancer in this area not unusual. We found TDLU in both at the base and papillae of nipple with equal frequency, unlike prior published study where TDLU were noted only near the base of nipple, with no TDLUs found at the tip. Occult nipple lesions which may be the source of recurrence / new malignancy were seen in 10.6%(7/66) of grossly uninvolved nipples. Our findings bring back the issue of oncologic safety when considering NSM and whether surgeons should routinely perform subcutaneous dissection under the areola that remove the maximum of glandular and ductal tissue.

306 A Single Institution Analysis of Metastatic Breast Carcinoma and Axillary Sentinel Lymph Node False-Negative Intraoperative Interpretations over a Ten Year Period

D Yu, S Silverman, J Danyluk. Misericordia Hospital, Edmonton, AB, Canada; University of Alberta, Edmonton, AB, Canada.

Background: We evaluated 1720 cases of breast carcinomas excised with axillary sentinel lymph nodes from 2000-2010 to determine the diagnostic accuracy of sentinel node intraoperative scrape preparations. The false-negative intraoperative interpretations were analyzed in relation to the size and location of metastatic deposits on permanent sections, and the characteristics of the underlying primary tumor. In addition, the node status was determined in patients who underwent subsequent axillary node dissection following a false-negative intraoperative interpretation.

Design: 1720 breast carcinomas excised with axillary sentinel lymph nodes and some with axillary contents in the period between 2000-2010 were reviewed. All sentinel node intraoperative scrape preparation interpretations were compared to the formalin fixed, paraffin embedded permanent sections to determine diagnostic accuracy using standard calculations. Sentinel lymph node false-negative intraoperative interpretations was analyzed with regard to the size, location of metastatic deposits, primary tumor histologic subtype, size, grade, lymphovascular invasion, and node status following subsequent axillary lymph node dissection.

Results: 109 false negative results were identified on permanent sections (32 macrometastasis and 77). Of the macrometastasis there were 21 (66%) ductal, 10 (31%) lobular, and 1 ductolobular carcinomas. Of the micrometastasis there were 63 (82%) ductal, 10 (13%) lobular, 2 ductolobular, and 2 mucinous carcinomas. 73 patients with false-negative intraoperative interpretations underwent subsequent axillary lymph node dissection with 7/73 patients having metastatic carcinoma (5 ductal, 1 ductolobular, 1 lobular carcinomas) in the axillary lymph nodes on permanent sections.

Conclusions: The sensitivity of the intraoperative scrape preparation was 71.3% and the specificity was 99.5%. The positive predictive value was 0.98 and the negative predictive value was 0.91. Micrometastases (71%) accounted for most of the false-negatives intraoperative interpretations. Overall, invasive ductal carcinoma was the predominant subtype within all false-negative sentinel lymph nodes. Macrometastases had a higher proportion of lobular carcinomas than micrometastases. Only a small number (10%) of patients with false-negative interpretations at intraoperative scrape preparation ultimately had metastatic carcinoma in their axillary nodes following a subsequent axillary lymph node dissection.

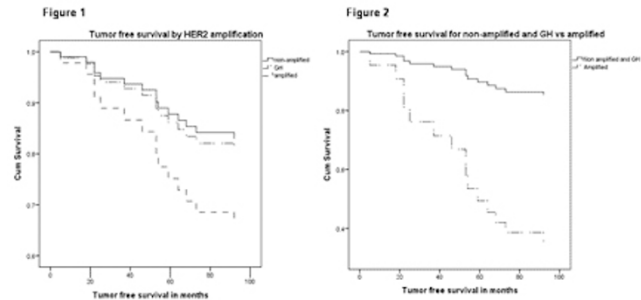
307 HER2 Gene Amplification: The Most Important Independent Prognostic Factor in Patients with Stage II Breast Cancer

P Zhang, E Castro-Echeverry, SM Dobin, A Rao. Scott and White Memorial Hospital, Temple, TX; Texas A&M Health Science Center, College Station, TX.

Background: HER2 gene amplification in invasive breast cancer is generally associated with poor prognosis. However, the long-term significance of HER2 status using the 2009 ASCO/CAP guidelines, with emphasis on genetic heterogeneity, has not been well established in stage II breast cancer.

Design: A retrospective chart review was performed on patients diagnosed with Stage II Breast Cancer in 2002. HER2 was evaluated by fluorescence in situ hybridization (FISH) and the cases were categorized per 2009 ASCO/CAP guidelines as amplified,

heterogeneous genetic heterogeneity (GH), and non-amplified. Covariates included age, Nottingham combined grade, Estrogen receptor (ER) and progesterone receptor (PR) status. Cox Proportional Hazards (PH) regression modeling and Kaplan-Meier Survival Curves were used to determine independent predictors of tumor free survival. **Results:** Of 347 registered breast cancer cases from 2002, 70 were stage II patients with HER2 data. HER2 gene amplification status is as follows: 7 cases (11.4%) amplified, 4 (5.7%) GH, 59 (84.3%) not amplified. After adjusting for age and ER/PR status, amplified HER2 status was the most important independent prognostic factor by Cox PH (HR 4.7, 95%CI 1.5-14.8, $p=0.009$). No significant difference ($P=0.37$) in prognosis was found between the HER2 non amplified group and the GH group (Figure 1). Compared to the non amplified and GH groups, the patients with HER2 amplification have worse prognosis ($P=0.035$) (Figure 2). Age, ER status, PR status and Nottingham combined grade were not significantly associated with tumor free survival in this cohort. **Conclusions:** HER2 amplification status is the single, independent, and most important prognostic factor in stage II breast cancer in our study while HER2 GH is not correlated with clinical outcome. With regard to the prognostic significance of HER2 amplification and the clinical relevance of HER2 heterogeneity, a large size, preferably randomized clinical trial, is needed.



308 The Management of Radial Sclerosing Lesions/Radial Scars Diagnosed in Core Biopsy: Excision or Not?

S Zheng, B O'Hea, M Singh, S Zee, C Tornos, J Liu. Stony Brook University Medical Center, Stony Brook, NY.

Background: Radial sclerosing lesions/radial scars (RSL/RS) are benign breast lesions that have a stellate appearance with radiating spicules mimicking breast cancer at imaging and histological levels. Though RSL/RS diagnosed by needle biopsies may lead to surgical excisions, the association of RSL/RS with breast cancer is not well-established due to conflicting data from various studies.

Design: Retrospective data were collected from women with a histological diagnosis of RSL/RS in needle core biopsies over an 11-year period from 2000 to 2011 in our institution. Patients with invasive carcinoma, ductal carcinoma in situ (DCIS), lobular carcinoma in situ (LCIS), atypical ductal hyperplasia (ADH), atypical lobular hyperplasia (ALH), or any type of atypia, as well as papilloma, in the same needle biopsies were excluded from this study. The histological findings of the initial biopsies and the following surgical excisions were analyzed to evaluate the necessity of open surgical excisions following a diagnosis of RSL/RS in core biopsy.

Results: 48 cases of RSL/RS on core biopsies were identified, and 34 of these 48 underwent surgical excisions. One (3%) had a small invasive ductal carcinoma in the surgical excision. None of the excision had DCIS. 4 cases showed atypia (12%) (including one atypical papilloma, one flat epithelial atypia, one with both ADH and ALH and one with ALH). The excisions in 15 of 34 cases had residual RSL/RS, and the remaining 14 cases had non-RSL/RS type benign findings on excision.

Conclusions: Surgical excisions following the diagnosis of RSL/RS on core biopsies had a very low rate of malignancy at our institution (3%). Surgical excision of RSL/RS may not be warranted in all cases.

309 Adenoid Cystic Carcinoma of the Breast: Clinicopathologic and Molecular Analysis of 56 Cases

X Zhu, J Chen, Y Xing, CT Albarracin, Y Zhao, PH Rao, X Li, D Bell, A El-Naggar, SC Abraham, Y Wu. UT MD Anderson Cancer Center, Houston; Cancer Hospital, Fudan University, Shanghai, China; Texas Children's Hospital, Houston.

Background: Adenoid cystic carcinoma (ACC) is a rare basal type of mammary gland malignancies with relatively good prognosis, representing only about 0.1% of all primary breast carcinomas. Except for the population-based study, the largest clinical series in the English literature includes fewer than 30 cases. The clinicopathologic features, molecular abnormalities, and clinical outcomes of this rare entity are not fully elucidated.

Design: We studied 56 primary ACCs of the breast from a single institution. The tumors were graded histologically based on the presence and extent of the solid component (Hum Pathol; 18:1276-81). Grade I: no solid component; grade II: solid component comprising $\leq 30\%$ of the tumor; grade III, solid component $>30\%$ of the tumor. Cytogenetic FISH analysis for MYB-NFIB gene fusion, commonly seen in ACC of the head/neck region, was performed using the published methods (Clin Cancer Res; 16:4722-31). Clinicopathologic features were correlated with clinical outcome.

Results: Patients ranged from 33 to 87 years (median: 60 years). Tumor size ranged from 0.8 to 25 cm (median: 2.4 cm). Three patients (5%) had regional lymph node metastasis at presentation. Clinical follow-up was available in 33 patients, with a median follow-up of 72 months. Twelve of 33 (36%) experienced distant recurrence. The 5-year and 10-year overall survival (OS) and recurrence-free survival (RFS) rates were 86%/68% (OS/RFS) and 62%/47%, respectively. Statistical analysis showed that older age (≥ 60 years) and presence of regional node metastasis at presentation were

significantly associated with poor OS ($p=.05$ and $<.001$) and RFS ($p=.009$ and $<.001$) (Figure 1). In addition, patients with grade III tumors were more likely to have lower OS and RFS rate than patients who had grade I or II tumors; although the differences were not statistically significant ($p=0.31$ for OS and $p=0.79$ for RFS) due to limited sample size. MYB-NFIB gene fusion was identified in 3 of 8 cases for which FISH study was performed.

Conclusions: Not all mammary ACCs have good prognosis. Old age, nodal metastasis at presentation and high histologic grade are poor prognostic indicators in this rare type of breast cancers.

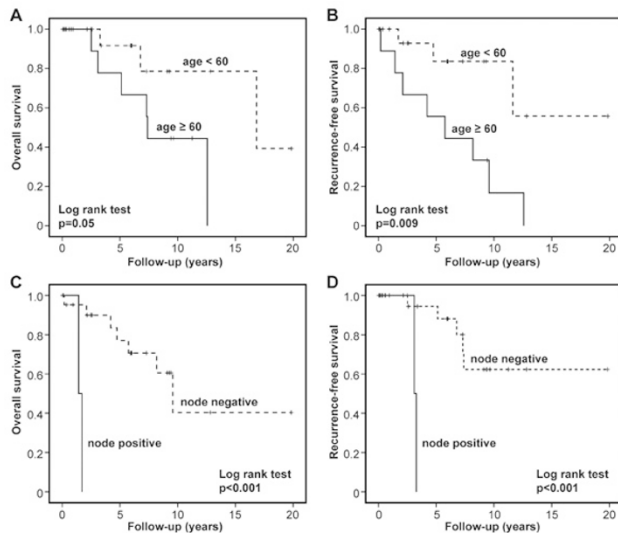
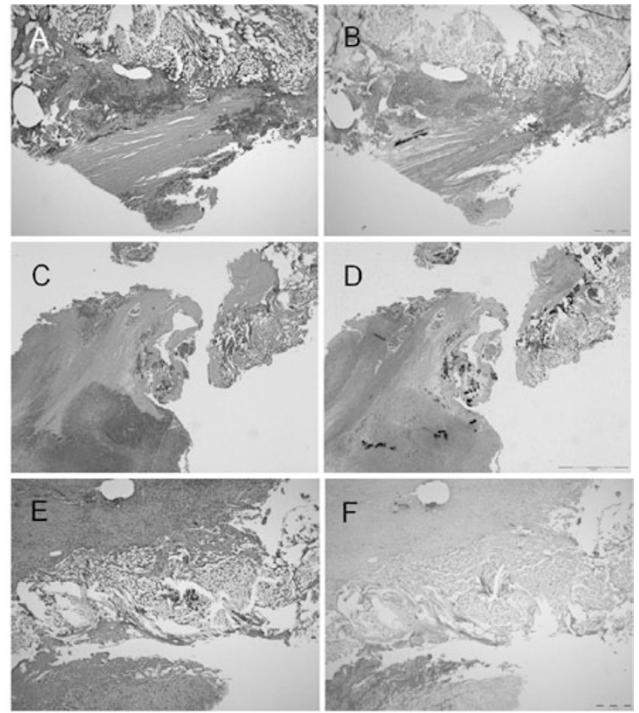


Figure 1. Older age (≥ 60 years) and the presence of regional node metastasis at presentation were significantly associated with poor OS and RFS in breast ACC.



Representative images of aortic specimens and adjacent graft material. (A, B) Images from a subject in Group A, Fig 2, showing small cluster of Gram (+) cocci near the graft implantation site. (C, D) Images from a subject in Group B, Fig 4, showing multiple clusters of Gram (+) cocci (arrows) and abscess formation (asterisk). (E, F) Images from a subject in Group C, Fig 6, negative Gram staining.

Cardiovascular

310 A Novel Dual Antibiotic-Bonded Graft for Preventing Vascular Aortic Infection

I Aboshady, A Shah, D Vela, T Dvorak, I Raad, KG Khalil, LM Buja. The Texas Heart Institute, Houston, TX; The University of Texas HSC, Houston, TX; M.D. Anderson Cancer Center, Houston, TX; Baylor College of Medicine, Houston, TX.

Background: Perioperative infection of an aortic graft is associated with a mortality rate of 10%-30% and an amputation rate $>25\%$. In vitro studies suggest that an antibiotic-impregnated graft could help prevent perioperative graft infection. In a pilot animal study, we bonded aortic grafts with 2 different antibiotics and evaluated their ability to prevent direct perioperative bacterial contamination.

Design: We surgically implanted a 6-mm Vascular Dacron graft in the infrarenal abdominal aorta of 6 Sinclair miniature pigs. Two pigs received grafts bonded with 60 mg/mL solutions of rifampin and minocycline; the other 4 pigs received unbonded grafts. Before implantation, both bonded grafts and 2 of the 4 unbonded grafts were immersed for 15 minutes in a 2-mL solution containing 1 to 2×10^7 colony-forming units (CFUs)/mL of *Staphylococcus aureus* (ATCC 29213). Two weeks after graft implantation, the pigs were euthanized, and the grafts were excised for clinical, microbiologic, and histopathologic study.

Results: The 2 *S. aureus*-treated bonded grafts showed no bacterial growth upon explantation, whereas the 2 *S. aureus*-treated unbonded grafts had high bacterial counts (6.25×10^6 and 1.38×10^7 CFU/graft). The 2 unbonded and untreated grafts had bacterial growth (1.8×10^3 and 7.27×10^3 CFU/graft) that presumably reflected accidental perioperative bacterial contamination; *Staphylococcus cohnii ssp urealyticus* and *Staphylococcus chromogenes*, but not *S. aureus*, were isolated. The histopathologic and clinical data confirmed the microbiologic findings. Only pigs that received unbonded grafts had histopathologic evidence of a perigraft abscess.

Conclusions: Bonding aortic grafts with 2 antibiotics appears to be a promising method of reducing direct perioperative bacterial contamination. Further studies are needed to explore this novel graft's ability to combat one of the most feared complications in vascular surgery.

311 Flat-Panel Computed Tomography for Longitudinal Assessment of Atherosclerotic Plaque Components: Quantitative Correlations with Pathologic Measurements

I Aboshady, DD Cody, EM Johnson, D Vela, KG Khalil, GW Gladish, LM Buja. The Texas Heart Institute, Houston, TX; M.D. Anderson Cancer Center, Houston, TX; The University of Texas HSC, Houston, TX; Baylor College of Medicine, Houston, TX.

Background: Flat-panel computed tomography (FpCT) provides better spatial resolution than 64-channel CT and better assesses atherosclerotic plaque components *in vivo* in animal aortas similar in size to human coronary arteries. We assessed the usefulness of FpCT in longitudinal studies of plaque development.

Design: We used a prototype FpCT scanner with a dual-panel rotating gantry and a commercial Performix CT x-ray source. 184 aortic histology sections from 6 Watanabe heritable hyperlipidemic rabbits were quantitatively compared with 64-CT (image thickness, 0.625 mm) and FpCT (image thickness, 0.150 mm) images. Images were reoriented perpendicular to the vessel centerline.

Results: Although FpCT was more sensitive in detecting eccentric lesions (42% vs 0%; $P=0.000$), the area under the curve (AUC) for FpCT (0.6) did not significantly differ from that for 64-CT (0.45; $P=NS$). In detecting plaques with $\leq 10\%$ lipid (low-attenuation foci), FpCT was more sensitive than 64-CT (24% vs 0.7%; $P<0.00$) and had a greater AUC (0.6 vs 0.5; $P<0.006$). Additionally, FpCT was more sensitive (65% vs 0%; $P<0.00$) in detecting plaques with $\leq 5\%$ calcium (high-attenuation foci) but not in detecting branch points. Both FpCT and histology could detect low-attenuation foci as small as 0.3 mm in diameter, whereas 64-CT could detect only low-attenuation foci ≥ 1.5 mm in diameter. In the current, long-term phase of the study, 30 New Zealand White hyperlipidemic rabbits receive a high-fat diet (0.5% cholesterol). Lesions are monitored and correlated through monthly serial scanning sessions over 6 months. Images are collected 30 seconds after Visipaque injection (560 mg/kg; through an ear vein).

Conclusions: FpCT seems to have more potential in quantitative screening for low-risk small atherosclerotic lesions, whereas 64-CT is limited to imaging established, well-characterized lesions, particularly when measuring the vascular wall thickness in a rabbit model of atherosclerosis. FpCT seems to have potential for quantitative monitoring the evolution of the calcific and lipid components of plaque.

312 Surgical Pathology of Native Valve Endocarditis in 310 Specimens from 287 Patients (1985-2004)

MC Castonguay, KD Burner, WD Edwards, LM Baddour, JJ Maleszewski. Mayo Clinic, Rochester, MN.

Background: Few large studies have separately documented the clinical and pathologic features of native valve endocarditis from those of prosthetic valve endocarditis. Furthermore, surgical management of valvular endocarditis has evolved considerably in the past 20 years.

Design: A retrospective study of medical records from all patients undergoing surgery for native valve endocarditis at our institution between 1985 and 2004. Medical records were reviewed from 287 patients for demographics, infected native valve(s), infecting organism, risk factors for endocarditis, and pathologic features. Because 22 patients