Journal of Human Genetics (2017) 62, 507–511

www.nature.com/jhg

SHORT COMMUNICATION

Norrbottnian clinical variant of Gaucher disease in Southern Italy

Simona Sestito[1], Mirella Filocamo[2], Ferdinando Ceravolo[1], Francesca Falvo[1], Michele Grisolia[1], Maria Teresa Moricca[1], Renato Cantaffa[3], Serena Grossi[2], Pietro Strisciuglio[4] and Daniela Concolino[1]

The Norrbottnian type of Gaucher disease (GD), as described many years ago, is due to a unique neuronopathic variant (c.1448T>G; L444P) that may have appeared during or before the sixteenth century in northern Sweden. It is a well-defined nosological entity with a characteristic course of clinical manifestations. In particular, Norrbottnian patients described in Sweden and Poland seem to share identical clinical histories characterized by the early onset of significant hepatosplenomegaly, often requiring splenectomy at an early age. Neurological involvement generally appears during the first or second decade of life, and includes horizontal gaze palsy, epilepsy, myoclonic movements, ataxia, dementia and cognitive impairment. Osteopenia occurs primarily in the spine, causing a severe and progressive thoracic kyphosis, although the involvement of other skeletal sites cannot be excluded. Here, we report on four Gaucher type 3 patients with Southern Italian ancestry presenting with clinical features and disease progression comparable to those of the 'Norrbottnian' Swedish phenotype, particularly regarding skeletal involvement with poor responsiveness to any therapeutical approach. Although a common ancestry among Southern Italian and Swedish Norrbottnian GD patients could not be investigated, the genotype [L444P]+[L444P] is the most frequently encountered in Southern Italy.
Journal of Human Genetics (2017) **62,** 507–511; doi:10.1038/jhg.2016.158; published online 22 December 2016

INTRODUCTION

Gaucher disease (GD; OMIM 230800, 230900 and 231000) is an autosomal recessive lysosomal storage disorder due to a deficiency of acid β-glucosidase (EC 3.2.1.45; glucocerebrosidase), which leads to progressive lysosomal accumulation of the β-glucosidase substrate, the glycolipid glucocerebroside, primarily in cells of the monocyte-macrophage system.[1] To date, more than 430 variants in the *GBA* gene (MIM # 606463) have been reported to cause the disease (see the Human Gene Mutation Database, www.hgmd.org).

The classic categorization of GD into three phenotypes, including types 1, 2 and 3, is based primarily on the presence and progression of central nervous system involvement.[1] Neuronopathic forms of GD are rare. It has been estimated that ~6% of Gaucher patients have neuronopathic forms of GD; 5% have the chronic neuronopathic form (GD type 3) and 1% have the acute form of the disease (GD type 2).[2] GD type 3 has been divided into three variants termed types 3A, 3B and 3C. Although subtype 3C presents with a distinct clinical manifestation, substantial clinical overlap exists between subtypes 3A and 3B. Type 3A patients show mild-to-moderate hepatosplenomegaly and slowly progressive neurological deterioration, as well as recurrent myoclonic seizures, whereas type 3B patients also show hepatosplenomegaly, and horizontal supranuclear gaze paresis is the major neurologic sign.[1]

The Norrbottnian type of GD, described many years ago, is a neuronopathic variant due to a unique mutation, c.1448T>G (traditionally known as L444P), which may have arisen during or before the sixteenth century in northern Sweden.[3] It is a well-defined nosological entity with a course of clinical manifestations characterized by the early onset of prominent hepatomegaly and splenomegaly, often requiring splenectomy at an early age.[4] Neurological involvement generally appears during the first or second decade of life, and includes horizontal gaze palsy, myoclonic epilepsy, ataxia and dementia. Osteopenia occurs primarily in the spine, causing a severe and progressive kyphoscoliosis as a predominant skeletal manifestation, although the involvement of other skeletal sites cannot be excluded. Intellectual retardation has been detected in many of these patients. Interestingly, the Norrbottnian Swedish phenotype has also been described in a type 3 GD subgroup of other populations, including those from Japan, Egypt and Poland.[5–7]

The aims of this study were to describe our experience with five Gaucher type 3 patients who are homozygous for the L444P allele and are of Southern Italian ancestry and to compare the haplotypes between our series of patients and those of ethnic Poles, for whom the haplotype has been previously published.[7]

[1]Department of Medical and Surgical Science, Paediatric Unit, University 'Magna Graecia', Catanzaro, Italy; [2]Centro di diagnostica genetica e biochimica delle malattie metaboliche, Istituto G. Gaslini, Genoa, Italy; [3]Hematology, 'Pugliese-Ciaccio' Hospital, Catanzaro, Italy and [4]Department of Translational Medical Science, Section of Paediatrics, University 'Federico II' of Naples, Naples, Italy
Correspondence: Professor D Concolino, Department Medical and Surgical Science, Paediatric Unit, University 'Magna Graecia' of Catanzaro, 'Pugliese-Ciaccio' Hospital, Viale Pio X, Catanzaro 88100, Italy.
E-mail: dconcolino@unicz.it
Received 23 March 2016; revised 9 November 2016; accepted 20 November 2016; published online 22 December 2016

PATIENTS

The series in the present study consisted of five patients, including one still of pediatric age. The adult patients (3 males, 1 female), median age 38.2 years (range 32–49 years) belong to three distinct families. The diagnosis, based on an enzymatic assay demonstrat ing the deficiency of β-glucosidase, was confirmed by a molecular analysis that detected the L444P mutation in the homozygous state in all patients. The main clinical, radiological and laboratory findings of these patients are summarized in Figure 1 and Table 1.

Family A. Patients #1 and #2 are siblings, aged 39 and 32 years, respectively (Table 1), born from healthy consanguineous (cousins of second grade) parents. The GD diagnosis was confirmed in patient #1 when he was 14 months old because of a severe growth retardation (body weight and height $<$3rd centile), moderate hepatosplenomegaly and hematological abnormalities. Owing to the presentation of a similar clinical phenotype, his brother (patient #2) was also confirmed to have GD at 6 months of age. Splenectomy was performed for both brothers (Pt 1 and Pt 2) at ages 8 and 4 years, respectively, because of a severe and rapidly progressive splenomegaly associated with thrombocytopenia. Neurological signs appeared in Pt 1 and Pt 2 at 15 and 20 years, respectively. Both patients showed a reduction in intelligence quotient (60 and 55, respectively). Although progressive thoracic kyphosis was present in both patients (Figure 2), Erlenmeyer flask deformity was only found in Pt 1, who also complained of chronic mild bone pain. The two brothers began enzymatic replacement therapy (ERT) with alglucerase (60 IU kg^{-1} every 2 weeks) at 19 and 12 years and with imiglucerase (60 IU kg^{-1} every 2 weeks) at 23 and 16 years, but showed poor improvement in neurological problems and a progressive worsening of skeletal deformities.

Family B. Patient #3, a 49-year-old woman, is the second daughter of healthy consanguineous parents, born at the end of pregnancy through an uneventful delivery. At 8 months of age, she presented with an enlarged spleen and anemia, and at 4 years she had recurrent epistaxis and began to show some signs of neurological impairment and mild cognitive difficulties. The initial workup results were negative for the osteomedullary biopsy and positive for the sweat test, thus leading to a misdiagnosis of cystic fibrosis. At 8 years, she showed a mild dorsolumbar kyphoscoliosis and, because of a severe splenomegaly, a splenectomy was performed, and GD was diagnosed. During the following years, her condition worsened dramatically, and at the age of 20 years, she presented with epilepsy characterized by myoclonic seizures. She began ERT at age 23 when her clinical conditions were characterized by severe mental delay burdened by neurological signs, hepatomegaly, absent deambulation and a severe kyphoscoliosis (Figure 2). ERT restored a normal hepatic size and reduced the dysphagia in 2 years but was ineffective in resolving the other clinical signs.

Family C. Patient #4, the first child of consanguineous parents, was evaluated at age of 4 years for growth retardation (body weight and height $<$3rd centile) and hepatosplenomegaly associated with hematological abnormalities (anemia, thrombocytopenia and leukopenia). The clinical conditions of the patient at 11 years, before he began ERT, were characterized by short stature with normal body weight, normal puberal stage for age, right-convex dorsal kyphoscoliosis, hypotrophy of lower limbs, prominent abdomen, liver palpable at 8 cm from the arch ribs and spleen not palpable because of a partial splenectomy, due to hypersplenism, which was performed when the patient was 5 years of age. The neurological examination revealed slight walking difficulties, postural tremor, horizontal nystagmus and mild mental retardation.

The ERT, administered every 2 weeks at a dose of 60 IU kg^{-1}, led to a reduction of organomegaly, improvement of blood counts and coagulation, and stabilization of neurological symptoms.

Interstitial pulmonary disease was identified when the patient was 15 years of age, because of instrumental (chest radiogram) and functional (pulmonary function tests) abnormalities. Despite these abnormalities, the patient had never experienced respiratory symptoms.

When the patient was 28 years old, we observed the onset of psychiatric symptoms (deflection of mood, insomnia, agitation and loss of appetite) and a worsening of neurological signs (increased postural tremor, gait ataxia and impaired motor coordination). A psychiatric evaluation was performed, and a psychotic disorder was diagnosed together with a state of depression. Skeletal manifestations, including thoracic kyphoscoliosis (Figure 2), were not ameliorated by ERT.

Family D. The pediatric patient is a 6-year-old boy born after an uneventful gestation at 39 weeks. He presented with a clinically evident enlarged abdomen at the age of 16 months and was referred to an oncology department. The initial workup showed weight and height in the 50th percentile, splenomegaly (spleen size of 12.5 cm), anemia (Hb: 10 mg dl^{-1}), thrombocytopenia (100 000 ul^{-1}) and normal values of gammaglobulines. A marrow biopsy showed the presence of foam cells, thus leading to biochemical tests that revealed elevated levels of acid phosphatase (47.8 IU l^{-1}; nv 5–7) and chitotriosidase (19 786 nmol ml^{-1}; nv 25.75 ± 17). Beta-glucosidase deficiency (0.8 nmol mgprot^{-1} h^{-1}; nv 30.5 ± 19) and L444P homozygosity confirmed the GD diagnosis. The patient began with ERT at 18 months of age at a dosage of 60 IU kg^{-1} every 2 weeks and, at the age of 3 years, substrate reduction therapy (Miglustat, at the dosage of 300 mg per day). During the first year of therapy, we observed a rapid decrease in splenomegaly and a normalization of hematological values. At present, the patient does not show any sign of neurological impairment or skeletal involvement apart from a slight reduction of bone density. However, as described in previous reports, divergent

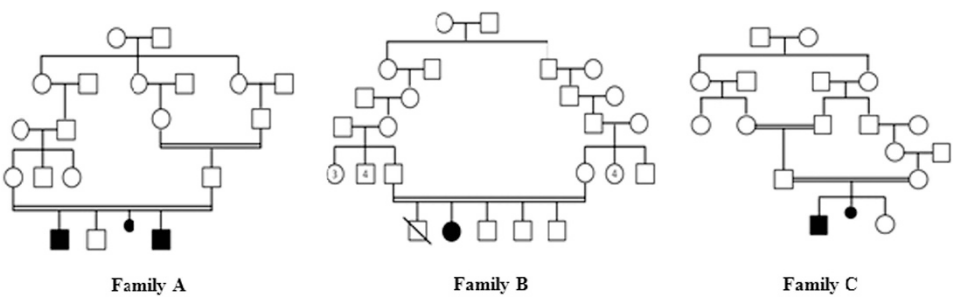

Figure 1 Pedigree of three unrelated families.

Table 1 Clinical and laboratory findings of the four adult GD patients

	Family A		*Family B*	*Family C*
	Pt #1	*Pt #2*	*Pt #3*	*Pt #4*
Age of onset	14 months	6 months	8 months	3 years and 6 months
Age at enzymatic diagnosis[a]	14 months	6 months	8 years	4 years
Genotype[b]	[L444P]+[L444P]	[L444P]+[L444P]	[L444P]+[L444P]	[L444P]+[L444P]
Clinical signs at diagnosis	Growth retardation, splenomegaly, anemia, thrombocytopenia	Growth retardation, hepatosplenomegaly	Splenomegaly, anemia, thrombocytopenia	Growth retardation, hepatosplenomegaly
Splenectomy	Total	Total	Total	Partial
Neurological signs	Horizontal supranuclear gaze palsy, myoclonic movements, low IQ, irritability	Mild myoclonic movements, low IQ, depression	Myoclonic movements, dysarthria, swallowing difficulties, seizures, supranuclear gaze palsy, ataxia, low IQ	Horizontal supranuclear gaze palsy, myoclonic movements, depression, progressive psychotic disorder, low IQ
Other signs	Thoracic kyphosis, bone pain, Erlenmeyer flask deformity	Mild thoracic kyphosis, interstitial lung involvement	Severe thoracic kyphosis, several skeletal deformities, loss of deambulation, interstitial lung involvement	Severe thoracic kyphosis, interstitial lung involvement
Familial history of Parkinsonism	No	No	No	No
Bone crises or osteonecrosis after splenectomy	No	No	No	No
Puberal development	Normal	Normal	Normal	Normal
Polyclonal/monoclonal gammopathy	No	No		
Acid phosphatase (nv = 0–7.4)	13.6 IU l^{-1} (28 y)[c]	49 IU l^{-1} (21 y)[c]	51 IU l^{-1}(38 y)[c]	37 IU l^{-1} (22 y)[c]
Chitotriosidase (nv = 25.75 ± 17)	61.35 nmol ml^{-1} (28 y)[c]	57.23 nmol ml^{-1} (21 y)[c]	129 nmol ml^{-1} h^{-1}(38 y)[c]	172 nmol ml^{-1} h^{-1} (22 y)[c]
Age at ERT start (years)	19	12	23	11
ERT duration (years)	20	10	27	22

Abbreviations: ERT, enzymatic replacement therapy; GD, Gaucher disease; IQ, intelligence quotient; nv, normal values; y, year.
[a]Beta-glucosidase activity in white blood cells was determined using 4-methylumbelliferyl-β-D-glucopyranoside as substrate in the presence of sodium deoxytaurocholate according to Raghavan *et al.*[20]
[b]Whenever possible, the homozygosity for L444P was confirmed on the DNA of parents. The variant L444P is described according to the traditional amino acid residue numbering, which excludes the first 39 amino acids of the leader sequence and, therefore, is reported without the prefix "p". GBA GenBank accession: NM_000157.3 NP_000148.2.
[c]Age at assay.

phenotypes have been observed in patients homozygous for L444P.[8,9] Hence, long-term neurological follow-up will be necessary to finally determine the phenotype, whether type 1 or type 3, in this young patient.

MOLECULAR STUDIES

Genomic DNA, collected after patients had provided written informed consent, was extracted from peripheral blood by using standard methods.[10] Mutation L444P (c.1448T > C) was confirmed by *Nci*I restriction endonuclease digestion and by sequencing duplicate PCR products; this testing also excluded the c.1448T > G (L444R) mutation. To detect possible recombinant alleles, long-template PCR was carried out by amplifying the *GBA* gene and pseudogene (intron 1-exon 11) using an Expand-Long-PCR-System (Boehringer, Mannheim, Germany), as previously reported.[11]

To compare the published haplotypes of Polish patients[7] with those of the patients from Southern Italy, long-template PCR products were amplified using two sets of *GBA*-specific primers. Sequencing analysis excluded the presence of the intronic variants g.3002G > A, g.3715G > C, g.4179A > G, g.6021A > C, g.7031A > G and g.5332C > T (*GBA* GenBank: J03059.1) previously found to be associated with c.1448T > C (L444P) on the Polish patient alleles.[7]

To investigate a potential founder effect in our series of patients, the haplotype analysis was also extended to the 142 intronic single-nucleotide polymorphisms reported in the Ensembl database (http://www.ensembl.org/index.html), but no single-nucleotide polymorphisms were identified.

DISCUSSION

The cohort of patients followed at our department, the Rare Disease Regional Centre located in the Calabria Region (in Southern Italy), consists of eight patients: three sisters belonging to one family with type 1 GD and five patients belonging to four families with type 3 GD. Interestingly, we have noticed that the clinical manifestations of the type 3 GD patients from Calabria were similar to those described in the Norrbottnian-derived Swedish GD population. In particular, the skeletal involvement, characterized by a severe progressive thoracic kyphosis, absence of bone crises and significant bone pain, along with the mild cognitive impairment in the four patients of the present study, have greater similarity to those

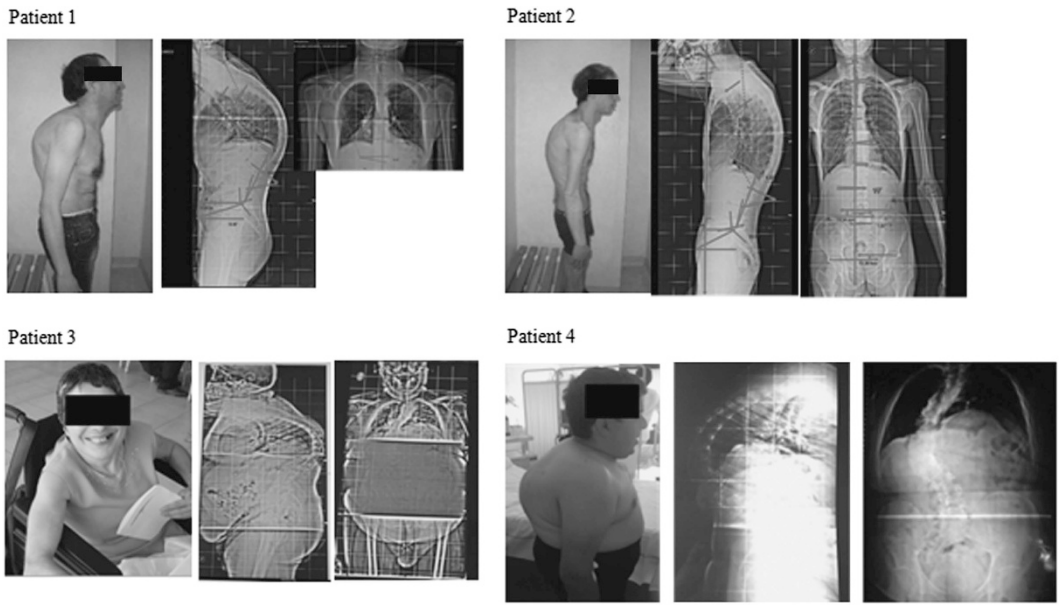

Figure 2 Progressive kyphoscoliosis and chest deformity observed in the four adult patients. A full color version of this figure is available at the *Journal of Human Genetics* journal online.

described in both Swedish and Polish population compared with other GD Norrbottnian-variant patients with different ancestry.[4–7] Even the neurological signs appeared to follow the same progression as reported in the Swedish Norrbottnian patients.

Evidence of the close phenotypic similarity among Swedish, Polish and Southern Italian populations led us to investigate whether the [L444P]+[L444P] genotype is on a common haplotype background. Because the haplotype of the Swedish patients was not available in the literature, we compared the haplotype of the patients of the present study with the only available haplotype previously described in homozygous L444P Polish patients.[7] The analysis, showing a haplotype diversity among the two populations, excluded a common ancestry of the present patients with ethnic Poles. Our results, however, cannot exclude that some correlation might still exist among Southern Italian and Swedish Norrbottnian GD patients.

The haplotype analysis of the patients from Calabria, which was extended to 142 intronic single-nucleotide polymorphisms, showed that no other variants were present on the L444P allele. These findings probably exclude a potential founder effect in this geographical area.

Clearly, genotype [L444P]+[L444P] is prevalent in the Southern Italy. Indeed, the data from the Gaslini Laboratory, one of the Italian reference centers for GD diagnostics, showed that among the 275 GD patients analysed, 26 out of 44 with the type 3 form (59%) were homozygous for the L444P variant and that 19/26 (73%) came from Southern Italy. Italian data regarding the type 3 GD genotype appeared to be in line with those obtained from the Neurological Outcomes Subregistry of the International Collaborative Gaucher Group (ICGG) Gaucher Registry showing that 76 out of 108 patients (70%) with Neuronopathic GD were homozygous for L444P.[12]

Given that mutations in the human *GBA* gene can be considered to be the strongest genetic predisposing factor for Parkinson's disease in all populations without a strong gene dosage effect,[13] obligate carriers of *GBA* mutations, potentially at risk for parkinsonism were searched and studied in the pedigrees of the patients described but no significant evidence was uncovered.

Responses to the treatment described in type 3 GD patients are highly variable. Altarescu *et al.*[14] have observed that among 21 type 3 GD patients (13 homozygous for L444P variant), cognitive function remained stable or improved over time in 13 patients but declined in 8 patients. Tajima *et al.*[8] have described the long-term follow-up (9–15 years) of the treatment of 10 patients with the homozygous L444P variant, 4 of whom had mental retardation. Kraoua *et al.*[15] have found that ERT prevented the evolution of neurological symptoms in four GD patients with the homozygous L444P variant. More recently, Sechi *et al.*[16] have reported the clinical and neurological outcomes of 10 type 3 GD patients who received regular ERT infusions for up to 21 years. Their data confirm that ERT improves the systemic manifestations of type 3GD but suggest that it does not prevent the progression of neurological symptoms in the long term.

In the pre-ERT era, 50% of Norrbottnian type 3 GD patients homozygous for the L444P variant died before age 12.[4] Today, treated patients respond to ERT with increased well-being.[17] In addition, long-term effects of ERT slowing down further neurological and mental deterioration have been observed in the eight patients from the Norrbottnian cohort.[18]

Disappointingly, however, no improvements in neurological or skeletal manifestations have been observed over time in the patients, even after many years of ERT. The progression of neurological symptoms in these patients probably reflects the neurological natural history of type 3GD and the inability of intravenous-administered ERT to cross the blood-brain barrier in significant amounts; thus, there is little, if any, effect on central nervous system parenchymal involvement.[14] In addition, kyphosis, the main skeletal manifestation in our GD patients, continues to deteriorate during ERT, probably because of its possible neurological basis and/or previous splenectomies in the patients. Another clinical feature that does not appear to benefit from ERT is interstitial lung disease. Indeed, it has been hypothesized that homozygosity for the variant L444P is associated with a major risk of developing intrinsic pulmonary involvement.[19] In these patients, primary lung disease appeared to occur at an early age and was not related to the duration of enzymatic therapy.

CONFLICT OF INTEREST

The authors declare no conflict of interest.

ACKNOWLEDGEMENTS

The patient samples were obtained from the 'Cell Line and DNA Biobank from patients affected by Genetic Diseases' (Istituto Giannina Gaslini), a member of the Telethon Network of Genetic Biobanks (project no. GTB12001). This work was partially supported by unrestricted grants from the 'Cinque per mille e Ricerca Corrente, Ministero della Salute.'

1 Beutler, E. & Grabowski, G. A. in: *The Metabolic and Molecular Bases of Inherited Disease* (eds Scriver, C. R., Baudet, A. L., Sly, W. S. & Valle, D.) 3635–3668 (McGraw-Hill, New York, 2001).
2 Charrow, J., Andersson, H. C., Kaplan, P., Kolodny, E. H., Mistry, P., Pastores, G. *et al.* The Gaucher registry: demographics and disease characteristics of 1698 patients with Gaucher disease. *Arch. Intern. Med.* **160**, 2835–2843 (2000).
3 Dahl, N., Hillborg, P. O. & Olofsson, A. Gaucher disease (Norrbottnian type III): probable founders identified by genealogical and molecular studies. *Hum. Genet.* **92**, 513–515 (1993).
4 Dreborg, S., Erikson, A. & Hagberg, B. Gaucher disease–Norrbottnian type. I. General clinical description. *Eur. J. Pediatr.* **133**, 107–118 (1980).
5 Ida, H., Rennart, O. M., Iwasawa, K., Kobayashi, M. & Eto, Y. Clinical and genetic studies of Japanese homozygotes for the Gaucher disease L444P mutation. *Hum. Genet.* **105**, 120–126 (1999).
6 Abdelwahab, M., Blankenship, D. & Schiffmann, R. Long-term follow-up and sudden unexpected death in Gaucher disease type 3 in Egypt. *Neurol. Genet.* **2**, e55 (2016).
7 Tylki-Szymañska, A., Keddache, M. & Grabowski, G. A. Characterization of neuronopathic Gaucher disease among ethnic Poles. *Genet. Med.* **8**, 8–15 (2006).
8 Tajima, A., Yokoi, T., Ariga, M., Ito, T., Kaneshiro, E., Eto, Y. *et al.* Clinical and genetic study of Japanese patients with type 3 Gaucher disease. *Mol. Genet. Metab.* **97**, 272–277 (2009).
9 Goker-Alpan, O., Hruska, K. S., Orvisky, E., Kishnani, P. S., Stubblefield, B. K., Schiffmann, R. *et al.* Divergent phenotypes in Gaucher disease implicate the role of modifiers. *J. Med. Genet.* **42**, e37 (2005).
10 Filocamo, M., Mazzotti, R., Stroppiano, M., Seri, M., Giona, F., Parenti, G. *et al.* Analysis of the glucocerebrosidase gene and mutation profile in 144 Italian Gaucher patients. *Hum. Mutat.* **20**, 234–235 (2002).
11 Filocamo, M., Bonuccelli, G., Mazzotti, R., Giona, F. & Gatti, R. Identification of a novel recombinant allele in three unrelated Italian Gaucher patients: implications for prognosis and genetic counseling. *Blood Cells Mol. Dis.* **26**, 307–311 (2000).
12 Tylki-Szymańska, A., Vellodi, A., El-Beshlawy, A., Cole, J. A. & Kolodny, E. Neuronopathic Gaucher disease: demographic and clinical features of 131 patients enrolled in the International Collaborative Gaucher Group Neurological Outcomes Subregistry. *J. Inherit. Metab. Dis.* **33**, 339–346 (2010).
13 Sidransky, E., Nalls, M. A., Aasly, J. O., Aharon-Peretz, J., Annesi, G., Barbosa, E. R. *et al.* Multicenter analysis of glucocerebrosidase mutations in Parkinsons disease. *N. Engl. J. Med.* **361**, 1651–1661 (2009).
14 Altarescu, G., Hill, S., Wiggs, E., Jeffries, N., Kreps, C., Parker, C. C. *et al.* The efficacy of enzyme replacement therapy in patients with chronic neuronopathic Gaucher's disease. *J. Pediatr.* **138**, 539–547 (2001).
15 Kraoua, I., Sedel, F., Caillaud, C., Froissart, R., Stirnemann, J., Chaurand, G. *et al.* A French experience of type 3 Gaucher disease: phenotypic diversity and neurological outcome of 10 patients. *Brain Dev.* **33**, 131–139 (2011).
16 Sechi, A., Deroma, L., Dardis, A., Ciana, G., Bertin, N., Concolino, D. *et al.* Long term effects of enzyme replacement therapy in an Italian cohort of type 3 Gaucher patients. *Mol. Genet. Metab.* **113,**, 213–218 (2014).
17 Erikson, A., Astrom, M. & Mansson, J. E. Enzyme infusion therapy of the Norrbottnian (type 3) Gaucher disease. *Neuropediatrics* **26**, 203–207 (1995).
18 Erikson, A., Forsberg, H., Nilsson, M., Aström, M. & Månsson, J. E. Ten years' experience of enzyme infusion therapy of Norrbottnian (type 3) Gaucher disease. *Acta Paediatr.* **95**, 312–317 (2006).
19 Santamaria, F., Parenti, G., Guidi, G., Filocamo, M., Strisciuglio, P., Grillo, G. *et al.* Pulmonary manifestations of Gaucher disease: an increased risk for L444P homozygotes? *Am. J. Respir. Crit. Care Med.* **157**, 985–989 (1998).
20 Raghavan, S. S., Topol, J. & Kolodny, E. H. Leukocyte beta-glucosidase in homozygotes and heterozygotes for Gaucher disease. *Am. J. Hum. Genet.* **32**, 158–173 (1980).