Journal of Human Genetics (2015) 60, 769–776

www.nature.com/jhg

ORIGINAL ARTICLE

A pilot study of gene testing of genetic bone dysplasia using targeted next-generation sequencing

Huiwen Zhang, Rui Yang, Yu Wang, Jun Ye, Lianshu Han, Wenjuan Qiu and Xuefan Gu

Molecular diagnosis of genetic bone dysplasia is challenging for non-expert. A targeted next-generation sequencing technology was applied to identify the underlying molecular mechanism of bone dysplasia and evaluate the contribution of these genes to patients with bone dysplasia encountered in pediatric endocrinology. A group of unrelated patients ($n = 82$), characterized by short stature, dysmorphology and X-ray abnormalities, of which mucopolysacharidoses, GM1 gangliosidosis, mucolipidosis type II/III and achondroplasia owing to *FGFR3* G380R mutation had been excluded, were recruited in this study. Probes were designed to 61 genes selected according to the nosology and classification of genetic skeletal disorders of 2010 by Illumina's online DesignStudio software. DNA was hybridized with probes and then a library was established following the standard Illumina protocols. Amplicon library was sequenced on a MiSeq sequencing system and the data were analyzed by MiSeq Reporter. Mutations of 13 different genes were found in 44 of the 82 patients (54%). Mutations of *COL2A1* gene and *PHEX* gene were found in nine patients, respectively (9/44 = 20%), followed by *COMP* gene in 8 (18%), *TRPV4* gene in 4 (9%), *FBN1* gene in 4 (9%), *COL1A1* gene in 3 (6%) and *COL11A1, TRAPPC2, MATN3, ARSE, TRPS1, SMARCAL1, ENPP1* gene mutations in one patient each (2% each). In conclusion, mutations of *COL2A1, PHEX* and *COMP* gene are common for short stature due to bone dysplasia in outpatient clinics in pediatric endocrinology. Targeted next-generation sequencing is an efficient way to identify the underlying molecular mechanism of genetic bone dysplasia.
Journal of Human Genetics (2015) **60,** 769–776; doi:10.1038/jhg.2015.112; published online 17 September 2015

INTRODUCTION

Genetic bone dysplasia is a clinically and genetically heterogeneous group with over 400 conditions under the new nosology in 2010.[1] After that, more genes involved in bone dysplasia had been identified.[2,3] Correct clinical diagnoses of a few of them which are having distinct characters are relatively easy, such as achondroplasia, osteogenesis imperfecta, Marfan syndrome, hypophosphatemic ricket and muco polysaccharidosis, while most of the others are difficult to group for the non-expert owing to high similarities of phenotypes among themselves. Thus, collaboration between local medical staff with expert diagnostic network is necessary to reach a diagnosis for difficult cases.[4]

As for the molecular confirmation of genetic bone dysplasia, it is even more complex. On one side, mutations of one gene can cause multiple phenotypes, for example, *COL2A1* mutations could cause a spectrum of phenotypes, ranging from premature arthritis to perinatally lethal disorder.[5] On the other side, one similar clinical phenotype can result from mutations of different genes, for example, in the case of multiple epiphyseal dysplasia, autosomal dominance of them may be owing to mutations of *COMP*, *MATN3*, *COL9A1*, *COL9A2* or *COL9A3*, and autosomal recessive pattern is because of *SLC26A2* gene mutations.[6]

As a group, bone dysplasia is very common with an estimated occurrence 1:1000. Most of them manifest as short stature and limb abnormalities, which are two common reasons for referral to pediatric endocrinology.[7,8] Pediatricians treat larger number of patients with bone dysplasia than 20 years ago.[9] Treatment with growth hormone for achondroplasia is approved in Japan. Bisphosphonate has been in off-label use for children with osteogenesis imperfecta in the past ten years. Statin treatment can rescue patient-specific induced pluripotent stem cell models and a mouse model of FGFR3 skeletal dysplasia, thus statin may be a new drug to treat FGFR3-related bone dysplasia.[10] Accurate molecular diagnosis of the bone dysplasia is increasingly important for possible treatment options and genetic counseling.

Owing to the high number of genes and the large size of each gene associated with most of these disorders, standard diagnostic testing using Sanger sequencing are expensive and time consuming. However, this shortage of Sanger sequencing could be overcome by targeted next-generation sequencing (NGS) technologies. With genomic capturing known genes, whose mutation cause bone dysplasia leading to short stature or dysmorphology, it is possible to screen those genes in the suspected patients in high throughput by NGS.

In China, there have been no population-based studies and most bone dysplasias have been reported as case reports with mutations identified in a few of them (1.16%).[11] In this study, we performed a comprehensive mutation screening of genes in a large cohort of children suspected with bone dysplasia using the targeted NGS.

Pediatric Endocrinology and Genetic Metabolism, Xinhua Hospital, Shanghai Institute for Pediatric Research, Shanghai Jiao Tong University School of Medicine, Shanghai, China
Correspondence: Dr H Zhang or Dr X Gu, Pediatric Endocrinology and Genetic Metabolism, Xinhua Hospital, Shanghai Institute for Pediatric Research, Shanghai Jiao Tong University School of Medicine, Kongjiang Road #1665, Shanghai 200092, China.
E-mail:huiwenzhang@yahoo.com or gu_xuefan@163.com
Received 10 April 2015; revised 13 August 2015; accepted 21 August 2015; published online 17 September 2015

Our results provided a preliminary overview of the genetic etiology of bone dysplasia in Chinese children seen in the pediatric endocrinology department.

SUBJECTS AND METHODS

Study subjects

This study has been approved by Ethics Committee of Shanghai Xinhua Hospital (XHEC-D-2014-006). A group of unrelated patients ($n=89$) characterized by short stature, bone dysmorphology and X-ray abnormalities in our outpatient clinics were included. Among them, 55 cases were male, the other 34 cases were female, and the average age was 5.3 years old (range 8 months to 17 years). This cohort of individuals included one patient with achondroplasia with *FGFR3* G380R mutation as positive control and six patients with confirmed diseases as negative control, for example, two patients with mucolipidosis type II/III; one with mucopolysacharidosis type I, IIIA and IVA each; and one with tyrosinemia type I who had secondary hypophosphatemia. For the rest 82 patients, mucopolysaccharidoses, GM1 gangliosidosis, and mucolipidosis type II/III have been pre-excluded by peripheral leukocytes or plasma lysosomal enzyme activity measurements. Typical patients with achondroplasia derived from *FGFR3* G380R mutation, a common reason of dwarfism in humans, had been pre-excluded by Sanger sequencing with primers specific to this site. This cohort of patients included 13 patients with hypophosphatemic rickets and three patients with osteogenesis imperfecta. The rest of them had no clear and confident clinical diagnosis.

Targeted exon capturing and NGS

Custom probes with amplicon size 425 bp targeted 61 bone dysplasia-related genes according to the 2010 nosology and classification of genetic skeletal disorders (Supplementary Table 1) were designed with Illumina's online DesignStudio software.[1] As a department of pediatric endocrinology, we pay more attention to genes related with short stature. Although *FBN1* gene belonged to group 30 overgrowth syndromes in the 2010 Nosology,[1] it also has been demonstrated to be the causative gene of acromelic dysplasia.[12] So *FBN1* gene was included, along with *FBN2* gene to investigate whether it is associated with other bone dysplasia besides congenital contractural arachnodactyly. As other site mutations of *FGFR3* gene besides G380R can also lead to bone dysplasia, this gene was still included in our targeted gene list. A total of 1292 exons and 182 675 bases were targeted. With setting of the probe parameters, the overall coverage of gene exons is 87.5%.

Genomic DNA was extracted from peripheral blood according to the manufacturer's protocol with the RelaxGene blood DNA isolation kit (Tiangen Biotech, Beijing, China). DNA with a concentration of 300 ng μl^{-1} was hybridized with probes. A library was established following the standard Illumina protocols, which was then sequenced on a MiSeq sequencing system (Illumina, San Diego, CA, USA). Data were analyzed by MiSeq Reporter. Reads were aligned to the NCBI37/hg19 assembly using the BWA Multi-Vision software package with single-nucleotide polymorphisms and indels identified using the SOAPsnp software and the GATK Indel Genotyper, respectively.

PCR and Sanger sequencing

Potential novel mutations identified by NGS were further verified by polymerase chain reaction with site-specific primers and Sanger sequencing. Parents of probands were also checked whether they carried the same mutations.

Pathogenicity evaluation of novel variants

The novel variants were interpreted according to the 2015 American College of Medical Genetics and Genomics standards and guidelines.[13] Glycine substitutions in the triple-helical domain G-X-Y of the *COL2A1* gene were presumed to be a moderate evidence of pathogenicity. Matching of genotypes with its phenotypes and co-segregation with disease status in family gene analysis are two required supporting evidence of pathogenicity. Null mutations including insertion, deletion, splicing and stop codon changes were regarded as a very strong evidence of pathogenicity. MutationTaster (http://www.mutationtaster.org/) and PolyPhen-2 (http://genetics.bwh.harvard.edu/pph2/index.shtml) for amino acid substitution were applied to evaluate the variation pathogenicities. The predicted result 'disease-causing' by MutationTaster and 'probably/possibly damaging' by PolyPhen-2, indicated that these variations had two lines of computational evidence supporting a pathogenic effect. Missense variants are common mechanism of X-linked recessive Chondrodysplasia punctata.[14] Thus, a missense variant of the *ARSE* gene is a supporting evidence of pathogenicity. Furthermore, the presumed pathogenic or likely pathogenic variants should not be a previously reported single-nucleotide polymorphism or polymorphisms.

RESULTS

The average sequencing depth was 96.8 and the sequencing depth over the region of interest was 84.7. As expected, no pathogenic variations had been identified in the targeted 61 genes in the six patients with confirmed other bone diseases, which were regarded as negative controls in this pilot study. In the achondroplasia patient, who was treated as positive control, G380R mutation in *FGFR3* gene was identified, consistent with his previous diagnosis by Sanger sequencing.

Totally 44 of the 82 patients (54%) had confirmed mutations, including nine patients with type II collagenopathy (Table 1), nine with *PHEX*-mutated X-linked hypophosphataemic rickets (Table 2), eight with *COMP* gene mutations (Table 3), four with *TRPV4* gene mutation, four with *FBN1*-related acromelic dysplasia[15] and three with *COL1A1*-mutated osteogenesis imperfecta. In addition, mutations of *COL11A1, TRAPPC2, MATN3, ARSE, TRPS1, SMARCAL1 and ENPP1* gene were identified in one patient each (Table 4). In all, mutations in 13 different genes were found from our targeted list involved in bone

Table 1 Patient characteristics with confirmed *COL2A1* gene mutations in our study

No.	Presenting age (years)	Gender	Mutation	AA changes	Novelty	MutationTaster	PolyPhen-2 (score)	Disease	Genetic mode
1	7	Male	c.4167delC	p.I1389fs	Novel	Disease causing	Unsuitable	SEDC	*De novo*
2	2	Male	c.3248G>A	p.G1083D	Novel	Disease causing	Probably damaging (0.999)	SEDC	Inherited from father
3	5	Female	c.2131G>C	p.G711R	Novel	Disease causing	Probably damaging (0.999)	SEMD, Strudwick	*De novo*
4	9	Male	c.1681G>A	p.G561S	Novel	Disease causing	Probably damaging (1.0)	SEDC	*De novo*
5	8.5	Male	c.1511G>C	p.G504A[a]	Novel	Disease causing	Probably damaging (0.996)	SEDC	Inherited from father
6	0.8	Female	c.3121G>A	p.G1041S	Known			SEMD, Strudwick[25]	*De novo*
7	7	Male	c.2965CT	p.R989C	Known			SEDC[26]	*De novo*
8	9	Male	c.1510G>A	p.G504S	Known			SEDC[27]	*De novo*
9	2.5	Female	c.1339G>A	p.G447S	Known			SEDC[28]	*De novo*

Abbreviations: SEDC, spondyloepiphyseal dysplasia congenita; SEMD, spondyloepimetaphyseal dysplasia.
[a]Different amino acid variation(s) reported at the same codon.

Table 2 Patient characteristics with confirmed mutations in *PHEX* gene

No.	Presenting age (years)	Gender	Mutation	AA changes	Novelty	Genetic mode
1	1.3	Female	c.958_960del3	p.del317K	Novel	*De novo*
2	6	Male	c.208_212del5	p.V70SfsX7	Novel	*De novo*
3	2.5	Male	c.1491_1509 del19	p.F497LfsX11	Novel	*De novo*
4	1	Male	c.1208G>A	p.E403X	Known[29]	Inherited from mother
5	0.8	Male	c.1543C>T	p.Q515X	Known[30]	*De novo*
6	1	Female	c.1302+1G>A	Splicing	Known	Inherited from mother
7	5.6	Female	c.1657G>T	p.G553X	Known	Inherited from mother
8	1	Male	c.842 T>A	p.I281K	Known	*De novo*
9	2	Female	c.2104C>T	p.R702X	Known[29]	*De novo*

Table 3 Patient characteristics with confirmed *COMP* gene mutations in our study

No.	Presenting age (years)	Gender	Mutation	AA changes	Novelty	MutationTaster	PolyPhen-2 (score)	Disease	Inheritance
1	7	Female	c.1316A>G	p.D439G[a]	Novel	Disease causing	Probably damaging (1.0)	MED	*De novo*
2	5	Male	c.1585A>G	p.T529A[a]	Novel	Disease causing	Possibly damaging (0.817)	PSACH	*De novo*
3	5.6	Female	c.1526A>T	p.D509V[a]	Novel	Disease causing	Probably damaging (1.0)	PSACH	*De novo*
4	4.9	Male	c.G1423C	p.D475H[a]	Novel	Disease causing	Probably damaging (1.0)	PSACH	*De novo*
5	2.2	Male	c.1526A>G	p.D509G	Known			PSACH[31]	*De novo*
6	2.5	Male	c.1526A>G	p.D509G	Known			PSACH[31]	*De novo*
7	2	Male	c.G1417C	p.D473H	Known			PSACH[6]	*De novo*
8	3	Female	c.1417_1419del3	p.473del	Known			PSACH[31]	*De novo*

Abbreviations: MED, multiple epiphyseal dysplasia; PSACH, pseudoachondroplasia.
[a]Different amino acid variation(s) reported at the same codon.

dysplasia. It has been the first time that Chinese cases of group 8, *TRPV4* group, and group 21, chondrodysplasia punctata, are being reported.[11]

There were only two patients with an autosomal recessive mode, which were hypophosphataemic rickets caused by biallelic mutations in *ENPP1* gene and Schimke immuno-osseous dysplasia caused by a homozygous mutation in *SMARCAL1* gene (Table 4). Most cases were sporadic. In only seven cases (7/44 = 16%), the mutation were familial, of which two cases with *COL2A1* mutations were derived from their respective father, one case with *COL11A1* mutation from the proband's mother, one case with an *ARSE* mutation derived from the proband's mother and three cases with *PHEX* mutations from their mother, respectively. Except the mother with heterozygous *ARSE* mutation being asymptomatic, the other parents with dominant inheritance mode were symptomatic and showed very similar clinical phenotypes with the proband.

In view of the novelty of mutations, we could see that nearly half of them (23/44 = 52.3%) were reported previously and the other half (21/44 = 47.7%) were novel. The novel variants were evaluated as pathogenic or highly pathogenic according to the joint consensus recommendations for the interpretation of sequence variants of American College of Medical Genetics and Genomics.[13] For example, p.G711R (No 3, Table 1) was a *de novo* variant based on family-based gene analysis, which was a strong evidence of pathogenicity. Furthermore, it was located with the well-established functional domain glycine of G-X-Y, and was absent in 1000 Genomes Project, which were two moderate evidences of pathogenicity. In addition, two lines of computational analysis (MutationTaster and PolyPhen-2) that supported p.G711R had a deleterious effect and the patient's phenotype was highly specific for spondyloepimetaphyseal dysplasia, Strudwick type (provided in the Discussion), which were two supporting evidences of pathogenicity. Totally, this variant has one strong, two moderate and two supporting evidences of pathogenicity, which support it pathogenically, according to the rules for combining criteria to classify sequence variants.[13] The evaluation of other novel variants was provided as Supplementary Table 2 except for three *FBN1* variants, which were reported previously.[15]

DISCUSSION

In this pilot study, type II collagenopathy is a common disorder in our cohort including seven cases with spondyloepiphyseal dysplasia congenita (SEDC) and two cases with spondyloepimetaphyseal dysplasia, Strudwick type. COL2A1 mutations may give rise to a spectrum of phenotypes, spanning from the mild late-onset premature arthritis to the severe intrauterine achondrogenesis.[5] The prevalent *COL2A1*-related SEDC of this study may be explained by our unique subject collection in pediatric endocrinology, where a large number of patients seek help for short stature. Otherwise, it may be explained that *COL2A1* gene mutations usually cause SEDC, as two-thirds were classified to SEDC in a large multinational study where 93 patients

Table 4 Genes with a small number of patients having mutations

No.	Genes	Mutation	AA changes	Novelty	MutationTaster	PolyPhen-2 (Score)	Disease	Genetic mode
1	*TRPV4*	c.1799G>A	p.G600E	Novel	Disease causing	Probably damaging (1.0)	SMD, Kozlowski type	*De novo*
2	*TRPV4*	c.1849T>C	p.F617L[a]	Novel	Disease causing	Probably damaging (1.0)	Metatropic dysplasia[32]	*De novo*
3	*TRPV4*	c.1781G>A	p.R594H	Known			SMD, Kozlowski type[22]	*De novo*
4	*TRPV4*	c.1781G>A	p.R594H	Known			SMD, Kozlowski type[22]	*De novo*
5	*COL1A1*	c.658C>T	p.R220X	Known			OI type I[20]	*De novo*
6	*COL1A1*	c.769G>A	p.G257R	Known			OI type I[33]	*De novo*
7	*COL1A1*	c.2299G>A	p.G767S	Known			OI type III[26]	*De novo*
8	*MATN3*	c.362G>A	p.R121Q[b]	Novel	Disease causing	Probably damaging (0.995)	MED	*De novo*
9	*COL11A1*	c.1245 +1G>A	Splicing	Novel	Disease causing	Unsuitable	Stickler syndrome	Inherited from mother
10	*TRAPPC2*	IVS3+5G/A	Splicing	Known			Spondyloepiphyseal dysplasia tarda[34]	*De novo*
11	*ARSE*	c.1180C>T	p.R394C	Novel	Disease causing	Probably damaging (0.999)	X-linked recessive Chondrodysplasia punctata	Mother was carrier
12	*TRPS1*	c.1630C>T	p.R544X	Known			Tricho-rhino-phalangeal syndrome type 1[35]	*De novo*
13	*SMARCAL1*	c.670C>T	p.Q224X	Novel	Disease causing	Unsuitable	Schimke immuno-osseous dysplasia	Homozygous
14	*ENPP1*	c.749C>T c.783C>G	p.P250L p.Y261X	Known Known			AR hypophosphataemic rickets	
15	*FBN1*	c.5198G>A	p.C1733Y	Known			Geleophysic dysplasia[12]	*De novo*
16	*FBN1*	c.5189A>T	p.N1730I	Novel	Disease causing	Probably damaging (0.984)	Geleophysic dysplasia[15]	*De novo*
17	*FBN1*	c.5198G>T	p.C1733F	Novel	Disease causing	Probably damaging (0.996)	Acromicric dysplasia[15]	*De novo*
18	*FBN1*	c.5243G>T	p.C1748F	Novel	Disease causing	Probably damaging (0.992)	Weill-Marchesani syndrome[15]	*De novo*

Abbreviations: MED, multiple epiphyseal dysplasia; OI, osteogenesis imperfecta; SMD, spondylometaphyseal dysplasia.
[a]Same amino acid change with different nucleotide change.
[b]Different amino acid variation(s) reported at the same codon.

with type II collagenopathy were reported.[16] There were five novel mutations and four known mutations with seven of them involved with glycine substitution in the triple-helical domain, which was consistent with previous result that glycine substitutions are the most common types of mutation.[16,17]

Thirteen patients with hypophosphatemic rickets were recruited in this study. Mutations in *PHEX* gene were identified in nine of them, and mutations on both the alleles in *ENPP1* gene were identified in one patient. No mutations were identified in *FGF23*, *DMMP1*, *SLC34A3* or *CLCN5*, which indicated that *PHEX* gene mutation was also the predominant cause of hypophosphatemic rickets in Chinese patients. A girl without family history and another girl whose mother has similar bone dysplasia, indicating an apparent dominant trait, revealed no mutations of six known genes related to hypophosphatemia, for example, *PHEX*, *FGF23*, *DMP1*, *ENPP1*, *CLCN5* and *SLC34A3*. As a multiplex ligation-dependent probe amplification analysis was an indispensable supplementary to detect larger deletions/duplications in *PHEX* or *FGF23* gene,[18] these two girls should be further analyzed by multiplex ligation-dependent probe amplification method. In one male child, the hypophosphatemia was secondary to kidney involvement of tyrosinemia type I. In another female child, the hypophosphatemia was secondary to renal tubule pathology of kidney.

For the *COMP*-related bone dysplasia, seven out of eight subjects were assigned to pseudoachondroplasia with one assigned to multiple epiphyseal dysplasia (MED). At the molecular level, there are three known mutations in four patients and four novel mutations with one occurrence each, for example, T529A, D509V, D475H and D439G. At all these four codons, different nucleotide transversions or transitions causing different amino acid substitutions had been reported with consistent clinical diagnosis.[19,20]

For unknown reasons, only a few of Chinese MED patients were reported.[11] Mutation p.R121Q in the *MATN3* gene was identified in one subject assigned to MED. At the same codon of the *MATN3* gene, another mutation R121W has been reported to be causative to MED.[21] Thus, our cohort of patients contained only two patients with confirmed MED at the molecular level, caused by *COMP* and *MATN3* gene, respectively. The rarity of MED in this cohort of study could be partially explained given that most people with MED have normal or mildly short stature. It was also possible that there is a low occurrence of MED in Chinese ethnics.

Furthermore, there were four cases with *TRPV4* gene mutation, which constituted 9% (4/44) of individuals with confirmed gene mutation, indicating *TRPV4* gene is a relatively common cause of bone dysplasia in Chinese. In accordance with previous findings,[22] two of these four patients carried the hot mutation R594H of *TRPV4* gene. On the basis of the clinical and radiological characters, three of them were diagnosed with spondylometaphyseal dysplasia Kozlowski type, and one with metatropic dysplasia.

Only one patient with type 11 collagen group has been identified. As most mutations were reported on *COL11A1* gene,[23] this novel mutation c.1245+1G>A also altered the splicing consensus sequences.

As stated, most confirmed cases in this cohort had been diagnosed only after the availability of genetic analysis by targeted NGS, such as *ARSE*-associated X-linked recessive chondrodysplasia punctata, *TRPV4*-related spondylometaphyseal dysplasia, type II collagenopathy and *FBN1*-associated acromelic dysplasia. We previously have reported the clinical characteristics of patients with *FBN1*-associated acromelic dysplasia.[15] Here we provided the clinical and radiographic characteristics of some patients with other confirmed genetic diagnosis.

The boy with *ARSE*-associated X-linked recessive chondrodysplasia punctata (No. 11 in Table 4) presented to our clinics for disability to raise head and macrocephaly at 5 months of age. He was the second baby of an unconsanguineous young couple. His old sister was healthy. As a fetus, he was found to have a comparatively larger head by ultrasound. He was spontaneously delivered at term with birth weight 3.7 kg (1 s.d.) and birth length 52 cm (1 s.d.) with head circumference 39 cm (4 s.d.). The physical examination on presenting to our clinic included a squared skull with the head circumference 46.5 cm (4 s.d.) and the anterior fontanel 4x4 cm, and length 66 cm (−1 s.d.) and weight 7 kg (−1.5 s.d.). Brain MRI revealed a small posterior fossa. Interestingly, retrospective review of the images of spine, pelvic, humeri and femurs taken at the age of 5 months did not show characteristic stippled epiphyses (Figure 1). However, imaging of distal phalanges was not properly taken, where chondrodysplasia punctata were frequently noted.[24] When re-examined at the age of 27 months, a depressed nasal bridge, a small nose and chin and ichthyosis on the dorsal skin of forearm and hand were observed. The anterior fontanel was still open with size 2.5 × 2 cm. He could not walk independently yet, neither could he utter meaningful words.

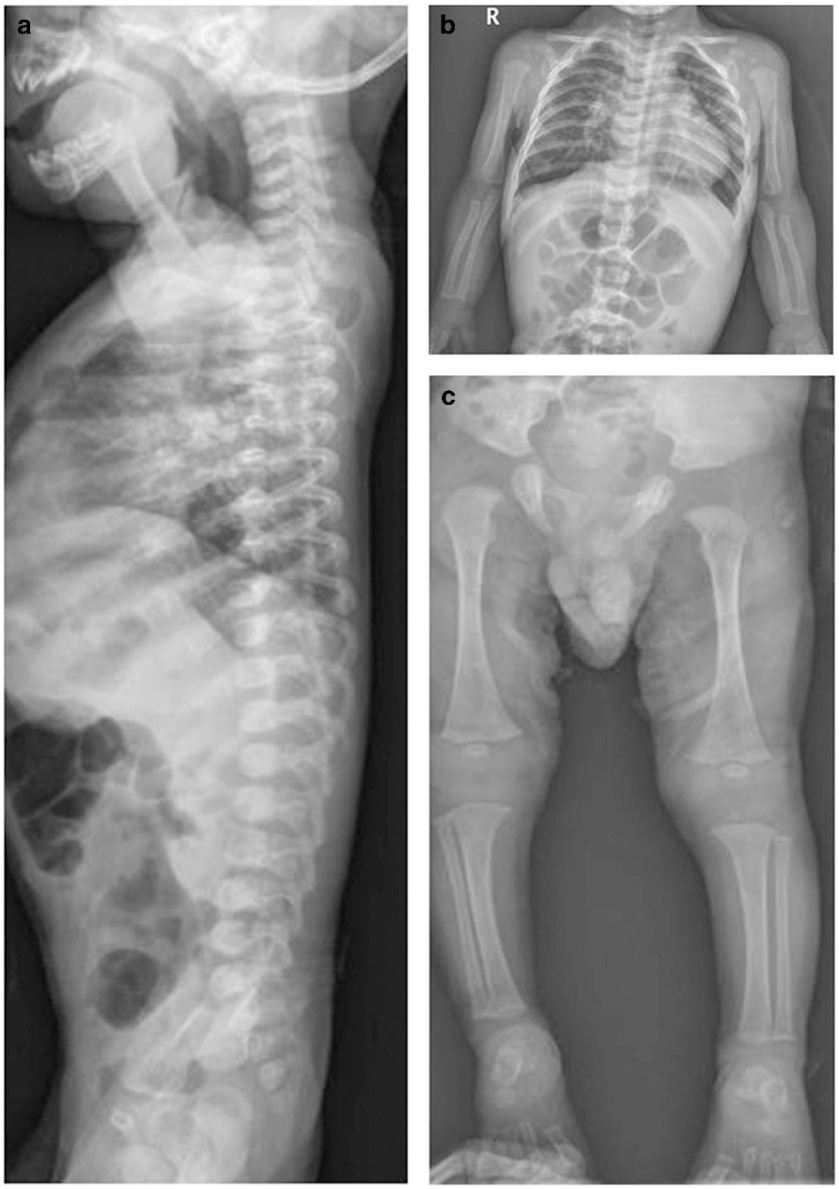

Figure 1 Radiographs of a boy with X-linked chondrodysplasia punctata. The bone epiphyses (**a**, lateral view of spine; **b**, upper limbs and chest; **c**, pelvis and lower limbs) taken at the age of 5 months did not show signs of stipples.

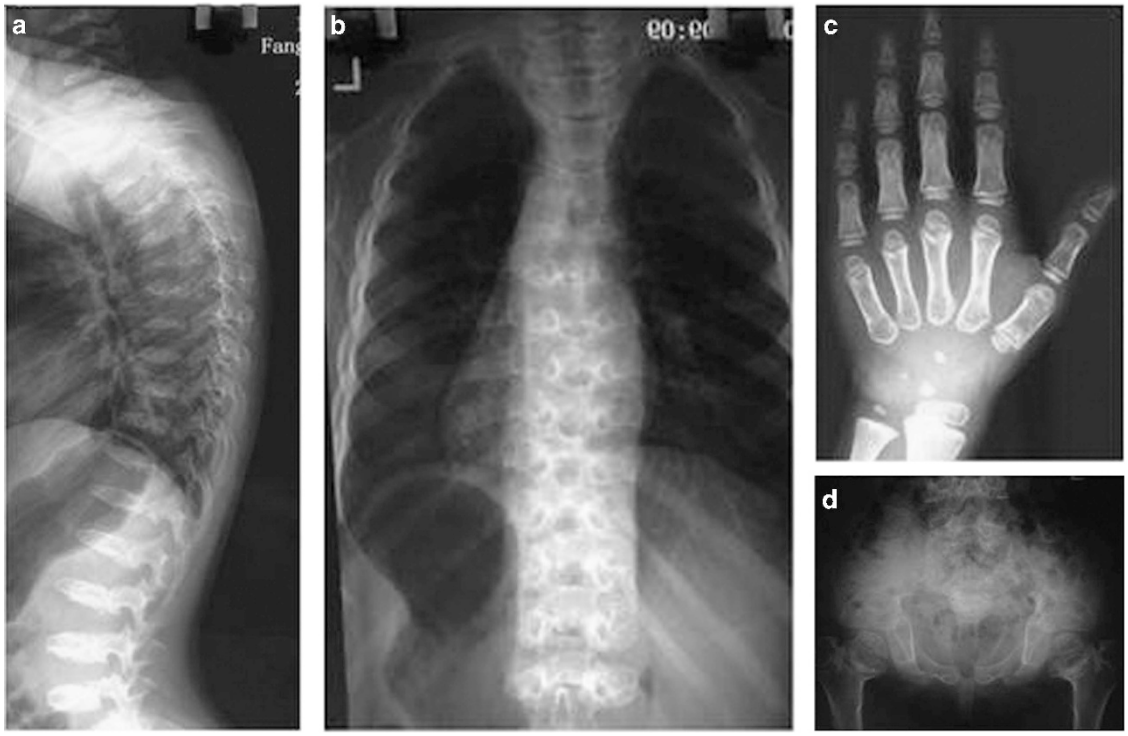

Figure 2 Radiographs of a girl with *TRPV4*-related spondylometaphyseal dysplasia. (**a**) Lateral view of the spine showed platyspondyly; (**b**) chest radiography showed mild oar-shaped ribs; (**c**) delayed carpal bone ossification in the left hand; (**d**) broad and short femoral neck indicated metaphyseal dysplasia. All the pictures were taken at the age of 4 years 5 months.

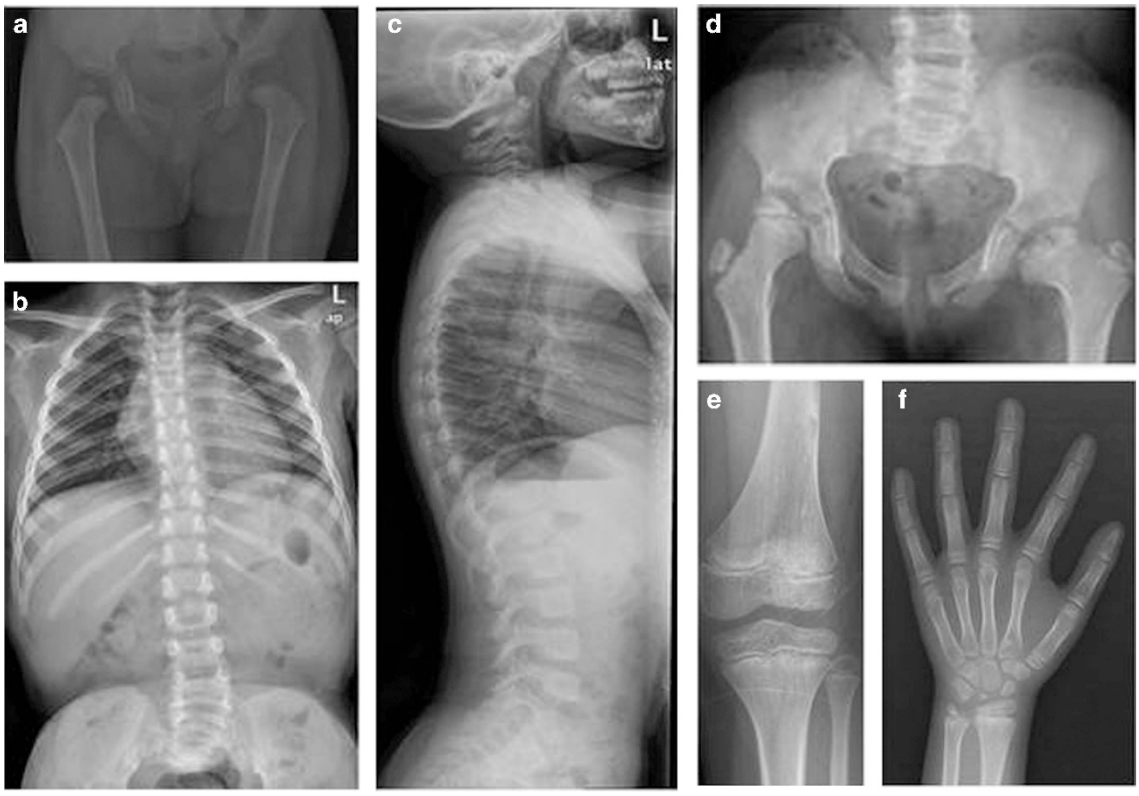

Figure 3 Radiographs of a girl with *COL2A1*-related spondyloepimetaphyseal dysplasia, Strudwick type. Hip at the age of 2 years showed ossification absence of epiphyseal center of left proximal femurs (**a**); imaging taken at 5 years old showed oar-shaped ribs (**b**) and the marked thoracic vertebral dysplasia in the lateral view of spine (**c**); imaging taken at 8 years old showed small and fragmented epiphyseal centers of both proximal femurs (**d**), and irregular metaphyses of left femur, tibia, fibula (**e**) and radius and ulna (**f**).

One patient with R594H mutation in *TRPV4* gene was a girl aged 4 years 5 months (No. 3 in Table 4), who had growth retardation in the past 2 years. As the lateral view of the spine was misinterpreted as bullet-shaped and ribs were likely oar-shaped (Figures 2a and b), she was referred to us for mucopolysaccharidosis-related lysosomal enzymatic assay. On physical examination, she was 99 cm (−2 s.d.) in height and 15.5 kg in weight (−1 s.d.). Neither did she have a coarse face, nor a tight or relaxed joint. Her teeth were also normal. However, she had a mild protruding sternum and a mild lumbar lordosis. All the tested lysosomal enzyme activities were normal. After identification of the R594H mutation of *TRPV4* gene, her X-rays were reviewed retrospectively, and platyspondyly (Figure 2a), delayed carpal bone ossification (Figure 2c) and short femoral neck (Figure 2d) were identified, which was consistent with the characteristics of spondylometaphyseal dysplasia, Kozlowski type. Without the result of NGS, we could not correctly diagnose this patient.

The girl (No. 3 in Table 1) with G711R mutation in *COL2A1* gene went to our clinic at the age of 5 years for short stature and wadding gait. On physical examination, she was 91.3 cm (−5 s.d.) in height and 14 kg in weight (−2 s.d.) and had a mild pectus carinatum. She had visited an orthopedic surgeon for shortness of left leg compared with her right leg at the age of 2 years when a pelvic radiogram indicating ossification, absence of epiphyseal center of left proximal femurs (Figure 3a). The paddle-shaped ribs (Figure 3b) and abnormal lateral view of spine (Figure 3c) had prompted the patients to take the lysosomal enzyme tests, which were unremarkable. He was then followed at the age of 8 years (Figures 3d–f). On the whole, the radiograph of this patient was in line with spondyloepimetaphyseal dysplasia, Strudwick.

In this study, nearly half the patients were without a clear diagnosis, which may be further investigated by whole-exome sequencing. With more patients getting precise molecular diagnosis, we can have a more accurate disease spectrum on genetic bone dysplasia.

In conclusion, we made a pilot study to investigate the genetic epidemiology of bone dysplasia in Chinese children. In the context of pediatric endocrinology, type II collagenopathies, *PHEX*-related X-linked hypophosphataemic rickets and *COMP*-related pseudoachondroplasia are the most common diseases in patients with bone dysplasia when excluding the lysosomal storage disorders and achondroplasia. Targeted next-generation sequencing may be adopted clinically to investigate the defective genes of difficult cases of genetic bone dysplasia, which are very critical for the patient's prognosis prediction and genetic counseling of the family.

CONFLICT OF INTEREST

The authors declare no conflict of interest.

ACKNOWLEDGEMENTS

This project is supported by NSFC (81071121, 81270936), Shanghai Rising-Star Program (12QH1401800), Major Program of Shanghai Committee of Science and Technology (11dz195030), National Key Technology R&D Program (2012BAI09B04).

1 Warman, M. L., Cormier-Daire, V., Hall, C., Krakow, D., Lachman, R., LeMerrer, M. *et al.* Nosology and classification of genetic skeletal disorders: 2010 revision. *Am. J. Med. Genet. A* **155A**, 943–968 (2011).
2 Volodarsky, M., Markus, B., Cohen, I., Staretz-Chacham, O., Flusser, H., Landau, D. *et al.* A deletion mutation in TMEM38B associated with autosomal recessive osteogenesis imperfecta. *Hum. Mutat.* **34**, 582–586 (2013).
3 Miyake, N., Elcioglu, N. H., Iida, A., Isguven, P., Dai, J., Murakami, N. *et al.* PAPSS2 mutations cause autosomal recessive brachyolmia. *J. Med. Genet.* **49**, 533–538 (2012).
4 Nampoothiri, S., Yesodharan, D., Sainulabdin, G., Narayanan, D., Padmanabhan, L., Girisha, K. M. *et al.* Eight years experience from a skeletal dysplasia referral center in a tertiary hospital in Southern India: a model for the diagnosis and treatment of rare diseases in a developing country. *Am. J. Med. Genet. A* **164A**, 2317–2323 (2014).
5 Kannu, P., Bateman, J. & Savarirayan, R. Clinical phenotypes associated with type II collagen mutations. *J. Paediatr. Child Health* **48**, E38–E43 (2012).
6 Jackson, G. C., Mittaz-Crettol, L., Taylor, J. A., Mortier, G. R., Spranger, J., Zabel, B. *et al.* Pseudoachondroplasia and multiple epiphyseal dysplasia: a 7-year comprehensive analysis of the known disease genes identify novel and recurrent mutations and provides an accurate assessment of their relative contribution. *Hum. Mutat.* **33**, 144–157 (2012).
7 Rubinato, E., Morgan, A., D'Eustacchio, A., Pecile, V., Gortani, G., Gasparini, P. *et al.* A novel deletion mutation involving TMEM38B in a patient with autosomal recessive osteogenesis imperfecta. *Gene* **545**, 290–292 (2014).
8 Hasegawa, K. & Tanaka, H. Children with short-limbed short stature in pediatric endocrinological services in Japan. *Pediatr. Int.* **56**, 809–812 (2014).
9 Ozono, K., Namba, N., Kubota, T., Kitaoka, T., Miura, K., Ohata, Y. *et al.* Pediatric aspects of skeletal dysplasia. *Pediatr. Endocrinol. Rev.* **10** (Suppl 1), 35–43 (2012).
10 Yamashita, A., Morioka, M., Kishi, H., Kimura, T., Yahara, Y., Okada, M. *et al.* Statin treatment rescues FGFR3 skeletal dysplasia phenotypes. *Nature* **513**, 507–511 (2014).
11 Cui, Y., Zhao, H., Liu, Z., Liu, C., Luan, J., Zhou, X. *et al.* A systematic review of genetic skeletal disorders reported in Chinese biomedical journals between 1978 and 2012. *Orphanet J. Rare Dis.* **7**, 55 (2012).
12 Le Goff, C., Mahaut, C., Wang, L. W., Allali, S., Abhyankar, A., Jensen, S. *et al.* Mutations in the TGFbeta binding-protein-like domain 5 of FBN1 are responsible for acromicric and geleophysic dysplasias. *Am. J. Hum. Genet.* **89**, 7–14 (2011).
13 Richards, S., Aziz, N., Bale, S., Bick, D., Das, S., Gastier-Foster, J. *et al.* Standards and guidelines for the interpretation of sequence variants: a joint consensus recommendation of the American College of Medical Genetics and Genomics and the Association for Molecular Pathology. *Genet. Med.* **17**, 405–423 (2015).
14 Matos-Miranda, C., Nimmo, G., Williams, B., Tysoe, C., Owens, M., Bale, S. *et al.* A prospective study of brachytelephalangic chondrodysplasia punctata: identification of arylsulfatase E mutations, functional analysis of novel missense alleles, and determination of potential phenocopies. *Genet. Med.* **15**, 650–657 (2013).
15 Wang, Y., Zhang, H., Ye, J., Han, L. & Gu, X. Three novel mutations of the FBN1 gene in Chinese children with acromelic dysplasia. *J. Hum. Genet.* **59**, 563–567 (2014).
16 Terhal, P. A., Nievelstein, R. J., Verver, E. J., Topsakal, V., van Dommelen, P., Hoornaert, K. *et al.* A study of the clinical and radiological features in a cohort of 93 patients with a COL2A1 mutation causing spondyloepiphyseal dysplasia congenita or a related phenotype. *Am. J Med. Genet. A* **167A**, 461–475 (2015).
17 Terhal, P. A., van Dommelen, P., Le Merrer, M., Zankl, A., Simon, M. E., Smithson, S. F. *et al.* Mutation-based growth charts for SEDC and other COL2A1 related dysplasias. *Am. J. Med. Genet. C Semin. Med. Genet.* **160C**, 205–216 (2012).
18 Beck-Nielsen, S. S., Brixen, K., Gram, J. & Brusgaard, K. Mutational analysis of PHEX, FGF23, DMP1, SLC34A3 and CLCN5 in patients with hypophosphatemic rickets. *J. Hum. Genet.* **57**, 453–458 (2012).
19 Kennedy, J., Jackson, G., Ramsden, S., Taylor, J., Newman, W., Wright, M. J. *et al.* COMP mutation screening as an aid for the clinical diagnosis and counselling of patients with a suspected diagnosis of pseudoachondroplasia or multiple epiphyseal dysplasia. *Eur. J. Hum. Genet.* **13**, 547–555 (2005).
20 Deere, M., Sanford, T., Ferguson, H. L., Daniels, K. & Hecht, J. T. Identification of twelve mutations in cartilage oligomeric matrix protein (COMP) in patients with pseudoachondroplasia. *Am. J. Med. Genet.* **80**, 510–513 (1998).
21 Chapman, K. L., Mortier, G. R., Chapman, K., Loughlin, J., Grant, M. E. & Briggs, M. D. Mutations in the region encoding the von Willebrand factor A domain of matrilin-3 are associated with multiple epiphyseal dysplasia. *Nat. Genet.* **28**, 393–396 (2001).
22 Krakow, D., Vriens, J., Camacho, N., Luong, P., Deixler, H., Funari, T. L. *et al.* Mutations in the gene encoding the calcium-permeable ion channel TRPV4 produce spondylometaphyseal dysplasia, Kozlowski type and metatropic dysplasia. *Am. J. Hum. Genet.* **84**, 307–315 (2009).
23 Majava, M., Hoornaert, K. P., Bartholdi, D., Bouma, M. C., Bouman, K., Carrera, M. *et al.* A report on 10 new patients with heterozygous mutations in the COL11A1 gene and a review of genotype-phenotype correlations in type XI collagenopathies. *Am. J. Med. Genet. A* **143A**, 258–264 (2007).
24 Nino, M., Matos-Miranda, C., Maeda, M., Chen, L., Allanson, J., Armour, C. *et al.* Clinical and molecular analysis of arylsulfatase E in patients with brachytelephalangic chondrodysplasia punctata. *Am. J. Med. Genet. A* **146A**, 997–1008 (2008).
25 Hoornaert, K. P., Dewinter, C., Vereecke, I., Beemer, F. A., Courtens, W., Fryer, A. *et al.* The phenotypic spectrum in patients with arginine to cysteine mutations in the COL2A1 gene. *J. Medi. Genet.* **43**, 406–413 (2006).
26 Chan, D., Taylor, T. K. & Cole, W. G. Characterization of an arginine 789 to cysteine substitution in alpha 1 (II) collagen chains of a patient with spondyloepiphyseal dysplasia. *J. Biol. Chem.* **268**, 15238–15245 (1993).
27 Nishimura, G., Haga, N., Kitoh, H., Tanaka, Y., Sonoda, T., Kitamura, M. *et al.* The phenotypic spectrum of COL2A1 mutations. *Hum. Mutat.* **26**, 36–43 (2005).
28 Ritvaniemi, P., Sokolov, B. P., Williams, C. J., Considine, E., Yurgenev, L., Meerson, E. M. *et al.* A single base mutation in the type II procollagen gene (COL2A1) that converts

glycine alpha 1-247 to serine in a family with late-onset spondyloepiphyseal dysplasia. *Hum. Mutat.* **3**, 261–267 (1994).
29 Rowe, P. S., Oudet, C. L., Francis, F., Sinding, C., Pannetier, S., Econs, M. J. *et al.* Distribution of mutations in the PEX gene in families with X-linked hypophosphataemic rickets (HYP). *Hum. Mol. Genet.* **6**, 539–549 (1997).
30 Morey, M., Castro-Feijoo, L., Barreiro, J., Cabanas, P., Pombo, M., Gil, M. *et al.* Genetic diagnosis of X-linked dominant Hypophosphatemic Rickets in a cohort study: tubular reabsorption of phosphate and 1,25(OH)2D serum levels are associated with PHEX mutation type. *BMC Med. Genet.* **12**, 116 (2011).
31 Hecht, J. T., Nelson, L. D., Crowder, E., Wang, Y., Elder, F. F., Harrison, W. R. *et al.* Mutations in exon 17B of cartilage oligomeric matrix protein (COMP) cause pseudoachondroplasia. *Nat. Genet.* **10**, 325–329 (1995).
32 Camacho, N., Krakow, D., Johnykutty, S., Katzman, P. J., Pepkowitz, S., Vriens, J. *et al.* Dominant TRPV4 mutations in nonlethal and lethal metatropic dysplasia. *Am. J. Med Genet. A* **152A**, 1169–1177 (2010).
33 Meredith, S. P., Richards, A. J., Bearcroft, P., Pouson, A. V. & Snead, M. P. Significant ocular findings are a feature of heritable bone dysplasias resulting from defects in type II collagen. *Br J Ophthalmol* **91**, 1148–1151 (2007).
34 Tiller, G. E., Hannig, V. L., Dozier, D., Carrel, L., Trevarthen, K. C., Wilcox, W. R. *et al.* A recurrent RNA-splicing mutation in the SEDL gene causes X-linked spondyloepiphyseal dysplasia tarda. *Am. J. Hum. Genet.* **68**, 1398–1407 (2001).
35 Ludecke, H. J., Schaper, J., Meinecke, P., Momeni, P., Gross, S., von Holtum, D. *et al.* Genotypic and phenotypic spectrum in tricho-rhino-phalangeal syndrome types I and III. *Am. J. Hum. Genet.* **68**, 81–91 (2001).

Supplementary Information accompanies the paper on Journal of Human Genetics website (http://www.nature.com/jhg)