J Hum Genet (2005) 50:21–25
DOI 10.1007/s10038-004-0212-x

ORIGINAL ARTICLE

**Kamini Kalidas · Adam C. Shaw · Andrew H. Crosby
Ruth Newbury-Ecob · Lynn Greenhalgh
Isabel K. Temple · Caroline Law · Amisha Patel
Michael A. Patton · Steve Jeffery**

Genetic heterogeneity in LEOPARD syndrome: two families with no mutations in *PTPN11*

Received: 21 September 2004 / Accepted: 19 October 2004 / Published online: 10 December 2004

Abstract LEOPARD syndrome (lentigines, electrocardiographic conduction abnormalities, ocular hypertelorism, pulmonary stenosis, abnormal genitalia, retardation of growth, and sensorineural deafness) is an autosomal dominant condition. The main clinical features include multiple lentigines, cardiovascular defects, and facial anomalies, some of which are shared with Noonan syndrome (NS). Recent reports have shown that LEOPARD syndrome can be caused by mutations in *PTPN11*, the gene in which mutations can produce NS. Here we report the findings of mutation screening and linkage analysis of *PTPN11* in three families with LEOPARD syndrome. We identified a novel mutation in one family. The mutation (1529A > C) substitutes proline for glutamine at amino acid 510 (Gln510Pro). No variations in sequence were observed in the other two families, and negative LOD scores excluded linkage to the *PTPN11* locus, showing that LEOPARD syndrome is genetically heterogeneous.

Keywords LEOPARD Syndrome · Noonan syndrome · *PTPN11* gene · Mutation screening · Linkage analysis

Introduction

LEOPARD syndrome (multiple lentigines, electrocardiographic conduction abnormalities, ocular hypertelorism, pulmonary stenosis, abnormal genitalia, retardation of growth, and sensorineural deafness, MIM#151100) is an autosomal dominant condition. The syndrome was established as a distinct disorder by Gorlin et al. (1969) and is characterised by lentigines and café au lait spots, facial dysmorphism, retardation of growth and cardiac defects. The most common cardiac defect is valvular pulmonary stenosis, which occurs in at least 40% of cases (Gorlin et al. 1990; Coppin et al. 1997). As expression is highly variable, minimum criteria for diagnosis include the presence of multiple lentigines and two other recognised features. If lentigines are absent, three other features in the patient and an immediate relative with LEOPARD syndrome are diagnostic (Voron et al. 1976). There is a distinct clinical overlap between LEOPARD syndrome and Noonan syndrome (NS), (MIM#163950), the common characteristics being cardiac defects, growth retardation and facial dysmorphism (Gorlin et al. 1990; Coppin et al. 1997; Blienden et al. 1983). This led to the speculation that the two conditions may be allelic (Gorlin et al. 1969). A gene mutated in about 50% of NS cases is *PTPN11*, which encodes a non-receptor protein tyrosine phosphatase (Tartaglia et al. 2001). Subsequently, Digilio et al. (2002), Legius et al. (2002), Conti et al. (2003) and Sarkozy et al. (2004) have reported mutations in exon 7 (836A > G), exon 12 (1403C > T) and exon 13 (1492C > T, 1493G > T and 1517A > C) of *PTPN11* in LEOPARD patients. We have ascertained three families with LEOPARD syndrome, performed mutation screening of the *PTPN11* gene and determined whether there is linkage to the NS1 locus.

Materials and methods

Subjects

Three families with (multiple lentigines) (ML)/LEOPARD were studied. DNA was extracted from peripheral

K. Kalidas · A. C. Shaw · A. H. Crosby · A. Patel
M. A. Patton · S. Jeffery (✉)
Medical Genetics Unit,
Department of Clinical Developmental Sciences,
St. George's Hospital Medical School, London, SW17 0RE, UK
E-mail: sggt100@sghms.ac.uk
Tel.: +44-0208-7255967
Fax: +44-0208-7251039

R. Newbury-Ecob · L. Greenhalgh
Clinical Genetics Service,
Bristol Royal Hospital for Sick Children, Bristol, UK

I. K. Temple · C. Law
Wessex Clinical Genetics Service,
Princess Anne Hospital, Southampton, UK

blood using standard procedures. The pedigrees are shown in Fig. 1. All members of families 1 and 2 were examined by R.N-E, and all members of family 3 were examined by I.K.T. The observed features of LEOPARD syndrome in these families are shown in Table 1.

Family 1

The proband (female, age 13 years) was born at term weighing 3.77 kg. There were feeding difficulties in the neonatal period, but early development was normal. On examination she was not dysmorphic but had multiple lentigines on the trunk, limbs and face. Echocardiography revealed pulmonary stenosis. In the rest of the family, the sister of the proband has short stature, NS facies and no lentigines. The mother of the proband has multiple lentigines and short stature. Echocardiography showed a mitral valve anomaly, and an ECG showed left axis deviation. A maternal uncle has multiple lentigines, short stature and a history of undescended testes, a maternal aunt has short stature and lentigines and the maternal grandmother has short stature and lentigines.

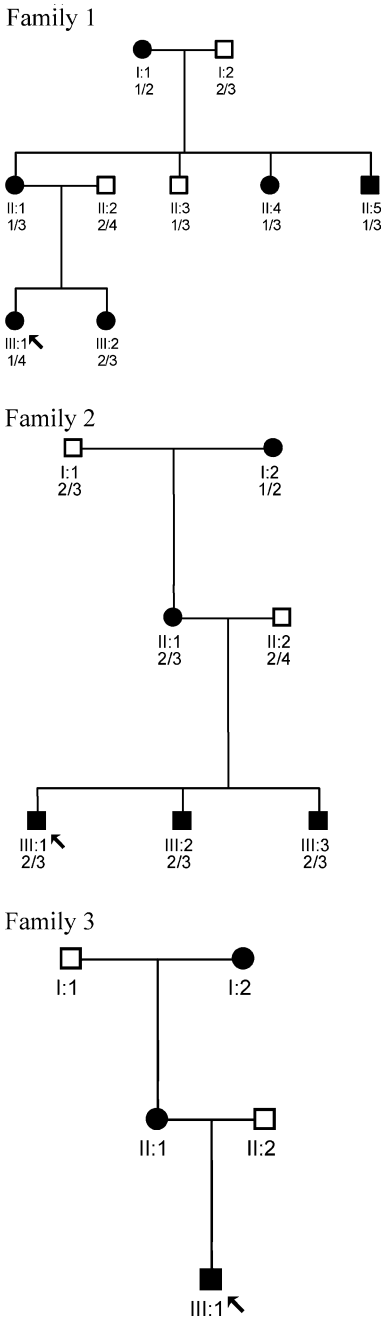

Fig. 1 Pedigrees of LEOPARD families. *Circles* are females; *squares* are males; *shaded* are affected. The *numbering* under each individual represents the *PTPN11* alleles in each family (not sized, therefore not comparable across pedigrees)

Family 2

The proband (male, age 12 years) was born at 34 weeks gestation with a birth weight of 1.22 kg. Early development was delayed, especially with regard to speech and fine motor skills, and he wears bilateral hearing aids for sensory-neural hearing loss. On examination the patient was on the 91st centile for height and the 50th centile for weight and head circumference while the cardiovascular system and genitalia were normal. There were multiple lentigines, particularly concentrated on the neck and thorax. ECG and echocardiography were normal. The proband has two brothers (aged 6 and 9 years); one requires bilateral hearing aids for deafness, has learning difficulties and a few lentigines. The other has learning difficulties, lentigines, but no deafness. ECG and echocardiography was normal on both. The proband's mother has multiple lentigines and a hearing impairment that is not sufficient to require a hearing aid. Her mother has a similar hearing loss and lentigines.

Family 3

The proband (male, age 4) was born at term weighing 3.23 kg. There were problems with feeding in infancy resulting in failure to thrive, and early motor milestones were delayed. On examination height and weight were between the 2nd and 9th centiles while head circumference was on the 9th centile. He was dysmorphic with down-slanting palpebral fissures, hypertelorism, broad nasal bridge and low-set, posteriorly rotated ears with thick helices. The neck was short but not webbed while wide-spaced nipples and dry skin were also noted. A "distraction" hearing test was passed while an ECG showed a superior axis and an echo showed a dysplastic pulmonary valve and small secundum ASD. The mother has severe sensory-neural deafness. On examination she has hypertelorism, posteriorly rotated ears and lentigines that are mostly over the trunk and limbs. ECG axis is $+90°$ and echocardiography is normal. The maternal grandmother of the proband also has multiple lentigines, similar dysmorphic features and short stature. ECG axis is $+45°$, and echocardiography reveals a sclerotic aortic valve.

Table 1 Observed features of LEOPARD syndrome in the families. *MVA* mitral valve anomaly, *LAD* left axis deviation, *PS* pulmonary stenosis, *ASD* atrial septal defect

	Lentigines	Structural cardiac defect	ECG defects	Genito-urinary abnormalities	Neurological defect	Dysmorphic features	Short stature	Skeletal defects	Family history
Family 1									
I:1	–	–	–	–	–	–	+	–	+
II:1	+	MVA	LAD	––	–	–	+	–	+
II:4	+	–	–	–	–	–	+	–	+
II:5	+	–	–	Bilateral cryptorchidism	–	–	+	–	+
III:1[a]	+	PS	–	–	–	–	–	–	–
III:2	–	–	–	–	–	+	+	–	+
Family 2									
I:2	+	–	–	–	Hearing loss	–	–	–	+
II:1	+	–	–	–	Hearing loss	–	–	–	+
III:1[a]	+	–	–	–	Bilateral nerve deafness	–	–	–	+
III:2	–	–	–	–	Mild mental retardation	–	–	–	+
III:3	–	–	–	–	Bilateral nerve deafness	–l	–	–	+
Family 3									
I:2	+	–	Superior axis	–	–	+	+	–	+
II:1	+		–	–	Bilateral nerve deafness	+	–	Scoliosis	+
III:1[a]	[b]	PS & ASD	Superior axis	–	–	+	+	–	+

[a]Indicates proband
[b]Indicates no lentigines at 1 year of age

Linkage analysis

Linkage analysis was performed using an intragenic microsatellite marker derived from intron 2 of the *PTPN11* gene. The marker was amplified under standard PCR conditions using primers F-5′GCTGAGGCACGAGAATCACT 3′ and R-5′GGAATGGAATTGC CTTATGGT 3′. Two-point linkage analysis was carried out using the MLINK option of the linkage package Ver 5.10 (Lathrop et al. 1984), assuming penetrance of 90%.

Screening of *PTPN11*

The *PTPN11* gene was screened for mutations in the probands of all three families. All 15 of the *PTPN11* exons and the flanking intronic sequences were amplified by PCR, as previously described (Tartaglia et al. 2002). Amplicons were purified using the Qiagen PCR purification kit. Direct bidirectional sequencing was performed using the Big-Dye Terminator kit (Applied Biosystems) with 2 µl of PCR product. Thermocycling was performed under the following conditions: an initial denaturation at 96°C for 2 min followed by 25 cycles of 96°C for 30 s, 55°C for 15 s and 72°C for 4 min. Products were analysed using the Applied Biosystems 3100 genetic analyzer.

Results

Sequencing

A new mutation was identified in exon 13 in the proband from family 3. A point mutation (A1529C) changes amino acid 510 from glutamine to proline. This change was present in all affected family members. The mutation was not observed in 100 control samples. Exons 7, 12 and 13 mutations previously reported (Digilio et al. 2002; Conti et al. 2003; Sarkozy et al. 2004) were not found in the probands from families 1 and 2. There were no sequence variations in the other exons.

Linkage data

Results of linkage analysis of the *PTPN11* gene in the LEOPARD syndrome families negative for PTPN11 mutations are shown in Table 1. LOD scores below -2 at $\theta = 0$ exclude this locus. Initial LOD scores were calculated using the affected status given in Fig. 1, but we recognise that in family 1, the status of I:1 can be regarded as equivocal (only short stature and lentigines as features), and in family 2, individuals III:2 (learning difficulties and lentigines) and III:3 (learning difficulties, only a few lentigines and deafness) can be considered in the same light. The simplest way to address these possibilities in linkage terms is to perform the analysis without the grandparental input in family 1 and assume unknown status for III:3 in family 2. In family 1, there is still an affected recombinant in generation III so that the value at $z = 0$ remains at $-\infty$, but the LODs at other values of θ become less negative (of no significance when using an intragenic marker).

A similar effect is observed for family 2 if III:3 is excluded (see Table 2).

Discussion

Mutations in *PTPN11* have been shown to account for approximately 50% of cases with NS (Tartaglia et al.

Table 2 LOD scores for two-point linkage analysis of the *PTPN11* gene in the LEOPARD families. Values in normal type assume the affectation status given in Fig. 1, those in italics indicate removal of the grandparental contribution in family 1 and assumed unaffected status for III:2 and III:3 in family 2

Pedigree	Value of θ		
	0	0.0001	0.001
Family 1	$-\infty$	−3.8	−2.8
	$-\infty$	*−3.47*	*−2.47*
Family 2	$-\infty$	−11.1	−8.1
	$-\infty$	*−3.14*	*−2.14*

2002), and recent reports have shown that in 11 out of 12 cases of LEOPARD syndrome, mutations were identified in this gene (Digilio et al. 2002; Legius et al. 2002; Conti et al. 2003; Sarkozy et al. 2004). These mutations were either in exon 7 (836A > G), exon 12 (1403C > T) or exon 13 (1492 C > T, 1493G > T 1517A > C). There has been a report of a large family with multiple lentigines not caused by mutations in *PTPN11* (Pacheco et al. 2002), but no family member had any other features associated with LEOPARD syndrome. Digilio et al. (2002), suggested that LEOPARD syndrome and NS are allelic. They also reported that the single case without a mutation in their series could suggest genetic heterogeneity, but it is possible that a mutation in the non-coding region of the gene may have been responsible for the disorder in this individual. We hoped that investigation of our families might determine whether or not there is genetic heterogeneity in LEOPARD syndrome.

Our studies on three families with LEOPARD syndrome revealed a novel mutation in exon 13 of the *PTPN11* gene in one family. The change (1529A > C) results in a conversion from proline to glutamine at amino acid 510. This amino acid conversion was not observed in controls, and is very close to the mutation described by Sarkozy et al. (2004), so we believe it to be causative. No mutations were observed in the coding regions of *PTPN11* in the two other families, thus excluding the published mutations in exons 7, 12 and 13. Since it was possible that we might also have missed non-coding mutations in *PTPN11*, we carried out linkage analysis to *PTPN11* to address this. The negative LOD scores exclude a role for *PTPN11* in the pathogenesis of LEOPARD syndrome in these families. These results demonstrate that LEOPARD syndrome is definitely a heterogeneous disorder. Genetic heterogeneity in NS has been established based on exclusion of linkage in some families (Jamieson et al. 1994) and the absence of *PTPN11* mutations in about 50% of cases (Tartaglia et al. 2002). Of the 31 patients described to date with LEOPARD syndrome and mutations in *PTPN11* (Digilio et al. 2002; Legius et al. 2002; Conti et al. 2003; Sarkozy et al. 2004), 13 had hypertrophic cardiomyopathy, five had pulmonary stenosis while eight had a normal ECG.

It seems that specific mutations in the *PTPN11* gene cause a Noonan-like phenotype with the additional features of skin pigmentation (ML & café au lait patches) and an increased tendency to develop hypertrophic cardiomyopathy (HCM). This is of particular interest, as patients with NS and *PTPN11* mutations have rarely been found to have HCM. Similarly, deafness is not a common finding in NS, and its association with particular mutations in LEOPARD syndrome might suggest specific functional changes in the *PTPN11* gene. Sarkozy et al. (2004) point out that there is one mutation, Y279C, which has been reported to cause both NS and LEOPARD syndrome, and this was reported as giving rise to NS by Tartaglia et al. (2002). This was a baby diagnosed with NS, but on follow, up the child has been found to have multiple lentigines (A. Shaw, personal communication). It does, therefore, appear at present that mutations in *PTPN11* that give rise to NS or LEOPARD syndrome are specific to the two conditions.

Here we describe one LEOPARD syndrome family with a novel mutation in *PTPN11* and two families with LEOPARD syndrome not attributable to *PTPN11* mutations. None of the families exhibit hypertrophic cardiomyopathy. Pulmonary stenosis is present in the family with a causative *PTPN11* mutation. Deafness is also found in the family with the *PTPN11* mutation and in an unlinked family. We therefore conclude that LEOPARD syndrome is a heterogeneous disorder. Studies are currently ongoing to identify the other genes contributing to NS, and discovery of these genes will enable us to evaluate their role in LEOPARD syndrome.

Acknowledgements This work was supported by grants from the British Heart Foundation and the Birth Defects Foundation (UK). The work was carried out within the network of the London IDEAS Genetics Knowledge Park using the facilities available at the SGHMS Biomics Centre. We thank Dr. Ingrid Scurr for help with family ascertainment.

References

Blienden LC, Schneeweiss A, Shem-Tov et al (1983) Unifying link between Noonan's and Leopard syndromes? Pediatric Cardiol 4:168–169

Conti E, Dottorini T, Sarkozy A et al (2003) A novel PTPN11 mutation in LEOPARD syndrome Hum Mutation 21(6):654–657

Coppin BD, Temple IK (1997) Multiple lentigines syndrome (LEOPARD syndrome or progressive cardiomyopathic lentiginosis). J Med Genet 34(7):582–586

Digilio MC, Conti E, Sarkozy A et al (2002) Grouping of multiple-lentigines/LEOPARD and Noonan syndromes on the *PTPN11* gene. Am J Hum Genet 71(2):389–394

Gorlin RJ, Andreson RC, Blaw M (1969) Multiple lentigines syndrome. Am J Dis Child 117:652–662

Gorlin RJ, Cohen MM, Levin LS (1994) Syndromes affecting the skin and mucosa. In: Gorlin RJ, Cohen MM, Levin LS (eds) Syndromes of the head and neck. Oxford University Press, New York, pp 461–464

Jamieson CR, van der Burgt I, Brady AF et al (1994) Mapping a gene for Noonan syndrome to the long arm of chromosome 12. Nat Genet 8(4):357–360

Lathrop GM, Lalouel JM, Julier C, Ott J (1984) Strategies for multilocus linkage analysis in humans. PNAS 81:3443–3446

Legius E, Schrander-Stumpel C, Schollen E et al (2002) *PTPN11* mutations in LEOPARD syndrome. J Med Genet 39(8):571–574

Pacheco TR, Bellus GA, Oreskovich NM et al (2002) Exclusion of candidate genes and loci for multiple lentigines syndrome. J Invest Dermatol 119(2):535–538

Sarkozy A, Conti E, Digilio CM, Marino B, Morini E, Pacilco G, Wilson M, Calabro R, Pizzuti A, Dallapiccola B (2004) Clinical and molecular analysis of 30 patients with multiple lentigines LEOPARD syndrome. J Med Genet 41:e68

Tartaglia M, Mehler EL, Goldberg R et al (2001) Mutations in *PTPN11*, encoding the protein tyrosine phosphatase SHP-2, cause Noonan syndrome. Nat Genet 29(4):465–468

Tartaglia M, Kalidas K, Shaw A et al (2002) *PTPN11* mutations in Noonan syndrome: molecular spectrum, genotype-phenotype correlation, and phenotypic heterogeneity. Am J Hum Genet 70(6):1555–1563

Voron DA, Hatfield HH, Kalkhoff RK (1976) Multiple lentigines syndrome. Case report and review of the literature. Am J Med Genet 60(3):447–456