References

1 Kamal AM, Abozeid D, Seif Y, Hassan M. A comparative study of adjustable and non -adjustable sutures in primary horizontal muscle surgery in children. *Eye* 2016; **30**: 1447–1451.
2 Engel JM, Guyton DL, Hunter DG. Adjustable sutures in children. *JAAPOS* 2014; **18**(3): 278–284.
3 Sun LS, Li G, Miller TL, Salorio C, Byrne MW, Bellinger DC *et al.* Association between a single general anesthesia exposure before age 36 months and neurocognitive outcomes in later childhood. *JAMA* 2016; **315**(21): 2312–2320.

N Tan[1], C Wu[2] and S Jain[1,3]

[1]Department of Ophthalmology, Royal Free Hampstead NHS Trust, London, UK
[2]Whittington Health NHS Trust, London, UK
[3]University College London Medical School, London, UK
E-mail: naomitan@doctors.org.uk

Eye (2017) **31,** 1746–1747; doi:10.1038/eye.2017.140; published online 4 August 2017

Sir,
Survival analysis of visual improvement after cataract surgery in advanced retinitis pigmentosa

We conducted a survival analysis to investigate the duration of visual improvement following cataract surgery in patients with retinitis pigmentosa. Consecutive records of patients with retinitis pigmentosa who underwent phacoemulsification cataract extraction from January 2001 to December 2015 at Hong Kong Eye Hospital were reviewed. All patients were followed-up annually. The duration at which postoperative best-corrected visual acuity (BCVA) returned to preoperative values was traced. For cases with visual improvement maintained or lost to follow-up, the interval between the date of surgery and the date of the last visit was recorded.

Wilcoxon signed-rank test was used to compare the BCVA over time. Visual acuities of hand movement and light perception were assigned the equivalent of 1.7 and 1.8 logMAR units, respectively. Kaplan–Meier survival analysis was performed to evaluate the duration of visual improvement following cataract surgery. A P-value of <0.05 was considered statistically significant.

Sixty-seven eyes of 42 patients with retinitis pigmentosa had phacoemulsification and intraocular lens implanted during the study period. The average age of cataract extraction was 59.2 ± 12.3 years. Preoperative BCVA improved from 1.27 ± 0.42 to 0.92 ± 0.49 and 0.97 ± 0.53 at 3 months and 1 year postoperatively ($P<0.001$). Final BCVA measured at a mean of follow-up duration of 6.9 ± 4.4 years was 1.18 ± 0.49 ($P=0.095$, compared to preoperative BCVA) with 37 (55.2%) eyes returned to or worse than preoperative values.

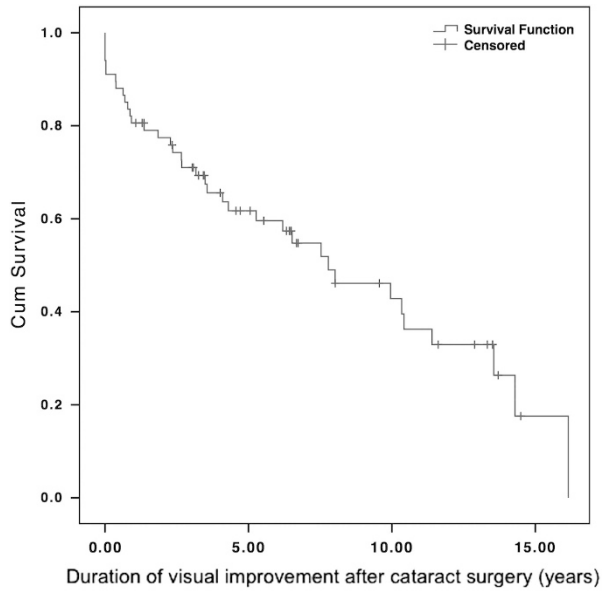

Figure 1 Kaplan–Meier survival curve of visual improvement after cataract surgery in retinitis pigmentosa patients.

Using survival analysis, the mean duration of visual improvement following cataract surgery was 8.10 ± 0.83 years (95% confidence interval, 6.47 to 9.72 years) (Figure 1). Preoperatively, visual field was $<10°$ in 43 eyes (64.2%) and $\geq 10°$ in 24 eyes (35.8%). There was no significant difference in the duration of visual improvement between the two groups (Log-rank test, $P=0.345$). Premorbid ocular diseases were noted in 25 (37.3%) eyes. No significant difference was found in the duration of visual improvement between eyes with or without premorbid ocular diseases (Log-rank test, $P=0.754$).

Similar to previous studies, our results showed a significant improvement in visual acuity after cataract surgery in patients with retinitis pigmentosa.[1,2] Using the Humphrey Field Analyzer, Yoshida *et al*[2] reported that less advanced disease with mean deviation of ≥ -15 decibels in central 10–2 program had significant visual improvement postoperatively.[2] Dikopf *et al* reported limited postoperative visual gain in their patients with very low vision ($<20/400$). They speculated that this was due to the pre-existing retinal disease or maculopathy.[1] Assessment of macular microstructure using optical coherence tomography could help predict postoperative visual prognosis.[2,3] The degenerative nature of the disease could lead to a drop in visual improvement over time.[4]

Patients in the current study had advanced disease as shown in their poor BCVA at postoperative 3 months. The cumulative incidence of patients with retinitis pigmentosa classified as low vision was 34 to 65% by the age of 60 years.[5] Here we showed that these patients could achieve visual improvement

over a significant duration after cataract surgery. Our findings support cataract surgery in patients with advanced retinitis pigmentosa and can provide useful information for preoperative counseling.

Conflict of interest

The authors declare no conflict of interest.

References

1 Dikopf MS, Chow CC, Mieler WF, Tu EY. Cataract extraction outcomes and the prevalence of zonular insufficiency in retinitis pigmentosa. *Am J Ophthalmol* 2013; **156**(1): 82–88.
2 Yoshida N, Ikeda Y, Murakami Y, Nakatake S, Fujiwara K, Notomi S *et al.* Factors affecting visual acuity after cataract surgery in patients with retinitis pigmentosa. *Ophthalmology* 2015; **122**(5): 903–908.
3 Nakamura Y, Mitamura Y, Hagiwara A, Kumagai K, Miura G, Sugawara T *et al.* Relationship between retinal microstructures and visual acuity after cataract surgery in patients with retinitis pigmentosa. *Br J Ophthalmol* 2015; **99**(4): 508–511.
4 Sandberg MA, Rosner B, Weigel-DiFranco C, Dryja TP, Berson EL. Disease course of patients with X-linked retinitis pigmentosa due to RPGR gene mutations. *Invest Ophthalmol Vis Sci* 2007; **48**(3): 1298–1304.
5 Pierrache LH, Hartel BP, van Wijk E, Meester-Smoor MA, Cremers FP, de Baere E *et al.* Visual prognosis in USH2A-associated retinitis pigmentosa is worse for patients with Usher syndrome type iia than for those with nonsyndromic retinitis pigmentosa. *Ophthalmology* 2016; **123**(5): 1151–1160.

TCY Chan[1,2], SC Lam[1,2], S Mohamed[1,2] and RLM Wong[1,2]

[1]Department of Ophthalmology and Visual Sciences, The Chinese University of Hong Kong, Kowloon, China
[2]Hong Kong Eye Hospital, Kowloon, China
E-mail: tommychan.me@gmail.com

Eye (2017) **31,** 1747–1748; doi:10.1038/eye.2017.164; published online 4 August 2017