

Preoperative clinical features of reactivated of Graves' orbitopathy after orbital decompression

YJ Woo, JW Kim and JS Yoon

Abstract

Purpose To investigate the incidence and preoperative clinical features of reactivated Graves' orbitopathy (GO) after orbital decompression.

Methods This study included patients with GO who underwent orbital decompression for disfiguring proptosis and not compressive optic neuropathy and received postoperative follow-up care for more than 12 months. Patients who experienced active inflammatory signs within 6 months of decompression were excluded from analysis. The demographic characteristics, ophthalmic manifestations, and biochemical parameters of the patients were analyzed for association with reactivation of GO by logistic regression analysis.

Results Out of the 92 patients included in this study, seven (7.6%) experienced reactivation of GO after orbital decompression. The mean time interval between surgery and reactivation of GO was 36.3 ± 14.3 weeks. Univariate logistic regression analysis identified age, existing smoking habits, and modified NOSPECS and Gorman scores as significant factors for the reactivation of GO. The results of multivariate logistic regression analysis revealed that smoking and modified NOSPECS and Gorman scores were associated with the reactivation of GO.

Conclusions Quitting smoking is important for the prevention of reactivation of GO after orbital decompression. Patients with severe symptoms, especially those with restrictive myopathy, should be carefully monitored for reactivation of GO after orbital decompression.

Eye (2017) 31, 643–649; doi:10.1038/eye.2016.304; published online 6 January 2017

Introduction

Graves' orbitopathy (GO) is an autoimmune disease associated with Graves' hyperthyroidism

and affecting the orbital and periorbital tissues. Although the pathogenesis of GO is not clearly understood, thyroid-stimulating hormone receptor (TSH-R) antigen expressed on orbital fibroblasts and thyroid follicular cells is considered to be a target co-antigen attacked by TSH-R antibodies in the blood.^{1,2} Orbital fibroblasts may undergo adipogenesis and produce excessive glycosaminoglycans in response to immunoglobulin G, a monoclonal stimulatory TSH-R antibody.^{3–5} This results in ocular manifestations of GO, such as proptosis, conjunctival chemosis, periorbital edema, altered ocular motility, as well as vision-threatening compressive optic neuropathy (ON) and exposure keratitis, all of which bear significant functional, social, and cosmetic consequences.^{6,7}

The natural history of GO is variable. Classically, an initial active inflammatory phase, lasting 6–24 months, is followed by a chronic fibrosis phase, as described by Rundle.⁸ However, GO can sometimes be reactivated after a certain period of quiescence.^{9,10} The incidence of reactivation of GO is not well known, but it has been reported to range from 5 to 15.7% depending on the definition of duration of inactivity.^{9,11} Reactivation of GO has been reported to be associated with periocular surgery, profound life stress, poorly controlled hypothyroidism, and smoking.^{9,12}

With the evolution in surgical techniques over the past few decades, orbital decompression has come to be performed not only in cases of compressive ON and exposure keratitis that are nonresponsive to medical treatment but also in cases of cosmetic disfigurement and orbital congestion.^{13,14} Thus, the number of orbital decompression procedures being performed has increased over time. However, since there has been a clinical hypothesis that surgery itself can activate antigen-presenting cells and orbital fibroblasts that produce proinflammatory

Institute of Vision Research, Department of Ophthalmology, Yonsei University College of Medicine, Seoul, South Korea

Correspondence: JS Yoon, Institute of Vision Research, Department of Ophthalmology, Yonsei University College of Medicine, 50-1 Yonsei-ro, Seodaemun-gu, Seoul 03722, South Korea
Tel: +82 2 2228 3570;
Fax: +82 2 312 0541.
E-mail: yoonjs@yuhs.ac

Received: 18 July 2016
Accepted in revised form: 20 November 2016
Published online: 6 January 2017

cytokines,¹⁵ the probability of reactivation of GO due to orbital decompression has also increased. Few studies have evaluated the reactivation of GO after orbital decompression. One previous study reported the incidence rate of this phenomenon as 1.3%; however, such rate might have been underestimated due to exclusion of patients who were treated with perioperative corticosteroids.¹⁵ Until now, no study has evaluated the risk factors or preoperative clinical features associated with the reactivation of GO after orbital decompression. In this study, we investigated the short-term incidence and clinical features of GO in patients who experienced reactivation of the disease after rehabilitative orbital decompression surgery.

Subjects and methods

Study design and statement of ethics

This retrospective observational study adhered to the tenets of the Declaration of Helsinki. Approval for this study was obtained before the start of study from the institutional review board of the Severance Hospital, Yonsei University College of Medicine, South Korea.

Study population

This study included Korean patients with GO who underwent rehabilitative orbital decompression for the treatment of disfiguring proptosis with or without orbital congestion at the Department of Ophthalmology, Severance Hospital, Yonsei University College of Medicine, Seoul, South Korea, between March 2009 and January 2015. Patients included in the study had undergone treatment for Graves' disease (GD) for at least 1 year before surgery, maintained euthyroid status for at least 3 months before surgery, and received at least 12 months of post-surgical follow-up. Patients who experienced active inflammatory signs after orbital decompression were identified. Active inflammation was defined as a CAS ≥ 3 .

Patients with preoperative compressive optic neuropathy were excluded. In addition, patients who exhibited active inflammation within 6 months of decompression were also excluded from analysis, since the active phase in such cases could be considered as a continuation of the preoperative inflammatory processes.¹¹

Clinical and biochemical variables

We reviewed the results of clinical ophthalmic examination including evaluation of best-corrected visual acuity and intraocular pressure, exophthalmometric

measurements performed with a Hertel exophthalmometer, Hess screen test, binocular single-vision test, and pre- and post-operative computed tomography (CT). We also recorded durations of GD and GO before surgery.

Patients who still had a smoking habit at the time of surgery were considered smokers. Severity of GO was quantified using a modified NOSPECS score,¹⁶ which involved grading of the following parameters: lid retraction (class 1, score 0–1), soft-tissue inflammation (class 2, score 0–3), proptosis (class 3, score 0–3), myopathy (class 4, score 0–3), corneal defect (class 5, score 0–1), and ON (class 6, 0 or 3). The sum of the scores constituted the modified NOSPECS score (range, 0–14). The Gorman score was used to evaluate the severity of diplopia: no diplopia (1), intermittent diplopia (2), gaze-evoked diplopia (3), and constant diplopia in the primary position (4).¹⁷ Activity of GO was assessed according to the seven-point clinical activity scoring system described by Mourits *et al*.¹⁸

Biochemical parameters, including free T4, thyroid stimulating hormone (TSH), thyrotropin-binding inhibitor immunoglobulin (TBII), and thyroid-stimulating immunoglobulin (TSI) concentrations, were measured within 4 weeks before surgery. Thyrotropin-binding inhibitor immunoglobulin levels were measured by an M22-TSH-receptor antibody (TRAb) assay using the automated Cobas electrochemiluminescence system (Elecsys, Roche Diagnostics GmbH, Penzberg, Germany) according to the manufacturer's instructions. The cutoff value for positive result using this system was 1.75 IU/L.¹⁹ Thyroid-stimulating immunoglobulin levels in patient sera were measured using the Mc4-based Thyretain TSI Reporter BioAssay (Diagnostic Hybrids, Inc., Athens, OH, USA) kit according to the manufacturer's instructions. The cutoff value for positive results using this system was 140 specimen-to-reference ratio (SRR)%.

Surgical techniques and postoperative management

A single surgeon (JSY) conducted orbital decompression surgery in all patients. Surgery was performed through a lower canthofornix and caruncle approach under general anesthesia, as previously reported.²⁰ Following septal incision, all postseptal medial, central, and lateral fat pads were excised. The retrobulbar inferolateral fat pocket, which has the greatest amount of fat, was dissected between the lateral and inferior rectus muscles, incising the tenon fascia towards the apex. In the same manner, maximal amounts of inferomedial and caruncular fat tissues were removed carefully to avoid damage to the inferior rectus, inferior oblique, and medial rectus muscles until satisfactory reduction of proptosis was achieved.

If fat decompression alone was insufficient for proptosis reduction, additional decompression of the posterior ethmoid bone and/or posterior floor, mostly involving the posterior strut, was performed. In patients with prominent muscle enlargement, bony wall decompression to release venous congestion was always performed along with the excision of orbital fat tissues.

Patients were routinely administered corticosteroids at a dose of 125 mg of on the day of surgery, followed by 15 and 5 mg doses in the first and second weeks after surgery, respectively.

Statistical analysis

Statistical analysis was performed using the SPSS software (Version 20.0 for Windows, SPSS, Inc., Chicago, IL, USA). The normality of data distribution was evaluated using the Kolmogorov–Smirnov test. Univariate logistic regression analyses were performed to identify clinical factors related to reactivation of GO after orbital decompression. Multivariate logistic regression analyses were subsequently performed to determine whether variables revealed as significant in the univariate model were independently associated with reactivation of GO after surgery. Results were considered statistically significant at P -values < 0.05 .

Results

A total of 92 patients underwent orbital decompression for the treatment of disfiguring proptosis within the study period. The mean duration of post-surgical follow-up was 2.9 ± 1.3 years (range, 1.0–6.0 years). The demographic and clinical features of the included patients are described in Table 1. Out of the 92 patients, seven (7.6%) experienced reactivation of GO after orbital decompression. The demographics, types of orbital decompression, as well as pre- and post-operative clinical characteristics of these patients are summarized in Table 2. All of these patients exhibited CAS ≤ 1 within 2 weeks of orbital decompression (Figure 1). The mean value of Hertel exophthalmometric measurement of the severely affected eye decreased from 21.6 ± 1.4 mm before surgery to 17.3 ± 1.5 mm post surgery ($P = 0.018$). Active signs and symptoms of GO developed at a mean interval of 36.3 ± 14.3 weeks (median, 32; range, 26–68, weeks) after surgery. At the point of reactivation, four were identified as euthyroid, two as hyperthyroid, and one as hypothyroid. TBII (9.95 IU/l) showed no significant increase ($P = 0.753$) in measurement, whereas TSI level (594.5 SRR%) increased significantly ($P = 0.043$) at reactivation compared with its level at preoperative status. Out of the seven patients, five were treated for active inflammation with parenteral corticosteroids, one

Table 1 Demographic and clinical characteristics of patients who underwent orbital decompression ($N = 92$)

Variable, unit	Value
Age, years	36.5 ± 13.3
Male, n (%)	22 (23.9)
Current smoker, n (%)	19 (20.7)
GO symptom duration, months	40.7 ± 46.2
GD symptom duration, months	47.3 ± 55.1
Clinical activity score	1.2 ± 0.9
Modified NOSPECS score	4.7 ± 1.9
Restrictive myopathy, n (%)	25 (27.2)
Exophthalmos of severe eye, mm	21.4 ± 2.7
Free T4, ng/ml	1.2 ± 0.3
TSH, mU/l	1.4 ± 2.0
TBII, IU/l	9.2 ± 12.3
TSI, SRR%	315.1 ± 144.7

Abbreviations: GD, Graves' disease; GO, Graves' orbitopathy; SRR, specimen-to-reference ratio; TBII, thyrotropin-binding inhibitor immunoglobulin; TSH, thyroid stimulating hormone; TSI, thyroid-stimulating immunoglobulin.

Data are expressed as mean \pm standard deviation or number (percentage).

with orbital irradiation (2 Gy \times 10 sessions), and one with both modalities. All patients were responsive to treatment.

Univariate and multivariate analysis

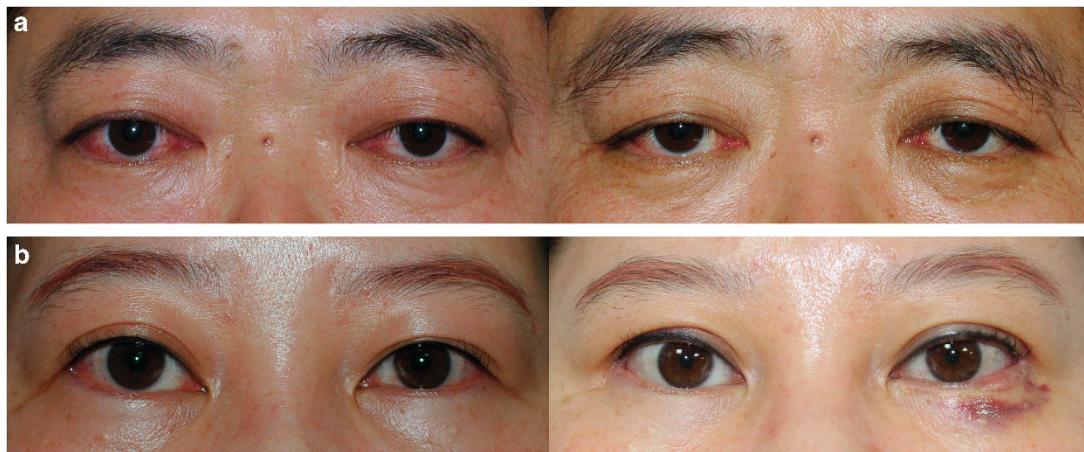
Table 3 presents possible preoperative factors affecting the reactivation of GO after orbital decompression, as determined by univariate logistic regression analyses. Age, smoking habits, and modified NOSPECS and Gorman scores were statistically significant positive factors related to the reactivation of GO after orbital decompression. The differences in preoperative durations of GO and GD, CAS, and biochemical variables including TBII and TSI levels between patients with or without reactivation of GO after surgery were not statistically significant.

In the multivariate model, age, sex, and factors identified in univariate analysis as significantly affecting the reactivation of GO after orbital decompression were used as independent variables to exclude the influence of confounding factors. Since the modified NOSPECS and Gorman scores are correlated, either one (model 1 and 2, respectively), but not both, was used as a variable in the multivariate model. The results of multivariate logistic regression analysis revealed smoking habits (odds ratio [OR], 11.291; 95% confidence interval (CI), 1.033–123.369 in model 1; OR, 41.315; 95% CI, 1.231–386.900 in model 2), modified NOSPECS scores (OR, 2.112; 95% CI, 1.111–4.016 in model 1), and Gorman scores (OR, 8.508; 95% CI, 1.033–68.561 in model 2) as being significant positive, independent factors related to reactivation of GO after orbital decompression (Table 4).

Table 2 Clinical characteristics of patients with reactivation of GO after orbital decompression

No.	Sex	Age (years)	Pre-op CAS	Type of orbital decompression	Duration of inactivity after surgery (months)	Thyroid status at reactivation	CAS at reactivation	TSI at reactivation (SRR%)	Duration of reactivation (months)	Treatment of reactivation
1	Female	58	2	Fat, bony (inf, med)	28	Hyperthyroid	5	743.8	9	IV steroid
2	Female	51	2	Fat, bony (inf, med)	32	Euthyroid	4	509.3	6	IV steroid, RT
3	Male	59	2	Fat, bony (med)	68	Euthyroid	4	574.0	10	RT
4	Male	47	3	Fat, bony (inf, med)	36	Euthyroid	3	728.7	6	IV steroid
5	Male	42	1	Fat, bony (inf, med)	26	Euthyroid	4	359.5	9	IV steroid
6	Female	52	1	Fat	32	Hypothyroid	4	675.5	5	IV steroid
7	Female	45	2	Fat, bony (inf, med)	32	Hyperthyroid	4	630.9	8	IV steroid

Abbreviations: CAS, clinical activity score; inf, inferior orbital wall; IV, intravenous; med, medial orbital wall; RT, radiation therapy; SRR, specimen-to-reference ratio; TSI, thyroid-stimulating immunoglobulin.

**Figure 1** Preoperative (left column) and 2 weeks postoperative (right column) photographs of patients who underwent orbital decompression. (a) Patient numbered 4 in Table 2. (b) Patient numbered 7 in Table 2.**Table 3** Univariate logistic regression analysis of various parameters in association with reactivation of GO after orbital decompression

	Reactivation (–)	Reactivation (+)	Exp(B)	95% CI	P-value
Number	85	7			
Age, years	35.2 ± 13.0	50.6 ± 6.4	1.085	1.020–1.154	0.010
Male gender, <i>n</i> (%)	18 (21.2)	3 (42.9)	0.421	0.086–2.061	0.286
Smoker, <i>n</i> (%)	13 (15.3)	5 (71.4)	11.923	2.081–68.299	0.005
GO symptom duration, months	40.1 ± 41.9	47.9 ± 84.8	1.003	0.989–1.018	0.670
GD symptom duration, months	46.4 ± 48.7	56.6 ± 107.5	1.003	0.991–1.015	0.642
Clinical activity score	1.2 ± 0.9	1.9 ± 0.7	2.317	0.898–5.979	0.082
Modified NOSPECS score	4.4 ± 1.7	7.9 ± 2.1	2.329	1.395–3.888	0.001
Gorman score	1.4 ± 0.8	2.9 ± 0.4	4.828	1.769–13.176	0.002
Exophthalmos of severe eye, mm	21.4 ± 2.7	21.6 ± 1.4	1.022	0.765–1.364	0.884
Free T4, ng/ml	1.2 ± 0.3	1.2 ± 0.5	1.178	0.082–17.023	0.904
TSH, mU/l	1.4 ± 2.0	1.3 ± 1.6	0.972	0.643–1.470	0.895
TBII, IU/l	9.3 ± 12.7	7.2 ± 6.3	0.984	0.908–1.066	0.688
TSI, SRR%	303.3 ± 136.3	399.5 ± 194.3	1.005	0.999–1.010	0.103

Abbreviations: CI, confidence interval; Exp(B), odds; GO, Graves' orbitopathy; GD, Graves' disease; SRR, specimen-to-reference ratio; TBII, thyrotropin-binding inhibitor immunoglobulin; TSH, thyroid stimulating hormone; TSI, thyroid-stimulating immunoglobulin.

Bold characters refer to statistical significance ($P < 0.05$).

Table 4 Multivariate logistic regression analysis of various parameters for predicting reactivation of GO after orbital decompression

Independent variable	Exp(B)	Standard error	P-value
<i>Model 1</i>			
Age	1.042	0.049	0.403
Gender	1.093	1.210	0.941
Current smoker	11.291	1.220	0.047
Modified NOSPECS	2.112	0.328	0.023
<i>Model 2</i>			
Age	1.073	0.056	0.206
Gender	12.091	1.633	0.127
Current smoker	41.315	1.793	0.038
Gorman score	8.508	1.065	0.044

Abbreviations: CAS, clinical activity score; Exp(B), odds.
Bold characters refer to statistical significance ($P < 0.05$).

Discussion

This study investigated the short-term incidence and preoperative clinical features of reactivated GO after rehabilitative orbital decompression. Out of the 92 patients with GO included in this study, seven (7.6%) experienced reactivation of GO after orbital decompression, with a mean quiescence period of 36.3 ± 14.3 weeks. Our results indicated that smoking habits and severe ophthalmic symptoms, especially myopathy, were preoperative factors contributing to the reactivation of GO after surgery.

Reactivation of GO is not a common phenomenon and has, therefore, been poorly documented.⁹ Its incidence is not well established and could vary depending on the definition of period of inactivity.^{9,11} Selva *et al* determined the late recurrence rate to be 5%, based on their definition of reactivation as recurrence of inflammation after 5 years of inactivity.⁹ More recently, recurrence of active inflammation after 6 months of inactivity has been defined as reactivation of GO, since a majority of clinicians define the stable phase of GO for orbital decompression as a quiescence period of 6 months. On the basis of this recent definition of recurrence, Patel *et al* reported the incidence of reactivation of GO as 15.7%.¹¹

Reactivation of GO after orbital decompression has been also rarely reported. Baldeschi *et al* reported three such cases among 239 patients (1.3%) who underwent rehabilitative orbital decompression and described the condition as delayed decompression-related reactivation.¹⁵ However, the reported incidence might have been underestimated because the authors excluded patients who received perioperative corticosteroid treatment, in order to examine the natural course and unaffected clinical manifestation of delayed

decompression-related reactivation. In the present study, patients who received perioperative corticosteroid treatment were also included. They were administered corticosteroids for 2 weeks in the same manner as the rest of the included patients, in order to prevent post-operative edema around the operation site. The incidence of reactivation of GO after orbital decompression observed in the present study (7/92 patients; 7.6%) was slightly higher compared with that reported by Baldeschi *et al*¹⁵ (5.9% (14/239), including 11 patients who received perioperative corticosteroid treatment).

In general, many clinicians have used CAS to evaluate disease activity in GO. Such application was first introduced by Mourits *et al*¹⁸ in 1989, in attempts to distinguish active GO patients who respond to corticosteroid treatment. However, despite the increasing use of CAS in clinical offices, it does not always represent real GO activity. For example, although patients with long standing orbital congestion have high CAS, they are only responsive to mechanical decompression and not corticosteroid treatment.¹² In addition, sometimes, postoperative inflammatory reaction cannot be distinguishable to disease activity of GO after orbital decompression when it assessed with CAS. In such cases, short-term postoperative corticosteroid administration can help with the selection process, since inflammation will arise again after corticosteroid tapering in real active phase of GO, and not in just postoperative inflammatory reaction. In the cases we observed, postoperative inflammatory reaction subsided with corticosteroid administration, and did not arise after corticosteroid cessation. The resulting CAS decreased after orbital decompression, due to resolution of orbital congestion and corticosteroid administration.

The average interval of inactivity between orbital decompression and reactivation in the present study was 36.3 ± 14.3 weeks (range, 26–68 weeks). The mean interval between the appearance of the first symptom of GO and reactivation of GO observed in our study (4.7 years) was shorter compared with that reported by Patel *et al*¹¹ (10.3 years; range, 2–56 years). Although the short duration of follow-up could have affected the results of the present study, we considered immune reaction triggered by orbital decompression to be the main reason for early reactivation. Surgical trauma could activate antigen-presenting cells and orbital fibroblasts that produce proinflammatory cytokines, including interleukin-2, interferon gamma, and tumor necrosis factors. In addition, exposure of orbital tissue to exogenous pathogens or endogenous normal flora also could induce inflammation.¹⁵

Smoking is a well-known risk factor for GO. A previous case-control study reported an OR of 7.7 for the association between smoking and incidence of GO.²¹

The severity of GO in smokers tends to be greater compared with that in nonsmokers.²² Smoking accelerates the progression of GO after radioiodine therapy and decreases the effect of corticosteroid or orbital irradiation therapy.²³ In the present study, patients with a smoking habit at the time of surgery were considered smokers. Our results indicated that smoking was a positive and independent factor for the reactivation of GO after orbital decompression, with ORs of 11.291 (model 1) and 41.315 (model 2), which were higher compared with that reported in a previous cohort study without surgery.²¹ Therefore, in case of patients who are expected to undergo orbital decompression, discontinuation of smoking is important for the prevention of reactivation after surgery.

On the basis of clinical features, two different phenotypes of GO have been described—type I with predominant retrobulbar fat proliferation and type II with predominant extraocular muscle enlargement.²⁴ Patients with type I GO usually present with symmetric proptosis with minimal or no diplopia, whereas those with type II GO often exhibit diplopia with restrictive myopathy. The reason behind the differential involvement of orbital fat and extraocular muscle in GO has thus far not been well defined. In a previous *in vitro* study, orbital fibroblasts were revealed as playing a certain role in the pathogenesis of both subtypes of GO, interacting with cytokines, prostaglandins, and immune cells.²⁵ In the present study, preoperative Gorman diplopia score was revealed to be a significant factor for reactivation of GO after orbital decompression. In other words, the degree of preoperative restrictive myopathy is associated with the postoperative reactivation of GO. This finding is supported by those of Nunery *et al*,²⁴ who suggested that type II GO might cause orbital inflammation more frequently than type I GO. In general, orbital decompression decreases orbital tissue pressure and improves orbital congestive conditions. In addition, removal of orbital fat tissues containing fibrocytes and auto-reactive lymphocytes decreases the production of inflammatory cytokines.^{26,27} However, the presence of an antigenic component of muscle tissue that was not removed during orbital decompression was thought to be a possible reason for immune response despite the anti-inflammatory effect of the surgery.²⁸

Because of the retrospective study design and the small number of patients with reactivated GO, a major limitation of this study is the interpretation of collected data. Since this was not a comparative controlled study, our findings are subject to the potential influence of factors that were not evaluated in this study. In addition, our mean follow-up duration (2.9 ± 1.3 years) was relatively short. Further studies with longer durations of follow-up are required for the evaluation of late-onset

reactivation of GO. Also, in order to determine whether or not orbital decompression affects GO reactivation in patients with restrictive myopathy, further case-control study comparing decompressed and non-decompressed GO patients would be needed.

Our results indicate that reactivation of GO after orbital decompression tends to occur in patients who experience severe preoperative ophthalmic symptoms, especially restrictive myopathy. In addition, smoking status at the time of surgery is a significant positive, independent factor for reactivation of GO after orbital decompression. Patients presenting with these factors should be carefully monitored for reactivation of GO even if it is observed to be inactive after orbital decompression. Especially, since smoking is a modifiable risk factor, patients should quit smoking before undergoing orbital decompression. Further investigation of the inflammatory mechanisms of GO and prospective controlled studies including large numbers of patients are required.

Summary

What was known before

- Reactivation of Graves' orbitopathy is not common phenomenon but periocular surgery including orbital decompression is associated with reactivation of Graves' orbitopathy.

What this study adds

- A smoking habit and restrictive myopathy are contributing factors to the reactivation of Graves' orbitopathy after orbital decompression.

Conflict of interest

The authors declare no conflict of interest.

Acknowledgements

This study was supported by a grant of the Korea Health Technology R&D Project through the Korea Health Industry Development Institute (KHIDI), funded by the Ministry of Health and Welfare, Republic of Korea (grant number: HI14C1324).

References

- 1 Bahn RS. Clinical review 157: Pathophysiology of Graves' ophthalmopathy: the cycle of disease. *J Clin Endocrinol Metab* 2003; **88**(5): 1939–1946.
- 2 Bahn RS. Graves' ophthalmopathy. *N Engl J Med* 2010; **362**(8): 726–738.
- 3 Chalvatzis NT, Tzamalakis AK, Kalantzis GK, El-Hindy N, Dimitrakos SA, Potts MJ. Safety and efficacy of combined immunosuppression and orbital radiotherapy in thyroid-

- related restrictive myopathy: two-center experience. *Eur J Ophthalmol* 2014; **24**(6): 953–959.
- 4 Kumar S, Nadeem S, Stan MN, Coenen M, Bahn RS. A stimulatory TSH receptor antibody enhances adipogenesis via phosphoinositide 3-kinase activation in orbital preadipocytes from patients with Graves' ophthalmopathy. *J Mol Endocrinol* 2011; **46**(3): 155–163.
- 5 Zhang L, Bowen T, Grennan-Jones F, Paddon C, Giles P, Webber J *et al*. Thyrotropin receptor activation increases hyaluronan production in preadipocyte fibroblasts: contributory role in hyaluronan accumulation in thyroid dysfunction. *J Biol Chem* 2009; **284**(39): 26447–26455.
- 6 Asman P. Ophthalmological evaluation in thyroid-associated ophthalmopathy. *Acta Ophthalmol Scand* 2003; **81**(5): 437–448.
- 7 Wiersinga WM, Bartalena L. Epidemiology and prevention of Graves' ophthalmopathy. *Thyroid* 2002; **12**(10): 855–860.
- 8 Bartley GB. Rundle and his curve. *Arch Ophthalmol* 2011; **129**(3): 356–358.
- 9 Selva D, Chen C, King G. Late reactivation of thyroid orbitopathy. *Clin Experiment Ophthalmol* 2004; **32**(1): 46–50.
- 10 Bunting H, Creten O, Muhtaseb M, Shuttleworth G. Late reactivation of thyroid associated ophthalmopathy causing optic neuropathy. *Postgrad Med J* 2008; **84**(993): 388–390.
- 11 Patel P, Khandji J, Kazim M. Recurrent thyroid eye disease. *Ophthal Plast Reconstr Surg* 2015; **31**(6): 445–448.
- 12 Dolman PJ. Evaluating Graves' orbitopathy. *Best Pract Res Clin Endocrinol Metab* 2012; **26**(3): 229–248.
- 13 Kingdom TT, Davies BW, Durairaj VD. Orbital decompression for the management of thyroid eye disease: an analysis of outcomes and complications. *Laryngoscope* 2015; **125**(9): 2034–2040.
- 14 Zhang-Nunes SX, Dang S, Garneau HC, Hwang C, Isaacs D, Chang SH *et al*. Characterization and outcomes of repeat orbital decompression for thyroid-associated orbitopathy. *Orbit* 2015; **34**(2): 57–65.
- 15 Baldeschi L, Lupetti A, Vu P, Wakelkamp IM, Prummel MF, Wiersinga WM. Reactivation of Graves' orbitopathy after rehabilitative orbital decompression. *Ophthalmology* 2007; **114**(7): 1395–1402.
- 16 Eckstein AK, Plicht M, Lax H, Neuhauser M, Mann K, Lederbogen S *et al*. Thyrotropin receptor autoantibodies are independent risk factors for Graves' ophthalmopathy and help to predict severity and outcome of the disease. *J Clin Endocrinol Metab* 2006; **91**(9): 3464–3470.
- 17 Bahn RS, Gorman CA. Choice of therapy and criteria for assessing treatment outcome in thyroid-associated ophthalmopathy. *Endocrinol Metab Clin North Am* 1987; **16**(2): 391–407.
- 18 Mourits MP, Prummel MF, Wiersinga WM, Koornneef L. Clinical activity score as a guide in the management of patients with Graves' ophthalmopathy. *Clin Endocrinol (Oxf)* 1997; **47**(1): 9–14.
- 19 Sanders J, Jeffreys J, Depraetere H, Evans M, Richards T, Kiddie A *et al*. Characteristics of a human monoclonal autoantibody to the thyrotropin receptor: sequence structure and function. *Thyroid* 2004; **14**(8): 560–570.
- 20 Lee KH, Jang SY, Lee SY, Yoon JS. Graded decompression of orbital fat and wall in patients with Graves' orbitopathy. *Korean J Ophthalmol* 2014; **28**(1): 1–11.
- 21 Prummel MF, Wiersinga WM. Smoking and risk of Graves' disease. *JAMA* 1993; **269**(4): 479–482.
- 22 Pfeilschifter J, Ziegler R. Smoking and endocrine ophthalmopathy: impact of smoking severity and current vs lifetime cigarette consumption. *Clin Endocrinol (Oxf)* 1996; **45**(4): 477–481.
- 23 Bartalena L, Marcocci C, Tanda ML, Manetti L, Dell'Unto E, Bartolomei MP *et al*. Cigarette smoking and treatment outcomes in Graves ophthalmopathy. *Ann Intern Med* 1998; **129**(8): 632–635.
- 24 Nunery WR, Martin RT, Heinz GW, Gavin TJ. The association of cigarette smoking with clinical subtypes of ophthalmic Graves' disease. *Ophthal Plast Reconstr Surg* 1993; **9**(2): 77–82.
- 25 Hatton MP, Rubin PA. The pathophysiology of thyroid-associated ophthalmopathy. *Ophthalmol Clin North Am* 2002; **15**(1): 113–119.
- 26 Oh SR, Tung JD, Priel A, Levi L, Granet DB, Korn BS *et al*. Reduction of orbital inflammation following decompression for thyroid-related orbitopathy. *Biomed Res Int* 2013; **2013**: 794984.
- 27 Verity DH, Rose GE. Acute thyroid eye disease (TED): principles of medical and surgical management. *Eye (Lond)* 2013; **27**(3): 308–319.
- 28 Kaspar M, Archibald C, De BA, Li AW, Yamada M, Chang CH *et al*. Eye muscle antibodies and subtype of thyroid-associated ophthalmopathy. *Thyroid* 2002; **12**(3): 187–191.