ARTICLE

The dystrophic retina in multisystem disorders: the electroretinogram in neuronal ceroid lipofuscinoses

RICHARD G. WELEBER

Abstract

The neuronal ceroid lipofuscinoses (NCL) are neurodegenerative disorders with psychomotor deterioration, seizures, visual failure and premature death, all associated with abnormal storage of lipoproteins within lysosomes. The most common forms of NCL are an infantile form (INCL, *CLN1*), a late infantile form (LINCL, *CLN2*) and a juvenile onset form (JNCL, *CLN3*). The electroretinogram (ERG) is abnormal early in all three of these forms and eventually is totally ablated. The purpose of this report is to describe the ERG in INCL, LINCL and JNCL. The ERGs of 7 patients who were examined by the author over the past 15 years were reviewed. Ganzfeld ERG responses were recorded using the ISCEV standard protocol and an intensity response series over a 3.7 log unit range. The earliest ERG manifestation of INCL is a marked loss of the scotopic and photopic b-wave with relative preservation of the a-wave; this defect, which was evident for both rods and cones, suggests preservation of photoreceptor outer segment function with severe disturbance of transmission of the signal to the second-order neuron, the bipolar cells. For LINCL, the rod responses were mildly abnormal but more preserved than in INCL or JNCL. The cone b-wave amplitudes in patients with early LINCL were severely subnormal with prolonged implicit times. Patients with JNCL invariably showed severe to profound ERG abnormalities when first tested, with essentially no rod-mediated activity and marked loss of a-wave amplitudes with even greater loss of b-wave amplitudes, creating electronegative configuration waveforms. Differences in the ERG responses were thus found that provide further clues to the earliest site of pathology within the retina.

Key words Electroretinogram, Neuronal ceroid lipofuscinosis, Retina

The neuronal ceroid lipofuscinoses (NCL) are a group of progressive neurodegenerative disorders characterised by accumulation of complex storage material within lysosomes accompanied by psychomotor deterioration, eventually leading to a vegetative state, seizures, visual failure from retinal degeneration and premature death.[1] Four classical forms of NCL exist: three childhood-onset forms, which are all autosomal recessive, and one adult-onset form, which may be autosomal recessive or dominant. The three childhood forms are: (1) an infantile-onset form (INCL, *CLN1*), also called Haltia-Santavuori disease, Hagberg-Santavuori disease or simply the Finnish form, which usually presents at age 8–24 months with severe psychomotor retardation, blindness and microcephaly;[2,3] (2) a late infantile-onset form (LINCL, *CLN2*), also called Jansky–Bielschowsky disease, which usually presents at age 2.5–4.0 years with ataxia, loss of speech, regression of developmental milestones, seizures and later loss of vision;[4–7] and (3) a juvenile-onset form (JNCL, *CLN3*), also called Batten–Mayou, Spielmeyer–Vogt disease or Spielmeyer–Sjögren syndrome, which presents at 4.5–8.0 years of age with visual acuity loss that over a year or more progresses relentlessly to loss of virtually all useful vision (see references[1,8,9] for reviews). The fourth classical form, the adult-onset disorder (ANCL, *CLN4*), also called Kufs disease, usually presents as a motor disturbance without visual symptoms or findings.[10,11] Although Kufs disease is believed to be an autosomal recessive trait, autosomal dominant inheritance has been described.[12] Besides the classical forms, as many as 15 atypical forms have been described, some of which may be allelic to certain of the classical forms.[13]

R.G. Weleber ✉
Oregon Health Sciences University
Casey Eye Institute
3375 S.W. Terwilliger Blvd
Portland
OR 97201-4197, USA
Tel: +1 (503) 494-8386
Fax: +1 (503) 494-6864
e-mail: weleberr@ohsu.edu

Supported in part by The Foundation Fighting Blindness and Research to Prevent Blindness

Eye (1998) 12, 580–590

The visual failure in the three childhood forms involves central vision early and eventually results in profound visual loss, and often complete blindness, within a few years. The electroretinogram (ERG) becomes abnormal early in the course of all these disorders and within a few years is usually totally abolished to standard single flash recording techniques. Goebel states that the ERG becomes flat (undetectable to standard techniques) for LINCL between ages 3 and 4 years and for JNCL between 5 and 7 years.[1] Visual symptoms and abnormalities on electrophysiological testing are rare and occur late in the course of ANCL.[14]

Although ERGs have been reported in the various forms of childhood NCL,[6,15–23] the techniques used varied considerably and no previous reports have utilised the recent ISCEV standard for clinical electroretinography.[24,25] This paper reports the ISCEV standard ERG findings on 7 patients with early stages of the childhood forms of NCL (INCL, LINCL and JNCL). The ERGs showed differences suggesting that the retinal effects of the metabolic defect occur at different levels and for different cell types among the three forms of NCL.

Patients and methods

The patients were all examined by the author. The diagnosis was established by the clinical course, ophthalmoscopy, abnormal ERG, and electron microscopy of conjunctival biopsies, which showed granular inclusions in the patient with INCL, curvilinear inclusions in the patients with LINCL and fingerprint inclusions in the patients with JNCL.[26,27] In all cases, the features and findings were diagnostic for the specific type of NCL according to conventionally accepted criteria.[28]

The ERGs were performed according to published methods that included, but were not confined to, the ISCEV standard.[29–31] Intravenous propofol sedation was used for the patient with INCL reported as case 1 and for the patient with JNCL reported as case 6. Chloral hydrate (50–100 mg/kg) was administered to the patients with LINCL (cases 2, 3 and 4). Patients reported as cases 5 and 7 with JNCL were tested unsedated. Pupils were fully dilated and recordings began after 45 min of dark adaptation. The ERGs were recorded with 0.1–1000 Hz bandpass using bipolar Burian–Allen contact lens electrodes and a Ganzfield stimulator that presented intensities over a 3.7 log range (+0.6 to −3.1 log cd-s/m^2). Oscillatory potentials were isolated from the full-frequency responses using a digital filter (100–300 Hz bandpass). Scotopically matched blue and red stimuli tested dark-adapted rods and cones. Flicker of 30 Hz was presented without background. The eyes were light-adapted for 10 min at 34 cd/m^2 prior to photopic testing. Flicker of 30 Hz was again presented with background. Discrete Fourier transform (DFT) analysis was used to remove drift and noise from the flicker responses by returning all frequencies above the fundamental or the fundamental (30 Hz) alone.[32]

Case reports

Infantile NCL

Case 1

This female child was the product of an uneventful pregnancy and delivery. Birth weight and head circumference were normal. Her parents were not consanguineous. She was considered to be developing normally until age 1 year. She sat alone at 6 months, began to crawl at 9 months, pulled-to-stand at 10 months and began to cruise by 11 months. She had acquired two or three words at 10 months but by 1 year of age she was noted to begin to regress in milestones, and shortly lost useful speech. Vision was normal until 14 months of age at which time she became less visually attentive and eye contact began to fail. Eye rubbing occurred at age 15 months but this stopped when at age 18 months she began to show further evidence of visual impairment and lost the ability to feed herself and to cruise.

The head circumference was normal at 2.5 months of age (39.0 cm; 75th percentile) but by 10.5 months of age her head circumference had begun to decrease relative to previous measures (44.5 cm; 50th percentile) and by age 23 months was clearly abnormal (45.0 cm; 5th percentile), indicating failure of head growth and acquired microcephaly. Height and weight growth were normal. Weakness of her left upper and both lower extremities was noted at age 18 months leading to the diagnosis of spastic diplegia; an MRI scan showed delayed myelination in the periventricular regions and borderline prominence of the cerebral sulci over the convexities and the occipital horns. The only significant finding on an extensive metabolic evaluation was an inexplicably low serum IgA level.

An electroencephalogram (EEG) was normal at age 19 months. At 20 months, she had no fixation or following of objects or lights but no nystagmus. Her optic discs were pink but the foveal reflex was absent and the retinal vessels were mildly attenuated (Fig. 1). An ERG performed using intravenous propofol sedation was markedly abnormal (Fig. 2)., showing a normal a-wave but a severely subnormal b-wave both scotopically and photopically. This electronegative configuration suggested the primary defect did not affect phototransduction in the outer segments but did severely disturb transmission (either pre- or post-synaptic) to the generators of the b-waves (bipolars) for both rod and cone activity. A conjunctival biopsy showed granular osmophilic membrane-bound inclusions with occasional lamellar deposits within endothelial cells (Fig. 3). An assay for palmitoyl-protein thioesterase (PPT) was severely subnormal and molecular testing showed homozygosity for the common Arg151stop nonsense mutation of the PPT gene (Sandra L. Hofmann, personal communication 1997). The child began to have seizures at age 23 months. At 27 months of age, the optic discs were mildly pale, the retinal vessels moderately attenuated, and the macular reflex blunted and mottled.

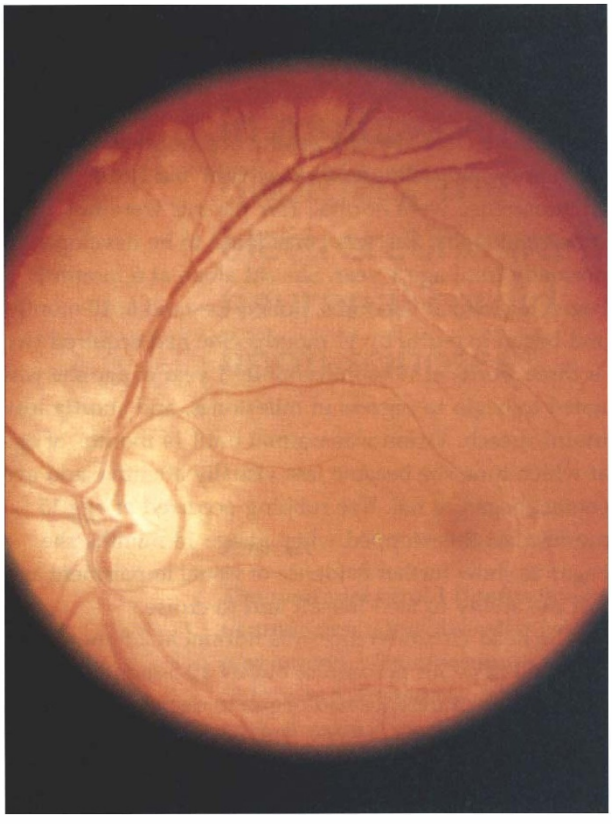

Fig. 1. *Fundus appearance of the left eye of case 1 at age 19 months, showing mildly attenuated retinal vessels.*

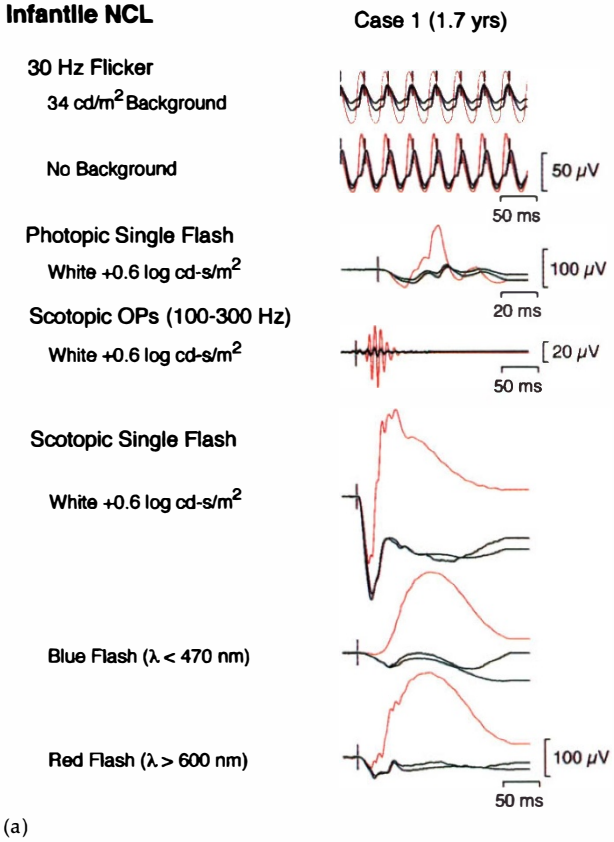

(a)

Fig. 2. *ERG for case 1 at age 19 months. (a) ISCEV standard ERG. (b) Scotopic intensity response series. The tracings from the patient's right and left eyes are shown in black. The tracings in red are the averaged tracing for both eyes of a normal subject of similar age (1.6 years).*

Late infantile NCL

Case 2

This child is the younger sister of case 3. Because her older sister had carried the diagnosis of LINCL, the parents were concerned when case 2 began to fall without reason at age 1.5 years. She had central, steady fixation with each eye and her ophthalmic examination was normal at this time. A skin biopsy found no ultrastructural abnormalities suggestive of Batten disease. At age 2.5 years she began to have frank drop attacks that were initially felt not to be seizures by her paediatrician. At age 3.0 years she was again examined. Her speech and motor skills were not developing normally and her gait was unsteady. She tended to look to the side or below objects of regard rather than centrally. Her fixation was eccentric but steady. Very mild retinal vessel attenuation was evident on fundus examination with no significant disc atrophy or abnormal pigmentation (Fig. 4).

An ERG showed normal to mildly subnormal and prolonged rod responses and severely subnormal, markedly prolonged cone b-wave responses (Fig. 5). The light-adapted cone a-wave was 72% of normal mean, whereas the cone b-wave was only 24% of normal mean; rod b-waves were 78% of normal mean. The oscillatory

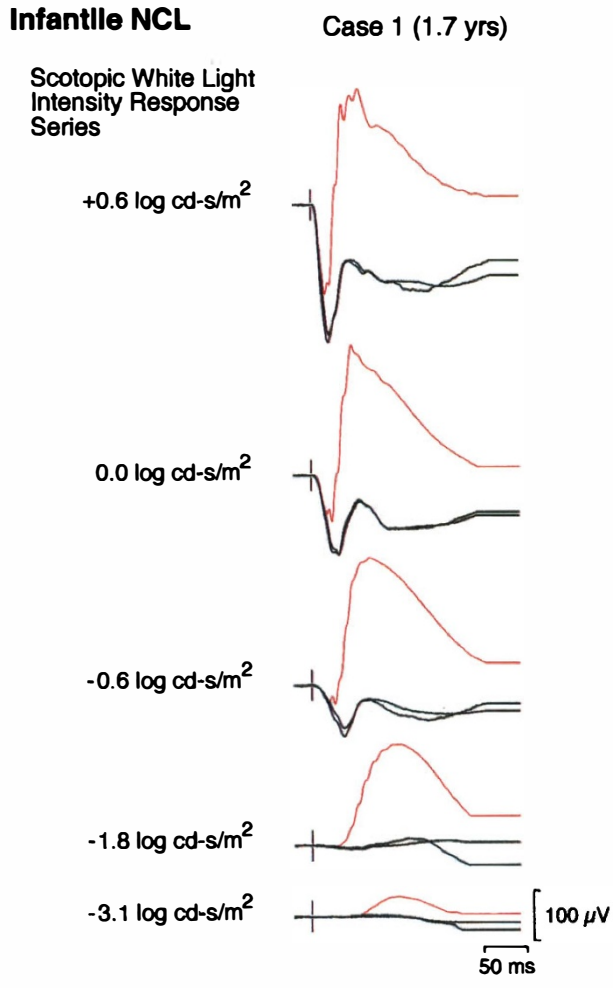

(b)

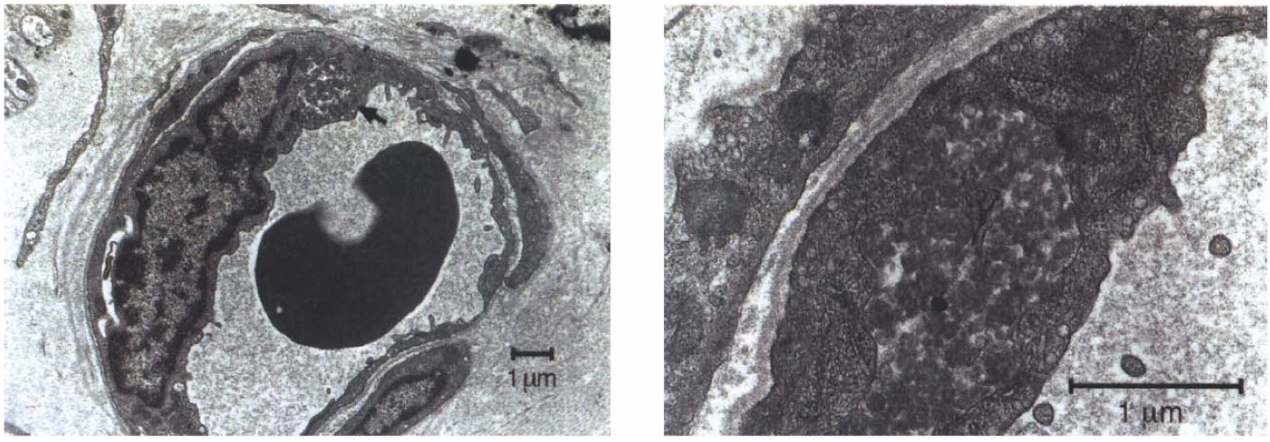

(a) (b)

Fig. 3. *(a) Conjunctival biopsy for case 1, showing granular inclusions (arrow). (b) Higher power of another field showing the crumb-like appearance of the granular inclusions.*

potentials were subnormal and prolonged. A conjunctival biopsy disclosed numerous curvilinear inclusions within pericytes and endothelial cells.

Case 3

This female, the older sister of case 2, was considered normal except for delayed speech development until the onset of seizures at 33 months of age. A CT scan and initial EEG were normal. At 34 months of age her head circumference was normal at 49.9 cm. At 35 months of age she was 7 months delayed in receptive language and 11 months delayed in expressive language skills. An EEG at age 36 months showed cerebral seizures with prominent spike and slow waves associated with extreme sensitivity to photic stimulation. A second CT scan revealed mild cortical and cerebellar atrophy. A brain stem auditory evoked potential was normal. Her seizures were only partially controllable with clonazepam and valproic acid. Electrophysiological testing elsewhere at 4.0 years of age found a normal visual evoked potential (VEP) and a 'probably normal' ERG but testing was conducted only under unspecified mesopic conditions. A skin biopsy suggested late infantile NCL but was not felt to be diagnostic.

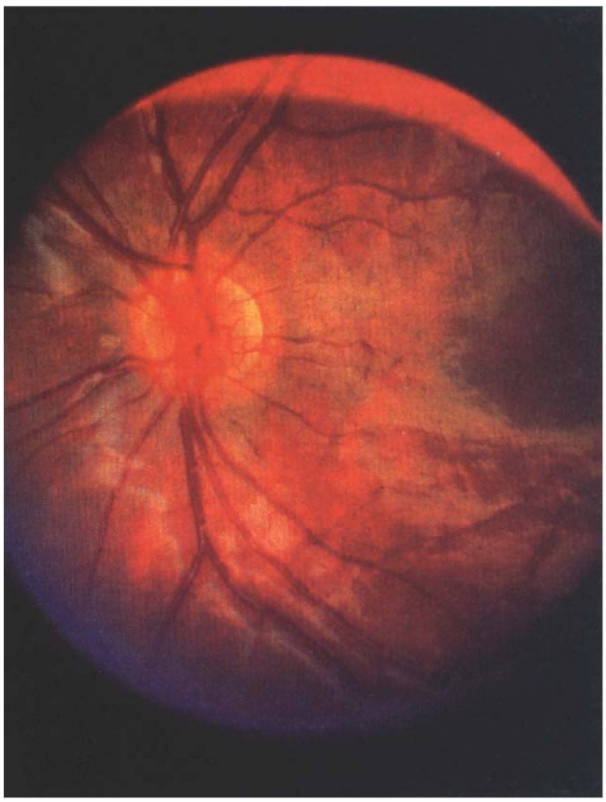

Fig. 4. *Fundus of the left eye of case 2 at age 3.0 years.*

At 4.2 years of age she allegedly had no difficulty visually at night or during the day and would fix and follow a penlight and finger puppets. Ocular motility was normal. Fundus appearance was normal except for possible mild narrowing of retinal vessels.

Ganzfeld ERG at 4.3 years of age demonstrated low range normal rod responses with dark-adapted and light-adapted cone-mediated responses that were severely subnormal in amplitude and prolonged in b-wave implicit time (Fig. 5). The light-adapted cone a-wave was 38% of normal mean, whereas the cone b-wave was only 6% of normal mean; rod b-waves were 80% of normal mean. The oscillatory potentials of the ERG were subnormal and prolonged. A bulbar conjunctival biopsy revealed intracytoplasmic aggregates of curvilinear profiles of the type described in late infantile NCL (Fig. 6).

She began to experience more frequent and uncontrollable seizures. At 4.6 years, she was felt to be visually impaired, her pupils were only minimally reactive to light, and her retinal vessels mildly attenuated. At 4.8 years she had deteriorated to the point where she was completely dependent on her parents for all her care and at 5.0 years all vision was lost. At 5.5 years of age her fundus examination showed severely attenuated vessels and waxy optic nerve head pallor (Fig. 7).

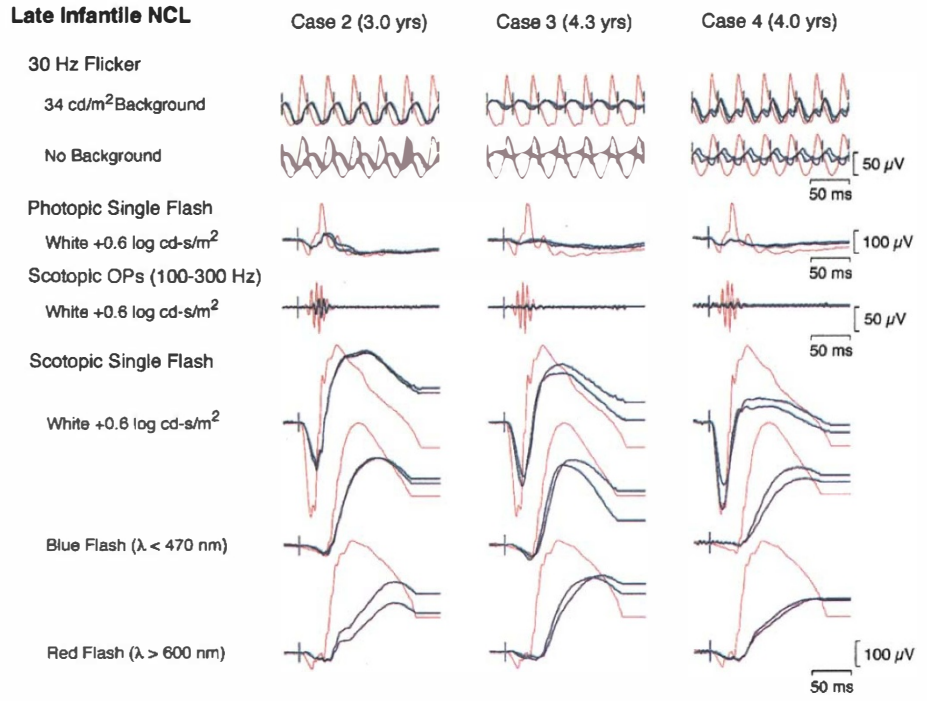

(a)

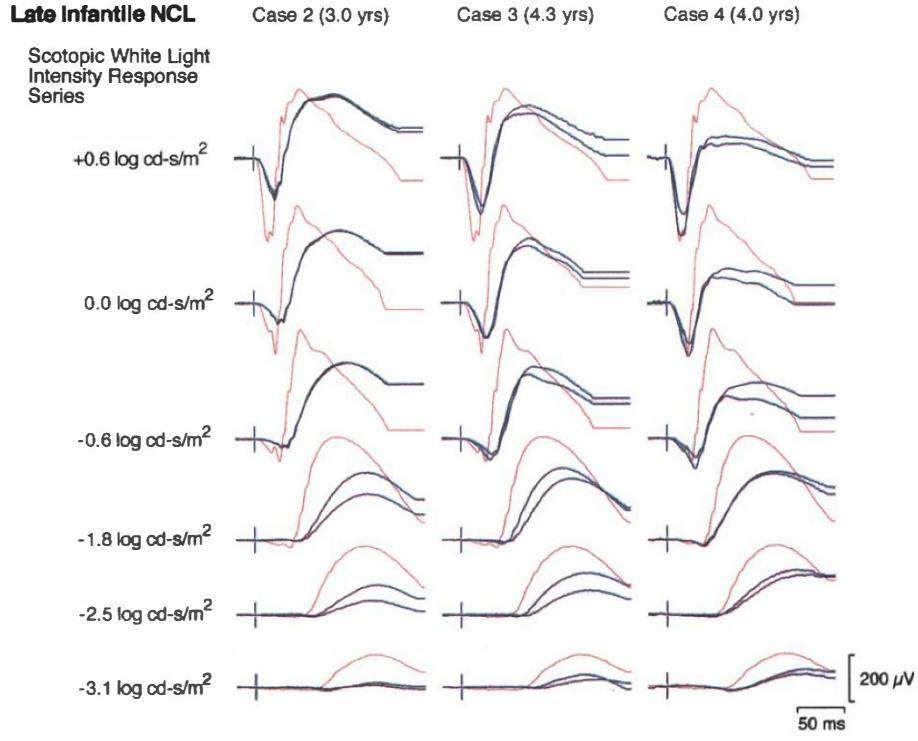

(b)

Fig. 5. *ERG for cases 2, 3 and 4. (a) ISCEV standard ERG. (b) Scotopic intensity response series. For each column, the tracings from the patient's right and left eyes are shown in black. The tracings in red are those of a normal subject.*

Case 4

This female was born to normal, non-consanguineous parents. Although her head circumference began to fall away from the normal curve at age 12 months, she was otherwise normal until she had a non-febrile seizure at 36 months of age. Just prior to this, she was walking, running and talking in full sentences. Her head circumference at age 36 months was 47 cm (well below the 5th percentile). Because she appeared otherwise normal on examination, no tests or medications were ordered. One month later, following another seizure, a CT scan and EEG were done, both of which were normal. The seizures were predominantly right focal motor in character, occurred five to six times daily, and were 2–3 min in duration. Phenobarbital and dilantin resulted in poor control, and at 39 months of age she began to

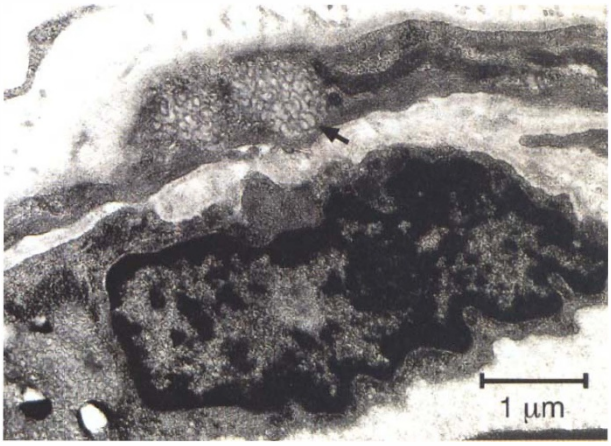

Fig. 6. *Bulbar conjunctiva of case 3 at age 4.3 years, showing curvilinear inclusions (arrow).*

experience myoclonic seizures, after which she began to lose expressive and receptive language skills. A second EEG was normal. Valproic acid, carbamazepine, and clonazepam were unsuccessful in controlling her seizures; neurological deterioration continued. At 41 months a CT scan showed cerebral atrophy and the EEG was read as showing diffuse slowing suggestive of epileptiform activity in the right posterior temporoparietal region. At 42 months of age her head circumference was still 47 cm. At 3 years 9 months she lost her speech and became unable to walk.

Examination at 3 years 10 months revealed an aware, but listless-appearing child with cold, mottled cyanotic extremities except for the left hand, which was flushed, warm and hyperaemic. Deep tendon reflexes were very brisk in the lower extremities with 3–4 beats of clonus at the ankle. Babinski's responses were equivocal. A sleep EEG demonstrated numerous single-spike discharges over the right occipital area. On several occurrences they spread to involve both hemispheres and were followed by 1–2 s of suppression. The waking EEG showed frequent paroxysmal spike and slow wave activity with marked potentiation of the paroxysmal activity by photic stimulation. Electron microscopy of buffy coat leucocytes revealed intracytoplasmic curvilinear and fingerprint profiles, consistent with NCL.

Although there was no history of visual disability, ophthalmic examination at 4.0 years of age showed poor fixation and following of penlight or objects. Her pupils reacted sluggishly to light. Although the discs appeared pink and uncupped, the retinal vessels were mildly attenuated and the entire fundus including the macular regions had fine granularity and mottling of the retinal pigment epithelium.

Ganzfeld ERG demonstrated severely subnormal dark- and light-adapted cone-mediated responses with prolonged cone b-wave implicit times (Fig. 5). The cone a-wave was more preserved at 34 μV (70% of normal mean, which is low normal) compared with the cone b-wave, which at 26 μV was 10% of normal mean (severely subnormal). The light-adapted cone 30 Hz flicker implicit time was prolonged (37.4 ms scotopic, normal < 32.3 ms; 35.1 ms photopic, normal < 28 ms).

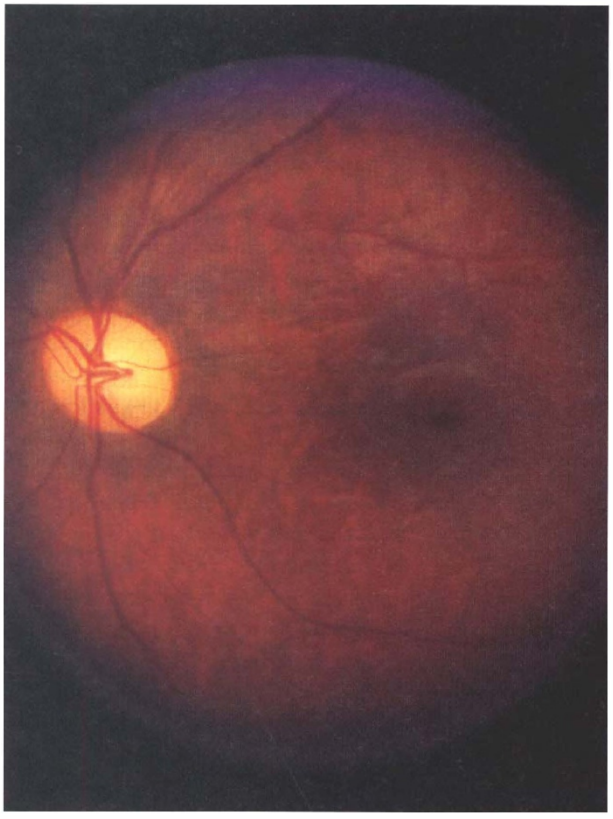

Fig. 7. *Fundus appearance of the left eye of case 3 at age 5.5 years, showing severely attenuated vessels and pale optic nerve heads.*

The dark-adapted rod responses were low normal to mildly subnormal (62% of normal mean) but the rod b-wave implicit times were prolonged (118 ms, normal 69–88 ms). A bulbar conjunctival biopsy showed the diagnostic curvilinear membranous structures within the cytoplasm of endothelial cells and pericytes (Fig. 8).

The mother subsequently became pregnant. After informed consent the parents allowed amniocentesis, which disclosed the characteristic inclusions on electron microscopy of amniotic fibroblasts.[33] The parents had decided prior to the procedure to carry the pregnancy to term. NCL was confirmed by skin biopsy of the live-born male infant[34] who, at 3 years of age, began to have

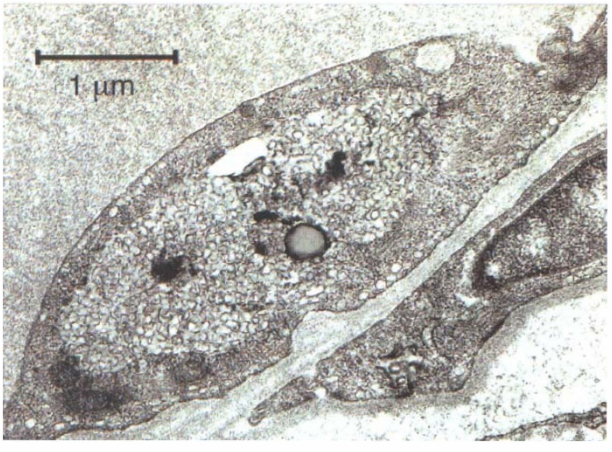

Fig. 8. *Conjunctival biopsy of case 4 at age 4.0 years, showing curvilinear inclusions.*

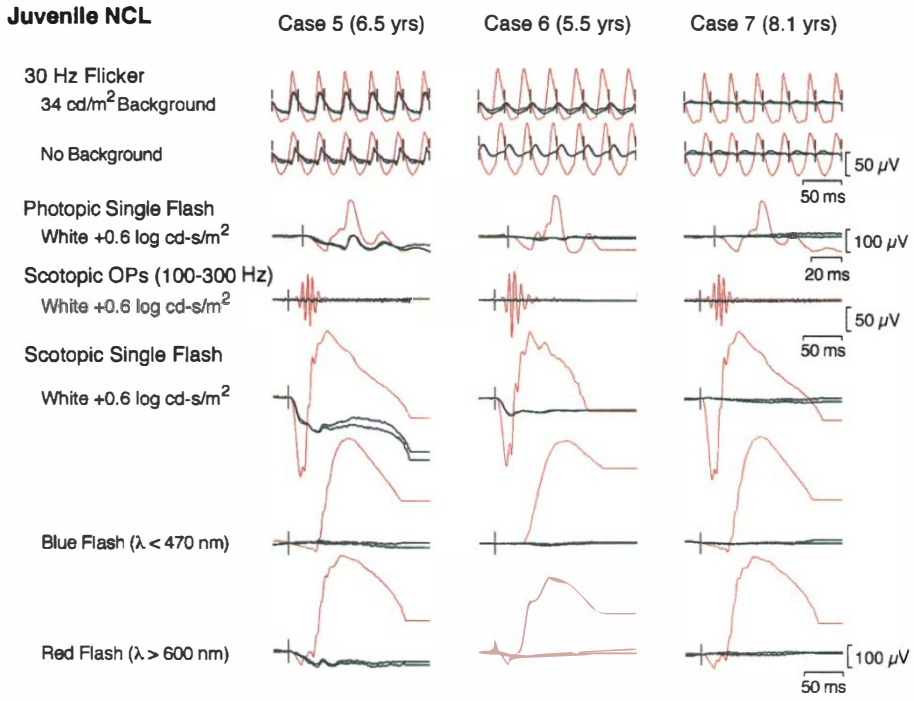

(a)

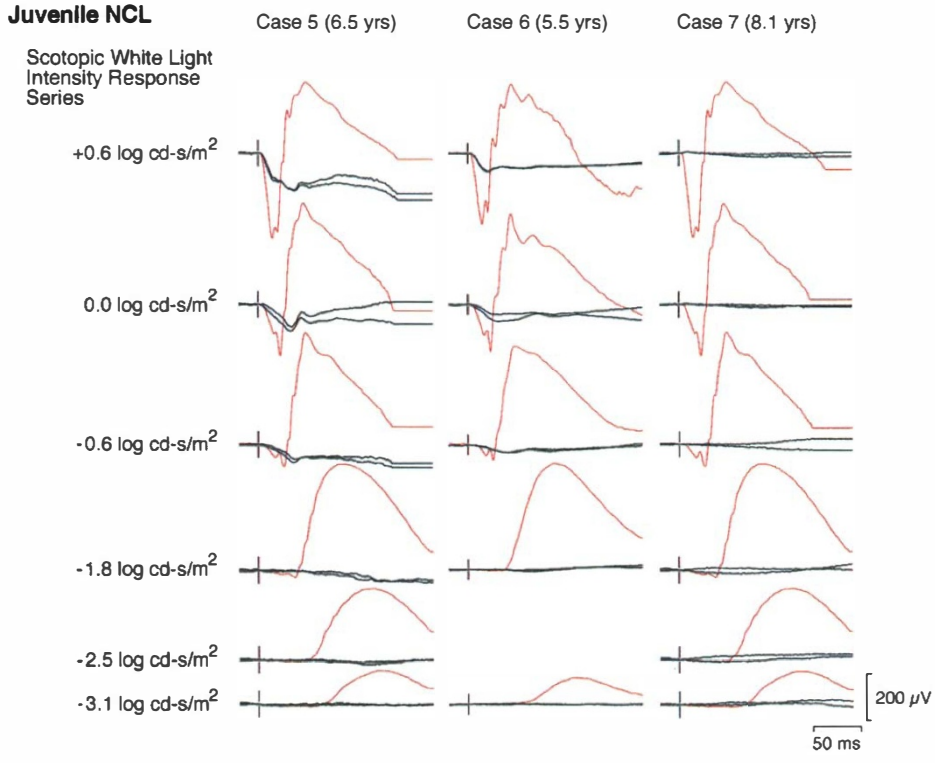

(b)

Fig. 9. *ERG of cases 5, 6 and 7. (a) ISCEV standard ERG. (b) Scotopic intensity response series. For each column, the tracings from the patient's right and left eyes are shown in black. The tracings in red are for normal subjects of the same age range. All responses were elicited using the same Ganzfeld stimulator, but because a different computer system was used for recording the responses for case 6, a different normal is shown.*

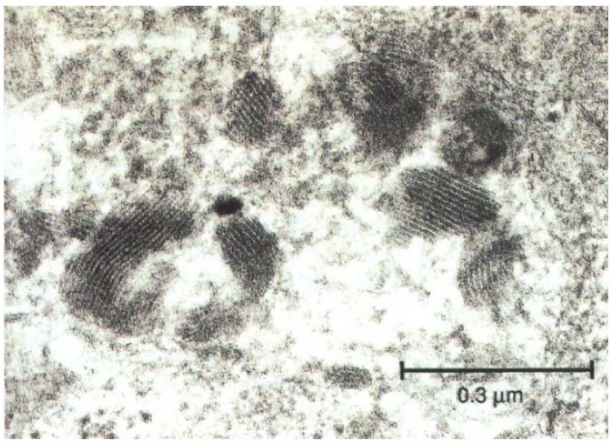

Fig. 10. *Conjunctival biopsy of case 5 at age 8.0 years, showing fingerprint inclusions. (Reproduced with permission from Weleber,[9] figure 20–121, A. p.441.)*

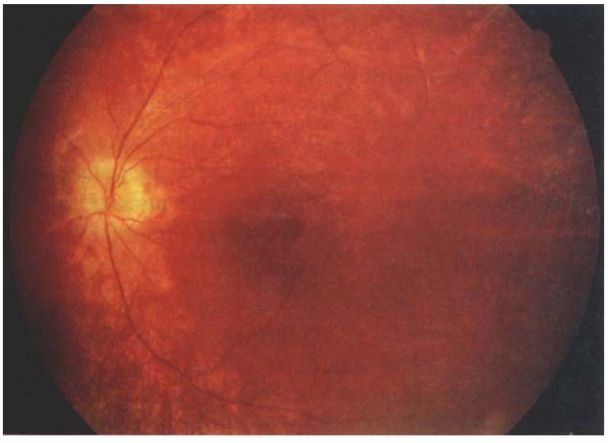

(a)

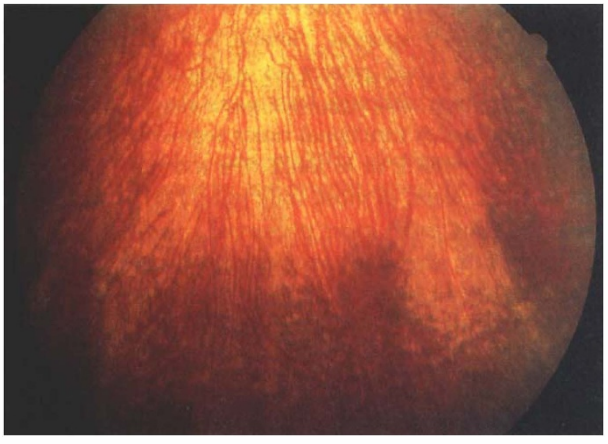

(b)

Fig. 11. *(a) Posterior pole of the left eye of case 7 at 8 years of age, showing attenuated vessels, pale optic discs and bull's eye maculopathy. (b) Inferior retina of the right eye of case 7, showing pigment dispersion and granularity.*

seizures and now appears to be following a course identical to his sister. Case 4 died at age 8 years. Autopsy permission was denied.

Juvenile NCL

Case 5

This young girl's case history has been published previously (see Weleber[9], case 52, pp. 438–41). She began to lose vision at age 3.5–4 years and was first thought to have a cone or cone–rod dystrophy with a bull's eye maculopathy. Her vision deteriorated to 20/70 at 6.5 years of age at which time she had an ERG (Fig. 9) that showed, essentially, no detectable rod responses and severely subnormal cone responses with an electronegative configuration both scotopically and photopically. At 165 µV, her scotopic a-wave amplitude was only 53% of the normal mean. Her vision continued to deteriorate and at age 8 years was 10/400 for each eye. A conjunctival biopsy disclosed numerous fingerprint inclusions within endothelial cells (Fig. 10). Neuropsychiatric testing revealed mild difficulty with central processing. Molecular testing found heterozygosity for the common 1.02 kb deletion of *CLN3* (Krystyna E. Wiśniewski, personal communication).[35]

Case 6

This boy presented at age 5.5 years with a history of poor vision for the previous 3 months. He appeared to have greatest difficulty seeing objects straight ahead. His night vision was poor but his peripheral field was grossly intact in good illumination. The visual acuity was 20/100 and he was unable to identify any of the AOHRR colour plates correctly. Fixation was eccentric. Fundus examination disclosed pink discs, mildly attenuated retinal vessels, a bull's eye maculopathy and fine pigment dispersion with granularity of the peripheral retina. The ERG was severely abnormal with severe loss of rod and cone responses, with greater loss of the b-wave than for that of the a-wave (Fig. 9). Cone b-wave implicit times were prolonged. A conjunctival biopsy showed fingerprint and rare curvilinear inclusions within endothelial cells.

Case 7

This girl was normal until age 7 years when she experienced difficulty adjusting from light to dark environments and blurred vision. At 8 years of age her visual acuity was 20/40, J3 right eye and 20/30, J3 left eye but she had moderately defective stereopsis and colour vision. Ophthalmoscopy disclosed optic disc pallor, attenuated retinal vessels, an incomplete bull's eye pigment epithelial defect in the maculas, and pigmentary dispersion in the mid-and-far periphery of the fundus bilaterally (Fig. 11). The ERG was profoundly abnormal, with only a tiny, delayed response remaining to 30 Hz flicker (Fig. 9). The initial diagnosis was retinitis pigmentosa. Six months later, although her acuity

remained unchanged, side vision and night vision were worse and she began to experience difficulty with her school work that was felt not to be explained by her defective acuity. At age 8.7 years her acuity was 20/40, J3 right eye and 20/80, J5 left eye; a conjunctival biopsy was performed, which was initially read as normal. At 8.9 years her visual acuity dropped to light perception in each eye and she began to learn Braille in school. Because of cognitive difficulties in school the previous conjunctival biopsy was re-examined with additional sections that revealed fingerprint inclusions consistent with JNCL. Molecular testing disclosed the presence of the common 1.02 kb deletion of *CLN3*.[35]

Discussion

The class of disorders known as neuronal ceroid lipofuscinoses is the most common neurodegenerative disorder to affect children, with a collective incidence of about 1 in 12 500 live births world-wide.[36] INCL has an incidence of 1 in 13 000 to 20 000 in Finland, 1 in 50 000 in Scandinavia, and 1 in 100 000 world-wide.[3,37] LINCL has a frequency of 0.46 per 100 000 in Germany.[38] JNCL has an incidence of 1 in 21 000 in Finland and a frequency of 0.71 per 100 000 in Germany.[38]

All of the forms of NCL show accumulation within lysosomes in neurons and other cells of storage material that is autofluorescent, sudanophilic and PAS-positive. Because of its osmophilic nature and appearance on light microscopy, the storage material resembles ceroid and lipofuscin, but it is in actuality a complex mixture of lipoproteins and other hydrophobic peptides. The lipoprotein deposits take on characteristic patterns within cells on electron microscopy that are used for diagnosis and classification: (1) granular inclusions are seen in INCL, Kufs disease, and some variants forms of JNCL, (2) curvilinear inclusions predominate in LINCL (with occasional to rare fingerprint inclusion), and (3) fingerprint inclusions are seen in JNCL (with occasional to rare curvilinear inclusions).[26,27]

The defective gene for INCL, *CLN1*, is palmitoyl-protein thioesterase, an enzyme that removes long-chain fatty acids, mostly palmitate residues, from *S*-acylated proteins. As such, this enzyme is necessary for the reversible palmitoylation–depalmitoylation cycles used by signal transport proteins.[39,40] The storage material in INCL includes saposins A and D, sphingolipid activator proteins necessary for the degradation of sphingolipids by lysosomal hydrolases, and various *S*-acylated peptides.[41,42] The most common mutation is Arg122Trp, which accounts for 98% of disease chromosomes in Finland and 75% of disease chromosomes worldwide.[39]

The gene for LINCL, *CLN2*, encodes a pepstatin-insensitive lysosomal peptidase that may either participate in the degradation of mitochondrial peptides or be needed for processing of neuron-specific trophic factors.[43] The storage material that accumulates in LINCL includes sphingolipid activator proteins[44] but is mostly composed of subunit *c* of mitochondrial ATP synthase, the latter by a defect in degradation,[45–47] suggesting that subunit *c* may be a substrate for the deficient enzyme.

The gene for JNCL, *CLN3*, has been cloned and mutations defined, although the function of the gene is undefined.[48–50] The most frequent mutation for JNCL is a 1.02 kb deletion that is present in 90% of abnormal chromosomes in Finland and in 81% of abnormal chromosomes in patients world-wide.[35] One study reported that 180 of 188 (96%) patients with JNCL from 16 countries had the 1.02 kb deletion on at least one chromosome; a total of 23 disease-associated mutations, including missense, nonsense, splice-site, insertions and deletions, were found.[50] Patients with JNCL also accumulate subunit *c* of mitochondrial ATP synthase.[46,47] One proposed function for the *CLN3* gene product is that it acts as a chaperone necessary for the normal folding/unfolding or assembly/disassembly of subunit *c* of mitochondrial ATP synthase.[51–53] The gene product of *CLN3* localises to mitochondria of Müller cells and inner retinal neuron mitochondria and to the mitochondria of inner segments of photoreceptors but not the outer segments.[54]

The ERG studies in the three classical forms of NCL were abnormal early in the course of the disease. The normal scotopic a-wave with profoundly subnormal b-wave to the 0.6 log cd-s/m^2 stimulus for the patient with INCL indicates that the earliest manifestation of this disease does not affect the response of the photoreceptor outer segment (i.e. phototransduction), but instead affects the proximal functions of the photoreceptors or otherwise disturbs the generators of the b-wave. Because of the role that PPT plays in signal transport, a possible pathogenetic mechanism includes disturbance of pre- or post-synaptic neurotransmission of the signal from proximal photoreceptors to the second-order neuron, the bipolar cells of the retina.

The ERGs of the patients with LINCL were different in showing normal (or near normal) rod amplitudes but prolonged rod implicit times and severely subnormal, prolonged cone responses. Patients with more advanced stages of LINCL had greater subnormality of the b-wave than the a-wave, although both were abnormal, suggesting loss of functional outer segments. Unlike the ERG in either INCL or in JNCL, the rod responses in early LINCL were, at most, only mildly subnormal and prolonged but much more preserved in amplitude even though at this stage the cone responses were severely subnormal and prolonged.

The patients with JNCL had an ERG phenotype that was different again, with essentially no discernible rod responses and severely subnormal cone responses that for one case (case 5) were normal in implicit times but for the other patients were prolonged. The scotopic a-wave was subnormal, indicating loss of effective outer segments, but the b-wave was even more subnormal, creating an electronegative configuration. OPs were profoundly subnormal. The greater disturbance of the b-wave than that of the a-wave for patients with JNCL is consistent with the intraretinal localisation of the gene

product for *CLN3* to mitochondria of Müller cells and inner retinal neuron mitochondria and to the mitochondria of inner segments of photoreceptors.[54]

References

1. Goebel HH. The neuronal ceroid-lipofuscinoses. Semin Pediatr Neurol 1996;3:270–8.
2. Santavuori P, Haltia M, Rapola J, Raitta C. Infantile type of so-called neuronal ceroid-lipofuscinosis. J Neurol Sci 1973;18:257–67.
3. Santavuori P, Vanhanen S-L, Sainio K, Nieminen M, Wallden T, Launes J, *et al*. Infantile neuronal ceroid-lipofuscinosis (INCL): diagnostic criteria. J Inherit Metab Dis 1993;16:227–9.
4. Jansky J. Sur un cas jusqu'à présent non décrit d'idiotie amaurotique familiale compliqué par une hypoplasie du cervelet. Sb Ved Pr Lek Fak Karlovy 1908;9:165–96.
5. Bielschowsky M. Über spät-infantile familiäre amaurotische Idiote mit Kleinhirnsymptomen. Dtsch Z Nervenheilkd 1913;50:7–29.
6. Pampiglione G, Harden A. So-called neuronal ceroid lipofuscinosis: neurophysiological studies in 60 children. J Neurol Neurosurg Psychiatry 1977;40:323–30.
7. Goebel HH, Gerhard L, Kominami E, Haltia M. Neuronal ceroid-lipofuscinosis – late-infantile or Jansky–Bielschowsky type – revisited. Brain Pathol 1996;6:225–8.
8. Zeman W, Donahue S, Dyken P, Green J. The neuronal ceroid-lipofuscinosis (Batten–Vogt syndrome). In: Vinken PJ, Bruyn GW, editors. Handbook of clinical neurology. Amsterdam: North-Holland, 1970:588–679.
9. Weleber RG. Retinitis pigmentosa and allied disorders. In: Ryan SJ, editor. Retina, vol 1. 2nd ed. St Louis, CV Mosby–Year Book, 1994:335–466.
10. Kufs H. Über einen Fall von spätester Form der amaurotischen Idiotie mit dem Beginn im 42 und Tod im 59 Lebens-jahre in klinischer, histologischer und Vererbungs-pathologischer Beziehung. Z Ges Neurol 1931;137:432–48.
11. Dom R, Brucher JM, Ceuterick C, Carton H, Martin JJ. Adult ceroid-lipofuscinosis (Kufs' disease) in two brothers: retinal and visceral storage in one; diagnostic muscle biopsy in the other. Acta Neuropathol 1979;45:67–72.
12. Boehme DH, Cottrell JC, Leonberg SC, Zeman W. A dominant form of neuronal ceroid-lipofuscinosis. Brain 1971;94:745–56.
13. Dyken P, Wisniewski K. Classification of the neuronal ceroid-lipofuscinoses: expansion of the atypical forms. Am J Med Genet 1995;57:150–4.
14. Dawson WW, Armstrong D, Greer M, Maida TM, Samuelson DA. Disease-specific electrophysiological findings in adult ceroid-lipofuscinosis (Kufs disease). Doc Ophthalmol 1985;60:163–71.
15. Copenhaver RM, Goodman G. The electroretinogram in infantile, late infantile, and juvenile amaurotic idiocy. Arch Ophthalmol 1960;63:203–10.
16. Pinckers A, Bolmers D. Neuronal ceroid lipofuscinosis (ERG et EOG). Ann Oculist (Paris) 1974;207:523–9.
17. Goebel HH, Zeman W, Damaske E. An ultrastructural study of the retina in the Jansky-Bielschowsky type of neuronal ceroid-lipofuscinosis. Am J Ophthalmol 1977;83:70–9.
18. Wachtmeister L. Clinical and electrophysiological findings in an early case of juvenile neuronal ceroid lipofuscinosis treated with selenium. Doc Ophthalmol Proc Ser 1982;31:209–15.
19. Herrick MK, Forno LS, Egbert PR, Urich H. Leber's congenital amaurosis as a manifestation of infantile ceroid lipofuscinosis (Haltia–Santavuori type). Neuro-ophthalmology 1984;4:151–63.
20. Goebel HH, Klein H, Santavuori P, Sainio K. Ultrastructural studies of the retina in infantile neuronal ceroid-lipofuscinosis. Retina 1988;8:59–67.
21. Gottlob I, Goebel HH, Kohlschütter A, Leipert KP, Eckl G. Ophthalmologische, elektrophysiologische und histologische Befunde bei neuronaler Ceroidlipofuscinose (NCL). Spektrum Augenheilkd 1988;2:64–70.
22. Gottlob I, Leipert KP, Kohlschütter A, Goebel HH. Electrophysiological findings of neuronal ceroid lipofuscinosis in heterozygotes. Graefes Arch Clin Exp Ophthalmol 1988;226:516–21.
23. Gottlob I. Neuronal ceroid lipofuscinosis. In: Heckenlively JR, Arden GB, editors. Principles and practice of clinical electrophysiology of vision. St Louis: Mosby-Year Book, 1991:786–92.
24. Marmor MF, Arden GB, Nilsson SEG, Zrenner E, for the Standardisation Committee of the International Society for Clinical Electrophysiology of Vision (ISCEV). Standard for clinical electroretinography. Arch Ophthalmol 1989;107:816–9.
25. Marmor MF, Zrenner E, for the Standardisation Committee of the International Society for Clinical Electrophysiology of Vision (ISCEV). Standard for clinical electroretinography (1994 update). Doc Ophthalmol 1995;89:199–210.
26. Libert J. Diagnosis of lysosomal storage diseases by the ultrastructural study of conjunctival biopsies. Pathol Annu 1980;15:37–66.
27. Arsenio-Nunes ML, Goutières F, Aicardi J. An ultramicroscopic study of skin and conjunctival biopsies in chronic neurological disorders of childhood. Ann Neurol 1981;9:163–73.
28. Carpenter S. Morphological diagnosis and misdiagnosis in Batten–Kufs disease. Am J Med Genet [Suppl] 1988;5:85–91.
29. Weleber RG. The effect of age on human cone and rod Ganzfeld electroretinograms. Invest Ophthalmol Vis Sci 1981;20:392–9.
30. Weleber RG, Tongue AT. Congenital stationary night blindness presenting as Leber's congenital amaurosis. Arch Ophthalmol 1987;105:360–5.
31. Weleber RG, Eisner A. Retinal function and physiological studies. In: Newsome DA, editor. Retinal dystrophies and degenerations. New York: Raven Press, 1988:21–69.
32. Severns ML, Johnson MA, Merritt SA. Automated estimation of implicit time and amplitude from the flicker electroretinogram. Appl Optics 1991;30:2106–12.
33. MacLeod PM, Dolman CL, Nickel RE, Chang E, Zonana Z, Silvey K. Prenatal diagnosis of neuronal ceroid-lipofuscinosis. N Engl J Med 1984;310:594–6.
34. MacLeod PM, Dolman CL, Nickel RE, Chang E, Zonana Z, *et al*. Prenatal diagnosis of neuronal ceroid-lipofuscinosis. Am J Med Genet 1985;22:781–9.
35. Järvelä I, Mitchison HM, Munroe PB, O'Rawe AM, Mole SE, Syvänen A-C. Rapid diagnostic test for the major mutation underlying Batten disease. J Med Genet 1996;33:1041–2.
36. Rider JA, Rider DL. Batten disease: past, present and future. Am J Med Genet [Suppl] 1988;5:21–6.
37. Jongen PJH, Gabreëls FJM, Schuurmans Stekhoven JH, Renier WO, le Coultre R, Begeer JH. Early infantile form of neuronal ceroid lipofuscinosis. Clin Neurol Neurosurg 1987;89:161–7.
38. Claussen M, Heim P, Knispel J, Goebel HH, Kohlschütter A. Incidence of neuronal ceroid-lipofuscinoses in West Germany: variation of a method for studying autosomal recessive disorders. Am J Med Genet 1992;42:536–8.
39. Vesa J, Hellsten E, Verkruyse LA, Camp LA, Rapola J, Santavuori P, *et al*. Mutations in the palmitoyl protein thioesterase gene causing infantile neuronal ceroid lipofuscinosis. Nature 1995;376:584–8.
40. Schriner JE, Yi W, Hofmann SL. cDNA and genomic cloning of the human palmitoyl-protein thioesterase (PPT), the enzyme defective in infantile neuronal ceroid lipofuscinosis. Genomics 1996;34:317–22.

41. Tyynelä J, Palmer DN, Baumann M, Haltia M. Storage of saposins A and D in infantile neuronal ceroid lipofuscinosis. FEBS Lett 1993;330:8–12.
42. Lu J-Y, Verkruyse LA, Hofmann SL. Lipid thioesters derived from acylated proteins accumulate in infantile neuronal ceroid lipofuscinosis: correction of the defect in lymphoblasts by recombinant palmitoyl-protein thioesterase. Proc Natl Acad Sci USA 1996;93:10046–50.
43. Sleat DE, Donnelly RJ, Lackland H, Liu C-G, Sohar I, Pullarkat RK, *et al*. Association of mutations in a lysosomal protein with classical late-infantile neuronal ceroid lipofuscinosis. Science 1997;277:1802–5.
44. Tyynelä, Baumann M, Henseler M, Sandhoff K, Hultia M. Sphingolipid activator proteins in the neuronal ceroid-lipofuscinoses: an immunological study. Acta Neuropathol 1995;89:391–8.
45. Ezaki J, Wolfe JS, Higuti T, Ishidoh K, Kominami E. Specific delay of degradation of mitochondrial ATP synthase subunit *c* in late infantile ceroid lipofuscinosis (Batten disease). J Neurochem 1995;64:733–41.
46. Ezaki J, Wolfe LS, Ishidoh K, Muno D, Ueno T, Kominami E. Lysosomal proteinosis based on decreased degradation of a specific protein, mitochondrial ATP synthase subunit *c*. Adv Med Biol 1996;389:121–8.
47. Dawson G, Kilkus J, Siakotos AN, Singh I. Mitochondrial abnormalities in CLN2 and CLN3 forms of Batten disease. Mol Chem Neuropathol 1996;29:227–35.
48. The International Batten Disease Consortium. Isolation of a novel gene underlying Batten disease, *CLN3*. Cell 1995;82:949–57.
49. Mitchison HM, Munroe PB, O'Rawe AM, Taschner PEM, de Vos N, Kremmidiotis G, *et al*. Genomic structure and complete nucleotide sequence of the Batten disease gene, *CLN3*. Genomics 1997;40:346–50.
50. Munroe PB, Mitchison HM, O'Rawe AM, Anderson JW, Boustany R-M, Lerner TJ, *et al*. Spectrum of mutations in the Batten disease gene, *CLN3*. Am J Hum Genet 1997;61:310–6.
51. Janes RW, Munroe PB, Mitchison HM, Gardiner RM, Mole SE, Wallace BA. A model for Batten disease protein CLN3: functional implications from homology and mutations. FEBS Lett 1996;399:75–7.
52. Lane SC, Jolly RD, Schmechel DE, Alroy J, Boustany R-M. Apoptosis as the mechanism of neurodegeneration in Batten's disease. J Neurochem 1996;67:677–83.
53. Tanner AJ, Dice JF. Minireview: Batten disease and mitochondrial pathways of proteolysis. Biochem Mol Med 1996;57:1–9.
54. Katz ML, Gao C-L, Prabhakaram M, Shibuya H, Liu P-C, Johnson GS. Immunochemical localisation of the Batten disease (CLN3) protein in retina. Invest Ophthalmol Vis Sci 1997;38:2375–86.