Eye (1990) **4**, 190–194

Visual Performance in Idiopathic Macular Holes

R. G. SMITH, S. J. HARDMAN LEA, N. R. GALLOWAY
Nottingham

Summary
Previously published reports on the clinical features of idiopathic macular holes highlight the predilection for post-menopausal women and implicate vitreomacular traction in the aetiology of these lesions. Relatively little attention, however, has been paid to the quality of visual loss in eyes with macular holes. Histological studies of full-thickness macular holes have shown loss of all retinal layers in the area of the hole, and this would be expected to produce a central absolute scotoma of the same diameter. The majority of patients with full-thickness holes in this series did not have an absolute scotoma large enough to be detected on the Amsler Chart or when reading. It is suggested that following formation of a macular hole, enlargement may occur without further loss of foveal tissue and without enlargement of the absolute scotoma, due to tangential vitreous traction or contraction of an associated epiretinal membrane.

Since the first detailed description of a macular hole by Noyes in 1871[1] much has been written about the pathogenesis, histopathology, clinical features, and course of these lesions. Although visual acuity is documented as a matter of course in all such studies, relatively little attention has been paid to the quality of visual disturbance experienced by patients with macular holes.

The cardinal symptoms of macular disease are positive scotoma, metamorphopsia, micropsia and macropsia.[2] From detailed histological descriptions of macular holes,[3,4] a full-thickness hole would be expected to give rise to an absolute scotoma, surrounded by an area of metamorphopsia (especially where there is an associated serous retinal detachment). With lamellar holes, disruption is confined to the inner retinal layers[4] and is less likely to give rise to an absolute scotoma.

While we were examining a group of patients with idiopathic macular holes as part of a separate study, it was noticed that in no case was positive scotoma a presenting symptom, the most consistent complaint being that objects appeared distorted or fragmented. We present the results of the clinical assessment of these patients, particularly with regard to the type and severity of central vision disturbance.

Subjects and Method

Twenty eight patients (24 female, four male) with age range 60–81 years (mean 69.9) with 32 idiopathic macular holes were recruited from outpatient clinics at the Queen's Medical Centre. The lesions had been present for between three weeks and eleven years (Table 1) and presenting complaints included metamorphopsia (14 eyes), reduced vision (12 eyes) and difficulty reading (three eyes). Three holes were discovered incidentally by

From: Department of Ophthalmology, The Queen's Medical Centre, Nottingham.

Correspondence to: Mr R. G. Smith, FRCS FCOphth, Department of Ophthalmology, The Queen's Medical Centre, Nottingham NG7 2UH.

Table I *Duration of Macular Holes (32 eyes)*

Duration	*Number*
0–2 months	4
3–6 months	2
7–12 months	7
1–5 years	11
>5 years	6
Unknown	2

Length of time from onset of symptoms to assessment for this study.

optometrists or ophthalmologists. All eyes with macular holes were otherwise healthy and had no history of previous disease, surgery or significant trauma.

A full medical history was taken and clinical examination included refraction, measurement of best corrected visual acuity at 6 m and at 0.3 m with a +3.00 dioptre addition, central visual field assessment (Amsler No. 1 Chart, Hamblin, London), slit lamp biomicroscopy and fundus photography. Amsler Chart examinations were carried out according to the method recommended by Amsler[5] with a working distance of 0.3 m and the same spectacle correction as used to test reading acuity. Fundus examinations were carried out using a Goldmann three mirror contact lens or a +90 dioptre double aspheric lens. Macular hole diameters were measured with the scale on the slit lamp (Haag Streit 900) and also with a graticule on the fundus photographs. In both cases, the measurement was made in comparison with the vertical diameter of the optic disc, assuming this to be 1.75 ± 0.19 mm,[6] the optic discs being morphologically normal in all cases.

The distinction between full-thickness and lamellar holes was made on the biomicroscopic criteria of Gass.[4] No difficulties were encountered in making this distinction and routine fluorescein angiography was not felt to be necessary.

All clinical assessments were carried out by two of the authors (R.S. and S.H.-L.).

Results

Of the 32 macular holes, 26 were classified as full thickness and six lamellar. Of the four patients with bilateral holes, one had bilateral lamellar holes, one had bilateral full-thickness holes and two had a full-thickness hole in one eye with a lamellar hole in the fellow eye.

Distance visual acuity in eyes with full-thickness holes ranged from 0.03 (2/60) to 0.25 (6/24) with a mean of 0.13, and in eyes with lamellar holes ranged from 0.33 (6/18) to 1.20 (6/5) with a mean of 0.57. The difference in visual acuity for the two types of macular hole is significant at $p<0.001$ (Student's t-test performed on the logarithm of the Snellen fractions).

Near visual acuities (Standard reading test types, Keeler, England) were converted to Snellen equivalents by measuring the height of lower case letters without ascenders and descenders and calculating the angle subtended at the eye at a distance of 0.3 m. When expressed as Snellen equivalents, visual acuities at 0.3 m accorded closely with those recorded at 6 m for all patients.

Refractive errors of the macular hole eyes and fellow eyes showed a small tendency toward hypermetropia but were not significantly different from a group of 119 control eyes with 6/12 or better vision (Age range 50–80, mean 63) taken from a local optometric practice (Fig. 1).

An absolute scotoma was detected on the Amsler Chart in eight eyes with full-thickness holes. Because there was associated metamorphopsia in all cases, the scotoma was sometimes difficult to delineate, but appeared to be less than 3° in diameter in all cases. Sixteen eyes with full-thickness holes and five eyes with lamellar holes detected only central distortion on the Amsler Chart. Two patients were unable to understand the test and one patient with a lamellar hole perceived no distortion.

Complete posterior vitreous detachment (PVD) appeared to be present in 15 eyes (58%) with full-thickness holes and five eyes (85%) with lamellar holes. Partial PVD was present in two eyes (8%) with full-thickness holes. One eye with a lamellar hole showed partial PVD with vitreous traction to an elevated flap of foveal tissue. Surprisingly the patient was unaware of any metamorphopsia. Nine eyes, all with full-thickness holes had no evidence of PVD on biomicroscopy.

Diameters of full-thickness holes ranged from 0.35–0.9 mm (mean 0.57, SD 0.13 mm)

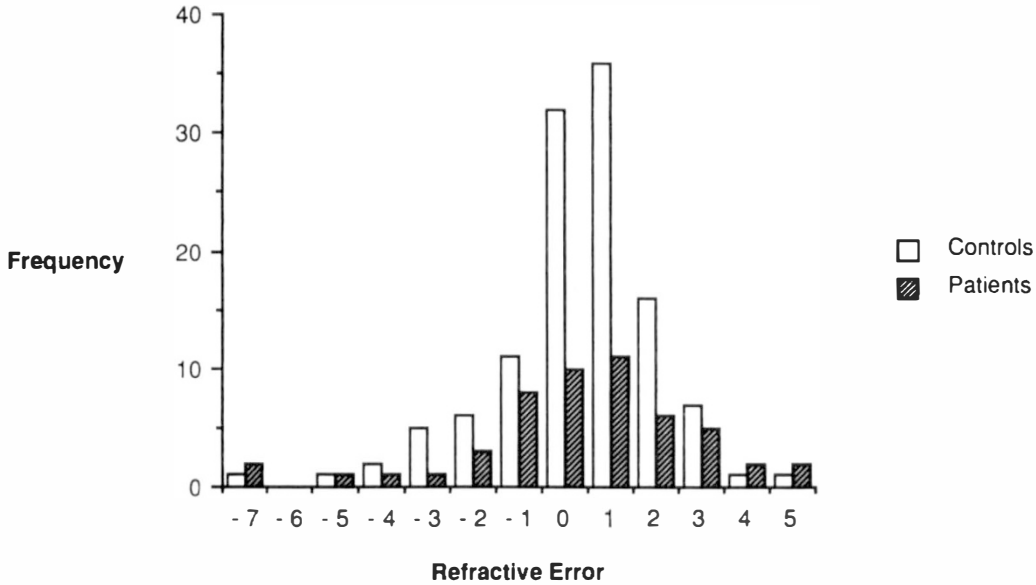

Fig. 1. *Mean spherical equivalent refractive errors for eyes with macular holes and fellow eyes (52 eyes) compared with 119 eyes with 6/12 or better vision taken from records from a local optometric practice. The difference between the two groups is not statistically significant.*

and diameters of lamellar holes ranged from 0.35–0.7 mm (mean 0.48, SD 0.15 mm). The difference between the groups was not significant.

There was no correlation between macular hole diameter and visual acuity, nor between macular hole diameter and the presence or absence of an absolute scotoma. However, macular hole diameter showed a significant correlation with the time since the onset of symptoms ($p<0.001$, Kendall rank correlation coefficient 0.495). A localised serous retinal detachment was present in 21 eyes (81%) with full-thickness holes, with a mean diameter of 1.19 mm (SD 0.4 mm).

An operculum was visible in three eyes (11.5%) with full-thickness holes. However, none of these could detect an absolute scotoma on the Amsler Chart.

A number of patients were being treated for other medical conditions, the commonest being hypertension (Table II). As far as is known, none of the female patients had undergone hysterectomy or had taken hormone replacement therapy.

Discussion

A number of recent reports have highlighted the clinical features of macular holes.[4,7-10] The condition has consistently shown a predilection for post-menopausal women (86% of patients in this series and 70–77% in the series cited above). Although vitreomacular traction is strongly implicated in the aetiology of macular holes, the association with posterior vitreous detachment (PVD) is less clear. The incidence of PVD in previously reported series varies from 40% to 100%,[7–10] but not all reports make a distinction between partial and complete separation of the posterior hyaloid. Trempe *et al.*[10] found that complete PVD in fellow eyes protected against subsequent development of macular holes and they observed some cases with vitreous traction to

Table II *Associated Medical Problems (28 patients)*

Disease	*Number*
Hypertension	9
Ischaemic Heart Disease	5
Hypercholesterolaemia	2
Cerebrovascular Disease	1
Diabetes Mellitus	2

Of the 28 patients with macular holes, a number were receiving treatment for the medical conditions shown above.

the margin of the hole, similar to one case in our series. They concluded that vitreomacular adhesion, combined with intravitreal traction or the process of posterior vitreous separation was responsible for macular hole formation. Gass[11] has suggested that tangential traction from the posterior vitreous surface may also be an aetiological factor. It may be that tangential traction forces are important in those cases where there is no evidence of PVD (28% of eyes in this series).

Morgan and Schatz[9] reported a close correlation between macular hole diameter and visual acuity at the initial assessment (61% were assessed within a year of onset of symptoms), but noted that the diameter of holes tended to increase during a period of follow-up, though visual acuity remained stable. The lack of correlation between macular hole diameter and visual acuity in this series is likely to be due to the fact that 53% of holes had been present for more than 12 months and 19% for more than five years. This is also reflected in the strong correlation between duration of symptoms and hole diameter.

It has been noted previously that central scotoma is rarely a presenting symptom of macular holes.[9] Mitra[12] detected absolute scotomas of up to 2.5° by means of contrast sensitivity gratings in all of a group of ten patients with full-thickness macular holes. However, 50% of these measured 1° or less. No details of the diameter of the holes were given. It is likely that a number of our patients with full-thickness holes failed to recognise an absolute scotoma on the Amsler Chart because their scotoma was 1° in diameter or less (ie less than one square on the chart). Accurate plotting of small central scotomas is a problem whichever method is used because of the difficulty of maintaining fixation. Our patients could usually say with confidence whether any lines on the Amsler Chart were missing or not, but found it difficult to count how many lines or squares were missing. For this reason, it was only possible to measure the size of an absolute scotoma approximately.

If the size of the absolute scotoma corresponded exactly with the diameter of the macular hole, a hole of 0.5 mm diameter would result in an absolute scotoma of 1.8° and a 0.75 mm hole would give a 2.8° scotoma.

The loss of foveal tissue in the development of a full-thickness hole presumably occurs by avulsion of an operculum during detachment of the posterior vitreous face, or secondary to degenerative changes in the fovea.[13] If, as Gass suggests, tangential traction from the posterior vitreous may contribute to the development of macular holes, this might provide a basis for enlargement of the hole without further loss of retinal tissue. Smiddy *et al.*[13] have found during vitrectomy for 'impending macular hole' that a thin layer of cortical vitreous may remain adherent to the macula despite apparently complete posterior vitreous detachment on biomicroscopy. Gass[4] has also shown that lamellar holes may be associated with a cellular epiretinal membrane which contracts, throwing the retinal surface adjacent to the hole into small folds.

If a macular hole enlarges through 'centrifugal' traction on it's margins, whether due to vitreous attachments or an epiretinal membrane, but without any further loss of foveal tissue, the enlargement would occur without an increase in the size of an associated absolute scotoma. The low incidence of a detectable scotoma in the eyes with full thickness holes in this series could be explained on this basis.

In conclusion, the clinical findings in this series of eyes with idiopathic macular holes are in broad agreement with those of previously published series, but we draw attention to the unexpectedly low incidence of central absolute scotomas in eyes with full-thickness holes and suggest that this may be due to enlargement of the hole without tissue loss by tangential traction on it's margins.

References

1 Noyes HD: Detachment of the retina, with laceration at the macula lutea. *Tr Am Ophthalmol Soc* 1871, **1:** 128.

2 Kanski JJ: Clinical Ophthalmology. Butterworths, 1984, **12:** 3.

3 Kornzweig AL and Feldstein M: Studies of the eye in old age. *Am J Ophthalmol* 1950, **33:** 243–7.

4 Gass JDM: Lamellar macular hole, a complication of cystoid macular edema after cataract extraction. *Arch Ophthalmol* 1976, **94:** 793–800.

5 Amsler M: Earliest symptoms of disease of the macula. *Br J Ophthalmol* 1953, **37:** 521–37.

6 Straatsma BR, Foos RY, Spencer LM: The retina: topography and clinical correlations. Symposium on retina and retinal surgery. *Trans New Orleans Acad Ophthalmol* Mosby, St.Louis. 1969, 1–26.

[7] Aaberg TM, Blair CJ, Gass JDM: Macular holes. *Am J Ophthalmol* 1970, **69:** 555–62.
[8] McDonnell PJ, Fine SL, Hillis AI: Clinical features of idiopathic macular cysts and holes. *Am J Ophthalmol* 1982, **93:** 777–86.
[9] Morgan CM and Schatz H: Idiopathic Macular Holes. *Am J Ophthalmol* 1985, **99:** 437–44.
[10] Trempe CL, Weiter JJ, Furukawa H: Fellow eyes in cases of macular hole. Biomicroscopic study of the vitreous. *Arch Ophthalmol* 1986, **104:** 93–5.
[11] Gass JDM: Macular dysfunction caused by vitreous and vitreoretinal interface abnormality. Vitreous traction maculopathies. Stereoscopic Atlas of Macular Disease. St Louis, CV Mosby Co. 1987, 676–93.
[12] Mitra S: Spatial contrast sensitivity in macular disorder. *Doc Ophthalmol* 1985, **59:** 247–67.
[13] Smiddy WE, Michels RG, Glaser BM, de Bustros S: Vitrectomy for impending idiopathic macular holes. *Am J Ophthalmol* 1988, **105:** 371–6.